

REVIEW ARTICLE

# 3-Nitropropionic Acid - Exogenous Animal Neurotoxin and Possible Human Striatal Toxin

A.C. Ludolph, F. He, P.S. Spencer, J. Hammerstad and M. Sabri

**ABSTRACT:** 3-Nitropropionic acid (3-NPA) — a suicide inhibitor of succinate dehydrogenase — is a widely distributed plant and fungal neurotoxin known to induce damage to basal ganglia, hippocampus, spinal tracts and peripheral nerves in animals. Recent reports from Northern China indicate that 3-NPA is also likely to be responsible for the development of putaminal necrosis with delayed dystonia in children after ingestion of mildewed sugar cane. This article discusses the role of 3-NPA in the causation of the disease in China, its neurotoxic effects in animals and the potential role for this compound as a probe of selective neuronal vulnerability.

**RÉSUMÉ:** L'acide trinitropropionique — une neurotoxine exogène animale et possiblement une toxine striatale humaine L'acide trinitropropionique (ATNP), un inhibiteur suicide de la succinate-déshydrogénase et une neurotoxine très répandue dans les plantes et les champignons, est reconnue comme provoquant des dommages aux ganglions de la base, à l'hippocampe, aux faisceaux spinaux et aux nerfs périphériques chez les animaux. Des communications récentes provenant du nord de la Chine indiquent qu'il est possible que l'ATNP soit également responsable du développement d'une nécrose du putamen avec dystonie retardée chez les enfants qui ingèrent de la canne à sucre moisie. Nous discutons du rôle de l'ATNP dans l'étiologie de la maladie en Chine, de ses effets neurotoxiques chez l'animal et du rôle potentiel de ce composé dans l'exploration de la vulnérabilité neuronale sélective.

*Can. J. Neurol. Sci. 1991; 18: 492-498*

Although dystonias may be secondary or symptomatic,<sup>1</sup> the etiopathogenesis of the majority of dystonic syndromes is unknown and may have genetic and environmental components. Toxic models of neurological diseases may provide insight into mechanisms of nerve cell degeneration.<sup>2,3</sup> This review (a) focuses on the potential role of an abundant plant and fungal toxin (3-nitropropionic acid, 3-NPA) in the causation of an encephalopathy with a delayed onset dystonia observed in Northern China, (b) compares the chemical-induced human disease with the neurological picture in animals treated with 3-NPA, (c) summarizes the pharmacological effects of 3-NPA, and (d) compares the toxicological properties of this compound with those of other biochemical agents with a similar target site in the central nervous system. We propose that 3-NPA is a useful compound to probe selective neuronal vulnerability in the extrapyramidal system, to explore the etiopathogenesis of hyperkinetic movement disorders, and to provide insights into possible therapeutic approaches.

## THE FUNGAL TOXIN — A LINK TO HUMAN DISEASES?

### Epidemiology and Clinical Picture of Mildewed Sugar Cane Poisoning

In recent years, Chinese authors have reported<sup>4-6</sup> that ingestion of sugar cane contaminated with the fungus *Arthrinium* is responsible for the development of an acute encephalopathy in children. This leads to bilateral symmetric necrosis of the basal ganglia and, in a varying number of individuals, to the development of irreversible generalized dystonia. The aliphatic nitro-compound 3-NPA, an inhibitor of the Krebs cycle enzyme succinate dehydrogenase (SDH), is the principal candidate for the causation of the encephalopathy and its tardive effects.<sup>4-6</sup>

Sugar cane is harvested in Southern China in Autumn (October), shipped to Northern China, stored, and frequently consumed in January and February around the Chinese New

From the Center for Research on Occupational and Environmental Toxicology, Portland, Oregon (A.C.L., P.S.S., M.S.); the Department of Neurology, School of Medicine, Oregon Health Sciences University, Portland, Oregon (A.C.L., P.S.S., J.H., M.S.); Institute of Occupational Medicine, Chinese Academy of Preventive Medicine, Beijing, People's Republic of China (F.H.).

Received January 17, 1991. Accepted in final form April 25, 1991

Reprint requests to: Dr. A.C. Ludolph, Center for Research on Occupational and Environmental Toxicology, Oregon Health Sciences University, 3181 S.W. Sam Jackson Park Road, Portland, Oregon, U.S.A. 97201

Year's Day. Storage in damp conditions promotes fungal growth ("mildew") within the body of the cane. Sugar cane is sold informally at the side of the road and purchased by children and adults alike. Adults who consume mildewed sugar cane may develop gastrointestinal symptoms but rarely disorders of the central nervous system. Children, however, may show signs of a severe encephalopathy. It is unclear whether the age distribution is due to eating habits (dosage) or related to an increased susceptibility of children. The "oldest patient" with an encephalopathy was 27 years old. Reportedly, more than 884 cases of encephalopathy after intoxication with contaminated sugar cane occurred in China from 1972-1989.<sup>4-6</sup> Eighty-eight individuals died from the intoxication.<sup>4-6</sup>

The stereotyped clinical course of the *acute* intoxication<sup>4-6</sup> is characterized by a sudden onset of gastrointestinal disturbances (nausea, vomiting, abdominal pain, and diarrhea) 2-3 hours after ingestion. Headache and dizziness sometimes precede these symptoms. Signs of infectious diseases (like fever and nuchal rigidity) are absent, and white blood cell counts and cerebrospinal fluid are unremarkable. Somnolence develops in many patients and is accompanied by visual and visuomotor deficits including double vision, forced upward gaze, conjugation of eyes to either side, and horizontal or vertical nystagmus. Abdominal and cremasteric reflexes are diminished and Babinski's sign is present. Within 3-18 hours after the initial symptoms, the majority of patients develop coma and convulsions (sometimes leading to status epilepticus). Opisthotonus and decerebrate rigidity are observed. Patients become comatose for a maximum of 20 days. After regaining consciousness, they are often unable to speak or to move voluntarily, and they display urinary and fecal incontinence. Neuro-ophthalmological examination occasionally shows sluggish pupillary reflexes, dilatation and tortuosity of retinal veins, and obscured edges of optic discs. After symptomatic treatment, half of the subjects described by He and associates<sup>4,5</sup> recovered completely. In a follow-up study, neurological examination and evoked potentials studies were normal in most patients.

The *chronic* neurological picture (6 of 12 patients) is characterized by appearance of a monophasic, non-progressive ("self-limiting") delayed dystonia 11-6 days after intoxication or 7-40 days after regaining consciousness.<sup>4,5</sup> The clinical picture includes facial grimacing, sustained athetosis of hands and fingers, torsion spasms, spasmodic torticollis, painful spasmodic attacks in the extremities, and jerklike movements. Speech disturbances — and in the most severely affected anarthria — are also present. Intelligence cannot be readily assessed, but most patients appear alert and communicative. CT-scan consistently reveals bilateral hypodensities in the lenticular nuclei, mainly the putamen and to a lesser extent the globus pallidus. Occasionally, caudate nuclei and claustrum are affected and, in 3 patients, more diffuse cerebral atrophy was observed.<sup>4,5</sup> Visual evoked potentials were delayed in 2 patients with dystonia.

In conclusion, the epidemiological and clinical observations in China strongly suggest that the intake of mildewed sugar cane is associated with a non-inflammatory encephalopathy, basal ganglia lesions and, sometimes, a late-onset dystonic movement disorder. The frequency of development of a chronic extrapyramidal syndrome seems to vary; a range of 1.7% ("large outbreak") — to 50% (N = 12) is reported. We do not know whether factors like hypoxia, seizures, and status epilepticus play a role

in the development of basal ganglia damage. He and colleagues<sup>4,5</sup> consider a coma longer than 3 days as a risk factor for the development of extrapyramidal disorders.

### Possible Etiology of the Disease

Samples of mildewed sugar cane contain fungal mycelia.<sup>4-6</sup> *Arthrimum* is the predominant fungus (46.7-70%).<sup>7,8</sup> Juices from the sugar cane and *Arthrimum* cultures isolated from juice induce "paralysis in cats and mice" and paroxysmal convulsions in dogs when given *per os*.<sup>4-6</sup> 3-NPA has been isolated from the *Arthrimum* culture,<sup>7</sup> and the neurotoxic effects of the cultures and 3-NPA on experimental animals are similar.<sup>6,8</sup> Biochemical and morphological changes seen in the experimental animals have yet to be published in the Western literature and are awaited with interest. However, the available information makes it very likely that *Arthrimum spp.* and the neurotoxin 3-NPA are causally related to the disease.

### 3-NITROPROPIONIC ACID AS A PLANT TOXIN

In addition to being a mycotoxin, 3-NPA and its derivatives (aliphatic nitrocompounds) are found in several higher plants (Figure 1). The toxicity of these plants is well recognized, and aliphatic nitrocompounds frequently cause acute and chronic diseases in some domestic animals. In particular, *Astragalus spp.* (milk vetches, locoweeds, poison vetches) are responsible for major livestock losses in the Western United States from British Columbia to Mexico.<sup>9-11</sup> Plant nitrocompounds are found as glucose esters of 3-nitropropionic acid (NPA), and ether glucosides of 3-nitropropanol (NPOH).<sup>10-13</sup> The potential health impact of two additional, less abundant, primary nitrocompounds, 1-phenyl-2-nitroethane and 1-(4'-hydroxyphenyl)-2-nitroethane,<sup>11</sup> is unknown. Aliphatic nitrocompounds related to or derived from NPA occur primarily in: a) *Leguminosae*, primarily the genera *Astragalus*,<sup>14-18</sup> *Coronilla*,<sup>19,20</sup> *Indigofera*,<sup>21-24</sup> and *Lotus*.<sup>25</sup> b) *Malpiaghazeae* (*Hiptage spp.*, *Heteropteris spp.*, *Janusia spp.*),<sup>26,27</sup> and c) *Corynocarpaceae* (*Corynocarpus laevigatus* and *C. similis*).<sup>28</sup>

### METABOLISM AND METABOLIC EFFECTS OF 3-NITROPROPIONIC ACID

3-NPA irreversibly inhibits the Krebs cycle enzyme succinate dehydrogenase (SDH).<sup>29,30</sup> SDH, an enzyme of the mitochondrial membrane (part of Complex II), catalyzes the oxidation of succinate to fumarate. The precise mechanism of inhibition is unknown: the NPA nitronate may be a suicide

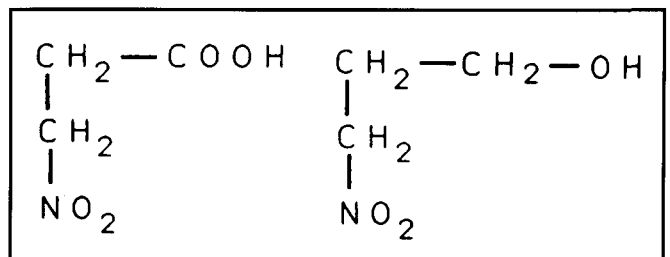


Figure 1 — Structure of 3-nitropropionic acid (left) and 3-nitropropanol (right). In plants, 3-NPOH occurs as ether glycoside whereas NPA conjugates are glucose esters.

inhibitor which irreversibly binds to the flavin component of DSH,<sup>29</sup> or the sulfhydryl group of SDH may attack 3-nitroacrylate, produced by oxidation of 3-NPA by flavin, and thereby affect enzyme inhibition.<sup>30</sup> 3-NPA also induces reversible inhibition of fumarase and aspartase (an enzyme not present in humans).<sup>31</sup> Schloss and Cleland described inhibition of the isocitrate lyase.<sup>32</sup> 3-NPA may also inhibit acetylcholinesterase in rat brain.<sup>33</sup>

After oral administration, the naturally occurring conjugates of the nitrocompounds are hydrolyzed in the gastrointestinal tract by an esterase (for 3-NPA) or by a  $\beta$ -glucosidase (for 3-NPOH). After absorption, 3-NPOH is irreversibly metabolized to 3-NPA, possibly by liver alcohol dehydrogenase.<sup>34</sup> Like other nitrocompounds, 3-NPA is metabolized by an amino-acid and glucose oxidase which results in the production of nitrites.<sup>35</sup> Nitrite induces oxidation of hemoglobin to methemoglobin, a biological effect that complicates the interpretation of the toxicity of the primary nitrocompounds and which can be reversed by methylene blue. Nitrite ions<sup>36</sup> have a direct effect on smooth muscle and dilate blood vessels. However, in the rat, 3-NPA reportedly induces arterial hypertonia not hypotonia.<sup>37</sup>

## ANIMAL DISEASES

### Uncontrolled Studies

Most descriptions of diseases occurring in domestic animals refer to poisoning by 3-NPA- or NPOH-containing *Astragalus spp.* in North America. The toxic effects of these plants must be distinguished from acute and chronic intoxication from (a) selenium-accumulating *Astragalus* and (b) locoweed poisoning caused by certain *Astragalus* species which contain swainsonine (8 $\alpha$ ,  $\beta$ -indolizidine-1 $\alpha$ , 2 $\alpha$ , 8 $\beta$  triol), the likely toxic principle.<sup>10</sup>

Aliphatic nitrocompounds induce *acute* and *chronic* effects on the nervous system of several species, including cattle, sheep, and horses.<sup>12</sup> The major signs of the *acute* syndrome (which leads to death within hours or days) are dyspnea, cyanosis, frequent urination, and muscular weakness or paralysis of the hindquarters.<sup>12,38</sup> James<sup>10,12</sup> described the picture of *chronic* intoxication ("roaring disease," "cracker heels," or "knocking disease") after "grazing of nitro-containing *Astragalus* at a much lower level than in acute poisoning and over an extended period of time." After small dosages of the toxin, a silent period of up to 21 days can be observed.<sup>10</sup> "The first signs of chronic intoxication in cattle are labored and rapid respiration." . . . "Other signs of intoxication include general body weakness, beginning in the pelvic limbs, knuckling of the fetlocks, goose stepping, and knocking together of the hind limbs when walking. As the disease progresses, there may be weakness of hindlimbs or even loss of control of this part of the body; the limbs may be dragged when the animal moves. Some indication of temporary blindness has been observed." Animals with advanced signs of intoxication rarely recover.<sup>10</sup>

### Controlled Studies

The toxicity of aliphatic nitrocompounds is greatly species-dependent.<sup>12,19,20,38,39</sup> Complicating the response is the tendency for 3-NPA and 3-NPOH to induce methemoglobinemia variably in different species. Chronic and acute toxicity must also be distinguished.

*Acute clinical signs* are similar in all species and include depressed food intake, posterior weakness and paralysis, stag-

gering gait, incoordination, sometimes temporary blindness (cattle), head extension, dyspnea, and terminal hyperpnea. *Chronic clinical signs* in cattle, sheep, meadow voles, and pigs<sup>10,12,20</sup> include posterior weakness, incoordination, knuckling of the fetlocks, stiffness of gait, interference of hind limbs when walking, and, sometimes in sheep, stiff front legs.

*Neuropathological findings in cattle and sheep* are described by James et al.<sup>12</sup> who conducted feeding trials of *Astragalus* species for periods from 1-98 days. Considerable inter-individual variability is seen. Findings include mild to moderate Wallerian degeneration in the spinal cord, "moderate spongy vacuolation in the white matter of the globus pallidum (N = 1)," and moderately severe Wallerian degeneration and loss of many nerve fibers in the sciatic nerve. Degeneration of Purkinje cells is observed in coyppu stocks consuming *Coronilla spp.* in experimental feeding trials in Hungary.<sup>40</sup>

### Controlled Studies in Laboratory Animals

*Mice* treated with a single or repeated i.p. injections of 120 mg/kg 3-NPA develop a "characteristic form of basal ganglia degeneration."<sup>41</sup> Initially, mice show depressed motor activity and are less responsive to external stimuli. Occasional episodes of hyperactivity and/or abnormal movements, such as tremors, head bobbing, head tilt, circling, tail rigidity and elevation, are observed. Later, more severe depression develops with intermittent periods of arousability and altered motor activity. No apparent seizures are seen. Gould and Gustine<sup>41</sup> monitored methemoglobinemia and showed this was unlikely to be responsible.

Large doses (120 mg/kg/d) of 3-NPA induce the following pattern of damage in the central nervous system of mice:

a) bilaterally symmetric lesions of the lateral aspect of the caudate-putamen, with marked swelling of (dendritic) processes; and cell bodies, with nuclear pyknosis and chromatin clumping;

b) postsynaptic lesions of the globus pallidus, the entopeduncular nucleus, and the pars reticulata of the anterior substantia nigra;

c) lesions of myelinated fiber tracts of the midbrain, medulla oblongata, and spinal cord including the lateral and ventral funiculi, the medial lemniscus, the descending tract of the fifth nerve, the reticular formation and the midbrain rubrospinal tract. "Larger myelinated fibers seemed to be preferentially involved." Myelin changes are more pronounced than alterations of the axon.

Despite the heterogenous pattern of tissue vulnerability, inhibition of SDH enzyme activity (determined biochemically and histochemically) is *uniform* throughout the cortex and the caudate/putamen.<sup>41,42</sup>

In rats, a single dose of 3-NPA (30 mg/kg s.c., LD 50 22 mg/kg s.c.) or 10 mg/kg/day for 1-4 days causes a stereotypic clinical picture to develop in stages:<sup>43</sup>

*Stage 1:* somnolence,

*Stage 2:* hyperactivity with uncoordinated "wobbly" gait; tendency to fall to one side; stereotyped paddling movements; axial "roll-over,"

*Stage 3:* ventral or lateral recumbency with hindlimbs rigidly extended; short periods of paddling movements.

The principal pathological changes are characterized by:

a) alterations of neuronal somata with marked chromatin clumping and increased cytoplasmic lucency, severe cellular



shrinkage or swelling, and swelling of mitochondria. Also present is swelling and chromatin clumping of astrocytes with relatively minor changes in the oligodendroglia.<sup>43</sup>

b) morphological changes of white matter tracts with axonal swelling and adaxonal splitting of myelin. Deficits are most evident in the internal capsule.

The following structures are selectively lesioned:

a) caudate-putamen, bilaterally symmetrical changes in all animals,

b) hippocampus, thalamus, and the roof of the fourth ventricle, less frequently described,

c) no pathological alterations in the cerebral (except areas subjacent to the rhinal sulcus) and cerebellar cortices and the hypothalamus.

Young rats treated with 10-25 mg/kg body weight 3-NPA twice daily developed hind limb paresis and paralysis.<sup>44</sup> The functional and morphological substrate of this deficit was not identified.

### RELATED TOXIC AND METABOLIC DISEASES

There are similarities between the responses of humans and animals to 3-NPA, to methanol/formate, and cyanide (which act via a related mechanism), and to inherited fumarase deficiency.

#### Methanol Intoxication

Methanol poisoning bears similarities to intoxication with 3-NPA. Common features include inhibition of the mitochondrial chain (cytochrome c oxidase), the pattern of vulnerability (bilateral, symmetric putaminal necrosis), and a profound acidosis (not in all species). Dystonia associated with bradykinesia and bilateral symmetric putaminal lesions in the CT-scan is a possible consequence of methanol poisoning in humans.<sup>45,46</sup> In addition, besides the well-known effect on the retina, anterior horn cell necrosis is described in the spinal cord.<sup>45</sup> Spasticity has been observed in two young patients.<sup>47</sup>

Experimental administration to rhesus monkeys of methanol — but not of formaldehyde or formate — produces extensor rigidity and tremor in association with hemorrhagic striatal lesions.<sup>48</sup> Management of systemic acidosis does not prevent the characteristic damage of the basal ganglia.<sup>48</sup> The pathogenesis of selective lesions of the optic nerve has been closely linked to the effects of formic acid generated from methanol by alcohol dehydrogenase.<sup>49</sup> Formate inhibits cytochrome oxidase resulting in blocked ATP generation.<sup>50,51</sup>

#### Cyanide Intoxication

Cyanide shuts down the cytochrome oxidase step of the electron transport chain producing an immediate termination of ATP production. Sublethal cyanide intoxication may be accompanied by late dystonia, with morphological evidence of striatal changes.<sup>52-54</sup>

#### Fumarase Deficiency — an Inherited Human Disease

Children with a deficiency of the Krebs cycle enzyme fumarase show developmental delay, mental retardation, hypotonia or spasticity.<sup>55-57</sup> Generalized brain atrophy is evident by CT-scanning. Gellera and colleagues<sup>58</sup> describe a child who suffered from partial seizures, permanent gaze deviation, abnormal posture of the head, hypotonia and delayed psychomotor development; later, the abnormal posture was permanent and mild

axonal dystonia developed. Metabolic acidosis was consistently present, deep tendon reflexes were absent, and the CT-scan showed diffuse cerebral atrophy. The child died at 7 months. Microcephaly, hypomyelination, and islets of cell heterotopia (mostly located in the cerebellum, as well as in the parietal and occipital areas) were demonstrated neuropathologically. No details of basal ganglia morphology were reported.

### OPEN QUESTIONS

Although much is known about the toxicity of 3-NPA, some important theoretical and practical questions are unresolved. Four questions arise:

1. Does 3-NPA induce histotoxic hypoxia?
2. Is 3-NPA linked to excitotoxicity?
3. Is there any evidence that 3-NPA induces human diseases in places other than China?
4. Are there other possible links between 3-NPA and human disease?

#### Does 3-NPA Induce Histotoxic Hypoxia?

Hamilton and Gould<sup>43</sup> suggested that 3-NPA induces "histotoxic hypoxia" in rats. The term describes brain damage due to failure of energy metabolism alone.<sup>59</sup> Based on their experience with experimental cyanide intoxication, Brierley and colleagues<sup>59-61</sup> strongly criticized the concept of "histotoxic hypoxia." These authors considered *hypotension* to be essential for the development of brain damage in cyanide-treated rats and *Macaca mulatta*. In the primate, they saw white matter involvement and "ischemic" neuronal alterations in the striatum (one animal). The latter were attributed to "major circulatory complications." Therefore, they concluded that no evidence exists for hypoxic damage of a purely histotoxic type in this model. In a study with rats,<sup>60</sup> they further stated that "cyanide can damage neurons only through the medium of secondary effects on circulation and respiration." Brierley postulated that "the distribution of a putative neuronal damage due to histotoxic hypoxia could only be defined if the brain were perfused artificially at a constant pressure with blood containing cyanide but of normal oxygen and carbon dioxide content and pH."<sup>61</sup> Hamilton and Gould addressed these questions in a second paper:<sup>37</sup> they showed in the rat that systemic change of blood pressure and hypoxia is *not* a contributing factor in NPA intoxication. Even though pH and bicarbonate were characteristically altered, the acidosis was slight compared with the changes Brierley had observed during his experiments. Hamilton and Gould<sup>37</sup> argued that although the acidosis might contribute to the morphology, it is unlikely to explain the pattern of tissue vulnerability. They could not exclude the possibility that regional changes of blood pressure contributed to their findings and also noted a few platelet microthrombi in brain regions susceptible to morphologic injury. Immunohistochemistry of 3-NPA rats<sup>37</sup> showed extensive albumin extravasation in animals with severe brain lesions. In mildly affected rats, extravasation was absent or limited to small cuffs around individual capillaries. The authors concluded that leakage of protein-rich fluid is not responsible for reduction of tissue change but may contribute to the severity of damage in major lesions.

In conclusion, 3-NPA intoxication of rats results in morphologically defined brain damage which is unlikely to be influ-

enced by systemic changes of blood pressure and only accompanied by mild acidosis. Regional changes are not ruled out, and a possible additional role of methemoglobinemia needs to be investigated. However, there is strong evidence to suspect that 3-NPA induces neuronal damage directly if not by histotoxic hypoxia.

### Is 3-NPA Linked to Excitotoxicity?

Hamilton and Gould<sup>37,43</sup> reported a "laminar pattern of injury in the hippocampus" comparable to that induced by subcutaneous injection of the excitotoxin kainate.<sup>62</sup> The presence of selective dendrosomatic swelling in mice,<sup>41</sup> and the extreme "ballooned swelling" of neurons in rats, also recalled the features of an excitotoxic injury.

These observations antedate by many years the observation of Henneberry and colleagues<sup>63,64</sup> who established a relationship between excitotoxicity and energy transformation. A priori, ATP is required to restore ionic and water balance in nerve cells depolarized by the action of a neurotransmitter such as glutamate. In practice, a variety of experimental maneuvers designed to depress ATP greatly increases neuronal vulnerability to endogenous excitotoxins. Moreover, nerve cells become vulnerable to injury from the depolarizing effects of excitatory neurotransmitters, and associated pathological changes are blocked by glutamate receptor antagonists. A comparable approach could be employed with 3-NPA.

### Does 3-NPA Induce Neurological Diseases in Humans in Places Other Than China?

Humans are more likely to come into significant contact with 3-NPA from mycotoxins rather than from plants. 3-NPA is produced by certain strains of *Aspergillus flavus* and has been isolated in cultures with a yield of approximately 100 mg from 6 liters.<sup>65</sup> Nakamura and Shimoda<sup>66</sup> identified 3-NPA among the metabolites of *Aspergillus oryzae*, 3-NPA is also a metabolite of certain strains of *Penicillium atrovenerum*; the maximum yield in one study<sup>67</sup> was 350 mg/l culture. Prior to recent Chinese reports,<sup>4-8</sup> the production of 3-NPA by *Arthrinium sacchari*, *saccharicola* or *phaespermum* was unknown. *Arthrinium spp.* are cosmopolitan; *A. phaespermum* is very common on bamboos, reeds, and many other substrates. *A. saccharicola* and *sacchari* are described on sugar cane, grasses, and fruits. Anzai and Suzuki<sup>68</sup> found 3-NPA on *Streptomyces spp.*

Although Chinese authors were the first to link primary nitrocompounds with human neurological disease, several authors had previously described contamination of human food with mycotoxins containing 3-NPA. Iwasaki and Koskowski<sup>69</sup> showed that various strains of *Aspergillus oryzae* produced 1-111 mg 3-NPA per liter culture. These strains grew well on cheese curds, soybeans, and peanuts. After 5 days, the cheese curds contained 427 mg/kg or 203 mg/kg 3-NPA. Soybean and peanut contained a maximum of 10-15 mg/kg 3-NPA. Kinoshita et al.<sup>70</sup> collected samples of popular (often home-made) fermented Japanese foodstuffs from local stores ("miso," fermented soy bean paste, "katsuobushi," fermented dry bonito, and starters for their fermentation process). On 24 samples, 21 toxic strains were identified of which many produced 3-NPA. A cycad miso from Oomi-Ooshima contained an unidentified fungus which produced 3-NPA (0.2 mg/ml).

### Other Possible Links Between 3-NPA and Human Disease

After the discovery of He<sup>4-6</sup> and Liu,<sup>8</sup> the observations made in the 1920's by Woods and Pendleton<sup>71</sup> deserve attention in a new context: the authors described an acute degenerative striatal disease in 14 Chinese children and adults after a winter of famine (1920-1921). "Villagers subsisted on poor quality of maize, which they say was somewhat fermented." Three families were involved, all of whom had close social contact with each other. Health problems included "sudden giving way of the lower limbs, speech defects, convulsive seizures in some and disturbances of automatic associated movements in others." In one subject, weakness of forearm and small hand muscles was observed. The disease onset was characterized by lethargy and sleepiness. Later, in some patients, choreoathetotic and dystonic movements appeared. Pathological examination of a single subject revealed "mild hydrocephalus, fibrillar glial proliferation around areas of softening, and a general increase of glial cells. There was widespread ganglion cell necrosis (most intense in the substantia nigra and the lower levels of the striate body)" . . . "The cytoplasm was vacuolated, often contained neurophages and there was lipid pigment in and around degenerated cells."

In 1938, Verhaart<sup>72</sup> suspected a toxic causation for symmetrical neostriatal degeneration in 6-8 month-old breast-fed Chinese children. "At that age breast feeding usually begins (in Batavia) to be insufficient." Pathologically, he observed "generalized or localized rarification of the tissue of the caudate nucleus and the putamen . . . with proliferation of the macroglia." The neurons in all cases were scanty, the microglia increased, and the oligodendrocytes swollen. "To a lesser extent the same changes were found in the globus pallidus, especially at the border of the putamen, the corpus subthalamicus and the red nucleus and the corpora quadrigemina in some cases."

### SUMMARY

The foregoing provides for a strong rationale to examine the question of whether the acute and chronic animal diseases induced by 3-NPA have their counterpart in the human species. 3-NPA also represents a useful tool to examine the relationship between the enzyme inhibition of SDH, energy decrements, excitotoxicity and selective neural damage. Therapeutic approaches for the virtually untreatable extrapyramidal hyperkinesias induced by this compound could be tested in an animal model of the 3-NPA-induced neurological disease.

### REFERENCES

1. Fahn, S, Marsden CD, Calne DB. Classification and investigation of dystonia. In: Marsden CD, Fahn S, eds. Movement Disorders 2. London: Butterworth 1987; 332-353.
2. Langston JW, Ballard P, Tetrud JW, et al. Chronic parkinsonism in humans due to a product of meperidine-analog synthesis. Science 1984; 219: 979-980.
3. Ludolph AC, Hugon J, Dwivedi MP, et al. Studies on the aetiology and pathogenesis of motor neuron diseases. I. Lathyrism: Clinical findings in established cases. Brain 1987; 110: 149-165.
4. He F, Zhang S, Zhang C, et al. Mycotoxin-induced encephalopathy and dystonia in children. In: Volans GN, et al, eds. Basic Science in Toxicology. London: Taylor & Francis 1990; 596-604.
5. He F, Zhang S, Zhang C, et al. Extrapyramidal lesions induced by mildewed sugar cane poisoning. Three case reports. Chin Med J 1987; 67: 395-396.

6. Hu W. The isolation and structure identification of a toxic substance, 3-nitropropionic acid, produced by *Arthrimum* from mildewed sugar cane. *Chin J Prev Med* 1986; 20: 321-323.
7. Liu X. Investigations on the etiology of mildewed sugar cane poisoning. A review. *Chin J Prev Med* 1986; 20: 306-308.
8. Liu X. Studies on the mycology and mycotoxins in an outbreak of deteriorated sugar cane poisoning. *Chin J Prev Med* 1989; 23: 345-348.
9. Williams MC, James LF. Livestock poisoning from nitro-bearing *Astragalus*. In: Keeler RF, Van Kampen KR, James LF, eds. *Effects of Poisonous Plants on Livestock*, New York: Academic Press 1978; 379-389.
10. James LF. Neurotoxins and other toxins from *Astragalus* and related genera. In: Keeler RF, Tu AT, eds. *Handbook of Natural Toxins*, Vol. 1 New York: Marcel Dekker 1983; 445-462.
11. Majak W, Pass MA. Aliphatic Nitrocompounds. In: Cheeke PR, ed. *Toxicants of Plant Origin*. Vol. 11. Glycosides. Boca Raton: CRC Press 1990; 143-160.
12. James LF, Hartley J, Williams MC, Van Kampen KR. Field and experimental studies in cattle and sheep poisoned by nitro-bearing *Astragalus* or their toxins. *J Am Vet Res* 1980; 41: 377-382.
13. Pass MA, Majak W, Muir AD, et al. Absorption of 3-nitropropanol and 3-nitropropionic acid from the digestive tract of sheep. *Toxicol Lett* 1984; 23: 1-7.
14. Williams MC, Barneby RC. The occurrence of nitro-toxins in North American *Astragalus* (Fabaceae). *Brittonia* 1977; 29: 310-326.
15. Williams MC, Barneby RC. The occurrence of nitro-toxins in Old World and South American *Astragalus* (Fabaceae). *Brittonia* 1977; 29: 327-331.
16. Williams MC. Nitro-compounds in foreign species of *Astragalus*. *Weed Sci* 1981; 29: 261-269.
17. Williams MC. 3-Nitropropionic acid and 3-nitropropanol in species of *Astragalus*. *Can J Bot* 1982; 60: 1956-1963.
18. Williams MC, Davies AM. Nitro compounds in introduced *Astragalus* species. *J Range Manage* 1982; 35: 113-115.
19. Shenk JS, Risius ML, Barnes RF. Weaning meadow vole responses to crownvetch forage. *Agron J* 1974; 66: 386-389.
20. Shenk JS, Wangsness PJ, Leach RM, et al. Relationship between betanitropropionic acid content of crownvetch and toxicity in nonruminant animals. *J Animal Sci* 1976; 42: 616-621.
21. Cooke AR. The toxic constituent of *Indigofera endecaphylla*. *Arch Biochem* 1955; 55: 114-120.
22. Morris MP, Pagan C, Warmke HE. Hiptagenic acid, a toxic component of *Indigofera endecaphylla*. *Science* 1954; 119: 322-323.
23. Williams MC. Toxic nitro compounds in *Indigofera* species. *Agr J* 1981; 73: 434-436.
24. Murray LR, Moore T, Sharman IM. The toxicity of *Indigofera enneaphylla* in rats. *Aust J Agric Res* 1965; 16: 713-720.
25. Williams MC. Toxic nitro compounds in *Lotus*. *Agr J* 1983; 75: 520-522.
26. Gorter K. Hiptagin, a new glucoside from *Hiptage madablota*. *Gaertn Bull Jordin Bot Buitenzorg* 1920; 2: 187-202.
27. Carter J. Karakin, the glucoside of *Corynocarpus laevigata*, and hiptagenic acid. *Soc Chem Ind (London)* 1943; 62: 238-240.
28. Moyer BG, Pfeffer PE, Valentine KM, Gustine DL. 3-Nitropropanoyl-D-glucopyranoses of *Corynocarpus laevigatus*. *Phytochemistry* 1979; 18: 111-114.
29. Alston TA, Mela L, Bright HJ. 3-Nitropropionate, the toxic substance of *Indigofera*, is a suicide inactivator of succinate dehydrogenase. *Proc Natl Acad Sci USA* 1977; 74: 3767-3771.
30. Coles CJ, Edmondson DE, Singer TP. Inactivation of succinate dehydrogenase by 3-nitropropionate. *J Biol Chem* 1979; 254: 5161-5167.
31. Porter DJT, Bright HJ. 3-Carbanionic substrate analogues bind very tightly to fumarase and aspartase. *J Biol Chem* 1980; 255: 4772-4880.
32. Schloss JV, Cleland WW. Inhibition of isocitrate lyase by 3-nitropropionate, a reaction-intermediate analogue. *Biochemistry* 1982; 21: 4420-4427.
33. Osman MY. Effect of  $\beta$ -nitropropionic acid on rat brain acetylcholinesterase. *Biochem Pharmacol* 1982; 31: 4067-4072.
34. Pass MA, Muir AD, Majak W, et al. Effect of alcohol and aldehyde dehydrogenase inhibitors on the toxicity of 3-nitropropanol in rats. *Toxicol Appl Pharmacol* 1985; 78: 310-315.
35. Matsumoto H, Hylin JW, Miyahara A. Methemoglobinemia in rats injected with 3-nitropropionic acid, sodium nitrite, and nitroethane. *Toxicol Appl Pharmacol* 1961; 3: 493-499.
36. Wilson BJ. Miscellaneous *Aspergillus* toxins. In: Ciegler A, Kadis S, Aji SJ, eds. *Microbial Toxins*, Vol. 6. Fungal Toxins. New York: Academic Press 1971; 251-257.
37. Hamilton BF, Gould DH. Correlation of morphologic brain lesions with physiologic alterations and blood-brain barrier impairment in 3-nitropropionic acid toxicity in rats. *Acta Neuropathol (Berlin)* 1987; 74: 67-74.
38. Williams MC, Van Kampen KR, Norris FA. Timber milk vetch poisoning in chickens, rabbits, and cattle. *Am J Vet Res* 1969; 30: 2185-2190.
39. Williams MC, James LF, Bleak AT. Toxicity of introduced nitro-containing *Astragalus* to sheep, cattle, and chicks. *J Range Manag* 1976; 28: 260-263.
40. Salyi G, Sztojokov V, Hilbertne Miklovics M. A nutria tarka koronafürt (*Coronilla varia L.*) okozta mergezese. *Magyar Allatorvosok Lapja* 1988; 43: 313-316.
41. Gould DH, Gustine DL. Basal ganglia degeneration, myelin alterations, and enzyme inhibition induced in mice by the plant toxin 3-nitropropionic acid. *Neuropathol Appl Neurobiol* 1982; 8: 377-393.
42. Gould DH, Wilson MP, Hamar DW. Brain enzyme and clinical alterations induced in rats and mice by nitroaliphatic toxicants. *Toxicol Lett* 1985; 27: 83-89.
43. Hamilton BF, Gould DH. Nature and distribution of brain lesions in rats intoxicated with 3-nitropropionic acid: a type of hypoxic (energy deficient) brain damage. *Acta Neuropathol (Berl)* 1987; 72: 286-297.
44. Pass MA, Majak W, Yost GS. Lack of a protective effect of thiamine on the toxicity of 3-nitropropanol and 3-nitropropionic acid in rats. *Can J Anim Sci* 1988; 68: 315-320.
45. McClean DR, Jacobs H, Mielke BW. Methanol poisoning: a clinical and pathological study. *Ann Neurol* 1980; 8: 161-167.
46. LeWitt PA, Martin SD. Dystonia and hyperkinesia with putaminal necrosis after methanol intoxication. *Clin Neuropharmacol* 1988; 11: 161-167.
47. Guggenheim MA, Couch JR, Weinberg W. Motor dysfunction as a permanent complication of methanol ingestion. *Arch Neurol* 1971; 24: 550-554.
48. Potts AM, Praglin J, Farkas L, et al. Studies on the visual toxicity of methanol: VII. Additional observations on methanol poisoning in the primate test object. *Am J Ophthalmol* 1955; 40: 76-82.
49. Martin-Amat G, McMartin KE, Hayreh SS, et al. Methanol poisoning: ocular toxicity produced by formate. *Toxicol Appl Pharmacol* 1978; 45: 201-208.
50. Nicholls P. Formate as an inhibitor of cytochrome c oxidase. *Biochem Biophys Res Commun* 1975; 67: 610-616.
51. Nicholls P. The effect of formate on cytochrome aa3 and on electron transport in the intact respiratory chain. *Biochim Biophys Acta* 1976; 430: 13-29.
52. Carella F, Grassi MP, Savoirdo M, et al. Dystonic-Parkinsonian syndrome after cyanide poisoning: clinical and MRI findings. *J Neurol Neurosurg Psychiatry* 1988; 51: 1345-1348.
53. Uitti RJ, Rajput AH, Ashenhurst EM, et al. Cyanide-induced Parkinsonism: a clinicopathologic report. *Neurology* 1985; 35: 921-925.
54. Finelli PF. Changes in the basal ganglia following cyanide poisoning. *J Comput Assist Tomogr* 1981; 5: 755-756.
55. Whelan DT, Hill RE, McClorry S. Fumaric aciduria: a new organic aciduria, associated with mental retardation and speech impairment. *Clinica Chimica Acta* 1983; 132: 301-308.
56. Robinson BH. Lactic acidemia. In: Scriver CR, Beaudet AL, Sly WS, Valle D, eds. *The Metabolic Basis of Inherited Disease*. New York: McGraw Hill 1989; 869-888.
57. Walker V, Mills GA, Hall MA, et al. A fourth case of fumarase deficiency. *J Inher Metab Dis* 1989; 12: 331-332.
58. Gellera MS, Uziel G, Rimoldi M, et al. Fumarase deficiency is an autosomal recessive encephalopathy affecting both the mito-

- chondrial and the cytosolic enzymes. *Neurology* 1990; 40: 495-499.
59. Brierley JB, Graham DI. Hypoxia and vascular disorders of the central nervous system. In: Adams JH, Corsellis JAN, Duchen LW, eds. *Greenfield's Neuropathology*, 4th ed. New York: John Wiley 1984; 125-207.
  60. Brierley JB, Brown AW, Calverley J. Cyanide intoxication in the rat: physiological and neuropathological aspects. *J Neurol Neurosurg Psychiatry* 1976; 9: 122-140.
  61. Brierley JB, Prior PF, Calverley J, et al. Cyanide intoxication in *Macaca mulatta*-physiological and neuropathological aspects. *J Neurol Sci* 1977; 31: 133-157.
  62. Olney JW, Fuller T, De Gubareff T. Acute dendrotoxic changes in the hippocampus of kainate-treated rats. *Brain Res* 1979; 176: 91-100.
  63. Hennebery RC, Novelli A, Cox JA, et al. Neurotoxicity at the N-methyl-D-aspartate receptor in energy-compromised neurons: An hypothesis for cell death in aging and disease. *Ann NY Acad Sci* 1989; 568: 225-233.
  64. Novelli A, Reilly JA, Lysko PG, et al. Glutamate becomes neurotoxic via the N-methyl-D-aspartate receptor when intracellular energy levels are reduced. *Brain Res* 1988; 451: 205-212.
  65. Bush MT, Touster O, Brockman JE. The production of beta-nitropropionic acid by a strain of *Aspergillus flavus*. *J Biol Chem* 1951; 188: 685-693.
  66. Nakamura S, Shimoda C. Studies on an antibiotic substance oryzacin, produced by *Asp. oryzae*. Part-5. Existence of 3-nitropropionic acid. *J Agr Chem Soc Japan* 1954; 28: 909-913.
  67. Raistrick H, Stössl A. Studies in the biochemistry of micro-organisms. 104. Metabolites of *Penicillium atrovirens* G. Smith:  $\beta$ -nitropropionic acid, a major metabolite. *Biochem J* 1958; 68: 647-653.
  68. Anzai K, Suzuki S. A new antibiotic bovinocidin, identified as  $\beta$ -nitropropionic acid. *J Antibiotics (Tokyo)* 1960; 13: 133-136.
  69. Iwasaki T, Koskowski FV. Production of  $\beta$ -nitropropionic acid in foods. *J Food Sci* 1973; 38: 1162-1165.
  70. Kinoshita R, Ishiko T, Sugiyama S, et al. Mycotoxins in fermented food. *Cancer Res* 1968; 28: 2296-2311.
  71. Woods AH, Pendleton L. Fourteen simultaneous cases of an acute degenerative striatal disease. *Arch Neurol Psych* 1925; 13: 549-568.
  72. Verhaart WJC. Symmetrical degeneration of the neostriatum in Chinese infants. *Arch Dis Child* 1938; 13: 225-234.