

Research Article

3D Printed Guides and Preoperative Planning for Uncemented Stem Anteversion Reconstruction during Hip Arthroplasty: A Pilot Study

Yingqi Zhang,¹ Zhitao Rao,¹ Jincheng Zhang,¹ Shijie Li,² Shimin Chang^{ID},²
and Yeqing Sun^{ID}¹

¹Department of Orthopedic Surgery, Tongji Hospital, Tongji University School of Medicine, Shanghai 200065, China

²Department of Orthopedic Surgery, Yangpu Hospital, Tongji University School of Medicine, Shanghai 200090, China

Correspondence should be addressed to Shimin Chang; jiu222117464@163.com and Yeqing Sun; yeqingsun@tongji.edu.cn

Received 21 December 2020; Revised 16 January 2021; Accepted 30 January 2021; Published 19 February 2021

Academic Editor: Tao Huang

Copyright © 2021 Yingqi Zhang et al. This is an open access article distributed under the Creative Commons Attribution License, which permits unrestricted use, distribution, and reproduction in any medium, provided the original work is properly cited.

Objective. To investigate if 3D printed guides and preoperative planning can accurately control femoral stem anteversion. **Methods.** A prospective comparative study was carried out from 2018 to 2020, including 53 patients who underwent hip arthroplasty for femoral neck fracture. The target rotation center of the femoral head is determined by three-dimensional planning. In group A, planning was made by 2D templates. In group B, preoperative 3D planning and 3D printed osteotomy/positioning guides were performed. After the operation, 3D model registration was performed to calculate the accuracy of anteversion restoration. **Results.** We screened 60 patients and randomized a total of 53 to 2 parallel study arms: 30 patients to the group A (traditional operation) and 23 patients to the group B (3D preoperative planning and 3D printed guide). There were no significant differences in demographic or perioperative data between study groups. The restoration accuracy of group A was $5.42^\circ \pm 3.65^\circ$ and of group B was $2.32^\circ \pm 1.89^\circ$. The number and rate of abnormal cases was 15 (50%) and 2 (8.7%), respectively. Significant statistical differences were found in angle change, restoration accuracy, and number of abnormal cases. **Conclusion.** Three-dimensional preoperative planning and 3D printed guides can improve the accuracy of the restoration of femoral anteversion during hip arthroplasty.

1. Introduction

Hip arthroplasty is an extremely successful procedure, which help improving range of motion and decreasing pain and finally improving patients' quality of life [1, 2]. However, mispositioning of the implants can result in premature implant failure requiring revision [1–4]. Although the most common cause of revision surgery was due to cup mispositioning (33%), surgeons should be aware of the variability of the femoral anteversion of uncemented stems [5, 6]. The traditional methods of using preoperative anteroposterior pelvis radiographs for planning and standard surgical instrumentation have shown potential for inaccuracy which varies with surgeon experience. With the development of digital orthopedics, CT-based three-dimensional planning and navigation systems

have been introduced to improve the accuracy of prosthesis implantation [7–9]. However, the implantation of the femoral stem is affected by the surgical incision, visual field, and irregular medullary cavity shape of the proximal femur. It is difficult to accurately restore the anteversion, even based on preoperative CT measurement results [6, 10].

3D printed personalized guides have been used in orthopedic surgery in recent years and have achieved good results [11, 12]. Based on a patient's unique bony morphologic features is an improvement over generic instruments by minimizing sources of error from standard surgical instruments that depend on appropriate patient positioning, exposure, and surgeon experience [13–15]. However, there are rare reports in the previous literature about the use of guide to assist the femoral anteversion restoration [6]. Based on the

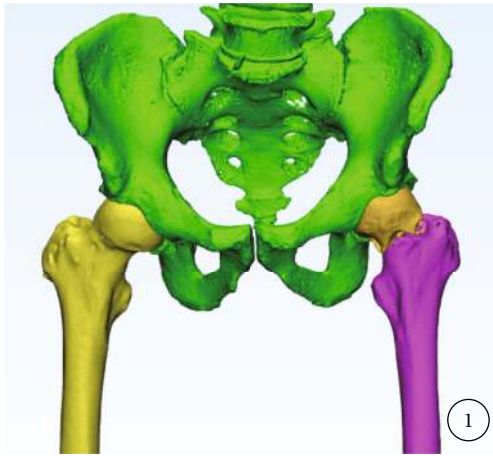


FIGURE 1: Fracture modeling build an independent three-dimensional model of fracture through CT.

preoperative three-dimensional planning, we developed a femoral osteotomy guide and a stem positioning guide. For hip arthroplasty, it is expected to accurately restore the femoral anteversion.

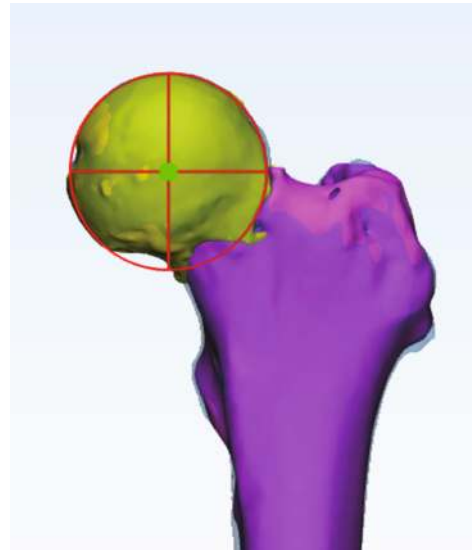
2. Materials and Methods

This prospective, controlled trial was performed from January of 2018 to January of 2020 at a single large academic institution. This study was approved by our institutional review board, and every patient gave written informed consent to participate.

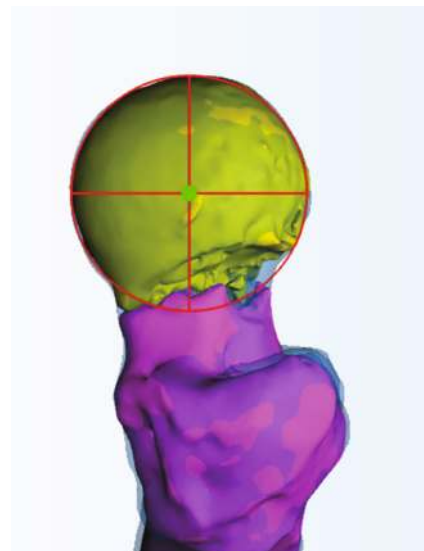
2.1. Patients. Patients scheduled for a primary arthroplasty were approached for the study. Inclusion criteria are as follows: (1) unilateral traumatic femoral neck fracture, (2) primary hip replacement, (3) age > 18 years old at time of surgery, (4) cementless straight stem (Johnson & Johnson/Zimmer Biomet, USA), and (5) able to get a preoperative and postoperative CT scans. Exclusion criteria are as follows: (1) hip joints had abnormalities before this injury and (2) condition deemed by physician to be nonconductive to patient's ability to complete the study. Demographic information collected on all patients was age, gender, and body mass index (BMI).

2.2. Three-Dimensional Planning. In all cases, the appropriate type of prosthesis was selected through the traditional two-dimensional template. Preoperative CT scans of the pelvis and proximal femur were obtained (Siemens, 120 kV, 350 mA, layer spacing < 1 mm). CT data was imported into the Mimics 20.0 software (Master, Belgium). Separate models of the pelvis, healthy femur, injured femoral head, and proximal shaft were established by threshold difference and manual segmentation (Figure 1). After virtual fracture reduction or mirror healthy model registration, the target femoral head center can be obtained by articular surface fitting (Figure 2).

Then, the femoral stem prosthesis model was imported into the software. Taking the center of the target femoral head as a reference, surgeon adjusted the posture of the prosthetic stem in the front view, lateral view, and top view. In the



(a)



(b)

FIGURE 2: Mirror/virtual fracture reduction, fitting articular surface to determine the target rotation center: front view (a); side view (b); the red circle is the fitting sphere, and the green dot is the planned center.

top view, the axis of the prosthesis's neck passes through the target center. In the front and lateral view, the axis of the prosthesis stem was coaxial with the centerline of the proximal medullary cavity (Figure 3). In group A, 3D process was performed after surgery. In group B, femoral neck osteotomy guide and stem positioning guide were designed (Figure 4). The guide models were output in STL format, printed with 0.1 mm precision photosensitive medical-grade resin. Guides were sterilized by low-temperature plasma.

2.3. Surgical Procedure. The operations were performed by the same group of surgeons. All femoral components were made with cementless devices. After receiving general anesthesia or nerve block anesthesia, patients were positioned in

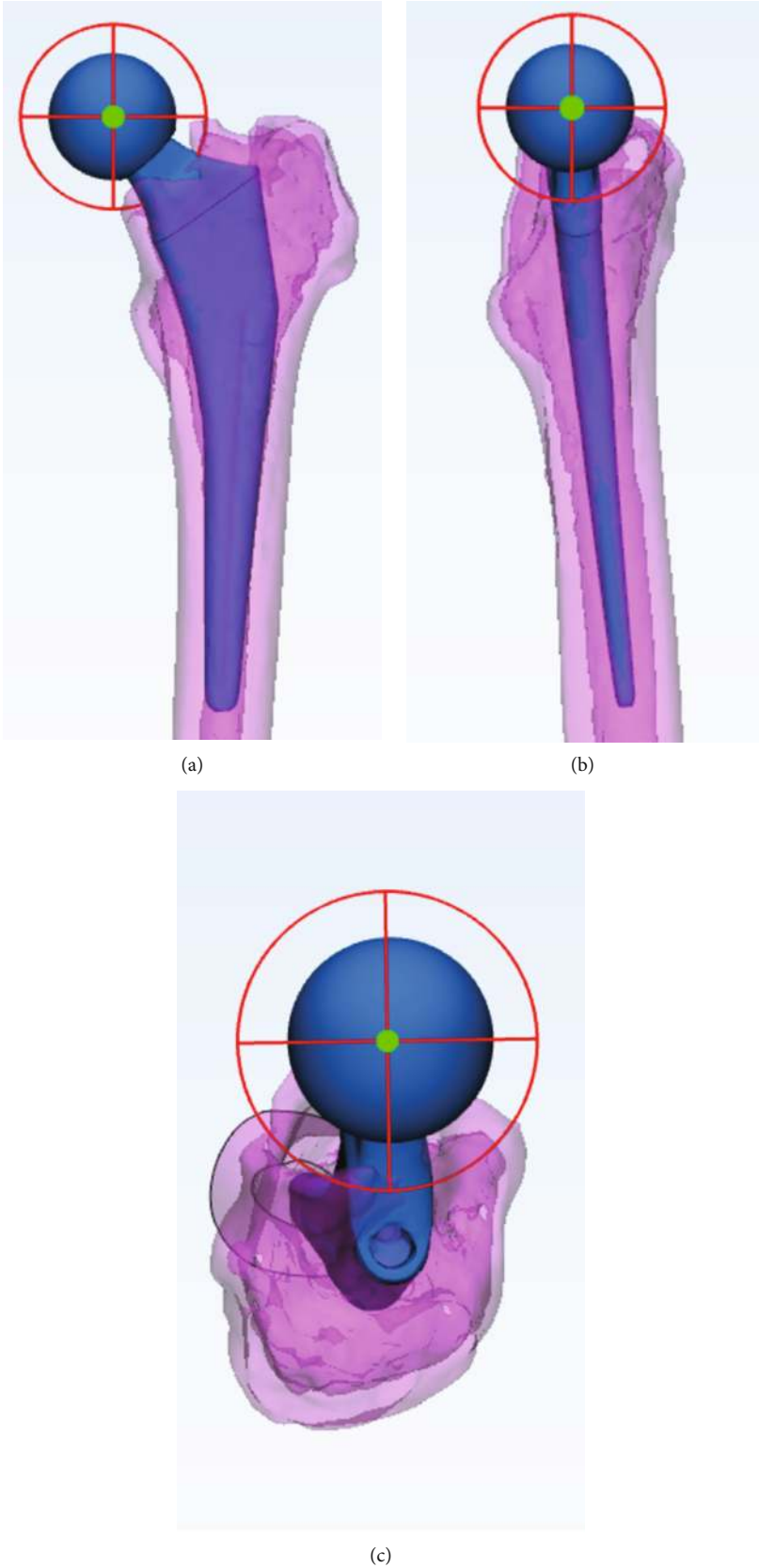


FIGURE 3: Simulated placement of femoral prosthesis: front view (a), lateral view (b), and top view (c).

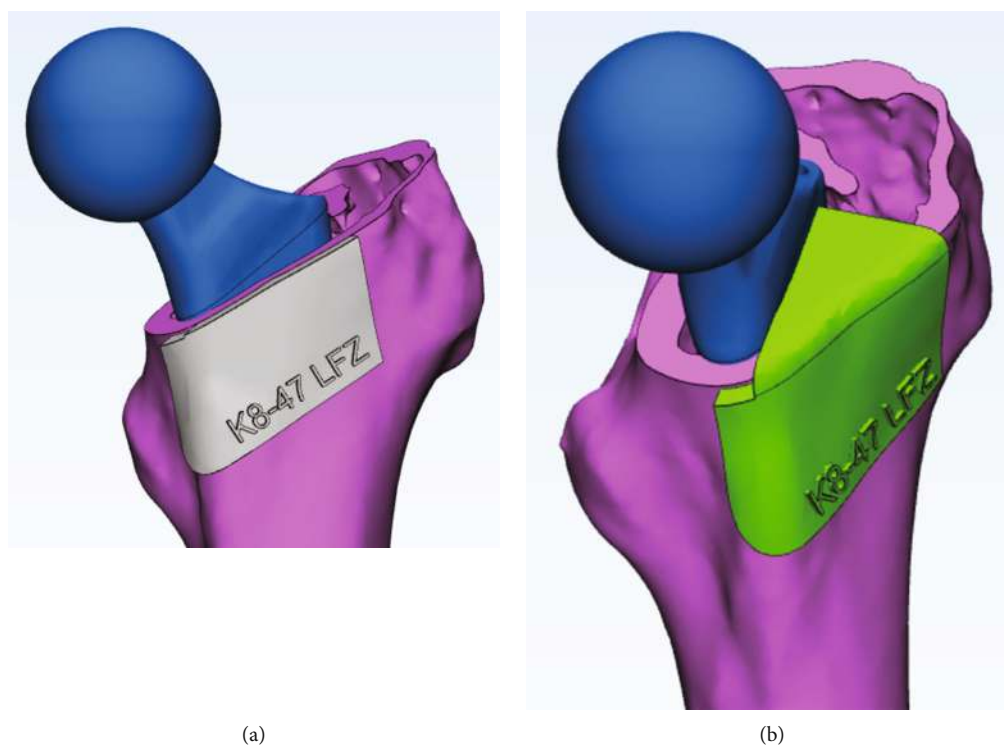


FIGURE 4: Design of femoral neck osteotomy guide (a) and prosthesis positioning guide (b).

the lateral decubitus position for all procedures. The operative technique for both groups was completed using anterolateral approaches. In the group A, surgeons performed operations based on two-dimensional planning and experience. In the group B, 3D preoperative planning was performed before surgery; after exposure of the femoral neck, the bone was cleaned to ensure a secure fit for the guides. Next, the guide was placed in a position to fit around bone in a “best fit” position. The femoral neck osteotomy was performed according to the edge of the guide (Figure 5(b)). After removing the femoral head, the acetabulum was cleaned. Then, the femoral medullary cavity was formed, and the position guide was placed on the osteotomy surface during the forming process (Figure 5(c)). After the stability testing, the femoral stem was implanted according to the guide (Figure 5(d)).

2.4. Postoperative Evaluation. All patients received a CT scan prior to discharge using the same technique as the preoperative scans. Evaluation of the final anteversion was determined by superimposing the previous planned stem position to the actual stem position and compared using Tsai’s definitions (Figure 6) [3]. From the top view, the planned and postoperative anteversion was measured. The angle difference between the postoperative femoral prosthesis neck axis and the preoperatively planned center was calculated as accuracy value (Figure 6(c)). Cases with the angle change more than 5° were counted as abnormal case.

2.5. Statistical Analysis. The data are reported using descriptive statistics, including mean, standard deviation, and range

values. The accuracy of the anteversion restoring was compared among groups. Chi-squared test and Mann–Whitney *U* test are used to test differences between groups. $P < 0.05$ was regarded as significant difference.

3. Results

We screened 60 patients and randomized a total of 53 to 2 parallel study arms: 30 patients to the group A (traditional operation) and 23 patients to the group B (3D preoperative planning and 3D printed guide). There were no significant differences in demographic or perioperative data between study groups (Tables 1 and 2).

The average planned anteversion for groups was $22.6^\circ \pm 11.4^\circ$ (group A) and $21.6^\circ \pm 9.9^\circ$ (group B), respectively. The average actual anteversion for groups was $21.8^\circ \pm 14.5^\circ$ and $21.8^\circ \pm 10.3^\circ$, respectively. The accuracy for groups was $5.42^\circ \pm 3.7^\circ$ (range 0.5° to 17.7°) and $2.32^\circ \pm 1.89^\circ$ (range 0.1° to 6.8°), respectively. The number and rate of abnormal cases was 15 (50%) and 2 (6.7%), respectively. Significant statistical differences were found in angle change, restoration accuracy, and number of abnormal cases.

4. Discussion

Component positioning in hip arthroplasty can have a major effect on both clinical outcome and complications rate. Previous studies have focused on the accuracy of acetabular implantation [3, 16–18]. With the introduction of concepts such as combined version, more and more attention has been paid to stem anteversion [19]. Substantial changes in femoral

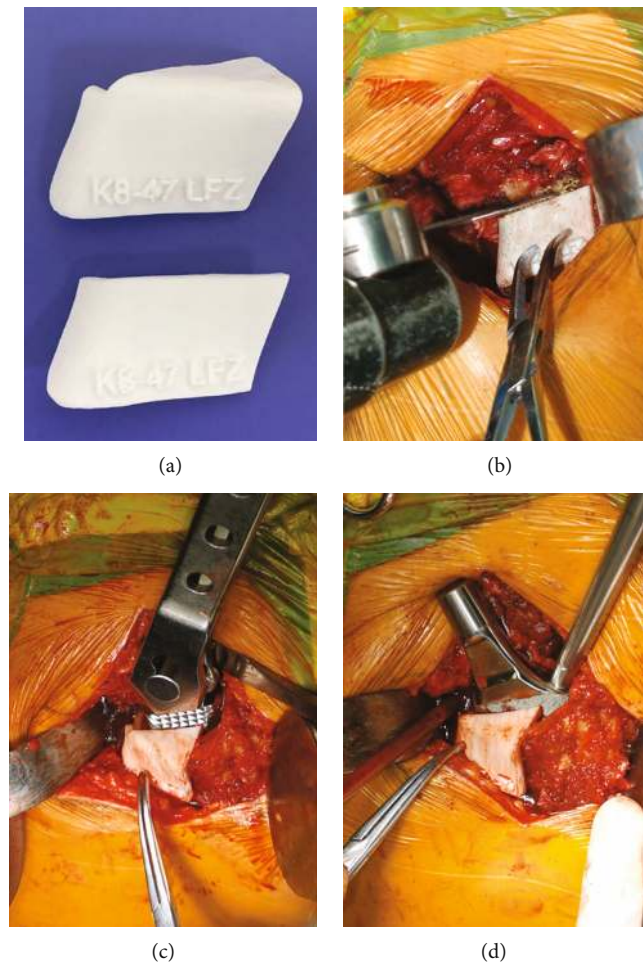


FIGURE 5: Guide plate printing (a), intraoperative osteotomy (b), intraoperative medullary cavity formation (c), and intraoperative implantation of femoral stem (d).

neck version with stem implantation create concurrent changes in anterior and lateral femoral offset, potentially resulting in decrements in abductor strength [20]. Surgical approaches also affect the anteversion change [21].

Traditionally, the recommended positioning for femoral stem is to restore natural offset and anteversion. Various works have in fact shown native femoral neck version that has a wide variation. Abe reported the mean preoperative femoral anteversion was $27.8^\circ \pm 10.6^\circ$ in Japanese population. Koerner reported average femoral version was $8.84^\circ \pm 9.66^\circ$, with no statistically significant differences between ethnicities [22]. Our study presented similar results that the standard deviation is about 10° . The variable anteversion may cause difficulty for the surgeon to implant correctly.

In order to accurately restore the femoral rotation center, surgeons usually control stem anteversion during the operation, based on experience and visual assessment. But the surgeon's estimation of the anteversion of the cementless femoral stem has poor precision [23]. Wines reported that the mean difference between the surgeons' intraoperative assessment of femoral component version and the CT measurement was an underestimation of 1.18° , with a standard deviation of 10.4° and a range of 25° underestimation to 30°

overestimation [24]. In a research of 65 patients, Woerner reported the mean difference between the 3D-CT results and intraoperative estimations by the eye was -7.3° (-34° to 15°) and an overestimation of $>5^\circ$ for stem torsion in 40 hips. Using 3D reconstruction and method, Tsai reported femoral anteversion of the implanted side was significantly increased by $11.4^\circ \pm 11.9^\circ$ [3]. In this study, date of group A also presented that even experienced surgeon's intraoperative estimation of stem position by the eye is not reliable.

Several studies have investigated the accuracy of measurements obtained using a goniometer or navigation systems [25–27]. Mitsutake developed an angle-measuring instrument; mean measurement accuracy was $0.9^\circ \pm 6.1^\circ$, and the absolute measurement accuracy was $4.9^\circ \pm 3.7^\circ$ [25]. Using stem-first technique with navigation system, Okada reported absolute discrepancy between intraoperative and postoperative assessment was $5.81^\circ \pm 4.42^\circ$ (range 0.01° – 17.4°) [28]. In a robotically assisted study, Marcovigi reported average difference between preoperative and actual stem anteversion was $1.6^\circ \pm 9.8^\circ$ (max 34° in anteversion, min -52° in retroversion). Previous literatures remind that the accurate restoration of femoral anteversion is still a concern for surgeons.

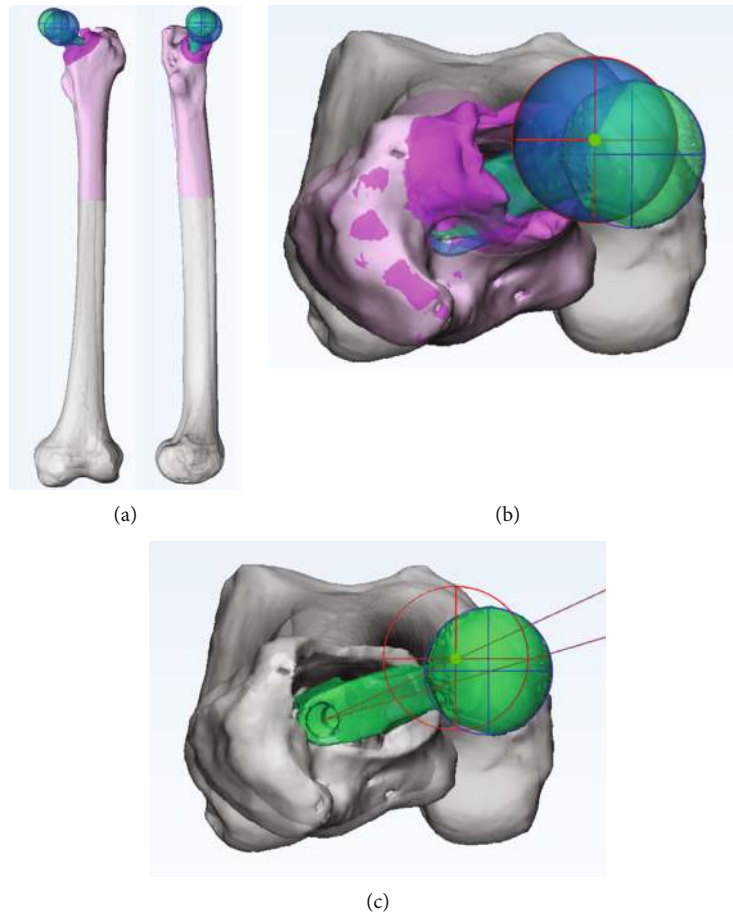


FIGURE 6: Postoperative modeling and registration (a). Fit the postoperative rotation center (b). Calculate the preoperative planning, the actual postoperative anteversion angle, and the difference (c). Red sphere indicates the planned center; blue sphere indicates the actual center.

TABLE 1: Patient characteristic data.

Variable	Group A	Group B	<i>P</i> value
Age at operation (years)	75.5 (54-89)	73.5 (52-86)	0.886 ^a
Sex distribution (M/F)	10/20	8/15	0.912 ^b
Height (m)	1.61 ± 0.08	1.61 ± 0.08	0.921 ^a
Weight (kg)	56.82 ± 10.26	60.48 ± 9.07	0.239 ^a
BMI (kg/m ²)	21.88 ± 3.23	23.34 ± 2.70	0.116 ^a
Location (L/R)	17/13	15/8	0.528 ^b
Operation type (T/H)	17/13	17/6	0.194 ^b

M: male; F: female; L: left hip; R: right hip; BMI: body mass index; T: total hip arthroplasty; H: hemiarthroplasty. ^aMann-Whitney *U* test. ^bChi-squared test, significance set at $P < 0.05$.

For joint arthroplasty, 3D printed instruments have already been successfully translated into large-scale clinical use for knee arthroplasty. Some studies introduced patient specific instruments that assist acetabular cup placement and femoral neck osteotomy in hip replacements [11, 14]. Lee combined 3D printed instrument and navigation system for an in vitro study with a sawbone model, and the absolute deviation between plan and actual anteversion was $1.41^\circ \pm 1.03^\circ$ (range 0.02° - 3.32°) [29]. However, Lee prepared the

TABLE 2: Comparison of preoperative and postoperative anteversion.

Variable	Group A	Group B	<i>P</i> value
Preoperative femoral anteversion (degrees)	22.61 ± 11.43	21.61 ± 9.96	0.816 ^a
Postoperative femoral anteversion (degrees)	21.77 ± 14.48	21.84 ± 10.25	0.971 ^a
Anteversion change (degrees)	5.42 ± 3.65	2.32 ± 1.89	0.000 ^a
Abnormal case (>5°)	15 (50%)	2 (8.7%)	0.002 ^b

^aMann-Whitney *U* test. ^bChi-squared test, significance set at $P < 0.05$.

proximal medullary canal using only a box chisel. Various authors have pointed out that, especially in cementless arthroplasty, the stem finds its way to an anteversion position, where it fits best to the rigid canal of the femur. It should be noted that the entry point of the medullary cavity will affect the anteversion angle and the center of rotation.

For the first time, this article compared the accuracy of anteversion restoration between 3D printed guide and traditional operation. The method of mirror model and virtual reduction was used to determine the target rotation center;

then, the personalized osteotomy/positioning guides were designed and manufactured. The results shown that the error of the traditional experience operation is relatively high. The number of abnormal cases is 15 (50%), which is like previous studies. The 3D printed guides improve the accuracy, even better than some navigation system in previous reports. The abnormal case was reduced from 50% to 6.7%. The reason may be that the positioning guide in this experiment is very close to the box chisel and stem, which helps the surgeon choose the appropriate entry point and be a reference during the medullary cavity formation process. The planned stem axis should be overlapped with the proximal medullary cavity axis, which can reduce the mismatch of medullary cavity. In this experiment, the guide does not need to be fixed on the bone and change the surgical procedure slightly.

5. Conclusions

We have proposed the method including 3D planning and 3D printed osteotomy/positioning guides for femoral anteversion restoration. The proposed method was more accurate and consistent than the conventional method. 3D printed guides can reduce the number of inappropriate anteversion. Paying attention to the relationship between the entry point of the box-chisel and the geometry of the osteotomy surface can improve the accuracy of the operation.

Data Availability

All the data could be provided if any qualified authors required.

Ethical Approval

This study was approved by the Medical Ethics Committee of Shanghai Tongji Hospital (No. 2018-054).

Disclosure

The project funding did not affect the opinions of article, the results data, and statistical analysis.

Conflicts of Interest

All authors declare no conflict of interest in the research.

Authors' Contributions

Yingqi Zhang and Zhitao Rao contributed equally. They were responsible for experimental design and operation, statistical analysis, and article writing. Yeqing Sun and Jincheng Zhang participated in the operation. Shijie Li collected the data. Yeqing Sun and Shimin Chang reviewed the content of the article. Yingqi Zhang and Zhitao Rao contributed equally to this work.

Acknowledgments

This work was granted by the Clinical Technology Innovation Project of Shanghai Shenkang Hospital Development

Center (No. SHDC12017X15) and the Shanghai Municipal Health Commission Clinical Research (No. 20184Y0279 and 201740078).

References

- [1] K. H. Widmer and B. Zurfluh, "Compliant positioning of total hip components for optimal range of motion," *Journal of Orthopaedic Research*, vol. 22, no. 4, pp. 815–821, 2004.
- [2] D. D. D'lima, A. G. Urquhart, K. O. Buehler, R. H. Walker, and C. W. Colwell JR., "The effect of the orientation of the acetabular and femoral components on the range of motion of the hip at different head-neck ratios," *The Journal of Bone and Joint Surgery. American Volume*, vol. 82, no. 3, pp. 315–321, 2000.
- [3] T. Y. Tsai, D. Dimitriou, G. Li, and Y. M. Kwon, "Does total hip arthroplasty restore native hip anatomy? Three-dimensional reconstruction analysis," *International Orthopaedics*, vol. 38, no. 8, pp. 1577–1583, 2014.
- [4] T. Y. Tsai, J. S. Li, D. Dimitriou, and Y. M. Kwon, "Does component alignment affect gait symmetry in unilateral total hip arthroplasty patients?," *Clinical Biomechanics*, vol. 30, no. 8, pp. 802–807, 2015.
- [5] G. D. Wera, N. T. Ting, M. Moric, W. G. Paprosky, S. M. Sporer, and C. J. Della Valle, "Classification and management of the unstable total hip arthroplasty," *The Journal of Arthroplasty*, vol. 27, no. 5, pp. 710–715, 2012.
- [6] M. A. Belzunce, J. Henckel, A. di Laura, and A. Hart, "Uncemented femoral stem orientation and position in total hip arthroplasty: a CT study," *Journal of Orthopaedic Research*, vol. 38, no. 7, pp. 1486–1496, 2020.
- [7] Y. Wako, J. Nakamura, M. Miura, Y. Kawarai, M. Sugano, and K. Nawata, "Interobserver and intraobserver reliability of three-dimensional preoperative planning software in total hip arthroplasty," *The Journal of Arthroplasty*, vol. 33, no. 2, pp. 601–607, 2018.
- [8] E. Sariali, R. Mauprivez, F. Khiami, H. Pascal-Moussellard, and Y. Catonné, "Accuracy of the preoperative planning for cementless total hip arthroplasty. A randomised comparison between three-dimensional computerised planning and conventional templating," *Orthopaedics & Traumatology, Surgery & Research*, vol. 98, no. 2, pp. 151–158, 2012.
- [9] L. Renner, V. Janz, C. Perka, and G. I. Wassilew, "What do we get from navigation in primary THA?," *EFORT open reviews*, vol. 1, no. 5, pp. 205–210, 2016.
- [10] D. Dimitriou, T. Y. Tsai, and Y. M. Kwon, "The effect of femoral neck osteotomy on femoral component position of a primary cementless total hip arthroplasty," *International Orthopaedics*, vol. 39, no. 12, pp. 2315–2321, 2015.
- [11] T. Small, V. Krebs, R. Molloy, J. Bryan, A. K. Klika, and W. K. Barsoum, "Comparison of acetabular shell position using patient specific instruments vs. standard surgical instruments: a randomized clinical trial," *The Journal of Arthroplasty*, vol. 29, no. 5, pp. 1030–1037, 2014.
- [12] M. Olsen, D. D. Naudie, M. R. Edwards, M. E. Sellan, R. W. McCalden, and E. H. Schemitsch, "Evaluation of a patient specific femoral alignment guide for hip resurfacing," *The Journal of Arthroplasty*, vol. 29, no. 3, pp. 590–595, 2014.
- [13] Q. Q. Xing, D. Zhong, Y. X. Pan et al., "A comparative study of patients' subjective feelings toward total hip arthroplasty with

- patient-specific instruments and traditional total hip arthroplasty,” *Orthopaedic Surgery*, vol. 12, no. 1, pp. 269–276, 2020.
- [14] J. Henckel, T. J. Holme, W. Radford, J. A. Skinner, and A. J. Hart, “3D-printed patient-specific guides for hip arthroplasty,” *The Journal of the American Academy of Orthopaedic Surgeons*, vol. 26, no. 16, pp. e342–e348, 2018.
- [15] M. O. Gauci, P. Boileau, M. Baba, J. Chaoui, and G. Walch, “Patient-specific glenoid guides provide accuracy and reproducibility in total shoulder arthroplasty,” *The bone & joint journal*, vol. 98-B, no. 8, pp. 1080–1085, 2016.
- [16] W. S. Murphy, H. H. Yun, B. Hayden, J. H. Kowal, and S. B. Murphy, “The safe zone range for cup anteversion is narrower than for inclination in THA,” *Clinical Orthopaedics and Related Research*, vol. 476, no. 2, pp. 325–335, 2018.
- [17] S. D. Steppacher, J. H. Kowal, and S. B. Murphy, “Improving cup positioning using a mechanical navigation instrument,” *Clinical Orthopaedics and Related Research*, vol. 469, no. 2, pp. 423–428, 2011.
- [18] T. Hananouchi, M. Saito, T. Koyama, N. Sugano, and H. Yoshikawa, “Tailor-made surgical guide reduces incidence of outliers of cup placement,” *Clinical Orthopaedics and Related Research*, vol. 468, no. 4, pp. 1088–1095, 2010.
- [19] L. D. Dorr, A. Malik, M. Dastane, and Z. Wan, “Combined anteversion technique for total hip arthroplasty,” *Clinical Orthopaedics and Related Research*, vol. 467, no. 1, pp. 119–127, 2009.
- [20] M. Hirata, Y. Nakashima, D. Hara et al., “Optimal anterior femoral offset for functional range of motion in total hip arthroplasty—a computer simulation study,” *International Orthopaedics*, vol. 39, no. 4, pp. 645–651, 2015.
- [21] H. Abe, T. Sakai, M. Takao, T. Nishii, N. Nakamura, and N. Sugano, “Difference in stem alignment between the direct anterior approach and the posterolateral approach in total hip arthroplasty,” *The Journal of Arthroplasty*, vol. 30, no. 10, pp. 1761–1766, 2015.
- [22] J. D. Koerner, N. M. Patel, R. S. Yoon, M. S. Sirkin, M. C. Reilly, and F. A. Liporace, “Femoral version of the general population: does “normal” vary by gender or ethnicity?,” *Journal of Orthopaedic Trauma*, vol. 27, no. 6, pp. 308–311, 2013.
- [23] L. D. Dorr, Z. Wan, A. Malik, J. Zhu, M. Dastane, and P. Deshmane, “A comparison of surgeon estimation and computed tomographic measurement of femoral component anteversion in cementless total hip arthroplasty,” *The Journal of Bone and Joint Surgery. American Volume*, vol. 91, no. 11, pp. 2598–2604, 2009.
- [24] A. P. Wines and D. McNicol, “Computed tomography measurement of the accuracy of component version in total hip arthroplasty,” *The Journal of Arthroplasty*, vol. 21, no. 5, pp. 696–701, 2006.
- [25] R. Mitsutake, H. Tanino, Y. Nishida, M. Higa, and H. Ito, “A simple angle-measuring instrument for measuring cemented stem anteversion during total hip arthroplasty,” *BMC Musculoskeletal Disorders*, vol. 21, no. 1, 2020.
- [26] Y. K. Lee, J. W. Kim, T. Y. Kim, Y. C. Ha, and K. H. Koo, “Validity of the intra-operative measurement of stem anteversion and factors for the erroneous estimation in cementless total hip arthroplasty using postero-lateral approach,” *Orthopaedics & Traumatology: Surgery & Research*, vol. 104, no. 3, pp. 341–346, 2018.
- [27] A. Marcovigi, L. Ciampalini, P. Perazzini, P. Caldora, G. Grandi, and F. Catani, “Evaluation of native femoral neck version and final stem version variability in patients with osteoarthritis undergoing robotically implanted total hip arthroplasty,” *The Journal of Arthroplasty*, vol. 34, no. 1, pp. 108–115, 2019.
- [28] T. Okada, S. Fukunishi, Y. Takeda et al., “Total hip arthroplasty using stem-first technique with navigation: the potential of achievement of the optimal combined anteversion being a risk factor for anterior cup protrusion,” *European Journal of Orthopaedic Surgery and Traumatology*, vol. 29, no. 4, pp. 807–812, 2019.
- [29] S. Lee, J. Y. Kim, J. Hong, S. H. Baek, and S. Y. Kim, “CT-based navigation system using a patient-specific instrument for femoral component positioning: an experimental in vitro study with a sawbone model,” *Yonsei Medical Journal*, vol. 59, no. 6, pp. 769–780, 2018.