

4D-SPECT/CT in orthopaedics: a new method of combined quantitative volumetric 3D analysis of SPECT/CT tracer uptake and component position measurements in patients after total knee arthroplasty

Helmut Rasch · Anna L. Falkowski · Flavio Forrer ·
Johann Henckel · Michael T. Hirschmann

Received: 28 February 2013 / Revised: 13 April 2013 / Accepted: 28 April 2013 / Published online: 22 May 2013
© ISS 2013

Abstract

Objective The purpose was to evaluate the intra- and inter-observer reliability of combined quantitative 3D-volumetric single-photon emission computed tomography (SPECT)/CT analysis including size, intensity and localisation of tracer uptake regions and total knee arthroplasty (TKA) position. **Materials and methods** Tc-99m-HDP-SPECT/CT of 100 knees after TKA were prospectively analysed. The anatomical areas represented by a previously validated localisation scheme were 3D-volumetrically analysed. The maximum intensity was recorded for each anatomical area. Ratios between the respective value and the mid-shaft of the femur as the reference were calculated. Femoral and tibial TKA position (varus–valgus, flexion–extension, internal rotation– external rotation) were determined on 3D-CT. Two consultant radiologists/nuclear medicine physicians interpreted the SPECT/CTs twice with a 2-week interval. The inter- and intra-observer reliability was determined (ICCs). Kappa values were calculated for the area with the highest tracer uptake between the observers.

Results The measurements of tracer uptake intensity showed excellent inter- and intra-observer reliabilities for all regions (tibia, femur and patella). Only the tibial shaft area showed ICCs <0.89. The kappa values were almost perfect (0.856, $p < 0.001$; 95 % CI 0.778, 0.922). For

measurements of the TKA position, there was strong agreement within and between the readings of the two observers; the ICCs for the orientation of TKA components for inter- and intra-observer reliability were nearly perfect (ICCs >0.84).

Conclusion This combined 3D-volumetric standardised method of analysing the location, size and the intensity of SPECT/CT tracer uptake regions (“hotspots”) and the determination of the TKA position was highly reliable and represents a novel promising approach to biomechanics.

Keywords Knee · Total knee arthroplasty · 3D voxel analysis · Intra- and inter-observer reliability · SPECT-CT · Component position

Introduction

Single-photon emission computed tomography (SPECT)/CT is becoming an increasingly available diagnostic imaging modality worldwide [1–8]. The clinical diagnostic benefits of SPECT/CT for orthopaedic patients such as the combination of functional, structural and mechanical information have been particularly highlighted for patients with problems after total knee arthroplasty (TKA) [4, 8–11] (Figs. 1, 2 and 3).

Hirschmann et al. reported a standardised, validated and highly reliable anatomical localisation scheme, which they used to identify typical distribution patterns of areas indicating increased or decreased SPECT/CT tracer intensity [8]. The analysis of SPECT tracer uptake was performed using a Likert scale in a semiquantitative manner on 2D axial, coronal and sagittal slices [8]. Others used more descriptive methods to characterise areas of altered SPECT tracer uptake [1, 9, 11–13].

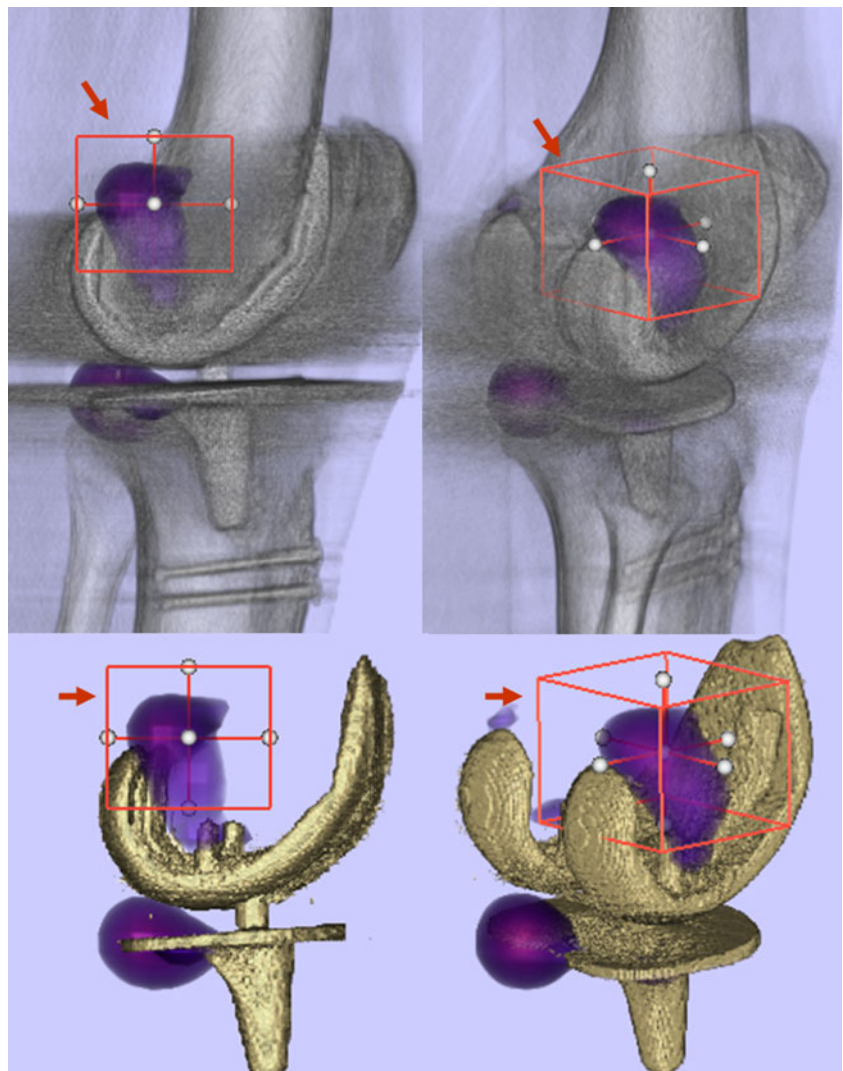
M. T. Hirschmann (✉)

Department of Orthopaedic Surgery and Traumatology,
Kantonsspital Baselland, 4101 Bruderholz, Switzerland
e-mail: Michael_Hirschmann@web.de

H. Rasch · A. L. Falkowski · F. Forrer
Institute for Radiology and Nuclear Medicine,
Kantonsspital Baselland, 4101 Bruderholz, Switzerland

J. Henckel
Imperial College London, London, UK

Fig. 1 3D-voxel based single-photon emission computed tomography (SPECT) tracer uptake analysis (OrthoImagingSolutions, London, UK): definition of a sample volume in the SPECT data set (*red box, red arrow*) and 3D-voxel-based quantification of absolute maximum, minimum and mean uptake values in different anatomical areas



Another limitation of the conventional analysis techniques is that only areas of increased tracer intensity were considered and lower intensity SPECT values were neglected [14]. In our experience the distribution pattern of SPECT tracer uptake is at least equally as important for accurate and correct establishment of the diagnosis [4, 14].

Striving for improvement of SPECT data analysis we have introduced a novel method of 3D-volumetric quantification, normalisation and thresholding of SPECT data [14]. Such a three-dimensional approach to SPECT data analysis promises a richer source of clinical information and allows quantitative comparison of SPECT/CT measurements across patients [14]. Together with the determination of TKA component position in 3D-CT, it represents a novel approach to biomechanics in patients after TKA [15].

The primary purpose of this study was to evaluate the inter- and intra-observer reliability of a standardised approach to combined quantitative 3D-volumetric SPECT/

CT analysis including assessment of the size, the intensity and the localisation of enhanced tracer uptake regions and determination of the TKA component position on 3D-CT. With the introduction of this analysis tool we aim to improve the process of establishing the diagnosis in patients with painful TKA. SPECT/CT could then be considered a screening tool and outcome measure in clinical trials.

Materials and methods

A total of 100 knees (male:female = 34:66, mean age \pm standard deviation 70 ± 11 years; right:left = 53:47) after total knee arthroplasty (TKA) that underwent Tc-99m-HDP-SPECT/CT were prospectively collected. Included was a consecutive series of patients undergoing SPECT/CT because of persistent pain after TKA. Patients who had previously undergone a revision TKA were excluded. The mean time from primary TKA to the date of

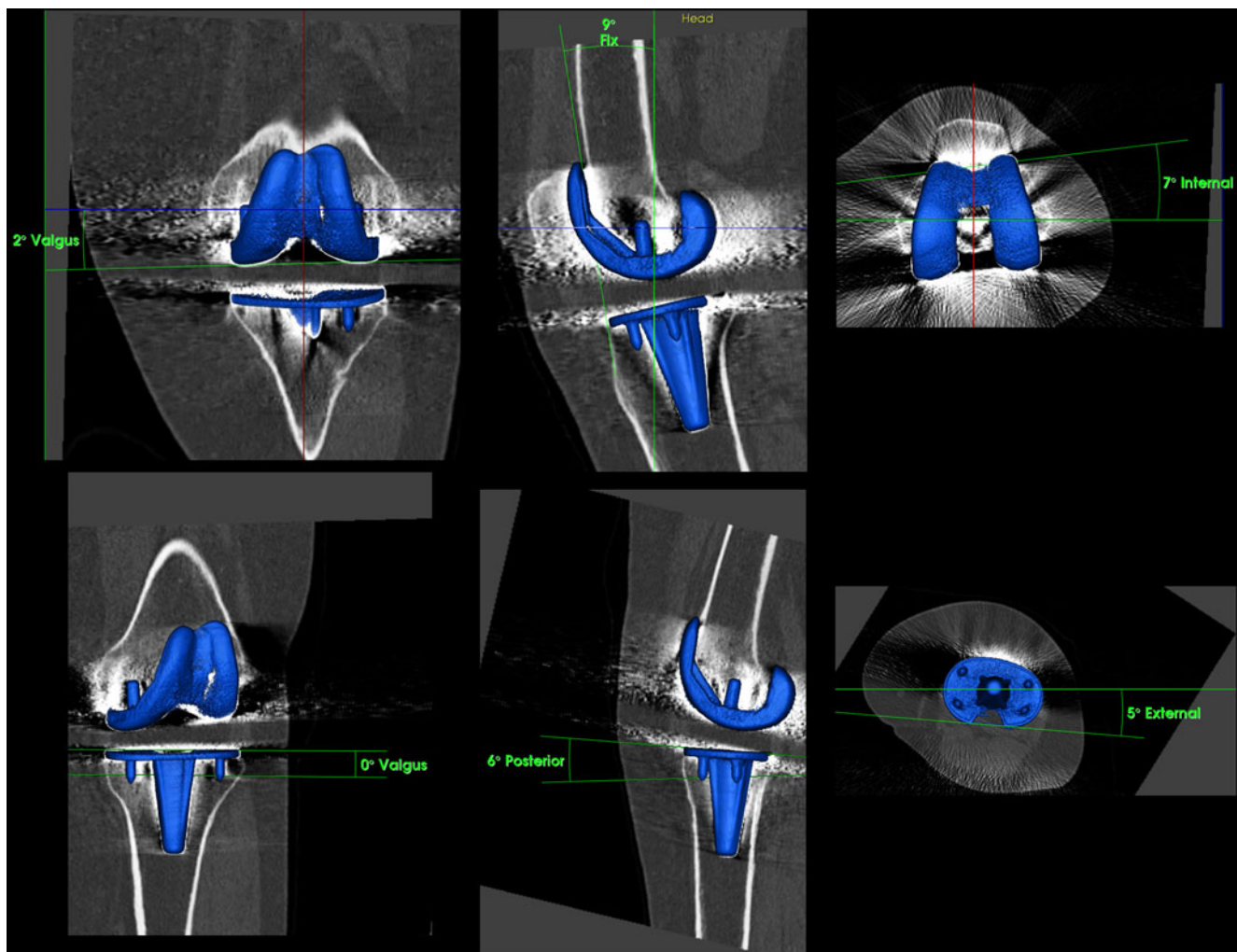


Fig. 2 Determination of tibial and femoral total knee arthroplasty (TKA) component position (varus–valgus, flexion–extension, internal rotation–external rotation) on 3D-CT using customised software after

reorientation in relation to the mechanical axis and definition of anatomical landmarks on the bone surface (OrthoImagingSolutions, London, UK)

SPECT/CT imaging was 48 ± 48 months. The study was approved by our local ethics committee.

^{99m}Tc-HDP-SPECT/CT

All patients received a commercial 700 MBq (18.92 mCi) Tc-99m-HDP injection (Malinckrodt, Wollerau, Switzerland). Tc-99m-HPD-SPECT/CT was performed using a hybrid system (Symbia T16; Siemens, Erlangen, Germany), which consists of dual head camera with a pair of low-energy, high-resolution collimators and an integrated full diagnostic CT with 16×0.75 -mm collimation. Planar scintigraphic images were taken in the perfusion phase (immediately after injection), the blood pool phase (2 to 5 min after injection) and the delayed metabolic phase (2–3 h after injection) followed by the SPECT/CT. For SPECT acquisition we used the step and shoot mode (32 steps/25 s) with a matrix of 128×128 . The CT protocol was modified according to the Imperial Knee

Protocol, which is a low-dose CT protocol that includes high-resolution 0.75-mm slices of the knee and 3-mm slices of the hip and ankle joints [16]. This protocol allows accurate determination of mechanical alignment and TKA component positions in 3D.

For tracer uptake analysis (intensity and anatomical distribution pattern) the 3D-reconstructed datasets of the delayed SPECT/CT images were used. The anatomical areas represented by a previously validated localisation scheme were 3D-volumetrically measured in terms of SPECT/CT tracer uptake values [8, 14]. This localisation scheme for patients after primary TKA consists of 9 tibial, 9 femoral and 4 patellar regions around TKA components to accurately map tracer uptake activity [4, 8]. The maximum intensity values were recorded for each anatomical area. In addition, ratios between the respective value in the measured area and the background tracer activity measured at the proximal end of the femoral field of view (FOV) were calculated.

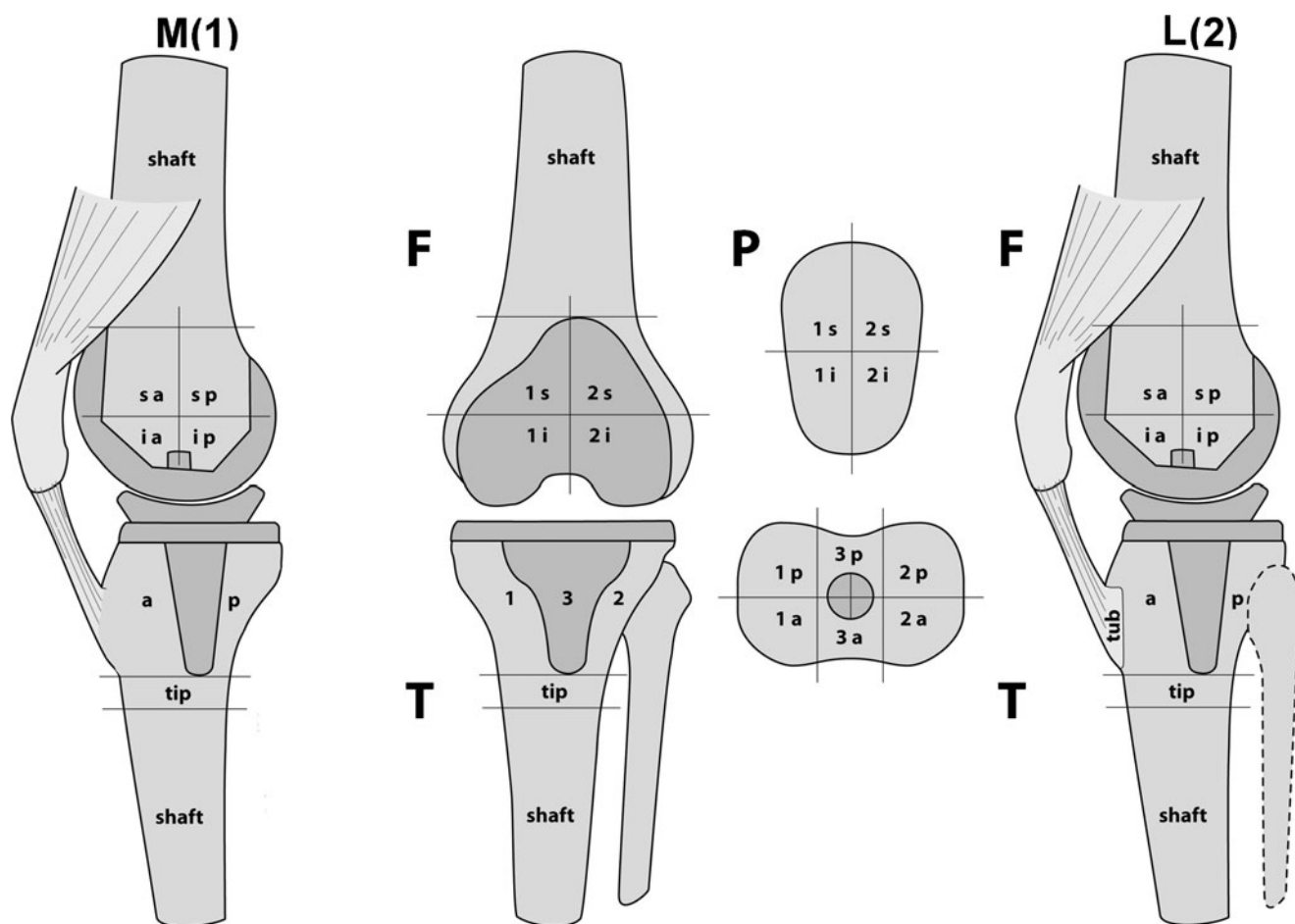


Fig. 3 The previously validated SPECT/CT scheme used for localisation of the Tc-99m HDP tracer activity in patients with painful knees after primary total knee arthroplasty. *F* femur, *T* tibia, *P* patella, *I*

medial, *2* lateral, *3* central around stem, *a* anterior, *p* posterior, *i* inferior, *s* superior, shaft, tip and tubercle. Reprinted with permission. Publication can be found at www.springerlink.com [11]

Measurements of TKA component position in 3D-CT

The position of the femoral and tibial TKA component was assessed on 3D-CT after reorientation to the mechanical axis. The sagittal (flexion–extension), coronal (varus–valgus) and rotational alignment (internal rotation– external rotation) of the femoral and tibial TKA components were determined on 3D-reconstructed CT images using customised software (OrthoImagingSolutions, London, UK). The rotation of the femoral component (femoral posterior component axis) was measured in relation to the anatomical transepicondylar axis. The rotation of the tibial component (tibial posterior component axis) was measured in relation to the posterior tibial plateau axis. One consultant radiologist/nuclear medicine specialist and one radiologist interpreted the SPECT/CTs for tracer uptake and component analysis twice with a 2-week interval between interpretations in a random order. Both were blinded to results from previous observations.

All data were analysed by an independent professional statistician using SPSS version 17.0 (SPSS, Chicago, IL,

USA.). Sample size was estimated according to the reported estimates for reliability studies using intraclass correlation coefficients (ICCs) [17].

The inter- and intra-observer reliability of the intensity and distribution analysis of SPECT/CT were determined by calculating the intraclass correlation coefficients (ICC). An ICC value of 1 indicated perfect reliability, 0.81 to 1 very good reliability and 0.61 to 0.80 good reliability [17].

In addition, an inter-observer reliability analysis using the Kappa statistic was performed to determine consistency on the area with the highest tracer uptake. Kappa values of < 0 represent poor, 0.0–0.20 slight, 0.21–0.40 fair, 0.41–0.60 moderate, 0.61–0.80 substantial and 0.81–1.00 an almost perfect agreement [18].

Results

All hotspots (areas with increased tracer uptake) were present in the localisation scheme and could be located to

Table 1 Absolute tracer intensity values measured for each anatomical area and both observers

	Observer 1					Observer 2					Both				
	Mean	Standard deviation	Median	Minimum	Maximum	Mean	Standard deviation	Median	Minimum	Maximum	Mean	Standard deviation	Median	Minimum	Maximum
f shaft	196.9	113.8	180	40	722	178.5	115.4	150	27	722	187.9	111.5	166	34	722
f med sa	472.4	389.1	381	47	2,550	442.8	383.8	364	38	2,550	457.7	384.3	379	43	2,550
f med sp	561.2	505.4	438	57	3,730	557.6	509.4	427	57	3,730	559.5	506.6	427	57	3,730
f med ia	441.9	308.7	360	31	1,652	427.3	303.1	353	30	1,652	434.8	303.2	367	31	1,652
f med ip	514.9	379.2	435	36	1,892	513.4	381.4	429	41	1,892	514.2	379.7	427	40	1,892
f lat sa	580.1	522.2	432	65	3,462	527.2	473.2	412	65	3,389	553.8	491.2	423	65	3,426
f lat sp	605.8	530.6	531	74	3,465	602.4	527.6	531	78	3,465	604.2	527.6	531	76	3,465
f lat ia	492.3	419.1	382	70	2,397	480.1	418.3	377	70	2,397	486.3	416.8	375	70	2,397
f lat ip	569.1	406.3	433	95	2,365	563.2	407.7	448	95	2,365	566.2	406	430	95	2,365
t med a	511.3	285.1	470	54	1,581	496.9	275.7	479	54	1,581	504.2	278.2	463	54	1,581
t med p	569.2	315.8	525	71	1,439	568.7	319.7	520	74	1,368	569	316.1	520	74	1,404
t lat a	483.3	275.3	460	77	1,496	488.5	277.2	457	77	1,496	485.9	274.3	460	77	1,496
t lat p	519.2	299.3	452	54	1,350	527.9	298.8	475	54	1,350	523.6	292.7	467	54	1,350
t stem	459.4	269.4	408	48	1,383	490.1	280.9	434	49	1,339	474.9	271.9	422	49	1,361
t tip	279.7	186.8	237	37	1,202	266.8	173.2	226	55	1,113	273.4	177.8	232	48	1,158
t shaft	214.2	113.5	189	46	552	161.1	82.8	146	34	378	187.9	93.8	174	41	428
p med s	591.8	386.5	512	77	1,852	597.4	398.4	502	77	1,852	594.7	390.7	508	77	1,852
p med i	527.7	333.2	500	61	1,715	521.6	347.9	483	61	1,775	524.8	336.9	490	61	1,715
p lat s	622.2	419.4	519	97	1,845	603.1	405.3	493	101	1,841	612.8	409.3	503	100	1,843
p lat i	566.6	394.1	463	103	1,602	552.8	396.3	440	98	1,760	559.9	390.7	442	103	1,602
p total	713.2	446.3	620	108	1,852	703.1	447.1	620	108	1,852	708.2	445.4	639	108	1,852

f femur, t tibia, p patella, sa superior–anterior, sp superior–posterior, ia inferior–anterior, ip inferior–posterior, med medial, lat lateral

Table 2 Relative tracer intensity ratios for both observers: for each anatomical area the maximum uptake value is divided by the maximum uptake measured at the distal femur shaft (background activity)

Area	Observer 1					Observer 2					Both				
	Mean	Standard deviation	Median	Minimum	Maximum	Mean	Standard deviation	Median	Minimum	Maximum	Mean	Standard deviation	Median	Minimum	Maximum
f shaft	1	0	1	1	1	1	0	1	1	1	1	0	1	1	1
f med sa	2.49	1.52	2.14	0.99	11.33	2.7	2.17	2.33	0.54	20.24	2.54	1.67	2.28	0.86	14.49
f med sp	2.88	1.95	2.46	0.9	16.58	3.36	3.07	2.87	0.8	29.6	3.05	2.31	2.77	0.94	21.19
f med ia	2.32	1.24	2.06	0.57	7.81	2.65	1.61	2.32	0.5	10.7	2.42	1.32	2.27	0.54	7.66
f med ip	2.69	1.59	2.39	0.76	11.76	3.11	1.85	2.84	0.55	12.6	2.82	1.61	2.51	0.72	10.98
f lat sa	3.06	2.23	2.76	1.1	15.64	3.22	2.51	2.62	0.56	18.72	3.08	2.15	2.65	0.92	13.91
f lat sp	3.23	1.92	2.78	1.02	13.02	3.75	2.77	3.31	0.94	23.25	3.4	2.15	2.98	1.07	16.65
f lat ia	2.6	1.66	2.35	0.66	12.89	2.87	1.69	2.49	0.62	10.24	2.67	1.58	2.35	0.69	11.41
f lat ip	3.07	1.49	2.8	0.48	6.95	3.5	1.86	3.22	0.62	10.84	3.21	1.54	2.92	0.54	7.24
t med a	2.85	1.56	2.46	0.75	8.49	3.23	1.9	2.9	0.7	12.35	2.97	1.63	2.62	0.85	9.69
t med p	3.22	1.93	2.67	0.67	9.74	3.72	2.27	3.12	0.63	10.98	3.39	2	2.82	0.67	9.15
t lat a	2.68	1.4	2.29	0.68	8.25	3.15	1.76	2.9	0.68	11.95	2.84	1.48	2.61	0.68	9.37
t lat p	2.91	1.62	2.52	0.5	10.23	3.41	1.88	3	0.61	10.27	3.08	1.61	2.73	0.62	9.68
t stem	2.5	1.3	2.19	0.77	8.1	3.12	1.77	2.75	0.79	12.35	2.74	1.42	2.37	0.79	9.69
t tip	1.48	0.66	1.36	0.21	4.49	1.68	0.81	1.67	0.21	4.37	1.55	0.67	1.4	0.21	3.58
t shaft	1.17	0.44	1.08	0.18	2.71	1.02	0.42	0.98	0.17	2.73	1.08	0.38	1.02	0.18	2.38
p med s	3.21	1.98	2.85	0.81	12.85	3.73	2.19	3.45	0.86	11.51	3.38	2	2.94	0.89	12
p med i	2.93	1.93	2.55	0.27	13.5	3.35	2.2	2.89	0.83	11.83	3.07	1.97	2.63	0.6	12.61
p lat s	3.36	2.05	2.95	1	11.04	3.76	2.21	3.26	0.88	10.4	3.47	2	3	1.03	10.31
p lat i	3.08	2	2.57	0.83	11.83	3.51	2.29	2.83	0.78	11.43	3.22	2.02	2.69	0.83	11.04
p total	3.9	2.25	3.49	1	13.5	4.48	2.61	3.92	0.97	11.83	4.08	2.29	3.69	1.03	12.61

specific anatomical regions of the localisation scheme. The absolute measurements of tracer intensity for each anatomical area and the ratios (in relation to the background intensity of the distal femur) of both observers are presented in Tables 1 and 2.

The measurements of tracer uptake intensity using this 3D voxel-based analysis showed very good inter- and intra-observer reliabilities for all regions (tibia, femur and patella). Only the tibial shaft area showed ICCs <0.89.

The detailed ICCs for the absolute values and the ratios (relative to the background tracer uptake in the mid-femoral shaft) are presented in Table 3.

Table 4 compares the areas indicating the maximum tracer uptake when measured by each observer. The inter-observer reliability for the agreement on the area with the highest tracer uptake was found to be almost perfect $Kappa=0.856$ ($p<0.001$; 95 % CI 0.778, 0.922).

For measurement of the femoral and tibial component position, there was strong agreement between the readings of the two observers; the ICCs for the orientation of the femoral and tibial components for inter- and intra-observer reliability were >0.84, which is nearly perfect. The mean differences \pm standard deviation in femoral and tibial measurements between the two observers (inter-observer) are presented in Table 5.

Discussion

The proposed method of combined quantitative 3D analysis of SPECT tracer uptake and measurements of TKA component position reflects a novel approach to biomechanics in patients after TKA.

The most important findings and implications of our present study are threefold:

First, the measurements of SPECT tracer uptake intensity using this 3D voxel-based analysis showed very good inter- and intra-observer reliabilities for all regions (tibia, femur and patella). The maximum uptake value in each anatomical area was almost perfectly reliable. The presented SPECT analysis method proved to be a valuable, consistent, reliable and useful tool in characterising tracer activity in patients with primary TKA. There was strong agreement for inter- and intra-observer reliability in the areas with the highest SPECT tracer uptake in each dataset. Taking only the area of highest tracer uptake into account for the establishment of a typical pathology-related SPECT distribution uptake pattern could facilitate SPECT data analysis for clinical routine. Using this approach typical SPECT/CT tracer uptake patterns should be identified for pathological conditions such as femoral or tibial loosening, patellofemoral hyperpression or instability, each specific type of TKA, component position and mechanical alignment [4].

Table 3 Intra- und inter-observer reliability (ICCs for absolute single-photon emission computed tomography [SPECT] values, relative SPECT values) of 3D voxel-based SPECT uptake measurement

Area	Absolute values			Ratio F shaft			Ratio T shaft		
	ICC	95 % CI		ICC	95 % CI		ICC	95 % CI	
f shaft	0.892	0.844	0.926	—	—	—	0.723	0.615	0.805
f med sa	0.978	0.967	0.985	0.795	0.709	0.857	0.913	0.874	0.941
f med sp	0.994	0.991	0.996	0.831	0.759	0.883	0.881	0.828	0.918
f med ia	0.965	0.948	0.976	0.805	0.724	0.865	0.857	0.794	0.901
f med ip	0.994	0.991	0.996	0.848	0.781	0.895	0.855	0.792	0.900
f lat sa	0.943	0.917	0.961	0.812	0.733	0.870	0.919	0.881	0.945
f lat sp	0.988	0.982	0.992	0.818	0.741	0.874	0.911	0.870	0.939
f lat ia	0.982	0.974	0.988	0.843	0.776	0.892	0.871	0.815	0.912
f lat ip	0.990	0.986	0.994	0.789	0.702	0.853	0.861	0.800	0.904
t med a	0.969	0.954	0.979	0.833	0.762	0.885	0.863	0.802	0.905
t med p	0.979	0.969	0.986	0.877	0.822	0.916	0.874	0.818	0.913
t lat a	0.971	0.958	0.981	0.816	0.739	0.873	0.827	0.753	0.880
t lat p	0.916	0.877	0.942	0.794	0.708	0.857	0.761	0.664	0.833
t stem	0.953	0.931	0.968	0.783	0.694	0.849	0.815	0.737	0.872
t tip	0.947	0.922	0.964	0.734	0.628	0.813	0.615	0.477	0.724
t shaft	0.785	0.697	0.850	0.542	0.388	0.667	—	—	—
p med s	0.981	0.973	0.987	0.879	0.826	0.917	0.837	0.766	0.887
p med i	0.956	0.936	0.970	0.867	0.809	0.909	0.793	0.707	0.856
p lat s	0.971	0.957	0.980	0.844	0.776	0.892	0.847	0.780	0.894
p lat i	0.955	0.934	0.970	0.847	0.781	0.895	0.820	0.743	0.875
p total	0.989	0.983	0.992	0.855	0.792	0.900	0.838	0.768	0.888

Table 4 Highest SPECT tracer uptake value with regard to anatomical areas shown for each observer (*Obs1*, *Obs 2*)

Area	Frequency Obs 1	Percentage Obs 1	Frequency Obs 2	Percentage Obs 2
f shaft	–	–	1	1.0
f med sa	–	–	–	–
f med sp	5	5.0	5	5.0
f med ia	–	–	–	–
f med ip	4	4.0	5	5.0
f lat sa	4	4.0	2	2.0
f lat sp	7	7.0	8	8.0
f lat ia	2	2.0	2	2.0
f lat ip	7	7.0	5	5.0
t med a	3	3.0	3	3.0
t med p	13	13.0	14	14.0
t lat a	2	2.0	2	2.0
t lat p	12	12.0	11	11.0
t tip	1	1.0	1	1.0
p med s	15	15.0	18	18.0
p med i	3	3.0	6	6.0
p lat s	11	11.0	10	10.0
p lat i	11	11.0	7	7.0

Inter-observer reliability analysis Kappa=0.856 ($p<0.001$; 95 % CI 0.778, 0.922)

Second, the distal femoral shaft region was identified as perfect reference region to build ratios between the measured SPECT values in each anatomical area and the SPECT background activity of the reference region. The tibial shaft region, which is also visible within the field of view of our SPECT/CT protocol, showed inferior inter- and intra-observer reliability. This might be due to the variable tibial anatomy. Hence, the femoral shaft area should be used to normalise the measured SPECT data.

This finding is a very important one as reference regions that represent SPECT background intensity are mandatory when aiming for an improved inter- and intra-patient comparison [14].

Generally, the measured SPECT tracer intensity for each anatomical region represents an individualised intensity grading, which is only valid within each patient at the time of SPECT and not directly comparable between patients, it is only possible to compare relative values (ratios), for example the activity in one region relative to the activity of the distal femoral shaft of the same patient [14]. Normalisation of SPECT data using ratios of absolute measures in the areas of interest in relation to absolute measures in reference regions, e.g. distal shaft of the femur, is an important cornerstone of SPECT data analysis [14].

Third, the determination of femoral and tibial TKA component position in 3D-CT was highly reliable. Based on our findings, we recommend the use of the proposed method for determining the rotational, sagittal and coronal orientation of the components after TKA. The described method is clinically easily applicable, highly reproducible and the measurements can be performed within 5 min per dataset. This new method enables radiologists, nuclear medicine physicians or orthopaedic surgeons to describe the accuracy of placement of the components with confidence.

To date, the accurate determination of TKA component position relating to the mechanical axis on 3D-CT has only been feasible using customised software, which is not tailored for this purpose and thus too complicated to use in clinical routine. Hence, most authors used axial 2D-CT slices for measurement of component position, although it has been shown that these measurements are very variable and less reliable [15].

Table 5 Mean angles \pm standard deviation of each observer and intraclass correlation coefficients (intra- and inter-observer reliability) of femoral and tibial component measurements

	Mean \pm SD	Mean difference \pm SD	ICCs intra-observer reliability	ICCs inter-observer reliability
Femoral component measurements				
Varus–valgus Obs1	0.30 \pm 2.50	0.40 \pm 0.44	0.99	0.99
Varus–vValgus Obs2	0.55 \pm 2.45		0.97	
Flexion–extension Obs1	5.77 \pm 4.22	0.76 \pm 0.67	0.97	0.99
Flexion–extension Obs2	5.53 \pm 4.18		0.97	
Internal–external rotation Obs1	2.36 \pm 3.47	1.65 \pm 1.81	0.92	0.85
Internal–external rotation Obs2	2.03 \pm 3.24		0.84	
Tibial component measurements				
Varus–valgus Obs1	−1.11 \pm 1.99	0.47 \pm 0.41	0.98	0.98
Varus–valgus Obs2	−1.19 \pm 2.07		0.94	
Anterior–posterior slope Obs1	4.16 \pm 3.85	0.62 \pm 0.57	0.99	0.99
Anterior–posterior slope Obs2	4.30 \pm 3.70		0.98	
Internal–external rotation Obs1	−2.93 \pm 7.17	3.06 \pm 2.70	0.95	0.93
Internal–external rotation Obs2	−4.88 \pm 7.03		0.89	

Conclusions

The proposed combined 3D-volumetric standardised method of analysing the location, size and the intensity of SPECT/CT tracer uptake regions (“hotspots”), as well as the determination of TKA component position, is highly reliable. It represents a novel, promising approach to the biomechanics of patients after TKA. Its clinical value will be further investigated in prospective clinical studies.

Acknowledgements We greatly thank the Gottfried und Julia Bangerter-Rhyner-Stiftung, Berne, Switzerland as well as the Deutsche Arthrose Hilfe e.V, Saarlouis, Germany for supporting our research.

Conflict of interest The authors declare that they have no conflict of interest.

References

1. Bybel B, Brunken RC, DiFilippo FP, Neumann DR, Wu G, Cerqueira MD. SPECT/CT imaging: clinical utility of an emerging technology. *Radiographics*. 2008;28(4):1097–113.
2. Delbeke D, Schöder H, Martin WH, Wahl RL. Hybrid imaging (SPECT/CT and PET/CT): Improving therapeutic decisions. *Semin Nucl Med*. 2009;39(5):308–40.
3. Gnanasegaran G, Barwick T, Adamson K, Mohan H, Sharp D, Fogelman I. Multislice SPECT/CT in benign and malignant bone disease: when the ordinary turns into the extraordinary. *Semin Nucl Med*. 2009;39(6):431–42.
4. Hirschmann MT, Konala P, Iranpour F, Kerner A, Rasch H, Friederich NF. Clinical value of SPECT/CT for evaluation of patients with painful knees after total knee arthroplasty—a new dimension of diagnostics? *BMC Musculoskelet Disord*. 2011;12:36.
5. Hirschmann MT, Schmid R, Dhawan R, et al. Combined single photon emission computerized tomography and conventional computerized tomography: clinical value for the shoulder surgeons? *Int J Shoulder Surg*. 2011;5(3):72–6.
6. Konala P, Iranpour F, Kerner A, Rasch H, Friederich NF, Hirschmann MT. Clinical benefit of SPECT/CT for follow-up of surgical treatment of osteochondritis dissecans. *Ann Nucl Med*. 2010;24(8):621–4.
7. Scharf S. SPECT/CT imaging in general orthopedic practice. *Semin Nucl Med*. 2009;39(5):293–307.
8. Hirschmann MT, Iranpour F, Konala P, et al. A novel standardized algorithm for evaluating patients with painful total knee arthroplasty using combined single photon emission tomography and conventional computerized tomography. *Knee Surg Sports Traumatol Arthrosc*. 2010;18(7):939.
9. Graute V, Feist M, Lehner S, et al. Detection of low-grade prosthetic joint infections using 99mTc-antigranulocyte SPECT/CT: initial clinical results. *Eur J Nucl Med Mol Imaging*. 2010;37(9):1751–9.
10. Hirschmann MT, Davda K, Iranpour F, Rasch H, Friederich NF. Combined single photon emission computerised tomography and conventional computerised tomography (SPECT/CT) in patellofemoral disorders: a clinical review. *Int Orthop*. 2011;35(5):675–80.
11. Hirschmann MT, Iranpour F, Davda K, Rasch H, Hugli R, Friederich NF. Combined single-photon emission computerized tomography and conventional computerized tomography (SPECT/CT): clinical value for the knee surgeons? *Knee Surg Sports Traumatol Arthrosc*. 2010;18(3):341–5.
12. Ahmad R, Kumar GS, Katam K, Dunlop D, Pozo JL. Significance of a “hot patella” in total knee replacement without primary patellar resurfacing. *Knee*. 2009;16(5):337–40.
13. Pagenstert GI, Barg A, Leumann AG, et al. SPECT-CT imaging in degenerative joint disease of the foot and ankle. *J Bone Joint Surg Br*. 2009;91(9):1191–6.
14. Hirschmann MT, Wagner CR, Rasch H, Henckel J. Standardized volumetric 3D-analysis of SPECT/CT imaging in orthopaedics: overcoming the limitations of qualitative 2D analysis. *BMC Med Imaging*. 2012;12(1):5.
15. Hirschmann MT, Konala P, Amsler F, Iranpour F, Friederich NF, Cobb JP. The position and orientation of total knee replacement components: a comparison of conventional radiographs, transverse 2D-CT slices and 3D-CT reconstruction. *J Bone Joint Surg Br Vol*. 2011;93(5):629–33.
16. Henckel J, Richards R, Lozhkin K, et al. Very low-dose computed tomography for planning and outcome measurement in knee replacement. The imperial knee protocol. *JBJS (Br)*. 2006;88(11):1513–8.
17. Walter SD, Eliasziw M, Donner A. Sample size and optimal designs for reliability studies. *Stat Med*. 1998;17(1):101–10.
18. Landis JR, Koch GG. The measurement of observer agreement for categorical data. *Biometrics*. 1977;33(1):159–74.