

CASE REPORT

A Case of Hepatocellular Carcinoma Treated by MR-guided Focused Ultrasound Ablation with Respiratory Gating

Atsuya OKADA¹, Takamichi MURAKAMI^{2*}, Koji MIKAMI³, Hiromitsu ONISHI³,
Noboru TANIGAWA⁴, Taro MARUKAWA¹, and Hironobu NAKAMURA³

¹Center of Diagnostic and Interventional Radiology, Iseikai Hospital

²Department of Radiology, Kinki University School of Medicine
377-2, Ohnohigashi, Osakasayama, Osaka 589-8511, Japan

³Department of Radiology, Osaka University Graduate School of Medicine

⁴Department of Radiology, Kansai Medical University

(Received July 11, 2006; Accepted September 14, 2006)

Focused ultrasound surgery (FUS) is a method of noninvasive focal thermal ablation. Temperature-sensitive phase-difference magnetic resonance (MR) imaging allows monitoring of the focal point and measurement of tissue temperature elevation in real time, ensuring delivery of a therapeutic dose. A newly developed respiratory monitoring system enables us to track liver tumors, which move with respiration. We report our initial experience using MR-guided FUS with respiratory gating in successfully treating a hepatocellular carcinoma 15 mm in diameter.

Keywords: *liver tumor, MRI, focused ultrasound surgery, interventional radiology, respiratory monitoring*

Introduction

In recent years, the effectiveness of image-guided techniques of liver tumor ablation, such as microwave coagulation, radiofrequency ablation (RFA), laser-induced thermotherapy, and cryotherapy, have been reported. However, these all require percutaneous insertion of a probe to deliver thermal energy into the tumor. Focused ultrasound ablation (FUS) is an alternative thermal ablation method. High, intensive ultrasound beams can be focused on precisely defined areas of tumor,¹ causing localized temperature elevation and coagulative necrosis without damaging surrounding normal tissue. FUS enables delivery of thermal energy to a precisely defined tumor deep in the body without insertion of a probe and without general anesthesia.

Magnetic resonance (MR) imaging has been used to guide and control FUS since the early 1990s.^{2,3} MR imaging provides precise localization of tumors, excellent anatomic resolution for precise targeting, and temperature sensitivity for measuring temperature elevation in treated tissue. The

technical feasibility of performing FUS with MR imaging to guide and monitor therapy has been established in both animal experiments and clinical trials for tumors, such as prostate cancer, breast tumor, and uterine fibroid.⁴⁻⁷ However, some problems occur at the time of clinical treatment of liver tumors with MR-guided FUS (MRgFUS) from such things as intervening ribs, lung air and bowel gas, and respiratory motion. To resolve the problem of respiratory motion, we developed a respiratory monitoring system compatible with MR.


We report our early experience using MRgFUS with respiratory monitoring to treat a patient with hepatocellular carcinoma.

Case Report

At 22 years, the patient was diagnosed with hepatitis B, and at 51, the patient underwent right anterior lobectomy of a tumor 7 cm in diameter that was found to be hepatocellular carcinoma. Multiple recurrent tumors detected in the liver 2 years later were treated with multiple sessions of transcatheter arterial embolization or RFA.

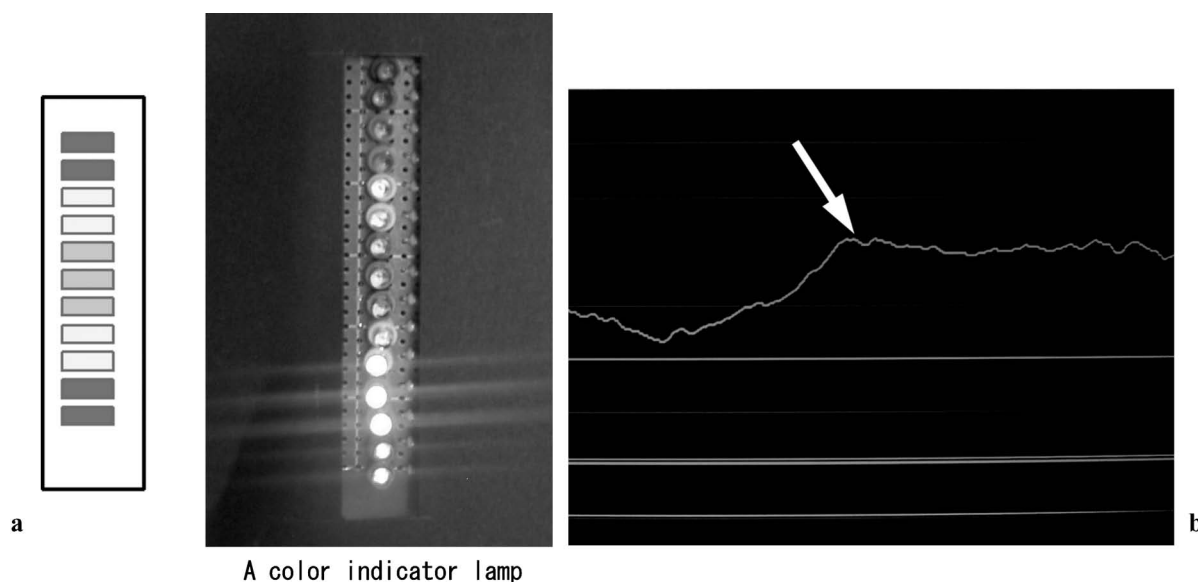
Soon after the local treatments, a lesion 15 mm in diameter was detected in the lateral segment of the liver. Because the patient refused treatment

*Corresponding author, Phone: +81-72-366-0221, Fax: +81-72-367-1685, E-mail: murakami@med.kindai.ac.jp



Belt with air pressure sensor

Fig. 1. Respiratory gating system. The respiratory cycle can be monitored using a magnetic resonance (MR)-compatible belt with an air pressure sensor.



A color indicator lamp

Fig. 2. Monitoring system of respiratory motion. **a:** The patient view a color indicator lamp inside the magnetic resonance (MR) room and, based on the indicator lamp's color, can hold breath at the same point in the respiratory cycle during sonications. **b:** The physician can see the patient's respiratory cycle on the monitor of a personal computer outside the MR room, near the focused ultrasound ablation (FUS) console. The line (arrow) shows the patient's respiratory phase, and the flat segment of the line indicates the status of breath-holding.

with RFA, informed consent was obtained to treat the lesion with MRgFUS, and approval of the institutional review board was obtained. We used a clinical FUS system (ExAblate® 2000; InSightec, Haifa, Israel) integrated with a 1.5T commercially available superconductive whole-body MR unit (Signa EchoSpeed; GE Healthcare, Milwaukee, Wisconsin, USA). We also used an MR-compatible respiratory monitoring system comprising a personal computer, color lamp indicator, and abdominal belt with pressure sensor (Figs. 1 and 2). The

patient viewed the color indicator lamp inside the MR room and was asked to breath hold during sonications when the green lamp flashed, which assisted the patient's breath holding at the same point in the respiratory cycle during each sonication (Fig. 2). The physician could monitor the patient's respiratory motion on a personal computer outside the MR room as well as on the FUS operating console.

Before FUS, we routinely administer intravenous (IV) conscious sedation with pethidine hydrochloride

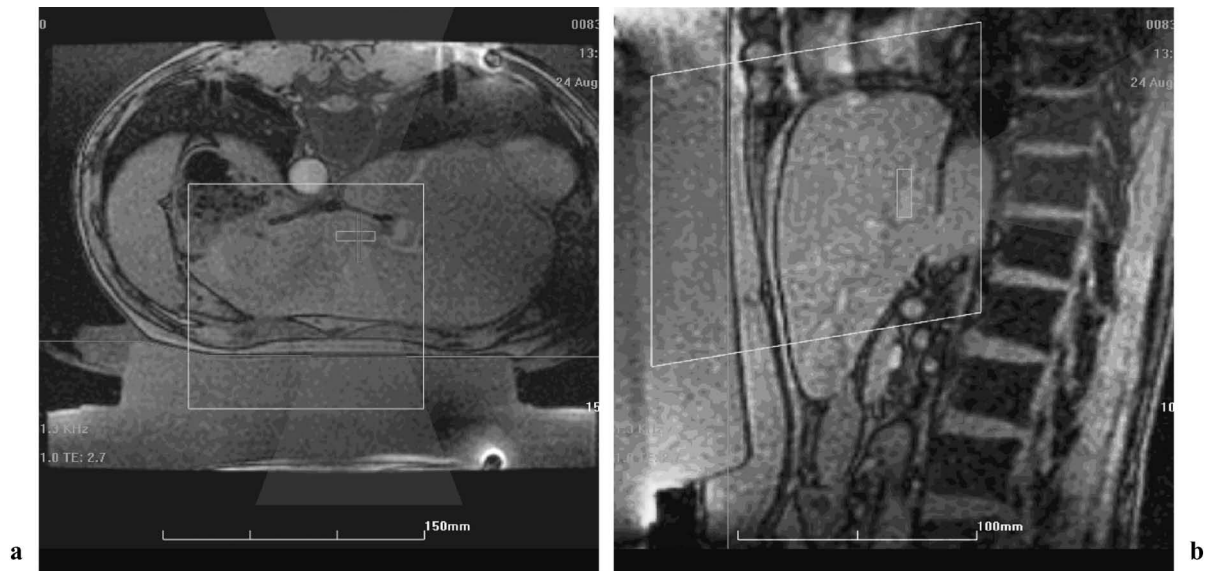


Fig. 3. Treatment planning (**a**: axial image, **b**: sagittal image). By evaluating the ultrasound beam path on pre-procedure T_2^* -weighted fast gradient echo images (repetition time/echo time [TR/TE], 51/2.7 ms; flip angle [FA], 30°), we avoid passage of energy through the bowel loops.

ride (Opystan, Tanabe Pharmaceutical, Tokyo, Japan), and we administered 52.5 mg in this case.

Using the respiratory gating system, we obtained breath-hold T_2^* -weighted gradient echo images in 3 planes through the liver (repetition time/echo time [TR/TE], 51/2.7 ms; flip angle [FA], 30° ; field of view [FOV], 360 mm \times 270 mm; matrix size, 192 \times 160; slice thickness, 5 mm with 1 mm gap). Based on these images, we used the MRgFUS operating system to measure tumor volume, draw the appropriate ablation target area, and manually define the ultrasound beam path to avoid passage of energy through ribs and bowel loops (Fig. 3). The operator can interactively modify the precise location of each sonication during treatment to completely cover the target volume. Using product software at the MRgFUS console, we defined the number and sequence of sonications needed to ablate the target tissue with sufficient thermal dose verified by MR thermometry. Before therapy, low-energy test sonications (typically 50–80 W for 18 s at 1.10 MHz) were directed to the target area. Power was increased until the temperature change could be determined on temperature-sensitive MR images (fast spoiled-gradient recalled-echo sequence; TR/TE, 25.2/12.5 ms; FA, 30°), which were used to estimate the temperature-dependent proton resonance frequency shift.⁸ We then administered a series of higher powered sonications (basically 150 W for 20 s at 1.10 MHz) until the thermal ablation temperature threshold (70° Centigrade) was reached in the target. Following each sonication, we measured the temperature elevation

and estimated the ablated volume on the basis of the temperature-sensitive MR images. Sonication parameters were changed to optimize treatment based on these real-time thermal maps. The procedure time of each session ranged from 120 to 240 s. To coagulate the tumor completely, sonication was overlapped and repeated on the same point of the tumor 42 times in total. During treatment, the patient had minor complaints of skin pain that did not preclude continued treatment. No other complication was seen. Total procedure time was about 120 min. After FUS, gadolinium-enhanced T_1 -weighted spoiled-gradient recalled-echo MR images (TR/TE, 6.4/2.8 s; FA, 10° ; FOV, 350 mm \times 263 mm; matrix size, 256 \times 128; slice thickness, 6 mm; Zip 2) showed no enhanced area within the lesion (Fig. 4), indicating that the tumor was fully ablated.

After treatment, the patient had no complaint, was observed overnight, and was discharged the next morning after review of post-treatment laboratory data showed no remarkable change.

Discussion

Wu and associates first reported the safety, efficacy, and feasibility of high-intensity FUS ablation of hepatocellular carcinomas.⁹ They performed FUS ablation with ultrasound guidance in patients under general anesthesia. Although ultrasonography can allow good target definition and focal spot control in some nonanesthetized patients able to hold their breath sufficiently long

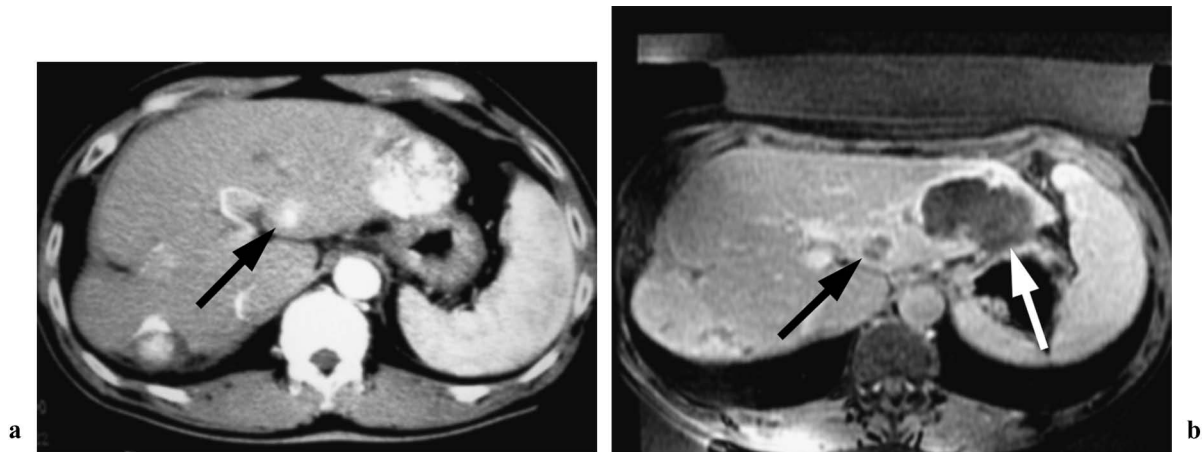


Fig. 4. Hepatocellular carcinoma. **a:** Enhanced computed tomographic (CT) image before focused ultrasound ablation (FUS). A small enhancing nodule 12 mm in diameter (arrow) can be seen on the arterial phase enhanced CT image before FUS. **b:** Gadolinium-enhanced T_1 -weighted spoiled gradient recalled-echo MR images (repetition time/echo time [TR/TE], 6.4/2.8 s; flip angle [FA], 10°) after FUS. After FUS, gadolinium-enhanced T_1 -weighted magnetic resonance (MR) image shows no enhancement of the entire lesion, indicating complete necrosis (black arrow). The large hepatocellular carcinoma (diameter, 5 cm) with iodized oil, seen in the lateral segment (white arrow), is the lesion previously treated with transcatheter arterial embolization with iodized oil that was not treated this time because it showed no sign of local recurrence.

at the same respiratory cycle, it does not allow monitoring of temperature elevation in treated tissue or detection of lesions deep in the body (remote from the transducer).

MR thermal mapping accurately portrays the treated area and enables real-time measurement of temperature elevation in the target area during treatment that enables user control of both the magnitude and time course of tissue heating during treatment.^{10,11} MR imaging also enables evaluation of the treated volume immediately after treatment.¹² Thus, the feasibility and safety of FUS greatly improved with the introduction of MR guidance. However, MRgFUS for liver tumors in humans has not been established because of technical hurdles, such as movement of the liver caused by respiration and difficulty of planning a beam path that avoids ribs and bowel loops.¹³ The respiratory monitoring system employed in this patient overcame the problem of liver motion during respiration. The tumor was located in the lateral segment of the liver, where there was no rib or bowel loop in the path of the ultrasound beam. The FUS system requires further development to enable beam paths that avoid these structures.

In this case, we treated a small tumor about 15 mm in diameter. However, the total procedure took about 120 min because sonication was overlapped and repeated on the same point of the tumor to coagulate the tumor completely. Treatment of larger tumors may require further development of

the FUS system or methods to enhance its effect, for example, the intravenous infusion of microbubbles.¹⁴

Because no needles or probes are inserted, FUS may be performed for a patient with ascites or bleeding tendency and without risk of tumor dissemination in the needle tract.

We believe that MRgFUS provides a less invasive method to treat small liver lesions, including primary and metastatic lesions, as well as local tumor recurrence after transcatheter arterial embolization or RFA. However, more clinical investigation and further device development is needed prior to routine clinical use.

References

1. Lynn JG, Zwemer RL, Chick AJ, et al. A new method for the generation and use of focused ultrasound in experimental biology. *J Gen Physiol* 1942; 26:179–193.
2. Jolesz FA, Jakab PD. Acoustic pressure wave generation within a MR imaging system: potential medical applications. *J Magn Reson Imaging* 1991; 1:609–613.
3. Hynynen K, Darkazanli A, Unger E, Schenck JF. MRI-guided noninvasive ultrasound surgery. *Med Phys* 1993; 20:107–115.
4. Uchida T, Muramoto M, Kyunou H, Iwamura M, Egawa S, Koshihara K. Clinical outcome of high-intensity focused ultrasound for treating benign prostatic hyperplasia: preliminary report. *Urology*

- 1998; 52:66-71.
5. Gianfelice D, Khiat A, Amara M, Belblidia A, Boulanger Y. MR imaging-guided focused US ablation of breast cancer: histopathologic assessment of effectiveness-initial experience. *Radiology* 2003; 227:849-855.
 6. Hynynen K, Pomeroy O, Smith DN, et al. MR imaging-guided focused ultrasound surgery of fibroadenomas in the breast: a feasibility study. *Radiology* 2001; 219:176-185.
 7. Tempany CM, Stewart EA, McDannold N, Quade BJ, Jolesz FA, Hynynen K. MR imaging-guided focused ultrasound surgery of uterine leiomyomas: a feasibility study. *Radiology* 2003; 226:897-905.
 8. Chen L, Bouley D, Yuh E, D'Arceuil H, Butts K. Study of focused ultrasound tissue damage using MRI and histology. *J Magn Reson Imaging* 1999; 10:146-153.
 9. Wu F, Wang ZB, Chen WZ, et al. Extracorporeal high intensity focused ultrasound ablation in the treatment of patients with large hepatocellular carcinoma. *Ann Surg Oncol* 2004; 11:1061-1069.
 10. Chung A, Hynynen K, Colucci V, Oshio K, Cline HE, Jolesz FA. Optimization of spoiled gradient-echo phase imaging for *in vivo* localization of focused ultrasound beam. *Magn Reson Med* 1996; 36:745-752.
 11. Kuroda K, Chung AH, Hynynen K, Jolesz FA. Calibration of water proton chemical shift with temperature for noninvasive temperature imaging during focused ultrasound surgery. *J Magn Reson Imaging* 1998; 8:175-181.
 12. Hynynen K, Darkazanli A, Damianou CA, Unger E, Schenck JF. The usefulness of contrast agent and GRASS imaging sequence for MRI guided noninvasive ultrasound surgery. *Invest Radiol* 1994; 29:897-903.
 13. Jolesz FA, Hynynen K, McDannold N, Freundlich D, Kopelman D. Noninvasive thermal ablation of hepatocellular carcinoma by using magnetic resonance imaging-guided focused ultrasound. *Gastroenterology* 2004; 127(5 Suppl 1): S242-S247.
 14. Kaneko Y, Maruyama T, Takegami K, et al. Use of a microbubble agent to increase the effects of high intensity focused ultrasound on liver tissue. *Eur Radiol* 2005; 15:1415-1420.
-