

A Case of Pancytopenia with Hyperthyroidism

Tae Hoon Kim, Ji Sung Yoon¹, Byung Sam Park¹, Dong Won Lee¹, Jae Ho Cho¹
Jun Sung Moon¹, Eui Hyun Kim, Kyu Chang Won¹, Hyoung Woo Lee¹

Department of Internal Medicine, Daegu Fatima Hospital,

¹Department of Internal Medicine, College of Medicine, Yeungnam University, Daegu, Korea

There has been an increase in the number of reports of atypical manifestations of Graves' disease (GD), such as jaundice, anemia, thrombocytopenia and leukopenia. Pancytopenia also rarely occurs in GD. In this paper, a case of pancytopenia with GD that was successfully treated with an anti-thyroid drug is reported. In this case, a 69-year-old woman showed pancytopenia with a normal peripheral blood smear, bone marrow aspiration smear and bone marrow biopsy. Her thyroid function test and thyroid scintigraphy confirmed her hyperthyroid status. Her laboratory abnormality and clinical condition improved after she was treated with an anti-thyroid drug. This is a rare case of pancytopenia associated with GD.

Key Words: Hyperthyroidism, Pancytopenia, Graves' disease

INTRODUCTION

Atypical manifestations of hyperthyroidism include hematological, cardiovascular, gastrointestinal, hepatic, and neurological abnormalities.¹ In hematological manifestation, single lineage abnormalities such as anemia (34%), leukopenia (5.8%) or thrombocytopenia (3.3%) were reported. However, pancytopenia without myelodysplastic syndrome or megaloblastic anemia is a rare presentation of hyperthyroidism.² All cases were completely reversible with the antithyroid hormonal treatment. The suspected pathogenic mechanisms of pancytopenia included ineffective hematopoiesis, reduction in blood cell life span due to functional hyperactivity of reticuloendothelial system, autoimmune process, and toxicity of thyroid hormone.^{3,4} We reported a case of pancytopenia that was precipitated by hyperthyroidism and completely resolved under anti-thyroid drug.

Received: January 25, 2013, Revised: March 5, 2013,
Accepted: March 11, 2013

Corresponding Author: Ji Sung Yoon, Department of Internal medicine, College of Medicine, Yeungnam University, 170 Hyeonchung-ro, Namgu, Daegu 705-703, Korea
Tel: (053) 620-3846, Fax: (053) 654-8386
E-mail: jsyoon9@ynu.ac.kr

CASE

A 69-year-old woman was hospitalized due to general weakness for 2 months. Associated symptoms included easy fatigability, dyspnea with intermittent palpitation, sweating, pallor, fine tremor, and 14 kg weight loss within two months. She had no evidence of focal or systemic infection. She did not take any medication on a regular basis and had no significant past medical history or family history. Her height was 155 cm and weight was 41 kg. Her vital signs were as follows: temperature 36.8°C, blood pressure 124/78 mm Hg, pulse rate 105/min regular, and respiratory rate 24/min.

She had a depressed and lethargic appearance, but her skin was warm and moist. Her thyroid was enlarged without tenderness. She did not have sign of ophthalmopathy such as lid retraction or lag and palpable neck mass except goitre. There are no abnormalities in her physical and neurological examinations.

Initial biochemical analysis revealed leukopenia (white blood cell count 3,120/ μ L, neutrophil count 1,675/ μ L, and lymphocyte count 882/ μ L), normocytic normochromic anemia (hemoglobin 8.4 g/dL, hematocrit 25%, mean cell volume 80.4 fL, and mean cell hemoglobin concentration 33.5 g/dL), and thrombocytopenia (platelet count 17,000/ μ L) (Fig. 1A).

There were no abnormal cells in peripheral blood smear except mild amount of elliptocytes (poikilocytosis) and no evidence of hemolytic anemia (reticulocyte count 1.87% and reticulocyte index 1.03). Serum bilirubin, aminotransferase, prothrombin time, lactate dehydrogenase, ferritin, Vitamin B12, haptoglobin and test findings for autoimmune disease (rheumatoid factor, anti-smith antibody, anti-neutrophil cytoplasmic antibodies, fluorescent antinuclear antibody and heterophil antibody) were all normal. The chemistry data also revealed no existence of viral hepatitis including B and C, human immunodeficiency virus, cytomegalovirus, and Epstein-Barr virus. Antip-platelet antibody was negative. Thyroid function tests showed abnormally high concentrations of free T₄ (fT₄: 51.64 pmol/L, reference value (RV): 10-25 pmol/L) and total T₃ (TT₃: 4.58 nmol/L, RV: 1.23-3.08) with a thyroid stimulating hormone (TSH) concentration below the detection limit (Fig. 1B). Anti-thyroid autoantibodies were as follows: thyroid stimulating antibody 264.2 U/L (RV: 0-10), antibody for thyroglobulin 773.1 U/mL (RV: 0-60), and antibody for thyroid peroxidase 3,000 U/mL (RV: 0-60). To explain the pancytopenia, bone marrow aspiration and biopsy

were performed. Bone marrow aspiration smears showed normocellular marrow. Megakaryocytes and their precursors were adequate in number. The myeloid series and erythroid series were orderly matured (Fig. 2A). Bone marrow biopsy showed about 40% cellularity and no chromosomal aberrations indicating an aplastic anemia and myelodysplastic syndrome (Fig. 2B).

The chest X-ray was normal and electrocardiogram showed sinus tachycardia with left ventricular hypertrophy. On abdominal ultrasonography, there was no evidence of hepatosplenomegaly. Thyroid ultrasonography showed mild diffuse enlargement of thyroid with heterogeneous echogenicity and showed lobulated contour in thyroid (Fig. 3A). Thyroid scintigraphy using Tc-99m pertechnetate revealed diffusely increased tracer uptake, which suggested diffuse thyroid disease (Fig. 3B).

On the basis of these results, the patient was diagnosed with pancytopenia associated with Graves' disease (GD). She was treated with propylthiouracil 100 mg bid, propranolol 40 mg bid and enteral dexamethasone 1 mg bid. Two days after treatment, the white blood cell count and platelet count started to increase gradually. Five days after treatment, she

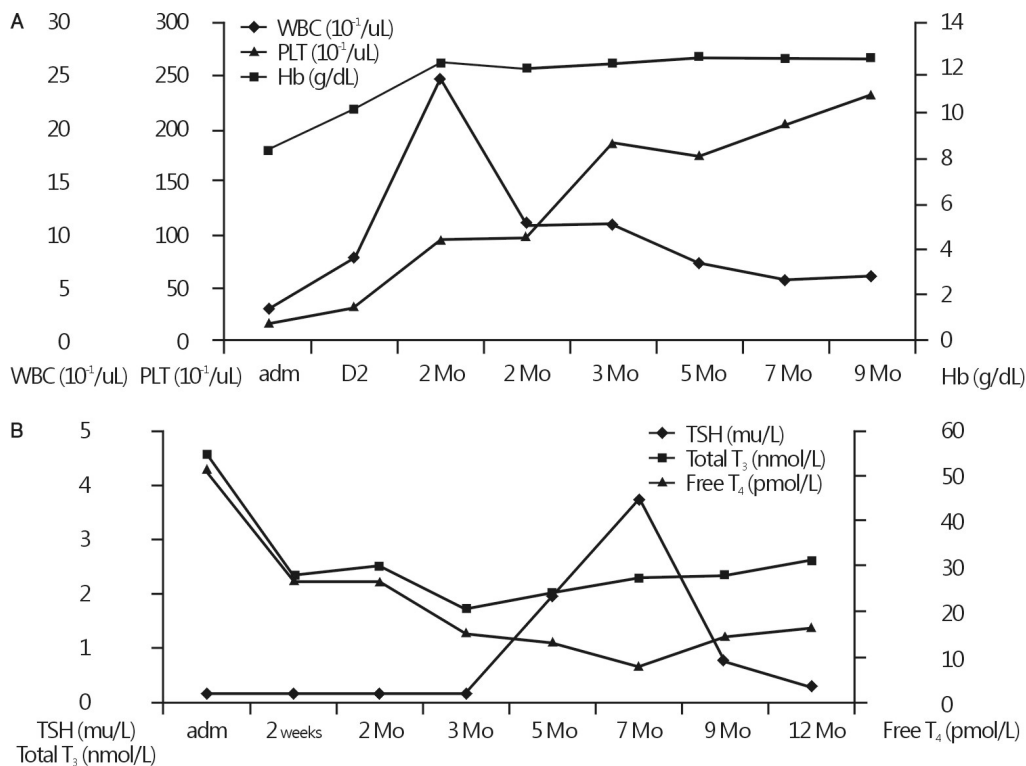


Fig. 1. Clinical course after treatment with propylthiouracil (200 mg/day). Mo: months, TSH: thyroid stimulating hormone, WBC: white blood cell, Hb: hemoglobin, PLT: platelets.

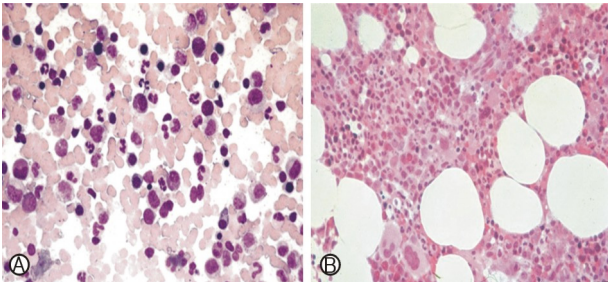


Fig. 2. (A) Bone marrow aspiration smear shows normocellular marrow and normal hematopoiesis (Wright-Giemsa stain, $\times 400$). (B) Bone marrow biopsy shows normal cellularity (H&E stain, $\times 200$).

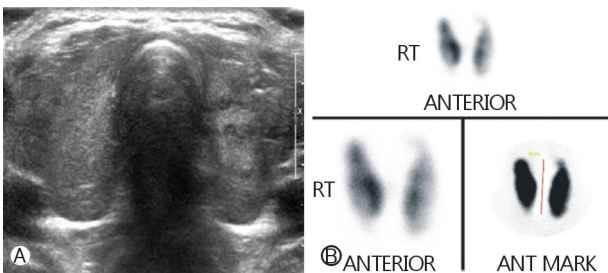


Fig. 3. (A) Thyroid ultrasound sonogram. Both lobes of the thyroid gland are lobulated in contour and show heterogeneous echogenicity. These findings suggest a diffuse thyroid disease. (B) thyroid scan (Tc-99m). The thyroid gland is enlarged and the tracer distribution is uneven. These findings suggest diffuse goiter.

was discharged with considerable improvement in her condition. She continued to take 200 mg/day of propylthiouracil and was observed at out patient department of the hospital. After 2 weeks of treatment, fT_4 and TT_3 levels decreased gradually. The same dose of propylthiouracil was continued, but enteral dexamethasone was stopped. Her symptoms disappeared after 2 months of treatment. Peripheral blood counts and thyroid function test were normal 3 and 5 months after treatment, respectively.

DISCUSSION

In our case, the patient presented pancytopenia and hyperthyroidism. She had received no drugs and laboratory findings didn't show evidence of viral infection. Bone marrow smear showed no signs of myelodysplastic syndrome. These results suggest that pancytopenia was caused by Graves' disease (GD).

Pancytopenia is a medical condition that is a reduction in the number of red and white blood cells, as well as platelets (hemoglobin <13.5 g/dL in male or <12 g/dL in female, total

white cell count $<4.0 \times 10^9/L$, platelet count $<150 \times 10^9/L$). It is not an uncommon clinical problem with an extensive differential diagnosis. Pancytopenia can be caused due to a decrease in hematopoietic cell production in the bone marrow (e.g. by infections, toxins, malignant cell infiltration or suppression) or can have normocellular or even hypercellular marrow, without any abnormal cells (e.g. ineffective hematopoiesis and dysplasia, maturation arrest of all cell lines and peripheral sequestration of blood cells). It can also be caused by immune-mediated destruction or drugs (antibiotics, blood pressure medications, and heart medications). Rarely, pancytopenia may have other causes, such as mononucleosis, or other viral diseases. Increasingly, HIV infection is a cause for pancytopenia.

Both thyrotoxicosis and the underlying autoimmunity of GD can be associated with various hematological disorders. Mild single lineage cytopenia is more frequent than pancytopenia in hyperthyroidism. Anemia has been found in 33% of GD patients and anemia can occur in up to 34% with hyperthyroidism.^{5,6} Thyroid hormones increase the metabolic rate and oxygen consumption that leading to tissue hypoxia. It stimulates the erythropoietin secretion, which may cause polycythemia in thyrotoxic patients.⁷ However, folic acid and vitamin B₁₂ deficiencies, iron metabolism disorders, a shortened erythrocyte lifespan in hypertrophic reticuloendothelial system, and ineffective erythropoiesis are common causes of anemia in thyrotoxic patients.^{1,5} The pathogenesis of GD anemia remains unclear. Non-specific binding of thyroid stimulating hormone receptor antibodies to the surface of the red blood cells may be basis for GD anemia. Generally, GD anemia resembled that associated with chronic disease. In this case, peripheral blood count and smear showed normocytic normochromic anemia without vitamin and iron deficiency and had no evidence of hemolytic anemia. Bone marrow cellularity and maturity was normal in bone marrow aspiration and biopsy, and there was no evidence of aplastic anemia and myelodysplastic syndrome. Therefore, we did not perform direct and indirect Coomb' test, fibrinogen, and anti-thrombin-III.

Leukopenia is reported in 15-30% of untreated thyrotoxicosis, but is usually associated with pancytopenia.⁸ Relative lymphocytosis with a normal or slightly low white blood cell count are the characteristic blood findings of GD, called Kocher's blood picture.⁹ It is suggested that a cross antigenicity

between human TSH receptors and polynuclear neutrophils, a decreased circulating time of granulocytes, and a reduced marrow granulocyte reserve are the causes of neutropenia in thyrotoxicosis.^{7,10} In this case, lymphocyte values were not compatible with Kocher's blood picture. And excessively corrected leukopenia was caused by short-term use of steroids in the early.

Thrombocytopenia is rarely observed in GD and is up to 4.3% of cases.⁹ Thrombocytopenia may be caused by reduced lifespan through functional hypersplenism with or without splenomegaly.^{7,11} It may be immunologically mediated. GD is occasionally associated with idiopathic thrombocytopenia purpura.¹² Severe autoimmune thrombocytopenia has been identified in 2-5% of thyrotoxicosis, and antiplatelet antibodies have been detected in 50% of the patients with GD and Hashimoto's thyroiditis.¹³ In this case, we could exclude idiopathic thrombocytopenic purpura as negative results of antiplatelet antibody and other laboratory test for autoimmune antibody, such as antinuclear antibody, platelet associated antibody, were all normal.

There are few reports about pancytopenia in hyperthyroidism. These cases had responded completely to treatment of anti-thyroid drug. The pathogenesis is poorly understood and various mechanisms have been postulated. The suspected pathogenic mechanisms include the following: 1) ineffective hematopoiesis caused by an excess of thyroid hormones, 2) reduction in blood cell life span caused by hypersplenism, 3) autoimmune process that induces antineutrophil or antiplatelet antibodies, and 4) toxicity of thyroid hormone to bone marrow stem cells.^{4,14,15}

In this case, the patients did not take any medication, had no medical history of connective tissue disease and malignant disease. After treatment with propylthiouracil, fT₄ and TT₃ concentrations decreased gradually and pancytopenia improved after 2 weeks. Other causes of pancytopenia were ruled out and the pancytopenia was resolved after correcting the hyperthyroidism, which meant that the pancytopenia was induced by GD. As the hyperthyroidism may cause pancytopenia, thyroid evaluation should be considered in unexplained pancytopenia.

REFERENCES

- Hegazi MO, Ahmed S. Atypical clinical manifestations of Graves' disease: an analysis in depth. *J Thyroid Res* 2012; 2012:768019.
- Hambusch K, Herrmann F, Fischer H, Langpeter D, Maller P, Sorger D. Changes in the blood picture in hyperthyroidism. *Z Gesamte Inn Med* 1989;44:300-6.
- Ansell JE. The blood in thyrotoxicosis. In: Braverman LE, Utiger RD, editors. *Werner and Ingbar's the thyroid: a fundamental and clinical text*. 7th ed. Philadelphia: Lippincott-Raven Publishers; 1996. p. 637-52.
- Soeki T, Tamura Y, Kondo N, Shinohara H, Tanaka H, Bando K, et al. A case of thyrotoxicosis with pancytopenia. *Endocr J* 2001;48:385-9.
- Macaron CI, Macaron ZG. Increased serum ferritin levels of hyperthyroidism. *Ann Intern Med* 1982;96:617-8.
- Gianoukakis AG, Leigh MJ, Richards P, Christenson PD, Hakimian A, Fu P, et al. Characterization of the anaemia associated with Graves' disease. *Clin Endocrinol (Oxf)* 2009;70: 781-7.
- Lima CS, Zantut Wittmann DE, Castro V, Tambascia MA, Lorand-Metze I, Saad ST, et al. Pancytopenia in untreated patients with Graves' disease. *Thyroid* 2006;16:403-9.
- Burns RW, Burns TW. Pancytopenia due to vitamin B12 deficiency associated with Graves' disease. *Mo Med* 1996;93: 368-72.
- Paydas S, Karademir M, Koak M, Burgut R, Guray A. Peripheral blood findings in thyrotoxicosis. *J Islamic Acad Sci* 1991;4:323-5.
- Shin JH, Kim HJ, Kim SB, Kim DP, Ko BS, Kim DS, et al. A case of Graves' disease with pancytopenia. *J Korean Endocr Soc* 2009;24:272-6. Korean.
- Adrouny A, Sandler RM, Carmel R. Variable presentation of thrombocytopenia in Graves' disease. *Arch Intern Med* 1982; 142:1460-4.
- Lee AC, Li CH, Wong LM. Childhood thrombocytopenia associated with Graves disease is distinct from idiopathic thrombocytopenic purpura. *Pediatr Hematol Oncol* 2003;20: 39-42.
- Kebapcilar L, Yeil S, Bayraktar F, Saklamaz A, Demir T, Gungor O, et al. Recovery from pancytopenia and liver dysfunction after administration of propylthiouracil for Graves' disease. *N Z Med J* 2005;118:U1615.
- Chen YH, Lin HJ, Chen KT. Rare presentations of hyperthyroidism-Basedow's paraplegia and pancytopenia. *Am J Emerg Med* 2009;27:258.e1-2.
- Weitzman SA, Stossel TP, Harmon DC, Daniels G, Maloof F, Ridgway EC. Antineutrophil autoantibodies in Graves' disease. Implications of thyrotropin binding to neutrophils. *J Clin Invest* 1985;75:119-23.