

## BRIEF REPORT

# A Case of Severe Ebola Virus Infection Complicated by Gram-Negative Septicemia

Benno Kreuels, M.D., Dominic Wichmann, M.D., Petra Emmerich, Ph.D., Jonas Schmidt-Chanasit, M.D., Geraldine de Heer, M.D., Stefan Kluge, M.D., Abdourahmane Sow, M.D., Thomas Renné, M.D., Ph.D., Stephan Günther, M.D., Ansgar W. Lohse, M.D., Marylyn M. Addo, M.D., Ph.D., and Stefan Schmiedel, M.D.

## SUMMARY

Ebola virus disease (EVD) developed in a patient who contracted the disease in Sierra Leone and was airlifted to an isolation facility in Hamburg, Germany, for treatment. During the course of the illness, he had numerous complications, including septicemia, respiratory failure, and encephalopathy. Intensive supportive treatment consisting of high-volume fluid resuscitation (approximately 10 liters per day in the first 72 hours), broad-spectrum antibiotic therapy, and ventilatory support resulted in full recovery without the use of experimental therapies. Discharge was delayed owing to the detection of viral RNA in urine (day 30) and sweat (at the last assessment on day 40) by means of polymerase-chain-reaction (PCR) assay, but the last positive culture was identified in plasma on day 14 and in urine on day 26. This case shows the challenges in the management of EVD and suggests that even severe EVD can be treated effectively with routine intensive care.

From the Division of Tropical Medicine, First Department of Medicine (B.K., A.W.L., M.M.A., S.S.), Department of Intensive Care Medicine (D.W., G.H., S.K.), Institute for Clinical Chemistry and Laboratory Medicine (T.R.), and Infectious Disease Unit for Outpatient Care (S.S.), University Medical Center Hamburg-Eppendorf, the German Center for Infection Research, Hamburg-Borstel-Lübeck (B.K., J.S.-C., S.G., A.W.L., M.M.A., S.S.), the Research Group for Infectious Disease Epidemiology, Bernhard Nocht Institute for Tropical Medicine (B.K.), and the Bernhard Nocht Institute for Tropical Medicine, World Health Organization Collaborating Center for Arbovirus and Hemorrhagic Fever Reference and Research (P.E., J.S.-C., S.G.) — all in Hamburg, Germany; Arboviruses and Hemorrhagic Fever Viruses Unit, Pasteur Institute, and Public Health and Development Institute, Cheikh Anta Diop University — both in Dakar, Senegal (A.S.); Bordeaux Public Health Institute, INSERM Unité 897, Bordeaux University, Bordeaux, France (A.S.); the Department of Molecular Medicine and Surgery, Karolinska Institutet, Stockholm (T.R.); and the Infectious Diseases Unit, Massachusetts General Hospital, Boston (M.M.A.). Address reprint requests to Dr. Addo or Dr. Schmiedel at University Medical Center Hamburg-Eppendorf, First Department of Medicine, Martinistr. 52, 20246 Hamburg, Germany, or at m.addo@uke.de or s.schmiedel@uke.de.

SINCE DECEMBER 2013, A ZAIRE EBOLAVIRUS (EBOV) EPIDEMIC OF UNPRECEDENTED scale has ravaged West Africa, with a focus on Guinea, Sierra Leone, and Liberia.<sup>1-4</sup> The current epidemic has led to a public health emergency in the region, exacerbated by high rates of infection among health care personnel. A substantial number of fatal cases are among health care workers.<sup>2</sup> Several international health care workers have been evacuated to specialized centers in Europe and the United States. The patient transferred to our isolation unit worked for the World Health Organization (WHO) as an epidemiologist in Sierra Leone and was airlifted at the request of the WHO. Brief descriptions of the unit for the treatment of highly contagious infections (UTHCI) and the measures of infection control, which were similar to those used in biosafety level 4 laboratories, are included in the Supplementary Appendix, available with the full text of this article at NEJM.org.

## HISTORY AND FINDINGS ON ADMISSION

The 36-year-old male patient had malaise, headache, myalgias, and arthralgias on day 1 of the illness (August 18, 2014). Fever developed on day 2, and the patient was treated empirically for malaria. On days 2 through 6, he also received empirical antimicrobial therapy with ceftazidime. On day 6, he tested positive for EBOV on real-time reverse-transcriptase-PCR (RT-PCR) assay. Nausea, vomiting, abdominal pain, and nonbloody diarrhea developed on day 7, prompting his admission to a treatment center in Sierra Leone. Single doses of ciprofloxacin and metronidazole were administered on day 8, and supportive therapy with intravenous fluids was initiated and maintained until day 10, when he was transferred to Hamburg.

Drs. Kreuels and Wichmann contributed equally to this article.

This article was published on October 22, 2014, and last updated on October 27, 2014, at NEJM.org.

DOI: 10.1056/NEJMoa1411677

Copyright © 2014 Massachusetts Medical Society.

**Table 1. Clinical Variables, Fluid Management, and Laboratory Values during the Course of Illness.\***

Variable	Day of Illness							
	10	11	12	13	14	15	16	17
Clinical variables†								
Temperature (°C)	38.4	39.3	38.8	40.0	40.0	39.8	38.8	38.8
Respiratory rate (breaths/min)	ND	ND	ND	ND	40	40	39	35
Oxygen saturation (%)	97	93	95	88	89	90	92	93
Heart rate (beats/min)	96	92	80	140	170	160	140	150
Oxygen (liters/min)	—	—	—	—	1	5	6	6
Noninvasive ventilation (hr)	—	—	—	—	—	—	—	—
Fluid measurements (ml)								
Intravenous fluids‡	7850	13,175	11,675	9200	7510	13,734	7574	4418
Oral fluids§	—	—	—	—	—	—	—	80
Diarrhea¶	4400	8400	6850	4030	2230	950	500	—
Vomiting	—	—	1200	1550	—	—	100	200
Urine	1330	1050	400	ND	ND	1760	4940	6870
Balance	2120	3725	3225	3620	5280	11,024	2034	-2572
Laboratory values								
Hemoglobin (g/dl)	18.0	15.8	15.4	16.0	14.1	13.4	13.2	11.1
Hematocrit (%)	55.2	48.4	42.9	49.4	43.3	44.1	39.4	33.6
White cells ( $\times 10^{-3}/\text{mm}^3$ )	6.8	6.4	7.3	14.1	21.8	28.7	19.7	13.0
Platelets ( $\times 10^{-3}/\text{mm}^3$ )	103	116	152	135	101	81	83	46
D-dimer (mg/liter)	33	38	38	37	35	28	24	11
AST (U/liter)	1054	942	924	950	834	592	321	205
CRP (mg/liter)	11	13	23	43	59	123	127	65
Lactate (mmol/liter)	1.8	2.7	1.5	2.8	6.5	9.3	1.7	1.1
Creatinine (mg/dl)**	1.9	1.3	1.0	1.0	1.1	1.2	1.0	1.3
Sodium (mmol/liter)	135	135	138	141	144	147	144	148
Potassium (mmol/liter)	3.4	3.5	3.5	3.6	3.3	3.9	4.4	3.9
Chloride (mmol/liter)	102	103	109	110	116	119	117	118
pH	7.45	7.38	7.45	7.44	7.45	7.37	7.47	7.43
Bicarbonate (mmol/liter)	20.5	24.1	22.9	21.9	15.5	14.2	24.7	27.6

\* Data are for the period starting with the patient's arrival in Hamburg, Germany, and ending on the day before transfer of the patient to the infectious disease ward. AST denotes aspartate aminotransferase, CRP C-reactive protein, and ND not determined.

† Temperature was measured tympanically until the insertion of a urinary catheter on day 15. The maximum respiratory rate, minimum oxygen saturation (as measured with the use of pulse oximetry), and maximum heart rate were assessed by means of continuous measurement on a medical monitor. The inspired oxygen concentration was not measured, but the patient was receiving oxygen with the use of a nasal cannula. Data on noninvasive ventilation are the number of hours of noninvasive ventilation delivered by means of the Evita 2 dura (Dräger) in 24 hours.

‡ Intravenous fluids included 5% glucose solution, Sterofundin ISO (B. Braun Medical Supplies), and intravenous nutrition.

§ Oral fluids included water, tea, and oral nutrition (low-fiber standard formula providing 1 kcal per milliliter).

¶ A fecal collector was inserted on day 16.

|| A nasogastric tube was inserted on day 16.

\*\* To convert values for creatinine to micromoles per liter, multiply by 88.4.

On the basis of the patient's history, the most likely source of infection was contact with a colleague who had had symptoms of EVD and died 10 days before the onset of symptoms in our

patient. The patient and his colleague shared an office for meetings and used the same restroom facilities until 3 days before the colleague died. On admission to our facility, the patient was

Day of illness									
18	19	20	21	22	23	24	25	26	27
38.5	38.8	39.0	38.6	37.8	37.8	38.0	38.2	37.8	37.6
35	40	31	40	32	27	36	30	24	24
<85	88	<85	<85	<85	97	<85	96	97	96
144	155	140	150	140	135	120	130	125	120
8	8	6	5	3	2	3	3	—	—
4	—	2	10	2	—	4	4	—	—
3818	3613	4064	6116	4316	2836	5520	3410	1264	1000
180	480	880	780	860	1420	1780	1920	2445	1585
300	100	—	900	800	300	700	—	—	—
—	—	—	—	—	—	—	—	—	—
6770	5870	6800	5690	5480	5500	6600	4480	4450	3550
-3072	-1877	-1856	306	-1104	-1544	0	-850	-741	-965
12.1	8.8	7.1	8.2	7.7	7.8	8.2	7.7	7.5	8.0
31.5	24.9	24.2	27.1	27.2	24.9	25.1	25.5	25.0	27.2
18.2	14.2	6.5	9.2	11.7	8.3	12.5	9.7	8.1	8.8
50	77	63	119	123	153	230	267	243	261
9	4	5	9	27	13	9	8	5	2
183	157	152	224	143	219	270	154	268	181
79	60	39	37	34	33	34	30	35	37
1.0	0.9	0.6	0.4	0.4	0.6	0.5	0.4	0.8	0.6
1.5	1.5	1.2	1.0	0.9	0.7	0.7	0.7	0.7	0.7
154	159	155	148	148	144	143	141	136	133
4.6	3.8	3.9	5.0	4.3	3.8	4.1	4.4	3.9	3.7
120	122	125	116	115	112	111	108	105	100
7.40	7.50	7.51	7.22	7.23	7.48	7.42	7.26	7.51	7.46
29.4	32.4	28.8	29.1	29.8	28.5	27.2	29.8	28.0	28.9

clinically stable, with an elevated temperature (38.4°C), but other vital signs were within normal limits. The oxygen saturation was 97% while the patient was breathing ambient air, the blood pressure 110/80 mm Hg, and the heart rate 87 beats per minute. The patient was awake, alert, and fully oriented. Physical examination revealed signs of dehydration and diffuse abdominal tenderness. Rash was absent.

The patient's medical history was notable for asymptomatic, chronic hepatitis B virus infection (viral DNA level, as assessed by means of PCR, 11,000 IU per milliliter, with no evidence of liver dysfunction). The results of laboratory

tests were consistent with substantial dehydration and hemoconcentration, with a hemoglobin level of 18.0 g per deciliter, a creatinine level of 1.9 mg per deciliter (170  $\mu$ mol per liter) (normal range,  $\leq$ 1.1 mg per deciliter [100  $\mu$ mol per liter]), and mild hypokalemia (potassium level, 3.4 mmol per liter; normal range, 3.5 to 5.0). Additional abnormal laboratory values included a platelet count of  $103 \times 10^3$  per cubic millimeter (normal range, 150 to 450), an aspartate aminotransferase level of 1054 U per liter (normal range,  $<$ 50), and a D-dimer level of 33 mg per liter (normal range, 0.1 to 0.4) (Table 1).

Tests for malaria and dengue were negative.

Ultrasonography of the abdomen revealed a complete collapse of the inferior vena cava, a paralytic ileus with pronounced edema of the small intestine and large intestinal wall, and distended intestinal loops. With the exception of enlarged mesenteric lymph nodes, all the other organs appeared normal. A full description of the clinical findings and additional laboratory findings are presented in the Supplementary Appendix.

---

#### CLINICAL COURSE AND MANAGEMENT

---

##### SYMPTOMATIC THERAPY

Treatment of nausea, vomiting, and fever was implemented intravenously immediately after admission, because oral drug intake was not possible. An overview of all the administered drugs with respective timelines and our treatment considerations regarding the administration of experimental therapies is provided in the Supplementary Appendix.

##### BASELINE FLUID AND NUTRITION MANAGEMENT

Maximal supportive measures were initiated, with a primary goal of restoring and maintaining volume and electrolyte balance. The patient was considered to be at high risk for hypovolemic shock on the basis of a stool output of more than 8000 ml per 24 hours in the first 3 days after the transfer to Hamburg (days 10 to 12) (Table 1). Nausea and vomiting precluded oral rehydration, and high-volume resuscitation of up to 10 liters per day, with a positive net-volume balance of 30 liters during the first week, was necessary to stabilize cardiocirculatory values. Rehydration was guided by clinical examination and by repeated ultrasonographic examinations of the inferior vena cava. Persistently low potassium levels necessitated continuous intravenous substitution of 8 to 10 mmol of potassium chloride per hour. To meet the demands of volume and electrolyte repletion, a central venous catheter was placed on day 15.

Owing to paralytic ileus and high gastric residual volumes with severe hiccups, enteral nutrition was not tolerated. Attempts to stimulate peristalsis with the use of erythromycin and neostigmine were unsuccessful, prompting the initiation of parenteral nutrition on day 11, including the administration of glutamine at a dose of 0.3 g per kilogram of body weight per day as

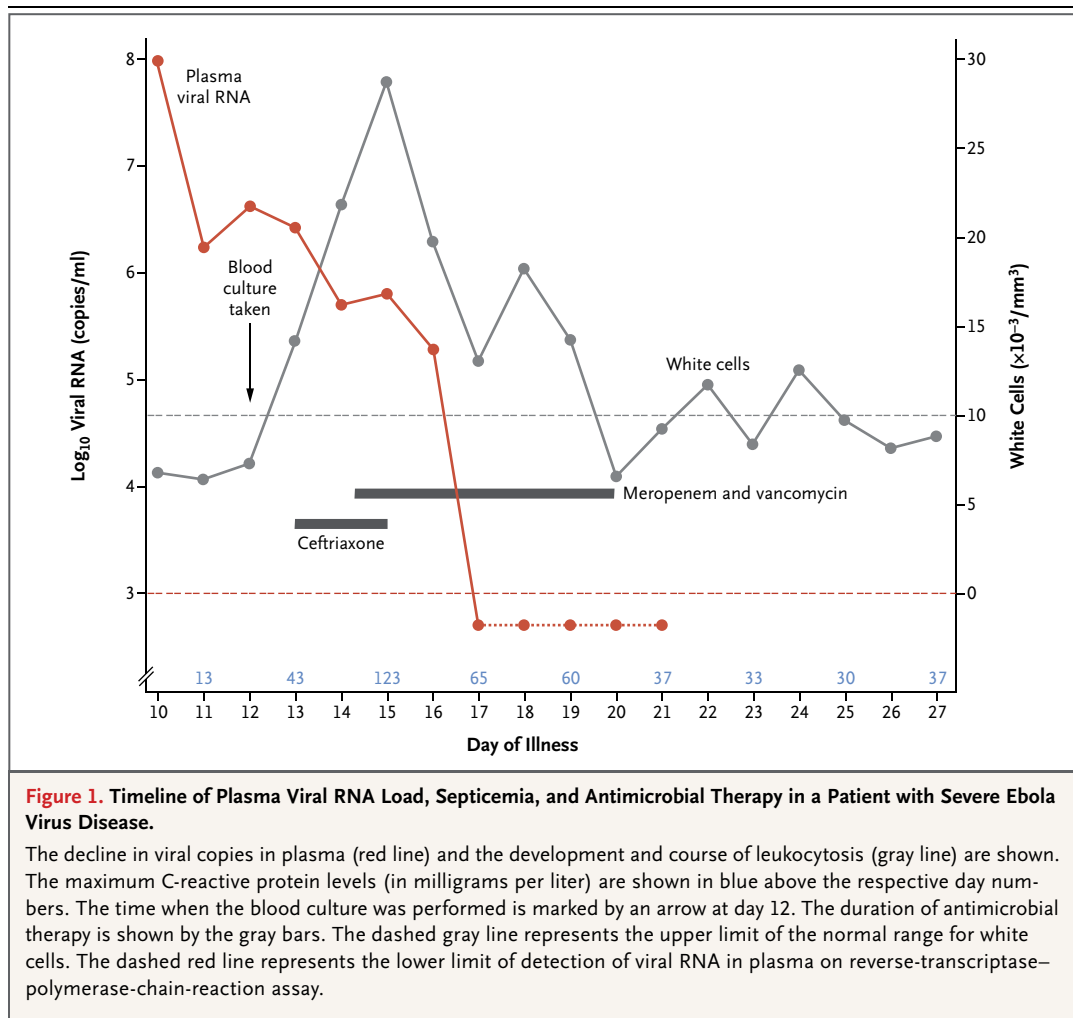
possible support for mucosal integrity.<sup>5</sup> After stabilization of the patient's condition, enteral nutrition with a low-fiber standard formula was initiated on day 17.

##### CLINICAL COURSE AND MANAGEMENT OF COMPLICATIONS

The patient remained clinically stable on days 10 through 12. Emesis ceased on day 13, and high-volume diarrhea (>1000 ml) resolved on day 15. Hemoglobin and creatinine levels returned to the normal range by day 12, and the aminotransferase levels gradually declined (Table 1). However, fever (40.0°C), hypoxemia, tachycardia, shortness of breath, and abdominal pain developed on day 13. Laboratory studies revealed leukocytosis ( $14.1 \times 10^3$  white cells per cubic millimeter) with a predominance of neutrophils (87%) and an elevated C-reactive protein level (43 mg per liter). These findings were interpreted as suggestive of concomitant secondary peritonitis and sepsis due to the loss of mucosal integrity and bacterial translocation.

Antimicrobial therapy with ceftriaxone was initiated on day 13 and was changed to meropenem and vancomycin on the evening of day 14, when the patient's condition deteriorated further, with an increase in the white-cell count ( $26.9 \times 10^3$  per cubic millimeter). Blood cultures drawn on day 12 and performed within the UTHCI revealed growth of a gram-negative bacterium resistant to ampicillin, ciprofloxacin, and third-generation cephalosporins but sensitive to meropenem. More advanced tools for full identification of the organism and assessment of speciation were not accessible under the conditions of the UTHCI. An overview of the timeline of sepsis is presented in Figure 1, showing that new severe systemic symptoms developed while the EBOV RNA load was already declining.

The patient's treatment course was further complicated by the development of small pleural and pericardial effusions, ascites, and increasing intestinal edema, which were probably due to a combination of EBOV endothelial-cell cytotoxicity<sup>6</sup> and decreasing serum protein concentrations as a consequence of rigorous volume management. On day 15, this condition led to a deficit in organ perfusion complicated by hypoglycemia and lactic acidosis, which was treated with increased volume repletion, sodium bicarbonate, and 40% glucose solution.



A combination of pulmonary atelectasis, volume overload, and encephalopathy with altered mental status resulted in acute respiratory failure on day 18. The respiratory status was further compromised by aspiration of blood from epistaxis in the context of thrombocytopenia. In spite of relative contraindications (gastroparesis and altered mental status), noninvasive ventilation was initiated. After 8 days of intermittent noninvasive ventilation, the patient gradually recovered, and his laboratory values started to normalize. However, the patient had persistent tachycardia (heart rate, 120 to 150 beats per minute) and hypertension (blood pressure, >150/80 to 180/100 mg Hg) with normal electrocardiographic and echocardiographic findings. The tachycardia and hypertension were unresponsive to metoprolol and clonidine but resolved gradually without intervention by day 35.

The patient had severe encephalopathy for 6 days (days 14 to 19) until vigilance slowly improved. However, the encephalopathy was followed by transient delirium with hallucinations (days 20 to 25), which were unresponsive to haloperidol but subsided spontaneously before discharge.

#### EBOV RNA LOAD AND SEROLOGIC FINDINGS

Before transfer, the patient had tested positive for EBOV RNA in blood, as measured by means of a real-time RT-PCR assay, on days 6 and 7 at a local treatment center. From the day of arrival in Hamburg (day 10), the EBOV RNA concentration in plasma was measured daily (RealStar Filovirus Screen RT-PCR Kit 1.0, Altona Diagnostics). The presence of EBOV-specific IgG and IgM antibodies was determined by means of an immunofluorescence assay with the use of EBOV-infected

Vero E6 cells as an antigen. The EBOV RNA load decreased starting on day 10 and first became negative on day 17. Anti-EBOV antibody titers steadily increased, with peak titers of 1:2560 for IgM antibodies and of more than 1:320,000 for IgG antibodies (Fig. 2).

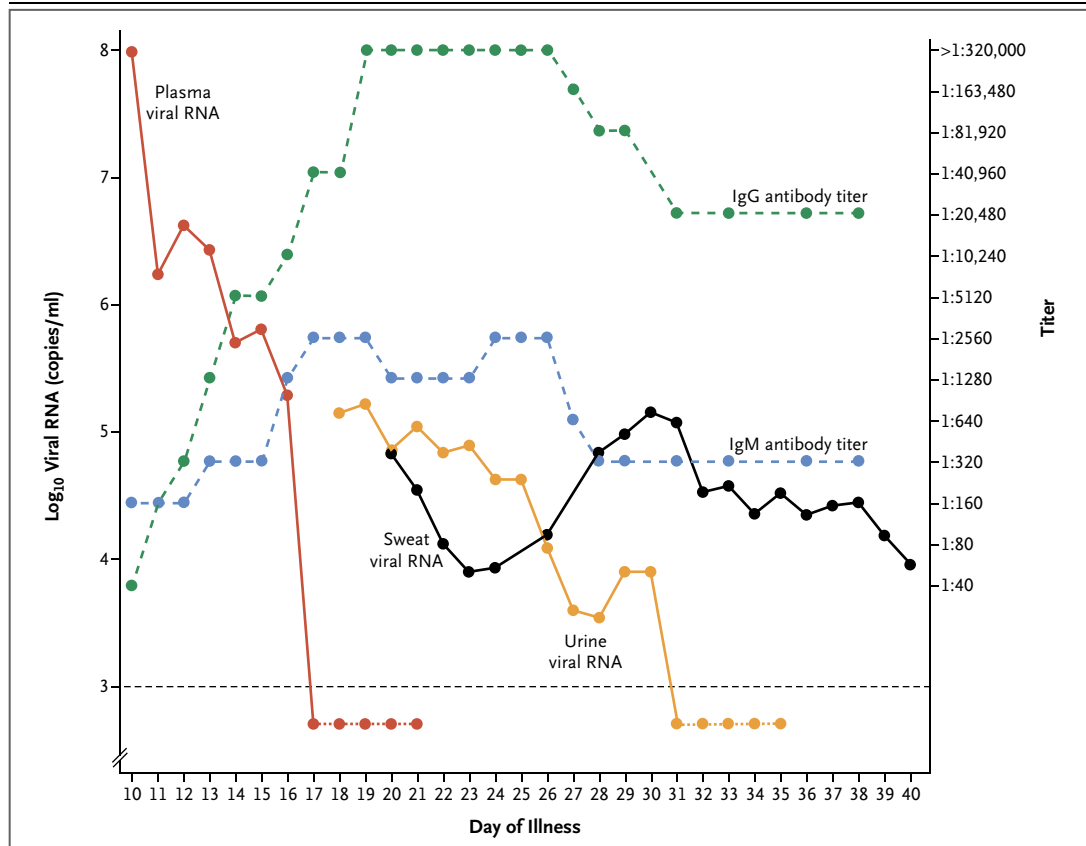
After plasma EBOV RNA became negative on day 17, real-time RT-PCR surveillance of sputum, saliva, conjunctival swabs, stool, urine, and sweat (from the axillary, forehead, and inguinal regions) was performed. Saliva, sputum, conjunctival swabs, and stool were already negative on the first day of testing (day 18). However, urine samples remained positive for EBOV RNA until day 30, and RNA extracts from sweat remained positive throughout the observation period until day 40.

In addition, to test for the infectivity of the specimens in cell culture, Vero E6 cells were inoculated with plasma, sweat, and urine (150  $\mu$ l

of inoculum per 25-cm<sup>2</sup> flask). Cell cultures were incubated for 40 days, and cells were monitored for viral growth by means of immunofluorescence assay. EBOV was isolated on cell culture from plasma samples obtained on days 10 to 14, when EBOV RNA was still detectable in the blood. In addition, viable EBOV was still isolated from urine samples obtained on days 18, 19, 20, 24, and 26, which was up to 9 days after the clearance of EBOV RNA from plasma. At the time of writing (day 63), all cell cultures of clinical specimens (plasma, sweat, and urine) obtained after day 26 of illness were negative for viable EBOV.

**DISCHARGE FROM UTHCI AND INFECTIOUS DISEASE WARD**

On day 28, the patient was transferred from the UTHCI to an infectious disease ward with barrier



**Figure 2. Timeline of Viral RNA Load in Plasma, Sweat, and Urine and Antibody Titers in Plasma.**

The y axis on the left side of the graph shows the viral RNA load (solid lines). Owing to strong fluctuations in single measurements, line plots for urine and sweat are shown as moving averages over a period of 3 days. The y axis on the right side of the graph shows the antibody titers (dashed lines). The horizontal dashed line indicates the lower limit of detection of viral RNA on reverse-transcriptase–polymerase-chain-reaction assay.



nursing precautions, which are similar to the precautions used in biosafety level 3 laboratories. In addition to negative results on the RT-PCR assay in plasma, the three criteria for the patient's transfer, based on an agreement between the hospital and local and national health authorities, were clinical recovery, continence for stool and urine, and ability to comply with instructions. Discharge from the hospital was delayed until day 40, owing to the prolonged detection of virus RNA in urine and sweat. On agreement with local health authorities, the patient was discharged after all cultures of PCR-positive samples of body fluids had been free of infectious virus particles for 20 days. The patient ultimately recovered, with all laboratory values, including liver-enzyme levels, within the normal range, and he was able to return to his family in Senegal without assistance.

#### INFECTION-CONTROL MEASURES

Staff members working in the UTHCI were protected by pressurized suits (Astro-Protect, Asatex) that were equipped with ventilators with high-efficiency particulate air filters to provide fresh air supply with a maximum airflow of 160 liters per minute (ProFlow 2 SC, Asatex). All the staff who cared for the patient did so without becoming infected. More details regarding the unit and protective measures are provided in the Supplementary Appendix.

---

#### DISCUSSION

---

We report a case of severe EVD in a 36-year-old man who had numerous complications but fully recovered with intensive routine treatment (i.e., without any EBOV-specific treatments). The treatment consisted of intensive fluid resuscitation, broad-spectrum antimicrobial therapy, and ventilatory support.

Diarrhea and vomiting have been observed in 66% and 68% of patients, respectively, in the current EVD outbreak, and diarrhea is associated with death.<sup>2</sup> In the case presented here, these symptoms were associated with concomitant severe enteropathy, including paralytic ileus, large gastric residual volumes, and persistent hiccups. Data from the current outbreak suggest that paralytic ileus is a common finding, with abdominal pain present in 44% of infected persons and hiccups representing a strong predictor of

death.<sup>2</sup> In our patient, paralytic ileus prevented oral rehydration and enteral nutrition and limited the potential choices for orally administered experimental therapies. In line with a recent report, this situation underscores the importance of aggressive volume repletion in patients with severe EVD.<sup>7</sup> Valuable tools for guiding fluid management were repeated ultrasonographic examinations of the abdomen and laboratory monitoring of electrolyte, pH, and lactate levels.

The patient also had severe gram-negative sepsis, presumably caused by bacterial translocation from the inflamed intestinal tract. Sepsis led to severe illness when the viral load was already decreasing (Fig. 1), which suggests that sepsis may contribute substantially to the mortality observed in the current outbreak, specifically with regard to deaths occurring late after disease onset.<sup>2</sup> The patient was treated initially with ceftazidime in Sierra Leone to prevent septicemia, as recommended by Médecins sans Frontières.<sup>8</sup> However, bacteremia in this case was related to a multidrug-resistant gram-negative organism, suggesting the importance of monitoring patients for signs of infection by means of laboratory tests (e.g., C-reactive protein). Sepsis may have contributed to the development of severe encephalopathy in our patient and may explain, at least in part, the confusion and coma or unconsciousness that have been observed in 13% and 6% of patients, respectively, in the ongoing EVD outbreak<sup>2</sup>; both symptoms have been associated with death.

Although respiratory failure has been described rarely in the current outbreak, it represents a predictor of a negative outcome. In the case presented here, respiratory failure occurred late in the disease course (day 18), probably owing to a combination of pulmonary atelectasis, altered mental status, volume overload, and capillary leakage. A major contributing factor was also likely to be aspiration after epistaxis in the context of thrombocytopenia. Gingival bleeding has been one of the strongest predictors of death in the current EVD outbreak, as reported by the WHO.<sup>2</sup>

In summary, this case shows that severe EVD with serious complications can be treated successfully with general intensive care measures, supporting suggestions by Lamontagne and colleagues<sup>7</sup> that the initiation of intravenous rehydration and improvement of clinical care and

laboratory diagnostics can increase survival considerably, even in the absence of new EBOV-specific therapies. Finally, the opportunity for intensive multisite sampling allowed for detailed insights into the real-time kinetics of EBOV viremia, the development of humoral immunity, and the evolution of viral RNA shedding from body fluids.

Disclosure forms provided by the authors are available with the full text of this article at NEJM.org.

We thank Claudia Beisel, Till Bornscheuer, Jakob Cramer, Claudia Frey, Johannes Jochum, Stefan Lüth, Hanna Matthews, Claudia Röder, Thierry Rolling, Camilla Rothe, Helmut Salzer, Guido Schäfer, Christoph Schramm, Julian Schulze zur Wiesch, Christof Vinnemeier, Tobias Werner, Dorothea Wiemer, and all the other

physicians and nurses involved in the clinical treatment of the patient; Florian Harder, Tom Hildebrandt, Hannes Kalb, and Kristina Scholz for intensive support in setting up, maintaining, and running the unit for the treatment of highly contagious infections (UTHCI) at the University Medical Center Hamburg–Eppendorf (UKE); Birgit Mähnß and colleagues for maintenance and support of the laboratory facilities within the UTHCI; Martin Gabriel, Beate Becker-Ziaja, Corinna Thomé-Bolduan, Insa Bonow, Sabine Köhler, Claudia Poggensee, Mathis Petersen, Alexandra Bialonski, Elisa Pallasch, and Sonja Maersmann for assistance in viral diagnostics; Markus Eickmann and Stephan Becker, Philipps University, Marburg, for the confirmation of the results of the polymerase-chain-reaction assay; Marcus Altfeld and Virginia A. Triant for critical review of an earlier version of the manuscript; and all the other members of the First Department of Medicine, Department of Intensive Care Medicine, and the technical support staff at the UKE, as well as the team of the German Armed Forces Joint Medical Service, for their support.

#### REFERENCES

1. Farrar JJ, Piot P. The Ebola emergency — immediate action, ongoing strategy. *N Engl J Med* 2014;371:1545-6.
2. WHO Ebola Response Team. Ebola virus disease in West Africa — the first 9 months of the epidemic and forward projections. *N Engl J Med* 2014;371:1481-95.
3. Baize S, Pannetier D, Oestereich L, et al. Emergence of Zaire Ebola virus disease in Guinea. *N Engl J Med* 2014;371:1418-25.
4. Briand S, Bertherat E, Cox P, et al. The international Ebola emergency. *N Engl J Med* 2014;371:1180-3.
5. Wischmeyer PE, Dhaliwal R, McCall M, Ziegler TR, Heyland DK. Parenteral glutamine supplementation in critical illness: a systematic review. *Crit Care* 2014;18:R76.
6. Zampieri CA, Sullivan NJ, Nabel GJ. Immunopathology of highly virulent pathogens: insights from Ebola virus. *Nat Immunol* 2007;8:1159-64.
7. Lamontagne F, Clément C, Fletcher T, Jacob ST, Fischer WA II, Fowler RA. Doing today's work superbly well — treating Ebola with current tools. *N Engl J Med*. DOI: 10.1056/NEJMp1411310.
8. Roddy P, Colebunders R, Jeffs B, Palma PP, Van Herp M, Borchert M. Filovirus hemorrhagic fever outbreak case management: a review of current and future treatment options. *J Infect Dis* 2011;204:Suppl 3:S791-S795.

Copyright © 2014 Massachusetts Medical Society.