

# A comparative CT evaluation of pharyngeal airway changes in class III patients receiving bimaxillary surgery or mandibular setback surgery

著者	Degerliyurt Kagan, Ueki Koichiro, Hashiba Yukari, Marukawa Kohei, Nakagawa Kiyomasa, Yamamoto Etsuhide
journal or publication title	Oral Surgery, Oral Medicine, Oral Pathology, Oral Radiology and Endodontology
volume	105
number	4
page range	495-502
year	2008-04-01
URL	<a href="http://hdl.handle.net/2297/9568">http://hdl.handle.net/2297/9568</a>

doi: 10.1016/j.tripleo.2007.11.012

**A comparative CT evaluation of pharyngeal airway changes in class III patients receiving bimaxillary surgery or mandibular setback surgery.**

KAGAN DEGERLIYURT, DDS, \* KOICHIRO UEKI, DDS, PhD, # YUKARI  
HASHIBA, DDS, § KOHEI MARUKAWA, DDS, PhD, ¶ KIYOMASA  
NAKAGAWA, DDS, PhD, † and ETSUHIDE YAMAMOTO, DDS, PhD, ‡

1. Department of Oral and Maxillofacial Surgery, Graduate School of Medicine,  
Kanazawa University, 13-1 Takaramachi, Kanazawa 920-8641, Japan
2. Gazi University, School of Dentistry, Department of Oral and Maxillofacial Surgery,  
8. Cad 82. Sok. 06510 Emek, Ankara, TURKEY

\* Research fellow<sup>1</sup> and Resident<sup>2</sup>

# Assistant Professor<sup>1</sup>

§ Graduate Student<sup>1</sup>

¶ Clinical Instructor<sup>1</sup>

† Associate Professor<sup>1</sup>

‡ Professor and Head<sup>1</sup>

Address Correspondence To: Kagan Degerliyurt, DDS

Gazi University, School of Dentistry, Department of Oral and Maxillofacial Surgery,

8. Cadde 82. sok. 06510 Emek, Ankara, TURKEY

Tel: +90 312 203 63 35

Fax: +90 312 223 92 26

Email: [mkdegerliyurt@gazi.edu.tr](mailto:mkdegerliyurt@gazi.edu.tr)

**A COMPARATIVE CT EVALUATION OF PHARYNGEAL AIRWAY CHANGES  
IN CLASS III PATIENTS RECEIVING BIMAXILLARY SURGERY OR  
MANDIBULAR SET BACK SURGERY**

**A COMPARATIVE CT EVALUATION OF PHARYNGEAL AIRWAY CHANGES  
IN CLASS III PATIENTS RECEIVING BIMAXILLARY SURGERY OR  
MANDIBULAR SET BACK SURGERY**

**Purpose:** The purpose of this study was to compare the morphologic changes of the upper airway space in Class III patients underwent mandibular set back or bimaxillary surgery (maxillary advancement and mandibular setback) by computed tomography at 2 levels: soft palate and base of tongue

**Materials and Methods:** The sample is consisted of 47 patients in 2 groups who had been diagnosed with Class III skeletal deformities and had been treated by mandibular setback or bimaxillary surgery (maxillary advancement and mandibular setback). Anteroposterior, lateral, cross sectional area dimensions of the airway at the level of soft palate and base of tongue was measured pre- and postoperatively on computed tomography images.

**Results:** However, anteroposterior dimensions of the airway decreased in both groups ( $p < .0001$ ), the reduction was significantly less in cases treated with bimaxillary surgery ( $p < .05$ ). In mandibular setback surgery group, the cross sectional area of the airway decreased significantly ( $p < .001$ ) Although, the cross sectional area of the airway decrease in bimaxillary surgery group, the reduction was not statistically significant ( $p > .05$ ).

**Conclusions:** This study suggested that bimaxillary surgery could prevent narrowing of the upper airway in the correction of Class III deformities rather than mandibular setback surgery .

**Keywords:** Mandibular setback, Bimaxillary surgery, Pharyngeal airway, Computed Tomography

## **Introduction**

Class III deformity can be the result of mandibular anteroposterior excess, maxillary deficiency or both in the same case<sup>1</sup>. Formerly, the surgical treatment of Class III anteroposterior excess was achieved by various types of mandibular setback surgeries alone<sup>2,3</sup>. Later studies indicated that isolated mandibular anteroposterior excess occurs in only approximately 20% to 25% of Class III cases. Some maxillary skeletal anteroposterior deficiency is involved in 75% of cases with Class III deformities<sup>4</sup>. With the advances in knowledge and techniques, corrective surgery progressed through bimaxillary surgery procedures<sup>2</sup>. Recently, mandibular setback surgery decreased in frequency to fewer than 10% of class III patients whereas bimaxillary surgery is preferred in about %40 of patients. Maxillary advancement is performed in the remaining patients<sup>5</sup>.

Both mandibular setback surgery and bimaxillary surgery can improve occlusion, masticatory function and esthetics by markedly changing the position of the mandible and maxilla. Some studies have also shown changes in the position of the tongue and hyoid bone and consequent narrowing of the pharyngeal airway space<sup>2,6-12</sup>. PAS narrowing has been implicated in the development of obstructive sleep apnea<sup>13-15</sup>. OSA is considered to be a risk factor for systemic and pulmonary hypertension, cor pulmonale, polycythemia and cardiac arrhythmias, and might increase morbidity and

mortality<sup>13,16</sup>.

Recently, several studies attempted to investigate the effect of orthognathic surgery on the PAS in patients with Class III deformities<sup>2, 6-11, 17</sup>. Most of these either investigated only the effects of mandibular setback surgery for the correction of the mandibular prognathism or the only resources used to investigate the structures of the pharyngeal airway was lateral cephalometric radiographs (LCR). There is only a few reports evaluating the effects of the bimaxillary surgery for correcting Class III skeletal deformities on PAS and all of them used LCR<sup>2,18,19</sup>. With conventional cephalometric radiography, it is possible to observe the pharyngeal airway, however the observation and measurement of the pharyngeal airway is always limited to the lateral viewing angle<sup>8</sup>. Therefore, a new study evaluating the three dimensional (3D) morphologic changes in pharyngeal airway in class III deformities after bimaxillary surgery and comparing them to mandibular setback surgery by computed tomography (CT) is needed.

Computed tomography (CT) and its 3-dimensional (3D) reconstructive imaging technique are widely used in diagnosis, treatment planning, surgical guidance, evaluation of results and follow-up studies of maxillofacial deformities<sup>8</sup>. Several studies have used CT to evaluate the airway in patients with OSA<sup>20-23</sup>. However, the information within the CT image data includes both hard and soft tissue structures, it



allows visualization of the pharyngeal airway without any obstruction of bony tissue structures<sup>8</sup>

The purpose of this study was to evaluate and compare the 3D morphologic changes in pharyngeal airway in Japanese patients with class III deformities who underwent bimaxillary surgery or mandibular setback surgery with CT imaging.

### **Patients and methods**

In this retrospective study 47 Japanese patients ( 34 females, 13 males) underwent either bimaxillary or mandibular setback surgery for the correction of Class III anteroposterior excess were evaluated. The average age of the patients was  $23.3 \pm 6.3$  years old, ranged from 16 to 42. All 47 patients had pre- and postoperative orthodontic treatment. The surgical procedure in all cases consisted of either bilateral sagittal split ramus osteotomy(BSSRO) or Le Fort I osteotomy with BSSRO fixed rigidly with either titanium or polylactic/polyglycolic acid miniplates. They were divided into 2 groups based on the type of orthognatic surgery they had received. Group A is consisted of 24 patients (17 females, 7 males;  $23.9 \pm 6.9$  years old, ranged from 17 to 42 ) underwent BSSRO setback with rigid fixation while group B is consisted of 23 patients (17 females, 6 males;  $22.6 \pm 5.6$  years old, ranged from 16 to 38) underwent BSSRO setback and Le Fort I with rigid fixation. The mean amount of setback in group A was  $7.0 \pm 3.1$  mm and  $7.0 \pm 3.4$  mm for the right and left sides, respectively. In group B, the mean

amount of setback was  $7.3 \pm 3$  mm for the right side and  $6.6 \pm 3.3$  mm for the left side.

All the patients had intermaxillary fixation (IMF) approximately 1 week after the operation. Elastics were placed maintain the ideal occlusion after IMF

The preoperative CT evaluation of individual patients was performed within a week before the surgery. The postoperative CT evaluation was performed at least 3 months after surgery for all patients as referred by many authors<sup>2, 7-9, 24</sup>. Informed consents were obtained from all patients and the study was approved by Kanazawa University Hospital Committee on Human Research.

The patients were placed in the gantry with the tragocanthal line perpendicular to the ground for CT scanning. The patients were instructed to breathe normally and to avoid swallowing during the scanning process. CT scans were obtained in the same radiology department by skilled radiology technicians using a high speed advantage type CT generator ( Light Speed Plus: GE healthcare, Milwaukee, WI, USA) with each sequence taken 1.25 mm apart for 3D reconstruction image ( 120 kV, average 150mA, 0.7 sec/rotation, helical pitch 0.75). The resulting images were stored in the attached workstation computer ( Advantage workstation ver. 4.2: GE healthcare, Milwaukee, WI, USA) and 3D reconstruction was performed using volume rendering method. The ExaVision LITE version 1.10 medical imaging software ( Ziosoft, Inc, Tokyo, Japan) was used for 3D morphologic measurements.

The exclusion criteria was set as obesity, craniofacial anomaly (Cleft lip, palate, alveolus) and OSA.

The pre- and postoperative upper airway of each patient was studied in two levels:

(Fig.1)

1. The level of most superior anterior point of second cervical spine (C2) parallel to Sella-Nasion line to evaluate the airway between soft palate (SP) and posterior pharyngeal wall (PPW) or between lateral pharyngeal walls (LPWs)

2. The level of most superior anterior point of third cervical spine (C3) parallel to Sella-Nasion to evaluate the airway between base of the tongue (BoT) and PPW or between LPWs

A set of three values was obtained at each airway level: (1) Anteroposterior (AP) dimension on the midsagittal plane (Fig. 2); (2) maximum lateral dimension (LAT) in an orientation perpendicular to the midsagittal plane (Fig. 2); (3) cross sectional area of the airway (CSA) (Fig. 3). The measurement of the CSA was performed simply by following the perimeter of the airway with the cursor. No tracing or digitizing of the axial images was required because the software available automatically calculated the area contained within the scribbled line.

All statistical analyses were carried out using StatView<sup>TM</sup> version 4.5 software (ABACUS Concepts, Inc, Berkeley, CA, USA) The arithmetic mean and standard

deviation were calculated for each variable. A paired *t* test, with statistical significance being inferred at  $P < .05$ , was used to evaluate the differences between preoperative and postoperative pharyngeal airway morphology in each group. Differences between the groups were analysed using unpaired *t* test and  $P < .05$  was considered significant.

All CT images was evaluated and AP, LAT and CSA dimensions were measured by an author (K.D). Fifteen patients was selected randomly and CT images were measured again 10 days later. Paired *t* test was applied to the first and second measurements. The difference between first and second measurements of 15 CT images was insignificant ( $p > .05$ ).

## **Results**

Preoperative and postoperative pharyngeal airway measurements, the paired *t* test results between preoperative and postoperative measurements, the percentage of difference in linear and area measurements of the pharyngeal airway for group A are shown in Table I. All six values in both studied levels were significantly decreased. ( $p < .05$ )

Preoperative and postoperative pharyngeal airway measurements, the paired *t* test results between preoperative and postoperative measurements, the percentage of difference in linear and area measurements of the pharyngeal airway for group B are summarised in Table II. However, all six values in the two studied levels were decreased,

only the reduction of AP dimension on the midsagittal plane between SP and PPW and AP dimension on the midsagittal plane between BoT and PPW were statistically significant ( $p < .0001$ ).

Unpaired  $t$  test revealed that the differences between the values measured among the patients who underwent bimaxillary surgery or mandibular setback surgery were statistically significant for four values: postoperative AP dimension on the midsagittal plane between SP and PPW ( $p = 0.0348$ ), postoperative CSA of the airway at the level of SP-PPW ( $p = .0024$ ), postoperative AP dimension on the midsagittal plane between BoT and PPW ( $p = 0.0092$ ) and postoperative CSA of the airway at the level of BoT-PPW ( $p = 0.0034$ ). The results of the unpaired  $t$  test are shown in Table 3

Although the AP dimensions and CSA areas of the airway significantly decreased in both groups, the decreases were less in cases treated with bimaxillary surgery than mandibular setback surgery. ( $p < .05$ ) The lateral dimensions of the airway decreased in both groups. However, there were no statistically significant differences between bimaxillary surgery and mandibular setback surgery. ( $p > .05$ )

The unpaired  $t$  test revealed no significant differences between in any preoperative values of the 2 groups. All six measured values showed a larger decrease in mandibular setback surgery group than bimaxillary surgery group after surgery.

## **Discussion**

PAS narrowing after orthognathic surgery has drawn increasing attention in recent years<sup>2, 18</sup>. Main reason for this interest, in a small number of patients, mandibular setback procedures can be the initiating factor in the development of OSA<sup>13-15</sup>. The mandible, base of tongue, hyoid bone and pharyngeal walls are intimately related by their muscular and ligamentous attachments. The mandible is related to the base of the tongue by the genioglossus muscle. The tongue, through multiple muscular and connective tissue attachments, is related to the hyoid bone and to the mandible in such a way that retraction of the mandible results in a narrowing of the airway and posterior movement of the tongue<sup>13</sup>.

Based on lateral cephalometric analysis, many studies indicated that the anatomic alterations for OSA were inferior displacement of the hyoid bone and, consecutive posterior displacement of the base of the tongue, consequent pharyngeal narrowing<sup>2</sup>.

Maxillomandibular advancement surgery has been shown to be very efficacious in the elimination of OSA because it enlarges the pharyngeal airway space and tightens the upper airway muscles and tendons, mainly the velopharyngeal and suprahyoid muscles, by advancement their bony origin<sup>7,23,24</sup>.

In contrast, mandibular setback surgery is known to cause a narrowing of pharyngeal airway<sup>2, 7-12,17,19</sup>. Previous studies have shown changes in the positions of the tongue and the hyoid bone and consequent narrowing of the PAS after orthognathic surgical

procedures in a pattern closely resembling that seen in sleep apnea subjects<sup>9-12,17,19</sup>. The narrowing of the pharyngeal airway leads to increased velocity of flow and subsequently to a further reduction in intraluminal pressure, further pharyngeal narrowing. Eventually, complete pharyngeal obstruction occurs<sup>25</sup>.

Although the vast majority of patients who undergo mandibular setbacks are able to adapt to the changes in the skeletal and muscular apparatus, there is a subset of patients who maybe at risk for developing overt sign of obstructive sleep apnea following mandibular setbacks<sup>13</sup>. Guilleminault et al<sup>14</sup> and Riley et al<sup>15</sup> reported two cases of OSA which were previously treated with mandibular setback as a surgical correction of mandibular hyperplasia with Class III malocclusion<sup>14, 15</sup>.

Many studies have been performed to assess time dependent pharyngeal airway changes after orthognathic surgery. Hochban et al<sup>7</sup> reported that no significant changes in pharyngeal dimensions could be seen on cephalometric follow-up at 3 months and 1 year, respectively, as compared to the 1-week postoperative situation<sup>7</sup> Chen et al<sup>2</sup> reported that changes in airway measurements showed significant differences from before surgery to 3-6 months after surgery and 2 years after surgery whereas changes from 3-6 months after surgery to 2 years after surgery showed no significant changes<sup>2</sup> Kawamata et al<sup>8</sup> found that there was a significant pharyngeal narrowing 3 months after surgery and no significant tendency to recover in the average rate of pharyngeal

narrowing at either 6 months or 1 year after surgery<sup>8</sup>. Kawakami et al<sup>9</sup> suggested that 1 month after surgery was adequate to let the postoperative swelling in the soft tissue to settle since the narrowed airway was also a result of this<sup>9</sup>. In deference to these results we selected 3 months as the post-surgical time frame.

Multiple imaging techniques include cephalometry, computed tomography, magnetic resonance imaging have been used to evaluate the PAS<sup>2,8,26</sup>.

Cephalometric radiography is an indispensable imaging technique for orthodontic treatment and able to provide valuable skeletal information for upper airway morphology. However, it provides 2-dimensional representation of a 3-dimensional structure and is unable to provide volumetric data or evaluate important soft tissue structures such as uvulopalatal complex and BoT, some authors stated that they were still used extensively in the assessment of sleep apnea and craniofacial form with the advantages of its wide availability, simplicity, low expense and ease of comparison with extensive normative data and other studies<sup>2, 27</sup>. Although, some studies comparing airway dimensions on LCRs and 3D CT, reported significant correlation between the PAS measured with LCR and the volume of the pharyngeal airway on CT, LCR provides no information about the lateral structures and CSA of the upper airway<sup>28</sup>. Besides, in frontal cephalometric radiography, hard tissue structures such as anterior teeth, mandible and the pharyngeal airway overlap<sup>8</sup>.



Computed tomography carries significant advantages over plain radiographs as it allows better delineation of soft tissue and air, therefore more accurate measurements for upper airway morphology<sup>21</sup>. Skeletal maxillary and mandibular changes may be described by the change in the sagittal dimension only, whereas the soft tissue pharyngeal changes must be considered in a 3D way<sup>7</sup>. CT scan is a noninvasive technique that permits a detailed 3D assessment of the entire upper airway and has been validated for quantitative measurements of the pharyngeal CSA<sup>20</sup>. Kawamata et al<sup>8</sup> reported that 3D CT provided an adequate image for evaluating morphologic airway changes<sup>8</sup>. Athanasios<sup>29</sup> stated that CT and MRI techniques appeared to be superior to cephalometry with regard to estimating the size of oropharynx and hypopharynx<sup>29</sup>.

Studies have been performed to quantify normal values for the PAS, as well as values in patients with OSA syndrome<sup>30</sup>. The normal value for PAS based on a lateral cephalometric radiograph is found to be  $11 \pm 2$  mm<sup>10</sup>. Hochban et al<sup>7</sup> evaluated 16 patients who underwent mandibular setback surgery and found that the average preoperative PAS in prognathic patient was 16.6 mm between BoT and PPW<sup>7</sup>. They proposed that preoperative airway size was larger than average in prognathic patients.

Chen et al<sup>31</sup> studied on 23 Japanese women with Class III deformity and found that the airway size was within normal values contrary to Hochban et al<sup>7</sup>'s findings<sup>31</sup>. In this present study, the average preoperative PAS in our patients was  $15 \pm 3.1$  mm. This

results supports Hochban et al<sup>7</sup>'s findings that claimed preoperative airway size was larger than normal values in patients with Class III deformity.

Reduced pharyngeal airway space is due to morphologic narrowing of the SP and/or the BoT against the PPW<sup>24</sup>. In a retrospective study, Tselnik and Pogrel<sup>6</sup> evaluated PAS after mandibular setback surgery with LCRs. They found the mean reduction in AP dimension from the BoT to PPW as 4.77 mm which correspond to a %28 reduction. They also reported that the mean reduction in PAS area was 12 % to 15 % in a lateral cephalogram<sup>6</sup>. Kawamata et al<sup>8</sup> studied pharyngeal airway changes after mandibular setback osteotomies in 30 patients by means of 3D CT and reported that average rate of the AP pharyngeal narrowing 3 months after surgery was %24 while average diminished rate of lateral pharyngeal narrowing was 12%<sup>8</sup>.

Chen et al<sup>2</sup> evaluated the lateral cephalograms of 66 Japanese women and found that in mandibular setback surgery alone AP dimension reduction between uvula- PPW and vallecula-PPW was 32% for short term follow-up and 21% for long term follow-up, respectively. Due to their study, in bimaxillary surgery AP dimension reduction between uvula-PPW was 20% for short term follow-up and 10% for long term follow-up and between vallecula-PPW was 15% for short term follow-up and 7% for long term follow-up<sup>2</sup>. In present study, we found %20 and 21% reduction of AP dimension between SP-PPW and BoT-PPW, respectively, among the patients who underwent

mandibular setback surgery alone. In bimaxillary surgery group, the reduction of AP dimension between SP-PPW and BoT-PPW was 16% and 15%, respectively. Our results was nearly consistent with findings of the other studies.

Bimaxillary surgery is considered to decrease the reduction effect of mandibular setback surgery<sup>2,32</sup>. Mehra et al<sup>18</sup> evaluated the effects of double-jaw surgery on the PAS and velopharyngeal anatomy with LCRs. They found that the mean decrease in PAS of the patients treated with mandibular setback and maxillary advancement was 47% for SP level and 65% for BoT level<sup>18</sup>. A review of available literature between 1987 and 2007 concluded that these findings are the most extreme results. Samman et al<sup>32</sup> studied pre- and postmaxillary surgery measurements regarding changes in pharyngeal airway dimensions at 6 months follow up in 19 patients and reported statistically significant decreases at the oropharyngeal and hypopharyngeal levels<sup>32</sup>. Our results are consistent with these findings.

A number of studies have also shown that diminished CSA of the pharynx may predispose a person to pharyngeal collapse<sup>20, 22, 24, 25</sup>. In our study, however, postoperative PAS CSA decreased at both levels evaluated in all patients, regardless of type of surgery performed, either mandibular setback surgery or bimaxillary surgery, the decreases were less in cases treated with bimaxillary surgery than mandibular setback surgery ( $p < .05$ ) and any of the patients complained about any symptoms of

pharyngeal collapse. The reason of absence of complains about any symptoms of pharyngeal collapse might be the larger AP dimensions and theoretically larger CSA dimensions related to AP dimension-. There is no information about normal CSA values. More studies are needed to compare the CSA dimensions of Class III patients and normal population

A systematic review of literature by Rama et al<sup>33</sup> revealed that oropharynx level might be the most compromised portion of the airway in OSA subjects<sup>33</sup>. Schwab<sup>34</sup> proposed that the retropalatal region in patients with OSA was narrowed in the lateral aspect and the contrary, the retropalatal region in nonapneic people was narrowed in the AP dimension<sup>34</sup>. Li et al<sup>20</sup> reported that lateral narrowing of retropalatal region was closely associated with the degree of sleep apnea in their study<sup>20</sup>. In our study, average rate of lateral pharyngeal narrowing was 12% and 7% at the level of SP-PPW and BoT-PPW, respectively in mandibular setback surgery group while it was 5% and 2% at the level of SP-PPW and BoT-PPW, respectively, in bimaxillary surgery group. Lateral pharyngeal narrowing was statistically significant in mandibular setback surgery group ( $p < .05$ ) while it was insignificant in bimaxillary surgery group. The reduction of the lateral pharyngeal width may have been due to postoperative displacement of the medial pterygoid muscles<sup>8</sup>. Maxillary surgery might decrease the reduction of lateral width, which is an effect of mandibular setback surgery, by elevating the tissues attached to the

maxilla like velum and velopharyngeal muscles<sup>32</sup>.

Lam et al<sup>21</sup> reported that CSA at the level of uvula-PPW was a significant determinant of the presence of OSA<sup>21</sup>. This result suggest that anatomical variation, specifically small CSA of the oropharyngeal airway, is likely to explain the presence of obstructive events. In our study, we observed that average rate of CSA narrowing was 35 % and 29 % at the level of SP-PPW and BoT-PPW, respectively in mandibular setback surgery group while it was 15% and 8 % at the level of U-PPW and BoT-PPW, respectively, in bimaxillary surgery group. CSA narrowing of both levels was significant in mandibular setback surgery group ( $p<.001$ ) and insignificant in bimaxillary surgery group.

Some studies suggested that ethnicity also was an important factor in OSA<sup>20-22</sup>. Li et al<sup>35</sup> reported that many Far East Asian subjects had greater severity of OSA syndrome<sup>35</sup>

Although many of the cephalometric measurements are less abnormal in the Far East Asian subjects, the cranial base dimensions were significantly decreased, thus, potentially contributing to narrowing of the airway between uvula and PPW<sup>35-36</sup>

However, in our study, we did not observe any significant narrowing at the level of SP-PPW preoperatively, CSA at the level of SP-PPW was the most narrowing part of the entire airway in both groups postoperatively. Although, any of the patients complained about any symptoms of OSA syndrome. With the knowledge of the anatomical differences in Far East Asian people and SP-PPW region was being the most

narrowing part of entire airway after mandibular setback procedures, one should be warned about the higher risk of OSAS after mandibular setback procedures in Far East Asian people .

In present study, postoperative PAS decreased in all patients after mandibular setback surgery with or without Le Fort I surgery. This agrees with the findings of previous studies<sup>2,18, 19</sup> . Although, airway dimensions decreased at both levels for all values measured in either mandibular set back surgery or bimaxillary surgery patients, the reduction is less in bimaxillary surgery patients than mandibular setback surgery patients. The advancement of the velum and velopharyngeal muscles caused by the Le Fort I osteotomy might be a reason for partly reducing the constriction effect of mandibular setback surgery . ( Samman 2002)

However, the mean postoperative AP dimension between BoT and PPW in mandibular setback surgery group (  $11.3\pm 2.7$ mm) decreased, it was slightly under normal values ( $11\pm 2$  mm). In bimaxillary surgery group, even postoperatively, the mean postoperative AP dimension between BoT and PPW ( $13.5\pm 2.9$  mm) was higher than normal values ( $11\pm 2$  mm). These results may explain why OSA syndrome was too rare after mandibular setback procedures in prognathic patient population.

## Conclusion

However, AP dimension seems important to evaluate the morphologic airway changes,

securing the CSA should also be considered. According to the results of this study, one should expect less narrowing in AP, LAT and CSA dimensions of the PAS after bimaxillary surgery when compared to mandibular setback surgery alone. Therefore, bimaxillary surgery rather than only mandibular setback surgery to correct a Class III deformity should be preferred to prevent the development of OSA.

## References

1. Samman N, Tong AC, Cheung DL, Tideman H. Analysis of 300 dentofacial deformities in Hong Kong. *Int J Adult Orthod Orthognath Surg* 1992; 7: 181-185.
2. Chen F, Terada K, Hua Y, Saito I. Effect of bimaxillary surgery and mandibular setback surgery on pharyngeal airway measurements in patients with Class III skeletal deformities. *Am J Dentofacial Orthop* 2007; 131: 372-377.
3. Bloomquist DL, Lee JL. Principles of mandibular orthognathic surgery. In: Miloro M, ed: *Peterson's principles of oral and maxillofacial surgery*. London: BC Decker: 2004; p.1135-1138.
4. Reyneke JP. *Essentials of orthognathic surgery*. Illinois: Quintessence Publishing Co, Inc, 2003; p.164.
5. Busby BR, Bailey LJ, Proffit WR, Phillips C, White RP Jr. Long term stability of surgical Class III treatment: a study of 5-year postsurgical results. *Int J Adult Orthod Orthognath Surg* 2002; 17: 159-170.
6. Tselnik M, Pogrel MA. Assesment of the pharyngeal airway space after mandibular setback surgery. *J Oral Maxillofac Surg* 2000; 58: 282-285.
7. Hochban W, Schürmann R, Brandenburg U, Conradt R. Mandibular setback for surgical correction of mandibular hyperplasia – does it provoke sleep-related breathing disorders? *Int J Oral Maxillofac Surg* 1996; 25: 333-338.



8. Kawamata A, Fujishita M, Ariji Y, Ariji E. Three dimensional computed tomographic evaluation of morphologic airway changes after mandibular setback osteotomy for prognathism. *Oral Surg Oral Med Oral Pathol Oral Radiol Endod* 2000; 89: 278-287.
9. Kawakami M, Yamamoto K, Fujimoto M, Ohgi K, Inoue M, Kirita T. Changes in tongue and hyoid positions and posterior airway space following mandibular setback surgery. *J Cranio-Maxillofac Surg* 2005; 33: 107-110.
10. Guven O, Saracoglu U Changes in pharyngeal airway space and hyoid bone positions after body osteotomies and sagittal split ramus osteotomies. *J Craniofac Surg* 2005;16: 23-30.
11. Enacar A, Aksoy AU, Sencift Y, Haydar B, Aras K. Changes in hypopharyngeal airway space and in tongue and hyoid bone positions following the surgical correction of mandibular prognathism. *Int J Adult Orthod Orthognath Surg* 1994; 9 :285-290.
12. Athanasiou AE, Toutountzakis N, Mavreas D, Ritzau M, Wenzel A. Alterations of hyoid bone position and pharyngeal depth and their relationship after surgical correction of mandibular prognathism. *Am J Dentofacial Orthop* 1991; 100: 259-265.
13. Tiner BD, Waite PD. Surgical and nonsurgical management of obstructive sleep apnea. In: Miloro M, ed: *Peterson's principles of oral and maxillofacial surgery*. London: BC Decker: 2004; p1301-1310.
14. Guilleminault C, Riley R, Powell N. Sleep apnea in normal subjects following

mandibular osteotomy with retrusion. *Chest* 1985; 88: 776-778.

15. Riley R, Powell R, Guilleminault C. Obstructive sleep apnea syndrome following surgery for mandibular hyperplasia. *J Oral Maxillofac Surg* 1987; 45: 450-452.

16. George CF, Smiley A. Sleep apnea and automobile crashes. *Sleep* 1999; 22: 790-795.

17. Saitoh K. Long-term changes in pharyngeal airway morphology after mandibular setback surgery. *Am J Dentofacial Orthop* 2004; 125: 556-561.

18. Mehra P, Downie M, Pita MC, Wolford LM. Pharyngeal airway space after counterclockwise rotation of the maxillomandibular complex. *Am J Dentofacial Orthop* 2001; 120: 154-159.

19. Turnbull NR, Battagel JM. The effects of orthognathic surgery on pharyngeal airway dimensions and quality of sleep. *J Orthod* 2000; 27: 235-247.

20. Li HY, Chen NH, Wang CR, Shu YH, Wang PC. Use of 3-dimensional computed tomography scan to evaluate upper airway patency for patients undergoing sleep-disordered breathing surgery. *Otolaryngol Head Neck Surg* 2003; 129: 336-342.

21. Lam B, Ooi CG, Peh WC, Lauder I, Tsang KW, Lam WK, Ip MS. Computed tomographic evaluation of the role of craniofacial and upper airway morphology in obstructive sleep apnea in chinese. *Respir Med* 2004; 98: 301-307.

22. Chen NH, Li KK, Li SY, Wong CR, Chuang ML, Hwang CC, Wu YK. Airway

assessment by volumetric computed tomography in snorers and subjects with obstructive sleep apnea in a Far East Asian population (Chinese) *Laryngoscope* 2002; 112: 721-726.

23. Waite PD, Vilos GA. Surgical changes of posterior airway space in obstructive sleep apnea. 2002; 14: 385-399.

24. Fairburn SC, Waite PD, Vilos G, Harding SM, Bernreuter W, Cure J, Cherala S. Three dimensional changes in upper airways of patients with obstructive sleep apnea following maxillomandibular advancement. *J Oral Maxillofac Surg* 2007; 65: 6-12.

25. Badr MS. Pathophysiology of obstructive sleep apnea *Oral Maxillofacial Surg Clin N Am* 2002; 14: 285-292.

26. Meisami T, Musa M, Keller MA, Cooper R, Clokie CM, Sandor GK. Magnetic resonance imaging assessment of airway status after orthoganthic surgery. *Oral Surg Oral Med Oral Pathol Oral Radiol Endod* 2007; 103: 458-463.

27. Ozbek MM, Miyamoto K, Lowe AA, Fleetham JA. Natural head posture, upper airway morphology and obstructive sleep apnea severity in adults. *Eur J Orthod* 1998; 20: 133-143.

28. Schwab RJ. Upper airway imaging *Clin Chest Med* 1998; 19: 33-54.

29. Athanasios AE. Assessment of the pharyngeal airway space after mandibular setback surgery. *J Oral Maxillofac Surg* 2000; 58: 285-287.

30. Prachartam N, Nelson N, Hans MG, Broadbent BH, Redline S, Rosenberg C, Strohl KP. Cephalometric assessment in obstructive sleep apnea. *Am J Dentofacial Orthop* 1996; 109: 410-419.
31. Chen F, Terada K, Hua Y, Saito I Predicting the pharyngeal airway space after mandibular setback surgery. *J Oral Maxillofac Surg* 2005; 63: 1509-1514.
32. Samman N, Tang SS, Xia J. Cephalometric study of the upper airway in surgically corrected class III skeletal deformity. *Int J Adult Orthod Orthognath Surg* 2002; 17: 180-190.
33. Rama AN, Tekwani SH, Kushida CA. Sites of obstruction in obstructive sleep apnea. *Chest* 2002; 122: 1139- 1147.
34. Schwab RJ Upper airway and soft tissue anatomy in normal subjects and patients with sleep-disordered breathing. Significance of the lateral pharyngeal walls. *Am J Respir Crit Care Med*. 1995; 152: 1673-89.
35. Li KK, Kushida C, Powell NB, Riley W, Guilleminault C. Obstructive sleep apnea syndrome: A comparison between far-east asian and white men. *Laryngoscope* 2000; 110: 1689-1693.
36. Liu Y, Lowe AA, Zeng X, Fu M, Fleetham JA. Cephalometric comparisons between Chinese and Caucasian patients with obstructive sleep apnea *Am J Dentofacial Orthop* 2000; 117: 479-485.

## **FIGURE LEGENDS**

Figure 1. M1: The level of most superior anterior point of second cervical spine (C2) parallel to Sella-Nasion line to evaluate the airway between soft palate (SP) and posterior pharyngeal wall (PPW)

M2: The level of most superior anterior point of third cervical spine (C3) parallel to Sella-Nasion to evaluate the airway between base of the tongue (BoT) and posterior pharyngeal wall (PPW)

Figure 2. Anteroposterior (AP) dimension on the midsagittal plane (black arrows) and maximum lateral (LAT) dimension (white arrows) between lateral pharyngeal walls (LPWs) in an orientation perpendicular to the midsagittal plane. A: SP-PPW level B: BoT-PPW level

Figure 3. Cross sectional area (CSA) of the airway (Arrows) A: SP-PPW level B: BoT-PPW level

## **TABLE LEGENDS**

Table 1. Statistical Analysis and reduction ratios for group A. APD: Anteroposterior dimension SP: Soft palate PPW: Posterior pharyngeal wall LD: Lateral dimension LPW: Lateral pharyngeal wall CSA: Cross sectional area BoT: Base of tongue

Table 2. Statistical Analysis and reduction ratios for group B

Table 3. The comparison of airway narrowing in linear and area measurements by

unpaired  $t$  test. between group A and group B

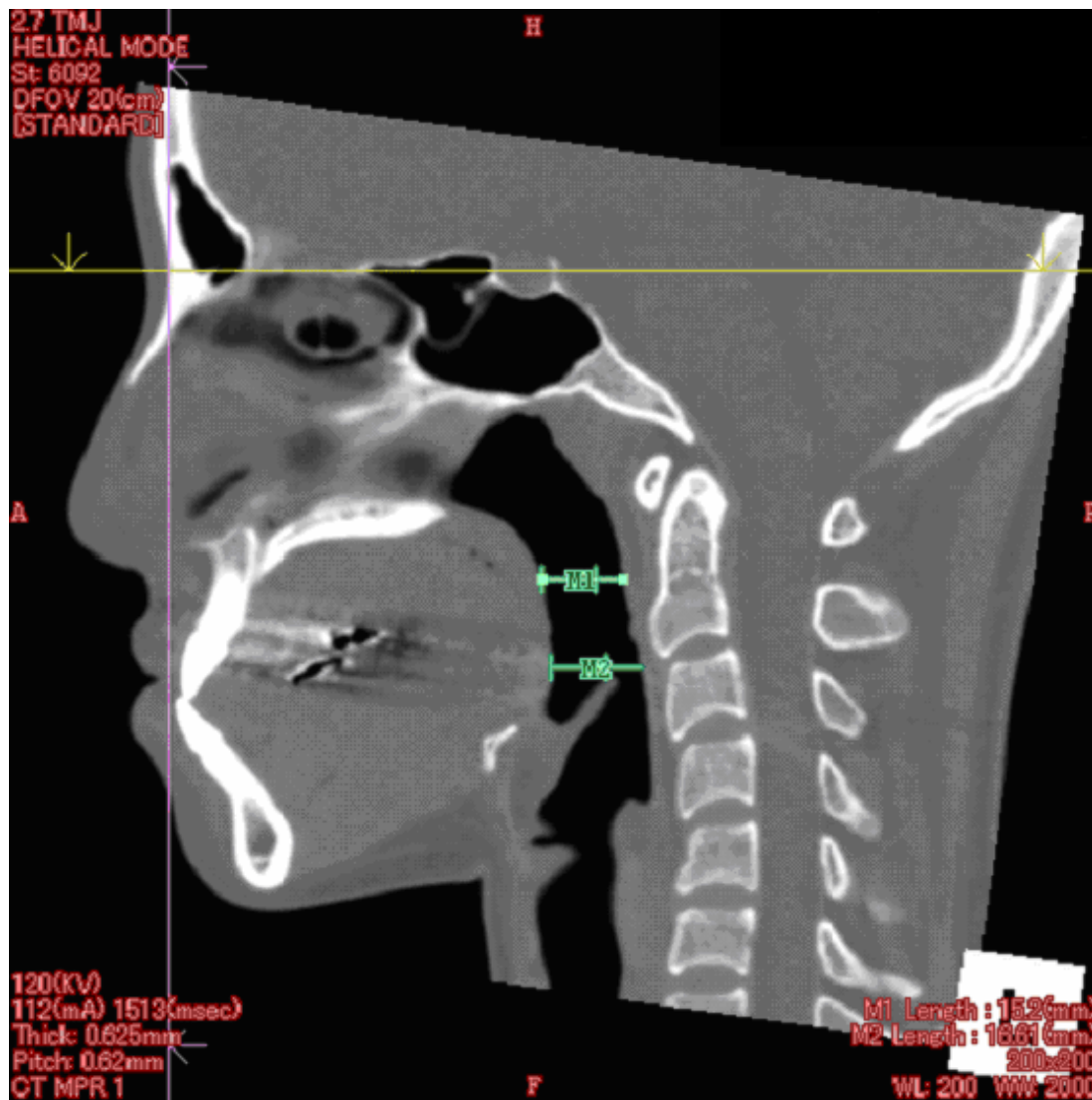


Figure 1.

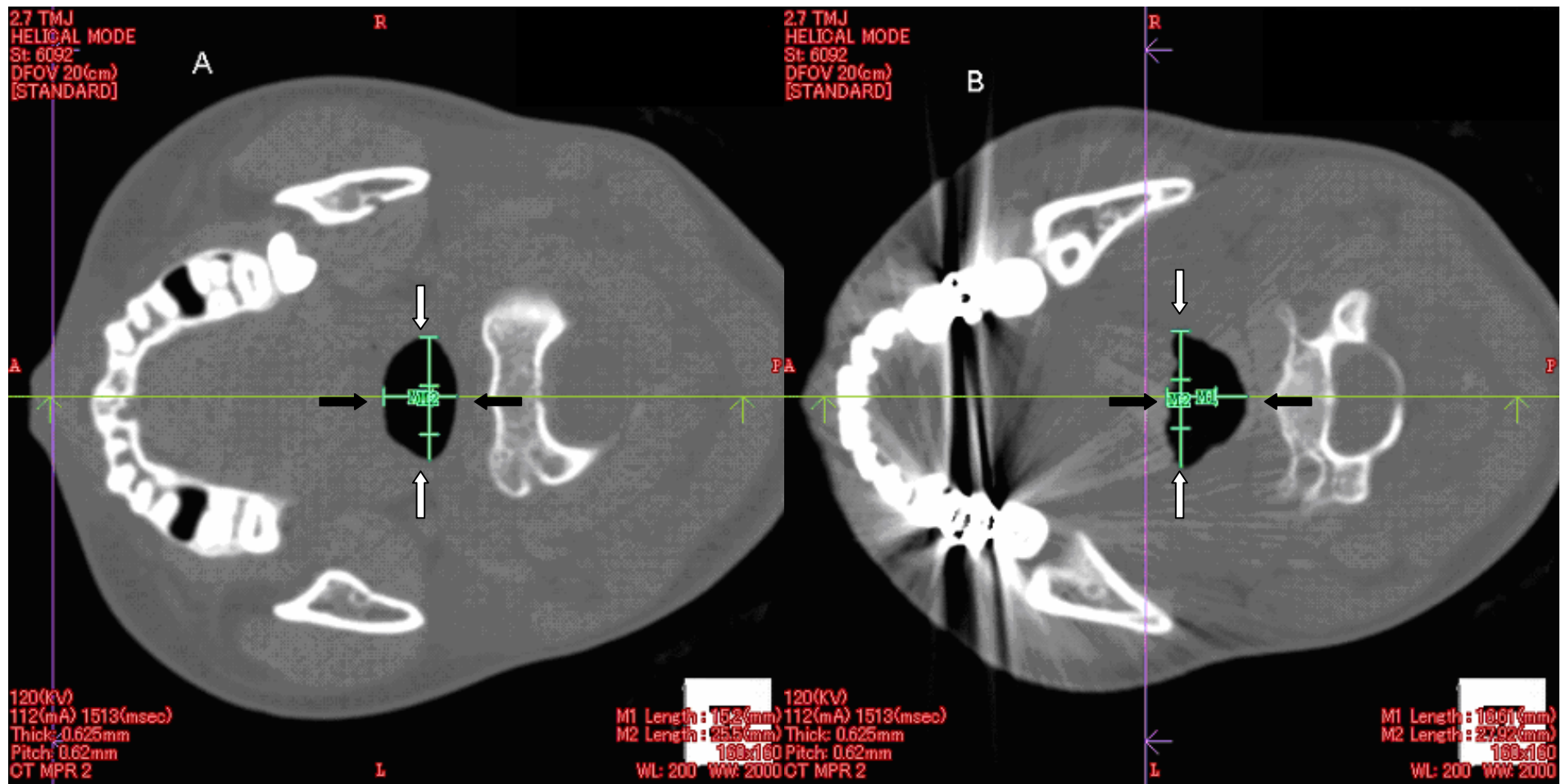


Figure 2.



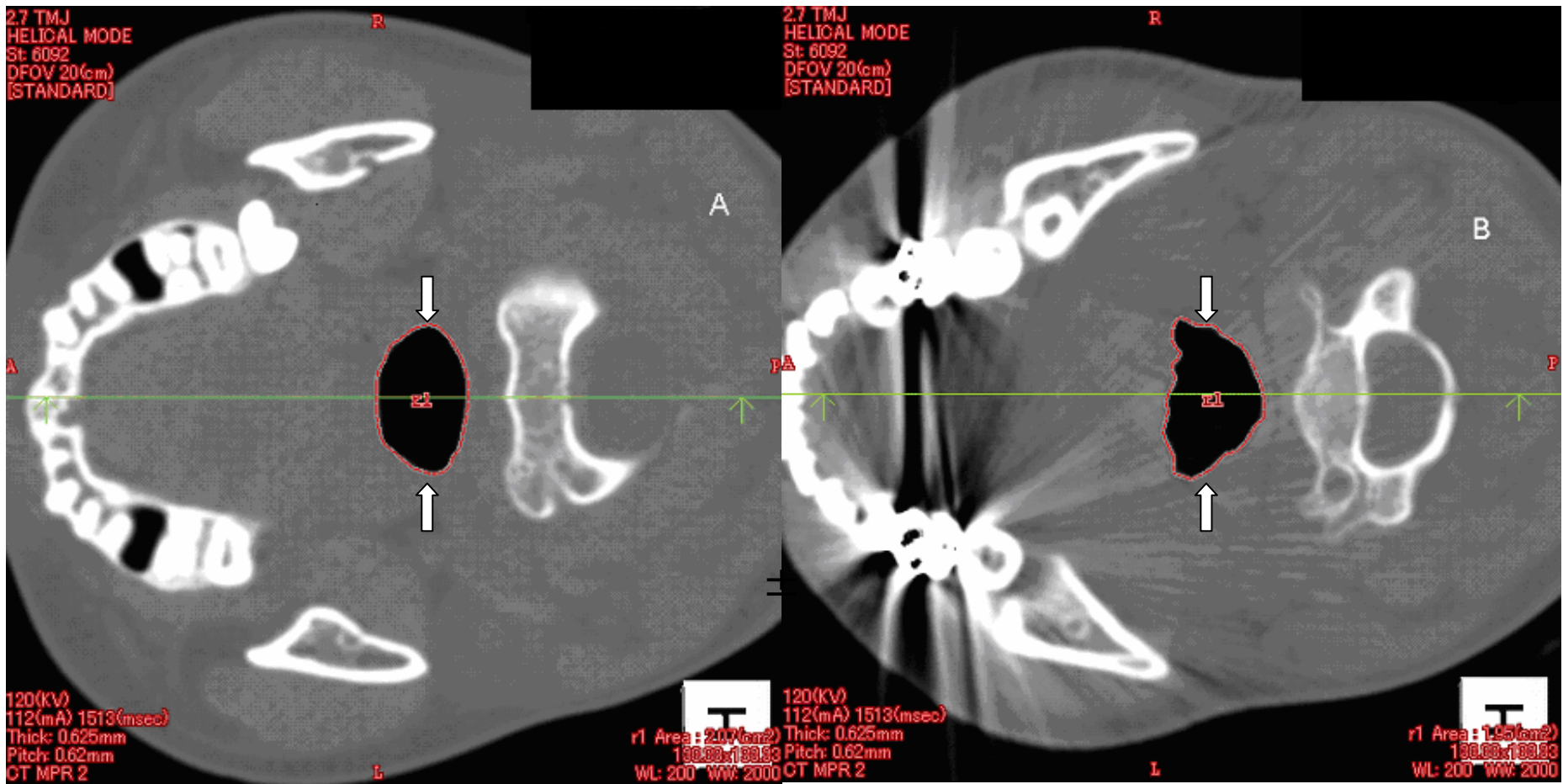


Figure 3.

	<b>Pre-Op</b>	<b>Post-Op</b>	<b><i>t</i> test</b>	<b>Reduction Rate</b>
APD SP-PPW	11.37±2.84	9.01±2.20	<.0001	20%
LD LPW <sub>s</sub> SP-PPW	21.81±5.42	19.17±4.37	.0006	12%
CSA SP-PPW	1.45±0.75	0.95±0.37	.0002	35%
APD BoT-PPW	14.24±3.16	11.27±2.67	<.0001	21 %
LD LPW <sub>s</sub> BoT-PPW	25.59±4.68	23.77±4.71	.0238	7%
CSA BoT-PPW	1.90±0.79	1.34±0.54	<.0001	29%

Table 1.

	<b>Pre-Op</b>	<b>Post-Op</b>	<b><i>t</i> test</b>	<b>Reduction Rate</b>
APD SP-PPW	13.07±4.94	10.93±3.69	<.0001	16%
LD LPWs SP-PPW	22.66±6.02	21.47±6.15	.2815	5%
CSA SP-PPW	1.78±0.91	1.52±0.78	.0633	15%
APD BoT-PPW	15.83±2.87	13.49±2.91	<.0001	15%
LD LPWs BoT-PPW	26.69±6.05	26.20±5.99	.5537	2%
CSA BoT-PPW	2.09±0.76	1.91±0.72	.2049	8%

Table 2.

	Pre-Op			Post-Op		
	Group A	Group B	<i>t</i> test	Group A	Group B	<i>t</i> test
APD SP-PPW	11.37±2.84	13.07±4.94	.1521	9.01±2.20	10.93±3.69	.0348
LD LPWs SP-PPW	21.81±5.42	22.66±6.02	.6117	19.17±4.37	21.47±6.15	.1455
CSA SP-PPW	1.45±0.75	1.78±0.91	.1819	0.95±0.37	1.52±0.78	.0024
APD BoT-PPW	14.24±3.16	15.83±2.87	.0777	11.27±2.67	13.49±2.91	.0092
LD LPWs BoT-PPW	25.59±4.68	26.69±6.05	.4877	23.77±4.71	26.20±5.99	.1282
CSA BoT-PPW	1.90±0.79	2.09±0.76	.4255	1.34±0.54	1.91±0.72	.0034

Table 3.