

A Comparative Study of Topical vs Retrobulbar Anesthesia in Complicated Cataract Surgery

Philipp C. Jacobi, MD; Thomas S. Dietlein, MD; Felix K. Jacobi, MD

Objectives: To evaluate and compare levels of patient discomfort and perioperative complications during phacoemulsification and implantation of a foldable intraocular lens under topical lidocaine hydrochloride and retrobulbar anesthesia in patients with cataract who also had exfoliation syndrome, uveitis, posterior synechia, phacodonesis, or previous intraocular surgery.

Design: A prospective, randomized, controlled trial was carried out at 2 institutions.

Participants: A total of 476 eyes of 476 patients with various well-established risk factors fulfilled the inclusion criteria. In 238 eyes, phacoemulsification was performed under retrobulbar anesthesia, while the other 238 eyes received topical anesthesia.

Interventions: All patients underwent temporal clear corneal phacoemulsification and implantation of a foldable intraocular lens. Patients under retrobulbar anesthesia received a single injection (3.5-5.5 mL) of a combination of 0.75% bupivacaine hydrochloride, 2% lidocaine, and hyaluronidase into the retrobulbar space. Patients in the topical anesthesia group received a minimum of 5 doses (approximately 40 μ L per dose) of 2% topical lidocaine. No intracameral injection of any anesthetic was given.

Main Outcome Measures: The number of complications and adverse events. The intraoperative conditions were judged by the surgeon (P.C.J. or F.K.J.), and a 10-point visual analog scale was used immediately after sur-

gery to assess each patient's overall severity of intraoperative pain.

Results: The overall intraoperative complication rate was 1.9% for capsular tear, 3.8% for zonular tear, 1.5% for vitreous loss, and 1.0% for iris prolapse. Apart from the incidence of vitreous loss, which was significantly ($P=.041$) lower in the topical anesthesia group, no statistically significant differences in intraoperative and early postoperative complications were found between the groups. A supplemental posterior sub-Tenon space injection was required in 1.3% of the topical anesthesia group and in 0.8% of the retrobulbar anesthesia group. Chemosis (2.5%), subconjunctival hemorrhage (1.7%), and periorbital hematoma (0.8%) were seen only in the retrobulbar anesthesia group. The mean \pm SE pain scores estimated by the patients were 0.84 ± 1.30 in the topical anesthesia group and 0.73 ± 1.50 in the retrobulbar anesthesia group ($P=.41$). Patient preference for topical anesthesia (91%) appeared to be significantly ($P=.01$) higher than for retrobulbar anesthesia (62%). The surgeons found anesthesia-related intraoperative difficulty to be slightly lower in the retrobulbar anesthesia group (8%) than in the topical anesthesia group (14%).

Conclusions: Surgery-related complications and patient discomfort were similar for the 2 methods of anesthesia. Topical anesthesia is justified as a means of improving safety without causing discomfort to the patient even in complicated cases of cataract surgery.

Arch Ophthalmol. 2000;118:1037-1043

From the Departments of Ophthalmology, University of Cologne, Cologne (Drs P. C. Jacobi and Dietlein), and University of Giessen, Giessen (Dr F. K. Jacobi), Germany. None of the authors has a proprietary interest in the development or marketing of any piece of equipment described in this study.

RETROBULBAR INJECTION of anesthetic agents has been used for more than a century in cataract surgery. Despite various modifications that have been devised over the decades to reduce the potential risks of injuring intraorbital structures, the "blind" insertion of a needle into the retrobulbar space has never been completely free of several sight- and life-threatening complications.¹⁻⁵ Topical anesthesia was first

proposed by Fichman⁶ as an attractive alternative to the traditional method of injecting local anesthetic agents, resulting in faster visual recovery and high patient satisfaction. The advantages of topical anesthesia include its ease of application, minimal to absent discomfort on administration, rapid onset of anesthesia and, most important, elimination of the potential risks associated with retrobulbar injections.⁶⁻¹⁰ In addition to all of these advantages, the technique is economical,

PATIENTS AND METHODS

PATIENT SELECTION

From April 1, 1998, to June 1, 1999, a continuous cohort of 1135 eyes of 1135 patients was eligible for phacoemulsification surgery and foldable IOL implantation with either topical or retrobulbar anesthesia in either of the 2 participating university eye centers. Patients were prospectively assigned to the topical or the retrobulbar anesthesia group using a random numbers table. The patients included in the study all had at least 1 of the following ocular comorbidities: exfoliation syndrome, uveitis, axial myopia (≥ 26 mm), axial hyperopia (≤ 21.0 mm), poor pupillary dilation (≤ 3 mm), posterior synechia, phacodonesis, or previous intraocular surgery (peripheral iridectomy, glaucoma filtering surgery, keratoplasty, or pars plana vitrectomy). Patients were excluded from the study if they had a history of allergic response to lidocaine hydrochloride or other topical anesthetic agents, hearing impairment, dementia, eye movement disorder, or excessive anxiety; had poor fixation due to nystagmus or strabismus; or were not native speakers of the language used in the operating room. Other contraindications to participation in the study included complex anterior segment pathological features that might preclude proper visualization of the anterior chamber intraoperatively or might cause problems affecting clear corneal tunnel preparation, such as the extensive corneal opacification resulting from spheroid degeneration or the marginal thinning of the cornea produced by Terrien marginal degeneration. Informed consent was obtained before surgery.

ANESTHESIA ADMINISTRATION

Patients in the retrobulbar anesthesia group received an oral sedation of 5.1 to 10.2 mg of midazolam hydrogenmaleat (Dormicum; Hoffmann-La Roche AG, Grenzach, Germany) 30 minutes before a single injection of a solution of 0.5% bupivacaine hydrochloride, 2% lidocaine, and 0.5 mL of hyaluronidase (Wydase), 3.75 IU/mL, into the retrobulbar space. The volume of the block was 3.5 to 5.5 mL, depending on the weight of the patient. Ocular compression for 10 minutes was achieved using a modified Honan balloon. Before surgery, the effectiveness of the block was assessed by the surgeon (P.C.J. or F.K.J.) and deemed satisfactory only if minimal ocular mobility or orbicularis function remained.

Patients in the topical anesthesia group received a minimum total of 5 doses (approximately 40 μ L per dose) of 2% topical lidocaine. Four doses were administered into the superior and inferior culs-de-sac at 10 minutes and 5 minutes before surgery, before draping, and immediately before initial corneal incision. The final dose was administered before the commencement of phacoemulsification. The protocol established for breakthrough pain allowed an additional 80 μ L of 2% lidocaine and 40 μ L of cocaine. If this was not effective within 2 minutes, the patient would receive a subconjunctival injection of 0.75% bupivacaine. Breakthrough pain was countered in the same way in the retrobulbar anesthesia group.

SURGICAL TECHNIQUE

All surgical procedures were performed in 1 of the 2 participating university eye centers by 1 of 2 surgeons (P.C.J. or F.K.J.) who had performed cataract surgery using topical

anesthesia since 1995, using a standardized clear corneal phacoemulsification technique. All patients underwent temporal clear corneal phacoemulsification and implantation of a foldable IOL. A temporal clear corneal incision was made using a 3-step incision while the globe was immobilized with a Thornton-Fine ring. This was followed by paracenteses of 2 side ports, each 90° from the temporal meridian, to allow for subsequent procedures. These included viscoelastic injection, continuous curvilinear capsulorhexis, hydrodissection, hydrodelineation, endocapsular phacoemulsification, bimanual aspiration of the remaining cortical lens material, and, finally, in-the-bag implantation of a foldable IOL. Where necessary, the pupil was dilated with sphincterotomies or iris retraction hooks. Following IOL implantation and removal of the viscoelastic substance, the pupil was constricted with intracameral application of 0.01% carbachol (Miostat; Alcon Surgical, Ft Worth, Tex). The wound was tested for leakage of fluid by gentle compression with a sponge, and none of the patients required a suture to close the wound. All patients received an identical topical regimen in the postoperative period, including 50 mg of mezlocillin (Baypen; Bayer, Leverkusen, Germany) and 2 mg of dexamethasone acetate (Fortecortin; Merck, Cologne, Germany) injected subconjunctivally immediately after surgery. During postoperative recovery, each patient received topical corticosteroid drops and a combination of a corticosteroid and antibiotic ointment at night, the dosage being rapidly reduced depending on the degree of postoperative inflammation.

PAIN ASSESSMENT

On completion of the operation, each patient was shown a visual analog pain scale with numeric and descriptive ratings from 0 (no pain) to 10 (severe pain), as described by Steven.¹⁵ Patients were asked to use this 10-point scale to rate the level of pain felt during the operation, including the pain felt after delivery of topical or retrobulbar anesthesia. If patients were unable to read the printed numbers and descriptive text on the pain scale, the examiner (T.S.D.) read them to the patient. In addition, any verbal expression of pain that patients made during the operation (eg, on manipulation of the iris) was recorded. The surgeon (P.C.J. or F.K.J.) was also requested to report difficulties encountered attributable to the operating conditions. The surgeon's response options were "no difficulty," "slightly difficult," "moderately difficult," "difficult," and "extremely difficult." The surgeon was asked to complete the form immediately after surgery.

OUTCOME MEASURES

Outcome measures were the number of complications and adverse events arising perioperatively, intraoperatively, and within 24 hours postoperatively; patients' pain scores; and intraoperative conditions as judged by the surgeon. In addition, after completion of the procedure, patients were asked whether the applied type of anesthesia would be their preferred type in the event of further eye surgery.

STATISTICAL ANALYSIS

Outcome measures were compared using an unpaired *t* test. Pain scores for each group were compared using the 2-tailed Mann-Whitney test for nonparametric statistics. Bivariate analysis was performed using the χ^2 test.

avoids undesirable cosmetic adverse effects, and allows instant visual rehabilitation. However, topical anesthesia only blocks the trigeminal nerve endings, providing at best “complete” analgesia of the eye. The patient’s optic nerve and motor neurons are typically not affected, resulting in fully preserved ocular motility. Although previous reports⁵⁻¹⁰ indicate that topical anesthesia is safe and effective in most uncomplicated cataract procedures, various studies^{7,11} suggest that topical anesthesia should not be considered in eyes with severe concomitant ocular pathological features. Manipulation of the iris or stretching of the ciliary and zonular tissues, which may be inevitable during surgery in complicated cases, could irritate the unanesthetized ciliary nerve endings and result in patient discomfort and inadvertent eye movements, compromising the overall safety of the procedure. While this has led an increasing number of surgeons to administer supplemental anesthetic agents by intracameral injection or by addition to the irrigation fluid used during the intraocular phase of surgery,^{9,10,12,13} this drawback has forced others¹⁴ to abandon topical anesthesia in favor of peribulbar injection.

To our knowledge, no prospective study has been performed analyzing the risk-benefit ratio of topical vs retrobulbar anesthesia in potentially difficult cases of cataract surgery. To investigate the efficacy and safety of topical anesthesia, we designed a prospective, randomized,

controlled clinical trial, to be carried out at 2 university centers, comparing retrobulbar anesthesia with topical anesthesia alone in patients with cataract who had complications and who were undergoing clear corneal phacoemulsification and foldable intraocular lens (IOL) implantation. Besides evaluating the anesthesia-related, intraoperative, and early postoperative complications, we also documented the patient pain score and intraoperative conditions judged by the surgeon (P.C.J. or F.K.J.) to obtain information that might help to indicate which type of anesthesia is preferable in difficult cases of cataract surgery.

RESULTS

From a total of 512 patients undergoing first eye cataract surgery at the 2 participating centers, 476 met the inclusion criteria and agreed to participate in this randomized, prospective trial. The mean ± SD age of all patients was 72.7 ± 6.3 years (range, 45-91 years), and 63% were women (**Table 1**). Two hundred thirty-eight eyes were randomized to the topical anesthesia group, and 238 to the retrobulbar anesthesia group. Differences between the 2 study groups in age and sex were not statistically significant ($P = .31$). The preoperative potential risk factors for phacoemulsification and IOL implantation are shown in **Table 2**. There were no statistical differences between the 2 study groups.

Complications were subgrouped into anesthesia-related, intraoperative, and within 24 hours postoperative complications (**Table 3**). Anesthesia-related complications differed significantly between the 2 groups. No patient required a change in type of anesthesia for cataract surgery to be completed. Anesthesia-related chemosis, periorbital hematoma, and subconjunctival hemorrhage occurred only in the retrobulbar anesthesia group, and never led to complete cancellation or significant delay of the planned surgical intervention.

Apart from vitreous loss, which was significantly more frequent in the retrobulbar anesthesia group, the incidences of other intraoperative complications did not

Table 1. Comparison of Patient Characteristics

Characteristic	Patients Who Received Topical Anesthesia (n = 238)	Patients Who Received Retrobulbar Anesthesia (n = 238)
Age, y		
Mean ± SD	73.1 ± 5.6	72.1 ± 6.8
Range	45-86	46-91
Female sex, %	63.2	64.9
Pain score*		
Mean ± SD†	0.84 ± 1.30	0.73 ± 1.50
Range	0-7	0-5

*The scale was from 0 to 10.

†The 2 groups were significantly different ($P = .41$).

Table 2. Preoperative Risk Factors*

Preoperative Risk Factor	All Patients (N = 476)	Patients Who Received Topical Anesthesia (n = 238)	Patients Who Received Retrobulbar Anesthesia (n = 238)	P†
Exfoliation syndrome	78 (16.4)	47 (19.7)	31 (13.0)	.06
Uveitis	31 (6.5)	13 (5.5)	18 (7.6)	.35
Axial myopia (≥26 mm)	37 (7.8)	20 (8.4)	17 (7.1)	.60
Axial hyperopia (≤21 mm)	44 (9.2)	19 (8.0)	25 (10.5)	.34
Poor pupillary dilation (≥3 mm)	212 (44.5)	114 (47.9)	98 (41.2)	.14
Posterior synechia	165 (34.7)	95 (39.9)	70 (29.4)	.16
Previous intraocular surgery	146 (30.7)	67 (28.2)	79 (33.2)	.19
Peripheral iridectomy	51 (10.7)	23 (9.7)	28 (11.8)	.45
Glaucoma filtering surgery	42 (8.8)	18 (7.6)	24 (10.1)	.33
Penetrating keratoplasty	29 (6.1)	14 (5.9)	15 (6.3)	.84
Pars plana vitrectomy	24 (5.0)	12 (5.0)	12 (5.0)	>.99
Phacodonesis	18 (3.8)	10 (4.2)	8 (3.4)	.63

*Data are given as number (percentage) of patients.

†According to the t test.

Table 3. Complications Intraoperatively and Within 24 Hours Postoperatively*

Complications	All Patients (N = 476)	Patients Who Received Topical Anesthesia (n = 238)	Patients Who Received Retrobulbar Anesthesia (n = 238)	P
Intraoperative				
Capsular tear	9 (1.9)	3 (1.3)	6 (2.5)	.31
Zonular tear	18 (3.8)	12 (5.0)	6 (2.5)	.15
Vitreous loss	7 (1.5)	1 (0.4)	6 (2.5)	.041
In-and-out placement	6 (1.3)	2 (0.8)	4 (1.7)	.41
Anterior chamber IOL	2 (0.4)	0	2 (0.8)	.15
Iris prolapse	5 (1.0)	4 (1.7)	1 (0.4)	.17
Anesthesia related				
Chemosis	6 (1.3)	0	6 (2.5)	.01
Periorbital hematoma	2 (0.4)	0	2 (0.8)	.15
Subconjunctival hemorrhage	4 (0.8)	0	4 (1.7)	.04
Supplemental paraocular anesthesia	5 (1.0)	3 (1.3)	2 (0.8)	.47
Early postoperative				
Corneal edema	12 (2.5)	6 (2.5)	6 (2.5)	>.99
Wound leak	1 (0.2)	0	1	...
IOP ≥30 mm Hg	20 (4.2)	11 (4.6)	9 (3.8)	.65
Retained lens materials	3 (0.6)	1 (0.4)	2 (0.8)	.56
Fibrinous threads within the AC	13 (2.7)	7 (2.9)	6 (2.5)	.78

*Data are given as number (percentage) of patients. IOL indicates intraocular lens; IOP, intraocular pressure; AC, anterior chamber of the eye; and ellipses, data not applicable.

Table 4. Complications Intraoperatively and Within 24 Hours Postoperatively*

Intraoperative Complications	All Patients (N = 476)	PEX (n = 78)	Miosis (n = 212)	Previous Surgery (n = 146)	Myopia (n = 37)	Hyperopia (n = 44)
Capsular tear	9	6	7	2	1	2
Zonular tear	18	8	4	9	4	2
Vitreous loss	7	5	5	2	0	0
Dropped nucleus	1	0	0	1	0	0
Out-of-bag placement	6	1	2	3	2	0
Anterior chamber intraocular lens	2	1	0	1	0	0
Iris prolapse	5	1	0	2	0	4

*Data are given as number of patients. PEX indicates pseudoexfoliation syndrome.

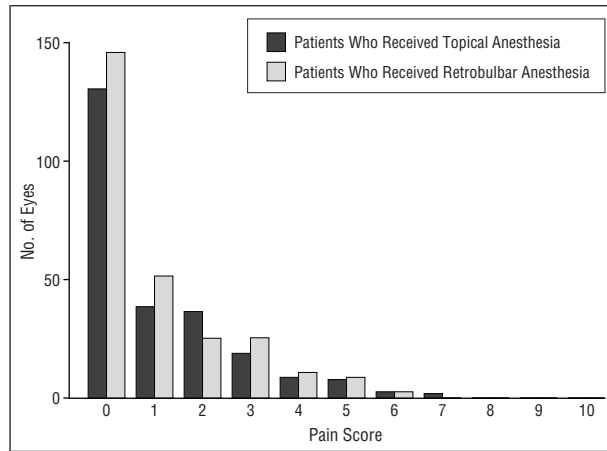
differ significantly between the 2 study groups. Considering all 476 eyes, zonular tear was the most common complication, followed by capsular tear and vitreous loss. Sulcus implantation of the haptics, with or without optic capture through the capsulorhexis, was necessary in 6 patients: 2 in the topical anesthesia group and 4 in the retrobulbar anesthesia group. The reasons for sulcus IOL implantation included anticipated zonular weakness or tear in 3 eyes, a prohibitively small anterior capsulorhexis with a miotic pupil in 1, and capsular rupture with anterior vitrectomy in 2. In 2 patients with extensive zonular defects and severely reduced general health, an anterior chamber IOL was preferred over a secondary sulcus-sutured IOL. Intraoperative iris prolapse into the tunnel incision occurred in 4 eyes in the topical anesthesia group and in 1 eye in the retrobulbar anesthesia group.

In the first 24 hours, no severe complications were observed in either of the 2 study groups. A transient pressure increase of 30 mm Hg occurred most frequently, but did not require surgical reintervention in any patient. Fibrinous aqueous reaction was the second most frequent complication but was successfully treated

by intensified topical corticosteroid application in each patient. Corneal edema leading to a transient loss in best-corrected visual acuity occurred in 6 eyes in each of the 2 groups. Retained cortex substance was observed in 3 patients with miotic pupils. In all instances, lens material eventually resolved spontaneously with surgical reintervention. One patient, who had pars plana vitrectomy, developed a transient wound leak through 1 of the 2 side-port incisions.

Despite some obvious trends (**Table 4**), the observed complications and preoperative risk factors could not be correlated or subjected to statistical analysis, because the number of confounding variables produced insufficient numbers for each category in the contingency tables and the few patients with complications were outside the range of acceptability for the common statistical tests.

The pain scores reported by the patients after surgery are shown in the **Figure**. Two hundred two patients (85%) in the topical anesthesia group and 219 (92%) in the retrobulbar anesthesia group reported minimal discomfort (a maximum score of 2) or no pain at all (a score of 0). The mean ± SD pain score in the



The pain scores reported by the patients after surgery using a 10-point scale to rate the level of pain felt during the operation, including the pain felt after delivery of topical or retrobulbar anesthesia.

Table 5. Anesthetic-Related Intraoperative Difficulties as Judged by the Surgeon*

Anesthetic-Related Difficulty	Patients Who Received Topical Anesthesia (n = 238)	Patients Who Received Retrobulbar Anesthesia (n = 238)
None to slightly difficult	211 (88.6)	220 (92.4)
Moderately difficult	18 (7.6)	12 (5.0)
Difficult to extremely difficult	9 (3.8)	6 (2.5)

*Data are given as number (percentage) of patients. Percentages may not total 100 because of rounding. The 2 groups were not significantly different ($P = .16$).

topical anesthesia group was 0.84 ± 1.30 (range, 0-7), while in the retrobulbar anesthesia group it was 0.73 ± 1.50 (range, 0-5). The difference between the mean pain scores was not statistically significant ($P = .41$). Anxiety before anesthesia administration was reported in 55 patients (23%) in the retrobulbar group; none of those due to receive topical anesthesia reported anxiety. During anesthesia application, approximately 17% in the retrobulbar group expressed discomfort (pain score, ≥ 4), while only 2% in the topical group reported increased stinging in the eye (pain score, ≥ 2). Intraoperatively, manipulation of the iris, distention of the anterior chamber, intracameral administration of acetylcholine chloride, and rotation of the IOL most often led to verbalization of patient discomfort. Patient preference for topical or retrobulbar anesthesia varied between the 2 groups. In the topical anesthesia group, only 9% of the patients said they would opt for another type of anesthesia (either retrobulbar or general anesthesia) for the second eye, while 23% of the patients in the retrobulbar anesthesia group stated a preference for either topical or general anesthesia ($P = .01$).

Intraoperative conditions as judged by the surgeon are shown in **Table 5**. In most patients in both groups, the surgeon reported no difficulty to slight difficulty.

Sutureless clear corneal incision techniques have gained popularity among cataract surgeons owing to the many advantages they offer, including a reduction of ocular tissue manipulation and surgical time.¹⁶ With topical anesthesia alone, potentially serious complications associated with retrobulbar and peribulbar anesthesia could be avoided.¹⁻⁴ Since its introduction, topical anesthesia has become increasingly popular, as indicated by the annual survey of the practice styles and preferences of members of the American Society of Cataract and Refractive Surgery.¹⁷ According to last year's survey, the use of topical anesthesia increased from 8% in 1995 to 14% in 1996 and to 37% in 1998. However, its use varied with the volume of surgery, increasing by 22% for surgeons doing 0 to 5 cataract procedures per month and by 63% for those doing more than 51, the latter having increased from 40% in 1996.

On the other hand, topical anesthesia can in certain circumstances be more demanding for the surgeon and seems to be particularly difficult in patients requiring more intraocular manipulation than usual, as in those with small pupils. The goal, however, should be to allow a wider range of patients to enjoy the benefits of topical anesthesia. The present study, comparing topical anesthesia with retrobulbar injection anesthesia in potentially complicated cases of cataract surgery, shows convincingly that topical anesthesia can provide safe operating conditions even under more demanding conditions without any noticeable reduction in patient comfort.

Our data showing 1.5% of capsular tear with vitreous loss and 1.9% of capsular tear without vitreous loss is well within the range of levels of complications reported in other series¹⁸⁻²⁴ of nonselected cases. In the present study, the incidence of capsular tearing alone did not differ significantly between the 2 anesthetic groups, while the frequency of vitreous loss was significantly higher in the retrobulbar injection group. However, there was no significant difference in relation to other complications occurring intraoperatively or within 24 hours postoperatively between the 2 groups. A statistical analysis of the incidence of complications observed in connection with preexisting ocular comorbidities did not reveal any significant differences, probably owing to the relative infrequency of such adverse events (Table 4). Nevertheless, exfoliation syndrome, especially when associated with smaller pupils, seems to increase the risk of breaking the posterior capsule. While previous intraocular surgery was accompanied by capsular tearing in only 2 instances, zonular tears were the most common complications in these eyes. The incidences of intraoperative complications and early postoperative problems and their correlation to potential risk factors are broadly comparable with those found in other series.¹⁸⁻²⁴

There was a 1% incidence of intraoperative iris prolapse in both groups. Although not statistically significant, iris prolapse occurred more often in the topical anesthesia group (1.7%) than in the retrobulbar anesthesia group (0.4%). Iris prolapse is most likely to occur in eyes with an intraoperatively raised intraocular pressure, especially in hyperopic or nanophthalmic eyes, but also

arises in anxious patients with a higher chance of extraocular muscle contraction. While the distribution of measurements of ocular axial length was similar in the 2 study groups, extraocular muscle contraction probably only occurs in the topical anesthesia group without motor blockade, which may account for the observed intergroup difference for this complication. Moreover, in patients receiving retrobulbar anesthesia, oculopression was performed routinely to counteract possible pressure increases during surgery, but this preoperative measure cannot be used in patients receiving topical anesthesia. Transient postoperative complications, such as corneal edema, a wound leak, an intraocular pressure increase, and a plasmod or fibrinous anterior chamber reaction, were similar in the 2 groups and, despite this study being a series of selected high-risk patients, were less frequent than those reported in other studies.¹⁸⁻²⁴ Anesthesia-related complications prevailed, as expected, in the retrobulbar group. Chemosis, subconjunctival hemorrhage, and periorbital hematoma were exclusively observed in the retrobulbar anesthesia group. But these adverse events were of no substantial clinical concern, since in no patient was the planned surgical intervention prevented or delayed.

We were primarily interested in the possible need for supplemental paraocular anesthesia in the topical anesthesia group. Previous studies^{9-11,14} indicated that increased iris manipulation and stretching of uveal tissues, which are inevitable during surgery in complicated cases, irritate patients under topical anesthesia, who may then require additional anesthetic measures. Between our study groups, however, we did not observe any statistically significant difference for supplemental paraocular anesthetic injection. Likewise, the pain scores reported by patients immediately after completion of surgery did not differ significantly between the groups. This similarity between the mean pain scores of the 2 study groups was not observed in any previous studies.^{5,7,8,14,25} The anomaly is even more confounding since we did not, as advocated by others,^{9-14,25-28} use an additional intracameral injection of unpreserved lidocaine in our study. Indeed, at the time our study protocol was established, the potential toxic effects of intracamerally applied lidocaine on various intraocular structures, particularly the corneal endothelium and the retina, were still a major point of concern in the literature. Apart from instilling lidocaine intracamerally, various other measures have been suggested for alleviating patient discomfort associated with intraocular manipulation. These include “adequate cycloplegia” to minimize stretching of zonules and the ciliary muscle²⁹ or lowering the irrigation solution bottle to minimize the intraocular hydrostatic pressure.³⁰ However, none of these measures are commonly applied in complicated cataract cases. The only explanation for the lack of any difference between the anesthetic groups for patient comfort during phacoemulsification is that, before certain potentially irritating preoperative or intraoperative steps, such as the instillation of anesthetic eye-drops, retrobulbar injection, iris manipulation, hydrodissection, activation of the irrigation line, or IOL implantation, were taken, the surgeons routinely informed the patient that the next maneuver might be “felt

or even be slightly painful.” We consider this verbal contact with the patient throughout the surgical procedure to be extremely helpful, if not crucial, for a comfortable and safe cataract procedure under topical anesthesia. Moreover, we believe that the low level of patient discomfort in our patients receiving topical anesthesia may also be explained by the speed with which phacoemulsification was performed and the caution we exercised during intraocular manipulation. This assumption was supported by our observation that, even in these surgically more demanding eyes, only 9% of those in the topical anesthesia group said they would opt for another type of anesthesia for the second eye, while 23% of those in the retrobulbar anesthesia group wanted another form of anesthesia.

Globe akinesia is commonly not achieved with topical anesthesia, making cataract surgery in demanding cases possibly even more difficult for the surgeon. As expected, overall surgical conditions assessed by the surgeon favored the use of retrobulbar anesthesia. However, the intergroup difference in surgeon’s assessment was not statistically significant. These results contradict the findings of a similar study⁷ comparing topical with retrobulbar anesthesia but are in agreement with the results of Uusitalo et al,²⁵ who found paraocular injection significantly less difficult. The lack of akinesia was not clinically significant since supplemental paraocular anesthesia was not required in any patient to continue surgery. The surgeons repeatedly observed that some patients were simply unaware of inadvertent eye movement during surgery, and muscle spasms were thought to account for an increase in intraocular pressure in some patients. Intraoperatively, the surgeons found minimizing eye movements during capsulorhexis to be most crucial. Photophobia, the cause of eye movement in some patients, could be overcome by simply reducing the brightness of the operating microscope. The necessity of dimming the light source in the topical anesthesia group was not found to increase the difficulty of the surgical procedure.

In summary, compared with retrobulbar anesthesia, topical anesthesia provides good surgical conditions for the surgeon and comfortable operative circumstances for the patient, even in difficult cases with associated ocular comorbidities. This study shows that complicated cataract surgery can be performed under topical anesthesia without compromising the safety of the procedure. While surgery-related complications under topical anesthesia were similar to those occurring when retrobulbar injections were used, anesthesia-related complications were seen exclusively in the retrobulbar-injected group. Although the results of pain assessment during anesthesia delivery favored the topical technique, patient assessments of pain during and shortly after anesthesia were not statistically different in the topical and retrobulbar groups. The fact that more anesthesia-related difficulties were encountered by the surgeons during cataract surgery in the topical anesthesia group leads us to conclude that in difficult cases cataract surgery is more demanding for the surgeon using topical anesthesia. However, we believe that topical anesthesia is justified to improve the safety and comfort of the pa-

tient even in complicated cases of cataract surgery and is likely to become the preferred type of anesthesia in small-incision phacoemulsification and foldable IOL implantation, particularly for so-called high-volume surgeons. Patient preference for topical anesthesia is increasing steadily and warrants all efforts to move away from more invasive forms of anesthesia so that cataract surgery can genuinely be described as “minimally invasive.”

Accepted for publication January 27, 2000.

Reprints: Philipp C. Jacobi, MD, Department of Ophthalmology, University of Cologne, Joseph-Stelzmannstrasse 9, 50931 Cologne, Germany (e-mail: Philipp.Jacobi@uni-koeln.de).

REFERENCES

1. Feibel RM. Current concepts in retrobulbar anesthesia. *Surv Ophthalmol.* 1985; 30:102-110.
2. Sullivan KL, Brown GC, Forman AR, et al. Retrobulbar anesthesia and retinal vascular obstruction. *Ophthalmology.* 1983;90:373-377.
3. Morgan CM, Schatz H, Vine AK, et al. Ocular complications associated with retrobulbar injections. *Ophthalmology.* 1991;95:660-665.
4. Nicoll JMV, Acharya PA, Ahlen K, et al. Central nervous system complications after 6000 retrobulbar blocks. *Anesth Analg.* 1987;66:1298-1302.
5. Maclean H, Burton T, Murray A. Patient discomfort during cataract surgery with modified topical and peribulbar anesthesia. *J Cataract Refract Surg.* 1997;23: 277-283.
6. Fichman RA. Use of topical anesthesia alone in cataract surgery. *J Cataract Refract Surg.* 1996;22:612-614.
7. Patel EA, Carlson TA, Crandall A, et al. A comparison of topical versus retrobulbar anesthesia for cataract surgery. *Ophthalmology.* 1996;103:1196-1203.
8. Zehetmayer M, Radax U, Skorpik C, et al. Topical versus retrobulbar anesthesia in clear corneal cataract surgery. *J Cataract Refract Surg.* 1996;22:480-484.
9. Koch PS. Efficacy of lidocaine 2% jelly as a topical agent in cataract surgery. *J Cataract Refract Surg.* 1999;25:632-634.
10. Tseng SH, Chen FK. A randomized clinical trial of combined topical-intracameral anesthesia in cataract surgery. *Ophthalmology.* 1998;105:2007-2011.
11. Davis DB, Mandel MR. Anesthesia for cataract extraction. *Int Ophthalmol Clin.* 1994;43:13-30.
12. Gills JP, Cherichio M, Raanan MG. Unpreserved lidocaine to control discomfort during cataract surgery using topical anesthesia. *J Cataract Refract Surg.* 1997; 23:545-550.
13. Koch PS. Anterior chamber irrigation with unpreserved lidocaine 1% for anesthesia during cataract surgery. *J Cataract Refract Surg.* 1997;23:551-554.
14. Fukasaku H, Marron JA. Pinpoint anesthesia: a new approach to local ocular anesthesia. *J Cataract Refract Surg.* 1994;20:468-471.
15. Steven JD. A new local anesthesia technique for cataract extraction by one quadrant sub-Tenon's infiltration. *Br J Ophthalmol.* 1992;76:670-674.
16. Kershner RM. Corneal anatomy and no-touch technique. In: Fine IH, Fichman RA, Grabow HB, eds. *Clear-Corneal Incision Cataract Surgery and Topical Anesthesia.* Thorofare, NJ: SLACK Inc; 1993:79-84.
17. Leaming DV. Practice styles and preferences of ASCRS members: 1998 survey. *J Cataract Refract Surg.* 1999;25:851-859.
18. Norregaard JC, Bernth-Petersen P, Bellan L, et al. Intraoperative clinical practice and risk of early complications after cataract extraction in the United States, Canada, Denmark, and Spain. *Ophthalmology.* 1999;106:42-48.
19. Willerscheidt AB, Healey ML, Ireland M. Cataract surgery outcomes: importance of co-morbidities in case mix. *J Cataract Refract Surg.* 1995;21:177-181.
20. Holland GN, Earl DT, Wheeler NC, et al. Results of inpatient and outpatient cataract surgery: a historical cohort comparison. *Ophthalmology.* 1992;99:845-852.
21. Desai P. The National Cataract Surgery Survey, II: clinical outcomes. *Eye.* 1993; 7:489-494.
22. Nishi O. Vitreous loss in posterior chamber lens implantation. *J Cataract Refract Surg.* 1987;13:424-427.
23. Chambless WS. Incidence of anterior and posterior segment complications over 3000 cases of extracapsular cataract extractions: intact and open capsules. *J Cataract Refract Surg.* 1985;11:146-148.
24. Chitkara DK, Smerdon DL. Risk factors, complications, and results in extracapsular cataract extraction. *J Cataract Refract Surg.* 1997;23:570-574.
25. Uusitalo RJ, Maunukela EL, Paloheimo M, et al. Converting to topical anesthesia in cataract surgery. *J Cataract Refract Surg.* 1999;25:432-440.
26. Crandall AS, Zabriskie NA, Patel BCK, et al. A comparison of patient comfort during cataract surgery with topical anesthesia versus topical anesthesia and intracameral lidocaine. *Ophthalmology.* 1999;106:60-66.
27. Garcia A, Loureiro F, Limao A, Sampaio A, Ilharco J. Preservative-free lidocaine 1% anterior chamber irrigation as an adjunct to topical anesthesia. *J Cataract Refract Surg.* 1998;24:403-406.
28. Belluccis R, Morselli S, Pucci V, et al. Intraocular penetration of topical lidocaine 4%. *J Cataract Refract Surg.* 1999;25:643-647.
29. Grabow HB. Topical anesthesia for cataract surgery. *Eur J Implant Refract Surg.* 1993;5:20-24.
30. Novak KD, Koch DD. Topical anesthesia for phacoemulsification: initial 20-case series with one-month follow-up. *J Cataract Refract Surg.* 1995;21:672-675.