



TITLE:

A foreign body of the corpus cavernosum in a patient with cleft glans penis: a case report

AUTHOR(S):

Matsuzaka, Junichi; Aoki, Hikaru; Banya, Yoshiaki; Fujioka, Tomoaki; Kubo, Takashi; Nagane, Yutaka

CITATION:

Matsuzaka, Junichi ...[et al]. A foreign body of the corpus cavernosum in a patient with cleft glans penis: a case report. 泌尿器科紀要 1994, 40(6): 545-547

ISSUE DATE:

1994-06

URL:

<http://hdl.handle.net/2433/115280>

RIGHT:

A FOREIGN BODY OF THE CORPUS CAVERNOSUM IN A PATIENT WITH CLEFT GLANS PENIS: A CASE REPORT

Junichi Matsuzaka, Hikaru Aoki, Yoshiaki Banyu,
Tomoaki Fujioka and Takashi Kubo

From the Department of Urology, Iwate Medical University School of Medicine

Yutaka Nagane

From the Department of Urology, Keijinkai Sanai Hospital

We had an opportunity to treat a rare case of foreign body in the corpus cavernosum in a patient with cleft glans penis. The foreign body was a 13 cm wire, which was inserted by the patient himself for masturbation, and was removed surgically. To our knowledge, such a case has never been reported in the literature.

(Acta Urol. Jpn. 40: 545-547, 1994)

Key words: Penis, Foreign body, Cleft glans penis

INTRODUCTION

Foreign bodies in the corpus cavernosum other than therapeutic penile prosthesis have not been reported to our knowledge. We report a case of a foreign body in the corpus cavernosum of a patient with cleft glans penis, which is a rare disease in the literature.

CASE REPORT

The patient was a 63-year-old man, whose wife had deceased one year ago. He had a long history of habitually inserting a wire into his penis for the purpose of masturbation. Three days prior to his hospital visit, the patient inserted the usual wire while drinking, but after masturbation, he could not pull out the wire by himself. Therefore, he visited our hospital for its removal. Physical examination revealed the presence of a lengthwise halved glans penis (cleft glans penis) and a tattoo covering the entire glans penis and extending 3 cm. along the shaft (Fig. 1). However, there was no definite evidence of the wire visually, and we were unable to locate a puncture hole. The wire could not be demonstrated by palpation either. The patient claimed that he inserted the wire

through the groove of the cleft glans. Laboratory studies indicated an inflammatory response [WBC 11,800/mm³, CRP (5+)], but the patient was afebrile (36.8 C).

Roentgenological examinations were made; plain pelviography revealed a wire shadow near the right pubic bone. Urethrography was taken to delineate the relationship of the wire shadow to the urethra. The wire was found to be located outside the urethral space (Fig. 2). The patient was then taken to surgery under our impression that the wire was present inside the corpus cavernosum.

Operation was performed under spinal anesthesia. After a 1 cm skin incision was made in the right penile root region, the intracavernous wire could now be felt via tunica albuginea. The wire was extracted with a forcels through a small window made on the tunica albuginea without difficulty. Both tunica albuginea and the skin were silk-sutured to finish the operation.

Corpus cavernosography on the 5th post-operative day revealed no leakage through the tunica albuginea. On the 6th post-operative day, the patient was discharged from the hospital with normal erectile function.

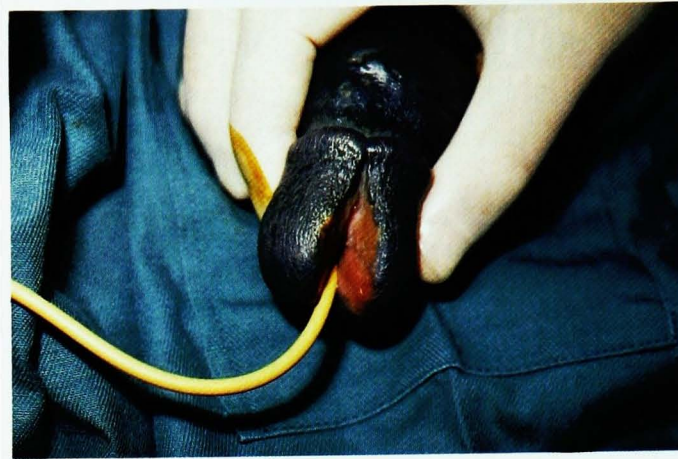


Fig. 1. This photography shows the cleft glans penis and blue tattoo covering the entire glans penis with 3cm extension along the shaft.

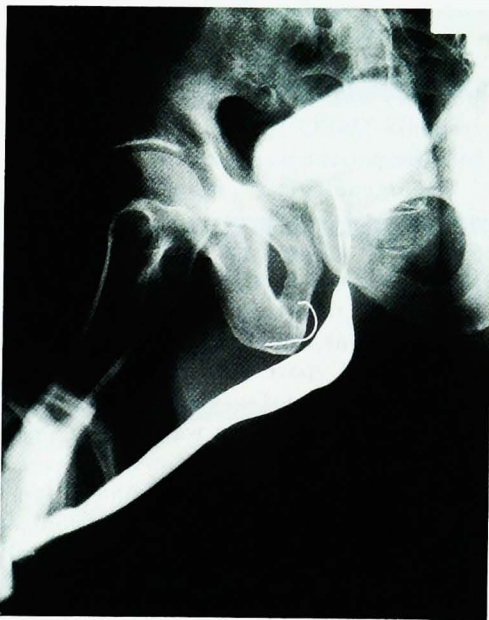

Fig. 2. Urethrography indicates that wire shadow was located outside the urethral space.

DISCUSSION

This case represented a combination of two rare clinical situations, an intracavernous foreign body and cleft glans penis that coexisted in a single patient. Penile foreign bodies such as those in the urethra are relatively common and those in

the form of several beads inserted into the foreskin via preputiotomy are also sporadically encountered in the literature¹⁻⁵. However, foreign bodies in the corpus cavernosum other than therapeutic penile prosthesis have not been reported to our knowledge. Insertion of a wire into the corpus cavernosum from the glans region as used in caverno-glans shunt (Winter's procedure⁶), would be technically difficult in the hands of an amateur when penile anatomy is normal. It is naturally expected to be accompanied by severe pain. It may be that the foreign body could be inserted more easily in our case because of the presence of cleft glans penis, although it is doubtful that insertion is less painful in the presence of this anatomical aberration. It is well known that some patients with psychiatric problems occasionally exhibit deviated sexual conducts including insertion of intraurethral foreign bodies. Our case was apparently a normal full-fledged member of society without known mental abnormalities, although the tattoo on the penis is bizarre by any usual standard. The psychology behind it can only be speculated since the patient was reluctant to discuss; perhaps the tattoo was intended to mask the penile malformation.

Since cleft glans penis was first reported by Rosenwald⁷ there have been only a

handful of case reports in the literature⁸⁻¹⁰⁾ In general, it is not associated with functional problems except for probable psychological impact. In fact our patient experienced no difficulty with sexual intercourse with his wife and he had two children. It is unclear how this anomaly develops. It has been suggested to be caused by a delayed disappearance of the urethral plate⁹⁾. Marshall¹¹⁾ suggested that cleft glans represents the mildest form of epispadia. Although this anomaly is of little clinical significance unless there is a meatal stenosis⁷⁾, we consider that reconstructive surgery of the glans region early in life is likely to benefit the patient considering the cosmetic and psychological aspects.

In the present case, cavernosography was not taken for a diagnostic purpose in fear of infectious complications, but it can be an effective approach to establish a pre-operative diagnosis. Ultrasonography, computed tomography and magnetic resonance imaging would be the method of choice if the object happens to be radiolucent.

REFERENCES

1) Lim KB, Seow CS, Tulip T, et al.: Artificial

- penile nodules: case reports. *Genitourin Med* 62: 123-125, 1986
- 2) Bacci M and Porena M: Masturbation injury resulting from intraurethral introduction of spaghetti. *Am J Med Pathol* 7: 254-255, 1986
- 3) Gelister JSK: Case profile: Penile necklace. *Urology* 26: 81, 1985
- 4) Kenney RD: Adolescent males who insert genitourinary foreign bodies: is psychiatric referral required? *Urology* 32: 127-129, 1988
- 5) Marzou K: Implantation of beads into the penile skin and its complications. *Scan. J Urol Nephrol* 24: 167-169, 1990
- 6) Winter CC: Priapism cured by creation of fistulas between glans penis and corpora cavernosa. *J Urol* 119: 227-228, 1978
- 7) Rosenwald L: Complete cleft of glans penis. *Urol & Cutan Rev* 18: 649-650, 1914
- 8) Leff RG, Peterson RE and Drago JR: Cleft glans penis: a case report. *J Urol* 120: 767, 1987
- 9) Herr HW, Jeppson PM and Bischoff AJ: Complete vertical cleft of the glans penis. *J Urol* 108: 282-283, 1972
- 10) Ohi T, Obara N, Matsumoto N, et al.: A case report: complete vertical cleft of the glans penis. *Rinsho Hinyoukika* 39: 781-783, 1985
- 11) Marshall F: Cleft glans penis: a case report. *J Urol* 120: 767, 1987, Editorial comment
(Received on December 3, 1993)
(Accepted on February 3, 1994)

和文抄録

二分亀頭を伴った陰茎海綿体異物の1例

岩手医科大学泌尿器科学教室 (主任: 久保 隆教授)

松坂 純一, 青木 光, 萬谷 喜明, 藤岡 知昭, 久保 隆

恵仁会三愛病院泌尿器科 (副院長: 長根 裕)

長根 裕

われわれは、陰茎異物のなかでも非常に稀である陰茎海綿体異物を報告した。症例は63歳、男性。以前よりマスターベーションのため、陰茎に針金を挿入していたが、自己抜去困難となり抜去目的にて受診した。針金は長さ 13 cm で、手術的に摘出した。われわれ

の調べたかぎり、陰茎海綿体異物は他にも報告はなく、第一例目と思われる。さらに陰茎は二分亀頭を合併し、入れ墨も認めた。

(泌尿紀要 40: 545-547, 1994)