

A giant femoral pseudo aneurysm secondary to arteriovenous fistula following stab injury

PK Biswas¹, M Mallick², SK Biswas³

Abstract

Pseudo aneurysm wall is not formed by vascular tissue but develops from organized thrombus, associated fibrosis and surrounding tissue. Post stab injury pseudo aneurysm associated with arteriovenous fistula of lower limb is exceptional. Here one such case is reported who was operated 4 months after the incidence of stab injury in his way back home at an incidence of robbery. The patient was very poor and did not have the ability to seek higher medical care. He was moving everywhere with a big pulsatile mass on supero medial part of his left thigh. Lastly surgical intervention was done and the patient got well.

Bang Med J Khulna 2015; 48 : 34-36

Introduction

Aneurysm is defined as dilation of localized segment of an arterial system. They can either be true aneurysm, containing all the three layers of arterial wall in aneurysm sac or false aneurysm, having a single layer of fibrous tissue as the wall of sac. Communication between an artery and a vein may be either congenital or the result of trauma.¹ All arteriovenous fistulae have a structural and physiological effect. The structural effect of arterial blood flow on the vein is characteristic; they become dilated, tortuous and thick walled (arterialized). The physiological effect, if the fistula is big enough, is an increase in cardiac output.

With increasing social unrest and violence pseudoaneurysm associated with arteriovenous fistulae are becoming common, yet many of these go unrecognized and diagnosed at late stages with complications. A pulsatile swelling with thrill and bruit is usually present if the lesion is superficial. Pressure on the artery, proximal to the fistula reduces the swelling and the thrill and bruit cease.

Duplex ultrasound scanning has become the screening test for patient with suspected arteriovenous fistulae.² Computerized Tomographic Angiogram becomes the most appropriate preliminary diagnostic tool in pseudo aneurysm with arteriovenous fistulas. Magnetic Resonance Angiography is used extensively in management of patients with congenital and chronic arteriovenous fistulae. Conventional angiography is essential in planning endovascular

treatment and in some cases before surgical treatment.

Minimally invasive interventions like ultrasound guided embolization are sometimes successful. Endovascular therapy has become the treatment of choice for stable patient with suitable anatomy and those with surgically inaccessible lesion in neck, thorax and abdomen. These are transcatheter embolization or placement of stent graft.

Surgical treatment is indicated in patient with acute arteriovenous fistulae whose lesion or anatomy is unsuitable for endovascular repair. The open surgical repair of extremity arteriovenous fistula is accomplished by isolating the vessels and repairing the defect primarily or with an appropriate autogenous patch or interpositional graft.

Case Report

Mr. Md. Nasir Miah, (Fig. 1) a 36 year old businessman hailing from Raghurampur, Jessore got admitted in Khulna C.T. Clinic, a private clinic in Khulna City on 11.08.14 with a giant pulsatile swelling over the upper and medial aspect of left thigh developed 2 days after stab injury on the supero-lateral part of thigh. The swelling gradually increased in size in following 4 months and he had pain over the thigh. He had leg cramp during walking.

1. Proshanta Kumar Biswas MS, Senior Consultant, Surgery, Khulna Medical College Hospital

2. Milton Mallick MBBS, Asstt. Registrar, Surgery, Khulna Medical College Hospital.

3. Sunil Kumar Biswas DA, Jr. Consultant (Anes), General Hospital, Khulna.

On examination, the patient was moderately anemic, non icteric, there was no palpable ipsilateral inguinal lymph node. The patient was of average built with good nutrition, pulse 89 b/m, BP 120/70 mmHg, RR 18/m, Temperature 98.0F. On local examination the swelling was about 25x20 cm (Fig.1) elongated,

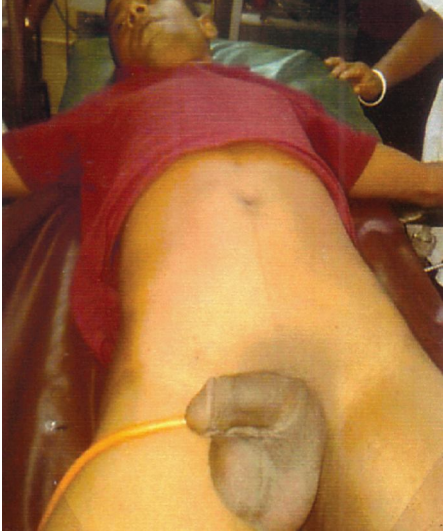

Fig 1 : Left femoral pseudo aneurysm with AVF

pulsatile, fixed to underlying structure of thigh. There was thrill and machinery murmur over the swelling. There is a scar on supero lateral part of thigh. His baseline hematological, biochemical investigation was all within normal limit. Chest X-Ray, ECG were normal. Doppler ultrasound revealed the mass as a pseudo aneurysm of left femoral artery. With the clinical impression of arteriovenous fistula and on duplex report of pseudo aneurysm the patient was operated.

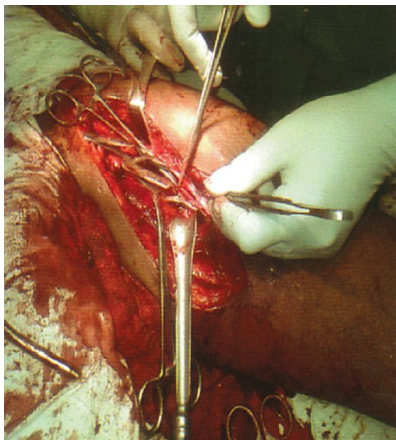


Fig. 2 : Pseudo-aneurysm sac is opened.

Under spinal anesthesia, good antiseptic skin preparation and all aseptic precaution with systemic heparinization through vertical incision the mass was explored (Fig 2). At first proximal

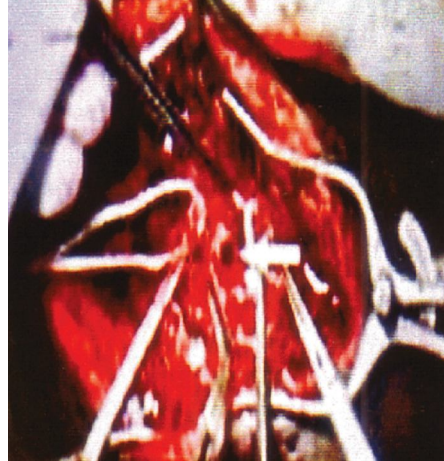

Fig 3 : Thrombus in the sac

control of left femoral artery was taken. Then isolation, separation of the mass was done medially, laterally and inferiorly. The blackish mass in adductor magnus at its lower part lined by false capsule was incised. One full medium kidney tray amount of thrombus (Fig. 3) was drained. Lastly fresh arterial blood was found to come from lower part of the cavity. The distal

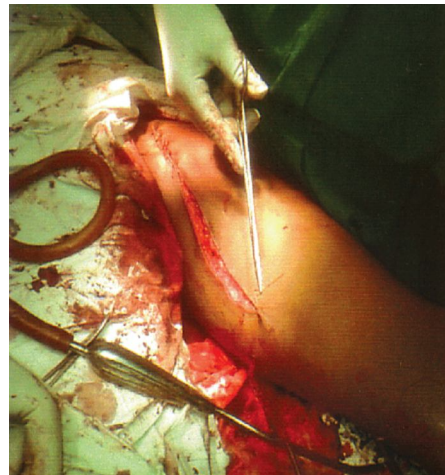


Fig 4 : Femoral artery pseudo-aneurysm with AVF at the end of operation

femoral artery and vein were clearly isolated and controlled by bull dog clamp, 2 cm long abnormal fistulous segment of artery was resected and end to end anastomosis was done after distal and proximal flash injection of heparin solution and ensuring patency and free flow of blood using 5/0 prolene. The small opening in femoral vein was repaired by continuous 5/0 prolene suture. Good distal popliteal and arteria dorsalis pedis pulsation were found. The wound was closed keeping negative suction drain (Fig. 4). Post operatively the

leg was elevated, cotton padded crepe bandage applied over the limb.

On 1st POD, a single rise of temperature upto 102°F occurred which soon became normal. Inj.Cefepime, clindamycin, metronidazole were used. On 2nd POD patient was ambulated, ecosprin 75mg daily orally was given for one month. Post operative period was quite normal and till date for 1 year period the patient is normal.

Discussion

In Khulna, Bangladesh due to limitation of facility of diagnosis and management of vascular disorders, proper treatment of the patient is delayed. Delayed diagnosis is also secondary to the poverty of the patient. As reported by others a pseudo aneurysm associated with arteriovenous fistula should be suspected when a penetrating injury next to major artery, profuse bleeding, expanding hematoma, signs of peripheral ischemia, shock with the need for blood transfusion and obvious sign of vascular lesion are present. All these signs were present in the patient and it is unlikely that the diagnosis would have been missed if they were seen in vascular clinic.³⁻⁴ Complications like rupture, infection and ischemia and thromboembolism might be life threatening. To avoid these, surgery should be done without delay.

Surgical treatment is indicated in patient with acute arteriovenous fistula with acute bleeding, cardiac decompensation, pulse deficit, acute ischemia, with chronic arteriovenous fistula where lesion or anatomy is unsuitable for endovascular repair. Open surgical repair of extremity arteriovenous fistula is accomplished by isolating the vessels and repairing the defect primarily or with an appropriate autogenous patch or interposition graft.

The pathogenesis of arteriovenous fistula is not fully disclosed. Marks et al suggest that rupture of vasavosorum of artery and vein in trauma region, with subsequent formation of hematoma lead to the development of endothelial bud that proliferate and create vascular channels connecting both systems originating arteriovenous fistula.⁵⁻⁷ After sometime the organization of hematoma creates a capsule wall constituted of fibrotic tissue and reabsorption of clots in its interior leads to the formation of a lumen generating pseudo aneurysm as described by Moran et al who mentioned a laceration mechanism of artery and vein leading to formation of arteriovenous fistula.^{8,9} The choice

of surgical treatment of the lesion in this case was justified due to the risk of bleeding.¹⁰ In this case, complete dissection, separation, isolation and radical excision followed by successful revascularization was done. The surgical procedure took place without any complication. Percutaneous intervention like stent grafting or embolization etc. are cumbersome in this case due to the anatomic proximity of the lesion to femoral artery bifurcation. In spite of multifactorial limitations, limb saving and sometimes life saving routine and emergency vascular operations are now done in Khulna.

Reference

1. Williams NS, Bulstrode CJK, Connell PR, Bailey & Love's Short Practice of Surgery, 26th ed, CRC Press, 2013; 899.
2. Jack L Cronenwett, K. Wayne Johnston, Rutherford's Vascular Surgery 7th ed, Saunders Elsevier, 2010; 1093-94.
3. Yetkin U and Gurbuz A, Post traumatic pseudo aneurysm of the brachial artery and its surgical treatment'. Texas Heart Institute Journal, 2003; 30: 293-97
4. Cambaz S, Acipayam M, Gurbuz H, Duran H, False aneurysm of perforating branch of the profunda femoris artery after external fixation for a complicated femur fracture. J. Cardiovas. Surg. 2002; 43: 519-22
5. Marks MW, Argenta LC, Dingman RO, Traumatic arteriovenous malformation of the external carotid arterial system. Head Neck Surg., 1984; 6: 1054-58
6. Chong KC, Yap EC, Lam KS, Low BY, Profunda femoris artery pseudo aneurysm presenting with triad of thigh swelling, bleeding and anaemia. Ann. Acad. Med. Singap. 2014; 33: 267-69
7. Amlashi SF, Ruffand L, Morandix, Arteriovenous fistula of superficial temporal artery: an exceptional complication of Pterional approach. J Neuroe. Neurosurg. Psychiatry 2004; 75: 1077-78.
8. Leal FS, Miranda CC, Guimaraes AC Traumatic pseudo aneurysm of the superficial temporal artery: Case report. Arq neuropsiquiatr 2005; 63: 859-61
9. Moran AM, Aleman TS, Gausas RE, et al. Traumatic arteriovenous fistula at the superficial temporal artery: a histopathologic report. Ophthal. Plast. Reconstr. Surg. 2013; 29: 126-28
10. Ishikawa E, Sugimoto K, Yonaka K, et al. Giant aneurism of the superficial temporal artery. Case report and review of the literature. Surg. Neurol. 2000; 53: 543-4