

# A Locus for Posterior Polymorphous Corneal Dystrophy (PPCD3) Maps to Chromosome 10

Satoko Shimizu,<sup>1,2</sup> Charles Krafchak,<sup>1,3</sup> Nobuo Fuse,<sup>1,4</sup> Michael P. Epstein,<sup>5,6</sup> Miriam T. Schteingart,<sup>7</sup> Alan Sugar,<sup>1</sup> Maya Eibschitz-Tsimhoni,<sup>1</sup> Catherine A. Downs,<sup>1</sup> Frank Rozsa,<sup>1</sup> Edward H. Trager,<sup>1</sup> David M. Reed,<sup>1</sup> Michael Boehnke,<sup>5</sup> Sayoko E. Moroi,<sup>1</sup> and Julia E. Richards<sup>1,3\*</sup>

<sup>1</sup>Department of Ophthalmology & Visual Sciences, W.K. Kellogg Eye Center, University of Michigan, Ann Arbor, Michigan

<sup>2</sup>Currently at Department of Ophthalmology, Teikyo University, Tokyo, Japan

<sup>3</sup>Department of Epidemiology, University of Michigan, Ann Arbor, Michigan

<sup>4</sup>Currently at Department of Ophthalmology, Tohoku University, Sendai, Japan

<sup>5</sup>Department of Biostatistics, University of Michigan, Ann Arbor, Michigan

<sup>6</sup>Department of Human Genetics, Emory University, Atlanta, Georgia

<sup>7</sup>Andersen Eye Center, Saginaw, Michigan

Posterior polymorphous corneal dystrophy (PPCD) is an autosomal dominant disorder characterized by corneal endothelial abnormalities, which can lead to blindness due to loss of corneal transparency and sometimes glaucoma. We mapped a new locus responsible for PPCD in a family in which we excluded the previously reported PPCD locus on 20q11, and the region containing *COL8A2* on chromosome 1. Results of a 317-marker genome scan provided significant evidence of linkage of PPCD to markers on chromosome 10, with single-point LOD scores of 2.63, 1.63, and 3.19 for markers D10S208 (at  $\theta = 0.03$ ), D10S1780 (at  $\theta = 0.00$ ), and D10S578 (at  $\theta = 0.06$ ). A maximum multi-point LOD score of 4.35 was found at marker D10S1780. Affected family members shared a haplotype in an 8.55 cM critical interval that was bounded by markers D10S213 and D10S578. Our finding of another PPCD locus, *PPCD3*, on chromosome 10 indicates that PPCD is genetically heterogeneous. Guttae, a common corneal finding sometimes observed along with PPCD, were found among both affected and unaffected members of the proband's sib ship, but were absent in the younger generations of the family. Evaluation of phenotypic differences between family members sharing the same affected haplotype raises questions about whether differences in disease severity, including differences in response to surgical interventions, could be due to genetic background or other factors independent of the *PPCD3* locus. © 2004 Wiley-Liss, Inc.

## INTRODUCTION

Posterior polymorphous corneal dystrophy (PPCD [MIM122000]), also sometimes referred to as PPMD, is a corneal dystrophy characterized by thickening of Descemet's membrane and transformation of corneal endothelial cells into cells with an epithelial-like appearance [Krachamer, 1985]. The clinical phenotype of PPCD can vary from relatively benign Descemet's thickening to severe progression towards vision loss from corneal edema [Cibis et al., 1977; Threlkeld et al., 1994; Weisenthal and Streeten, 1997]. In about 40% of the cases, PPCD includes glaucoma [Bourgeois et al., 1984]. In the subject of this report, family UM:139, Moroi et al. [2003] previously found that PPCD is excluded from the 30 cM genetic inclusion interval for autosomal dominant PPCD [Heon et al., 2002] on chromosome 20q11. This locus, which was referred to as a PPMD locus when reported by Heon et al. [2002], has been designated *PPCD1* by the Human Genome Nomenclature Committee. Moroi et al. [2003] also indicated that PPCD in family UM:139 is unlikely to be the result of a mutation at the autosomal dominant congenital hereditary endothelial dystrophy locus (*CHED1* [MIM121700]) located within and potentially allelic to the chromosome 20q PPCD locus [Toma et al., 1995], the autosomal recessive *CHED2* locus (MIM217700) on chromosome 20p [Chan et al., 1982; Hand et al., 1999]. This paper also found that PPCD in this family is unlikely to be the result of mutations in the *COL8A2* gene (MIM120252) on chromosome 1p [Biswas et al., 2001], which causes Fuchs endothelial corneal dystrophy (FECD) and has been given the alias *PPCD2* by the Human Genome Nomenclature Committee because of the observation of a *COL8A2* FECD mutation in two members of one PPCD family [Biswas et al., 2001]. In this study we provide significant evidence of a new PPCD locus, *PPCD3*, and discuss phenotypic variability within a single large family with PPCD.

## METHODS

### Subjects

Twenty-six members of family UM:139 provided informed consent and blood samples according to a protocol approved by the Institutional Review Board for Human Subject Research of the University of Michigan Medical School. One or more of the authors (MTS, AS, ME, and SEM) performed complete ocular examinations on 23 of the family members, which included slit lamp bio-microscopy, gonioscopy, measurement of intraocular pressure, optic disc examination, and corneal pachymetry. The remaining three individuals were assessed based on records obtained from their ophthalmologists. The presence or absence of guttae in the central portion of the cornea was

Grant sponsor: NIH; Grant numbers: EY07003 (Core grant), EY00353 (to SEM), EY11671 (to JER), T32 HG00040 (to MPE and CK); Grant sponsor: The Lew R. Wasserman Award from Research to Prevent Blindness (to JER); Grant sponsor: Research to Prevent Blindness (career development award to SEM and an unrestricted grant).

\*Correspondence to: Julia E. Richards, PhD, Department of Ophthalmology & Visual Sciences, University of Michigan, 1000 Wall Street, Ann Arbor, MI 48105. E-mail: richj@umich.edu

Received 25 July 2003; Accepted 31 March 2004

DOI 10.1002/ajmg.a.30267

evaluated by using a thin slit beam on the highest magnification on a slit lamp biomicroscope. Specular microscopy was not performed on this family.

Based on slit-lamp biomicroscopic evaluation of the cornea [Cibis et al., 1977; Miller and Krachmer, 1997], participants were classified as having PPCD if they showed any of the following: vesicular, geographic, or band-like lesions at the level of Descemet's membrane, or posterior vesicles in at least one eye. If outside ophthalmologic records did not specify the presence or absence of bands and vesicles, then the affected status was based on the clinical diagnosis of PPCD. In addition, all subjects examined by the authors were evaluated for the presence of guttae based on the finding of excrescences visible on specular reflection of the posterior corneal surface. The physicians who carried out the exams and assigned affection status had no knowledge of the subjects' genotypes. Based on a lack of reported hearing problems or a history of kidney disease among family members, we presumed that we were not dealing with Alport syndrome (MIM 301050, MIM104200, MIM 203780), which can sometimes include PPCD as a feature of the disease [Alport, 1927; Colville and Savage, 1997].

### Molecular Genetic Analysis

Genomic DNA was isolated from 26 members of UM:139 using Puregene (Gentra Systems, Minneapolis, MN) according to the manufacturer's instructions. An initial genome scan using 317 fluorescence-labeled microsatellite autosomal markers from the ABI Prism Linkage Mapping Set MD-10 Version 1 was performed (Applied Biosystems MD-10 v. 1, Foster City, CA). Markers were PCR-amplified according to the manufacturer's recommended protocols and size fractionated on 4% acrylamide gel using an ABI377 automated sequencer (Applied Biosystems). Based on data suggesting possible linkage, we tested eight additional markers on chromosome 10, and six additional markers on chromosome 13 (ABI Prism Linkage Mapping Set MD-10 Version 2 (Applied Biosystems; Research Genetics, Foster City). Previously, another 15 markers had been run in the vicinity of the PPCD-related loci on chromosomes 1 and 20 [Moroi et al., 2003].

Data were transferred electronically from the ABI sequencer into the Cicada database (E. Trager, University of Michigan, Eyegene Server <http://eyegene.ophthy.med.umich.edu>) and formatted with the use of an analysis and formatting program called Madeline (E. Trager, University of Michigan, Eyegene Server <http://eyegene.ophthy.med.umich.edu>). Clinical data were managed with the use of an Access database (Microsoft Corp., Redman, WA) and were displayed with Cyrillic (Cherwell Scientific Publishing Ltd., Palo Alto, CA) and Madeline.

Marker allele frequencies were estimated by a maximum likelihood method using all family members and taking their relationships into account [Boehnke, 1991]. Possible genotyping incompatibilities were evaluated by the method of O'Connell and Weeks [1998] with the use of the program Pedcheck and by the method of Sobel and Lange [1996] as implemented in SIMWALK2. Single-point linkage analysis was performed by the method of LOD scores [Morton, 1955] using the program MENDEL [Lange et al., 1988]. Multi-point linkage analysis was performed with the use of the Markov chain Monte Carlo method of Sobel and Lange [1996] through use of the program SIMWALK2. Haplotype construction was conducted independently by manual haplotype construction and by using SIMWALK2 [Sobel and Lange, 1996]. The test for linkage was performed under an autosomal dominant model, assuming a disease allele frequency of 0.001, 1% sporadic rate, and 90% penetrance based on one apparent case of non-penetrance in this family. For purposes of analysis, individuals

were designated affected if they were diagnosed with PPCD or unaffected if they had a normal ophthalmologic exam. Individuals with other ophthalmologic findings were treated as having unknown phenotype for purposes of analysis. Tests for significant differences in the pachymetry data used a two-sample *t*-test and the data appeared approximately normally distributed.

### RESULTS

We have previously reported that the transmission of PPCD in family UM:139 appears to be autosomal dominant with incomplete penetrance (Fig. 1) [Moroi et al., 2003]. The 26 sampled individuals include 13 individuals affected with PPCD and one case of apparent non-penetrance that may represent age-related penetrance (IV-2). The posterior corneal findings, pachymetry, iris features, angle features on gonioscopy, and ocular diagnosis for examined family members are summarized in Table I.

The proband (IV-10) has been described in detail previously [Moroi et al., 2003]. Her clinical course showed an aggressive form of PPCD that required 17 procedures on her left eye and eight procedures on her right eye. An unusual manifestation of her disease was the documented growth of the retrocorneal membrane onto the crystalline lens and intraocular lens. Our previous paper [Moroi et al., 2003] presented data supporting the diagnosis of PPCD in the proband, including images from light and transmission electron microscopy of the corneal button as well as use of anticytokeratin antibodies to evaluate presence or absence of cytokeratins in the epithelial and endothelial layers of the corneal button. Only one other family member, IV-11, has needed penetrating keratoplasty; however, his clinical course has, so far, not been complicated by the aggressive growth of a retrocorneal membrane and development of secondary glaucoma.

The presence of guttae in seven of the eight siblings for whom information is available, and in no one in the two younger generations, is consistent with prior reports of guttae as being an age-related finding [Kaufman et al., 1966; Lorenzetti et al., 1967; Jackson et al., 1999]. Guttae were present in both affected and unaffected individuals, and not present in one of the individuals with PPCD, which we interpret to mean that guttae in this family may be independent of the PPCD phenotype.

The mean corneal thickness, obtained by pachymetry, was larger for the PPCD family members (mean 600 microns, standard deviation (SD) 41 microns) than for the normal family members (mean 577 microns, SD 29 microns). For all individuals carrying the affected haplotype, including individual V-18 who carries the affected haplotype for part of the identified genetic inclusion interval, the mean was 592 microns (SD 47). In individuals with guttae, the mean thickness was 578 microns (SD 47). There was substantial overlap of the ranges and no strong evidence for a difference in mean values ( $P > 0.13$  for all pairwise comparisons).

Single-point analyses of family UM:139 suggested linkage of PPCD to markers on chromosome 10. Utilizing data from the whole family, we obtained maximum single-point LOD scores of 2.63, 1.63, and 3.19 for markers D10S208 (at  $\theta = 0.03$ ), D10S1780 (at  $\theta = 0.00$ ), and D10S578 (at  $\theta = 0.06$ ), respectively (Table II). An affecteds-only analysis produced maximum single-point LOD scores of 2.76, 1.32, and 2.05 at markers D10S208 (at  $\theta = 0.00$ ), D10S1780 (at  $\theta = 0.00$ ), and D10S578 (at  $\theta = 0.06$ ), respectively.

Subsequent multi-point analyses of family UM:139 suggested significant evidence of linkage on the short arm of chromosome 10 according to the criteria of Morton [1955]. A maximum multi-point LOD score of 4.3 was found at marker D10S1780 when data from the whole family were used (Fig. 2),

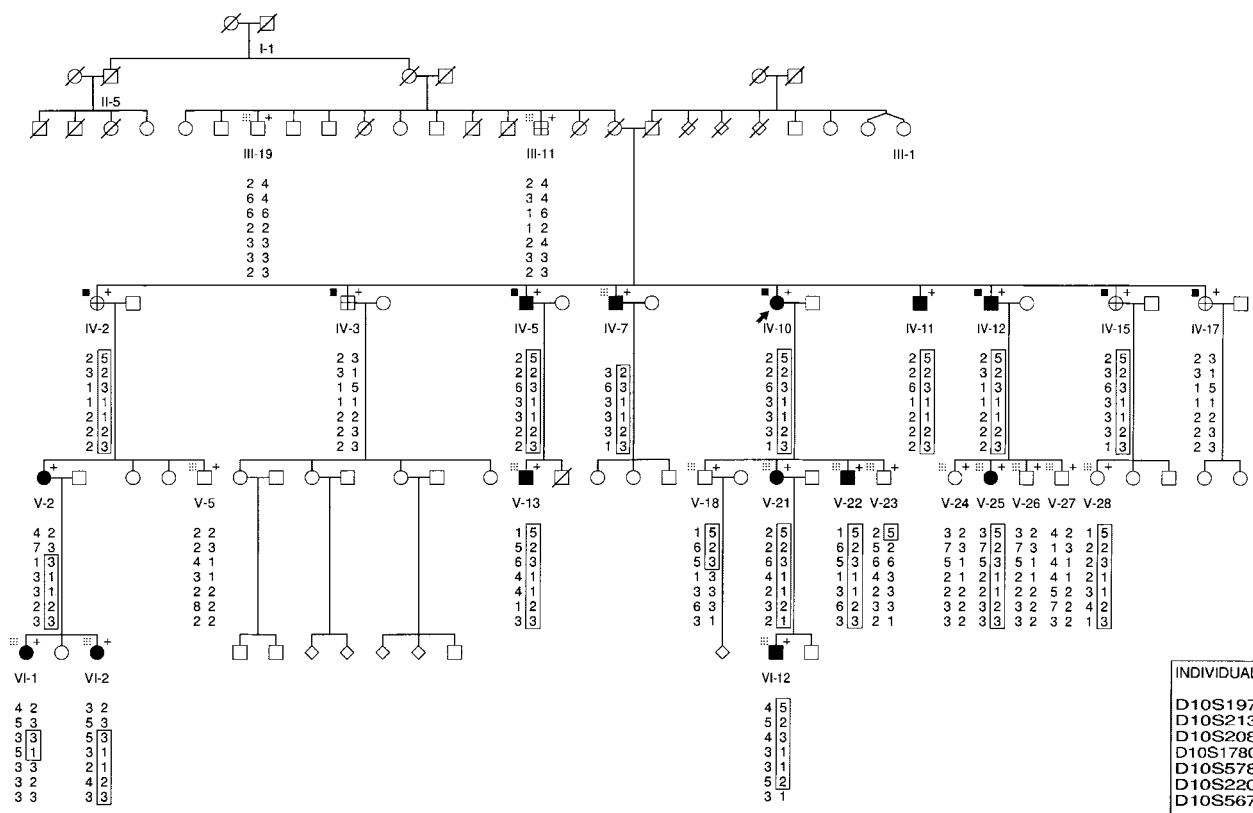


Fig. 1. Family UM:139 with PPCD. Among those individuals for whom molecular data were generated for use in the analysis (marked with +), filled symbols are individuals with PPCD, open symbols are individuals deemed unaffected with PPCD, and a cross within symbol indicates individuals who were scored as having an indeterminate PPCD status for purposes of analysis. Open symbols not marked with + are individuals for whom molecular data were not generated; they are free of PPCD by family report, but were not examined by us. Arrow indicates proband. Squares represent males; circles represent females. Diagonal line through symbol indicates individual is deceased. Box to the left of the + indicates presence (black dot) or absence (gray box) of guttae. Data on guttae are not available for

individuals not marked with a box. Other significant eye disease in the family includes: angle-closure glaucoma in the proband (IV-10); primary open-angle glaucoma (POAG) in III-11; blindness from an accident in I-1; blindness from unspecified glaucoma in II-5; and blindness from cataract surgery in III-1. Haplotypes are displayed for each individual genotyped, with a genetic inclusion interval between D10S213 and D10S578 indicated by recombination events apparent in data for individuals V-2 and VI-1. A recombination event in individual V-18 is not considered to further reduce the interval since this individual is unaffected in a family showing evidence of reduced penetrance.

with a 5.1 cM one-LOD support interval whose boundaries are roughly approximated by D10S208 and D10S578. An analogous affecteds-only multipoint analysis also suggested significant evidence of linkage of PPCD with a maximum multipoint LOD score of 3.53 at marker D10S208 (Fig. 2), although it appears that the LOD score value remains almost constant between D10S280 and D10S1780. An affected haplotype was identified and recombination events were identified that flank the 8.55 cM critical interval between markers D10S213 and D10S578.

In addition to the region with the highest observed LOD score, we also evaluated other regions showing some evidence of linkage. We were initially interested in the possibility of an alternative location on chromosome 13 because of the maximum single-point LOD score of 2.60 at D13S263 in the affecteds-only analysis. To follow up on this result, we evaluated this region at the 5 cM level by screening six additional markers, including three markers in an 18 cM region surrounding D13S263. The result was a broad peak with maximum multipoint LOD score of 1.76 at D13S263 for the affecteds-only analysis and a narrower peak with maximum multipoint LOD score of 1.51 between D13S217 and D13S1287 when all data from the family were used. Haplotype analysis failed to identify any single haplotype shared by all affected

family members, and all haplotypes present in affected family members were also present in unaffected individuals.

As further support for the argument that the gene responsible for PPCD in this family is located on chromosome 10p, it is important that data from other points in the genome fail to identify alternative locations and that such data support exclusion of other PPCD-associated regions previously reported. Our previous report excluded the region on chromosome 20 containing *PPCD1* and the *VSX1* gene (MIM605020) and the region on chromosome 1 containing *COL8A2* (MIM 120252) [Hand et al., 1999; Biswas et al., 2001; Heon et al., 2002; Moroi et al., 2003]. We conclude that we have excluded the region on chromosome 2q that contains two of the Alport syndrome genes *COL4A3* (MIM120070) and *COL4A4* (MIM120131) [Kashtan, 1999; Kent et al., 2002] based on our finding of LOD scores below  $-3.0$  across that whole region of chromosome 2. In addition, we can dismiss the X-linked Alport syndrome gene *COL4A5* (MIM 303630) [Kashtan, 1999] based on the autosomal dominant mode of inheritance in this family.

Once we had confirmed that our data suggest a locus on chromosome 10 and do not support locations elsewhere, we considered possible candidate genes within the *PPCD3* genetic inclusion interval. The 8.55 cM region between D10S213 and D10S578 contains 26 known genes and hundreds of predicted

TABLE I. Summary of Ocular Findings and Ocular Diagnoses in Examined Members of Family UM:139

Individual	Affected status	Ocular diagnosis	Corneal findings (OD/OS)			Pachymetry OD/OS ( $\mu$ m)	Iris findings (OD/OS)		Gonioscopy (OD/OS)	
			Posterior vesicles	Posterior band	Guttae		Ectropionuveae	"glass membrane"	Fine Synechiae	Broad synechiae
III-11	I	POAG	-/-	-/-	-/-	548/550	-/-	-/-	-/-	-/-
III-19	U	Normal	-/-	-/-	-/-	618/601	-/-	-/-	N/A	-/-
IV-2	I	Guttae	-/-	-/-	+/+	521/522	-/-	-/-	-/-	-/-
IV-3	I	Guttae	-/-	-/-	+/+	589/579	-/-	-/-	-/-	-/-
IV-5	A	PPCD guttae	-/-	+/+	+/+	563/589	-/-	-/-	-/-	-/-
IV-7	A	PPCD	+/+	-/-	-/-	582/567	-/-	-/-	-/-	-/-
IV-10 (proband)	A	PPCD guttae angle-closure glaucoma	+/+	-/-	+/+	580/680	+/+	+/+	-/-	+/+
IV-11	A	PPCD	-/+	+/+	N/A	720/610	-/-	-/-	-/-	-/-
IV-12	A	PPCD Guttae	+/+	+/+	+/+	567/603	-/-	-/-	-/-	-/-
IV-15	I	Guttae	-/-	-/-	+/+	N/A	-/-	-/-	-/-	-/-
IV-17	I	Guttae	-/-	-/-	+/+	N/A	-/-	-/-	-/-	-/-
V-2	A	PPCD <sup>a</sup>	+/+	-/-	-/-	N/A	N/A	-/-	N/A	-/-
V-5	U	Normal	-/-	-/-	-/-	520/523	-/-	-/-	-/-	-/-
V-13	A	PPCD	+/+	+/+	-/-	637/656	-/-	-/-	-/-	-/-
V-18	U	Normal	-/-	-/-	-/-	571/582	-/-	-/-	-/-	-/-
V-21	A	PPCD	+/+	-/-	-/-	582/575	-/-	-/-	N/A	-/-
V-22	A	PPCD	+/+	-/-	-/-	611/586	-/-	-/-	-/-	-/-
V-23	U	Normal	-/-	-/-	-/-	599/602	-/-	-/-	-/-	-/-
V-24	U	Normal	-/-	-/-	-/-	593/592	-/-	-/-	-/-	-/-
V-25	A	PPCD	+/+	-/-	-/-	640/623	-/-	-/-	-/+	-/+
V-26	U	Normal	-/-	-/-	-/-	581/565	-/-	-/-	-/-	-/-
V-27	U	Normal	-/-	-/-	-/-	607/590	-/-	-/-	-/-	-/-
V-28	U	Normal	-/-	-/-	-/-	N/A	N/A	-/-	N/A	-/-
VI-1	A	PPCD <sup>a</sup>	+/+	-/-	-/-	N/A	N/A	-/-	N/A	-/-
VI-3	A	PPCD <sup>a</sup>	+/+	-/-	-/-	540/550	N/A	-/-	N/A	-/-
VI-12	A	PPCD	+/+	-/-	-/-	573/574	-/-	-/-	N/A	-/-

<sup>a</sup>Diagnosis based on records from outside ophthalmologist, OD, right eye; OS, left eye; I, indeterminate status for purposes of analysis; A, affected status for purposes of analysis; U, unaffected status for purposes of analysis, N/A indicates that the information is not available.

genes and expressed sequence tags (EST's) [Kent et al., 2002]. Since the homeodomain transcription factor *Vsx1* has been implicated in PPCD [Heon et al., 2002], it is of interest to note that the *PPCD3* critical interval contains the transcription factor, *TCF8* (MIM189909), which has both homeodomain and zinc finger motifs [Williams et al., 1992; Funahashi et al., 1993; Franklin et al., 1994; Kent et al., 2002]. Although several collagen genes have been implicated in PPCD [Biswas et al., 2001] and in Alport syndrome, which can include PPCD [Colville and Savige, 1997; Kashtan, 1999], none of the known collagen genes are located in the interval between D10S213 and D10S578. Prioritization of candidate genes within this interval will call for additional bioinformatic analysis and evaluation of gene expression in relevant ocular tissues.

## DISCUSSION

Analysis of the genome scan data for family UM:139 has provided significant evidence for a new PPCD locus (*PPCD3*) in a 8.55 cM region on chromosome 10p near D10S1780. While we initially identified substantial single-point linkage evidence for a marker on chromosome 13, additional marker genotyping and multipoint analysis resulted in a substantial decrease in the linkage evidence. Thus, while chromosome 13 has not been formally excluded as containing a locus responsible for PPCD in this family, the evidence for this region is not strong. We cannot rule out the possibility that a locus in this region might be playing a role in the phenotype in some members of family UM:139, but there is no evidence of correlation of a specific

TABLE II. Single Point Analysis of Linkage of Chromosome 10 Markers to PPCD for all Data in Family UM:139

Marker	Position on chromosome 10 <sup>a</sup>	Recombination fraction						$\hat{Z}$	$\hat{\theta}$	$\theta(-2)$
		0.01	0.05	0.10	0.20	0.30	0.40			
D10S197	52.10	-0.26	0.62	0.98	1.08	0.81	0.36	1.10	0.17	0.00
D10S213	57.42	0.52	1.20	1.38	1.26	0.88	0.37	1.39	0.12	0.00
D10S208	60.64	2.61	2.62	2.48	1.96	1.26	0.49	2.63	0.03	0.00
D10S1780	63.83	1.61	1.49	1.34	1.01	0.64	0.27	1.63	0.00	0.00
D10S578	65.97	2.97	3.19	3.11	2.58	1.79	0.82	3.19	0.06	0.00
D10S220	70.23	1.51	1.38	1.21	0.85	0.51	0.20	1.55	0.00	0.00
D10S567	71.83	1.05	1.54	1.58	1.32	0.90	0.37	1.59	0.08	0.00
D10S539	72.90	1.44	1.70	1.69	1.38	0.88	0.31	1.71	0.07	0.00
D10S1790	75.57	0.79	1.63	1.80	1.54	0.98	0.31	1.80	0.10	0.00
D10S1652	80.77	-0.64	0.56	0.94	1.00	0.73	0.34	1.03	0.16	0.00
D10S581	82.50	0.73	1.30	1.41	1.24	0.87	0.39	1.41	0.10	0.00
D10S537	91.13	0.03	1.06	1.32	1.24	0.88	0.40	1.35	0.13	0.00

<sup>a</sup>Marker positions in cM from the tip of the short arm of the chromosome taken from the Marshfield Institute sex averaged map.  $\hat{Z}$  = maximum LOD score, displaying only those markers on chromosome 10 with  $\hat{Z} \geq 1.0$ ,  $\hat{\theta}$  = recombination fraction at which the LOD score is maximized,  $\theta(-2)$  = region around the marker that can be excluded at a level of LOD = -2.00 or less. Bracket flanks proposed genetic inclusion interval.

## Chromosome 10 Multipoint Analysis

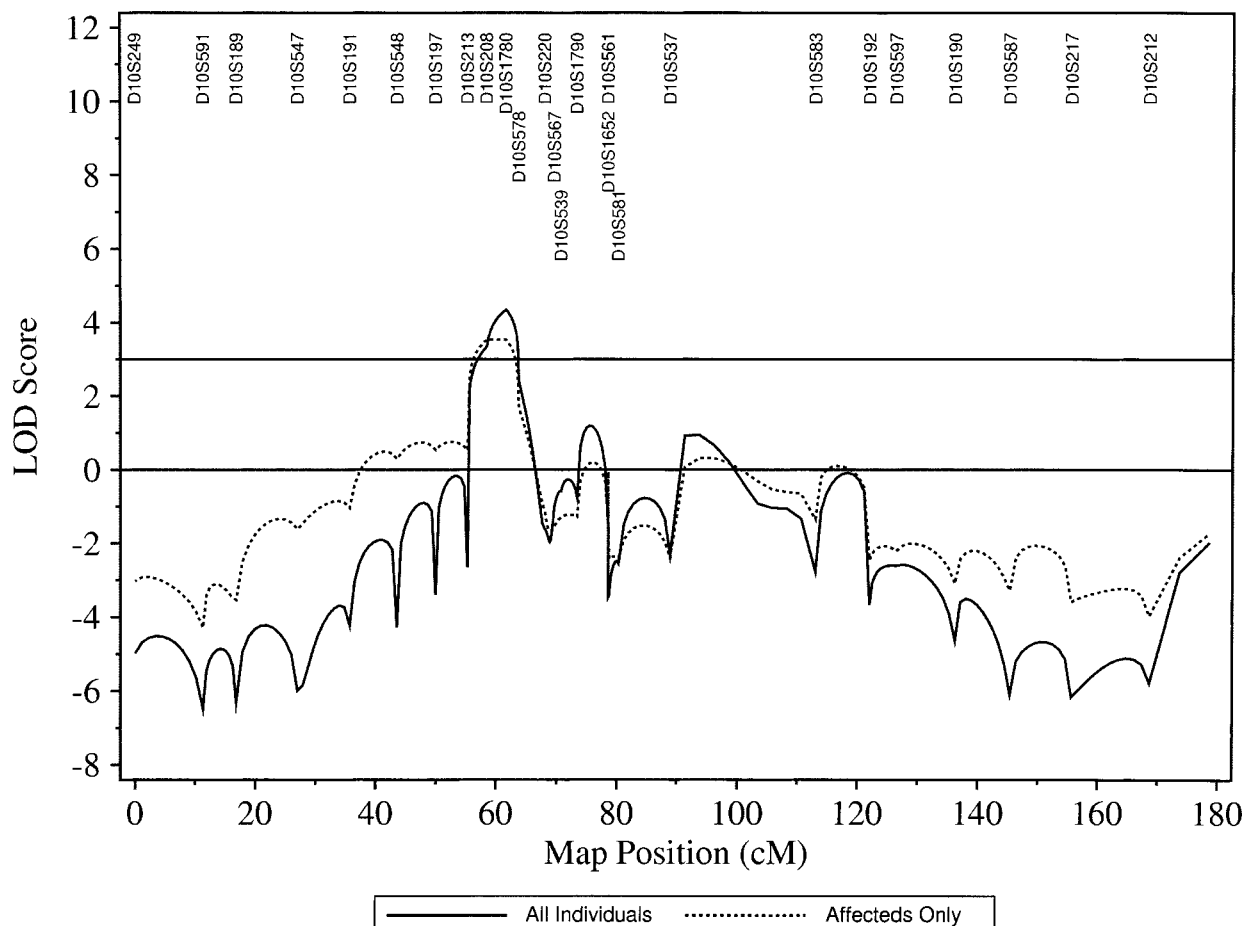


Fig. 2. Multipoint analysis of markers on 10p provides strong evidence of linkage with a maximum multipoint LOD score of 4.35 at marker D10S1780 when data from the whole family were used (solid line), and 3.53 at marker D10S208 when an affecteds-only analysis was done (dotted line). The map position indicates the distance from the tip of the short arm of the chromosome to the position of the marker tested. The LOD score indicates the level of statistical significance associated with the finding of possible linkage for each of the loci tested along the chromosome.

haplotype with disease severity or presence of specific characteristics such as guttae.

Our data allow us to exclude the region on chromosome 2 that contains two collagen genes implicated in Alport syndrome [Kashtan, 1999]. Previously, we excluded both the mapped PPCD locus on chromosome 20 [Heon et al., 2002] and the reported candidate PPCD gene on chromosome 1 [Biswas et al., 2001] as being responsible for PPCD in this family. Thus, the validity of this new PPCD locus is supported by: (1) significant evidence of linkage to markers in the vicinity of D10S1780, (2) a lack of evidence that the locus is elsewhere in the genome, and (3) evidence of exclusion of the other regions of the genome reportedly involved in PPCD.

In family UM:139, the expressivity of the PPCD phenotype varied widely, a characteristic previously described in PPCD families [Cibis et al., 1977]. Typically, the clinical course of PPCD is slowly progressive, and occasionally the clinical course may be severe with corneal decompensation and secondary glaucoma as found for proband, IV-10 [Moroi et al., 2003]. The striking feature of the proband, IV-10, was the documented accelerated growth of the retrocorneal membrane on the crystalline lens and intraocular lens after surgical interventions. A comparably aggressive pattern to the disease

has not been seen in the other 12 affected individuals, but if surgical intervention or penetrating trauma is what induces the membrane growth, then we would not know whether other family members have the potential for a similarly serious reaction since only one other family member has had a penetrating surgical procedure or trauma.

Another clinical feature worth noting is the presence of guttae in most members of generation IV, both in those with and those without PPCD. The underlying genetic components of guttae remain unknown. Guttae were absent in reports of some families with PPCD [McGee and Falls, 1953] and present in four of five PPCD individuals in one generation of a three-generation family [Threlkeld et al., 1994]. At present, it appears that the guttae are segregating independently of PPCD in the one generation affected with guttae, and our data are consistent with previous observations of guttae as an age-related finding [Goar, 1934; Kaufman et al., 1966; Lorenzetti et al., 1967; Nagaki et al., 1996]. If the one member of generation IV, who is known to currently lack guttae, were to develop guttae, then possible mitochondrial inheritance would become a consideration in this family with PPCD and guttae. This concept is reinforced by the fact that multiple genetic and biochemical scenarios have been reported for Fuchs

endothelial corneal dystrophy (MIM136800), a disorder that also includes guttae [Fuchs, 1910; Wilson and Bourne, 1988; Albin, 1988; Gottsch et al., 2003].

In summary, we have identified a new *PPCD3* locus on chromosome 10p in family UM:139. Given the previously reported locus on chromosome 20q and the report of *COL8A2* involvement in PPCD, it is clear that this disease is a genetically heterogeneous disorder. Determination of the underlying genetic components of PPCD will provide fundamental insights into the pathologic processes affecting the corneal endothelium and Descemet's membrane. Localization of a new PPCD locus will also provide new tools with which to study the relationship between PPCD and glaucoma.

### ELECTRONIC-DATABASE INFORMATION

See Online Mendelian Inheritance in Man (OMIM), <http://www.ncbi.nlm.nih.gov/Omim/> for *PPCD* or *PPMD* (MIM122000), *CHED1* (MIM121700), *CHED2* (MIM217700), Alport Syndrome (MIM 301050, MIM104200, MIM 203780), *COL4A3* (MIM120070), *COL4A4* (MIM 120131), *COL4A5* (MIM 303630), *COL8A2* (MIM120252), *TCF8* (MIM189909), and *VSX1* (MIM605020).

See the EyeGene Server <http://eyegene.ophthy.med.umich.edu> to download data formatting program Madeline and its documentation without charge.

### REFERENCES

- Albin RL. 1988. Fuch's corneal dystrophy in a patient with mitochondrial DNA mutations. *J Med Genet* 35:258–259.
- Alport AC. 1927. Hereditary familial congenital haemorrhagic nephritis. *Brit Med J* 1:504–506.
- Biswas S, Munier FL, Yardley J, Hart-Holden N, Perveen R, Cousin P, Sutphin JE, Noble B, Batterbury M, Kielty C, Hackett A, Bonshek R, Ridgway A, McLeod D, Sheffield VC, Stone EM, Schorderet DF, Black GCM. 2001. Missense mutations in *COL8A2*, the gene encoding the alpha-2 chain of type VIII collagen, cause two forms of corneal endothelial dystrophy. *Hum Mol Genet* 10:2415–2423.
- Boehnke M. 1991. Allele frequency estimation from data on relatives. *Am J Hum Genet* 48:22–25.
- Bourgeois J, Shields MB, Thresher R. 1984. Open-angle glaucoma associated with posterior polymorphous dystrophy. A clinicopathologic study. *Ophthalmol* 91:420–423.
- Chan CC, Green WR, Barraquer J, Barraquer-Somers E, de la Cruz ZC. 1982. Similarities between posterior polymorphous and congenital hereditary endothelial dystrophies: A study of 14 buttons of 11 cases. *Cornea* 1:155–172.
- Cibis GW, Krachmer JA, Phelps CD, Weingeist TA. 1977. The clinical spectrum of posterior polymorphous dystrophy. *Arch Ophthalmol* 95:1529–1537.
- Colville D, Savage J. 1997. Alport syndrome: A review of ocular manifestations. *Ophthalmol* 18:161–173.
- Franklin AJ, Jetton TL, Shelton KD, Magnuson MA. 1994. BZP, a novel serum-responsive zinc finger protein that inhibits gene transcription. *Mol Cell Biol* 14:6773–6788.
- Fuchs E. 1910. Dystrophia epithelialis corneae. *Albrecht Von Graefes Arch Ophthalmol* 76:478–508.
- Funahashi J, Sekido R, Murai K, Kamachi Y, Kondoh H. 1993. Delta-crystallin enhancer binding protein delta EF1 is a zinc finger-homeodomain protein implicated in postgastrulation embryogenesis. *Development* 119:433–446.
- Goar EL. 1934. Dystrophy of the corneal endothelium (cornea guttata), with a report of a histological examination. *Am J Ophthalmol* 17:215.
- Gottsch JD, Bowers AL, Margulies EH, Seitzman GD, Kim SW, Saha S, Jun AS, Stark WJ, Liu SH. 2003. Serial analysis of gene expression in the corneal endothelium of Fuchs' dystrophy. *Invest Ophthalmol Vis Sci* 44:594–599.
- Hand CK, Harmon DL, Kennedy SM, FitzSimon JS, Collum LMT, Parfrey NA. 1999. Localization of the gene for autosomal recessive congenital hereditary endothelial dystrophy (CHED2) to chromosome 20 by homozygosity mapping. *Genomics* 61:1–4.
- Heon E, Greenberg A, Koop KK, Rootman D, Vincent AL, Billingsley G, Priston M, Dorval KM, Chow RL, McInnes RR, Heathcote G, Westall C, Sutphin JE, Semina E, Bremner R, Stone EM. 2002. *VSX1*: A gene for posterior polymorphous dystrophy and keratoconus. *Hum Mol Genet* 11:1029–1036.
- Jackson AJ, Robinson FO, Frazer DG, Archer DB. 1999. Corneal guttata: A comparative clinical and specular micrographic study. *Eye* 13:737–743.
- Kashtan CE. 1999. Alport syndrome. An inherited disorder of renal, ocular, and cochlear basement membranes. *Medicine* 78:338–360.
- Kaufman HE, Capella JA, Robbins JE. 1966. The human corneal endothelium. *Am J Ophthalmol* 61:835–841.
- Kent WJ, Sugnet CW, Furey TS, Roskin KM, Pringle TH, Zahler AM, Haussler D. 2002. The human genome browser at UCSC. *Genome Research* 12:996–1006, Accessed April 2003.
- Krachmer JH. 1985. Posterior polymorphous corneal dystrophy: A disease characterized by epithelial-like endothelial cells which influence management and prognosis. *Tr Am Ophth Soc* 83:413–475.
- Lange K, Weeks D, Boehnke M. 1988. Programs for pedigree analysis: MENDEL, FISHER, and dGENE. *Genet Epidemiol* 5:471–472.
- Lorenzetti DWC, Uotila MH, Parikh N, Kaufman HE. 1967. Central cornea guttata: Incidence in the general population. *Am J Ophthalmol* 64:1155.
- McGee HB, Falls HF. 1953. Hereditary polymorphous deep degeneration of the cornea. *Arch Ophthalmol* 50:462–467.
- Miller CA, Krachmer JH. 1997. Endothelial dystrophies. In: Kaufman HE, Barron BA, McDonald MB, editors. *The cornea*. 2nd edn. Boston, MA: Butterworth-Heinemann. p 453–475.
- Moroi SE, Gokhale PA, Schteingart MT, Sugar A, Downs CA, Shimizu S, Krafchak C, Fuse N, Elner SG, Elner VM, Flint A, Epstein MP, Boehnke M, Richards JE. 2003. Clinicopathologic correlation and genetic analysis in a case of posterior polymorphous corneal dystrophy. *Am J Ophthalmol* 135:461–470.
- Morton NE. 1955. Sequential tests for the detection of linkage. *Am J Hum Genet* 7:277–318.
- Nagaki Y, Hayasaka S, Kitagawa K, Yamamoto S. 1996. Primary cornea guttata in Japanese patients with cataract: Specular microscopic observations. *Jpn J Ophthalmol* 40:520–525.
- O'Connell JR, Weeks DE. 1998. PedCheck: A program for identification of genotype incompatibilities in linkage analysis. *Am J Hum Genet* 63:259–266.
- Sobel E, Lange K. 1996. Descent graphs in pedigree analysis: Applications to haplotyping, location scores, and marker-sharing statistics. *Am J Hum Genet* 58:1323–1337.
- Threlkeld AB, Green WR, Quigley HA, de la Cruz Z, Stark WJ. 1994. A clinicopathologic study of posterior polymorphous dystrophy: Implications for pathogenetic mechanism of the associated glaucoma. *Tr Am Ophth Soc* 92:133–165.
- Toma NM, Ebenezer ND, Inglehearn CF, Plant C, Ficker LA, Bhattacharya SS. 1995. Linkage of congenital hereditary endothelial dystrophy to chromosome 20. *Hum Mol Genet* 4:2395–2398.
- Weisenthal RW, Streten BW. 1997. Posterior membrane dystrophies. In: Krachmer JH, Mannis MJ, Holland EJ, editors. *Cornea Vol. II. Cornea and external disease: Clinical diagnosis and management*. St. Louis, MO: Mosby-Year Book, Inc. p 1063–1090.
- Williams TM, Montoya G, Wu Y, Eddy RL, Byers MG, Shows TB. 1992. The *TCF8* gene encoding a zinc finger protein (Nil-2-a) resides on human chromosome 10p11.2. *Genomics* 14:194–196.
- Wilson SE, Bourne WM. 1988. Fuchs' dystrophy. *Cornea* 7:2–18.