

PEDIATRICS®

OFFICIAL JOURNAL OF THE AMERICAN ACADEMY OF PEDIATRICS

A Long-term Competent Chimeric Immune System in a Dizygotic Dichorionic Twin

Valerie Biran, Marie Bornes, Azzedine Aboura, Sonia Masmoudi, Séverine Drunat, Clarisse Baumann, Sara Osimani, Jean-Hugues Dalle, Ghislaine Sterkers, Alain Verloes, Caroline Farnoux, Laure Maury, Thomas Schmitz, Suonavy Khung and Olivier Baud

Pediatrics 2011;128:e458; originally published online July 11, 2011;
DOI: 10.1542/peds.2010-3557

The online version of this article, along with updated information and services, is located on the World Wide Web at:

<http://pediatrics.aappublications.org/content/128/2/e458.full.html>

PEDIATRICS is the official journal of the American Academy of Pediatrics. A monthly publication, it has been published continuously since 1948. PEDIATRICS is owned, published, and trademarked by the American Academy of Pediatrics, 141 Northwest Point Boulevard, Elk Grove Village, Illinois, 60007. Copyright © 2011 by the American Academy of Pediatrics. All rights reserved. Print ISSN: 0031-4005. Online ISSN: 1098-4275.

American Academy of Pediatrics

DEDICATED TO THE HEALTH OF ALL CHILDREN™



A Long-term Competent Chimeric Immune System in a Dizygotic Dichorionic Twin

abstract

We present here a rare case that involved the long-term coexistence of 2 mature, functional, and equilibrated immune systems in a single child after fetofetal transfusion between dizygotic twins. A dichorionic diamniotic pregnancy complicated by twin anemia-polycythemia sequence resulted in the demise of 1 twin. The detection of abnormal vessels on the dichorionic plate strongly suggested the existence of functional vascular anastomoses leading to blood chimerism in the survivor. Genetic, phenotypic, and immunologic analyses at 2 years revealed chimeric lymphoid and myeloid cells in the surviving twin, although no tissue mosaicism was detected, which indicates that early transfusion led to mutual immune tolerance. *Pediatrics* 2011;128:e458–e463

AUTHORS: Valerie Biran, MD, PhD,^{a,b,c} Marie Bornes, MD,^d Azzedine Aboura, MD, PhD,^e Sonia Masmoudi, MD,^f Séverine Drunat, PharmD, PhD,^e Clarisse Baumann, MD,^e Sara Osimani, MD,^e Jean-Hugues Dalle, MD, PhD,^g Ghislaine Sterkers, MD, PhD,^f Alain Verloes, MD, PhD,^e Caroline Farnoux, MD,^b Laure Maury, MD,^b Thomas Schmitz, MD, PhD,^{c,d} Suonavy Khung, MD,^h and Olivier Baud, MD, PhD^{a,b,c}

^aINSERM, U676, AVENIR R05230HS Team, Paris, France; ^bNeonatal Intensive Care Unit and Departments of ^dObstetrics, ^eHuman Genetics, ^fBiological Immunology, ^gClinical Hematology, and ^hFetal Pathology, Robert Debré Children's Hospital, Assistance Publique-Hôpitaux de Paris, Université Paris 7-Denis Diderot, Paris, France; and ^cPremUP, Paris, France

KEY WORDS

chimeric twins, twin anemia-polycythemia sequence, immune tolerance, vascular anastomoses, immune system

ABBREVIATION

TAPS—twin anemia-polycythemia sequence

Drs Biran, Bornes, Khung, and Baud contributed equally to this study.

All the authors made substantive intellectual contributions to this article by contributing to conception and design, acquisition of data, or analysis and interpretation of data, drafting of the article and revising it critically for important intellectual content, and approving the final version submitted.

www.pediatrics.org/cgi/doi/10.1542/peds.2010-3557

doi:10.1542/peds.2010-3557

Accepted for publication Mar 25, 2011

Address correspondence to Olivier Baud, MD, PhD, Service de Réanimation et Pédiatrie Néonatales, Hôpital Robert Debré, 48 Blvd Sérurier, F-75019 Paris, France. E-mail: olivier.baud@rdb.aphp.fr

PEDIATRICS (ISSN Numbers: Print, 0031-4005; Online, 1098-4275).

Copyright © 2011 by the American Academy of Pediatrics

FINANCIAL DISCLOSURE: *The authors have indicated they have no financial relationships relevant to this article to disclose.*

Chimerism is the presence in a single person of cells derived from 2 or more zygotes. Blood chimerism in dizygotic twins is a rare condition caused by the intrauterine anastomoses of blood vessels, which leads to fetofetal transfusion.^{1,2} Fetal immunologic immaturity allows transfused stem cells to proliferate in the bone marrow of the co-twin and results in the coexistence of 2 populations of blood cells in 1 person.³ The mutual nonreactivity of these populations has been demonstrated by mixed lymphocyte reaction in 3 cases of dizygotic twins with blood-group chimerism and HLA disparity.⁴⁻⁶ However, the long-term immunologic characteristics, maturation, and tolerance of these immune systems have, to our knowledge, never been described in chimeric human twins with nonidentical HLA. We report here the case of a spontaneous dichorionic diamniotic twin pregnancy complicated by a twin anemia-polycythemia sequence (TAPS), a newly characterized form of fetofetal transfusion,⁷ and the demise of 1 twin. The surviving twin underwent extensive genetic and immunologic analyses, which revealed for the first time the existence of 2 mutually tolerant, equilibrated, mature, and functional immune systems at 2 years of age.

CASE REPORT

A spontaneous dichorionic diamniotic twin pregnancy was confirmed at 12 weeks of gestation by the presence of a twin-peak sign on ultrasound scan in a 20-year-old woman. Fetal growth, amniotic fluid index, and umbilical and uterine artery resistance index were normal. At 29 weeks of gestation, twin 1 showed growth below the 5th percentile according to French AUDIPOG curves⁸ and an increased umbilical artery resistance index. Growth parameters remained normal for twin 2, and amniotic fluid volumes were considered normal for both twins. At 32 weeks of gestation, ultrasonography revealed normal amni-

otic fluid volumes for both twins, although twin 1 displayed reversed diastolic flow within the umbilical artery and the ductus venosus, cardiomegaly with pericardial effusion, and ascites. The death of twin 1 in utero was followed rapidly by the preterm delivery of twin 2 at 32 $\frac{2}{7}$ weeks of gestation. The necropsy of twin 1 and genetic investigations of twins 1 and 2 were conducted after receiving written informed consent from the parents.

Twin 1 was a growth-restricted hydropic boy. Postmortem examination

revealed pathologic signs of chronic anemia: pale viscera, adrenal steatosis, cardiomegaly, and mild erythroblastosis without signs of viral infection. Cerebral examination revealed white matter edema and astrogliosis consistent with ischemic damage. Twin 2 was a phenotypically eutrophic girl with a birth weight of 1650 g. She developed transient respiratory distress that resolved in 24 hours. Her hemoglobin levels were 19 g/dL. Her subsequent neonatal course was uneventful.

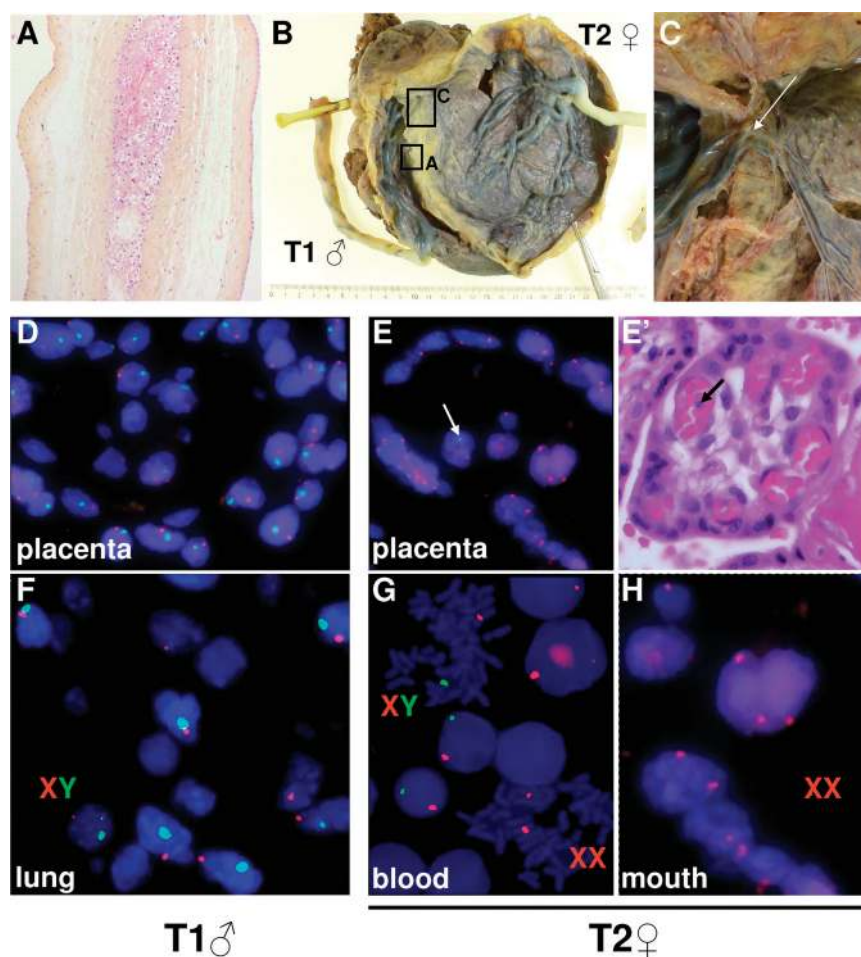


FIGURE 1

Pathologic examination of placentas and cytogenetic analyses in twins 1 and 2. Pathologic examination revealed dichorionic placentas (A) with unequal surfaces: 17 × 4 cm (twin 1) and 18 × 18 cm (twin 2). Unusual vessels crossed the placental fusion area (arrow) from twin 1 to twin 2 (B) and arborized over the chorionic plate of twin 2 (C). Fluorescent in situ hybridization analysis revealed only XY cells in the placenta and frozen lung tissue of twin 1 (D and F). In the placenta of twin 2, XX cells, probably trophoblasts, were found on the border, and XY cells, probably leukocytes, were found within the capillaries (E and E'). Peripheral blood from twin 2 revealed 2 equilibrated XX and XY cell populations (G), whereas buccal smears revealed a homogeneous XX cell population (H).

Placental examination revealed dichorionic placentas fused over 17 cm: the septum contained 2 chorionic leaves between the 2 amniotic layers (Fig 1A). The chorionic plates showed very small and unusual anastomotic vessels issuing from twin 1, crossing a region at the area of placental fusion, and arborizing over an area of 9 × 6 cm on the twin 2 chorionic plate (Fig 1B and C). In sections, the parenchyma of the placenta of twin 1 appeared paler than that of twin 2. One of the cotyledons between twin 1 and twin 2 showed avascular stem villi resulting from the collapse of villar vessels. These findings, associated with the anemia observed in twin 1 and the polycythemia in twin 2, supported the evidence of a pregnancy complicated by TAPS.

Fluorescent in situ hybridization on paraffin-embedded placental sections taken close to the umbilical cord insertion points revealed only XY cells in the territory of twin 1 (Fig 1D), whereas 2 cell populations were observed in twin 2. The shape of the villi was recognizable; there were XX trophoblasts at the border and some XY cells, possibly circulating leukocytes, in the center (Fig 1E and E'). Only XY cells were observed in lung sections from twin 1 (Fig 1F). The peripheral blood karyotype was 25% 46,XX and 75% 46,XY at birth and 40% 46,XX and 60% 46,XY at 2 years of age (Fig 1G). The allelic profile of twin 2 obtained by using blood DNA revealed that 40% of the cells were 46,XX, and 60% were 46,XY cells. In contrast, somatic fluorescent in situ hybridization karyotyping of a buccal smear at 2 years revealed homogeneously 46,XX cells (400 cells) (Fig 1H). At 3 months, twin 2 had a normal pelvic ultrasound examination, and her gonadotrophin levels (luteinizing hormone (LH), follicle-stimulating hormone (FSH)) confirmed female gender. Microsatel-

lite studies confirmed that the fetuses were dizygotic (data not shown).

Potential blood chimerism was investigated by using molecular cytogenetics, HLA typing, and genetic and immunologic analyses. The father, mother, and twin 2 had identical blood groups: A DcE/dce. HLA typing revealed 2 haplotypes each for the mother (HLA-A*03-B*58-DRB1*08 and HLA-A*33-B*58-DRB1*13), the father (HLA-A*31-B*35-

DRB1*03 and HLA-A*68-B*35-DRB1*11), and twin 1 (HLA-A*03-B*58-DRB1*08 and HLA-A*68-B*35-DRB1*11). HLA typing of twin 2 performed at the ages of 5 months and 2 years revealed 3 haplotypes: HLA-A*03-B*58-DRB1*08, HLA-A*31-B*35-DRB1*03, and HLA-A*68-B*35-DRB1*11.

HLA typings of family members and haplotype assignment revealed that twins 1 and 2 shared the same mater-

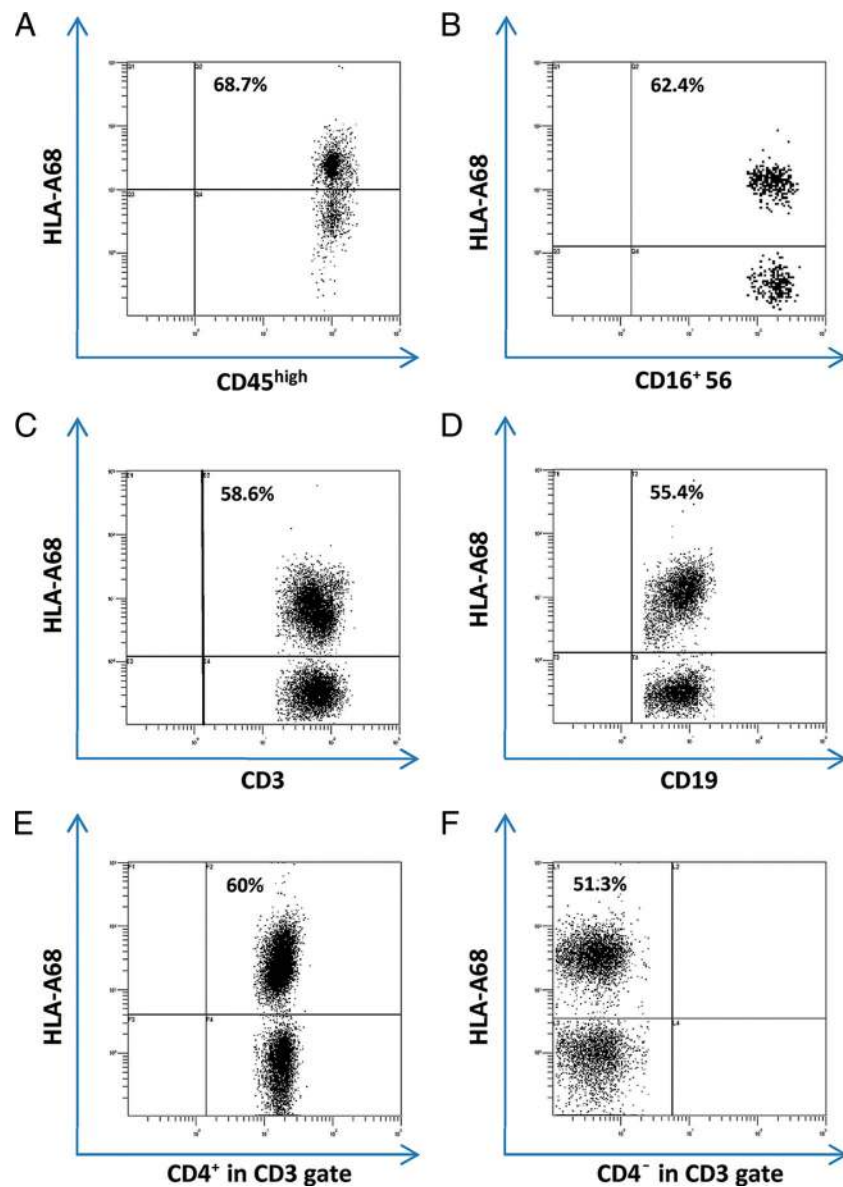
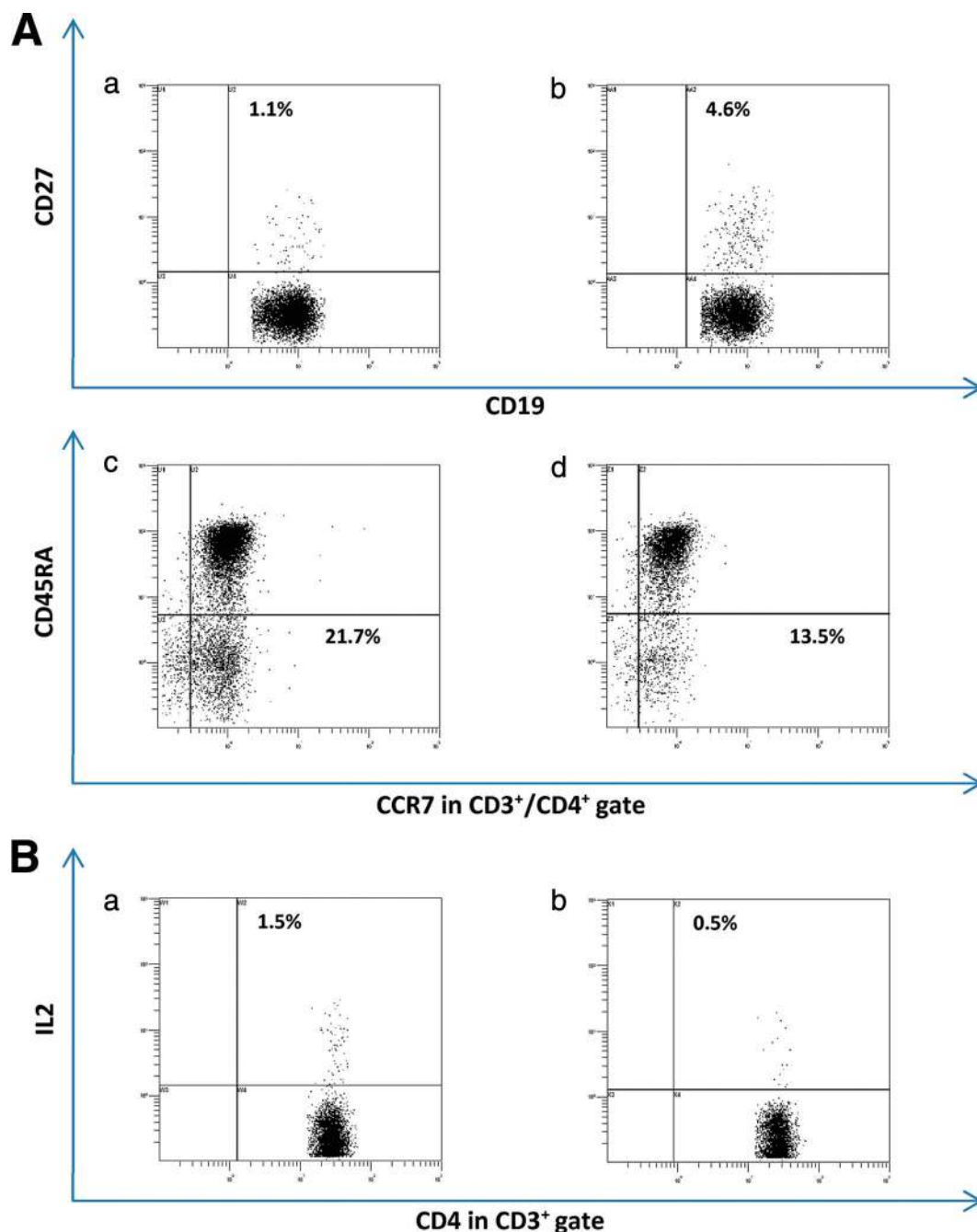


FIGURE 2 Distribution of transmitted and autologous leukocytes in twin 2. Shown are percentages of HLA-A*68–positive cells gating for natural killer, B (CD19), T (CD3), CD4⁺, and CD8⁺ T cells. A, Monocytes; B, natural killer cells; C, TCD3 cells; D, B cells; E, TCD4 cells; F, TCD8 cells.

**FIGURE 3**

Maturation and function of transmitted and autologous leukocytes in twin 2. A, Expression of CD27 on B lymphocytes (a and b) and of CD45RA and CCR7 on CD4⁺ T cells (c and d) after gating in HLA-A68⁺ (transmitted) or HLA-A68⁻ (autologous) subsets. B, Interleukin 2 expression after in vitro stimulation in HLA-A68 positive (transmitted) (a) and negative (autologous) (b) CD4⁺ T cells.

nal haplotype and that the A*68-B*35-DRB1*11 haplotype from twin 1 was transmitted to twin 2. Therefore, a monoclonal antibody (MAb) specific for the HLA-A68 antigen was used for the identification of twin 1–derived blood leukocytes in twin 2. Approxi-

mately half the cells of lymphoid origin, namely B and T cells (CD4⁺ and/or CD8⁺ and natural killer cells), and an even higher proportion of monocytes (of myeloid origin) derived from twin 1 (HLA-A68⁺) (Fig 2). Using a specific MAb against CD27, a B-cell differentia-

tion marker, we found both autologous (HLA-A68⁻) and twin 1–derived (HLA-A68⁺) mature (CD27⁺) B cells in twin 2 (Fig 3A). Similar distributions of central memory (CCR7⁺) and effector memory (CCR7⁻) CD4⁺CD45RA⁻ T cells were found in both HLA-A68⁺ and

TABLE 1 Immunophenotyping in Twin 2 Compared With Age-Matched Control Children

Immunophenotyping	TCD3	TCD4	TCD8	B	Natural Killer	Activated TCD3	Naive TCD4
Twin 2							
Absolute count, nb/ μ L	2026	1192	594	1823	214	287	918
%	52	32	16	45	5	14	77
Controls ^a							
Absolute count, nb/ μ L (range)	3068 (1575–5385)	1896 (1146–3530)	984 (378–2276)	949 (378–2521)	469 (86–1195)	192 (67–422)	1312 (874–3212)
% (range)	68 (62–81)	43 (29–57)	20 (13–30)	20 (12–29)	10 (4–21)	5 (1.81–6.4)	82 (70–91)

nb indicates number of cells.

^a Age-matched healthy children ($n = 10$): mean age, 2.5 years (range: 0.41–4 years).

TABLE 2 Proliferative responses in Twin 2 Compared With Age-Matched Control Children

Proliferative Responses	TT	PPD	HADV
Twin 2			
cpm	84586	150000	93068
Index	99	176	109
Controls ^a			
cpm (range)	97805 (44 467–200 000)	39652 (11 190–57 825)	36407 (14 750–66 722)
Index (range)	256 (82–495)	108 (51–173)	98 (46–199)

TT: tetanus toxin; PPD: purified protein derivative.

^a Healthy children ($n = 5$): mean age: 6 years (range: 5–9 years).

HLA-A68⁻ compartments, which indicates T-cell maturation. HLA-A68⁺ and HLA-A68⁻ CD4 T cells secreted interleukin 2 after polyclonal stimulation with an anti-CD3 MAb (Fig 3B), which confirms that both autologous and engrafted T lymphocytes were functional. Immunologic investigations further revealed that the expression of the main blood lymphocyte subsets in twin 2 was within the range seen in healthy age-matched children (Table 1). Intense proliferative responses to tetanus toxoid (84 586 counts per minute (cpm); SI: 99) PPD (150 000 cpm; SI: 176) and adenovirus indicated the competence of cellular immunity (Table 2). Serum immunoglobulin classes, subclasses, and tetanus toxoid-specific immunoglobulins were within normal ranges, which confirms the integrity of humoral immunity (data not shown).

The demise of 1 twin precluded a standardized reciprocal mixed lymphocyte reaction. Mixed lymphocyte reaction and proliferative responses to nominal antigens were analyzed as previously described.⁹ The expression of 1 paternal haplotype on autologous twin

2 cells and of the other on transmitted lymphocytes provided an opportunity for testing reciprocal tolerance by using twin 2 peripheral blood mononuclear cells as effectors and irradiated paternal peripheral blood mononuclear cells as stimulators. Nonresponsiveness to the father's cells was selectively observed in twin 2 (cpm: 486; SI: 2) versus a healthy age-matched control child (cpm: 21 088; SI: 10), whereas both twin 2 (cpm: 120 000; SI: 381) and the control child (cpm: 140 000; SI: 61) showed intense proliferative responses to the polyclonal activator phytohemagglutinin (PHA), used as an internal control.

DISCUSSION

To our knowledge, this is the first report to show that chimeric T lymphocytes in a dizygotic twin after TAPS are fully functional over the long-term. Regarding placental pathology, Assaf et al¹⁰ previously described twin-twin transfusion syndrome in a dizygotic monochorionic diamniotic twin gestation complicated by TAPS. The functional vascular anastomoses observed on the dichorionic plate could account

for the unequal blood transfer between twins.¹¹ These anastomoses cross over the part of the chorionic plates specific to each twin, which suggests a clastic event that allowed the 2 chorionic plates to merge, probably at an early stage of development (ie, during vasculogenesis).¹² Therefore, this blood chimerism confined to blood cells can be explained by the exchange of hematopoietic stem cells in dizygotic twins, as previously described.^{13,14} However, immune system maturation and function in dizygotic chimeric children have never been explored.

In this subject, we found 2 distinct, competent, and functional immune systems at 2 years of age. Persistent chimerism implies that there are at least 2 lineages in the lymphohematopoietic compartment. Engraftment as a consequence of immune or myelopoietic deficiency was excluded by lymphocyte subset counts, immunoglobulin dosage, and T-cell proliferation assays. The acquisition of reciprocal tolerance was suggested by the nonresponsiveness of twin 2 lymphocytes to both paternal HLA haplotypes, which were differentially expressed by inherited and engrafted immune cells.

Previous studies on blood-cell chimerism in twins have mostly been based on the analysis of blood groups.¹⁵ Only 4 other studies^{4–6,16} used HLA differences to extend the analysis of chimerism to the leukocytic compartment, and 3 of them^{4–6} documented the reciprocal nonresponsiveness of chimeric

lymphocytes in a mixed lymphocyte reaction assay. Blood-cell chimerism and the acquisition of tolerance through the confluence of fetal vessels are well-known events in dizygotic twin cattle.¹⁷ Human fetuses older than 16 weeks of gestation seem capable of developing an immune reaction against allogenic cells.¹⁸ In our case, the exchange of blood during the first trimester of gestation likely created optimal conditions for the acquisition of tolerance. It could have led to the engraftment of hematopoietic stem cells with high self-renewal capacity from twin 1 and, subsequently, to long-term

chimerism as previously reported in immunocompetent mice.¹⁹

The HLA disparity between the twins permitted the distribution and maturation capacity of the chimeric lymphocytes to be investigated. At 2 years, twin 2 displayed remarkably stable proportions of chimeric lymphocytes and monocytes. In addition, T lymphocytes from HLA-disparate twins could mature and become functional in a single person. Theoretically, thymocytes must share HLA antigens with thymic epithelial cells to differentiate into lymphocytes. Similarly, HLA compatibility between lymphocytes and host

cells is needed for memory T-cell development. The role of the maternal haplotype shared by the 2 twins in this process remains plausible.

CONCLUSIONS

We report the case of a dizygotic twin with long-term mature and functional HLA-disparate immune cells. Blood exchange early in the fetal period through anastomosis of placental vessels likely contributed to the acquisition of tolerance. Whether chimeric twins are tolerant only with respect to hematopoiesis or to other tissues also remains a question.

REFERENCES

1. Lage JM, Vanmarter LJ, Mikhail E. Vascular anastomoses in fused, dichorionic twin placentas resulting in twin transfusion syndrome. *Placenta*. 1989;10(1):55–59
2. Dunsford I, Bowley CC, Hutchison AM, et al. A human blood-group chimera. *Br Med J*. 1953;2(4827):81
3. van Dijk BA, Boomsma DI, de Man AJ. Blood group chimerism in human multiple births is not rare. *Am J Med Genet*. 1996;61(3):264–268
4. Angela E, Robinson E, North D. A case of twin chimerism. *J Med Genet*. 1976;13(6):528–530
5. Thomsen M, Hansen HE, Dickmeiss E. MLC and CML studies in the family of a pair of HLA haploidentical chimeric twins. *Scand J Immunol*. 1977;6(5):523–528
6. Viëtor HE, Hamel BC, van Bree SP, et al. Immunological tolerance in an HLA non-identical chimeric twin [published correction appears in *Hum Immunol*. 2000;61(7):720]. *Hum Immunol*. 2000;61(3):190–192
7. Lopriore E, Middeldorp JM, Oepkes D, Kanhai HH, Walther FJ, Vandenbussche FP. Twin anemia-polycythemia sequence in two monochorionic twin pairs without oligo-polyhydramnios sequence. *Placenta*. 2007;28(1):47–51
8. Mamelle N, Munoz F, Grandjean H. Fetal growth from the AUDIPOG study. I. Establishment of reference curves [in French]. *J Gynecol Obstet Biol Reprod (Paris)*. 1996;25(1):61–70
9. Guérin V, Dalle JH, Pédrón B, et al. Cellular immune parameters associated with spontaneous control of CMV in children who underwent transplantation. *Bone Marrow Transplant*. 2010;45(3):442–449
10. Assaf SA, Randolph LM, Benirschke K, et al. Discordant blood chimerism in dizygotic monochorionic laser-treated twin-twin transfusion syndrome. *Obstet Gynecol*. 2010;116(2):483–485
11. Slaghekke F, Kist WJ, Oepkes D, et al. Twin anemia-polycythemia sequence: diagnostic criteria, classification, perinatal management and outcome. *Fetal Diagn Ther*. 2010;27(4):181–190
12. Ekelund CK, Skibsted L, Sogaard K, et al. Dizygotic monochorionic twin pregnancy conceived following intracytoplasmic sperm injection treatment and complicated by twin-twin transfusion syndrome and blood chimerism. *Ultrasound Obstet Gynecol*. 2008;32(6):832–834
13. Quintero RA. Twin-twin transfusion syndrome. *Clin Perinatol*. 2003;30(3):591–600
14. Souter VL, Kapur RP, Nyholt DR, et al. A report of dizygous monochorionic twins. *N Engl J Med*. 2003;349(2):154–158
15. Machin G. Non-identical monozygotic twins, intermediate twin types, zygosity testing, and the non-random nature of monozygotic twinning: a review. *Am J Med Genet C Semin Med Genet*. 2009;151C(2):110–127
16. Bird GW, Gibson M, Wingham J, Mackintosh P, Watkins W, Greenwell P. Another example of haemopoietic chimaerism in dizygotic twins. *Br J Haematol*. 1980;46(3):439–445
17. Owen RD. Immunogenetic consequences of vascular anastomoses between bovine twins. *Science*. 1945;102(2651):400–401
18. Adinolfi M, Lessof MH. Development of humoral and cellular immunity in man. *J Med Genet*. 1972;9(1):86–91
19. Fleischman RA, Custer RP, Mintz B. Totipotent hematopoietic stem cells: normal self-renewal and differentiation after transplantation between mouse fetuses. *Cell*. 1982;30(2):351–359

A Long-term Competent Chimeric Immune System in a Dizygotic Dichorionic Twin

Valerie Biran, Marie Bornes, Azzedine Aboura, Sonia Masmoudi, Séverine Drunat, Clarisse Baumann, Sara Osimani, Jean-Hugues Dalle, Ghislaine Sterkers, Alain Verloes, Caroline Farnoux, Laure Maury, Thomas Schmitz, Suonavy Khung and Olivier Baud

Pediatrics 2011;128:e458; originally published online July 11, 2011;
DOI: 10.1542/peds.2010-3557

Updated Information & Services	including high resolution figures, can be found at: http://pediatrics.aappublications.org/content/128/2/e458.full.html
References	This article cites 19 articles, 4 of which can be accessed free at: http://pediatrics.aappublications.org/content/128/2/e458.full.html#ref-list-1
Subspecialty Collections	This article, along with others on similar topics, appears in the following collection(s): Infectious Disease & Immunity http://pediatrics.aappublications.org/cgi/collection/infectious_disease
Permissions & Licensing	Information about reproducing this article in parts (figures, tables) or in its entirety can be found online at: http://pediatrics.aappublications.org/site/misc/Permissions.xhtml
Reprints	Information about ordering reprints can be found online: http://pediatrics.aappublications.org/site/misc/reprints.xhtml

PEDIATRICS is the official journal of the American Academy of Pediatrics. A monthly publication, it has been published continuously since 1948. PEDIATRICS is owned, published, and trademarked by the American Academy of Pediatrics, 141 Northwest Point Boulevard, Elk Grove Village, Illinois, 60007. Copyright © 2011 by the American Academy of Pediatrics. All rights reserved. Print ISSN: 0031-4005. Online ISSN: 1098-4275.

American Academy of Pediatrics

DEDICATED TO THE HEALTH OF ALL CHILDREN™

