Radboud Repository

Radboud University Nijmegen

PDF hosted at the Radboud Repository of the Radboud University Nijmegen

The following full text is a publisher's version.

For additional information about this publication click this link.
http://hdl.handle.net/2066/24511

Please be advised that this information was generated on 2022-08-23 and may be subject to change.

MR spectroscopy with short echo times. Radiology 1996;199: 805–810.
49. Tracey I, Carr C, Guimaraes A, Worth J, Navia B, Gonzalez R. Brain choline-containing compounds are elevated in HIV-positive patients before the onset of AIDS dementia complex: a proton magnetic resonance spectroscopic study. Neurology 1996;46:783–788.
50. Husted C, Goodin D, Hugg J, et al. Biochemical alterations in multiple sclerosis lesions and normal-appearing white matter detected by in vivo ^{31}P and ^{1}H spectroscopic imaging. Ann Neurol 1994;36:157–165.
51. Berger M, Mucke L. Prolonged survival and partial recovery in AIDS-associated progressive multifocal leukoencephalopathy. Neurology 1988;38:1060–1065.

A new leukoencephalopathy with vanishing white matter

M.S. van der Knaap, MD, PhD; P.G. Barth, MD, PhD; F.J.M. Gabreëls, MD, PhD; E. Franzoni, MD; J.H. Begeer, MD, PhD; H. Stroink, MD; J.J. Rotteveel, MD, PhD; and J. Valk, MD, PhD

Article abstract—We identified nine children with a leukoencephalopathy of similar type according to clinical and MRI findings. The patients included three affected sibling pairs. The age range was 3 to 19 years. The onset of the disease was in childhood; the course was both chronic-progressive and episodic. There were episodes of deterioration following infections and minor head traumas, and these could result in unexplained coma. In eight patients with advanced disease, MRI revealed a diffuse cerebral hemispheric leukoencephalopathy, in which increasing areas of the abnormal white matter had a signal intensity close to that of CSF on all pulse sequences. In one patient in the early stages of disease, initial MRI showed diffusely abnormal cerebral white matter, which only reached the signal characteristics of CSF at a later stage. In the patients in whom the disease was advanced, magnetic resonance spectroscopy (MRS) of the white matter showed an almost complete disappearance of all normal signals and the presence of glucose and lactate, compatible with the presence of mainly CSF and little brain tissue. Spectra of the cortex were much better preserved. However, in addition to the normal resonances, there were signals representing lactate and glucose. MRS of the white matter in the patient whose disease was at an early stage was much less abnormal. Autopsy in one patient confirmed the presence of extensive cystic degeneration of the cerebral white matter with reactive change and a preserved cortex. Typical involvement of pontine tegmental white matter was suggested by MRI and confirmed by autopsy. The disease probably has an autosomal recessive mode of inheritance, but the basic metabolic defect is not known.

NEUROLOGY 1997;48:845–855

There is a growing number of progressive encephalopathies identified and defined by enzyme defect, gene defect, or both.[1] MRI has contributed considerably to the detection of leukoencephalopathies,[2] but a significant proportion remains unclassified.[3] In some cases, MRI and magnetic resonance spectroscopy (MRS) findings are sufficiently distinct to be used as criteria for a classifying diagnosis.[4]

As part of an ongoing study of unclassified leukoencephalopathies, we identified nine patients with a distinct disorder, as defined by clinical and MRI criteria. We describe the clinical picture, metabolic investigations, and neurophysiologic studies, as well as MRI, MRS, and autopsy findings, and provide criteria for the diagnosis.

Methods. Clinical history, neurologic findings, biochemical tests, and neurophysiologic studies were documented.

All nine patients underwent MRI, six of them on two occasions. In all patients, T_1-weighted (T_1W), proton-density (PD), and T_2-weighted (T_2W) images were made. The images were evaluated for the localization and appearance of white-matter abnormalities and the presence of gray-matter lesions with the help of a standardized scoring list (see reference 5 for details).

Proton (^{1}H) MRS was performed in five patients (patients 3, 4, 5, 7, and 9) with the standard imaging head coil. We used single-voxel spectroscopy in order to achieve a high-quality assessment of the neurochemical composition of white matter versus cortex. A $2 \times 2 \times 2$ cm^3 voxel was chosen in the mid-occipital area, containing mainly occipital cortex of both hemispheres and some white matter and CSF. Another voxel of $2 \times 2 \times 2$ cm^3 was chosen in the parieto-occipital area, containing white matter and, at most, some ventricular CSF. The spectra were acquired with use of the PRESS sequence, with a repetition time of

From the Departments of Child Neurology (Dr. van der Knaap) and Diagnostic Radiology (Dr. Valk), Free University Hospital, Amsterdam; Departments of Pediatrics and Neurology (Dr. Barth), Emma Children's Hospital and Academic Medical Center, Amsterdam; Interdisciplinary Child Neurology Institute (Drs. Gabreëls and Rotteveel), Sint Radboud University Hospital, Nijmegen; Department of Child Neurology (Dr. Begeer), University Hospital, Groningen; Department of Child Neurology (Dr. Stroink), Sophia Children's Hospital and University Hospital, Rotterdam, The Netherlands; Dipartimento di Pediatria (Dr. Franzoni), Centro di Neurologia Pediatrica, Universita di Bologna, Bologna, Italy.

Received July 22, 1996. Accepted in final form October 10, 1996.

Address correspondence and reprint requests to Dr. M.S. van der Knaap, Department of Child Neurology, Free University Hospital, P.O. Box 7057, 1007 MB Amsterdam, The Netherlands.

Copyright © 1997 by the American Academy of Neurology

2,500 msec, echo times of 135 and 270 msec, and 128 acquisitions (see reference 6 for technical details), and the STEAM sequence, with a repetition time of 2,500 msec, an echo time of 20 msec, and 128 acquisitions (see reference 7 for technical details). Another procedure was used in patient 9 only. MR spectra were obtained from three 2 × 2 × 2 cm^3 voxels in the left frontal and left and right occipital white matter, with use of the PRESS sequence with an echo time of 135 msec. The averaged measurements were zero-filled to 2,048 data points, exponentially filtered to give 1-Hz line-broadening before fast-Fourier transformation. The spectra were quantified by peak area measurements with system software (Siemens SP 63). Ratios of concentrations of metabolites were calculated relative to creatine (Cr). We did not convert these ratios into "absolute" concentrations with the help of known Cr or tissue water concentrations, as, considering the extent of tissue damage and loss, all metabolites, including Cr, were probably considerably decreased and tissue water highly increased.

Autopsy was performed in patient 2. The brain and spinal cord were fixed in 4% formaldehyde. For histopathologic examination, paraffin sections were stained with hematoxylin-eosin, Luxol fast blue, Nissl, Sudan black, Kluver, and Bodian stain. In addition, immunostaining was performed for myelin basic protein (MBP), glial fibrillary acidic protein (GFAP), neurofilament, and neuron-specific enolase (NSE).

Results. *Clinical profiles.* The clinical data are summarized in table 1. A full description of two representative patients is presented below.

Patient 1 is a female, born in March 1987, first child of healthy, unrelated parents. Initial psychomotor development was normal. She could walk independently at the age of 15 months, but her gait was never quite stable. At the age of 2½ years, motor coordination deteriorated within the course of a few weeks. She stopped speaking. Recurrent vomiting occurred. Behavioral changes were present with irritability and screaming. The girl became apathetic, somnolent, and, finally, comatose. Over a period of a few months she made a partial recovery. The subsequent course of the disease was characterized by episodic deterioration following minor infections, usually of the upper respiratory tract, accompanied by fever. During these episodes, she sometimes had tonic-clonic seizures. On several occasions, the deterioration led to recurrent vomiting and lowering of consciousness. She died in November 1993 during her fourth coma, which followed a urinary tract infection with fever.

The neurologic findings in the course of her disease included normal eye movements, no nystagmus, prominent cerebellar ataxia, dysarthria, and some spasticity with brisk tendon reflexes and extensor plantar reflexes. She remained normocephalic. She developed optic atrophy at the age of 5 years. There was no clinical evidence of peripheral nerve involvement. Mental functions were better preserved than motor functions.

Patient 2 is the younger sister of patient 1, born in August 1989. Her psychomotor development was slightly retarded. She walked independently at the age of 2 years. Her gait was mildly unstable and gradually deteriorated within a matter of months. At the age of 2½ years, she fell off the couch and was unconscious for a few minutes. On regaining consciousness, her gait had become less stable. She recovered within a few weeks. Another fall from the couch 3 months later immediately resulted in decreased stability and loss of the ability to walk independently, which she never regained. The subsequent course of disease was characterized by chronic-progressive and sometimes stepwise deterioration of motor coordination and vision, but she did not suffer episodes of major deterioration or coma. She had infrequent epileptic seizures. In April 1995 she had a minor upper respiratory tract infection, which was followed by rapid deterioration and loss of motor function, frequent vomiting, epileptic seizures, and coma. She died in June 1995 after prolonged coma.

The neurologic findings in the course of her disease included normal eye movements, no nystagmus, severe cerebellar ataxia, and some spasticity with brisk tendon reflexes. Head circumference was normal. She developed optic atrophy at the age of 4 years. There was no clinical evidence of peripheral nerve involvement, and mental functions were relatively preserved.

Laboratory investigations. Many of the laboratory tests were performed only in the first of two affected siblings within one family.

In all patients, routine blood tests with assessment of liver function, renal function, glucose, capillary blood gases, calcium, and phosphate were normal. There was no evidence of an autoimmune disorder (patient 1). Lumbar puncture, performed either during an episode of coma or subcoma (patients 1, 3, 5, and 7) or in a period of relative stability (patients 2, 5, 6, 7, 8, and 9) revealed normal CSF protein level, cell count, glucose, IgG index, lactate, and pyruvate, and no evidence of oligoclonal banding. Some elevation of CSF lactate was found only in patients 3 and 7 during episodes of deterioration, but the level returned to normal as they improved. In patient 1, some elevation of CSF protein was found once during an episode of deterioration. CSF level of MBP was normal in patient 3 and elevated during a period of deterioration in patient 7, returning to normal after clinical improvement. CSF GABA (patient 2) and 5-HIAA and HVA (patients 3 and 7) were normal. Active infection with *Borrelia burgdorferi* (patients 1 and 7), neurotropic viruses (patients 1, 3, 7, and 8), and *Mycoplasma pneumoniae* (patients 3 and 7) was excluded by analysis of blood and CSF. Vitamin B_1, B_2 (patient 1), B_{12} (patients 1 and 7), folic acid (patient 7), and vitamin E levels (patients 1 and 6) were normal. No evidence of thyroid dysfunction (patients 1, 3, 6, and 7), adrenal dysfunction (patients 3, 5, 6, and 7), or gonadal dysfunction (patient 3, age 19 years) was found. Serum levels of copper and ceruloplasmin were normal (patients 1, 3, 6, and 7). Metabolic screening of a 24-hour sample of urine, with assessment of amino acids, organic acids, oligosaccharides, monosaccharides, disaccharides, mucopolysaccharides, purines, and pyrimidines, was normal in all patients, with the exception of patient 5 (see below). Amino acids in plasma were normal. Serum levels of ammonia, lactate, pyruvate, acetoacetate, 3-hydroxybutyrate, and carnitine were normal in all patients with the exception of patient 7 (see below). Transferrin focusing of blood samples revealed a normal subfraction distribution (patients 3, 4, and 7). Assessment of lysosomal enzymes in leukocytes, in particular arylsulfatase A, galactocerebroside β-galactosidase,

Table 1 Clinical history and present findings

Patient	1	2	3
Sex	F	F	F
Affected sibling	No. 2	No. 1	No. 4
Unaffected siblings	0	0	0
Consanguinity of parents	–	–	–
Present age (yr)	Died at 6½	Died at 6	19
Age at 1st MRI (yr)	3	2	14
Age at 2nd MRI (yr)	4½	–	18
Initial motor development	n	Mild delay	n (clumsy)
Walking (mo)	15 (unstable)	24 (unstable)	15
Initial mental development	n	n	n
Onset of motor deterioration (yr)	2½	2½	5
Loss of walking (yr)	2½	2¾	12
Type of deterioration			
Episodic	+	+	+
Chronic	+	+	+
Comas	4	1	1
Provoking factors			
Infections	+	+	+
Head traumas	–	+	–
Epilepsy	+	+	–
Motor signs			
Ataxia	++	++	+
Spasticity	+	+	+
Mental capacities	Rel. better	Rel. better	Rel. better
Optic atrophy	Late	Late	–
Head circumference	n	n	98%
Abnormalities internal organs	–	–	–

* Preceding epileptic status during fever at 11 and 21 months.

n = normal; Rel. = relatively.

4	5	6	7	8	9
M	F	M	M	F	M
No. 3	–	–	–	No. 9	No. 8
0	2	0	0	2	2
–	+	–	–	–	–
16	12	Died at 2½	9	Died at 4	3
11	9	2	6	4	2
15	12	–	9	–	2¾
n	n	n	Mild delay	n	n
16	11	14 (unstable)	24 (unstable)	? (n)	12
Mild delay in speaking	Mild delay in speaking	n	Mild delay in speaking	n	n
5	2½	1½	3	1¾	2¾*
Walks with aid	2½	2	4	2½	3
–	+	+	+	+	+
+	+	+	+	+	+
0	4	1	7	0	0
–	+	+	+	–	+
–	–	+	+	+	+
–	+	–	+	+	+
+	+	++	++	+	++
+	++	++	++	++	±
Rel. better	Rel. better	Rel. better	Rel. better	Rel. better	Rel. better
–	Late	Late	–	–	–
98%	n	n	90%	n	n
–	–	–	–	–	–

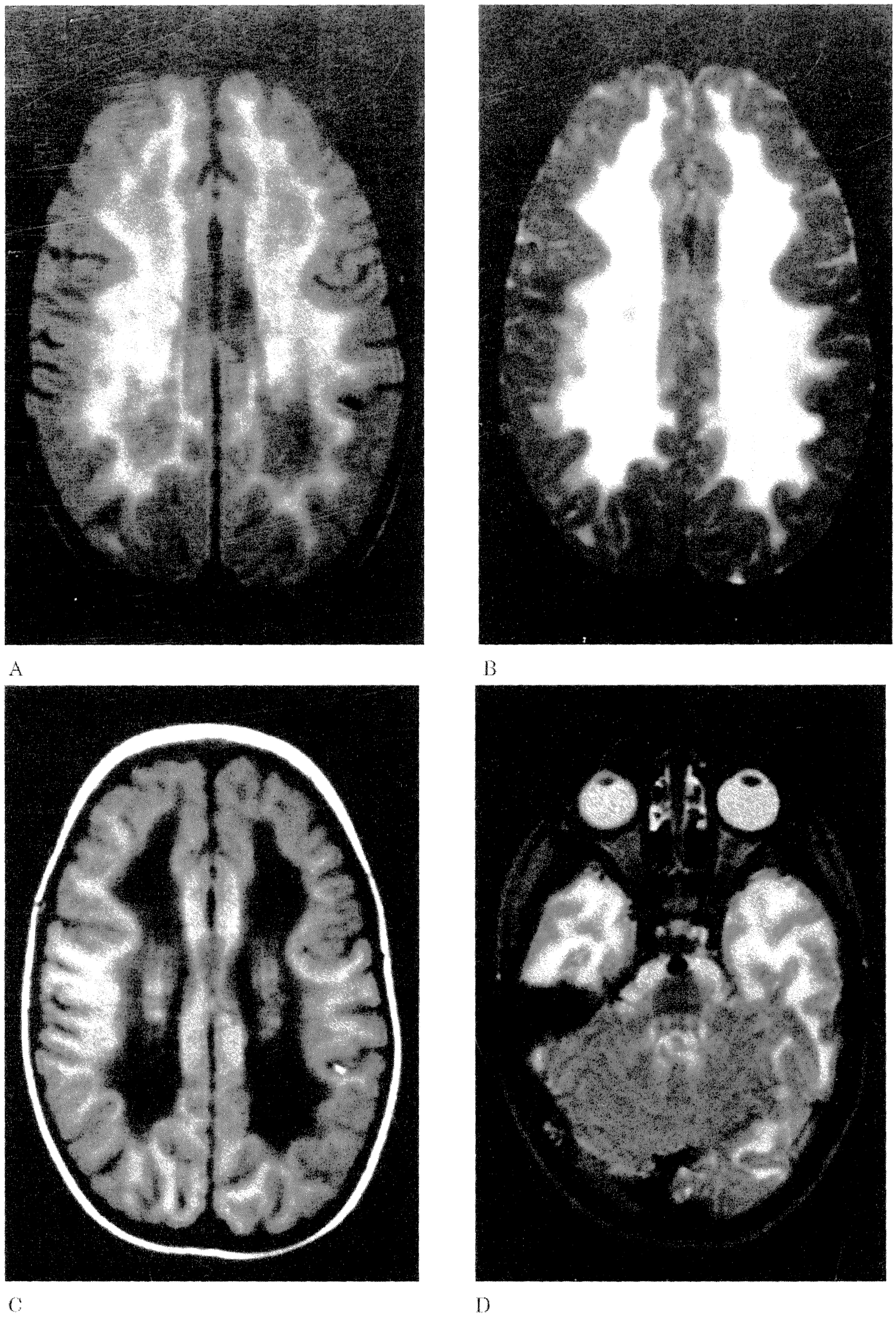

Figure 1. MR images of patient 2, at the age of 2 years, soon after the onset of first signs. Shown are PD (A), T_2W (B), and T_1W (C) transverse images through the centrum semiovale, and a T_2W image through the level of the pons (D). Almost all hemispheric white matter has an abnormal signal intensity, with the exception of part of the arcuate fibers (C). On PD images (A), the signal intensity of the abnormal white matter is partly low and partly high and on T_2W images (B) homogeneously high. In the pontine tegmentum, two high-signal-intensity dots are present (D).

acid β-galactosidase, and β-hexosaminidase, produced normal results in all patients. Electron microscopy of white blood cells showed no evidence of storage. Screening for peroxisomal disorders with assessment of very long-chain fatty acids, phytanic acid, pristanic acid, pipecolic acid, and cholic acids in blood was normal in all patients. Glucose tolerance testing indicated a normal glucose and pyruvate response (patients 1 and 3). Sural nerve biopsy (patient 3) revealed no abnormalities, in particular no evidence of dys- or demyelination. Light microscopy and electron microscopy of muscle biopsy tissue revealed no abnormalities, especially no evidence of ragged red fibers (patients 2, 3, and 7). Mitochondrial function, assessed in fresh mitochondria isolated from muscle tissue, was normal in patients 2 and 3. In patient 5, assays in fibroblasts showed normal ATP synthesis and normal presence of respiratory chain complexes. Analysis of mitochondrial DNA, isolated from muscle tissue (patient 2) or white blood cells (patient 9), revealed no abnormalities.

In patient 5, a minor elevation of ethylmalonic acid was repeatedly found in urine (2 to 6 mmol/mol creatinine; normal, <0.2 mmol/mol creatinine). The ethylmalonic acid excretion did not change significantly during protein load or fasting. Ammonia levels remained normal during protein load. During fasting, serum glucose, lactate, pyruvate, and urinary excretion of organic acids and dicarboxylic acids remained normal. The short-chain, medium-chain, and long-chain acyl-CoA dehydrogenases assessed in fibroblasts according to Coates et al.[8] were normal. Hence, despite the consistent mild elevation of ethylmalonic-acid ex-

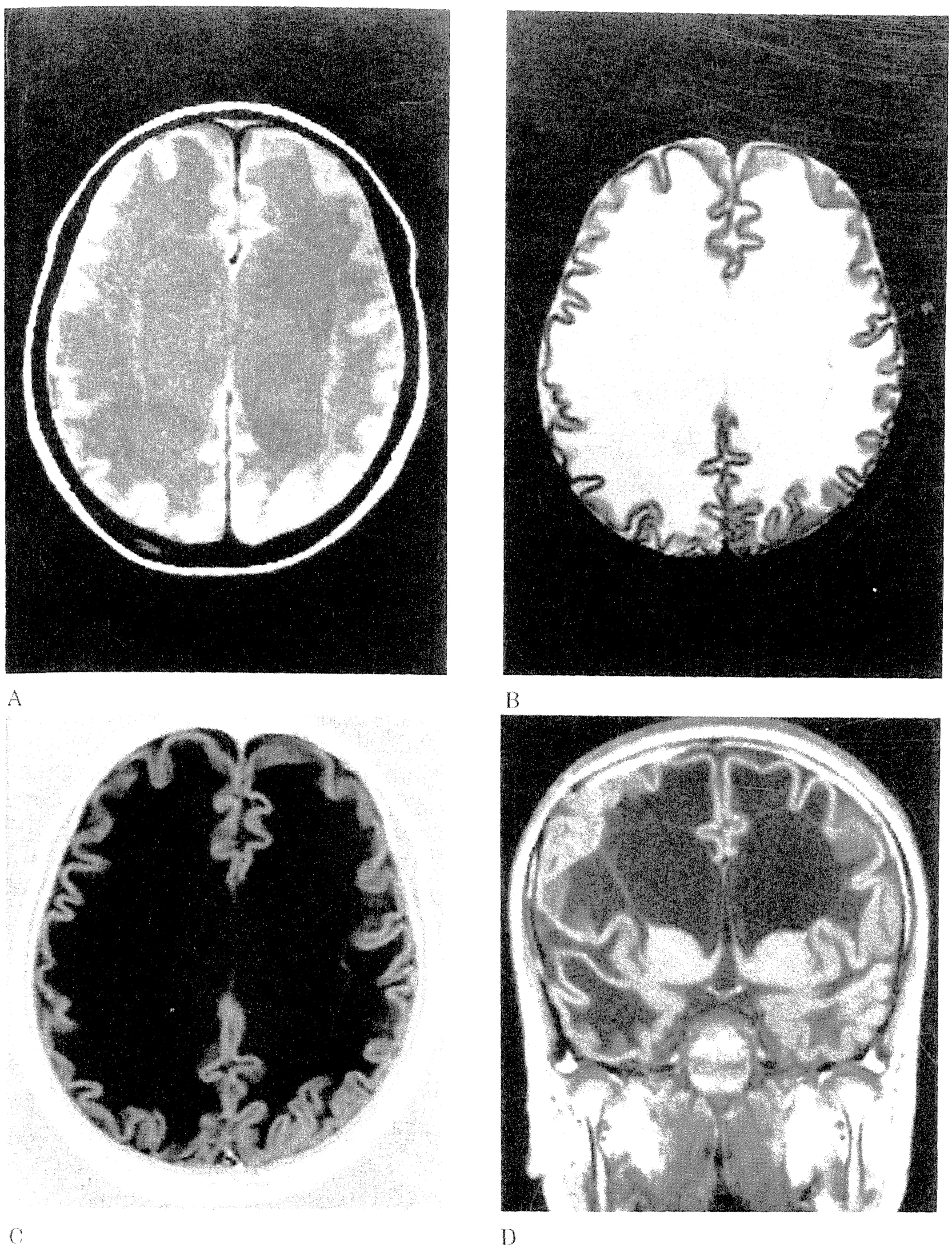

Figure 2. MR images of patient 5 at the age of 12 years. Shown are PD (A), T_2W (B), and T_1W (C) transverse images, and a coronal T_1W image (D). The ventricular lining is visible, separating CSF from the white matter. The white matter has the same signal intensity as CSF on all sequences. The white matter appears mildly swollen with some broadening of gyri. The internal capsule and basal nuclei are spared (D).

cretion, fatty-acid oxidation and respiratory-chain defects could be ruled out.

In patient 7, some elevation of serum and urine acetoacetate and 3-hydroxybutyrate was found repeatedly during a period of deterioration. Ketone bodies were normal outside these periods. During fasting, a considerable increase in ketone bodies was found in the presence of normal lactate, pyruvate, glucose, blood gases, free fatty acids, cholesterol, and triglycerides. A defect in ketolysis was suspected, but known defects in ketolysis were excluded by enzyme analysis.

Neurophysiology. Neurophysiologic studies were performed repeatedly in patients 1, 3, 5, 6, 7, 8, and 9. Sensory and motor nerve conduction were normal in all patients, as was the electroretinogram. The EEG results depended on the stage of the disease. They were normal in the early stages, outside the periods of deterioration. During periods of deterioration, generalized slowing, irregularities of the background rhythm, sharp waves, and spike-wave complexes were observed. These abnormalities became permanent as the disease progressed. Somatosensory, visual, and brain stem auditory evoked responses were initially normal, but as the disease progressed they became delayed, their amplitude decreased, and they eventually disappeared.

Magnetic resonance imaging. The ages at which the first and second MRIs were performed are mentioned in table 1, so that the MRI findings can be related to the duration and course of the disease in individual patients. In all patients, the cerebral hemispheric white matter was diffusely and symmetrically involved with only some sparing of the arcuate fibers in patients 2, 4, 6, and 9 (figure 1C). The abnormal white matter had a homogeneous high signal intensity on heavily T_2W images. However, the signal intensity was either partially high and partially low or homogeneously low on PD images (figures 1A and 2A). On T_1W images, the signal intensity of the abnormal white matter was low (figures 1C and 2C). Therefore, the signal intensity of part or all of the cerebral hemispheric white matter resembled that of CSF on all pulse sequences. In fact, in several patients, the ventricular CSF seemed to merge with the abnormal white matter with no clear bor-

Table 2 ^1H *MRS findings, as obtained from the cortex voxel*

		PRESS 135 spectra		STEAM 20 spectra		
	Age (yr)	NAA/Cr	Cho/Cr	NAA/Cr	Cho/Cr	mIno/C
Patient						
3	18	1.45	0.67	1.32	0.58	0.60
4	15	1.57	0.83	1.45	0.70	0.52
5	12	1.35	0.79	1.23	0.69	0.58
7	9	1.25	0.85	1.18	0.76	0.62
Control						
1	8	1.72	0.73	1.57	0.59	0.64
2	12	1.76	0.68	1.50	0.54	0.59
3	17	1.70	0.70	1.63	0.59	0.68

der. In other patients, the ventricular lining was quite clear, whereas all or most of the white matter was otherwise indistinguishable from CSF (see figure 2). In some patients, a fine meshwork of residual strands of brain tissue was seen in the areas of CSF-like white matter (figure 1A).

Only the first MRI of patient 9, obtained before the development of somatic neurologic abnormalities, was different. The cerebral white matter had a homogeneous high signal intensity on both PD and T_2W images. Repeat MRI obtained after onset of somatic neurologic deterioration showed that parts of the cerebral white matter now had a lower signal intensity on PD images, close to that of CSF.

In most patients, the white matter appeared mildly swollen with some broadening of gyri, particularly in patient 5 (see figure 2). The lateral ventricles were mildly to moderately enlarged in patients 3, 4, and 5, but they were normal in the others. The inner rim of the corpus callosum was involved in all patients except patient 3, whereas the outer rim of the corpus callosum was spared in all but patient 5. The posterior limb of the internal capsule was affected in patients 1, 5, 7, and 8; the anterior limb was spared in all patients. The signal intensity of the cerebellar white matter was mildly elevated in all patients on both PD and T_2W images. All patients except number 9 had some cerebellar atrophy, particularly involving the vermis. Both cerebellar vermis and hemispheres were highly atrophic in patient 5, who also showed atrophy of the brain stem. A striking finding in all patients except numbers 3 and 5 consisted of two symmetrical high signal intensity dots in the pontine tegmentum on PD and T_2W images (figure 1D). Pyramidal tracts in pons and mesencephalon were involved in patients 1, 3, 4, and 9. A cavum septi pellucidi and cavum vergae of variable size were present in all but patients 8 and 9. No signal abnormalities were seen in gray-matter structures.

On follow-up, MRI was unchanged in patient 4, showed an increase in CSF-like white-matter areas in patients 1, 3, 7, and 9, and showed an increase in cerebellar atrophy in patients 1, 5, and 7.

Magnetic resonance spectroscopy. In patients 3, 4, 5, and 7, MRS was performed when the disease was in an advanced stage. The spectroscopic findings were similar.

Well-defined spectra were obtained from the voxel containing mainly cortex (table 2). The PRESS spectra, obtained with an echo time of 135 msec, showed a decreased *N*-acetylaspartate (NAA, 2.02 ppm) and a normal or slightly elevated choline level (Cho, 3.21 ppm) relative to Cr (3.02 ppm). An inverted doublet was seen centered at 1.33 ppm with a 7-Hz spin-spin splitting. With use of an echo time of 270 msec, the doublet was again in the upright position, confirming it to be lactate. Minor signals were consistently seen at 3.56 ppm (*myo*-inositol, mIno) and at 3.43 and 3.8 ppm (interpreted as glucose). The STEAM spectra, obtained with an echo time of 20 msec, confirmed the decrease in NAA and the normal or mildly elevated level of Cho relative to Cr (figure 3). The relative level of mIno was in the normal or low-normal range. In patients 3 and 5, very high additional resonances were seen at 1.33, 3.43, and 3.8 ppm (see figure 3); in patients 4 and 7, these peaks were also present, but they were lower.

Only minor resonances were obtained from the white-matter voxel in all four patients (figure 4). The peaks of NAA, Cho, Cr, and mIno were just discernible within the noise. A small lactate doublet was visible at 1.33 ppm. The STEAM spectra obtained with an echo time of 20 msec showed small additional resonances at 3.43 and 3.80 ppm.

In patient 9, white-matter spectra were obtained soon after the onset of neurologic deterioration and revealed well-defined peaks of near-normal height. Relative to Cr, NAA was mildly decreased and Cho mildly increased. No evidence of elevated resonances at 1.33, 3.43, and 3.8 ppm was found.

Histopathologic findings. In the case of patient 2, a full autopsy was performed. An extensive bronchopneumonia with alveolar hemorrhage and edema was found to have affected both lungs. Some hepatic steatosis was present. There were bilateral streak ovaria. Otherwise, body autopsy findings were unremarkable.

Brain weight was 1,224 grams. External examination of the fixed brain revealed some swelling of the surface with flattening of gyri. No cingulate or hippocampal herniation or grooving was noted. Coronal sections of the brain revealed diffuse abnormality of the cerebral hemispheric white matter, which was partly gelatinous and partly cystic (figure 5). A fine meshwork of residual tissue strands was observed within some of the cystic areas. Cerebral cortex, basal nuclei, thalami, brain stem, and cerebellar white matter were macroscopically preserved.

On microscopic examination, the cerebral cortex appeared almost entirely normal with normal neuronal ar-

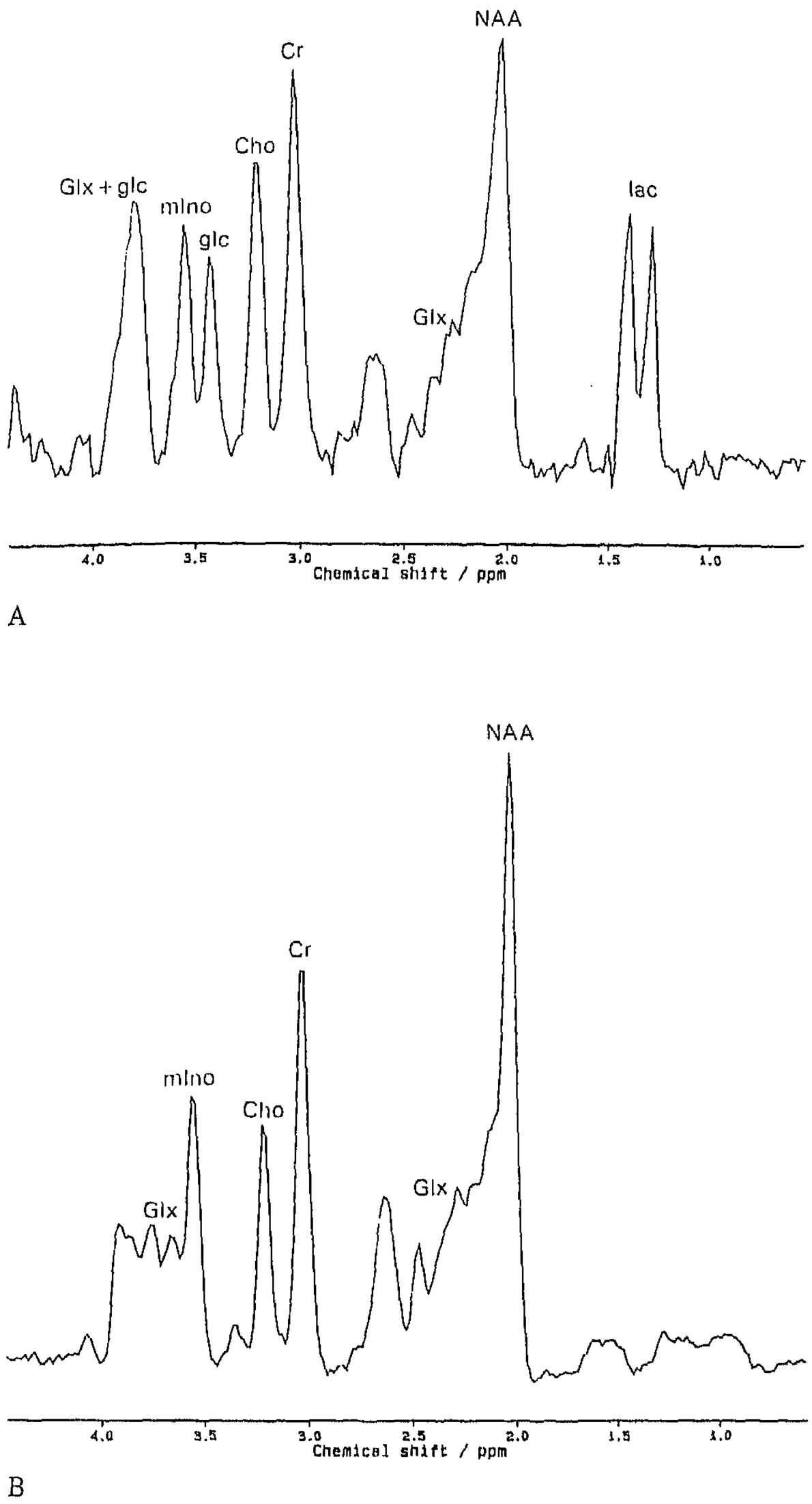

Figure 3. STEAM 20 spectra of patient 5 (A) and a normal control (B), obtained from a cortex voxel. Note that in the patient NAA is mildly decreased and Cho is mildly increased relative to Cr. There is a high lactate (lac) doublet. Note the highly elevated resonances at 3.43 and 3.80 ppm, representing glucose (glc), with a contribution of glutamine/glutamate (Glx) at 3.80 ppm.

chitecture and lamination. The cerebral white-matter abnormalities started immediately under the cortex, although in some areas the U-fibers were partially preserved and contained myelin. The white matter between the ependymal layer and the U-fibers was largely destroyed, with cystic degeneration progressing from frontal to occipital. The integrity of the white matter was best preserved in the temporal areas. In those areas of white matter that were not completely cystic, there was diffuse and severe loss of myelin with spongy alterations (figure 6A). MBP staining was positive in the lining of vacuoles and in many thin fibers. In addition, axonal loss, reactive astrocytosis (figure 6B), and macrophage infiltration were

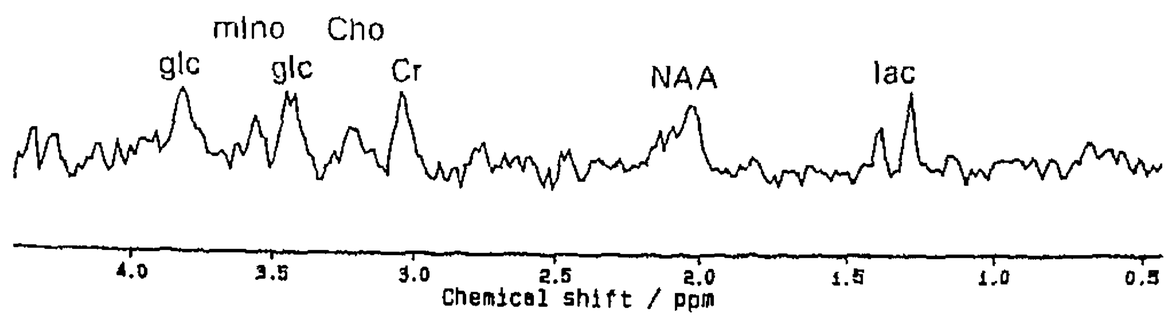

Figure 4. STEAM 20 spectrum of patient 5, obtained from a white-matter voxel. Only minor resonances are discernible at 1.33 ppm (lactate doublet, lac), 2.02 ppm (NAA), 3.02 ppm (Cr), 3.22 ppm (Cho), 3.43 ppm (glucose, glc), 3.56 ppm (mIno), and 3.80 ppm (glucose, glc).

present in these areas. Numerous large fibrous astrocytes were seen with large extensions (GFAP-positive). Macrophages contained punctate, weakly PAS-positive material. There was a decrease in the number of oligodendrocytes.

Areas that were less severely affected were the corpus callosum, anterior commissure, optic tract, internal capsule, and intrinsic fibers of the thalami. In the caudate nucleus, the number of large neurons was decreased. Otherwise, the basal nuclei were normal. In the mesencephalon, the cerebral peduncles were intact. In the pons, the volume of the longitudinal fibers was decreased, but there was no myelin loss. The ventral trigeminothalamic tract and, in particular, the central tegmental tract were severely affected at the level of the pons (figure 7). Within the central part of the cerebellar white matter, there were areas of myelin loss, but the myelin density within the foliae was normal. The dentate nucleus was normal, but the hilus of the dentate nucleus was demyelinated. Myelin paucity was also observed in the hilus of the inferior olives, the pyramids, the spinothalamic tracts, and the corpus restiforme. Myelin density was normal in the peripheral part of cranial nerves. In the spinal cord, the posterior columns were best preserved, though not completely. Myelin density was decreased in the spinocerebellar tracts, the lateral and anterior corticospinal tracts, and the anterolateral fascicles containing the spinoreticular and spinothalamic tracts.

Discussion. *Disease entity.* The clinical pictures of the patients and the findings at MRI and MRS are strikingly similar. The more severe end of the clinical spectrum is represented by patients 1, 2, 6, and 8, who died after an illness lasting several years. Patients 3 and 4 represent the more benign form, having severe neurologic handicap after many years of illness. Patients 5 and 7 represent an intermediate severity with end-stage neurologic handicap after illness lasting a considerable number of years. Clinically, the disease is a white-matter disorder with prominent ataxia, spasticity, relatively better preserved mental capacities, and no or mild epilepsy. Optic atrophy may develop, but not always and not early. The course of disease is chronic-progressive, with episodes of deterioration initiated by minor infections and minor head traumas. There was no evidence of seizure activity or onset of neurologic deterioration preceding a minor head trauma in any of the patients. There was never evidence of brain damage directly related to the trauma, in particular no evidence of intracranial blood on the MRI performed

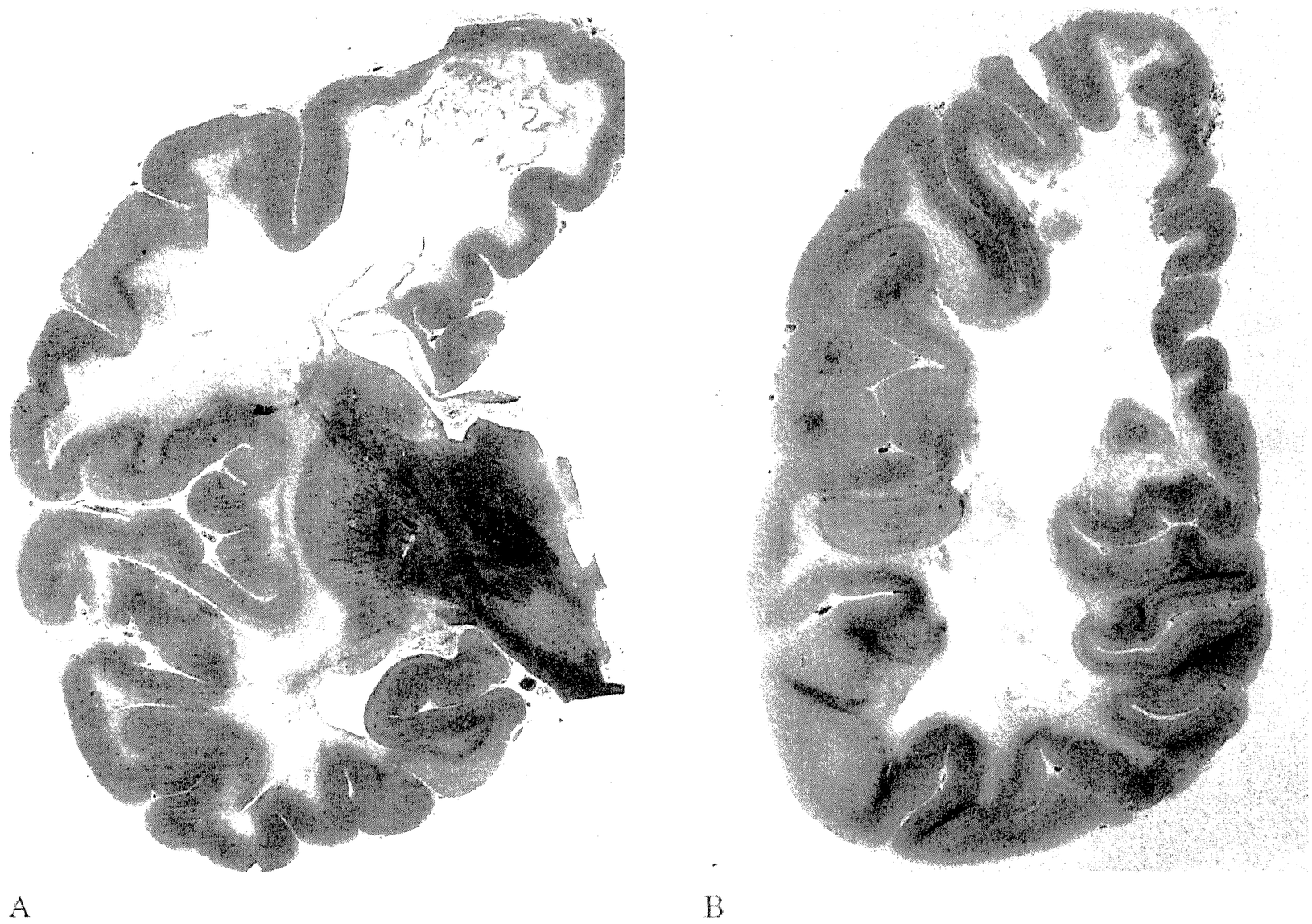

Figure 5. Coronal sections of the right cerebral hemisphere show the severe destruction of the hemispheric white matter (A and B). In some areas, the U-fibers are spared. The myelin of the medullary laminae, cerebral peduncle, and internal capsule is spared (A). (Luxol fast blue stain)

because of a deterioration following a trauma. The deterioration is often accompanied by lethargy and may result in unexplained coma. During the episodes of deterioration, vomiting is frequently present. Recovery is slow and incomplete.

MRI findings are characteristic. The usual finding in leukoencephalopathies of any origin, be it demyelination, hypomyelination, or white-matter gliosis, is that the affected white matter has a high signal intensity on both PD and T_2W images.[5,9] It is highly unusual for abnormal white matter to have a low signal intensity on PD images, similar to CSF. In our patients, at least certain areas of the cerebral hemispheric white matter are indistinguishable from or closely resemble CSF on all sequences.

MRS findings are also characteristic. White-matter spectra show only minor "normal" resonances and small additional resonances at 1.33, 3.43, and 3.8 ppm. Cortex spectra show much better preserved "normal" peaks and, in addition, variably prominent "extra" peaks at 1.33, 3.43, and 3.8 ppm.

Previous publications. There are previous less-detailed descriptions of similar patients. In 1976, Deisenhammer and Jellinger[10] described autopsy findings of a severe cystic leukoencephalopathy in a girl who had a progressive ataxic-spastic disease



Figure 6. Microscopic section of subcortical (upper part) and deep frontal white matter (lower part); myelin basic protein stain; marker bar = 140 μm (A). The subcortical white matter is better preserved than the deep white matter. Vacuolar changes can be observed. GFAP stain of the frontal section (B; marker bar = 350 μm) shows an increase in reactive glial cells in the white matter adjacent to the cortex (upper part of the photograph).

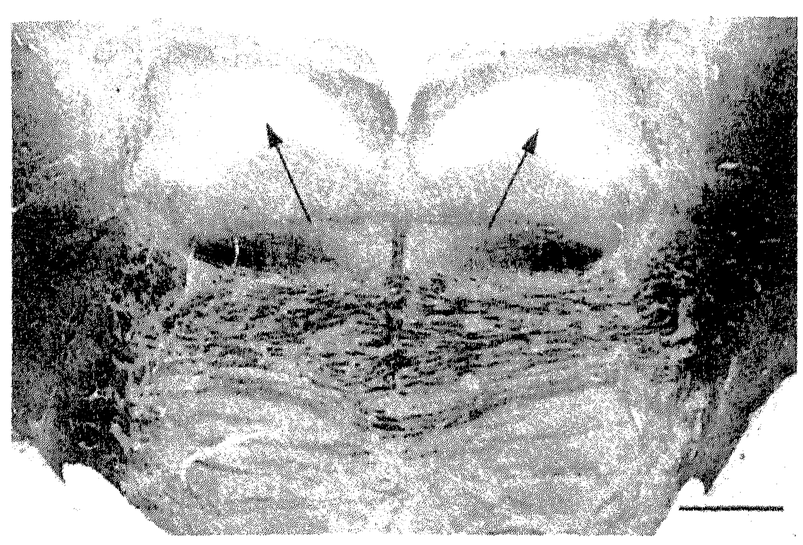

A

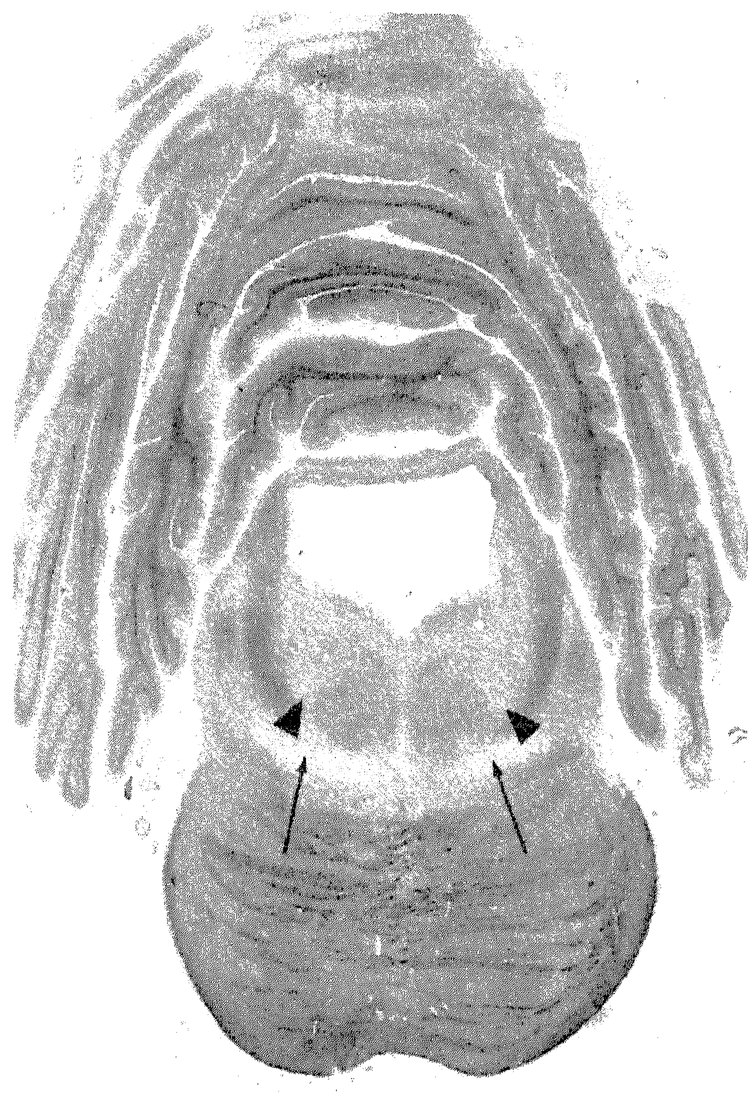

B

Figure 7. A transverse section of the pons at the level of the middle cerebellar peduncles (A) shows well-defined bilateral lesions in the central tegmental tracts (arrows). A transverse section through the upper part of pons and cerebellum (B) shows a sharply delimited band of myelin loss bilaterally and immediately dorsal to the medial lemniscus, corresponding to the ventral trigeminothalamic tracts (arrows). The myelin loss in the central tegmental tracts is just visible (arrowheads). Luxol fast blue stain; marker bar (in A) = 2.63 mm.

with episodic course, including periods of lowered consciousness and seizures. In 1993, Hanefeld et al.[11] described three similar patients. One of them repeatedly experienced deterioration following mild head traumas. Deterioration following infections was not mentioned. The authors did not discuss the distribution and signal characteristics of the severe cerebral white-matter abnormalities on MRI, but it is apparent from the images published that the signal intensity of the white matter follows that of CSF on different pulse sequences, and that the white matter has a mildly swollen appearance with some broadening of gyri. Short-echo-time (20 msec) white-matter spectra were similar to ours with disappearance of all normal signals and presence of minor resonances at 1.33, 3.43, and 3.8 ppm, interpreted as lactate and glucose; gray-matter spectra were not reported. In 1994 and 1995, Schiffmann et al.[12] and Tedeschi et al.[13] described six patients with a similar clinical picture. Two sibs had episodic deterioration following infections.[13] The MR images published showed diffuse, homogeneous abnormality of the cerebral hemispheric white matter on T_2W images.[12,13] PD images were not described or shown.[12,13] With MRS, there was a marked decrease in NAA, Cho, and Cr in long-echo-time (272 msec) spectra of the white matter, whereas gray-matter spectra were almost normal. Lactate was present in three of the six patients.[13] Resonances at 3.43 and 3.8 ppm were not present, but might have been if the investigators had used a short echo time.

Differentiation from other leukoencephalopathies. The disease presented here can be differentiated from other white-matter disorders of unknown origin on the basis of clinical and MRI characteristics. MRS findings are also helpful. The combination of hemispheric white-matter abnormalities with a swollen appearance and cystic degeneration of the periventricular white matter is reminiscent of Alexander's disease.[14] However, constant features of Alexander's disease are macrocephaly, non-episodic deterioration, a fronto-occipital gradient in white-matter changes, and Rosenthal fibers on histologic examination,[14] not present in our patients. The extensive hemispheric white-matter abnormalities, the mildly swollen appearance, and the complete or relative sparing of central structures, including internal capsule, basal ganglia, and brain stem, are also suggestive of another leukoencephalopathy, recently described by Van der Knaap et al.[4] However, in the latter disease,[4] the children become very macrocephalic from infancy onwards; the course of the disease is mild; MRI invariably shows cysts in the frontoparietal and anterior-temporal subcortical areas and a high signal intensity of the white matter on PD images, unlike CSF; MR spectra do not show an elevation of glucose or lactate.

In patient 2, postmortem investigation revealed streak ovaria. None of the previously reported patients[10-13] had ovarial dysgenesis or dysfunction. Progressive cerebellar ataxia with hypogonadism (Holmes' type ataxia) is usually associated with central hypogonadism, a later onset of neurologic dysfunction, milder course, and usually no white-matter abnormalities.[15,16] The significance of the ovarian finding in patient 2 is not known. In patient 4, normal menstrual bleeding and normal levels of luteinizing hormone and follicle-stimulating hormone were present at the age of 19 years.

Morphologic substrate and basic defect. The basic defect of the disease is unknown. Since three pairs of siblings were affected and one patient had consanguineous parents, autosomal recessive inheritance is probable.

Patient 9 underwent his first MRI before onset of somatic neurologic deterioration, and patient 4 un-

derwent CT at the age of 2 years in the presymptomatic stage. In both patients, extensive cerebral white-matter abnormalities were already present. The abnormal white matter had a high signal intensity on both T_2W and PD images. MRI obtained in patient 9 immediately after onset of somatic neurologic deterioration showed that part of the abnormal white matter now had a lower signal intensity on PD images, though not yet as low as CSF, whereas in his severely affected elder sister, part of the white matter was indistinguishable from CSF. Clinical deterioration in the patients was not associated with more extensive white-matter abnormalities, as is the case in the "common" demyelinating disorders, but with larger areas of already abnormal white matter becoming CSF-like. The MRI findings would be compatible with primary hypomyelination of the cerebral hemispheric white matter, with subsequent degeneration and disappearance of all structures within the white matter, and replacement by CSF. The progressive cerebellar atrophy, associated with the clinical deterioration, occurs in most disorders characterized by cerebral neurodegeneration and is not specific.

MRS findings suggest that the cortex is relatively well preserved. The mild decrease in NAA suggests some neuronal damage and loss.[17] In addition, a doublet was centered at 1.33 ppm, representing lactate, and two resonances at 3.43 and 3.8 ppm, interpreted as glucose.[18,19] With glycogen, there should have been additional resonances.[20,21] Elevation of cortical lactate and glucose probably has pathophysiologic significance, but is unexplained. We have not observed similar changes in other demyelinating or neuronal degenerative disorders. White-matter spectra contained only minor "normal" signals originating from remnants of brain tissue, and small "extra" resonances representing lactate and glucose, which are normally present in CSF. The white-matter spectra are consistent with the presence of mainly CSF and little brain tissue.

Histopathology demonstrated an extensively cavitating leukoencephalopathy. The white matter between the ependyma and U-fibers had largely disappeared and was replaced by CSF. In some areas, there was a meshwork of residual tissue strands. In areas where the white matter structure was relatively better preserved, signs of myelin loss, spongy degeneration, astrogliosis, and macrophage proliferation and activation were present. On the basis of these histopathologic findings, we cannot determine whether there was initial hypomyelination, but there was definitely a component of active demyelination. Based on two brain biopsies, Schiffmann et al.[12] concluded that the myelin paucity was a consequence of both hypomyelination and demyelination. This conclusion would be compatible with our MRI and autopsy findings.

Diagnostic criteria. We propose the following criteria for diagnosis of this disease:

(1) Initial psychomotor development is normal or only mildly delayed.

(2) Early-childhood onset of neurologic deterioration with episodic and chronic progressive course. Episodes of deterioration may follow infection and minor head trauma. Deterioration may lead to lethargy or coma.

(3) Neurologic signs mainly consist of cerebellar ataxia and spasticity. Optic atrophy may develop but is not obligatory. Epilepsy may occur, but is not prominent. Mental abilities are relatively better preserved than motor functions.

(4) MRI indicates symmetrical involvement of the cerebral hemispheric white matter; part or all of the white matter has a signal intensity similar to CSF on PD, T_2W, and T_1W images. Cerebellar atrophy varies from mild to severe and primarily involves the vermis.

The diagnosis can be made on the basis of these four obligatory criteria. MRS can be used as additional evidence for the disease. White-matter ^1H MR spectra resemble CSF spectra, showing the presence of only some lactate and glucose, and the lack of most or all normal signals. Cortex spectra maintain a more normal appearance, apart from variably elevated lactate and glucose.

These criteria may not allow a definite diagnosis in a presymptomatic or early symptomatic stage of the disease, unless there is another child with a definite diagnosis within the family. However, until a diagnostic biochemical or DNA test is available, the diagnosis will eventually be reached with repeat MRI (and MRS). We initiated a linkage-analysis study to determine the possibility of a DNA-based diagnosis.

Acknowledgments

We are grateful to Dr. F.J.A.M. Holtus, pediatrician (Almelo), for referring patients 1 and 2, and to Dr. R.F.H.M. Tummers, pediatrician (Enschede), for referring patient 5. Dr. L. Naudin ten Cate, pediatric pathologist (Enschede), performed the body autopsy on patient 2. Dr. R. de Vos, neuropathologist (Enschede), kindly provided us the opportunity for histologic examination of brain and spinal cord. Dr. Vianey-Liaud, Hôpital Debrousse, Lyon, performed the assay of fatty acid oxidation in patient 5. Dr. B.D. Ross, Huntington Medical Research Institute, Pasadena, and P.C.M. van Zijl, Johns Hopkins University School of Medicine, Baltimore, gave their expert opinion on the spectroscopic findings. Dr. H.W. Moser, Kennedy Krieger Institute in Baltimore, kindly reviewed the manuscript. Lenie de Vries, secretary, was responsible for preparing the manuscript.

References

1. Scriver CR, Beaudet AL, Sly WS, et al., eds. The metabolic and molecular bases of inherited disease, vol I–III. New York: McGraw-Hill, 1995.
2. Van der Knaap MS, Valk J. Magnetic resonance in myelin, myelination, and myelin disorders. Berlin: Springer, 1995.
3. Boltshauser E, Martin E, Wichmann V, Valavanis A. Grenzen der Kernspintomographie aus neuropädiatrischer Sicht. Klin Neuroradiol 1993;3:79–82.
4. Van der Knaap MS, Barth PG, Stroink H, et al. Leukoencephalopathy with swelling and a discrepantly mild clinical course in eight children. Ann Neurol 1995;37:324–334.
5. Van der Knaap MS, Valk J, de Neeling N, Nauta JJP. Pattern recognition in magnetic resonance imaging of white-matter disorders in children and young adults. Neuroradiology 1991; 33:478–493.
6. Grodd W, Krägeloh-Mann I, Klose U, Sauter R. Metabolic and destructive brain disorders in children: findings with localized proton MR spectroscopy. Radiology 1991;181:173–181.

7. Frahm J, Michaelis T, Merboldt KD, Bruhn H, Gyngell ML, Hänicke W. Improvements in localized ^{1}H-NMR spectroscopy of human brain: water suppression, short echo times, and 1 ml resolution. J Magn Reson Imaging 1990;90:464–473.
8. Coates PM, Hale DE, Stanley CA, Corkey BE, Cortner JA. Genetic deficiency of medium-chain acyl coenzyme A dehydrogenase: studies in cultured skin fibroblasts and peripheral mononuclear leukocytes. Pediatr Res 1985;19:671–676.
9. Van der Knaap MS, Valk J. Non-leukodystrophic white matter changes in inherited disorders. Int J Neuroradiol 1995;1:56–66.
10. Deisenhammer E, Jellinger K. Höhlenbildende neutralfett-Leukodystrophie mit Schubverlauf. Neuropediatrics 1976;7: 111–121.
11. Hanefeld F, Holzbach U, Kruse B, Wilichowski E, Christen HJ, Frahm J. Diffuse white matter disease in three children: an encephalopathy with unique features on magnetic resonance imaging and proton magnetic resonance spectroscopy. Neuropediatrics 1993;24:244–248.
12. Schiffmann R, Moller JR, Trapp BD, et al. Childhood ataxia with diffuse central nervous system hypomyelination. Ann Neurol 1994;35:331–340.
13. Tedeschi G, Schiffmann R, Barton NW, et al. Proton magnetic resonance spectroscopic imaging in childhood ataxia with diffuse central nervous system hypomyelination. Neurology 1995;45:1526–1532.
14. Pridmore CL, Baraitser M, Harding B, Boyd SG, Kendall B, Brett EM. Alexander's disease: clues to diagnosis. J Child Neurol 1993;8:134–144.
15. De Michele G, Filla A, Striano S, Rimoldi M, Campanella G. Heterogeneous findings in four cases of cerebellar ataxia associated with hypogonadism (Holmes' type ataxia). Clin Neurol Neurosurg 1993;95:23–28.
16. De Michele G, Filla A, D'Armiento FP, et al. Cerebellar ataxia and hypogonadism. Clin Neurol Neurosurg 1990;92:67–70.
17. Van der Knaap MS, van der Grond J, Luyten PR, et al. ^{1}H and ^{31}P magnetic resonance spectroscopy of the brain in degenerative cerebral disorders. Ann Neurol 1992;31:202–211.
18. Gruetter R, Rothman DL, Novotny EJ, Shulman GI, Prichard JW, Shulman RG. Detection and assignment of the glucose signal in ^{1}H NMR difference spectra of the human brain. Magn Reson Med 1992;27:183–188.
19. Kreis R, Ross BD. Cerebral metabolic disturbances in patients with subacute and chronic diabetes mellitus: detection with proton MR spectroscopy. Radiology 1992;184:123–130.
20. Zang LH, Howseman AM, Shulman RG. Assignment of the ^{1}H chemical shifts of glycogen. Carbohydr Res 1991;220:1–9.
21. Zang LH, Rothman DL, Shulman RG. ^{1}H NMR visibility of mammalian glycogen in solution. Proc Natl Acad Sci USA 1990;87:1678–1680.

Peripheral neuropathy associated with sicca complex

Ian A. Grant, MD; Gene G. Hunder, MD; Henry A. Homburger, MD; and Peter J. Dyck, MD

Article abstract—Peripheral neuropathy occurs in Sjögren's syndrome, a disorder in which systemic immunologic phenomena, including vasculitis, are common. Neuropathy also occurs with isolated sicca complex (keratoconjunctivitis sicca and xerostomia); whether this represents a distinct syndrome is unclear. We retrospectively studied 54 patients with sicca complex and peripheral neuropathy to determine mode of presentation, neuropathic patterns, frequency and pattern of serologic abnormalities, and frequency of systemic disease, including necrotizing vasculitis. Peripheral neuropathy was the presenting problem in 87%. Although sicca symptoms occurred in 93%, they were a presenting complaint in only 11% and were usually mild, reported only after specific inquiry. Minor salivary gland biopsy was positive in 73%. Sensory neuropathies strongly predominated; 61% of patients manifested either sensory polyneuropathy or polyganglionopathy. Less common patterns included sensorimotor polyneuropathy (17%) and polyradiculoneuropathy (11%). Vasculitic neuropathy was demonstrated in only two patients, but nonspecific epineurial inflammation was present in 70% of nerve biopsies. Clinical evidence of systemic disease was uncommon, particularly in the sensory polyganglionopathy group, in whom extraglandular features other than weight loss occurred in only 1 of 12 patients. Antibodies to extractable nuclear antigens, the most specific serologic marker of Sjögren's syndrome, were present in 10.4%. We conclude that peripheral neuropathy and isolated sicca complex form a distinctive syndrome in which neuropathy is the presenting feature and sicca is easily overlooked; sensory polyneuropathy and polyganglionopathy predominate; serology is confirmatory but very insensitive; and extraglandular disease, including vasculitis, is uncommon compared with typical Sjögren's syndrome. Tests of ocular or salivary involvement are needed for diagnosis, and demonstration of inflammation in biopsied nerve is supportive. Improved definition of this disorder should permit further studies of natural history and efficacy of immunotherapy.

NEUROLOGY 1997;48:855–862

Peripheral neuropathy occurs in Sjögren's syndrome (SS), a chronic autoimmune disorder of exocrine glands.[1-5] The central feature of SS is the sicca complex (xerophthalmia and xerostomia) related to mononuclear infiltration and destruction of lacrimal and salivary glands. However, SS is a systemic dis-

From the Peripheral Neuropathy Research Center (Drs. Grant and Dyck), Division of Rheumatology (Dr. Hunder), and Department of Laboratory Medicine (Dr. Homburger), Mayo Clinic, Rochester, MN.

Supported in part by funds from a center grant from the National Institute of Neurological Diseases and Stroke (14304).

Received July 19, 1996. Accepted in final form August 26, 1996.

Address correspondence and reprint requests to Dr. P.J. Dyck, Mayo Clinic, 200 1st Street S.W., Rochester, MN 55905.

Copyright © 1997 by the American Academy of Neurology