

A NEW ORAL LOW-CARBOHYDRATE ALCOHOL LIQUID DIET PRODUCING LIVER LESIONS: A PRELIMINARY ACCOUNT

KAI O. LINDROS* and HARRI A. JÄRVELÄINEN

National Public Health Institute, Alcohol Research Center, POB 719, 00101 Helsinki, Finland

(Received 9 December 1997; in revised form 9 February 1998; accepted 9 February 1998)

Abstract — Male Wistar rats were administered a modified, but nutritionally adequate, ethanol liquid diet with a low content of carbohydrate (5.5% of energy). The high daily intake of ethanol (mean 12.9 g/kg body wt) resulted in consistently sustained elevation of diurnal blood ethanol levels (mean 40.3 ± 14.9 mmol/l, corresponding to 180 mg/dl). Marked micro- and macrovesicular panlobular steatosis, occasional inflammatory foci and a threefold elevation of serum alanine aminotransferase activity developed in 6 weeks. In livers from rats on regular 11% carbohydrate diet, lesions beyond periportal located steatosis were rare. These observations suggest that oral administration of a low-carbohydrate liquid ethanol diet may provide an affordable alternative to the technically demanding intragastric feeding model for experimental studies of alcoholic liver disease.

INTRODUCTION

Much effort has been undertaken to develop a reproducible and manageable rodent model to study factors initiating the development of alcohol liver disease. By the inclusion of ethanol into a nutritionally adequate liquid diet, the daily ethanol intake could be enhanced (Lieber *et al.*, 1965). However, although daily ethanol intake of animals on this diet approached their elimination capacity, the liver lesions observed were restricted to the development of fatty infiltration (Lieber *et al.*, 1965; Lieber and DeCarli, 1989). In 1985 the intragastric ethanol liquid diet feeding model was introduced (Tsukamoto *et al.*, 1985a). With this model, sustained high ethanol levels were obtained and progressive steatosis was accompanied by the development of focal inflammation and necrosis (Tsukamoto *et al.*, 1985a), especially when a diet rich in polyunsaturated fatty acids was used (Nanji *et al.*, 1989, 1995). However, such liver lesions were not found in one laboratory using the intragastric ethanol liquid diet feeding model (Badger, 1997). For some time, the reason for this discrepancy remained unclear. Recent studies by this latter author strongly suggested that the development of liver lesions is related to the

amount of carbohydrate in the diet, i.e. a low carbohydrate content provokes the development of lesions (Badger, 1997). This interpretation is supported by earlier data indicating the importance of the amount of dietary carbohydrate in the development of experimental alcoholic liver disease (Rao and Larkin, 1984).

The notion that a low-carbohydrate/high-fat ethanol diet provokes the development of liver lesions prompted us to investigate whether such lesions would appear also after oral administration of a similarly composed diet. This communication describes our preliminary data, suggesting that new avenues may be opened in studies of mechanisms of alcohol-induced liver damage after oral ethanol feeding.

MATERIALS AND METHODS

Male Wistar rats were individually housed in stainless steel wire cages. Equicaloric normal-carbohydrate (NC) and low-carbohydrate (LC) ethanol and control diets were pair-fed for 6 weeks. During the first week, the amount of ethanol in the diet was gradually increased to 5% (w/w). In preliminary experiments, the commercially available nutritionally adequate Lieber-DeCarli liquid diet (Lieber and DeCarli, 1982) (LD 101A; Purina Mills, Richmond, IN, USA) was given. This diet (NC diet in this paper)

*Author to whom correspondence should be addressed.

Table 1. Basic composition of the normal- (NC = Lieber-DeCarli) and low-carbohydrate (LC) diets

| Diet | Caloric contribution (% of components) | | | | | |
|-------------|--|-----------------|--------------|-----------------------|----------|---------|
| | Protein | Fat | Carbohydrate | Vitamins ^a | Minerals | Ethanol |
| NC, control | 18 | 35 | 47 | LD | LD | 0 |
| NC-ethanol | 18 | 35 | 11 | LD | LD | 36 |
| LC, control | 16 | 44 ^b | 40 | LD | LD | 0 |
| LC-ethanol | 16 | 44 | 5.5 | LD | LD | 34.5 |

^aAll diets were supplemented with vitamins and minerals to give the same composition as in the original diet of Lieber and DeCarli (1982).

^bAdditional fat (corn oil) was added to normal NC diet (consisting of olive, safflower and corn oil).

contains 11% of the calories as carbohydrates (dextromaltose), 36% as ethanol (or 47% carbohydrate for controls), 18% as protein (casein) and 35% as fat (olive, safflower and corn oil) (Table 1). In subsequent experiments, this diet was modified by reducing the content of carbohydrate to 5.5%. For technical reasons, the content of protein of this diet was slightly lower (16%). A diet containing 16% protein is nutritionally adequate according to feeding regimes for the laboratory rat (National Research Council, 1978). The amount of fat was increased correspondingly, by addition of an equicaloric amount of corn oil. Casein (technical grade; Sigma, St Louis, MO, USA), vitamins and minerals were added to equal the composition of the NC diet (Table 1). In addition, 0.4% carboxymethylcellulose (CMC; Metsa Specialty Chemicals Oy, Äänekoski, Finland) was added as a stabilizer to increase viscosity. The metabolically inert CMC is widely used as a thickener in a variety of dairy and other food industry products. Diet intake was recorded daily and weight gain twice a week. Tail-vein blood samples (50 µl) were taken from rats on the NC diet at 09:00, and from rats on the LC diet on four different days at 06:00, 12:00, 18:00 and 24:00. Blood ethanol concentration was determined by head-space gas chromatography (Hu *et al.*, 1995).

After 6 weeks of treatment, the animals were anaesthetized with sodium pentobarbital (60 mg/kg *i.p.*). Heart blood was taken, livers were perfused *in situ* with saline, removed and samples taken into buffered formalin for histopathology. Serum alanine aminotransferase (ALAT, EC 2.6.1.2.) activity was determined using a commercial kit (Boehringer, GMBH, Mannheim, Germany). Light microscopy sections

stained with haematoxylin and eosin were graded for the degree of fatty change and inflammation according to Nanji *et al.* (1994). Ten fields were examined per liver. Steatosis was graded from 0 to 4, with 0 denoting no fat present and 4 denoting >75% of cells containing fat. Inflammation was graded as 1+ or 2+, respectively, if there was one focus or two or more foci per low power field.

The data are expressed as mean \pm SD ($n = 4-7$). Analysis of variance (ANOVA) or Student's *t*-test was used. For comparison of pathological scores, the Mann-Whitney test was used.

RESULTS

A number of studies based on the chronic administration of regular Lieber-DeCarli diet have been published. These studies have shown that the liver changes observed after chronic administration of this diet is restricted to steatosis (Lieber *et al.*, 1989). Our preliminary experiment confirmed these observations. When animals were given diet with only half the amount of carbohydrates, several interesting differences between the two diets were observed. The daily dietary intake of the NC and LC diets was approximately the same, as seen from the weight gain during the 6-week treatment period (Table 2). There was a tendency towards higher mean daily ethanol intake by rats on the LC diet (12.9 g/kg/day) as compared to rats on the NC diet (11.3 g/kg/day). This difference was reflected in a correspondingly slightly higher caloric intake by rats on the LC diet (237 \pm 34 kcal/kg/day) as compared to rats on the NC diet (183 \pm 40 kcal/kg/day). However, these differences are probably due to the somewhat lower starting weight of the LC rats and were not statistically significant. The NC diets differed

Table 2. Effects of chronic ethanol feeding in the normal- (NC) and low-carbohydrate (LC) liquid diets

| Group | Weight gain (g) (initial-final) | Ethanol intake (g/kg body wt per day) | Liver/body wt ratio (%) |
|-------------|---------------------------------|---------------------------------------|-------------------------|
| NC, control | 143 (298-441) | - | 3.2 ± 0.3 |
| NC-ethanol | 6 (304-400) | 11.3 ± 1.2 | 3.3 ± 0.2 |
| LC, control | 91 (246-337) | - | 3.4 ± 0.2 |
| LC-ethanol | 82 (220-303) | 12.9 ± 1.4 | 4.3 ± 0.4* |

* $P < 0.05$ for difference from the corresponding control group.

slightly also with respect to their content of protein (18 versus 16%) and ethanol (36 versus 34.5%). As stated in the Materials and Methods section, a diet containing 16% protein is nutritionally adequate, and therefore it is unlikely that the small differences in the protein and ethanol contents contributed to the observed differences between the diets. Interestingly, whereas ethanol in the NC diet had no significant effect on the relative liver weight, animals on the ethanol-LC diet were found to exhibit a significantly higher liver/body weight ratio ($P < 0.05$) compared to the corresponding controls.

The failure of the NC diet to initiate damage beyond steatosis has been attributed to the moderate and fluctuating blood ethanol levels. In this study blood samples from rats on the NC diet were taken only on one occasion, at 09.00. The average blood ethanol levels were 24.5 ± 15.0 mmol/l (corresponding to 110 mg/dl). In the next experiment with rats on the LC diet the diurnal fluctuation and the degree of ethanol intoxication were monitored by sampling during 4 consecutive days, at 06.00, 12.00, 18.00 and 24.00. All animals were found to be ethanol-

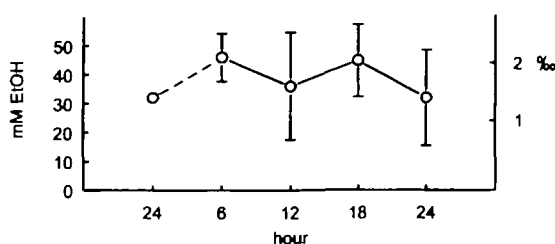


Fig. 1. Diurnal blood ethanol (EtOH) concentrations in rats during chronic oral intake of low-carbohydrate (LC) ethanol liquid diet.

Blood samples were taken from the tip of the tail on separate days at 6 h intervals. Data are expressed as mean ± SD, both in mmol/l (left-hand scale) and in promille (right-hand scale).

intoxicated throughout the 24 h period, the mean diurnal blood ethanol level being 40.3 ± 14.9 mmol/l (corresponding to 180 mg/dl; $P < 0.01$ as compared to the NC group) (Fig. 1). To our knowledge, such consistently elevated blood ethanol levels in rats consuming ethanol liquid diet have not been documented previously. The data also suggest that higher blood ethanol levels may be reached when combined with a low dietary carbohydrate content. Analysis of sera revealed that treatment with the LC-ethanol diet had induced a threefold increase in the activity of ALAT as compared to the controls ($P < 0.05$) (Fig. 2). No significant effect on ALAT activity was observed when ethanol was given to animals

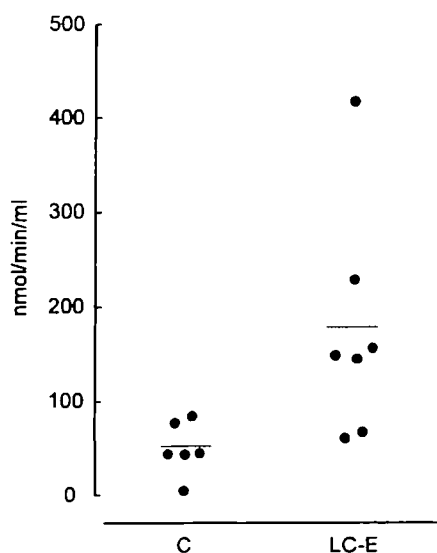


Fig. 2. Effect of ethanol administration in the low-carbohydrate (LC) diet on serum alanine aminotransferase activity.

C = control diet, LC-E = ethanol-containing low-carbohydrate diet. The effect of ethanol was significant ($P < 0.05$).

on the NC diet (results not shown).

Histopathological evaluation of liver specimens from rats fed the regular (NC) ethanol diet confirmed earlier observations (Lieber *et al.*, 1965; Rao and Larkin, 1984; Lieber and DeCarli, 1989) that rats receiving ethanol by this regimen only developed steatosis, which was mainly macro- but also microvesicular (Fig. 3a). The fatty lesion was characteristically restricted to the periportal region. No significant focal inflammation or necrosis was observed. The histopathological picture observed in livers of rats given ethanol in the new LC diet was markedly different. Massive steatosis, both macro- and micro- ('foamy') vesicular, had developed and it was panacinar, rather than periportal restricted (Fig. 3b,c). Occasionally, foci of inflammation were observed (Fig. 3b). The overall pathological score was significantly higher ($P < 0.01$) in livers of rats on the LC diet, as compared to rats on the NC diet (Fig. 4). This difference was due mainly to the more severe steatosis in LC rats (score 3.6 ± 0.7) compared to NC rats (1.8 ± 0.5 ; $P < 0.01$), but also to a tendency to more frequent focal inflammation in LC rats (0.8 ± 0.7) compared to NC rats (0.5 ± 0.6).

DISCUSSION

This study suggests that the chronic administration to rats of an ethanol-containing liquid diet low in carbohydrate but comparably high in unsaturated fatty acids results in distinctly different liver changes, as compared to those observed in this study and in numerous earlier studies based on the use of the regular diet with a normal content of carbohydrates. These data support recently presented results based on the intragastric feeding model, suggesting that by reducing the content of carbohydrate in the diet, alcohol-induced liver pathology is observed (Badger, 1997). This suggests that either the carbohydrate content by itself or the caloric carbohydrate/fat ratio is a crucial factor in the development of damage. In the new ethanol diet, the carbohydrate/fat ratio was 1:8, as compared to 1:3 in the regular diet.

It is well documented that ethanol-induced fatty infiltration is reduced when the dietary carbohydrate content is increased (Stanko *et al.*, 1978; Yonekura *et al.*, 1993). In addition, increasing the dietary carbohydrate/fat ratio reduces lipid peroxi-

dation and induction of P4502E1 (Nakajima *et al.*, 1992; Nanji *et al.*, 1994), both factors having been suggested to provoke the development of damage. A carbohydrate-free diet does not by itself produce any lesions (Lieber *et al.*, 1965), indicating that a relative lack of carbohydrates only becomes important in combination with chronic ethanol feeding. Since carbohydrates form the natural source for Krebs cycle intermediates and glycogen formation, a restricted carbohydrate intake may reduce the glycogen content of the liver, which will restrict anaerobic energy production via glycogenolytic ATP formation in situations of acute local hypoxia. Ethanol may in addition interfere with carbohydrate metabolism via its well-known inhibitory action on gluconeogenesis. Furthermore, chronic alcohol treatment sensitizes Kupffer cells to endotoxin activation (Järveläinen *et al.*, 1997), which stimulates the secretion of prostaglandin E_2 (PGE₂) (Qu *et al.*, 1996). Secretion of PGE₂ also stimulates glycogenolysis and could therefore contribute to local glycogen depletion. Enhanced oxygen radical formation as a consequence of production of lipid peroxides from unsaturated fatty acids may be another important confounding factor contributing to alcoholic liver disease. Indeed, polyunsaturated fat seems to be a prerequisite for lesions to develop, since their substitution with saturated fats prevents damage (Nanji *et al.*, 1995).

In this study we demonstrated that rats on the LC-ethanol diet had significantly higher blood ethanol levels than rats on the NC diet. Although these two separate experiments cannot be directly compared, the low carbohydrate content seems to be associated with elevated blood ethanol levels. In fact, when ethanol is administered together with carbohydrates, lowered blood ethanol levels have been observed, possibly as a consequence of accelerated hepatic metabolism and/or faster gastrointestinal absorption (Sankaran *et al.*, 1991; Yonekura *et al.*, 1993). Further experiments will be needed to evaluate the role of these factors in more detail. Our observation that the blood ethanol levels of animals fed on LC remained elevated 24 h per day may also be important. The blood ethanol levels approach those reported in animals fed ethanol diet by the intragastric feeding model, but in this model ethanol levels cycle with a characteristic 4-5 day frequency (Tsukamoto *et al.*, 1985b; Badger *et al.*, 1993). A corresponding

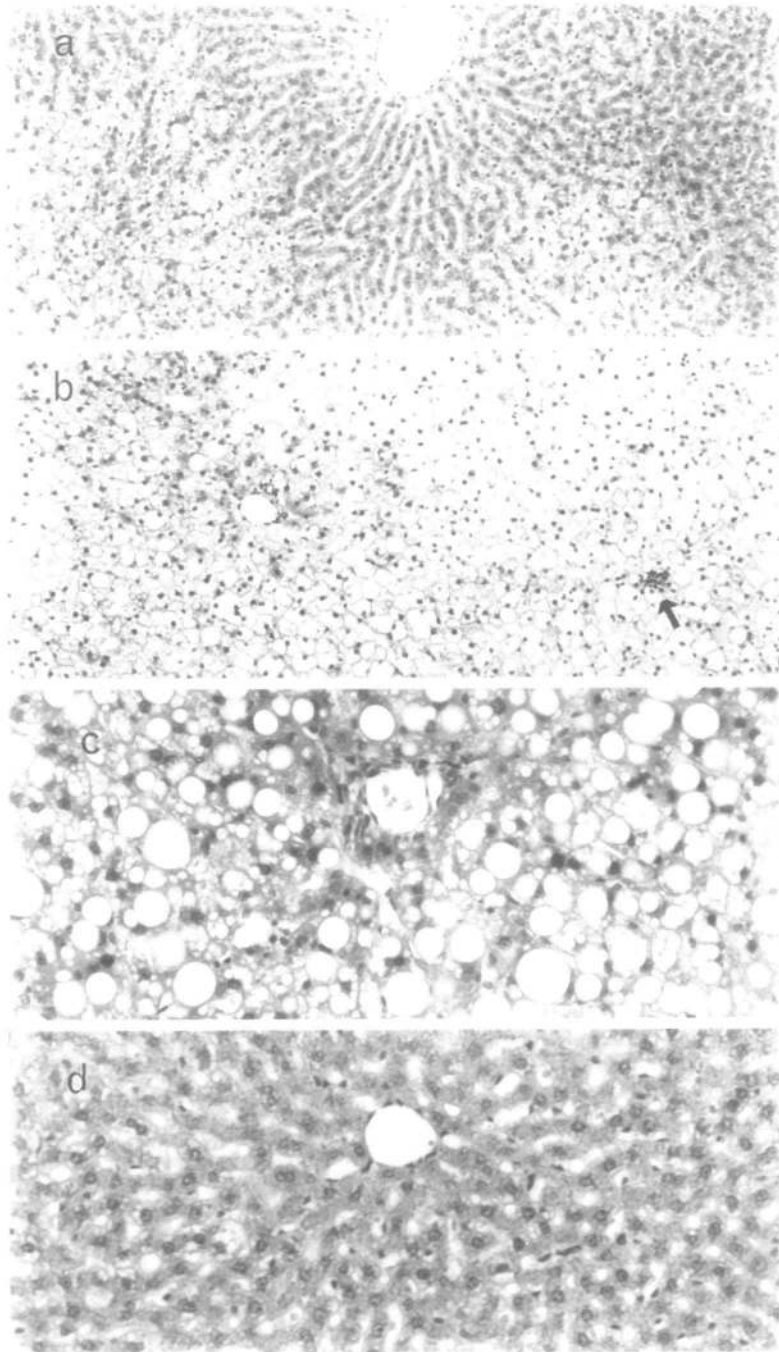


Fig. 3. Different histopathology of livers of rats fed ethanol with normal- (NC) or low-carbohydrate (LC) diet for 6 weeks.

Note the absence of fatty infiltration in the pericentral area of livers of rats on the NC diet (a), in contrast to the panlobular steatosis in livers of rats on the LC diet (b). A focal inflammation site is seen in the right-hand lower corner (arrow). The mixture of macro- and microvesicular steatoses in livers of rats on the LC diet is depicted in (c) (d) is from a control animal. Haematoxylin–eosin staining, $\times 24$ (a, b) and $\times 60$ (c, d).

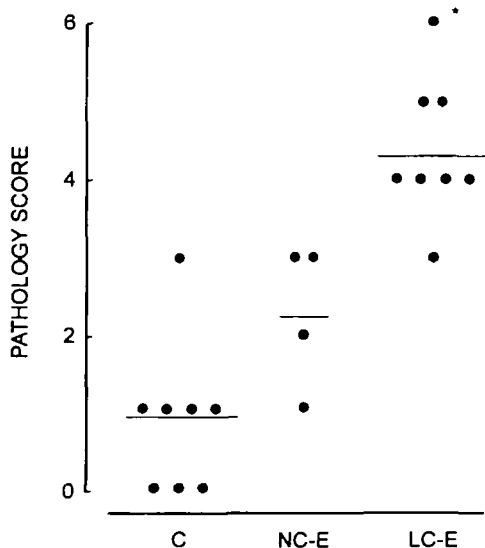


Fig. 4. Histopathological score of livers on normal- (NC) and low-carbohydrate (LC) ethanol diets and in controls.

Only pair-fed controls from rats on LC diet are shown, since there was no difference between NC and LC controls. The pathology score of ethanol-LC rats was significantly higher ($P < 0.01$) than that of ethanol-NC rats.

cycling has not been reported and is unlikely to occur after oral diet intake, but could be an important confounding pathogenetic factor. In the intragastric feeding model a positive correlation between the degree of steatosis and blood ethanol levels has been observed (Tsukamoto *et al.*, 1985a), but to what extent more severe liver lesions correlate to blood ethanol levels is not clear.

In summary, this preliminary account indicates that chronic oral feeding of ethanol in a low-carbohydrate but otherwise nutritionally adequate diet may offer an affordable alternative to the intragastric feeding model for rodent studies on basic pathogenic mechanisms of alcohol-induced liver damage. However, as this is a preliminary report, several questions remain unanswered and some effects need to be confirmed. For example, are the lesions observed in the low-carbohydrate animals related to higher blood ethanol levels, are the lesions worsened by further reducing the carbohydrate content; and will prolonged diet treatment lead to more severe damage? Is the blood ethanol cycling observed in the intragastric model a pathogenetic factor, that is not observed in

the oral model? To answer these questions, a larger study, based on different degrees of carbohydrate deficiency, on prolonged exposure to ethanol diet and on regular monitoring of ethanol intoxication and other physiological processes is presently being initiated.

Acknowledgements — We are indebted to Ms Gunilla Rönholm and Ms Han Jun for their help in the feeding experiments and to Dr Thomas Badger, University of Arkansas, for access to his preliminary data from experiments based on intragastric administration of a low-carbohydrate ethanol-supplemented diet.

REFERENCES

- Badger, T. M. (1997) The importance of nutritional factors for the development of alcohol-induced liver disease. *Alcohol and Alcoholism* **32**, 324.
- Badger, T. M., Ronis, M. J., Ingelman-Sundberg, M. and Hakkak, R. (1993) Pulsatile blood alcohol and CYP2E1 induction during chronic alcohol infusions in rats. *Alcohol* **10**, 453–457.
- Hu, Y., Ingelman-Sundberg, M. and Lindros, K. O. (1995) Induction mechanisms of cytochrome P450 2E1 in liver: interplay between ethanol treatment and starvation. *Biochemical Pharmacology* **50**, 155–161.
- Järveläinen, H. A., Oinonen, T. and Lindros, K. O. (1997) Alcohol-induced expression of the CD14 endotoxin receptor protein in rat Kupffer cells. *Alcoholism: Clinical and Experimental Research* **21**, 1547–1551.
- Lieber, C. S. and DeCarli, L. M. (1982) The feeding of alcohol in liquid diets: two decades of applications and 1982 update. *Alcoholism: Clinical and Experimental Research* **6**, 523–531.
- Lieber, C. S. and DeCarli, L. M. (1989) Liquid diet technique of ethanol administration: 1989 update. *Alcohol and Alcoholism* **24**, 197–211.
- Lieber, C. S., Jones, D. P. and DeCarli, L. M. (1965) Effects of prolonged ethanol intake: production of fatty liver despite adequate diets. *Journal of Clinical Investigation* **44**, 1009–1021.
- Lieber, C. S., DeCarli, L. M. and Sorrell, M. F. (1989) Experimental methods of ethanol administration. *Hepatology* **10**, 501–510.
- Nakajima, T., Ikatsu, H., Okino, T., Wang, R. S., Murayama, N., Yonekura, I. and Sato, A. (1992) Enhancement of ethanol-induced lipid peroxidation in rat liver by lowered carbohydrate intake. *Biochemical Pharmacology* **43**, 245–250.
- Nanji, A. A., Mendenhall, C. L. and French, S. W. (1989) Beef fat prevents alcoholic liver disease in the rat. *Alcoholism: Clinical and Experimental Research* **13**, 15–19.
- Nanji, A. A., Zhao, S., Lamb, R. G., Dannenberg, A. J., Sadrzadeh, S. M. and Waxman, D. J. (1994) Changes in cytochromes P-450, 2E1, 2B1, and 4A, and phospholipases A and C in the intragastric feeding rat model for alcoholic liver disease: relationship to

- dietary fats and pathologic liver injury. *Alcoholism: Clinical and Experimental Research* **18**, 902–908.
- Nanji, A. A., Sadrzadeh, S. M., Yang, E. K., Fogt, F., Meydani, M. and Dannenberg, A. J. (1995) Dietary saturated fatty acids: a novel treatment for alcoholic liver disease. *Gastroenterology* **109**, 547–554.
- National Research Council (1978) Nutrient requirements of the laboratory rat. In *Nutrient Requirements of Laboratory Animals*, 3rd rev. edn, no. 10, pp. 7–37. National Academy of Sciences, Washington, DC.
- Qu, W., Zhong, Z., Moritaka, G. and Thurman, R. G. (1996) Kupffer cell prostaglandin E₂ stimulates parenchymal cell O₂ consumption: alcohol and cell–cell communication. *American Journal of Physiology* **270**, G574–G580.
- Rao, G. A. and Larkin, E. C. (1984) Alcoholic fatty liver: A nutritional problem of carbohydrate deprivation and concomitant ethanol ingestion. *Nutrition Research* **4**, 903–912.
- Sankaran, H., Baba, G. C., Deveney, C. W. and Rao, G. A. (1991) Enteral macronutrients abolish high blood alcohol levels in chronic alcoholic rats. *Nutrition Research* **11**, 217–222.
- Stanko, R. T., Mendelow, H., Shinozuka, H. and Adibi, S. A. (1978) Prevention of alcohol-induced fatty liver by natural metabolites and riboflavin. *Journal of Laboratory and Clinical Medicine* **92**, 228–235.
- Tsukamoto, H., French, S. W., Benson, N., Delgado, G., Rao, G. A., Larkin, E. C. and Largman, C. (1985a) Severe and progressive steatosis and focal necrosis in rat liver induced by continuous intragastric infusion of ethanol and low fat diet. *Hepatology* **5**, 224–232.
- Tsukamoto, H., French, S. W., Reidelberger, R. D. and Largman, C. (1985b) Cyclical pattern of blood alcohol levels during continuous intragastric ethanol infusion in rats. *Alcoholism: Clinical and Experimental Research* **9**, 31–37.
- Yonekura, I., Nakano, M. and Sato, A. (1993) Effects of carbohydrate intake on blood ethanol level and alcoholic fatty liver damage in rats. *Journal of Hepatology* **17**, 91–101.