

# A New Rating Scale for Age-Related White Matter Changes Applicable to MRI and CT

L.O. Wahlund, MD, PhD; F. Barkhof, MD, PhD; F. Fazekas, MD; L. Bronge, MD; M. Augustin, MD; M. Sjögren, MD, PhD; A. Wallin, MD, PhD; H. Ader, PhD; D. Leys, MD, PhD; L. Pantoni, MD, PhD; F. Pasquier, MD, PhD; T. Erkinjuntti, MD, PhD; P. Scheltens, MD, PhD; on behalf of the European Task Force on Age-Related White Matter Changes

**Background and Purpose**—MRI is more sensitive than CT for detection of age-related white matter changes (ARWMC). Most rating scales estimate the degree and distribution of ARWMC either on CT or on MRI, and they differ in many aspects. This makes it difficult to compare CT and MRI studies. To be able to study the evolution and possible effect of drug treatment on ARWMC in large patient samples, it is necessary to have a rating scale constructed for both MRI and CT. We have developed and evaluated a new scale and studied ARWMC in a large number of patients examined with both MRI and CT.

**Methods**—Seventy-seven patients with ARWMC on either CT or MRI were recruited and a complementary examination (MRI or CT) performed. The patients came from 4 centers in Europe, and the scans were rated by 4 raters on 1 occasion with the new ARWMC rating scale. The interrater reliability was evaluated by using  $\kappa$  statistics. The degree and distribution of ARWMC in CT and MRI scans were compared in different brain areas.

**Results**—Interrater reliability was good for MRI ( $\kappa=0.67$ ) and moderate for CT ( $\kappa=0.48$ ). MRI was superior in detection of small ARWMC, whereas larger lesions were detected equally well with both CT and MRI. In the parieto-occipital and infratentorial areas, MRI detected significantly more ARWMC than did CT. In the frontal area and basal ganglia, no differences between modalities were found. When a fluid-attenuated inversion recovery sequence was used, MRI detected significantly more lesions than CT in frontal and parieto-occipital areas. No differences were found in basal ganglia and infratentorial areas.

**Conclusions**—We present a new ARWMC scale applicable to both CT and MRI that has almost equal sensitivity, except for certain regions. The interrater reliability was slightly better for MRI, as was the detectability of small lesions. (*Stroke*. 2001;32:1318-1322.)

**Key Words:** dementia ■ magnetic resonance imaging ■ rating scales  
■ tomography, x-ray computed ■ white matter

White matter changes (WMC) are defined as areas with high signal intensities on T2-weighted MRI and as areas with low attenuation on CT. The mechanisms for development of WMC are not fully understood, but several histopathologic correlates have been reported. These include enlarged perivascular (Virchow-Robin) spaces, as well as degeneration of myelin and axons with increased intracellular and extracellular water content, gliosis, and even infarction.<sup>1-10</sup>

The clinical significance of WMC has not been fully elucidated. There is a relationship between several cerebro-

vascular risk factors and the presence of WMC. One of the strongest risk factors, apart from hypertension, is that of age.<sup>11-13</sup> Henceforth, we will designate WMC as “age-related white matter changes” (ARWMC).

There is also evidence for a relationship between ARWMC and cognitive impairment in demented patients<sup>14-16</sup> as well as in healthy elderly individuals.<sup>13,17-19</sup> However, the extent of this association is still controversial. Little is known about the natural history of ARWMC, starting from their development to possibly subsequent progression. It is also unclear whether it is possible to affect the evolution of ARWMC with

Received October 23, 2000; final revision received January 18, 2001; accepted January 19, 2001.

From the Department of Clinical Neuroscience, NEUROTEC (L.O.W.), and Department of Radiology (L.B.), Karolinska Institutet at Huddinge University Hospital, Huddinge, Sweden; Departments of Radiology (F.B., P.S.) and Neurology (P.S.), Research Institute Neurosciences, Academisch Ziekenhuis Vrije Universiteit, Amsterdam, the Netherlands; Department of Neurology and MR Center, Karl-Franzens University (F.F. M.A.), Graz, Austria; Institute of Clinical Neuroscience, Section of Psychiatry, Göteborg University (M.S., A.W.), Mölndal, Sweden; Department of Clinical Epidemiology and Biostatistics, Faculty of Medicine, Vrije Universiteit (H.A.), Amsterdam, the Netherlands; Service de Neurologie Vasculaire, Hôpital Roger Salengro (D.L., F.P.), Lille, France; Department of Neurological and Psychiatric Sciences, University of Florence (L.P.), Florence, Italy; and Memory Research Unit, Department of Clinical Neuroscience, Helsinki University Central Hospital (T.E.), Helsinki, Finland.

Correspondence to L.O. Wahlund, MD, PhD, Department of Clinical Neuroscience, NEUROTEC, B 56, Huddinge University Hospital, S-141 86 Huddinge, Sweden. E-mail lars-olof.wahlund@neurotec.ki.se

© 2001 American Heart Association, Inc.

Stroke is available at <http://www.strokeaha.org>

pharmacological treatment and whether this would have any impact on cognitive performance or other tasks that require more complex cerebral processing, such as coordinated movement. The advent of MRI has focused attention on ARWMC due to the conspicuousness of such lesions on proton density (PD) and T2-weighted images, including fluid-attenuated inversion recovery (FLAIR). Also, the high sensitivity of this technique has increasingly brought into question the utility of CT for delineating ARWMC.

Given the possible effect of ARWMC on cognitive function in modern pharmacological antedementia treatment, there is a need for the evaluation of ARWMC. The degree and distribution of ARWMC are important in vascular dementia as well as in other dementia disorders, such as Alzheimer's disease. CT is less costly and more easily performed than MRI, and in many regions the number of MRI scanners is still limited. Several rating scales exist for visual rating of ARWMC on MRI scans.<sup>20</sup> Many of them are validated and widely used. Similarly, there are a number of rating scales for CT.<sup>20</sup> At present, there is only a single study in which the authors have attempted to design a scale applicable to both CT and MRI scans.<sup>5</sup> However, this scale, as designed by van Swieten, uses different criteria for CT and MRI scans, thus leading to different sensitivities for the respective modalities. It is therefore impossible to compare the results of different studies on ARWMC within and, even more so, between the 2 imaging modalities. By generating a combined CT-MRI ARWMC rating scale, we wanted to provide a tool for such between-modality comparison as well as to have an instrument for comparing the sensitivity for ARWMC and the reliability of their rating between CT and MRI.

Such a scale was developed under the auspices of the European Task Force on Age-Related White Matter Changes. In this study, we compared the regional sensitivity of MRI and CT for ARWMC within the same patient. The interobserver reliability of the new scale in both imaging techniques was also studied.

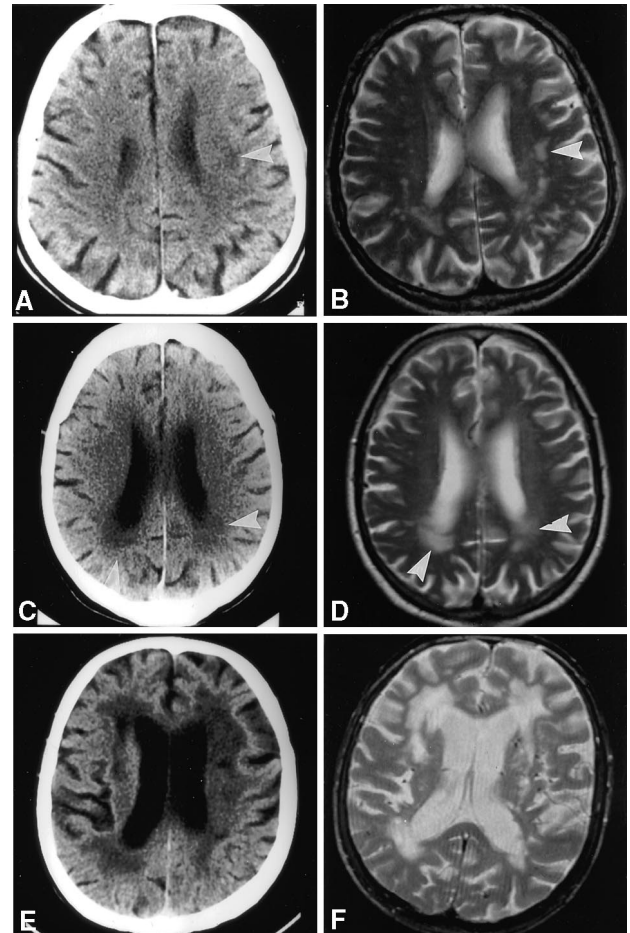
### Subjects and Methods

In the ARWMC scale, the degree of white matter changes is rated on a 4-point scale. Ratings were done on CT images by using standard hard copies and on MRI images on computer screen with either PD and T2-weighted images or T2 and FLAIR images. Examples of the different rating scores are shown in Figure 1.

White matter changes on MRI were defined as ill-defined hyperintensities  $\geq 5$  mm on both T2 and PD/FLAIR images, and on CT as ill-defined and moderately hypodense areas of  $\geq 5$  mm. Lacunes were defined as well-defined areas of  $>2$  mm with attenuation (on CT) or signal characteristics (on MRI) the same as cerebrospinal fluid. If lesions with these characteristics were  $\leq 2$  mm, they were considered perivascular spaces, except around the anterior commissure, where perivascular spaces can be large.

Changes in the basal ganglia were rated in the same way and considered white matter lesions even if located in the gray matter nuclei, which contains a small amount of white matter. The definitions of rating scores (0–3) are shown in Table 1.

Five different regions were rated in the right and left hemispheres separately: (1) the frontal area, which was the frontal lobe anterior to the central sulcus; (2) the parieto-occipital area, which consisted of the parietal and occipital lobes together; (3) the temporal area, which was the temporal lobe (the border between the parieto-occipital and temporal lobes was approximated as a line drawn from the posterior part of the Sylvian fissure to the trigone areas of the lateral



**Figure 1.** A through F, Examples of the rating scores 1, 2, and 3 from CT and MRI scans. Each pair of images (CT/MRI) refers to the same patient. The lesions are chosen from matching slices. Note that the slice angulation differs between CT and MRI (T2-weighted MRI images are shown). For a rating score of 1, a single lesion is clearly seen on CT (A) (see arrow); on MRI (B), additional lesions are rated as 2; rating score 2 is exemplified in C and D (see arrows); rating score 3 is shown in E and F.

ventricles); (4) the infratentorial area, which included the brain stem and cerebellum; and (5) the basal ganglia, which included the striatum, globus pallidus, thalamus, internal and external capsules, and insula.

All ratings were performed on one occasion at Huddinge Hospital. After a training session in which all 4 raters (F.B., L.B., M.A., and M.S.) together rated 10 cases, the raters were divided into pairs. Each pair of raters then evaluated MRI and CT scans from half of the cases. Within each pair, the 2 raters reached consensus. Interrater reliability values were calculated from a further series of rating both MRI and CT images from 20 patients, in which all 4 raters rated individually.

Previously acquired cerebral scans from 77 patients were used in this study. The patients had been examined at either Huddinge (n=20), Amsterdam (n=5), Lille (n=14), or Graz (n=38). They were included if ARWMC was noticed on a routine examination (on either MRI or CT) and when both MRI and CT had been performed no more than 3 months apart. We assume that no major alterations in the degree of white matter changes occurred during this time period. Patients with other gross pathological findings such as tumors, large bleedings, and recent territorial infarctions were excluded. We did not consider the final diagnosis or underlying risk factors in these patients; our only purpose was to compare ARWMC on MRI and CT scans. To simulate routine clinical conditions, we also did not advise

**TABLE 1. The ARWMC Rating Scale for MRI and CT**

White matter lesions	
0	No lesions (including symmetrical, well-defined caps or bands)
1	Focal lesions
2	Beginning confluence of lesions
3	Diffuse involvement of the entire region, with or without involvement of U fibers
Basal ganglia lesions	
0	No lesions
1	1 focal lesion ( $\geq 5$ mm)
2	>1 focal lesion
3	Confluent lesions

White matter changes on MRI were defined as bright lesions  $\geq 5$  mm on T2, PD, or FLAIR images. Lesions on CT were defined as hypodense areas of  $\geq 5$  mm; left and right hemispheres were rated separately.

The following brain areas were used for rating: frontal, parieto-occipital, temporal, infratentorial/cerebellum, and basal ganglia (striatum, globus pallidus, thalamus, internal/external capsule, and insula).

a common scanning protocol and we allowed the use of different machinery.

Different CT scanners were used. Slice thicknesses varied from 2.5 to 10 mm. The MRI equipment used operated at 1.0 T or 1.5 T, and T2/PD sequences were used as well as FLAIR. Slice thickness was 5 mm at all centers. All images were transferred to 1 center (Huddinge Hospital) on either digital media or as hard copies. These were then presented to the raters on either computer screen or viewing boxes.

The subsample ( $n=38$ ) of the study population that was imaged with the FLAIR technique was evaluated separately as well as together with the whole material ( $n=77$ ).

### Statistics

No descriptive data were available to perform power calculations. Therefore, type II errors could not be excluded for some comparisons.

The nonparametric sign test was used to compare visual ratings between MRI and CT. Weighted  $\kappa$  values were calculated as a measure of reproducibility:  $\kappa$  values  $<0.4$  indicated poor agreement, values from 0.41 through 0.6 indicated moderate agreement, values from 0.61 through 0.8 indicated good agreement, and  $\kappa$  values  $>0.81$  indicated excellent agreement.<sup>21</sup>

### Results

The means and standard deviations of the MRI and CT ratings in each separate area are shown in Table 2 (medians are not shown due to lack of variability). As expected, most lesions were found in the frontal and parieto-occipital regions. The distribution of the rating scores (sum of the right side and left side) according to brain region is presented in Figure 2. There was a size-dependent difference in the distribution of rating scores between MRI and CT. MRI detected more of the small ARWMC whereas CT was equal or superior in detecting larger lesions.

To address the relative detection capacity of each imaging modality, we compared in a pairwise fashion the MRI and CT and described them as either (1) MRI and CT scoring equal, (2) MRI scoring higher than CT, or (3) CT scoring higher than MRI. Few lesions were detected in the temporal areas, and therefore no comparison was made between MRI and CT in this region. The data are shown as a percentage of all rated

**TABLE 2. Rating Scores (Mean $\pm$ SD) According to Location and Modality**

Location	MRI	CT
Frontal		
L	0.97 $\pm$ 0.99	0.95 $\pm$ 1.12
R	0.97 $\pm$ 1.0	0.92 $\pm$ 1.10
Parieto-occipital		
L	1.20 $\pm$ 1.11	1.01 $\pm$ 1.21
R	1.17 $\pm$ 1.15	1.04 $\pm$ 1.12
Temporal		
L	0.23 $\pm$ 0.56	0.31 $\pm$ 0.63
R	0.24 $\pm$ 0.63	0.26 $\pm$ 0.69
Basal ganglia		
L	0.67 $\pm$ 1.05	0.67 $\pm$ 0.92
R	0.54 $\pm$ 0.94	0.52 $\pm$ 0.84
Infratentorial		
L	0.11 $\pm$ 0.36	0
R	0.26 $\pm$ 0.49	0.06 $\pm$ 0.24

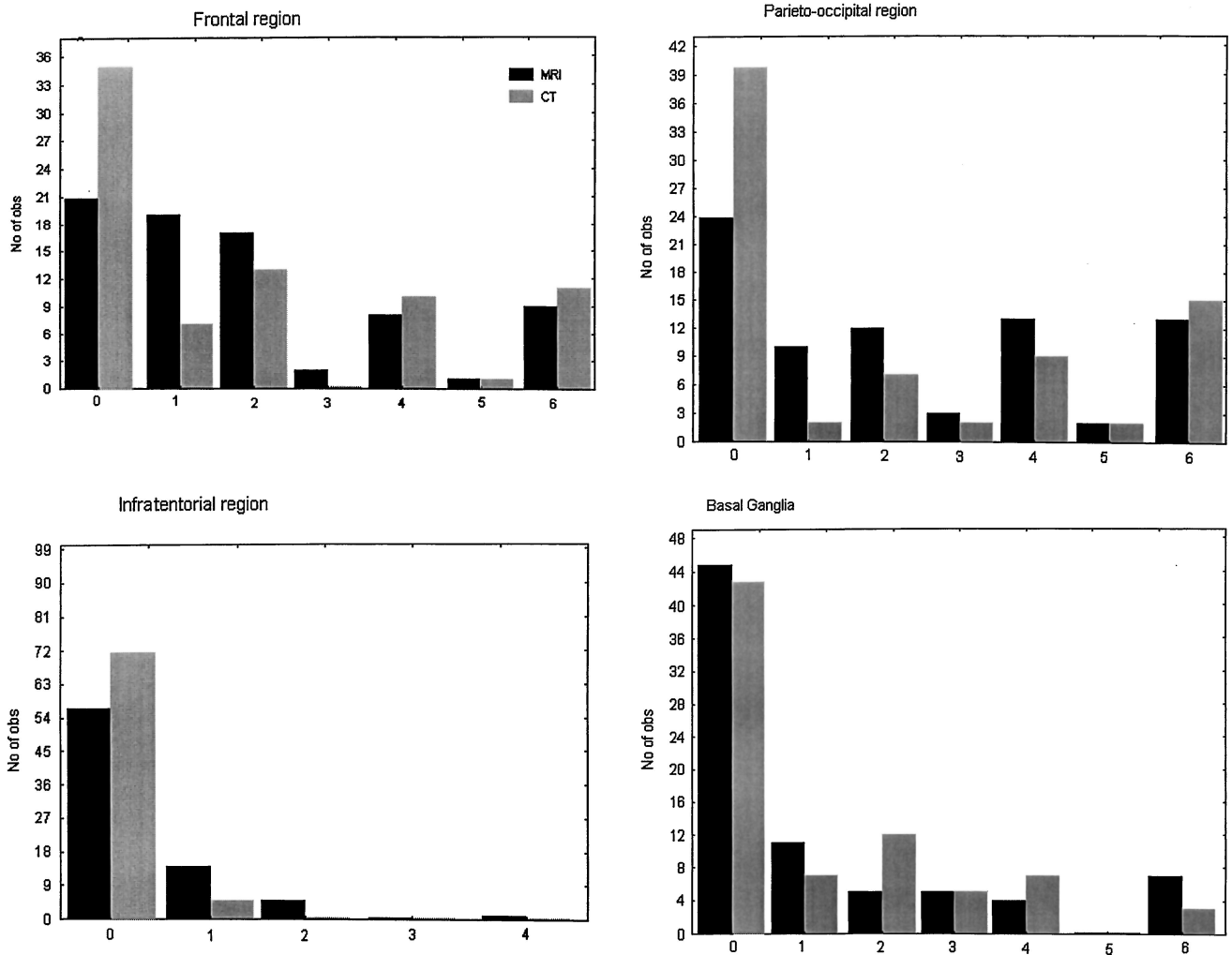
subjects. As evident from Table 3, MRI and CT were equal in  $>50\%$  of all ratings. However, in the parieto-occipital and infratentorial areas, MRI rated significantly more ARWMC than did CT. When the MRI ratings were based on the FLAIR sequence (38 subjects), significantly more ARWMC were rated in all areas except for the basal ganglia and infratentorial area. Also in these cases,  $>50\%$  of all ratings from CT were equal to MRI (see Table 4).

The results of the interrater reliability are presented in Table 5. This showed moderate-excellent agreement for MRI and CT. The highest  $\kappa$  values were found for the rating of frontal, parieto-occipital, and basal ganglia areas, whereas the  $\kappa$  score was lower for the temporal area as well as for the number of infarcts. As expected, the infratentorial area was significantly more reliably rated with MRI than with CT. When ARWMC in all areas were considered together, good agreement was found for MRI (0.67) and moderate agreement for CT (0.48). From Table 5 it is evident that the  $\kappa$  value was larger for MRI than CT in all but 1 region. The lack of statistical significance might be due to type II error.

### Discussion

To be able to assess the degree of ARWMC from both MRI and CT examinations obtained on a clinical, day-to-day basis, we developed a scale that can be applied to MRI and CT alike. This ARWMC scale could also be used in clinical trials with large patient samples, in which drugs affecting brain degenerative processes are tested and both MRI and CT are used for evaluation.

The scale was evaluated by 4 raters and showed good reliability for both CT and MRI in most regions. As expected, the reliability was higher for MRI rating than for CT rating. This was especially true in the frontal and parieto-occipital regions, where very high  $\kappa$  values were detected. Furthermore, MRI was significantly more reliably rated in the parietal/occipital area than CT. This might be explained by



**Figure 2.** The distribution of rating scores (0 through 6; sum of left and right sides) of ARWMC, according to brain region, using the ARWMC scale on CT and MRI.

the fact that CT scans were obtained from a variety of scanners with different slice thickness and image quality.

We found that when using standard T2/PD images, MRI was more sensitive in detecting ARWMC in the parieto-occipital and infratentorial regions of the brain. The latter region is easier to study with MRI than with CT because no bone artifacts are present. Moreover, the differences were mainly due to the ability of MRI to detect small ARWMCs. CT was as good as MRI in detecting larger lesions. This might explain why many studies have shown that ARWMC

found on CT correlate better with symptoms than do the changes detected with MRI. When the FLAIR sequence was used for MRI rating, ARWMC were found significantly more often than with CT. This suggests that FLAIR may be preferable for the study of ARWMC. However, this issue will have to be addressed more extensively in a further study.

To summarize, this study shows that differences of MRI and CT in detecting ARWMC are primarily related to lesion size. MRI was superior due to its better detection of small ARWMC, whereas medium and large lesions were detected

**TABLE 3. Comparison of MRI and CT in Detection of ARWMC, by Region**

Area	MRI>CT	CT>MRI	MRI=CT	P
Frontal	29%	16%	56%	NS
Parieto-occipital	31%	12%	57%	<0.02
Basal ganglia	22%	22%	56%	NS
Infratentorial	23%	3%	76%	<0.01

Based on ratings of all 77 subjects. The columns show percentage of patients in whom MRI scored higher than CT, CT scored higher than MRI, and CT and MRI scored equal. P values obtained sign test.

**TABLE 4. Comparison of MRI and CT in Detection of ARWMC in the Subsample of 38 Patients With FLAIR Images**

Area	MRI>CT	CT>MRI	MRI=CT	P
Frontal	34%	8%	58%	<0.02
Parieto-occipital	37%	1%	61%	<0.002
Basal ganglia	20%	10%	68%	NS
Infratentorial	13%	0%	87%	<0.07

The columns show percentage of total number of ratings in which MRI scored higher than CT, CT scored higher than MRI, and CT and MRI scored equal. P values obtained with sign test.

**TABLE 5.  $\kappa$  Scores for Interobserver Agreement or Rating of ARWMC**

Location	MRI	CT	$P^*$
Frontal			
R	0.8512 (0.0496)	0.7238 (0.0709)	0.1409
L	0.8622 (0.0447)	0.7215 (0.0718)	0.0962
Total	0.8560 (0.0401)	0.7723 (0.0693)	0.2958
Parieto-occipital			
R	0.8680 (0.0386)	0.7281 (0.0629)	0.058
L	0.8831 (0.0399)	0.6626 (0.0711)	0.0068
Total	0.8749 (0.0345)	0.7155 (0.0639)	0.0282
Temporal			
R	0.5841 (0.1008)	0.3474 (0.1188)	0.2308
L	0.6190 (0.0968)	0.6258 (0.0868)	0.9583
Total	0.6033 (0.0903)	0.5103 (0.0948)	0.3057
Basal ganglia			
R	0.6627 (0.0723)	0.4561 (0.0835)	0.0614
L	0.6613 (0.0773)	0.4827 (0.0678)	0.0824
Total	0.6535 (0.0698)	0.4707 (0.0667)	0.0583
Infratentorial			
R	0.5858 (0.0944)	0.3093 (0.0167)	0.0039
L	0.5981 (0.0804)	0.0983 (0.0772)	<0.0001
Total	0.5826 (0.0818)	0.1845 (0.0633)	0.0001
Frontal+temporal+parieto-occipital			
Total	0.6654 (0.089)	0.4837 (0.0907)	0.1527

Agreement is shown according to location for MRI and CT in 20 patients. Values in parentheses are SD.

\* $P$  value of test for  $\kappa$  differences between MRI and CT.

equally well by both modalities. Regional differences played a subordinate role, which is not unexpected from the predominant location of ARWMC in areas that can usually be imaged with high quality by both MRI and CT. Therefore, CT studies in combination with MRI might be used in evaluation of ARWMC in multicenter studies when attempting to address primarily more marked white matter damage. (This could also be the type of white matter damage that shows closer relation to clinical-cognitive deficits, at least in cross-sectional studies). In this context, the new ARWMC rating scale may be a useful tool that demonstrates good interrater reliability. However, for minor ARWMC, MRI appears mandatory, and it is probably also the technique needed for monitoring ARWMC progression.

### Acknowledgments

This study was financially supported by Alzheimerfonden, Lund. We acknowledge Dr Richard Cowburn, research nurse Ulla Swahn, and Dr Leif Svensson for excellent typographic and technical support.

### References

- Scarpelli M, Salvolini U, Diamanti L, Montironi R, Chiaromoni L, Maricotti M. MRI and pathological examination of post-mortem brains:

the problem of white matter high signal areas. *Neuroradiology*. 1994;36:393–398.

- Brun A, Englund E. A white matter disorder in dementia of the Alzheimer type: a pathoanatomical study. *Ann Neurol*. 1986;19:253–262.
- Munoz DG. The pathological basis of multi-infarct dementia. *Alzheimer Dis Assoc Disord*. 1991;5:77–90.
- Scheltens P, Barkhof F, Leys D, Wolters E, Ravid R, Kamphorst W. Histopathologic correlates of white matter changes on MRI in Alzheimer's disease and normal aging. *Neurology*. 1995;45:883–888.
- Van Swieten JC, Van den Hout JHW, van Ketel BA, Hijdra A, Wokke JHJ, van Gijn J. Periventricular lesions in the white matter on magnetic resonance imaging in the elderly: a morphometric correlation with arteriosclerosis and dilated perivascular spaces. *Brain*. 1991;114:761–774.
- Janota I, Mirsen T, Hachinski VC, Lee DH, Merskey H. Neuropathologic correlates of leuko-araiosis. *Arch Neurol*. 1989;46:1124–1128.
- Fazekas F, Kleiner R, Offenbacher H, Payer F, Schmidt R, Kleinert G, Radner H, Lechner H. The morphologic correlate of incidental punctate white matter hyperintensities on MR images. *AJNR Am J Neuroradiol*. 1991;12:915–921.
- Munoz DG, Hastak SM, Harper B, Lee D, Hachinski VC. Pathologic correlates of increased signals of the centrum ovale on magnetic resonance imaging. *Arch Neurol*. 1993;50:492–497.
- Erkinjuntti T, Benavente O, Eliasziw M, Munoz DG, Sulkava R, Haltia M, Hachinski V. Diffuse vacuolization (spongiosis) and arteriosclerosis in the frontal white matter occurs in vascular dementia. *Arch Neurol*. 1996;53:325–332.
- Awad IA, Johnsson PC, Spetzler RF, Hodak JA. Incidental subcortical lesions identified on magnetic resonance imaging in the elderly, II: postmortem pathological correlations. *Stroke*. 1986;17:1090–1097.
- Schmidt R, Fazekas F, Kleinert G, Offenbacher H, Gindl K, Payer F, Freidl W, Niederkorn K, Lechner H. Magnetic resonance imaging signal hyperintensities in the deep and subcortical white matter: a comparative study between stroke patients and normal volunteers. *Arch Neurol*. 1992;49:825–827.
- van Swieten JC, Geyskes GG, Derix MA, Peck BM, Ramos LMP, van Latum JC, van Gijn J. Hypertension in the elderly is associated with white matter lesions and cognitive decline. *Ann Neurol*. 1991;30:825–830.
- Breteler MMB, van Swieten JC, Bots ML, Grobbee D, Claus J, van den Hout J, van Harskamp F, Tanghe HL, de Jong PT, van Gijn J, et al. Cerebral white matter lesions, vascular risk factors, and cognitive function in a population-based study: the Rotterdam study. *Neurology*. 1994;44:1246–1252.
- Lopez O, Becker J, Reynolds C, Jungreis C, Weinman S, DeKosky S. Psychiatric correlates of MR deep white matter lesions in probable Alzheimer's disease. *J Neuropsychol Clin Neurosci*. 1997;9:246–250.
- Almqvist O, Wahlund L-O, Andersson-Lundman G, Basun H, Bäckman L. White-matter hyperintensity and neuropsychological functions in dementia and healthy aging. *Arch Neurol*. 1992;49:626–632.
- Skoog I, Berg S, Johansson B, Palmertz B, Andreasson LA. The influence of white matter lesions on neuropsychological functioning in demented and non-demented 85-year-olds. *Acta Neurol Scand*. 1996;93:142–148.
- Breteler M, van Amerongen NM, van Swieten JC, Claus JJ, Grobbee DE, van Gijn J, Hofman A, van Harskamp F. Cognitive correlates of ventricular enlargement and cerebral white matter lesions on magnetic resonance imaging: the Rotterdam study. *Stroke*. 1994;25:1109–1115.
- Ylikoski R, Ylikoski A, Erkinjuntti T, Sulkava R, Raininko R, Tilvis R. White matter changes in healthy elderly persons correlate with attention and speed of mental processing. *Arch Neurol*. 1993;50:818–824.
- Longstreth WT Jr, Manolio TA, Arnold A, Burke GL, Jungreis CA, Enright PL, O'Leary D, Fried L. Clinical correlates of white matter findings on cranial magnetic resonance imaging of 3301 elderly people: the Cardiovascular Health Study. *Stroke*. 1996;27:1274–1282.
- Scheltens P, Erkinjuntti T, Leys D, Wahlund, L-O, Inzitari D, Del Ser T, Pasquier F, Barkhof F, Mäntylä R, Bowler J, Wallin A, Ghika J, Fazekas F, Pantoni L. White matter changes on CT and MRI: an overview of visual rating scales. *Eur Neurol*. 1998;39:80–89.
- Altman DG. *Practical Statistics for Medical Research*. London, UK: Chapman & Hall; 1991:404–408.

# Stroke

JOURNAL OF THE AMERICAN HEART ASSOCIATION



**A New Rating Scale for Age-Related White Matter Changes Applicable to MRI and CT**  
L. O. Wahlund, F. Barkhof, F. Fazekas, L. Bronge, M. Augustin, M. Sjögren, A. Wallin, H. Ader, D. Leys, L. Pantoni, F. Pasquier, T. Erkinjuntti and P. Scheltens  
on behalf of the European Task Force on Age-Related White Matter Changes

*Stroke*. 2001;32:1318-1322

doi: 10.1161/01.STR.32.6.1318

*Stroke* is published by the American Heart Association, 7272 Greenville Avenue, Dallas, TX 75231

Copyright © 2001 American Heart Association, Inc. All rights reserved.

Print ISSN: 0039-2499. Online ISSN: 1524-4628

The online version of this article, along with updated information and services, is located on the World Wide Web at:

<http://stroke.ahajournals.org/content/32/6/1318>

**Permissions:** Requests for permissions to reproduce figures, tables, or portions of articles originally published in *Stroke* can be obtained via RightsLink, a service of the Copyright Clearance Center, not the Editorial Office. Once the online version of the published article for which permission is being requested is located, click Request Permissions in the middle column of the Web page under Services. Further information about this process is available in the [Permissions and Rights Question and Answer](#) document.

**Reprints:** Information about reprints can be found online at:  
<http://www.lww.com/reprints>

**Subscriptions:** Information about subscribing to *Stroke* is online at:  
<http://stroke.ahajournals.org/subscriptions/>