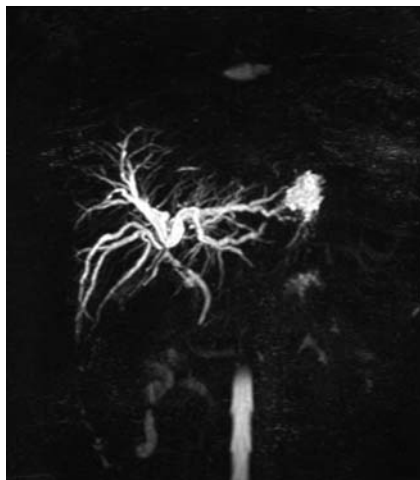
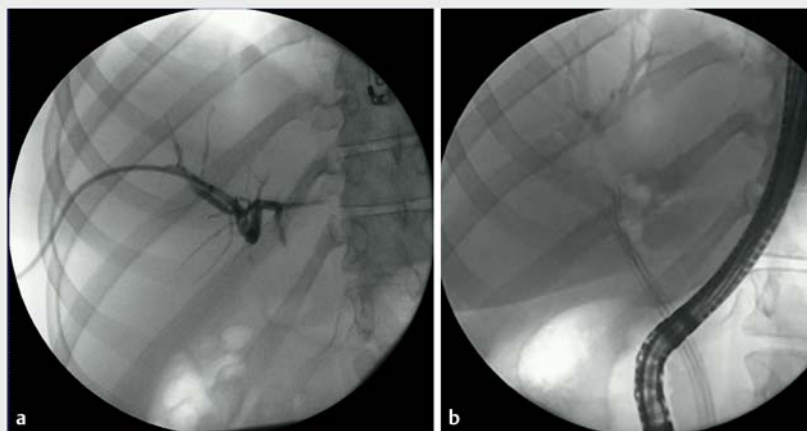


A novel case of biliary common bile duct reconstruction by the rendezvous technique using endoscopic cholangioscopy and percutaneous cholangioscopy

OPEN
ACCESS



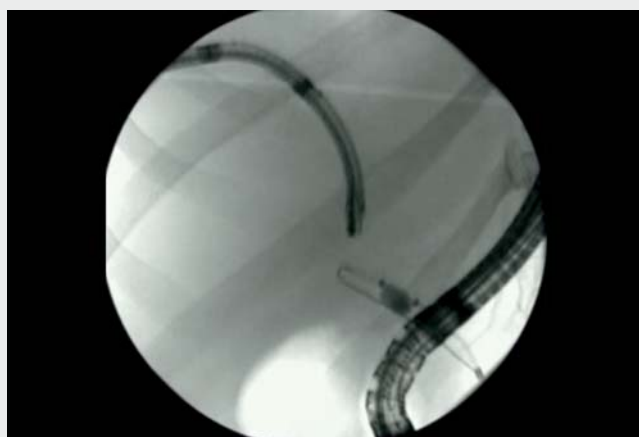
► **Fig. 1** Magnetic resonance cholangiography image showing a Strasberg–Bismuth E2 stricture.



► **Fig. 2** Fluoroscopic images showing: **a** the 12-Fr external drain in the intrahepatic duct; **b** multiple endoscopic stents placed a few weeks after the initial reconstruction.

Biliary tract injuries during cholecystectomy are a rare, but not exceptional, adverse event, with severe consequences. The Strasberg classification with Bismuth modification is most frequently used to classify biliary tract injuries [1, 2]. Expertise in endoscopic, radiologic, and surgical management is required, especially for major biliary tract injuries [3]. A transhepatic-endoscopic approach is useful in difficult cases [4, 5]. We aim to describe a new solution after failure of the standard rendezvous technique, namely double cholangioscopy rendezvous.

A 21-year-old woman developed jaundice 3 months after she underwent cholecystectomy for lithiasis. The patient was referred to our center after undergoing an initial endoscopic retrograde cholangiopancreatography (ERCP), which was unsuccessful because of a blockage below the hilum (Strasberg–Bismuth E2) (► **Fig. 1**). A repeat ERCP attempt also resulted in failure, and external percutaneous drainage was required, with an 8.5-Fr drain placed. The patient's jaundice subsequently decreased.



► **Video 1** After several failed rendezvous procedures, a novel rendezvous technique is performed using cholangioscopy for the endoscopic retrograde cholangiopancreatography to visualize the stricture, along with percutaneous cholangioscopy using a bronchoscope.

A joint decision was made by the gastroenterologists and surgeons to perform the rendezvous technique to avoid a hepaticojejunostomy with a high risk of secondary stricture because of its proximity to the convergence. The first attempt made at this procedure was un-

successful, and the 8.5-Fr percutaneous drain was replaced with a 12-Fr drain (► **Fig. 2a**). A second attempt using simultaneous percutaneous cholangioscopy and ERCP was scheduled for a few days later (► **Video 1**), but this repeat classical rendezvous technique was a fail-

ure too. Attempts guided with cholangioscopy by the endoscopic route were also unsuccessful.

Cholangioscopy was used for ERCP to visualize the stricture, while percutaneous cholangioscopy was performed with a bronchoscope. A needle was used with the bronchoscope to puncture the stricture, and the common bile duct was found with a guidewire. The guidewire was then recovered by the ERCP approach, and a percutaneous internal/external drain (12 Fr) was inserted. A few weeks later, the percutaneous internal/external drain was exchanged with three 12-Fr plastic stents (► **Fig. 2 b**), which were replaced every 4 months for a duration of 1 year.

Endoscopy_UCTN_Code_TTT_1AR_2AG

Competing interests

The authors declare that they have no conflict of interest.

The authors

Jean-Philippe Ratone¹, Fabrice Caillol¹, Mariola Marx¹, Solene Hoibian¹, Yanis Dahel¹, Marc Giovannini¹, Jacques Devière²

1 Endoscopy Unit, Paoli-Calmettes Institute, Marseille, France

2 Department of Gastroenterology, Erasme Hospital, Université libre de Bruxelles, Brussels, Belgium

Corresponding author

Jean-Philippe Ratone, MD

Endoscopy Unit, Paoli-Calmettes Institute,
232 Boulevard de Sainte Marguerite, 13009
Marseille, France
jpratone@hotmail.fr

References

- [1] Bismuth H, Majno PE. Biliary strictures: classification based on the principles of surgical treatment. *World J Surg* 2001; 25: 1241–1244
- [2] Stasberg SM, Hertl M, Soper NJ. An analysis of the problem of biliary injury during laparoscopic cholecystectomy. *J Am Coll Surg* 1995; 180: 101–125
- [3] de'Angelis N, Catena F, Memeo R et al. 2020 WSES guidelines for the detection and management of bile duct injury during cholecystectomy. *World J Emerg Surg* 2021; 16: 30
- [4] Fiocca F, Salvatori FM, Fanelli F et al. Complete transection of the main bile duct: minimally invasive treatment with an endoscopic-radiologic rendezvous. *Gastrointest Endosc* 2011; 74: 1393–1398
- [5] Dumonceau JM, Baize M, Deviere J. Endoscopic transhepatic repair of the common hepatic duct after excision during cholecystectomy. *Gastrointest Endosc* 2000; 52: 540–543

Bibliography

Endoscopy 2022; 54: E950–E951

DOI 10.1055/a-1883-9446

ISSN 0013-726X

published online 21.7.2022

© 2022. The Author(s).

This is an open access article published by Thieme under the terms of the Creative Commons Attribution-NonDerivative-NonCommercial License, permitting copying and reproduction so long as the original work is given appropriate credit. Contents may not be used for commercial purposes, or adapted, remixed, transformed or built upon. (<https://creativecommons.org/licenses/by-nc-nd/4.0/>)

Georg Thieme Verlag KG, Rüdigerstraße 14,
70469 Stuttgart, Germany



ENDOSCOPY E-VIDEOS

<https://eref.thieme.de/e-videos>



Endoscopy E-Videos is an open access online section, reporting on interesting cases and new techniques in gastroenterological endoscopy. All papers include a high quality video and all contributions are freely accessible online. Processing charges apply (currently EUR 375), discounts and waivers acc. to HINARI are available.

This section has its own submission website at

<https://mc.manuscriptcentral.com/e-videos>