

## Brief Reports

# A Novel DYT-5 Mutation with Phenotypic Variability within a Colombian Family

Oscar Bernal-Pacheco<sup>1,4\*</sup>, Genko Oyama<sup>1</sup>, Angela Briton<sup>2</sup>, Andrew B. Singleton<sup>2</sup>, Hubert H. Fernandez<sup>3</sup>, Ramon L. Rodriguez<sup>1</sup>, Irene A. Malaty<sup>1</sup> & Michael S. Okun<sup>1\*</sup>

<sup>1</sup>Departments of Neurology, and Neurosurgery, University of Florida, Center for Movement Disorders & Neurorestoration, Gainesville, FL, USA, <sup>2</sup>Laboratory of Neurogenetics, National Institute on Aging, Bethesda, MD, USA, <sup>3</sup>Center for Neurological Restoration, Cleveland Clinic, Cleveland, OH, USA, <sup>4</sup>Military Central Hospital, Bogota, Colombia

## Abstract

**Background:** DYT-5 dystonia usually presents as a dopa-responsive dystonia (DRD) with early or late parkinsonian manifestations and/or dystonic features. Genetically, these patients have been described as having a wide array of independent mutations in the guanosine triphosphate cyclohydrolase 1 gene (*GCHI*), and these patients may also have a wide array of clinical manifestations.

**Methods:** A Colombian family with six affected female members was characterized.

**Results:** Three members, including the index case, revealed mild parkinsonism, whereas three granddaughters of the index case showed severe generalized dystonia. No men were affected. There was anticipation, and a female predominance was uncovered. Treatment with levodopa was generally effective except in a case with severe skeletal deformities and contractions. Detailed genetic analysis in the index case revealed a new mutation in exon 1 of *GCHI* (c.159delG).

**Discussion:** This study revealed a new mutation of *GCHI* that resulted in heterogeneous clinical presentations of DRD within a large family.

**Keywords:** DRD, dopamine, Parkinson's disease, dystonia, genetics

**Citation:** Bernal-Pacheco O, Oyama G, Briton A, et al. A novel DYT-5 mutation with phenotype variability within a Colombian family. Tremor Other Hyperkinet Mov 2013; 3: <http://tremorjournal.org/article/view/138>

\*To whom correspondence should be addressed. E-mail: [oscarbernalp@gmail.com](mailto:oscarbernalp@gmail.com); [Okun@neurology.ufl.edu](mailto:Okun@neurology.ufl.edu)

**Editor:** Elan D. Louis, Columbia University, United States of America

**Received:** October 15, 2012 **Accepted:** September 9, 2013 **Published:** October 10, 2013

**Copyright:** © 2013 Bernal-Pacheco et al. This is an open-access article distributed under the terms of the Creative Commons Attribution–Noncommercial–No Derivatives License, which permits the user to copy, distribute, and transmit the work provided that the original author(s) and source are credited; that no commercial use is made of the work; and that the work is not altered or transformed.

**Funding:** This work was supported by the UF National Parkinson Foundation Center of Excellence and the Tyler's Hope for a Dystonia Cure Foundation. This work was supported in part by the Intramural Research Program of the National Institute on Aging, National Institutes of Health, Department of Health and Human Services (Z01AG000958-08).

**Funding disclosure:** None.

**Conflict of interest:** The authors report no conflict of interest.

## Introduction

DYT-5 dystonia is an autosomal dominant hereditary dopa-responsive dystonia (DRD), first described by Segawa et al. in 1976.<sup>1</sup> Since the original description, many mutations and clinical presentations have been described.<sup>2-5</sup> Characteristic features of DYT-5 dystonia include generalized dystonia and parkinsonism often with diurnal fluctuations. These symptoms usually respond to low dose levodopa without dyskinesia or wearing-off episodes commonly observed in common Parkinson's disease (PD).<sup>2-4,6</sup> DYT-5 dystonia is associated with mutations in the guanosine triphosphate cyclohydrolase 1 gene (*GCHI*) on chromosome 14 q21.1-q22.2.<sup>4,7</sup> More than 200 mutations have been reported in the gene (see The Human Gene Mutation Database [HGMD]: <http://www.hgmd.cf.ac.uk/ac/gene.php?gene=GCH1> for a complete published list of mutations). DYT-5 dystonia exhibits reduced penetrance and highly

variable expressivity. Women are more commonly affected than men. The prevalence of DYT-5 dystonia is approximately one or two in every two million individuals.<sup>3</sup>

The usual clinical presentation includes lower limb dystonia with progressive walking difficulties, and rapid involvement of all four extremities, the trunk, and the head. There are three described clinical phenotypes: early onset (below age 20) with episodic dystonia, toe walking, or progressive scoliosis; infantile onset with hypotonia followed by early onset severe dystonia;<sup>8</sup> adult-onset (above age 30) with non-tremor parkinsonian type features and mild dystonia or possibly focal dystonia type.<sup>6</sup> Tremor, writer's cramp, and cerebellar signs with saccadic eye alterations can also occur in DYT-5 dystonia cases.<sup>9</sup> Due to the variety of clinical presentations, the disease can be misdiagnosed, and cerebral palsy or parkinsonism are the most common misdiagnoses.<sup>10,11</sup>

We report a novel DYT-5 mutation in the *GCHI* gene with a variable phenotype that occurred within a single Colombian family.

### Methods

We describe a Colombian family with a DRD phenotype. The pedigree for the family is summarized in Figure 1. The index case was an 82-year-old, right-handed female (number 1 in the pedigree). She married three times. She had a daughter with similar clinical manifestations (number 2 in the pedigree). Her daughter had an affected daughter with dystonic features (number 3 in the pedigree). The index case had two affected granddaughters with her first husband (numbers 4 and 5). With her third husband, she also had a granddaughter with dystonic features (number 6). All of the unaffected family members underwent neurological examination, and no abnormalities were discovered. The clinical evaluations were performed by the same movement disorders fellowship-trained neurologist (O.B-P.) in Colombia.

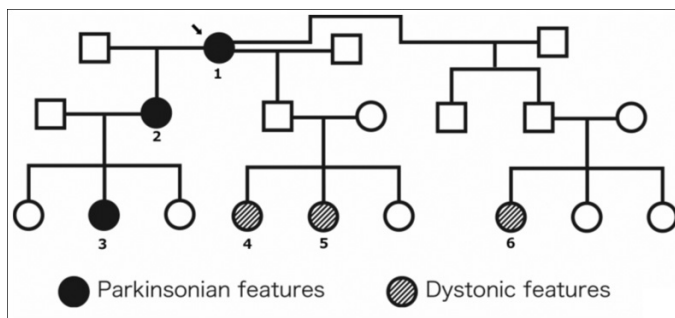
### Results

#### Case 1 (Index case)

The index case was an 82-year-old, right-handed female. She gradually developed tremor, rigidity, bradykinesia, and gait abnormality at age 41. These issues developed after her last child was delivered. She also had shuffling, slow and small steps, and some postural instability. She had been medicated for 20 years with levodopa/carbidopa 250/25 mg, one tablet daily. She reported a good response to therapy without any side effects. During the examination, she was able to perform her activities of daily living without difficulties. Magnetic resonance imaging (MRI) was normal. Blood chemistry, including serum copper, was normal. Neuropsychological evaluations were normal.

#### Cases 2 and 3

Case 2 was a 53-year-old female who was the daughter of the index case. Her symptoms began when she was approximately 40 years old. Case 3 was a 36-year-old female who was the daughter of Case 2, and her symptoms began at age 31. The response to levodopa in both cases was adequate and similar to that of the index case. Both were treated with levodopa/carbidopa 250/25 mg one tablet every morning, and motor function and activities of daily living were essentially normal when in the “on” state. There were no reported side effects.



**Figure 1. Pedigree of a Colombian Family with DYT-5 dystonia.** Only women affected. Genetic analysis in the index case (arrow) revealed a new mutation in exon 1.

#### Case 4

Case 4 was a 28-year-old female, the granddaughter of the index case, who developed symptoms around age 7, including abnormal postures of her feet and twisting movements that produced unsteadiness. She was initially diagnosed with cerebral palsy. The severity of the disease required devices for gait assistance. In a very short period of time (months to years), she developed abnormal postures of her legs and arms with twisted postures of her head and trunk. She required assistance in activities of daily living, however she did not develop cognitive issues. MRI and blood chemistry were normal. Due to the original diagnosis and the persistence of her symptoms, she underwent a bilateral tenosynovectomy and later a surgical hip dislocation at age 9. Despite three surgeries and multiple physical therapy sessions, her symptoms did not improve. She was bedridden with generalized contractures. At age 26, she received a treatment with levodopa/carbidopa 250/25 mg half tablet daily, which produced nausea. She later received biperiden, which partially relieved her contractures.

#### Case 5

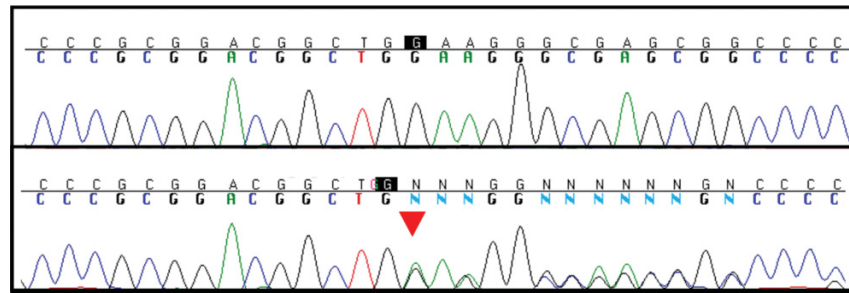
The 18-year-old sister of case 4 developed abnormal postures of the feet and twisting movements around age 7. She also required assistant for gait. MRI, blood chemistry, and neuropsychological evaluation were all normal. At age 16, she received levodopa/carbidopa 125 mg in the morning with an excellent response, and her activities of daily living were normal after 3 months of treatment. She had returned to school.

#### Case 6

Case 6 was a 13-year-old female of the third son of the index case. At the age of 6, she developed contractures in both legs, and after a short period of time the symptoms progressed to involve her arms and also produced abnormal painful postures that persisted both during the day and night. She required assistance in her activities of daily living, and she became dependent on a wheelchair. At age 11, she received a trial of levodopa/carbidopa 250/25 mg half tablet every morning with a good response, and she became independent in her activities of daily living and ambulation. She became able to go to school.

#### Genetic analysis

Only the index case was tested. Each of the protein-coding exons of *GCHI* was polymerase chain reaction-amplified and sequenced using standard protocols. Conditions and primer sequences are available upon request. Sequence data, produced on an ABI3730 genetic analyzer (Applied Biosystems, Foster City, CA), was visualized using Sequencher (Gene Codes Corp, Ann Arbor, MI). Review of the chromatograms from this sequencing revealed a deletion in exon 1 of *GCHI* (c.159delG, based on sequence accession number NM\_000161), which resulted in a frame shift and the creation of a premature stop codon p.W53X (based on sequences accession number NP\_000152.1). See attached chromatogram, which displays the sequences (Figure 2).



**Figure 2. GCHI Mutation.** Upper panel, wild-type sequence from unaffected control. Lower panel, deletion of G nucleotide, signified by red arrowhead, (c.159delG, based on sequence accession number NM\_000161), which results in a frame shift and the creation of a premature stop codon p.W53X (based on sequences accession number NP\_000152.1).

### Discussion

We discovered an index case in a Colombian family with a clinical course revealing a mild parkinsonism that could have been mistaken for idiopathic PD. Also, severe dystonia emerged in multiple offspring and in multiple generations. A wide array of clinical and genetic variability in DYT-5 dystonia has been previously reported.<sup>12</sup> Generalized or focal dystonic features and parkinsonian and cerebellar manifestations have been observed. The various presentations can make diagnosis difficult. Variation in expressivity, even within members of the same family, has also been reported,<sup>13</sup> and although genetic testing is now available, most experts would reason that a levodopa-challenge test should be attempted whenever the diagnosis is suspected. In our cases, all patients exhibited a good response to levodopa, except the most affected woman who had severe bony contractions.

Interestingly, this family's genetics analysis revealed evidence for female-dominant penetration with anticipation (worsening in successive generations). Gender preference for females has been reported in DRD.<sup>14</sup> Although a mechanism for such an effect in a disease caused by a stable point mutation remains unclear, the reduced penetrance associated with GCHI mutations would suggest that there are other genetic, environmental, or stochastic factors mediating the disease process, and that these factors may be responsible for the apparent anticipation and severe clinical manifestations in the index case's three granddaughters.

In conclusion, a new stop mutation in exon 1 of GCHI (c.159delG) was found in a Colombian family. The clinical features of this family included female dominance and anticipation.

### References

1. Segawa M, Hosaka A, Miyagawa F, Nomura Y, Imai H. Hereditary progressive dystonia with marked diurnal fluctuation. *Adv Neurol* 1976;14:215–233.
2. Segawa M. Hereditary progressive dystonia with marked diurnal fluctuation. *Brain Dev* 2011;33:195–201, doi: <http://dx.doi.org/10.1016/j.braindev.2010.10.015>.
3. Nygaard TG, Wilhelmsen KC, Risch NJ, et al. Linkage mapping of dopa-responsive dystonia (DRD) to chromosome 14q. *Nat Genet* 1993;5:386–391, doi: <http://dx.doi.org/10.1038/ng1293-386>.

4. Tassin J, Durr A, Bonnet AM, et al. Levodopa-responsive dystonia. GTP cyclohydrolase I or parkin mutations? *Brain* 2000;123:1112–1121, doi: <http://dx.doi.org/10.1093/brain/123.6.1112>.
5. Nemeth AH. The genetics of primary dystonias and related disorders. *Brain* 2002;125:695–721, doi: <http://dx.doi.org/10.1093/brain/awf090>.
6. Steinberger D, Topka H, Fischer D, Muller U. GCHI mutation in a patient with adult-onset oromandibular dystonia. *Neurology* 1999;52:877–879, doi: <http://dx.doi.org/10.1212/WNL.52.4.877>.
7. Ichinose H, Ohye T, Takahashi E, et al. Hereditary progressive dystonia with marked diurnal fluctuation caused by mutations in the GTP cyclohydrolase I gene. *Nat Gen* 1994;8:236–242, doi: <http://dx.doi.org/10.1038/ng1194-236>.
8. Kong CK, Ko CH, Tong SF, Lam CW. Atypical presentation of dopa-responsive dystonia:generalized hypotonia and proximal weakness. *Neurology* 2001;57:1121–1124, doi: <http://dx.doi.org/10.1212/WNL.57.6.1121>.
9. Trender-Gerhard I, Sweeney MG, Schwingenschuh P, et al. Autosomal-dominant GTPCH1-deficient DRD:clinical characteristics and long-term outcome of 34 patients. *J Neurol Neurosurg Psychiatry* 2009;80:839–845, doi: <http://dx.doi.org/10.1136/jnnp.2008.155861>.
10. Nygaard TG, Waran SP, Levine RA, Naini AB, Chutorian AM. Dopa-responsive dystonia simulating cerebral palsy. *Pediatr Neurol* 1994;11:236–240, doi: [http://dx.doi.org/10.1016/0887-8994\(94\)90109-0](http://dx.doi.org/10.1016/0887-8994(94)90109-0).
11. Bonifati V, De Michele G, Lücking CB, et al. The parkin gene and its phenotype. Italian PD Genetics Study Group, French PD Genetics Study Group and the European Consortium on Genetic Susceptibility in Parkinson's Disease. *Neurol Sci* 2001;22:51–52, doi: <http://dx.doi.org/10.1007/s100720170042>.
12. Ichinose H, Suzuki T, Inagaki H, Ohye T, Nagatsu T. Molecular genetics of dopa-responsive dystonia. *Biol Chem* 1999;380:1355–1364, doi: <http://dx.doi.org/10.1515/BC.1999.175>.
13. Steinberger D, Weber Y, Korinthenberg R, et al. High penetrance and pronounced variation in expressivity of GCHI mutations in five families with dopa-responsive dystonia. *Ann Neurol* 1998;43:634–639, doi: <http://dx.doi.org/10.1002/ana.410430512>.
14. Segawa M. Autosomal dominant GTP cyclohydrolase I (AD GCHI 1) deficiency (Segawa disease, dystonia 5;DYT 5). *Chang Gung Med J* 2009;32:1–11.