

# A novel lumen-apposing metal stent for endoscopic ultrasound-guided drainage of pancreatic fluid collections: a prospective cohort study

## Authors

Daisy Walter<sup>1</sup>, Uwe Will<sup>2</sup>, Andres Sanchez-Yague<sup>3</sup>, Dirk Brenke<sup>4</sup>, Jochen Hampe<sup>5</sup>, Helge Wollny<sup>6</sup>, Jose Miguel Esteban López-Jamar<sup>7</sup>, Gertrud Jechart<sup>8</sup>, Peter Vilmann<sup>9</sup>, Joan B. Gornals<sup>10</sup>, Sebastian Ullrich<sup>11</sup>, Martin Fähndrich<sup>12</sup>, Alberto Herreros de Tejada<sup>13</sup>, Félix Junquera<sup>14</sup>, Ferran Gonzalez-Huix<sup>15</sup>, Peter D. Siersema<sup>1</sup>, Frank P. Vleggaar<sup>1</sup>

## Institutions

Institutions are listed at the end of article.

## submitted

27. January 2014

## accepted after revision

25. July 2014

## Bibliography

**DOI** <http://dx.doi.org/10.1055/s-0034-1378113>  
Published online: 30.9.2014  
Endoscopy 2015; 47: 63–67  
© Georg Thieme Verlag KG  
Stuttgart · New York  
ISSN 0013-726X

## Corresponding author

### Daisy Walter, MD

Department of  
Gastroenterology  
and Hepatology  
University Medical  
Center Utrecht  
P.O. Box 85500  
3508 GA Utrecht  
Netherlands  
Fax: +31-88-755533  
[d.walter@umcutrecht.nl](mailto:d.walter@umcutrecht.nl)

**Background and study aims:** A novel large-diameter, lumen-apposing, self-expanding metal stent with bilateral flanges was recently developed for endoscopic ultrasound (EUS)-guided transmural drainage of symptomatic pancreatic fluid collections (PFCs). The aim of this study was to evaluate the efficacy and safety of this stent in a large cohort.

**Patients and methods:** Patients with a PFC undergoing EUS-guided drainage with this novel stent were prospectively enrolled in this multicenter cohort study.

**Results:** There were 61 patients: 46 patients (75%) with walled-off necrosis (WON) and 15 (25%) with a pancreatic pseudocyst. Stent placement was technically successful in 60 patients (98%, 95%CI 95%–100%). Clinical success, defined as resolution of clinical symptoms in combination with a decrease in the PFC size to  $\leq 2$  cm on imaging, was

achieved in 93% of patients with a pancreatic pseudocyst (95%CI 77%–100%) and in 81% of patients with WON (95%CI 69%–94%). Treatment failure occurred in nine patients (16%, 95%CI 6%–26%), including four patients who required surgical intervention. Stent removal was performed in 82% of patients after a median of 32 days (range 2–178) and was rated as easy in all but one patient. In 10 patients, endoscopic stent removal was not performed because of stent migration (n=3), stent dislodgement during necrosectomy (n=3), stent removal during surgery (n=2), or refusal by the patient (n=2). In total, five major complications were reported (9%, 95%CI 2%–16%), including PFC infection (n=4) and perforation (n=1).

**Conclusion:** EUS-guided drainage using this novel stent is feasible and the clinical results obtained are promising with a low major complication rate.

## Introduction

Endoscopic ultrasonography (EUS)-guided transmural drainage with placement of double-pigtail plastic stents is the recommended drainage modality for symptomatic pancreatic fluid collections (PFCs) [1–3]. Clinical success rates largely depend on the type of PFC, with higher success rates reported for pancreatic pseudocysts (82%–100%) compared to walled-off necrosis (WON; 53%–100%) [1,4]. However, the efficacy of drainage is limited by the small diameter (7–10Fr) of the double-pigtail plastic stents. Therefore, multiple pigtail stents are placed to ensure a wider drainage opening. The risk of stent occlusion from secondary infection of the collection is high, in particular when the PFC contains large pieces of necrotic debris. Furthermore, if access to the collection is required for endoscopic transmural necrosectomy, balloon dilation of the tract is required to allow the endoscope to be passed into the collection [1].

To overcome these limitations, placement of a self-expanding metal stent (SEMS) may be an alternative to plastic pigtail stents. The main advantage of a SEMS is its larger luminal diameter ( $\geq 10$  mm), which potentially results in longer stent patency, faster PFC resolution, a reduced need for endoscopic re-intervention, and a lasting access route for necrosectomy.

The use of different types of SEMSs has been reported in case reports and small case series. Most of these SEMSs were tubular stents designed for transluminal drainage, such as bile duct drainage [5–10]. When used for transmural drainage, these SEMSs have some limitations, including a high risk of stent migration. Therefore, a novel large-diameter SEMS with bilateral flanges, the AXIOS stent (Xlumena Inc., Mountain View, California, USA), has been designed especially for transmural drainage. Until now, only three small studies have reported on the use of this new stent but these have demonstrated high rates of technical success (89%–100%) and clinical success

(93%–100%) in patients with successful stent placement [11–13]. In this paper, we report the experience with the AXIOS stent for drainage of PFCs from a larger cohort study.

## Patients and methods

### Patients

From May 2011 to November 2012, all patients with a symptomatic PFC who underwent AXIOS stent placement in 15 European centers were prospectively enrolled in a web-based database. The decision to place an AXIOS stent was at the discretion of the treating physician and there were no specific inclusion or exclusion criteria. PFCs were classified according to the revised 2012 Atlanta Classification [14] as pancreatic pseudocysts or WON. The protocol was approved by the Medical Ethics Committees and all patients gave their informed consent prior to AXIOS stent placement.

### AXIOS stent

The AXIOS stent is a SEMS constructed of braided nitinol that is fully covered with silicone (● Fig. 1). The stent design, with wide flanges on both ends, provides anchoring within the PFC and an even distribution of pressure on the luminal walls. The stent is delivered through a 10.5-Fr catheter, which is Luer-locked to the inlet port of the endoscope instrumentation channel to provide controlled deployment of the stent. The stent is CE-marked for drainage of PFCs. For this study, stents with a length of 10 mm between the flanges and luminal diameters of 10 mm or 15 mm were used.

### Procedure


Drainage was performed while the patients were under conscious sedation, monitored anesthesia care, or general anesthesia. Prophylactic antibiotics were administered at the discretion of the endoscopist.

Under linear EUS-guidance, the collection was punctured from the stomach or duodenum using a 19-gauge EUS-guided fine needle aspiration (FNA) needle or the NAVIX access device (Xlumena Inc.). A 0.035-inch guidewire was passed through the needle or the NAVIX access device and was coiled in the PFC. The fistula tract was then dilated using a cystostome or the NAVIX access device. Further balloon dilation was performed at the discretion of the endoscopist. The delivery catheter was placed over the guidewire and the distal end of the stent was deployed in the PFC lumen under fluoroscopic and/or EUS guidance, while the proximal stent end was deployed under fluoroscopic and/or endoscopic view.

The use of endoscopic intervention, including necrosectomy and placement of a nasocystic drain, was dictated by the clinical course of the patient (for example, the presence of persisting fever).

### Definition of endpoints

The study endpoints included technical success, clinical success, and safety. Technical success was defined as satisfactory access and drainage of the PFC following placement of the AXIOS stent. Clinical success was defined as resolution of clinical symptoms in combination with a decrease in the PFC size to  $\leq 2$  cm on imaging, without the need for placement of an additional endoscopic or percutaneous stent or drain, or surgery.



**Fig. 1** The AXIOS stent, which has wide flanges on both ends to provide anchorage.

Safety was defined as the number of minor and major procedure-related complications. Procedure-related major complications (including bleeding, PFC infection, perforation, and stent migration) were defined as complications that required admission, and/or endoscopic or surgical intervention. PFC infection was defined as any new septic event that occurred after the initial endoscopic drainage, as proven by new-onset fever and/or positive blood cultures. Perforation was defined as free intraperitoneal air on imaging studies in association with peritoneal signs. Stent migration was defined as an adverse event if an intervention was required to retrieve the stent either from within the PFC or from the enteral lumen. Procedure-related minor complications were defined as complications that did not require admission or endoscopic intervention.

### Statistical analysis

SPSS (version 20.0) statistical software was used for data analysis. Continuous variables were reported using means (standard deviation) and medians (range), as appropriate. Categorical variables were reported in terms of frequency counts and proportions. Logistic regression analysis was performed to calculate odds ratios (ORs) and their corresponding 95% confidence intervals (CIs) for predictors of clinical success.

## Results

### Patients

In total, 61 patients were included in 15 centers with a median of three patients per center (range 1–12) (● Table 1). Data on four patients (6.6%) were limited to the technical procedure and these patients were excluded from the further analysis. Two patients with WON and one patient with a pancreatic pseudocyst were lost to follow-up after transfer back to their referring hospitals; one patient with WON died from an unrelated cause (myocardial infarction) 116 days after placement of the stent.

### Technical success

Stent placement was technically successful in 60 patients (98%, 95%CI 95%–100%). In one patient, the entire stent was fully deployed inside the PFC and two plastic pigtail stents had to be placed to achieve adequate drainage. During repeat endoscopy, it was possible to successfully remove the AXIOS stent from the PFC. In another patient, the entire stent was initially deployed in the PFC, but it was possible to reposition the stent correctly. In two patients, the stent did not deploy properly and a new stent was placed. Details on the characteristics of the PFCs and the endoscopic procedures that were performed are shown in ● Table 2 and ● Fig. 2.

**Table 1** Characteristics of 61 patients with pancreatic fluid collections.

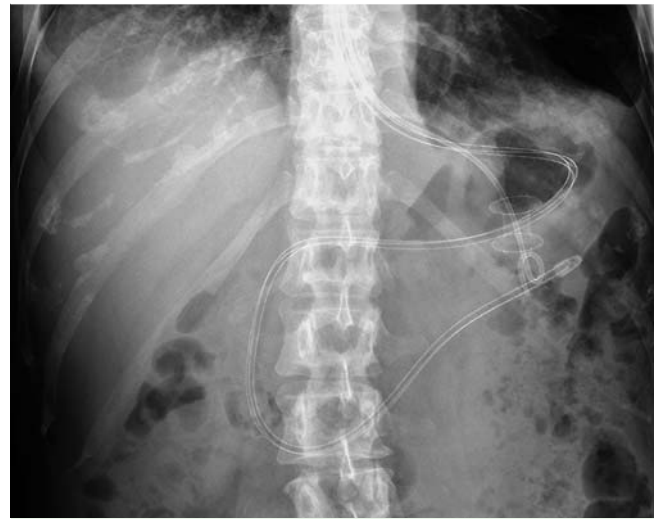Characteristic	
Age, mean ± SD, years	55 ± 14
Male sex, n (%)	38 (62)
Etiology of pancreatitis, n (%)	
Gallstone disease	19 (31)
Alcoholic	22 (36)
Idiopathic	9 (15)
Post-surgical	6 (10)
Other*	5 (8)
Indication for drainage, n (%)	
Pain	19 (31)
Infection	16 (26)
Enlargement	9 (15)
Gastric outlet/bile duct obstruction	8 (13)
Combination of complaints	5 (8)
Missing	4 (7)
Type of pancreatic fluid collection, n (%)	
Pancreatic pseudocyst	15 (25)
Walled-off necrosis	46 (75)

SD, standard deviation.

\* Other includes: drugs, trauma, post-endoscopic retrograde cholangiopancreatography (ERCP), unknown, and pancreas divisum.

**Table 2** Details of the drainage procedure in 61 patients with pancreatic fluid collections.

Characteristic	
Technical success, n (%)	60 (98)
Location of fluid collection, n (%)	
Body	35 (57)
Tail	11 (18)
Head	7 (11)
Neck	4 (7)
Entire pancreas	2 (3)
Peripancreatic	2 (3)
Pancreatic fluid collection dimension, median (range), cm	9 (4–20)
Infected pancreatic fluid collection, n (%)	
Yes	33 (54)
No	28 (46)
Bulging, n (%)	
Yes	41 (67)
No	20 (33)
Drainage site, n (%)	
Gastric	58 (95)
Cardia	8 (13)
Body	40 (66)
Antrum	10 (16)
Duodenum	3 (5)
Dilation of tract before placement, n (%)	
No	34 (56)
Yes	27 (44)
Stent size, n (%)	
10 × 10 mm	22 (36)
10 × 15 mm	39 (64)
Anesthesia, n (%)	
Conscious sedation	30 (49)
Monitored anesthesia care	18 (30)
General anesthesia	13 (21)



**Fig. 2** Abdominal radiograph showing a 10-mm transgastric AXIOS stent in position for drainage of an area of walled-off pancreatic necrosis and a nasocystic irrigation tube (with pigtail end) that has been passed through the lumen of the AXIOS stent because of lack of clinical improvement. A nasoenteral feeding tube that was placed to ensure adequate intake is also seen.

**Clinical success**

Clinical success was achieved in 13 of 14 patients with a pancreatic pseudocyst (93%, 95%CI 77%–100%) and in 35 of 43 patients with WON (81%, 95%CI 69%–94%) ( $P=0.31$ ). The mean time to confirmed resolution of the PFC was  $38 \pm 35$  days (median 29 days; range 1–136). In none of the patients with a pancreatic pseudocyst was additional endoscopic intervention required to achieve clinical success. In contrast, in patients with WON, additional necrosectomy and/or irrigation was performed in 43% of patients (15/35): seven patients (20%) required one intervention and eight patients (23%) more than one intervention.

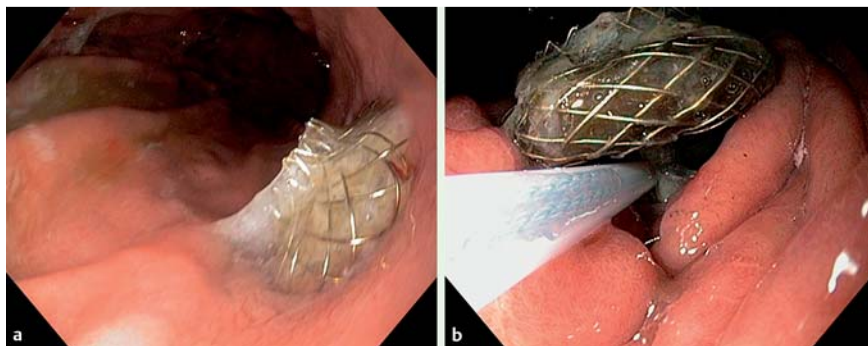
Univariate logistic regression showed no association between clinical success and infection of the PFC (OR 0.50, 95%CI 0.11–2.23), PFC size (OR 0.99, 95%CI 0.98–1.01), or PFC etiology (gallstone vs. alcohol, OR 7.14, 95%CI 0.75–67.98; gallstone vs. other, OR 0.53, 95%CI 0.33–8.35).

Treatment failure occurred in nine patients (16%, 95%CI 6%–26%), including four patients who required surgical intervention: one patient with a pancreatic pseudocyst who had a perforation and three patients with WON who had persistent infection ( $n=1$ ), a retroperitoneal abscess ( $n=1$ ), and a paracolic necrotic cavity ( $n=1$ ). The other reasons for treatment failure included: placement of plastic pigtail stents because of AXIOS stent dislodgement during necrosectomy ( $n=3$ ), nasocystic tube placement for irrigation ( $n=1$ ), and additional AXIOS stent placement to obtain a more convenient route of approach to perform necrosectomy ( $n=1$ ).

**Stent removal**

Endoscopic stent removal was performed in 47 of 57 patients (82%) after a median of 32 days (range 2–178). Stent removal was successful in all patients using a snare or rat-tooth forceps. In 11 of these 47 patients (23%), hyperplastic tissue ingrowth or overgrowth of the stent had occurred, but stent removal was uneventful (Fig. 3). In 10 patients, endoscopic stent removal was not performed because of migration of the stent ( $n=3$ ), stent dislodgement during necrosectomy ( $n=3$ ), removal during

This document was downloaded for personal use only. Unauthorized distribution is strictly prohibited.



**Fig. 3** Endoscopic views showing: **a** hyperplastic tissue overgrowth at the gastric end of a stent that had been in position for 75 days; **b** safe removal of the stent using a snare, after a first attempt at removal using a rat-tooth forceps had failed because of unraveling of the nitinol wires.

surgery (n=2), and refusal by the patient (n=2). Stent migration was observed during follow-up abdominal ultrasound (n=2) or upper gastrointestinal endoscopy (n=1), 65, 86, and 216 days after stent placement, respectively. On further imaging (abdominal radiograph, abdominal ultrasound, and upper gastrointestinal endoscopy) these stents could no longer be visualized. None of these patients experienced symptoms due to stent migration.

### Complications

Major complications were seen in five of 57 patients (9%, 95%CI 2%–16%): PFC infection (n=4) and perforation (n=1). The PFC infections were new-onset infections in patients with WON, which in three patients were caused by their stents becoming occluded by necrotic debris. All four patients were successfully treated with endoscopic necrosectomy, in combination with antibiotics and/or nasocystic drainage. One patient with a 6×8-cm pseudocyst presented with fever and peritoneal signs a few hours after stent placement. Imaging showed free air in the abdominal cavity, and during surgery it appeared that, although the proximal flange of the AXIOS stent was still positioned in the stomach, the distal flange was completely detached from the pancreatic pseudocyst and was facing the peritoneal cavity. There were 16 minor complications, which occurred in 14 patients (25%, 95%CI 14%–36%), including self-limiting device-related bleeding (n=4), transient fever of unknown origin (n=3), stent migration (n=3), stent dislodgement (n=3), and food substances entering the PFC (n=3).

### Discussion

This multicenter prospective cohort study is the largest series to report on the use of SEMSs for EUS-guided drainage of PFCs. We demonstrated that EUS-guided placement of the AXIOS stent for transmural drainage was feasible, with a technical success rate of 98%, and a clinical success rate of 93% for pancreatic pseudocysts and 81% for WON. Furthermore, placement was found to be safe, with a major complication rate below 10%.

The large luminal diameter of SEMSs ( $\geq 10$  mm) is thought to facilitate effective drainage, which results in higher clinical success rates and faster PFC resolution. For patients with WON, the clinical success rate of drainage with SEMSs in our study (81%) is in the upper range when compared with the reported success rate of drainage with plastic pigtail stents (53%–100%) [1,4], while the success rate with SEMSs for pancreatic pseudocysts (93%) is similar when compared to plastic pigtail stents (82%–100%) [1,4].

The already high success rate for pancreatic pseudocyst drainage with plastic stents results from the fact that fluid from pancreatic

pseudocysts can easily flow through and alongside plastic pig-tails. However, in most reported studies at least one additional intervention was required to achieve pancreatic pseudocyst resolution [4], whereas we found that with SEMSs no additional interventions were required to achieve clinical success. If this reduction can be confirmed in a randomized trial comparing SEMSs with plastic stents, the use of more expensive SEMSs may be justified for the drainage of pancreatic pseudocysts.

In the 35 patients with WON, only 15 of them (43%) required additional necrosectomy and/or an irrigation procedure to achieve resolution. In 7 of these 15 patients (47%) only one intervention was required, while the remaining patients required more than one intervention. This suggests that using SEMSs may also result in a reduction in the number of procedures for the treatment of WON; however, limited data have been published on the exact number of repeat interventions to achieve resolution of WON.

In the first reports on the use of SEMSs for transmural drainage of PFCs, stents with a tubular design were used, including stents that were intended for use in the biliary tract, trachea, or esophagus. In an effort to prevent SEMS migration, double-pigtail stents were placed in or alongside the SEMSs as anchoring device. Nonetheless, stent migration was still reported in 6%–10% of patients [5,8]. Stents that were partially covered have also been used to prevent migration of the stent. The mechanistic idea here is that tissue ingrowth at both stent ends will reduce migration. Barresi et al. [15] reported that partially covered stents did effectively prevent stent migration, but in one patient surgery was required to remove a stent that became fully embedded in the stomach wall.

To improve on the results of transmural drainage, novel SEMS designs have been developed, such as the AXIOS and NAGI stent (Taewoong Medical, Seoul, South Korea). The AXIOS stent was designed in a saddle shape with large bilateral flanges to achieve firm anchorage. Despite this anchoring design, stent migration and stent dislodgement have been reported with this device [11,12]. Migration into the stomach was reported in one patient (7%), in whom the cystgastrostomy tract had been dilated up to 15 mm before placement of a 10-mm stent [11]. In another study, both spontaneous migration, with no clinical consequences for the patient, and stent dislodgement were reported [12].

We also observed spontaneous stent migration and stent dislodgement, each of which occurred in three patients (5%). Although migration was not associated with any adverse consequences, SEMS migration may cause severe complications such as perforation or obstruction in the gastrointestinal tract. In addition, the anchoring design could not prevent the stent became completely detached from the pancreatic pseudocyst a few hours after placement in one patient. In our opinion, further refinements in stent design are therefore required to improve the

anchoring capacity and, in that way, reduce the risk of stent migration and dislodgement.

The current study has several strengths and limitations. First, this is the largest prospective study on EUS-guided SEMS placement for transmural drainage of PFCs published to date. Furthermore, we used clear and predefined definitions for classification of PFCs and study endpoints. A limitation of the study was the lack of a control group treated with plastic pigtail stents or other types of SEMSs. Therefore, definite conclusions on efficacy of the device cannot be drawn. Furthermore, no standardized time points for follow-up were defined in the study protocol and repeat endoscopy was performed at the discretion of the endoscopist. Patients were followed until resolution of their PFC; therefore, no data are available with regard to long-term complications or recurrence rates. Finally, the decision to place an AXIOS stent was at the discretion of the physician with no predefined criteria; as a result, selection bias of the study population is possible. However, the high percentage of patients with WON might indicate that it was not only the easy cases that were treated with the AXIOS stent. In conclusion, this study shows that EUS-guided drainage using the AXIOS stent is feasible and the clinical results we obtained seem promising. However, before SEMS placement is widely adopted, randomized controlled studies are required to confirm these results and to compare them with alternative treatment modalities for PFCs in terms of their long-term results and cost-effectiveness.

**Competing interests:** None

#### Institutions

- <sup>1</sup> Department Gastroenterology and Hepatology, University Medical Center Utrecht, Utrecht, Netherlands
- <sup>2</sup> Department of Gastroenterology, Municipal Hospital, Gera, Germany
- <sup>3</sup> Endoscopy Unit, Hospital Costa del Sol, Marbella, Spain
- <sup>4</sup> Department of Internal Medicine II, Department of Gastroenterology, Städt. Klinikum Karlsruhe, Karlsruhe, Germany
- <sup>5</sup> Department of Internal Medicine I, University Hospital Dresden, TU Dresden, Dresden, Germany
- <sup>6</sup> Department of Internal Medicine and Gastroenterology, Medical Center Städte Region Aachen, Würselen, Germany
- <sup>7</sup> Department of Endoscopy, Hospital Clinico San Carlos, Madrid, Spain
- <sup>8</sup> Department of Gastroenterology, Klinikum Augsburg, Augsburg, Germany
- <sup>9</sup> Department of Surgery, Copenhagen University Hospital Herlev, Copenhagen, Denmark
- <sup>10</sup> Department of Endoscopy, Hospital Universitari de Bellvitge-IDIBELL, Barcelona, Spain
- <sup>11</sup> Department of Internal Medicine I, Asklepios Klinik Altona, Hamburg, Germany
- <sup>12</sup> Department of Interventional Endoscopy, Klinikum Dortmund, University Münster, Dortmund, Germany
- <sup>13</sup> Department of Gastroenterology, IDIPHIM, Puerta de Hierro University Hospital, Autónoma University, Madrid, Spain
- <sup>14</sup> Department of Digestive Disease, Hospital Parc Tauli, Barcelona, Spain
- <sup>15</sup> Endoscopy Unit, Clinica Girona, Girona, Spain

#### References

- 1 Seewald S, Ang TL, Kida M et al. EUS 2008 Working Group document: evaluation of EUS-guided drainage of pancreatic-fluid collections (with video). *Gastrointest Endosc* 2009; 69: S13–S21
- 2 Varadarajulu S, Christein JD, Tamhane A et al. Prospective randomized trial comparing EUS and EGD for transmural drainage of pancreatic pseudocysts (with videos). *Gastrointest Endosc* 2008; 68: 1102–1111
- 3 Varadarajulu S, Bang JY, Sutton BS et al. Equal efficacy of endoscopic and surgical cystogastrostomy for pancreatic pseudocyst drainage in a randomized trial. *Gastroenterology* 2013; 145: 583–590
- 4 Hookey LC, Debroux S, Delhaye M et al. Endoscopic drainage of pancreatic-fluid collections in 116 patients: a comparison of etiologies, drainage techniques, and outcomes. *Gastrointest Endosc* 2006; 63: 635–643
- 5 Talreja JP, Shami VM, Ku J et al. Transenteric drainage of pancreatic-fluid collections with fully covered self-expanding metallic stents (with video). *Gastrointest Endosc* 2008; 68: 1199–1203
- 6 Fabbri C, Luigiano C, Cennamo V et al. Endoscopic ultrasound-guided transmural drainage of infected pancreatic fluid collections with placement of covered self-expanding metal stents: a case series. *Endoscopy* 2012; 44: 429–433
- 7 Berzosa M, Maheshwari S, Patel KK et al. Single-step endoscopic ultrasonography-guided drainage of peripancreatic fluid collections with a single self-expandable metal stent and standard linear echoendoscopy. *Endoscopy* 2012; 44: 543–547
- 8 Penn DE, Draganov PV, Wagh MS et al. Prospective evaluation of the use of fully covered self-expanding metal stents for EUS-guided transmural drainage of pancreatic pseudocysts. *Gastrointest Endosc* 2012; 76: 679–684
- 9 Weilert F, Binmoeller KF, Shah JN et al. Endoscopic ultrasound-guided drainage of pancreatic fluid collections with indeterminate adherence using temporary covered metal stents. *Endoscopy* 2012; 44: 780–783
- 10 Belle S, Collet P, Post S et al. Temporary cystogastrostomy with self-expanding metallic stents for pancreatic necrosis. *Endoscopy* 2010; 42: 493–495
- 11 Itoi T, Binmoeller KF, Shah J et al. Clinical evaluation of a novel lumen-apposing metal stent for endosonography-guided pancreatic pseudocyst and gallbladder drainage (with videos). *Gastrointest Endosc* 2012; 75: 870–876
- 12 Shah J, Shah JN, Waxman I et al. EUS-guided drainage of pancreatic pseudocysts (PP) utilizing a novel anchoring, covered self-expanding metal stent (Acsems): results from a prospective, multi-center study. *Gastrointest Endosc* 2013; 77: AB128
- 13 Gornals JB, De la Serna-Higuera C, Sanchez-Yague A et al. Endosonography-guided drainage of pancreatic fluid collections with a novel lumen-apposing stent. *Surg Endosc* 2013; 27: 1428–1434
- 14 Banks PA, Bollen TL, Dervenis C et al. Acute Pancreatitis Classification Working Group. Classification of acute pancreatitis – 2012: revision of the Atlanta classification and definitions by international consensus. *Gut* 2013; 62: 102–111
- 15 Barresi L, Tarantino I, Curcio G et al. Buried stent: New complication of pseudocyst drainage with self-expandable metallic stent. *Dig Endosc* 2012; 24: 285