

Stroke

American Stroke
AssociationSM

JOURNAL OF THE AMERICAN HEART ASSOCIATION

A Division of American
Heart Association



**A Novel, Self-Expanding, Nitinol Stent in Medically Refractory Intracranial
Atherosclerotic Stenoses: The Wingspan Study**

Arani Bose, Marius Hartmann, Hans Henkes, Hon Man Liu, Michael M.H. Teng,
Istvan Szikora, Ansgar Berlis, Jurgen Reul, Simon C.H. Yu, Michael Forsting, Matt
Lui, Winston Lim and Siu Po Sit

Stroke 2007;38;1531-1537; originally published online Mar 29, 2007;

DOI: 10.1161/STROKEAHA.106.477711

Stroke is published by the American Heart Association, 7272 Greenville Avenue, Dallas, TX 75214
Copyright © 2007 American Heart Association. All rights reserved. Print ISSN: 0039-2499. Online
ISSN: 1524-4628

The online version of this article, along with updated information and services, is
located on the World Wide Web at:

<http://stroke.ahajournals.org/cgi/content/full/38/5/1531>

Subscriptions: Information about subscribing to Stroke is online at
<http://stroke.ahajournals.org/subscriptions/>

Permissions: Permissions & Rights Desk, Lippincott Williams & Wilkins, a division of Wolters
Kluwer Health, 351 West Camden Street, Baltimore, MD 21202-2436. Phone: 410-528-4050. Fax:
410-528-8550. E-mail:
journalpermissions@lww.com

Reprints: Information about reprints can be found online at
<http://www.lww.com/reprints>

A Novel, Self-Expanding, Nitinol Stent in Medically Refractory Intracranial Atherosclerotic Stenoses

The Wingspan Study

Arani Bose, MD; Marius Hartmann, MD, PhD; Hans Henkes, MD; Hon Man Liu, MD; Michael M.H. Teng, MD; Istvan Szikora, MD; Ansgar Berlis, MD; Jurgen Reul, MD; Simon C.H. Yu, MD; Michael Forsting, MD; Matt Lui, MD; Winston Lim, MD; Siu Po Sit, PhD

Background and Purpose—The purpose of this study was to assess the safety and performance of the Wingspan stent system and Gateway percutaneous transluminal angioplasty balloon catheter in the treatment of high-grade, intracranial atherosclerotic lesions in patients who had failed medical therapy.

Methods—In this prospective, multicenter, single-arm study, medically refractory patients with a modified Rankin score ≤ 3 and recurrent symptoms attributable to angiographically demonstrated intracranial stenosis $\geq 50\%$ in a vessel 2.5 to 4.5 mm in diameter were enrolled. Intracranial lesions were predilated with an undersized Gateway balloon catheter to 80% of the native vessel diameter, followed by deployment of the self-expanding Wingspan stent to facilitate further remodeling of the atherosclerotic plaque and to maintain vessel patency. Neurologic examinations and angiograms were performed at 6 months after the procedure.

Results—Among the 45 patients enrolled, the degree of stenosis was reduced from a baseline of $74.9 \pm 9.8\%$ to $31.9 \pm 13.6\%$ after stenting and $28 \pm 23.2\%$ at the 6-month follow-up. The 30-day composite ipsilateral stroke/death rate was 4.5% (2/44); at the 6-month follow-up, the ipsilateral stroke/death rate was 7.0%, the rate for all strokes was 9.7%, and all-cause mortality was 2.3%. Physician-reported follow-up in 43 patients (average of 13 months) conducted outside the study protocol (not adjudicated by the clinical event committee) reported 1 additional ipsilateral stroke.

Conclusions—In medically refractory patients with high-grade intracranial atherosclerotic stenoses, a new treatment paradigm involving predilation with an undersized Gateway percutaneous transluminal angioplasty balloon catheter and placement of a self-expanding Wingspan stent system appears to be safe, may facilitate remodeling, and may contribute to favorable angiographic outcomes. (*Stroke*. 2007;38:1531-1537.)

Key Words: atherosclerosis ■ medical therapy ■ nitinol stent ■ stenosis ■ stroke

It has been reported that intracranial (IC) atherosclerosis may be the underlying pathology in up to 15% of patients with ischemic stroke.¹⁻⁵ Stroke prevention by open surgical vascular intervention in patients with extracranial atherosclerotic disease was demonstrated by a landmark study in symptomatic patients with stenosis $>70\%$ of the internal carotid artery.⁶ These benefits were subsequently confirmed in patients with less severe stenoses (50% to 70%).⁷

In contrast to extracranial atherosclerotic stenosis, little is known about the natural history or best therapy for the management of IC stenosis. As illustrated by the recent termination of the Warfarin-Aspirin Symptomatic Intracranial Disease Study (WASID), the safety and efficacy of

antithrombotics in the treatment of IC atherosclerotic lesions has yet to be defined.^{8,9}

Recent reports involving small numbers of patients with IC atherosclerotic disease who were treated with coronary angioplasty catheters or balloon-expandable stents have shown promising results.¹⁰⁻²⁷ However, the safety of these procedures may be compromised by (1) limited flexibility of the coronary balloons or balloon-mounted stent delivery systems; (2) high inflation pressure required to deploy stainless steel stents in fragile IC vessels; (3) risk of shearing the stent from the balloon while navigating to the target lesion; and (4) difficulty in accurately sizing the balloons and stents to the vessel diameter. To our knowledge, there have been no

Received November 10, 2006; accepted November 23, 2006.

From the Lenox Hill Hospital (A.B.), New York, NY; University of Heidelberg Medical Center (M.H.), Heidelberg, Germany; Robert Janker Klinik and Alfried Krupp Krankenhaus (H.H.), Bonn, Germany; National Taiwan University Hospital (H.M.L.), Taipei, Taiwan; Taipei Veterans General Hospital and National Yang Ming University (M.T.), Taipei, Taiwan; National Institute of Neurosurgery (I.S.), Budapest, Hungary; Klinikum der Universität Freiburg (A.B.), Freiburg, Germany; Kreis Krankenhaus Siegen (J.R.), Siegen, Germany; Prince of Wales Hospital (S.Y.), Hong Kong; Universitätsklinikum Essen (M.F.), Essen, Germany; Queen Mary Hospital (M.L.), Hong Kong; Singapore General Hospital (W.L.), Singapore; and Penumbra Inc (S.P.S.), San Leandro, Calif.

Correspondence to Siu Po Sit, PhD, Penumbra Inc, 2401 Merced St, San Leandro, CA 94577. E-mail ssit@penumbrainc.com

© 2007 American Heart Association, Inc.

Stroke is available at <http://www.strokeaha.org>

DOI: 10.1161/STROKEAHA.106.477711

reports of treatment paradigms using a combination of IC balloon angioplasty and self-expanding stent systems for the management of this disease.

The purpose of this clinical investigation was to assess the safety and performance of a novel, nitinol, self-expanding stent system (Wingspan stent system and Gateway percutaneous transluminal angioplasty [PTA] balloon catheter; Boston Scientific Corp) in medically refractory patients with high-grade, symptomatic IC atherosclerotic stenoses. This stent system is designed to support a treatment paradigm different from that of balloon-expandable stents. Target lesions are predilated with an undersized Gateway balloon catheter at nominal pressure with slow inflation, followed by deployment of the self-expanding Wingspan stent system to further remodel the target vessel to maintain patency without the need for postdilation. The results of this investigation were used to support an application to the US Food and Drug Administration for a humanitarian device exemption application, which received approval in August 2005.

Methods

The protocol for this study received institutional review board or ethics committee approval at the respective clinical centers before enrolling any patients. Primary safety end points at the 6-month follow-up (ipsilateral stroke or death) and selected other events were adjudicated by a clinical events committee (CEC) composed of specialists in the areas of neuroradiology, neurology, and interventional neuroradiology. All angiographic results were adjudicated by an independent core laboratory. A qualified contract research organization monitored data collection. The degree or percent stenosis of the target lesion was determined from the formulas as described by the WASID method.²⁸

Patients

From January 29, 2004 to September 21, 2004, 45 patients were enrolled at 12 international centers. All patients provided signed, informed consent before enrollment. Target patients had high-grade, symptomatic IC atherosclerotic lesions, had failed antithrombotic therapy, and had no alternative treatment options. Enrollees were between 18 and 80 years of age, were at least 7 days after stroke, had a modified Rankin Scale score (mRS) ≤ 3 , and had recurrent symptoms attributable to angiographically demonstrated IC stenosis $\geq 50\%$ in a vessel 2.5 to 4.5 mm in diameter. Pregnant women were excluded.

Description of Stent System

The Wingspan stent system is intended for use in the treatment of IC atherosclerotic stenosis. The stent system comprises a self-expanding nitinol stent preloaded in a delivery catheter and a separately packaged Gateway PTA balloon catheter. The balloon catheter is used to predilate the stenotic lesion; the stent is then deployed across the lesion, further remodeling the target vessel to maintain luminal patency (Figure 1).

Preprocedure Evaluation

Baseline assessments included a blood test, urinary pregnancy test for women of child-bearing potential, physical examination, neurologic examination, and stroke scales (mRS, National Institutes of Health Stroke Scale, Barthel Index). Preoperative evaluation of stenotic lesions was performed by digital subtraction angiography (DSA). Four-vessel cerebral angiography with at least 2 orthogonal views was performed to delineate minimum lumen diameter. An independent core laboratory evaluated the films; the measurements obtained were used as source data for analyzing angiographic end points. Target-lesion stenosis was determined by the WASID method.⁴




Figure 1. Illustration of the Wingspan stent.

Preprocedure Medical Therapy

Each patient received clopidogrel (75 mg PO QD for 3 days before the procedure or 225 mg PO on the day before treatment) and aspirin (300 or 325 mg PO QD for 3 days before procedure or 300 to 650 mg PO on the day before treatment). Anesthesia was administered in accordance with the standard of care at each participating center. A bolus and continuous intravenous infusion of heparin were given before the procedure to raise and maintain the activated clotting time at 2 to 3 times baseline throughout the procedure.

Procedure

The Wingspan stent system was available in 5 diameters (2.5 to 4.5 mm) and 3 lengths (9, 15, and 20 mm). Size selection was based on the native diameter of the target vessel (fully expanded stent diameter was 0.5 to 1.0 mm greater than the labeled diameter) and length of the stenotic lesion (deployed stent to extend at least 3 mm on either side of the lesion).

The stent delivery catheter was a 3.5F, coaxial, over-the-wire catheter with segments of varying stiffness and a nominal working length of 135 mm. The outer body of the delivery catheter was hydrophilically coated, and the distal end of the inner shaft had a soft, atraumatic tip for trackability. An integrated rotating hemostasis valve permanently attached to the proximal end of the outer body allowed continuous heparinized saline flush and provided a hemostatic seal around the inner body. The stent was constrained by the outer body shaft before deployment. The recommended Gateway balloon diameter (when inflated at the nominal pressure of 6 atm) was 80% of the native vessel diameter. The undersizing of the PTA balloon was intended to restrict the barotrauma to the plaque while minimizing intimal damage to the native parent vessel.

Postprocedure Evaluation and Medical Therapy

On completion of angioplasty and stenting, each patient was evaluated by DSA. Investigators evaluated several aspects of the procedure by clinical research questionnaires. Heparin infusion was continued for 24 hours to maintain the activated clotting time at 2 to 3 times baseline or a partial thromboplastin time at 70 to 90 seconds. Each patient received clopidogrel (75 mg PO QD) for 30 days and aspirin (300 or 325 mg PO QD) for life.

Follow-Up

Each patient was evaluated with a neurologic examination (including stroke scales) at discharge and at 30-day and 6-month follow-ups. Angiographic follow-up with DSA was conducted postoperatively and at 6 months.

End Points

The primary end points were composite ipsilateral stroke/death at 30 days, stent success, and procedure success. Stent success was defined as adequate device performance based on an investigator rating system and a reduction in the degree of stenosis to $<50\%$ immediately after implantation. Each procedure was evaluated by an investigator who completed a clinical research questionnaire form on various aspects (tracking, maneuverability, accuracy of positioning, deployment, visibility of markers, overall functioning/reliability/

performance) of the catheter and stent. Procedure success was defined as stent success without stroke or death at discharge. The secondary end points were angiographic evidence of vessel dissection, symptomatic restenosis, stent migration, access-site complications, and clinical outcomes at the 6-month follow-up.

Statistical Methods

Analyses of the data gathered from this trial were primarily descriptive. Simple descriptive statistics (n, mean, median, SD, minimum and maximum for continuous variables, and n and percentage for discrete variables), graphs, and patient listings were used to summarize most data.

Primary and secondary end points were analyzed on an intent-to-treat basis as well as on the evaluable patients. Evaluable patients were those patients who met eligibility requirements for primary end-point assessment and who received a Wingspan stent. The primary safety and performance end points measured immediately after the procedure and at discharge, 30-day follow-up, and 6-month follow-up were reported.

Results

Patient Characteristics

Forty-five patients were enrolled in the study. One enrollee was not treated owing to problems with guidewire access through the patient's tortuous anatomy; the remaining 44 patients were treated with the Wingspan stent system. The mean length of hospital stay for these patients was 5.1 days (range, 1 to 20 days).

Thirty-three of the 45 patients (73.3%) in the study were male, 33 (73.3%) were white, and 12 (26.7%) were Asian. The mean age at enrollment was 66 years. Forty-two patients (93.3%) had stroke as the qualifying event; 3 patients (6.7%) had a history of transient ischemic attack. The most common risk factors reported were hypertension (41 [91.1%]), hypercholesterolemia/hyperlipidemia (26 [55.6%]), smoking (24 [53.3%]), diabetes (24 [53.3%]), and angina/coronary artery disease (10 [22.2%]). All 45 patients enrolled into the study were taking antithrombotic medications at the time of entry. Of these, 38 patients (84%) were taking ≥ 1 antiplatelet medications (aspirin, clopidogrel, or ticlopidine), 19 (42%) were taking anticoagulants (heparin or warfarin), and 12 (27%) were taking a combination of antiplatelets and anticoagulants. Further analysis indicated that 80% of the patients were taking aspirin and 13% were taking warfarin, either as monotherapy or in combination.

Preoperative neurologic exams revealed the following most common presenting symptoms: hemiparesis (18 [40%]), transient neurologic deficit (12 [26.7%]), focal neurologic deficit (10 [22.2%]), and ataxia (7 [15.6%]). Stroke scale evaluations were consistent with the presenting neurologic symptoms. The majority of the patients had mild to moderate residual neurologic and functional deficits (mRS ≤ 3 , National Institutes of Health Stroke Scale ≤ 8 , Barthel Index ≥ 55) from before or ongoing cerebral ischemia associated with IC atherosclerosis.

Table 1 summarizes lesion locations and dimensions as determined by preoperative DSA. Twenty-three (51.1%) of the lesions were located in the anterior circulation, and 22 (48.9%) were located in the posterior circulation. The mean degree of stenosis was 74.9%; all patients had $\geq 50\%$ stenosis at baseline.

TABLE 1. Lesion Locations and Baseline Characteristics

Location	n	Percent
Anterior circulation		
Middle cerebral artery (M1)	10	22.2
Carotid artery, petrous segment	5	11.1
Carotid artery, cavernous segment	4	8.9
Carotid artery, ophthalmic segment	1	2.2
Carotid artery, communicating segment	1	2.2
Carotid artery, supraclinoid segment	1	2.2
Carotid artery, terminus	1	2.2
Posterior circulation		
Vertebral artery	13	28.9
Basilar trunk	9	20
Lesion dimensions	Mean \pm SD	Range
Lesion length, mm	7.2 \pm 2.9	1.30–14.0
Reference vessel diameter, mm	3.1 \pm 0.8	1.3–4.8
Minimum lumen diameter, mm	0.8 \pm 0.4	0.0–2.0
Percent stenosis*	74.9 \pm 9.8	57.0–99.0

*The degree (%) of stenosis was determined by the WASID method.²⁸

Treatment Results

Primary End Points

Two patients experienced stroke or death within 30 days of the procedure. One patient had an ipsilateral hemorrhagic stroke 24 hours after the procedure and expired 10 days later. Another patient was successfully treated and discharged neurologically intact but subsequently had an ipsilateral circumscribed infarction in the deep pons 7 days after the procedure. Thus, the 30-day composite ipsilateral stroke or death rate was 4.5% (2/44).

Preprocedure and postprocedure angiographic results for the Wingspan stent system are summarized in Table 2. The mean percent stenosis at the target lesion was reduced from 74.9% to 50.0% after angioplasty and further reduced to 31.9% after stent placement. Mean responses from the investigators' device performance rating on a scale of 1 (poor) to 5 (excellent) ranged from 4.3 to 4.5 for the Gateway PTA balloon catheter and 4.4 to 4.6 for the Wingspan stent system. Stent success was 100% (ie, all target lesions were reduced to $< 50\%$ stenosis with adequate device performance), and procedure success was 97.7% (1 patient had a hemorrhagic stroke and expired before discharge).

Secondary End Points

Of the 43 patients evaluated at 6 months, 1 additional patient had an ipsilateral stroke and another had a contralateral stroke, resulting in a 6-month ipsilateral stroke rate of 7.1% (3/43) and an all-stroke rate of 9.7% (4/43). There were no additional deaths; the 6-month composite ipsilateral stroke or death rate was 7.1% (3/43). In the nonadjudicated, physician-reported follow-up of 43 patients ranging from 7 to 22 months (average of 13 months) conducted outside the study protocol, there was 1 additional ipsilateral stroke and no additional neurologic deaths. Thus, the ipsilateral stroke rate at 1-year follow-up was 9.3%.

TABLE 2. Angiographic Evaluation of IC Vessel Treatment Results With the Wingspan or NEUROLINK Stent System

	Baseline	After Stenting	6 Months
Wingspan	n=45	n=44	n=40
Reference vessel diameter, mm			
Mean±SD	3.1±0.8	3.2±0.8	3.1±0.8
Range, minimum, maximum	1.3, 4.8	1.3, 4.8	1.3, 4.8
Minimum lumen diameter at lesion, mm			
Mean±SD	0.8±0.6	2.1±0.5	2.2±0.8
Range, minimum, maximum	0.0, 2.0	1.3, 3.2	0.4, 4.0
Percent stenosis*			
Mean±SD	74.9±9.8	31.9±13.6	28.0±23.2
Range, minimum, maximum	57.0, 99.0	−8.0, 49.0	−33.0, 81.0
≥50% stenosis, n (%)	45 (100)	0 (. . .)	3 (7.5)
NEUROLINK†	n=42	n=42	n=27
Reference vessel diameter, mm			
Mean±SD	3.3±0.7	3.3±0.7	3.3±0.7
Range, minimum, maximum	1.7, 4.6	1.9, 4.7	2.0, 4.4
Minimum lumen diameter at lesion, mm			
Mean±SD	1.0±0.5	2.6±0.7	1.9±1.0
Range, minimum, maximum	0, 2.0	1.5, 4.2	0.4, 4.2
Percent stenosis*			
Mean±SD	71.1±13.1	19.7±15.7	43.4±24.1
Range, minimum, maximum	42.0, 100	−9.1, 50.0	0, 84.4
≥50% stenosis, n (%)	40 (95.2)	1 (2.4)	10 (37.0)

*The degree (%) of stenosis was determined by the WASID method.²⁸

†IC vessels only.

Forty of the patients were examined angiographically at 6 months; their mean percent stenosis (28.0%) was similar to that observed immediately after the procedure. Three patients showed a late loss of lumen diameter leading to regression of stenosis to >50% but were asymptomatic. No stent migration or parent-vessel dissections was reported after the procedure or at the 6-month follow-up. Five patients experienced a total of 7 access site-related adverse events during the 6 months after stenting. Four of the events (hematomas [3] and infection [1]) required treatment but resolved without further complications.

One patient required retreatment 72 days after an uneventful procedure. Angiographic evaluation indicated a new stenosis of ≥90% within the implanted stent but at a location distal to the previously treated target lesion. The degree of stenosis at the previous lesion was unchanged. The CEC determined that this was not a restenosis. The investigator implanted a balloon-expandable, drug-eluting coronary stent within the Wingspan stent, and patency was restored.

Adverse Events

Eighteen procedural adverse events were reported in 12 patients, but none resulted in long-lasting sequelae. Vasospasm was observed in 5 patients. One patient sustained an asymptomatic frontal medial branch occlusion in a small territory of the middle cerebral artery. Other procedural adverse events reported were hematoma (3 patients), hyper-

tension (3 patients), and arrhythmia, fever, hypervolemia, hyperglycemia, neurologic symptom (nystagmus), and respiratory failure due to epiglottis edema (1 patient each). There were no reports of procedural in-stent thrombosis or parent-vessel dissection or perforation.

Discussion

In the United States, of the ≈700 000 patients who experience new or recurrent stroke, 88% are diagnosed as ischemic.¹ Of these, up to 15% are thought to be related to atherosclerosis.^{2,3} The rate of ischemic events (stroke or transient ischemic attack) in patients with IC atherosclerosis can range from 10% to 50% per year, depending on the severity of the lesions and other conditions.^{1–5,8,9} In this report, we present the first clinical evidence of a new treatment paradigm with undersized predilation followed by deployment of a novel, self-expanding stent without the need for postdilation. The device was able to access distal lesions safely and provided sufficient appositional force to remodel an atherosclerotic lesion, with patency maintained for at least 6 months after the procedure (Table 2, Figure 2). The patient population evaluated was a stroke cohort with high-grade IC stenosis refractory to standard antithrombotic therapy. The preponderance of evidence in the literature suggests these patients are at high risk of recurrent events but have no other treatment options.^{3,4,8,9,29,30}

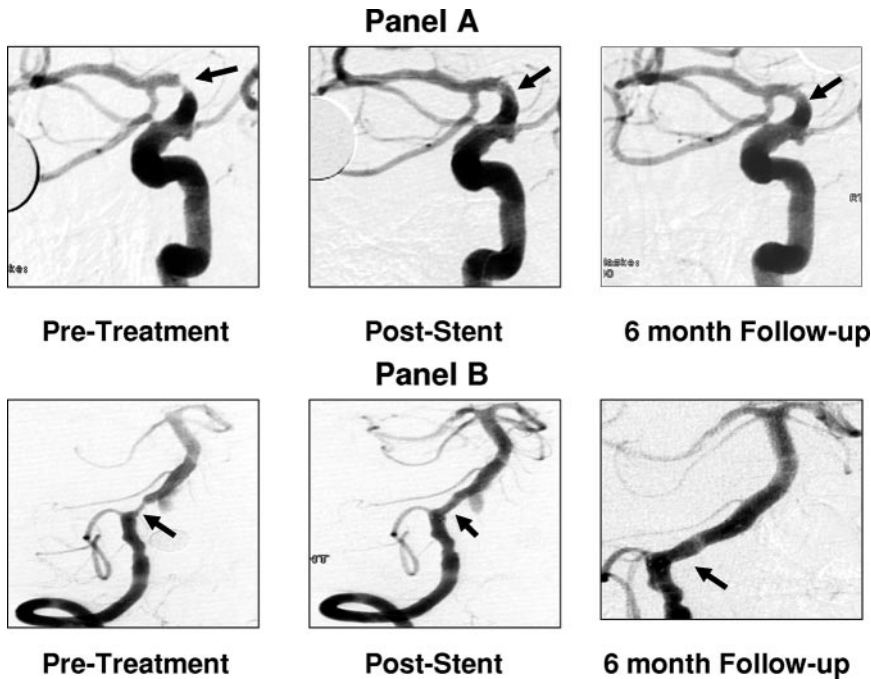


Figure 2. Angiographic results in the anterior (A) and posterior (B) circulations before and after treatment with the Wingspan stent system. A, 72-year-old female patient with stenosis of the right carotid bifurcation before treatment (79%), after stenting, and at 6-month follow-up. B, A 62-year-old male patient with stenosis of the right vertebral artery before treatment (71%), after stenting, and at 6-month follow-up. Note the continuing remodeling observed on the 6-month follow-up angiogram.

The treatment paradigm for the self-expanding Wingspan stent system is different from that of balloon-expandable stents and is designed to offer several advantages. First, the undersizing of the angioplasty balloon confines the remodeling force to the atherosclerotic plaque, minimizing barotrauma to the adjacent normal parent vessel. Second, the nitinol stent is more flexible than balloon-mounted stents and is designed to reach distal lesions through tortuous anatomy. Third, the self-expanding stent facilitates sizing as well as conformability in curved and tapered vessels. A balloon-expandable stent must be oversized to provide good wall apposition, which makes sizing problematic in tapered vessels. In contrast, Wingspan is designed to conform to vessels that vary in diameter across the length of the stent. Finally, the Wingspan stent provides a force of <0.1 atm at deployment, a small fraction of the 6 to 9 atm required to deploy a balloon-expandable stent, thus reducing trauma to the vessel and the risk of vessel rupture. The results of this study support the assumptions behind the new treatment paradigm. Wingspan was able to reach all lesions that could be accessed by a guidewire, including 9 in the M1 territory. The study also demonstrated a low rate of acute and periprocedural complications with no instances of procedural stroke, vessel rupture, or stent migration.

The new treatment paradigm also demonstrated an ability to maintain patency compared with the only prospective study of a balloon-expandable stent. Table 2 compares the angiographic results observed in the current investigation with those from the SSYLVA trial, which assessed the safety and performance of a balloon-expandable stent system (NEUROLINK; Guidant Corp) in a similar stroke cohort.^{11,13} NEUROLINK-treated lesions appeared to regress over time, both in the mean degree of stenosis (from 19.7% to 43.4% stenosis) and in restenosis of the target lesion to $\geq 50\%$ (37% of patients). Wingspan-treated patients

showed an opposite trend, with the mean degree of stenosis declining slightly (from 31.9% to 28%) and 7.5% of the patients showing restenosis to $\geq 50\%$ at 6 months (Table 2). There were no instances of symptomatic restenosis in the Wingspan patients. The NEUROLINK trial also reported intraprocedural serious adverse events of stroke, arterial dissection, carotid cavernous fistula, nerve paresis, and acute stent occlusion,^{11,13} whereas none were reported for the Wingspan patients. At 6 months after the procedure, the ipsilateral stroke rate was 14% for the NEUROLINK-treated patients and 7.1% for the Wingspan patients.^{11,13} These results indicate that acute endovascular intervention with the Wingspan stent system not only did not pose undue risk but also may have contributed to acceptable clinical outcomes in patients at high risk of recurrent IC ischemic events, who, having failed medical therapy, had no other treatment options available to them.

Previous studies provide the context for understanding the potential risks and benefits of IC angioplasty and stenting with the Wingspan stent system compared with antithrombotic therapy. The 6-month event rate of the Wingspan patients appears to be less than expected for this cohort. For example, in the GESICA study, it was observed that patients with symptomatic IC atherosclerotic stenosis on antithrombotic therapy had a 2-year event rate of 38.2%, and those with more severe lesions had an event rate as high as 60.7%.³¹ The median time to recurrent ischemic events was only 2 months from the first qualifying event. The WASID group compared the efficacy of aspirin and warfarin in patients with symptoms attributable to high-grade (50% to 99%) stenosis of an IC artery. It reported the 1-year rate for ischemic stroke in the territory of the lesion in patients on warfarin or aspirin therapy to be 11% and 12%, respectively.⁸ Analysis of the cumulative probability of these events revealed a steep rise in the event curves within the first 3 months of enrollment, perhaps an indication of the unstable nature of the atheroscle-

TABLE 3. Cohort Risk Factor Profiles: Wingspan vs Historical Controls

Risk Factor	Wingspan (n=45)	SSYLVA ¹³ (n=61)*	Thijs and Albers ³ (n=51)	GESICA ³¹ (n=102)	WASID ⁸ (n=569)
Age, y	66	63	66.5	63.3	63.6
Male	73.3%	80.3%	59.6%	71.6%	61.5%
Hypertension	91.1%	63.9%	73.1%	73.5%	84.1%
History/current smoking	53.3%	52.5%	42.3%	70.6%	64.5%
Diabetes mellitus	53.3%	32.8%	26.9%	30.4%	38%
Hypercholesterolemia/hyperlipidemia	55.6%	54.1%	38.5%	59.8%	70.8%
Angina/coronary artery disease	22.2%	24.6%	23.1%	33.3%	27.1%
Qualifying event					
Transient ischemic attack	6.7%	39.3%	N/A	48.4%	39%
Stroke	93.3%	60.7%	44.2%	51.6%	61%
Target vessel					
Posterior circulation	51.1%	36.1%	59.6%	48%	39.7%
Anterior circulation	48.9%	34.4%	40.4%	52%	54.1%
Mean % stenosis of target lesion	74.9%	69.9%	≥50%	≥50%	63.7%

*Including extracranial vessels.

rotic plaque in this high-risk cohort (Figure 2 of Chimowitz et al⁸). This observation is consistent with results reported in a retrospective study by Thijs and Albers,³ wherein the event rates of patients with high-grade (≥50%), symptomatic IC atherosclerosis who failed antithrombotic therapy were assessed. In a follow-up (median 13.6 months) of 29 patients who failed antithrombotic therapy, the median time to event (24.1% all-cause stroke, 6.9% death, and 27.6% composite all-cause stroke/death) was 36 days.

The favorable event rates in the Wingspan-treated patient cohort compared with other published series is more compelling, considering that at baseline, the Wingspan patients had higher incidences of hypertension, diabetes, and stroke as the qualifying event, as well as a higher degree of mean stenosis of the affected artery (Table 3). This last characteristic is particularly relevant, because WASID identified severe stenosis (≥70%) as one of the primary risk factors for recurrent stroke in the territory of the lesion.⁹ In the WASID patients who entered the study with stroke and severe stenosis, the ipsilateral stroke rate was 23% at 1 year.⁹

Because of the small sample size, these findings are unable to assess the potential effectiveness of the Wingspan stent system in the prevention of stroke/death in these high-risk patients. However, the short-term treatment results and follow-up analysis provide compelling evidence supporting the safety of endovascular therapy with the Wingspan stent system for stroke prevention in a very high-risk patient population.

Conclusions

The short-term treatment results and follow-up analysis reported herein provide evidence demonstrating the safety of the Wingspan stent system when used as endovascular therapy in a high-risk patient population. The treatment paradigm of predilation by slow inflation of an undersized Gateway PTA balloon catheter followed by deployment of the self-expanding Wingspan stent without postdilation may

have contributed to the favorable procedural and 6-month angiographic outcomes observed in this study.

Appendix

Imaging Core Laboratory: Professor Olav Jansen, MD, Universitätsklinikum Schleswig-Holstein Campus Kiel, Kiel, Germany.

CEC: Professor Olav Jansen, MD, Dr Karsten Alfke, and Dr Robert Stingle, Universitätsklinikum Schleswig-Holstein Campus Kiel, Kiel, Germany.

Participating centers principal investigator (PI), coinvestigator(s) (Co), and study coordinator(s) (SC) in order of enrollment (N):

PI: Hans Henkes, MD; Co: Elina Miloslavski, MD, Jörg Reinartz, MD, Stephan Lowens, MD; SC: Petra Häckmanns-Hanf; Robert Janker Klinik and Alfried Krupp Krankenhaus, Bonn, Germany (15).

PI: Prof Marius Hartmann, MD, PhD; Co: Peter Ringleb, MD, Stefan Hähnel, MD; University of Heidelberg Medical Center, Heidelberg, Germany (9).

PI: Hon Man Liu, MD; Co: Yao-Hung Wang, MD, Ping-Keung Yip, MD; National Taiwan University Hospital, Taipei, Taiwan (4).

PI: Michael Mu Huo Teng, MD; Co: Feng-Chi Chang, MD, Chao-Bao Luo, MD, Han-Hwa Hu, MD, Li-Chi Hsu, MD, Jiing-Feng Lirng, MD, Wen-Jang Wong, MD; Taipei Veterans General Hospital and National Yang Ming University, Taipei, Taiwan (4).

PI: Istvan Szikora, MD; Co: Zsolt Kulcsar, MD, Judit Afra, MD; National Institute of Neurosurgery, Budapest, Hungary (3).

PI: Ansgar Berlis, MD; Co: Prof Martin Schumacher, MD, Stefan Kretzer, MD, Andreas Hetzel, MD; Klinikum der Universität Freiburg, Freiburg, Germany (2).

PI: Jurgen Reul, MD; Co: Simon Holm, MD; SC: Michaela Becker; Kreiskrankenhaus Siegen, Siegen, Germany (2).

PI: Simon C.H. Yu, MD; Co: Prof Lawrence Wong, MD, Thomas Leung, MD; SC: Roxanna Liu; Prince of Wales Hospital, Hong Kong (2).

PI: Prof Michael Forsting, MD; Co: Isabel Wanke, MD, Arnd Dörfler, MD; Universitätsklinikum Essen, Essen, Germany (2).

PI: Matt Lui, MD; Co: Kai Ming Au-Yeung, MD, Raymond Cheung, MD; SC: Kam Wah Lam, Shan Boo Man; Queen Mary Hospital, Hong Kong (1).

PI: Winston Lim, MD; Co: Christopher Chen, MD, Bien Soo Tan, MD, Kiang Hiong Tay, MD; SC: Nelson Wong Chen Ru, Huey Bee Pey; Singapore General Hospital, Singapore. (1).

Acknowledgments

The authors would like to express their gratitude to Birgit Bock of MedPass International, Paris, and Hope Buell of Abbott Laboratory

for their invaluable assistance in the execution of the Wingspan study.

Sources of Funding

The study was sponsored and funded by Boston Scientific Corp.

Disclosures

Dr Arani Bose, Dr Michael Forsting, Dr Marius Hartmann, and Dr Istvan Szikora consult for Boston Scientific Corp. Dr Siu Po Sit was a full-time employee of Boston Scientific during the conduct of this trial. The study sponsor (Boston Scientific) worked with stroke experts to review existing trial evidence, design the trial, choose the investigators, control the allocation schedule, and monitor, analyze, interpret, and present the data. A CEC adjudicated adverse events, and an independent angiographic Core Laboratory analyzed angiographic data. The sponsor could not suppress publication of the report if the results were negative or detrimental to the product under study.

References

- American Heart Association. *Heart Disease and Stroke Statistics—2005 Update*. Dallas, Tex: American Heart Association; 2005:16.
- Sacco RL, Kargman DE, Gu Q, Zamanillo MC. Race-ethnicity and determinants of intracranial atherosclerotic cerebral infarction: the Northern Manhattan Stroke Study. *Stroke*. 1995;26:14–20.
- Thijs VN, Albers GW. Symptomatic intracranial atherosclerosis: outcome of patients who fail antithrombotic therapy. *Neurology*. 2000;55:490–497.
- Chimowitz MI, Kokkinos J, Strong J, Brown MB, Levine SR, Silliman S, Pessin MS, Weichel E, Sila CA, Furlan AJ, Kargman DE, Sacco RL, Wityk RJ, Ford G, Fayad PB, for the Warfarin-Aspirin Symptomatic Intracranial Disease Study Group. The Warfarin-Aspirin Symptomatic Intracranial Disease Study. *Neurology*. 1995;45:1488–1493.
- The Warfarin-Aspirin Symptomatic Intracranial Disease (WASID) Study Group. Prognosis of patients with symptomatic vertebral or basilar artery stenosis. *Stroke*. 1998;29:1389–1392.
- North American Symptomatic Carotid Endarterectomy Trial Collaborators. Beneficial effect of carotid endarterectomy in symptomatic patients with high-grade carotid stenosis. *N Engl J Med*. 1991;325:445–453.
- Barnett HJ, Taylor DW, Eliasziw M, Fox AJ, Ferguson GG, Haynes RB, Rankin RN, Clagett GP, Hachinski VC, Sackett DL, Thorpe KE, Meldrum HE, Spence JD, for the North American Symptomatic Carotid Endarterectomy Trial Collaborators. Benefit of carotid endarterectomy in patients with symptomatic moderate or severe stenosis: North American Symptomatic Carotid Endarterectomy Trial Collaborators. *N Engl J Med*. 1998;339:1415–1425.
- Chimowitz MI, Lynn MJ, Howlett-Smith H, Stern BJ, Hertzberg VS, Frankel MR, Levine SR, Chaturvedi S, Kasner SE, Benesch CG, Sila CA, Jovin TG, Romano JG, for the Warfarin-Aspirin Symptomatic Intracranial Disease Trial Investigators. Comparison of warfarin and aspirin for symptomatic intracranial arterial stenosis. *N Engl J Med*. 2005;352:1305–1316.
- Kasner SE, Chimowitz MI, Lynn MJ, Howlett-Smith H, Stern BJ, Hertzberg VS, Frankel MR, Levine SR, Chaturvedi S, Benesch CG, Sila CA, Jovin TG, Romano JG, Cloft HJ, for the Warfarin Aspirin Symptomatic Intracranial Disease (WASID) Trial Investigators. Predictors of ischemic stroke in the territory of a symptomatic intracranial arterial stenosis. *Circulation*. 2006;113:555–563.
- Mori T, Kazita K, Mori K. Cerebral angioplasty and stenting for intracranial vertebral atherosclerotic stenosis. *AJNR Am J Neuroradiol*. 1999;20:787–789.
- Food and Drug Administration, CDRH. NEUROLINK system summary of safety and probable benefit page. Available at: <http://www.fda.gov/cdrh/pdf/H010004b.pdf>. Last accessed June 19, 2006.
- Lylyk P, Cohen JE, Ceratto R, Ferrario A, Miranda C. Angioplasty and stent placement in intracranial atherosclerotic stenoses and dissections. *AJNR Am J Neuroradiol*. 2002;23:430–436.
- The SSVLVIA Study Investigators. Stenting of symptomatic atherosclerotic lesions in the vertebral or intracranial arteries (SSVLVIA). *Stroke*. 2004;35:1388–1392.
- Higashida RT, Tsai FY, Halbach VV, Dowd CF, Hieshima GB. Cerebral percutaneous transluminal angioplasty. *Heart Dis Stroke*. 1993;2:497–502.
- Clark WM, Barnwell SL, Nesbit G, O'Neill OR, Wynn ML, Coull BM. Safety and efficacy of percutaneous transluminal angioplasty for intracranial atherosclerotic stenosis. *Stroke*. 1995;26:1200–1204.
- Touho H. Percutaneous transluminal angioplasty in the treatment of atherosclerotic disease of the anterior cerebral circulation and hemodynamic evaluation. *J Neurosurg*. 1995;82:953–960.
- McKenzie JD, Wallace RC, Dean BL, Flom RA, Khayata MH. Preliminary results of intracranial angioplasty for vascular stenosis caused by atherosclerosis and vasculitis. *ANJR Am J Neuroradiol*. 1996;17:263–268.
- Terada T, Higashida RT, Halbach VV, Dowd CF, Nakai E, Yokote H, Itakura T, Hieshima GB. Transluminal angioplasty for arteriosclerotic disease of the distal vertebral and basilar arteries. *J Neurol Neurosurg Psychiatry*. 1996;60:377–381.
- Callahan AS III, Berger BL. Balloon angioplasty of intracranial arteries for stroke prevention. *J Neuroimag*. 1997;7:232–235.
- Takis C, Kwan ES, Pessin MS, Jacobs DH, Caplan LR. Intracranial angioplasty: experience and complications. *ANJR Am J Neuroradiol*. 1997;18:1661–1668.
- Mori T, Fukuoka M, Kazita K, Mori K. Follow-up study after intracranial percutaneous transluminal cerebral balloon angioplasty. *ANJR Am J Neuroradiol*. 1998;19:1525–1533.
- Connors JJ III, Wojak JC. Percutaneous transluminal angioplasty for intracranial atherosclerotic lesions: evolution of technique and short-term results. *J Neurosurg*. 1999;91:415–423.
- Eckard DA, Zarnow D, McPherson CM, Siegel EL, Eckard VR, Batnitzky S, Hermreck A. Intracranial internal carotid artery angioplasty: technique with clinical and radiographic results and follow-up. *ANJR Am J Neuroradiol*. 1999;172:703–707.
- Marks MP, Wojak JC, Al-Ali F, Jayaraman M, Marcellus ML, Connors JJ, Do HM. Angioplasty for symptomatic intracranial stenosis: clinical outcome. *Stroke*. 2006;37:1016–1020.
- Alazzaz A, Thornton J, Aletich VA, Debrun GM, Ausman JJ, Charbel F. Intracranial percutaneous transluminal angioplasty for arteriosclerotic stenosis. *Arch Neurol*. 2000;57:1625–1630.
- Nasher HC, Henkes H, Weber W, Berg-Dammer A, Kuhne D. Intracranial vertebrobasilar stenosis: angioplasty and follow-up. *ANJR Am J Neuroradiol*. 2000;21:1293–1301.
- Gress DR, Smith WS, Dowd CF, Halbach VV, Finley RJ, Higashida RT. Angioplasty for intracranial symptomatic vertebrobasilar ischemia. *Neurosurgery*. 2002;51:23–29.
- Samuels OB, Joseph GL, Lynn MJ, Smith HA, Chimowitz MI. A standardized method for measuring intracranial arterial stenosis. *AJNR Am J Neuroradiol*. 2000;21:643–646.
- Albers GW, Easton JD, Sacco RL, Teal P. Antithrombotic and thrombolytic therapy for ischemic stroke. *Chest*. 1998;114:683S–698S.
- Moufarrij NA, Little JR, Furlan JA, Leatherman JR, Williams GW. Basilar and distal vertebral artery stenosis: long-term follow-up. *Stroke*. 1986;17:938–942.
- Mazighi M, Tanasescu R, Ducrocq X, Vicaut E, Bracard S, Houdart E, Woimant F. Prospective study of symptomatic atherothrombotic intracranial stenoses: the GESICA Study. *Neurology*. 2006;1187–1191.