

A PET study on brain control of micturition in humans

Bertil F. M. Blok¹, Antoon T. M. Willemsen² and Gert Holstege¹

¹Department of Anatomy and Embryology, Faculty of Medical Sciences, University of Groningen, ²Groningen PET Center, University Hospital Groningen, Groningen, The Netherlands

Correspondence to: Bertil F. M. Blok, Department of Anatomy and Embryology, Faculty of Medical Sciences, University of Groningen, Oostersingel 69, 9713 EZ Groningen, The Netherlands

Summary

Although the brain plays a crucial role in the control of micturition, little is known about the structures involved. Identification of these areas is important, because their dysfunction is thought to cause urge incontinence, a major problem in the elderly. In the cat, three areas in the brainstem and diencephalon are specifically implicated in the control of micturition: the dorsomedial pontine tegmentum, the periaqueductal grey, and the preoptic area of the hypothalamus. PET scans were used to test whether these areas are also involved in human micturition. Seventeen right-handed male volunteers were scanned during the following four conditions: (i) 15 min prior to micturition during urine withholding; (ii) during micturition; (iii) 15 min after micturition; (iv) 30 min after micturition. Ten of the 17 volunteers were able to micturate during scanning. Micturition was associated with increased blood flow in the right dorsomedial pontine tegmentum, the periaqueductal

grey, the hypothalamus and the right inferior frontal gyrus. Decreased blood flow was found in the right anterior cingulate gyrus when urine was withheld. The other seven volunteers were not able to micturate during scanning, although they had a full bladder and tried vigorously to do so. In this group, during these unsuccessful attempts to micturate, increased blood flow was found in the right ventral pontine tegmentum, which corresponds with the hypothesis, formulated from results in cats, that this area controls the motor neurons of the pelvic floor. Increased blood flow was also found in the right inferior frontal gyrus during unsuccessful attempts at micturition, and decreased blood flow in the right anterior cingulate gyrus was found during the withholding of urine. The results suggest that, as that of the cat, the human brainstem contains specific nuclei responsible for the control of micturition, and that the cortical and pontine micturition sites are predominantly on the right side.

Key words: right pontine tegmentum; periaqueductal grey; hypothalamus; right anterior cingulate gyrus; right inferior frontal gyrus

Abbreviations: ANCOVA = analysis of covariance; BA = Brodmann area; MPO = medial preoptic area; PAG = periaqueductal grey; PMC = pontine micturition centre; rCBF = regional cerebral blood flow; SPM = statistical parametric mapping

Introduction

It is generally accepted that the brain plays a crucial role in normal micturition, but in humans little is known about which specific brain areas are involved. This lack of knowledge is the more surprising, since it is highly probable that dysfunction of certain brain areas causes incontinence in many elderly people (Andrew and Nathan, 1964; Blaivas, 1982). Incontinence in the elderly is a major social problem. At least 10 million adults in the United States (Consensus Conference, 1989), up to 30% of elderly citizens (age ≥ 60 years) residing in the community (Teasdale *et al.*, 1988) and

over 50% of those living in care (Resnick *et al.*, 1989) suffer from urinary incontinence, in particular urge incontinence (Jewett *et al.*, 1981; Ouslander *et al.*, 1982). In 1987 the direct annual costs for care of patients with incontinence were estimated to exceed \$10.3 billion in the United States alone (Consensus Conference, 1989).

Urge incontinence occurs when patients sense the urge to void, but are unable to delay it long enough to reach the toilet (Consensus Conference, 1989). In healthy individuals this 'urge' is not immediately followed by micturition and it

usually disappears when micturition is not appropriate at that particular time and place. Urge incontinence is also frequently found in patients with stroke (Khan *et al.*, 1981) or with CNS diseases, such as multiple sclerosis (Blaivas *et al.*, 1979). Urge incontinence should not be confused with genuine stress incontinence, which is not the result of lesions in the CNS and will not be discussed in this study. In humans, complete interruption of the brainstem–sacral cord pathways always results in unco-ordinated contractions of bladder and sphincter (i.e. bladder–sphincter dyssynergia; Blaivas, 1982). Patients with brain lesions rostral to the pons never show bladder–sphincter dyssynergia, but may suffer from urge incontinence (Blaivas, 1982). Apparently, micturition, as such, is not co-ordinated by regions in the spinal cord, but in the caudal brainstem. The beginning of micturition, however, is determined by regions in the forebrain. Evidence from animal experiments supports this conclusion. The experiments of Blok and Holstege (1994) and Blok *et al.* (1995) in the cat have led to a concept for the micturition reflex (Fig. 1).

The pelvic nerve conveys information about the degree of bladder filling to neurons in the lumbosacral cord (Morgan *et al.*, 1981), which, in turn, project to the periaqueductal grey (PAG) (Noto *et al.*, 1991; Blok *et al.*, 1995; VanderHorst *et al.*, 1996), a midbrain area known for its role in nociception and emotional responses (Depaulis and Bandler, 1991; Holstege, 1995). When the bladder is filled to such a degree that voiding is appropriate, the PAG, according to this concept, activates an area in the dorsomedial pontine tegmentum, referred to as the pontine micturition centre (PMC) or M-region (Blok and Holstege, 1994), which produces complete (synergic) micturition via long descending pathways to the parasympathetic bladder motor neurons in the sacral cord (Holstege *et al.*, 1979, 1986).

In the cat, stimulation of forebrain structures, including the anterior cingulate gyrus, preoptic area of the hypothalamus, amygdala, bed nucleus of the stria terminalis and septal nuclei, have been shown to elicit bladder contractions (Gjone and Setekleiv, 1963; Gjone, 1966). All these structures give rise to descending pathways to the PAG and other regions belonging to the so-called emotional motor system (Holstege, 1995), but only one, the medial preoptic area (MPO), being the rostral part of the hypothalamus, projects directly to the PMC or M-region (Holstege, 1987). Possibly, the MPO plays a role in the start of micturition.

Another pontine area has been implicated in the maintenance of continence. This area, called the L-region, is located more laterally and ventrally than the PMC or M-region, and maintains direct projections to the nucleus of Onuf in the sacral cord (Holstege *et al.*, 1979, 1986). Onuf's nucleus contains motor neurons innervating the pelvic floor, including the anal and urethral sphincters (Sato *et al.*, 1978). In the cat, bilateral lesions in the L-regions cause an extreme form of 'urge' incontinence (Holstege *et al.*, 1986; Griffiths *et al.*, 1990).

PET is a non-invasive technique used to study changes in

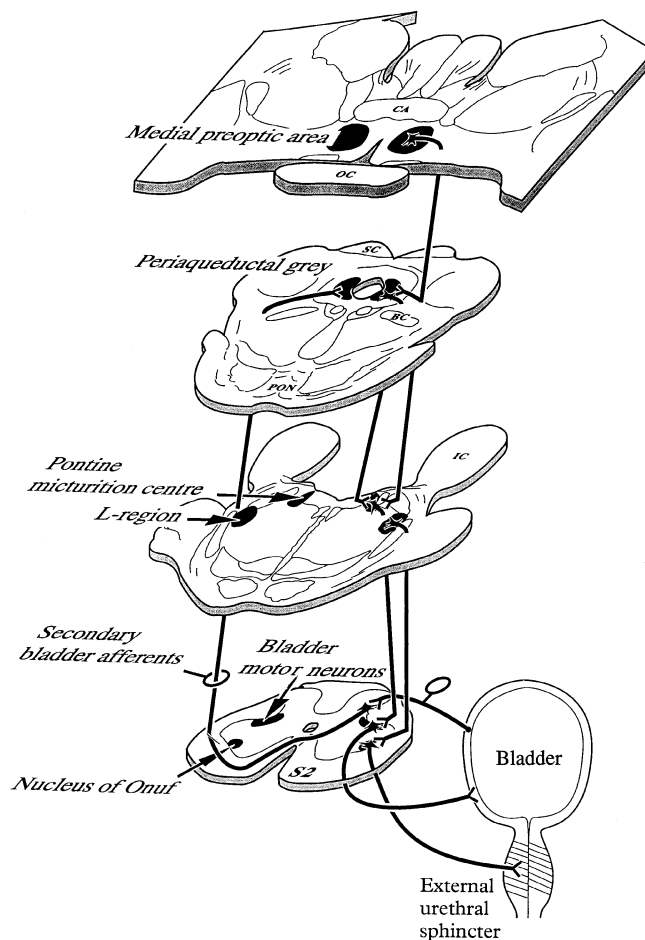


Fig. 1 A schematic overview of the spinal and supraspinal structures involved in the control of micturition based on experiments in the cat. The locations of the micturition control areas (see text) in the brainstem and diencephalon were used in the null hypotheses for the present study in humans. Pathways are indicated on one side only. BC = brachium conjunctivum; CA = anterior commissure; IC = inferior colliculus; OC = optic chiasm; PON = pontine nuclei; SC = superior colliculus; S2 = second sacral segment.

regional cerebral blood flow (rCBF) in humans performing specific tasks (Fox and Mintun, 1989). The rCBF is used as an index of the presynaptic activity in the area under consideration (Jueptner and Weiller, 1995). In the present PET study we tested the hypothesis that the same brain areas are active in humans during micturition, as those in the cat. Therefore, areas in the brainstem and diencephalon, such as the PMC, PAG and the MPO of the hypothalamus, received special attention. Additional areas, other than those implicated by the cat experiments, were investigated too. However, because of the limitation of the detection field of the camera areas located at the top of the brain were not scanned.

Methods

Subjects

In all experiments, the volunteers completed a general health questionnaire. No subject reported a history of neurological,

Table 1 Subjects

Subject	Age (years)	Micturition initiation, time after start of Scan 2 (s)
A	25	28
B	28	11
C	23	No micturition
D	46	-2
E	31	No micturition
F	43	1
G	22	15
H	23	0
I	50	13
J	29	No micturition
K	45	No micturition
L	26	No micturition
M	22	25
N	49	0
O	41	No micturition
P	42	-2
Q	21	No micturition
Mean	32.3	

psychiatric or urologic illnesses. All subjects were exclusively right-handed, and gave their written, informed consent according to the declaration of Helsinki. The protocol of the study was approved by the research-ethics committee of the University Hospital of Groningen.

Experimental design

Brain activation was measured in 17 right-handed male volunteers (age range 21–50 years; mean age 32 years; *see* Table 1). During each scan, the lights were dimmed and the subjects had their eyes closed and did not move. During each session, which lasted 1.5 h in total, scans were carried out under the following four conditions: Scan 1 was with a filled bladder, 15 min prior to micturition (the 'withholding' scan); Scan 2 was just after the command to start micturition (micturition scan); Scan 3 was 15 min after micturition (first empty-bladder scan); Scan 4 was 30 min after micturition (second empty-bladder scan).

Before Scan 1, all volunteers affirmed that their bladder was full. The right index finger of the volunteer was touched to indicate that they could start micturition 15 s after the beginning of injection of the H₂¹⁵O bolus and 8 s before Scan 2. No specific assignment was given prior to the other three scans.

A few days before the scanning session, the volunteers were asked to practise urinating in a horizontal position. All volunteers reported that they had no problems in emptying their bladders during such a practice session. During the training and the scanning session, a self-adhesive external condom catheter was used which was attached to the volunteer's penis and connected to a plastic bag to collect the urine.

Data acquisition

The subjects were placed in a horizontal position in the PET camera (Siemens-CTI 951/31, Knoxville, Tenn., USA) parallel to, and 5 cm below, the glabella–inion line as determined by external examination. Because of the technical characteristics of the PET camera, the most caudal limit of the scanned area was the pons, and the most rostral limit was the cingulate gyrus. This resulted in images extending between 28 mm below and 44 mm above the intercommissural plane. This implied, for example, that the motor cortex was not included in the investigated brain regions.

An individually constructed head mould was used to minimize changes in head position from one scan to another. First, a transmission scan of 20 min was made for attenuation correction of the emission scans and then the four main scans were carried out. Before each scan, the subjects were given 1.85 GBq of H₂¹⁵O in saline. The H₂¹⁵O bolus, followed by 40 ml saline, were injected into the right brachial vein from an automatic pump. Data acquisition was initiated 23 s after the beginning of the injection, at which time the peak in radioactivity was assumed to reach the cerebral circulation, and it was continued for 90 s. To allow the radiation to return to background levels, there were 15 min intervals between the injections.

Data analysis

The data were sampled using a voxel size of 2.2×2.2×2.4 mm³. They were analysed using the Statistical Parametric Mapping procedure (SPM95 from the Wellcome Department of Cognitive Neurology, London, UK) implemented in Matlab (Mathworks Inc., Sherborn, Mass., USA) on a SPARC workstation (Sun Microsystems Inc., Surrey, UK). The SPM95 software was used for anatomical realignment, normalization and smoothing of the data, and then for statistical analysis.

Anatomical realignment

The rCBF was reconstructed for each scan, using an attenuation correction based on the preliminary transmission scan. Movement-related components between scans were corrected during the realignment, using the first recorded scan from each subject as a reference.

Normalization

Following realignment, all images were transformed into a stereotactic standard space (Talairach and Tournoux, 1988). This normalizing spatial transformation matches each scan to a reference or template image that conforms to the standard space (Friston *et al.*, 1991a). Stereotactic normalization of PET images allows comparison of scan data in identical pixels across different subjects and scans.

Smoothing

Prior to the statistical analysis, the scans were smoothed in order to increase the signal-to-noise ratio and to suppress effects due to residual differences in functional and gyral anatomy between subjects during inter-subject averaging. During smoothing, a Gaussian filter of $8 \times 8 \times 8$ mm³ was used (full width, half maximum in the *x*-, *y*- and *z*-axes, respectively). This relatively small filter was used because the main part of the study was aimed at the relatively small brainstem and diencephalon.

Statistical analysis

Differences in global activity within and between subjects were removed by analysis of covariance (ANCOVA) on a pixel-by-pixel basis with global counts as covariate. This was done because inter- and intra-subject differences in global activity may obscure regional alterations in activity following cognitive processes (Friston *et al.*, 1990). For each pixel in the stereotactic space, the ANCOVA generated a condition-specific adjusted mean rCBF value (normalized to 50 ml/dl/min) and an associated adjusted error variance. A repeated-measures ANCOVA was used for the comparison of the second micturition scan (Scan 4) with the other scans, each subject being studied under all conditions. The ANCOVA allows comparison of the means across conditions using the *t* statistic. The resulting set of *t* values constitutes a statistical parametric map [SPM{*t*}; Friston *et al.*, 1991b]. During analysis, special attention was put on the expected micturition control areas in the diencephalon and brainstem, i.e. the PMC, PAG and hypothalamus, including the MPO. An uncorrected *P* value of 0.001 was used for these areas since the exact location could be predicted on the basis of cat experiments. This (omnibus) approach can be used when the location of the area, in which activation is expected, is known (Friston *et al.*, 1991b). Trends in activation in the expected micturition control areas are reported when they reach a significance level of *P* < 0.005. This level of significance gives sufficient protection against false positives (Warburton *et al.*, 1996). Other brain areas observed to be activated were considered statistically significant only after a correction for multiple comparisons (corrected threshold *P* < 0.05); this is necessary when there is no preconceived hypothesis (Friston *et al.*, 1991b).

Results

Ten of the 17 volunteers were able, as requested, to urinate within 30 s after the beginning of Scan 2, i.e. within 53 s after the injection of H₂¹⁵O (Table 1).

The collected urine volume was 567 ± 267 ml (mean \pm SD). The results obtained in this group will be referred to as 'Micturition successful'.

The other seven volunteers tried to urinate during scanning,

but did not succeed (Tables 1 and 2). However, these seven were able to micturate within 5 min of finishing Scan 2 (mean urine volume = 712 ± 234 ml).

The scanning data from this group were analysed separately and the results are reported under the heading 'Micturition unsuccessful'.

Micturition successful

The activated brain areas of the 10 subjects of this group are presented in Table 3. The overall activation, revealed by comparing activation during successful micturition (Scan 2) with that recorded during the withholding of urine (Scan 1), is shown in Fig. 2.

During micturition, the rCBF was significantly increased (uncorrected *P* < 0.001) in the PAG and hypothalamus and on the right in the dorsomedial pontine tegmentum (Figs 2 and 3). The activation in the hypothalamus appeared to be located predominantly in its rostral part (Fig. 4).

Of the cortex cerebri, only the right inferior frontal gyrus [Brodmann areas (BA) 45 and 47, and the most dorsal tip of BA 44] and the right anterior cingulate gyrus (BA 24 and 32) were significantly more activated during micturition than in the urine withholding phase (corrected *P* < 0.05). The right medial temporal gyrus (BA 21) and the rostral striatum were also more active, although not significantly for multiple comparisons.

Comparing successful micturition (Scan 2) with the conditions 15 and 30 min after micturition (Scans 3 and 4), similar results were obtained. During micturition, the rCBF increased (uncorrected *P* < 0.001) in the same areas as it did when micturition (Scan 2) was compared with urine withholding (Scan 1). Exceptions were the anterior cingulate gyrus and the rostral striatum, which did not show any statistically significant difference in activity (Table 3).

A significant increase in activity was found in the anterior cingulate gyrus (corrected *P* < 0.05) when the bladder was empty (Scans 3 and 4) compared with when the urine was being withheld (Scan 1).

Decreases in rCBF were also found. During micturition (Scan 2) compared with Scan 1 or with Scans 3 or 4, decreased rCBF was found in the left inferior and medial frontal gyri (BA 9 and 44; peak activation -42 , $+10$, $+32$; *Z* score = 3.1) and the left medial temporal gyrus (BA 21; peak activation -56 , -48 , -8 ; *Z* score = 3.2). However, these differences were not significant after correction for multiple comparisons (corrected *P* < 0.05).

Micturition unsuccessful

In the unsuccessful micturition group, increased rCBF was found in distinct brain areas during Scan 2 when the volunteers tried hard to micturate, but failed, compared with the empty-bladder condition (Scans 3 and 4). Prior to the statistical analysis, it was hypothesized that the ventrolateral pons would be activated during the unsuccessful micturition (Scan

Table 2 Study design

Subjects (<i>n</i>)	Scan 1	Scan 2	Scan 3	Scan 4
Group 1 (10)	Withholding urine	Micturition successful	Empty bladder for 15 min	Empty bladder for 30 min
Group 2 (7)	Withholding urine	Micturition unsuccessful	Empty bladder for 15 min	Empty bladder for 30 min

All subjects in Group 2 (unable to micturate when requested: micturition unsuccessful) were able to micturate within 5 min of completion of the second scan.

Table 3 Results from Group 1 subjects (successful micturition during Scan 2)

	Peak position (<i>x</i> , <i>y</i> , <i>z</i>) (mm)	Min/max of <i>z</i> (mm)***	%rCBF increase	Z-score
Micturition successful—withholding urine (Scan 2 – Scan 1)				
Right hemisphere				
Inferior frontal gyrus (BA 44, 45, 47)	+52, +16, +4	-8/+12	10.0	5.5*
Anterior cingulate gyrus (BA 24, 32)	+12, +32, +16	0/+28	7.9	4.5*
Medial temporal gyrus (BA 21)	+50, -2, -12	-24/-4	4.9	4.2
Left hemisphere				
Striatum	-22, +22, +4	0/+4	7.3	3.6
Diencephalon and brainstem				
Hypothalamus	-4, -4, -4	-8/+4	8.2	4.0
Periaqueductal grey	+4, -34, -12	-12/-4	7.1	3.7
Right dorsomedial pons	+10, -42, -24	-28/-24	7.7	3.4
Micturition successful—empty bladder (Scan 2 – Scan 3)				
Right hemisphere				
Inferior frontal gyrus (BA 45, 47)	+48, +26, -4	-8/+4	11.9	4.6*
Medial temporal gyrus (BA 21)	+50, -2, -12	-28/-4	4.4	3.1
Diencephalon and brainstem				
Hypothalamus	-4, -4, -4	-8/0	6.5	3.4
Periaqueductal grey	+4, -34, -12	-12/-8	5.5	3.1
Right dorsomedial pons	+10, -42, -24	-24	6.1	2.6**
Empty bladder—withholding urine (Scan 3 – Scan 1)				
Right hemisphere				
Anterior cingulate gyrus (BA 24, 32)	+8, +36, -4	-8/+20	10.5	5.4†
Medial temporal gyrus (BA 21)	+50, -18, 0	0/+4	4.7	4.1

The location of the peak activation is indicated by *x*, *y* and *z* coordinates, according to the atlas of Talarach and Tournoux (1988). The differences between Scan 2 (micturition successful) and Scan 4 (30 min after bladder emptying) were in the same range as those between Scans 2 and 3 (15 min after emptying bladder), and are not shown. BA = Brodmann area. *Significant after a correction for multiple comparisons with a threshold of $P < 0.05$; **significant for an uncorrected threshold of $P < 0.004$; ***extent in *z*-axis is based on an uncorrected threshold of $P < 0.001$, unless otherwise indicated.

2). Previously, this area has been implicated in the process of maintaining continence on the basis of cat experiments. Indeed, increased activation (uncorrected $P < 0.0001$) was found in the right ventral pons (peak activation $x = +8$ mm, $y = -28$ mm, $z = -28$ mm; Z score = 3.7; extent in *z*-axis relative to the AC-PC line (the line between the anterior and posterior commissure): -24 to -28 mm (on the basis of an uncorrected threshold of $P < 0.001$); see Fig. 5, right).

In the right inferior frontal gyrus (BA 45 and 47; peak activation $x = +50$, $y = +26$, $z = 0$; Z score = 4.3; extent in *z*-axis 0 to +4 mm) an activation was found also, but this was not significant after a correction for multiple comparisons (corrected $P < 0.05$).

Comparing Scan 2 with Scan 1, which was carried out

during the withholding of urine, a slight increase (uncorrected $P < 0.002$) in the rCBF was found during Scan 2 in the right ventral pons (peak activation $x = +8$, $y = -28$, $z = -28$; Z score = 2.9). Furthermore, a significant difference (corrected $P < 0.05$) was observed in the right anterior cingulate gyrus (BA 24 and 32; peak activation $x = +10$, $y = +20$, $z = +24$; Z-score = 4.7; extent in *z*-axis +24 to +28 mm). Remarkably, the location of the activated area was more posterior and superior than when successful micturition was compared with withholding of urine (Fig. 6 at the bottom).

In the inferior frontal gyrus (BA 45 and 47; peak activation, $x = +50$, $y = +26$, $z = 0$; Z score = 3.4; extent in *z*-axis 0 to +4 mm) an increase in rCBF was found, but after

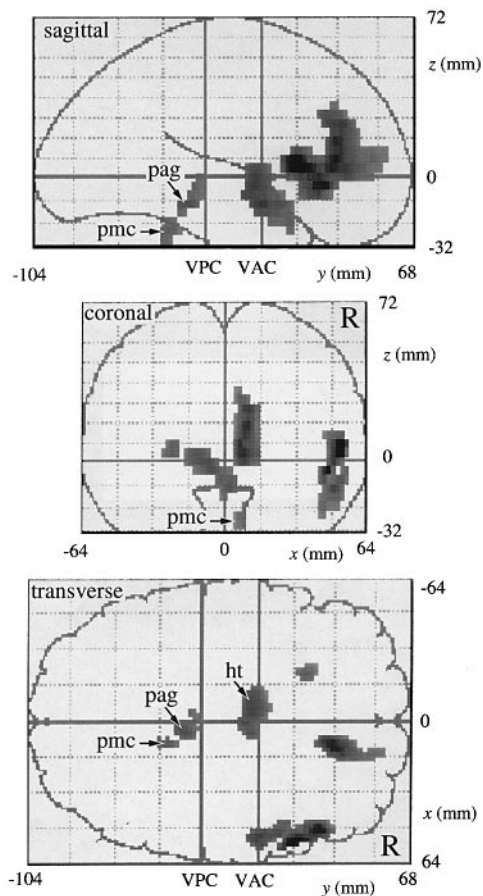


Fig. 2 Differences in rCBF, comparing successful micturition with voluntary withholding of urine (Scan 2–Scan 1; average of 10 subjects). Pixels that are significant at the threshold of an uncorrected $P < 0.002$ are displayed on single sagittal, coronal and transverse projections of the brain. The numbers refer to the distance (in mm) relative to the intercommissural plane. The activation of the expected micturition control areas have been indicated by arrows. R = right side of the brain; VAC = vertical line through the anterior commissure; VPC = vertical line through the posterior commissure; pmc = pontine micturition centre; pag = periaqueductal grey; ht = hypothalamus.

correction for multiple comparisons (corrected $P < 0.05$) it appeared to be non-significant.

Comparing Scan 3 (empty bladder for 15 min) with Scan 1 (withholding urine), a significant difference (corrected $P < 0.05$) was found in the right anterior cingulate gyrus (BA 24 and 32; peak activation $x = +8$, $y = +24$, $z = +24$; Z score = 4.6; extent in z-axis +20 to +28 mm).

Discussion

The present study demonstrates, for the first time, that specific human brain structures have an increased rCBF during micturition. In all likelihood, these areas are involved in micturition control. There are not many studies on the CNS control of micturition in humans. Based on studies on patients with lesions in brain and spinal cord, Blaiwas (1982) concluded that the coordination between the bladder

(detrusor) and the urethral sphincter takes place in the pons, similar to the organization observed during micturition in the cat (Holstege *et al.*, 1986; Griffiths *et al.*, 1990). This led us to pay special attention to the brainstem in the present PET study. In general, the results indicate that micturition in the humans seems to be organized in the brainstem in very much the same way as in the cat (Fig. 1). In the following discussion, each of the various brain structures which have been highlighted in this PET study will be discussed separately.

Areas involved in micturition

Dorsomedial pontine tegmentum

A distinct area in the dorsomedial pontine tegmentum was activated during micturition (Scan 2) when compared with the withholding of urine (Scan 1) or an empty bladder (Scans 3 and 4).

Retrograde and anterograde tracing studies have shown that, in the rat and cat, a cell group exists in the dorsomedial pons, which is associated with micturition. This has been referred to as the pontine micturition centre (PMC; Loewy *et al.*, 1979), the M-region (Holstege *et al.*, 1986) and Barrington's nucleus (Barrington, 1925). Cells in this region project directly to the sacral intermediolateral cell column (Holstege *et al.*, 1979; Loewy *et al.*, 1979; Holstege *et al.*, 1986), which contains the parasympathetic motor neurons innervating the bladder. In the cat, electrical stimulation of the PMC produces an immediate and sharp decrease in urethral pressure and pelvic floor electromyogram, followed in ~2 s by a steep rise in the intravesical pressure, mimicking complete micturition. Bilateral lesions in the PMC result in urinary retention, during which detrusor activity is depressed and bladder capacity increases (Holstege *et al.*, 1986; Griffiths *et al.*, 1990). The present PET results strongly suggest that a similar group of neurons exists in the dorsomedial pons of humans.

The periaqueductal grey

In humans, the midbrain PAG appears to be more active during micturition than when urine is withheld or the when the bladder is empty. In the cat, electrical stimulation of the PAG has been shown to evoke complete micturition (Skultety, 1959), facilitate bladder reflexes and reduce bladder capacity (Kruse *et al.*, 1990). The PAG receives fibres from the sacral cord (Blok *et al.*, 1995; VanderHorst *et al.*, 1996), which possibly conveys information concerning the degree of bladder filling. In turn, the PAG sends fibres to the PMC (Blok and Holstege, 1994).

A previous human PET study showed that the PAG is also involved in the perception of visceral pain which appears in angina pectoris (Rosen *et al.*, 1994). The present PET results suggest that, in humans, the PAG is also important in the control of micturition.

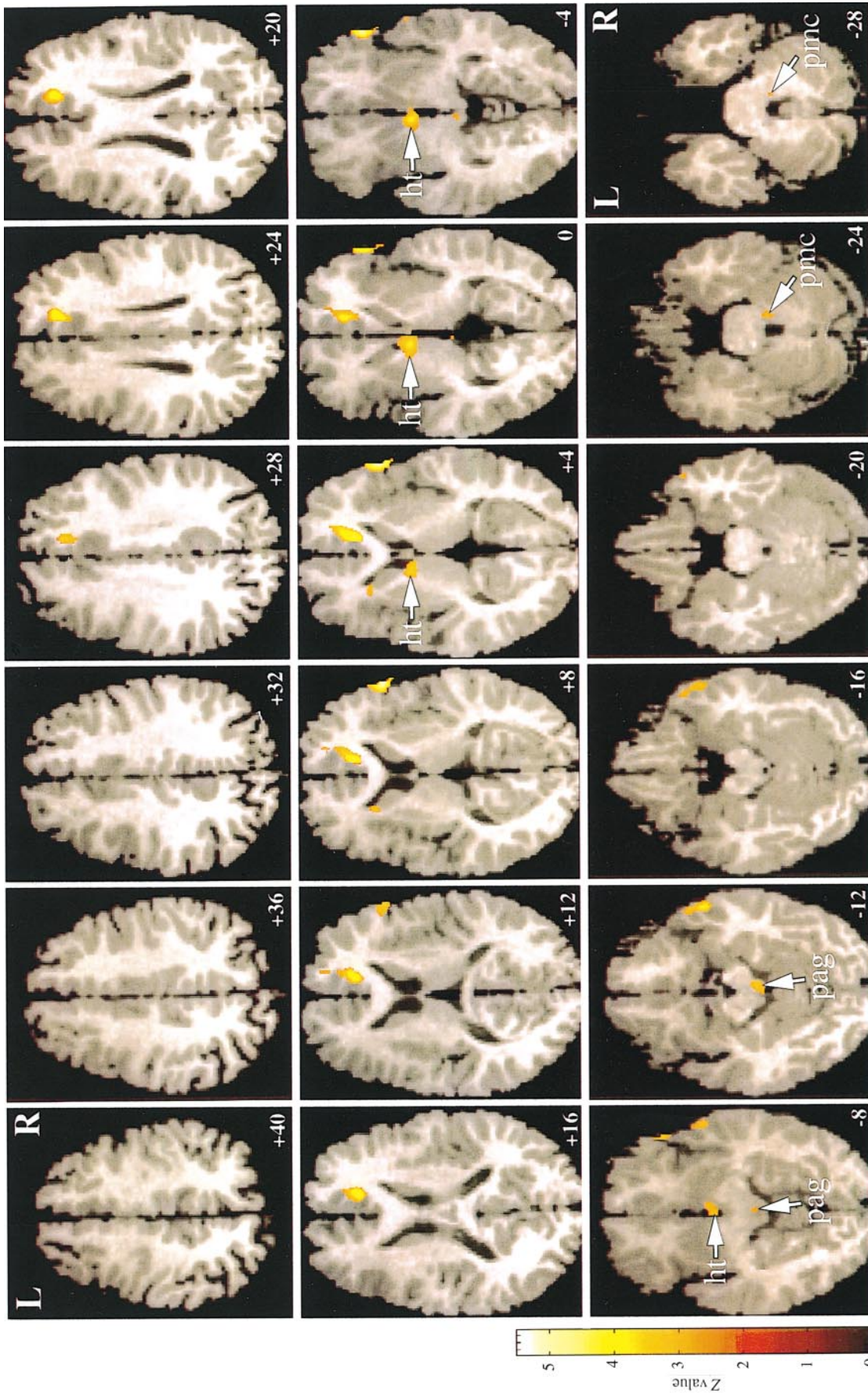


Fig. 3 Regions with a significantly higher rCBF during successful micturition (Scan 2) than during the withholding of urine (Scan 1). An uncorrected threshold of $P < 0.002$ (micturition, successful minus withholding of urine) was used for display. The differences have been superimposed onto averaged MRI scans which have been transformed stereotactically to fit a standard atlas (Talairach and Tournoux, 1988). The numbers refer to the distance (in mm) relative to the intercommissural plane. Significant activation was observed in the same three areas as have been demonstrated in the cat to be involved in micturition control: the dorsomedial pontine tegmentum (indicated by pmc), the periaqueductal grey (pag), and the hypothalamus (ht). Significant activation was also observed on the right in the anterior cingulate gyrus, inferior frontal gyrus and medial temporal gyrus, and on the left in the rostral striatum. Of these regions, only the anterior cingulate gyrus and the inferior frontal gyrus appeared to be statistically significant after a correction for multiple comparisons (corrected $P < 0.05$). L = left side of the brain; R = right side of the brain.

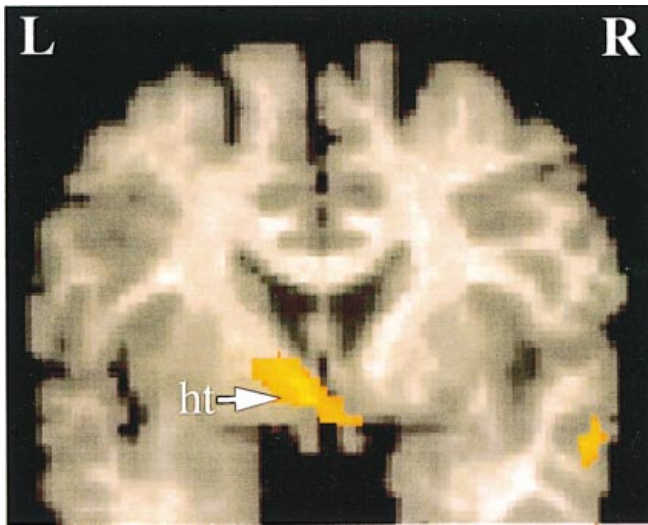


Fig. 4 The activation of the hypothalamus (ht) as seen on the coronal section ($y = -4$ mm relative to the anterior commissure), comparing successful micturition with voluntary withholding of urine (Scan 2 – Scan 1; average of 10 subjects). The peak activation seems to be located just ventral to the anterior commissure in the preoptic area of the hypothalamus. The activation in the right temporal lobe was not significant after a correction for multiple comparisons. An uncorrected threshold of $P < 0.002$ was used for display. For the Z score scale see Fig. 3. ht = hypothalamus.

The hypothalamus

Hypothalamic involvement in micturition control in humans, as implicated by our results, has also been demonstrated in the cat (Tang and Ruch, 1956). In the cat, stimulation of forebrain structures, including the anterior cingulate gyrus, preoptic area of the hypothalamus, amygdala, bed nucleus of the stria terminalis and septal nuclei, elicits bladder contractions (Gjone and Setekleiv, 1963; Gjone, 1966). All these structures give rise to descending pathways to the PAG and other regions belonging to the so-called ‘emotional motor system’ (Holstege, 1995; Blok and Holstege, 1996). Only the preoptic area, being the rostral part of the hypothalamus, has been shown to project directly onto the PMC (Holstege, 1987).

Although our PET results suggest that the preoptic area also plays an important role in human control of micturition, its exact role is unknown. One might speculate that the direct influence of the preoptic area on the PMC determines the beginning of micturition. Whether or not micturition takes place is always related to the environment in which the individual is situated. In other words, when a full bladder signals, via fibres to the sacral cord and the PAG, that micturition should occur, it only takes place when forebrain structures have ‘decided’ that the situation is safe enough.

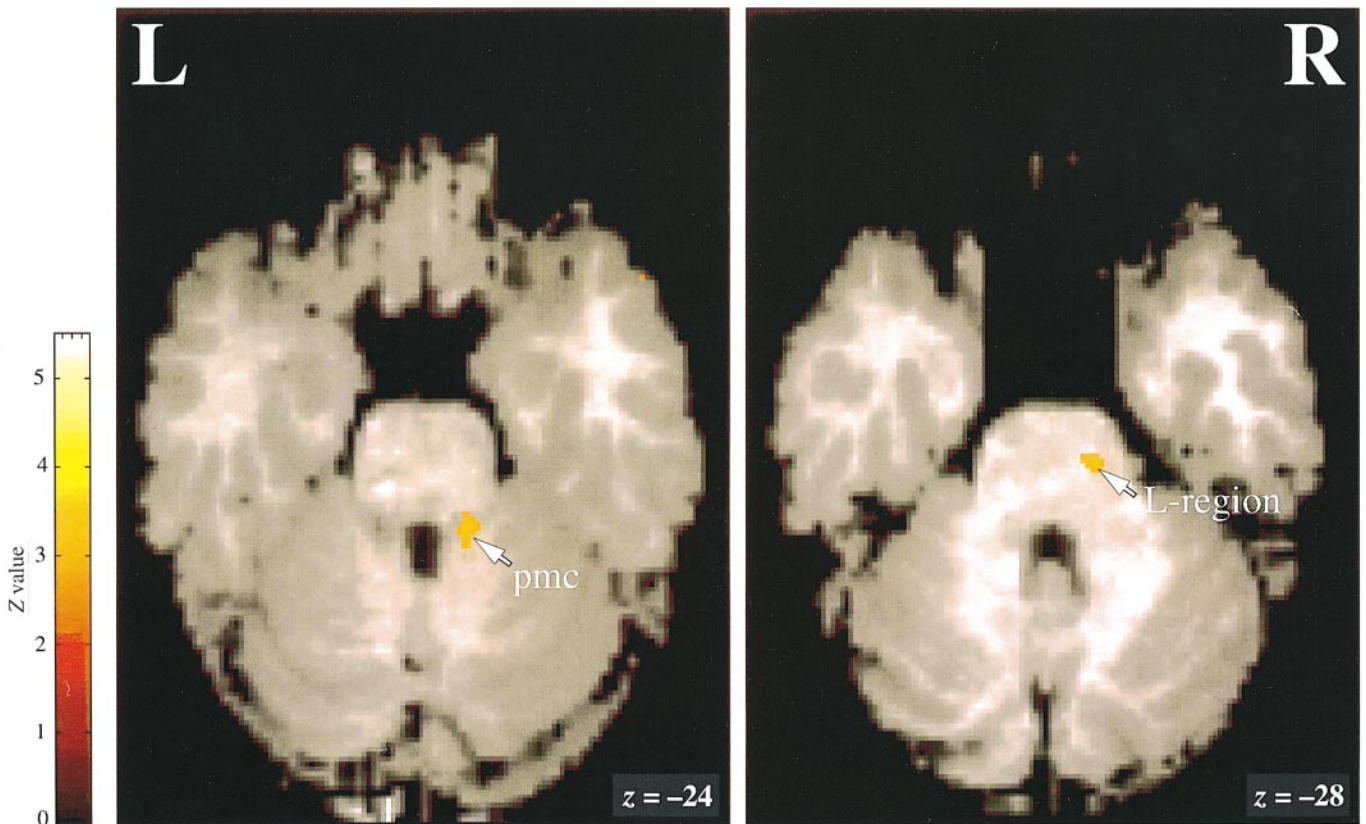


Fig. 5 *Left*: significant differences in rCBF in the right dorsomedial tegmentum (indicated by pmc), comparing successful micturition with voluntary withholding of urine (Scan 2 – Scan 1; average of 10 subjects). *Right*: significant differences in rCBF in the right ventral tegmentum (indicated by L-region), comparing unsuccessful micturition with an empty bladder, 15 min after micturition (Scan 2–Scan 3; average of seven subjects). Uncorrected threshold of $P < 0.002$.

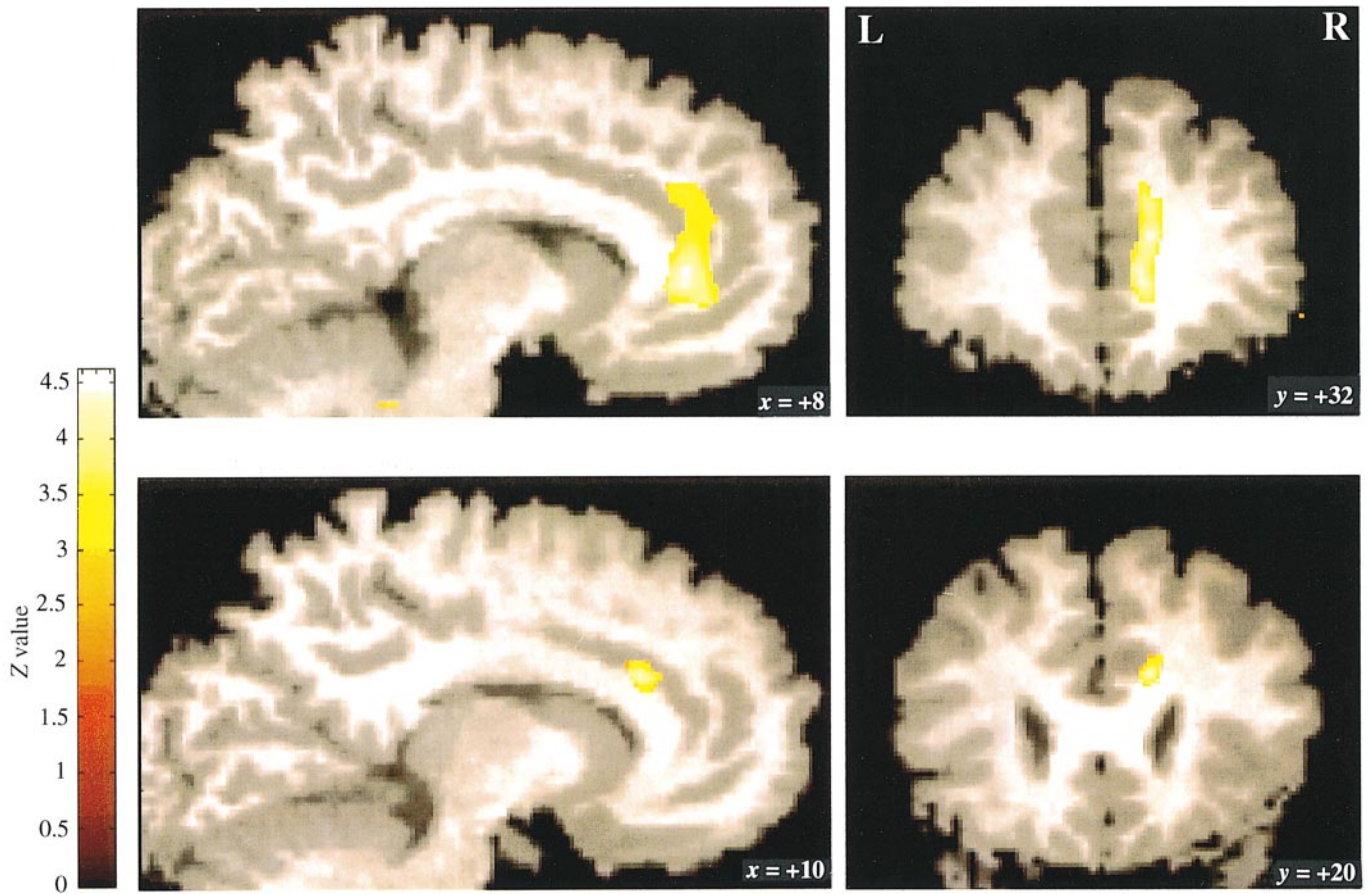


Fig. 6 *Top*: significant differences in rCBF in the anterior cingulate gyrus, comparing successful micturition with voluntary withholding of urine (Scan 2 – Scan 1; average of 10 subjects). *Bottom*: significant difference in rCBF in the anterior cingulate gyrus, comparing unsuccessful micturition with voluntary withholding of urine (Scan 2 – Scan 1; average of seven subjects). Uncorrected threshold of $P < 0.001$.

Right inferior frontal gyrus

The present results demonstrate that the right inferior frontal gyrus is significantly activated during micturition. The same region is involved in attention mechanisms (Pardo *et al.*, 1991) and response selection (Jenkins *et al.*, 1994). With respect to micturition, this region might play a role in making the decision as to whether or not micturition should take place at that particular time and place.

Right anterior cingulate gyrus

The rCBF in the right anterior cingulate gyrus was significantly decreased during the withholding of urine (Scan 1) compared with successful micturition (Scan 2) or an empty bladder (Scans 3 and 4). Possibly, this decrease in rCBF in the anterior cingulate gyrus during withholding of urine (Scan 1) reflects a general suppression of sensory input and motor output in order to suppress the sensation of a filled bladder and subsequent urge to void. Additionally, the rCBF during withholding of urine (Scan 1) is also lower in this area than when the bladder is empty (Scans 3 and 4). Apparently, the relatively high rCBF during Scans 2, 3 and 4 was not specific for response selection or attention, because that was only the

case during Scan 2 and not during Scans 3 and 4. According to Paus *et al.* (1993) the anterior cingulate gyrus facilitates possible responses to incoming sensory input (*see also* Pardo *et al.*, 1990; Jenkins *et al.*, 1994). In other words, it might be considered as a level setting system, facilitating certain blueprints of behaviour. However, whilst urine is withheld, the reverse of facilitation is needed, i.e. the urge of voiding has to be inhibited. This might explain the decreased rCBF in the anterior cingulate gyrus during withholding of urine, even when compared with the empty-bladder condition. On the other hand, lesions in the forebrain including the anterior cingulate gyrus have been reported to cause urge incontinence (Andrew and Nathan, 1964; Maurice-Williams, 1974). This would favour the idea that the anterior cingulate gyrus also plays a specific role in micturition control.

Observations during unsuccessful micturition

Seven of the 17 volunteers were unable to micturate when requested (for Scan 2). In this group the ventral pontine tegmentum showed increased rCBF during Scan 2 in comparison with the other three scans (Scans 1, 3 and 4).

During Scan 2, the volunteers who were unsuccessful in

their attempt at micturition, probably for emotional reasons, contracted their urethral sphincter and withheld their urine, although they had a full bladder and tried to urinate. At first glance the condition withholding of urine (Scan 1) is the same as Scan 2, also taken when these volunteers withheld their urine. The difference was that the volunteers, albeit involuntarily, contracted their urethral sphincter much more strongly during Scan 2 than during the withholding of urine condition of Scan 1. From cat experiments, it has been shown that a distinct cell group in the ventrolateral pontine tegmentum is associated with powerful contraction of the bladder sphincter (Holstege *et al.*, 1986). This cell group, located ventrolateral to the PMC, is called the 'L-region' and projects to the nucleus of Onuf in the sacral cord (Holstege *et al.*, 1979, 1986). The nucleus of Onuf contains motor neurons of the pelvic floor muscles including the external urethral sphincter. Electrical stimulation of the L-region produces closure of the sphincter, and bilateral lesions in this area result in a condition that can best be explained as an extreme kind of 'urge' incontinence (Holstege *et al.*, 1986; Griffiths *et al.*, 1990). The L-region possibly plays an important role in the storage of urine. We predicted that a human homologue of the cat's L-region in the ventral pontine tegmentum might be activated in the unsuccessful micturition group, and our PET results, described above, corroborate this idea.

The anterior cingulate gyrus showed decreased rCBF during Scan 1, compared with the other three scans, as in the successful micturition group, and the prefrontal cortex showed increased rCBF. The possible involvement of these areas in more general mechanisms, other than in the regulation of micturition itself has been discussed in the previous paragraph.

In summary, the results of this study suggest that, in humans, as in cats, the dorsomedial and ventral pontine areas are involved in micturition and maintaining continence, respectively. The distance between the peak activation of these areas in the pons was >15 mm, well within the resolution of the scanner, which was ~6 mm in the *x*, *y* and *z* directions, and within in the smoothing limits of the applied Gaussian filter of 8 mm in the *x*, *y* and *z* directions.

Lateralized activation

A striking observation was that the micturition-control areas were found predominantly on the right side of the brain (frontal and cingulate cortices) and brainstem (pontine areas). This finding corresponds with studies reporting that urge incontinence is specifically correlated with lesions in the right hemisphere (Maurice-Williams, 1974; Kuroiwa *et al.*, 1987). The importance of the right side of the brain in autonomic behaviour in general was also indicated by a PET study on human respiration by Corfield *et al.* (1995), who found an increase in rCBF in the anterior cingulate gyrus, predominantly on the right side. In a SPECT (single photon emission computer tomography) study, an increase in the

right prefrontal cortex was observed during male orgasm (Tiihonen *et al.*, 1994).

Future studies using dynamic imaging techniques are underway to find out whether the micturition control structures in the brain, as demonstrated in the present study, are dysfunctional in patients with urge incontinence.

Acknowledgements

We wish to thank members of the Groningen PET Centre and all the volunteers who participated in the experiments. Medtronic Interstim, Maastricht, The Netherlands contributed towards the cost of the colour illustrations.

References

- Andrew J, Nathan PW. Lesions of the anterior frontal lobes and disturbances of micturition and defaecation. *Brain* 1964; 87: 233–62.
- Barrington FJF. The effect of lesions of the hind- and mid-brain on micturition in the cat. *Q J Exp Physiol Cogn Med* 1925; 15: 81–102.
- Blaivas JG. The neurophysiology of micturition: a clinical study of 550 patients. *J Urol* 1982; 127: 958–63.
- Blaivas JG, Bhimani G, Labib KB. Vesicourethral dysfunction in multiple sclerosis. *J Urol* 1979; 122: 342–7.
- Blok BFM, Holstege G. Direct projections from the periaqueductal gray to the pontine micturition center (M-region). An anterograde and retrograde tracing study in the cat. *Neurosci Lett* 1994; 166: 93–6.
- Blok BFM, Holstege G. Neuronal control of micturition and its relation to the emotional motor system. *Prog Brain Res* 1996; 107: 113–26.
- Blok BFM, De Weerd H, Holstege G. Ultrastructural evidence for a paucity of projections from the lumbosacral cord to the pontine micturition center or M-region in the cat. A new concept for the organization of the micturition reflex with the periaqueductal gray as central relay. *J Comp Neurol* 1995; 359: 300–9.
- Consensus Conference. Urinary incontinence in adults. [Review]. *JAMA* 1989; 261: 2685–90.
- Corfield DR, Fink GR, Ramsay SC, Murphy K, Harty HR, Watson JDG, et al. Evidence for limbic system activation during CO₂-stimulated breathing in man. *J Physiol (Lond)* 1995; 488: 77–84.
- Depaulis A, Bandler R, editors. The midbrain periaqueductal gray matter. Functional, anatomical, and neurochemical organization. New York: Plenum Press, 1991.
- Fox PT, Mintun MA. Noninvasive functional brain mapping by change-distribution analysis of averaged PET images of H₂¹⁵O tissue activity. *J Nucl Med* 1989; 30: 141–9.
- Friston KJ, Frith CD, Liddle PF, Dolan RJ, Lammertsma AA, Frackowiak RSJ. The relationship between global and local changes in PET scans. *J Cereb Blood Flow Metab* 1990; 10: 458–66.
- Friston KJ, Frith CD, Liddle PF, Frackowiak RSJ. Plastic transformation of PET images. *J Comput Assist Tomogr* 1991a; 15: 634–9.
- Friston KJ, Frith CD, Liddle PF, Frackowiak RSJ. Comparing

- functional (PET) images: the assessment of significant change. *J Cereb Blood Flow Metab* 1991b; 11: 690–9.
- Gjone R, Setekleiv J. Excitatory and inhibitory bladder responses to stimulation of the cerebral cortex in the cat. *Acta Physiol Scand* 1963; 59: 337–48.
- Gjone R. Excitatory and inhibitory bladder responses to stimulation of 'limbic', diencephalic and mesencephalic structures in the cat. *Acta Physiol Scand* 1966; 66: 91–102.
- Griffiths D, Holstege G, de Wall H, Dalm E. Control and coordination of bladder and urethral function in the brain stem of the cat. *NeuroUrol Urodyn* 1990; 9: 63–82.
- Holstege G. Some anatomical observations on the projections from the hypothalamus to brainstem and spinal cord: an HRP and autoradiographic tracing study in the cat. *J Comp Neurol* 1987; 260: 98–126.
- Holstege G. The basic, somatic, and emotional components of the motor system in mammals. In: Paxinos G, editor. *The rat nervous system*, 2nd ed. San Diego: Academic Press, 1995: 137–54.
- Holstege G, Kuypers HGJM, Boer RC. Anatomical evidence for direct brain stem projections to the somatic motoneuronal cell groups and autonomic preganglionic cell groups in cat spinal cord. *Brain Res* 1979; 171: 329–33.
- Holstege G, Griffiths D, de Wall H, Dalm E. Anatomical and physiological observations on supraspinal control of bladder and urethral sphincter muscles in the cat. *J Comp Neurol* 1986; 250: 449–61.
- Jenkins IH, Brooks DJ, Nixon PD, Frackowiak RSJ, Passingham RE. Motor sequence learning: a study with positron emission tomography. *J Neurosci* 1994; 14: 3775–90.
- Jewett MAS, Fernie GR, Holliday PJ, Pim ME. Urinary dysfunction in a geriatric long-term care population. Prevalence and patterns. *J Am Geriatr Soc* 1981; 29: 211–4.
- Jueptner M, Weiller C. Review: does measurement of regional cerebral blood flow reflect synaptic activity?—Implications for PET and fMRI. *Neuroimage* 1995; 2: 148–56.
- Khan Z, Hertanu J, Yang WC, Melman A, Leiter E. Predictive correlation of urodynamic dysfunction and brain injury after cerebrovascular accident. *J Urol* 1981; 126: 86–8.
- Kruse MN, Noto H, Roppolo JR, de Groat WC. Pontine control of the urinary bladder and external urethral sphincter in the rat. *Brain Res* 1990; 532: 182–90.
- Kuroiwa Y, Tohgi H, Ono S, Itoh M. Frequency and urgency of micturition in hemiplegic patients: relationship to hemisphere laterality of lesions. *J Neurol* 1987; 234: 100–2.
- Loewy AD, Saper CB, Baker RP. Descending projections from the pontine micturition center. *Brain Res* 1979; 172: 533–8.
- Maurice-Williams RS. Micturition symptoms in frontal tumours. *J Neurol Neurosurg Psychiatry* 1974; 37: 431–6.
- Morgan C, Nadelhaft I, de Groat WC. The distribution of visceral primary afferents from the pelvic nerve to Lissauer's tract and the spinal gray matter and its relationship to the sacral parasympathetic nucleus. *J Comp Neurol* 1981; 201: 415–40.
- Noto H, Roppolo JR, Steers WD, de Groat WC. Electrophysiological analysis of the ascending and descending components of the micturition reflex pathway in the rat. *Brain Res* 1991; 549: 95–105.
- Ouslander JG, Kane RL, Abrass IB. Urinary incontinence in elderly nursing home patients. *JAMA* 1982; 248: 1194–8.
- Pardo JV, Pardo PJ, Janer KW, Raichle ME. The anterior cingulate cortex mediates processing selection in the Stroop attentional conflict paradigm. *Proc Natl Acad Sci USA* 1990; 87: 256–9.
- Pardo JV, Fox PT, Raichle ME. Localization of a human system for sustained attention by positron emission tomography. *Nature* 1991; 349: 61–4.
- Paus T, Petrides M, Evans AC, Meyer E. Role of the human anterior cingulate cortex in the control of oculomotor, manual, and speech responses: a positron emission tomography study. *J Neurophysiol* 1993; 70: 453–69.
- Resnick NM, Yalla SV, Laurino E. The pathophysiology of urinary incontinence among institutionalized elderly persons [see comments]. *N Engl J Med* 1989; 320: 1–7. Comment in: *N Engl J Med* 1989; 320: 1421–2.
- Rosen SD, Paulesu E, Frith CD, Frackowiak RSJ, Davies GJ, Jones T. Central nervous pathways mediating angina pectoris [see comments]. *Lancet* 1994; 344: 147–50. Comment in: *Lancet* 1994; 344: 964–5.
- Sato M, Mizuno N, Konishi A. Localization of motoneurons innervating perineal muscles: a HRP study in cat. *Brain Res* 1978; 140: 149–54.
- Skultety FM. Relation of periaqueductal gray matter to stomach and bladder motility. *Neurology* 1959; 9: 190–8.
- Talairach J, Tournoux P. *Co-planar stereotaxic atlas of the human brain*. Stuttgart: Thieme, 1988.
- Tang PC, Ruch TC. Localization of brain stem and diencephalic areas controlling the micturition reflex. *J Comp Neurol* 1956; 106: 213–45.
- Teasdale TA, Taffet GE, Luchi RJ, Adam E. Urinary incontinence in a community-residing elderly population. *J Am Geriatr Soc* 1988; 36: 600–6.
- Tiihonen J, Kuikka J, Kupila J, Partanen K, Vainio P, Airaksinen J, et al. Increase in cerebral blood flow of right prefrontal cortex in man during orgasm. *Neurosci Lett* 1994; 170: 241–3.
- VanderHorst VGJM, Mouton LJ, Blok BFM, Holstege G. Distinct cell groups in the lumbosacral cord of the cat project to different areas in the periaqueductal gray. *J Comp Neurol* 1997. In press.
- Warburton E, Wise RJS, Price CJ, Weiller C, Hadar U, Ramsay S, et al. Noun and verb retrieval by normal subjects. [Review]. *Brain* 1996; 119: 159–79.

Received July 15, 1996. Revised August 24, 1996.

Accepted September 10, 1996