

A PROSPECTIVE OBSERVATIONAL STUDY OF THE COURSE OF CLINICAL INFECTIVE CONJUNCTIVITIS & ANALYSIS OF THE SEQUEL OF ITS CORNEAL INVOLVEMENTManoj Vasudevan¹, G. Premnath², R. Pandurangan³**HOW TO CITE THIS ARTICLE:**

Manoj Vasudevan, G Premnath, R Pandurangan. "A Prospective Observational Study of the Course of Clinical Infective Conjunctivitis & Analysis of the Sequel of its Corneal Involvement". Journal of Evolution of Medical and Dental Sciences 2014; Vol. 3, Issue 58, November 3; Page: 13135-13141, DOI: 10.14260/jemds/2014/3746

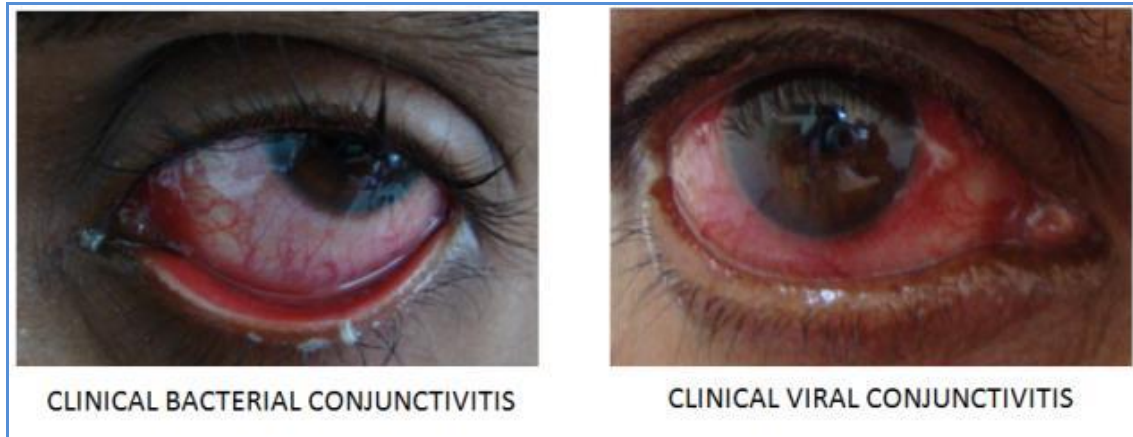
ABSTRACT: AIM: To study the corneal involvement in conjunctivitis during the course of infection or during the convalescence period, the correlation of the corneal involvement with the clinical diagnosis of viral or bacterial conjunctivitis and correlation of the time taken for the complete clinical resolution of conjunctivitis. **MATERIALS AND METHODS:** 100 consecutive patients with clinically diagnosed infective conjunctivitis were analyzed. They underwent slit lamp evaluation on every visit from the time of presentation till complete clinical resolution of conjunctivitis. All of them were treated with 0.5% Moxifloxacin eye drops and eye ointment and followed up regularly till the resolution. **STATISTICAL ANALYSIS:** Frequency distribution and Chi square test. **RESULTS:** The mean time to resolution of conjunctivitis was prolonged with viral conjunctivitis when one eye as well as both eyes were involved & was found to be statistically significant. The corneal involvement as a sequel to infective conjunctivitis was seen only with viral infection & was statistically significant. Also the time taken for resolution of viral conjunctivitis was prolonged when there was a corneal involvement when compared to those who didn't have corneal involvement & was statistically significant. **CONCLUSION:** In this study viral conjunctivitis had prolonged time of resolution and only viral conjunctivitis showed corneal involvement as a sequel.

KEYWORDS: Conjunctivitis, Viral, Bacterial.

INTRODUCTION: Conjunctivitis is a common problem and acute conjunctivitis accounts for around 10% of all eye problems ⁽¹⁾. Conjunctivitis can be broadly classified into infective and non-infective types. Infective conjunctivitis includes viral and bacterial conjunctivitis which are the first and second most common causes of conjunctivitis respectively.⁽²⁾ Most of the cases are diagnosed clinically as the definitive investigation is expensive and time consuming.

Generally conjunctivitis is self-limiting except in some cases. The aim of this study is to analyze the corneal involvement with conjunctivitis during the course of infection or during the convalescence period, the correlation of the corneal involvement with the clinical diagnosis of viral or bacterial conjunctivitis and correlation of the time taken for the complete clinical resolution of conjunctivitis.

ORIGINAL ARTICLE



MATERIALS AND METHODS: The study is conducted in accordance with the Helsinki Declaration of 1975 that was revised in 2000 and after being cleared by the institutional ethical committee. After obtaining informed written consent, 100 consecutive patients with clinically diagnosed infective conjunctivitis fulfilling the inclusion criteria were analyzed. They underwent slit lamp evaluation on every visit from the time of presentation till complete clinical resolution of conjunctivitis.

All of them were treated with 0.5% Moxifloxacin eye drops 6 times a day & 0.5% Moxifloxacin eye ointment at bed time for 7 days or till patient is symptomatic (whichever is later) and followed up on day 3, 7, 12, 15 & 30. The patients diagnosed as clinically viral conjunctivitis are also treated alike to prevent the secondary bacterial infection during the course of the disease.

INCLUSION CRITERIA: All patients with clinical diagnosis of infective conjunctivitis who have not been started on any medication prior to the presentation, not on any systemic medications & satisfying the classification criteria in the age group of 14-65 years.

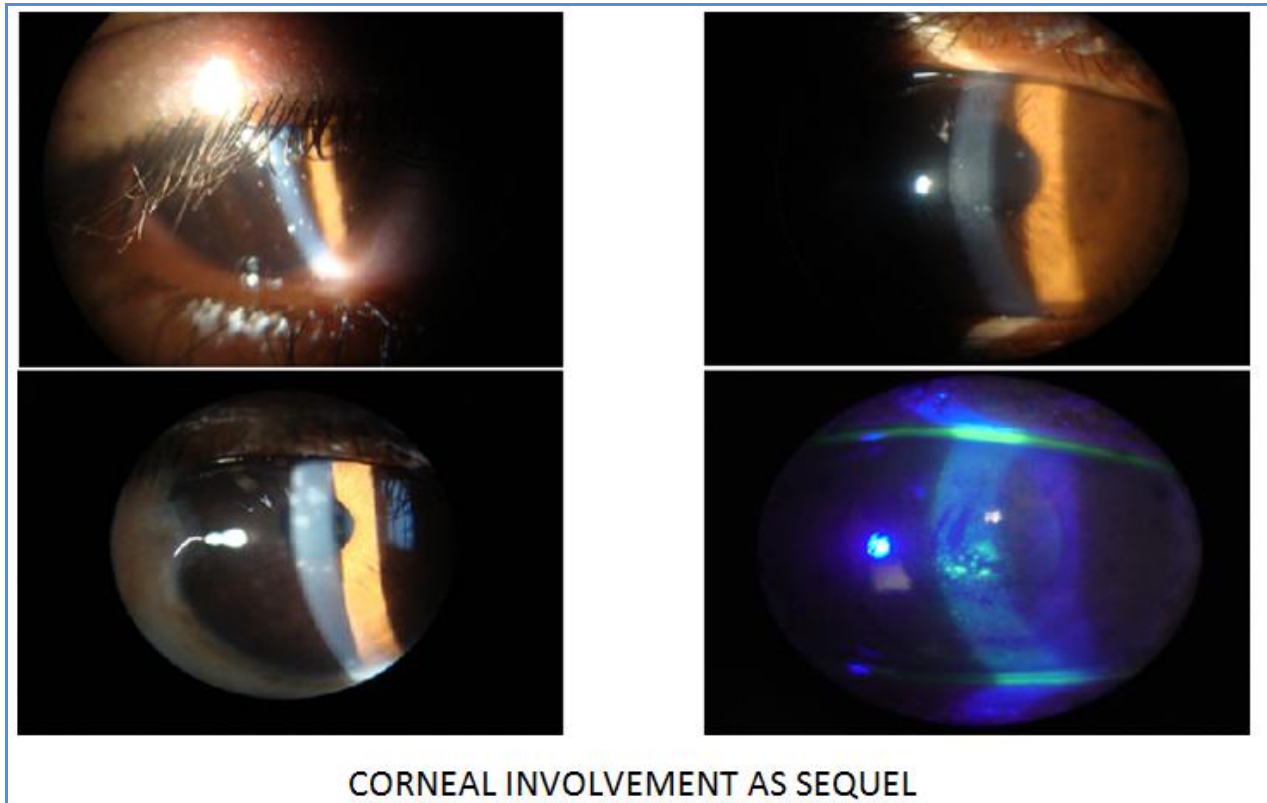
EXCLUSION CRITERIA: All patients who have started on any prior medication OR with any systemic diseases for which the patient is on medication OR with a clinical diagnosis of infective conjunctivitis suspected to be caused by other than bacteria/adeno virus, like herpes/Pox virus.

CLINICAL CLASSIFICATION CRITERIA:

CLINICALLY BACTERIAL: Patients with conjunctival congestion and presence of purulent /mucopurulent discharge⁽²⁾ from the onset with no pre auricular lymphadenopathy. Other associated criterions were mattering and adherence of the eyelids on waking, lack of itching, and absence of a previous history of conjunctivitis^(2,3) in favor of bacterial.

CLINICALLY VIRAL (Adeno viral): Patients with conjunctival congestion, watery discharge ^(2, 4, 5) with petechial hemorrhages either on bulbar/upper palpebral conjunctiva and pre auricular lymphadenopathy ⁽⁶⁾ in favor of viral.

RESOLUTION OF CONJUNCTIVITIS: The conjunctivitis was considered to be completely resolved when the conjunctiva becomes white & eye is free from any discharge.



RESULTS: 100 consecutive patients with clinically infective conjunctivitis were analyzed which included 52 male and 48 female patients. 52 patients had clinically bacterial and the rest had clinically viral conjunctivitis. Table 1 gives the distribution among age, gender and eye involvement. The mean time to resolution of conjunctivitis was prolonged with viral compared to bacterial when one eye as well as both eyes were involved & was found to be statistically significant (Table 2) & (Table 3).

The corneal involvement as a sequel to infective conjunctivitis was seen only with viral infection & was statistically significant (Table 4). Also the time taken for resolution of viral conjunctivitis was prolonged when there was a corneal involvement when compared to those who didn't have corneal involvement & was statistically significant (Table 6). The corneal involvement was found to be associated with viral conjunctivitis & was seen with increased frequency when only one eye was infected compared to when both eyes were infected in viral conjunctivitis but was found to be statistically not significant (Table 4a).

The time to resolution of bacterial conjunctivitis was prolonged when both eyes were involved in comparison to one eye involvement but was found to be statistically not significant (Table 5). The time to resolution of viral conjunctivitis was prolonged when only one eye was involved in comparison to both eyes involvement but was found to be statistically not significant (Table 5).

ORIGINAL ARTICLE

	Bacterial (N=52)	Viral (N=48)
Age (in yrs)	32.90±14.81	28.27±9.05
Male	33 (63.5)	25 (52.1)
Female	19 (36.5)	23 (47.9)
Right Eye involvement	19 (36.5)	15 (31.3)
Left Eye involvement	12 (23.1)	23 (47.9)
Both Eyes involvement	21 (40.4)	10 (20.8)

Table 1: Distribution

	Bacterial(N=52) Mean±SD	Viral(N=48) Mean±SD	p-value
Duration of Symptoms (in days)	1.73±0.68	1.94±0.63	0.122
Time to Resolution of Conjunctivitis (in days)	5.48±0.64	12.63±4.06	<0.001

Table 2: Time to resolution

	N	Bacterial Mean±SD	N	Viral Mean±SD	p-value
Time to Resolution of Conjunctivitis (in days) – Among one eye involved	31	5.45±0.62	38	12.71±4.11	<0.001
Time to Resolution of Conjunctivitis (in days) – Among Both eyes involved	21	5.52±0.68	10	12.30±4.02	<0.001

Table3: Comparison of Time to resolution of conjunctivitis between Bacterial and Viral

Corneal Involvement as Squeal	Bacterial	Viral	p-value
Yes	-	29 (60.4)	<0.001
No	52 (100.0)	19 (39.6)	

Table 4: Corneal involvement as sequel

ORIGINAL ARTICLE

Eye Involved	Corneal involvement as sequel		p-value
	Yes (N=29)	No (N=19)	
One Eye	25 (86.2)	13 (68.4)	0.164
Both Eye	4 (13.8)	6 (31.6)	

Table 4a: Comparison of eye involvement and corneal involvement among viral conjunctivitis

Eye Involved	Time to resolution of Conjunctivitis (in days)			
	N	Bacterial Mean±SD	N	Viral Mean±SD
One Eye	31	5.45±0.62	38	12.71±4.11
Both Eye	21	5.52±0.68	10	12.30±4.02
p-value		0.695		0.780

Table5: Time to resolution of Conjunctivitis when one or both eyes are involved

	Corneal Involvement as a Sequel		
	Yes(N=29) Mean±SD	No(N=19) Mean±SD	p-value
Time to resolution of Conjunctivitis (in days)	15.07±2.61	8.89±2.84	<0.001

Table 6: Comparison of time to resolution of conjunctivitis in corneal involvement among viral conjunctivitis

DISCUSSION: Infective conjunctivitis mainly involves viruses and bacteria and the diagnosis is mainly clinical. Generally infective conjunctivitis is self-limiting⁽⁷⁾ except in some cases and investigation involves both cost and time. Use of antibiotic eye drops, particularly in clinically bacterial conjunctivitis results in early resolution⁽⁸⁾ and decreased complications.⁽⁷⁾ The knowledge about the time to resolution and the possible sequel of infective conjunctivitis when it looks clinically viral is to be discussed with the patients at the time of diagnosis so that they get an awareness about the condition and report early in case of development of such clinical situation.

This helps the treating physician to alleviate the anxiety of such patients and also the confidence of the patient in the course of treatment. This study found the involvement of cornea during the active infective period of viral conjunctivitis as a form of superficial punctate keratitis and that during the convalescence is nummular keratitis. If the nummular keratitis involved the visual axis the patients vision dropped by 2 lines in the distance visual acuity on the Snellen's chart.

The patients who developed superficial punctuate keratitis were also given topical preservative free artificial tears and those who developed nummular lesions were started on topical 0.5% Loteprednol etabonate eye drops 4times a day and tapered over a period of 4-6 weeks. There are no studies in the literature on infective conjunctivitis correlating the time to resolution of the

ORIGINAL ARTICLE

conjunctivitis and the corneal involvement which are quite often seen by the practicing ophthalmologists but still not documented, though various studies have been done relating to microbiological diagnosis^(9, 10). Clinically significant results were obtained in terms of time to resolution and corneal involvement among viral and bacterial conjunctivitis in our study.

CONCLUSION: Infective conjunctivitis is a common entity which is mostly diagnosed clinically. The knowledge of time to resolution and the possible sequel is important during treatment particularly to educate the patients. Our study showed that viral conjunctivitis had prolonged time to resolution and showed corneal involvement as a possible sequel and also when cornea is involved viral conjunctivitis took more time to resolve.

REFERENCES:

1. Agarwala H S, Raichaudhury M, Munsri N K. Bacterial flora in acute conjunctivitis. *Indian J Ophthalmol* 1967; 15:58-66.
2. Amir A Azar, Neal P Barney. Conjunctivitis. A Systematic Review of Diagnosis and Treatment; *JAMA*. Oct 23, 2013; 310(16): 1721–1729.
3. Rietveld RP, van Weert HC, ter Riet G, Bindels PJ. Diagnostic impact of signs and symptoms in acute infectious conjunctivitis: systematic literature search. *BMJ*. 2003; 327 (7418):789.
4. Tasman W, Jaeger EA. *Duane's clinical ophthalmology on CD-ROM*. Lippincott Williams & Wilkins, 2001.
5. Kanski JJ, Bowling Brad. *Clinical ophthalmology: a systematic approach*. 7th ed. Elsevier, 2011: 132.
6. Rietveld RP, ter Riet G, Bindels PJ, Sloos JH, van Weert HC. Predicting bacterial cause in infectious conjunctivitis: cohort study on informativeness of combinations of signs and symptoms. *BMJ*. 2004 Jul 24; 329(7459):206-10.
7. Hovding G. Acute bacterial conjunctivitis. *Acta Ophthalmol*. 2008; 86(1):5–17.
8. Sheikh A, Hurwitz B, van Schayck CP, McLean S, Nurmatov U. Antibiotics versus placebo for acute bacterial conjunctivitis. *Cochrane Database Syst Rev*. 2012; 9:CD001211.
9. Stenson S, Newman R, Fedukowicz H. Laboratory studies in acute conjunctivitis. *Arch Ophthalmol*. 1982; 100(8):1275–1277.
10. Epling J, Smucny J. Bacterial conjunctivitis. *Clin Evid*. 2005; 2(14):756–761.

ORIGINAL ARTICLE

AUTHORS:

1. Manoj Vasudevan
2. G. Premnath
3. R. Pandurangan

PARTICULARS OF CONTRIBUTORS:

1. Assistant Professor, Department of Ophthalmology, Chettinad Hospital & Research Institute, Kelambakkam, Tamil Nadu.
2. Assistant Professor, Department of Ophthalmology, Chettinad Hospital & Research Institute, Kelambakkam, Tamil Nadu.

3. Professor & HOD, Department of Ophthalmology, Chettinad Hospital & Research Institute, Kelambakkam, Tamil Nadu.

NAME ADDRESS EMAIL ID OF THE CORRESPONDING AUTHOR:

Dr. Manoj Vasudevan,
1/305, Kalathumettu St.,
Kottivakkam, Chennai-41,
Tamil Nadu.
Email: manojvasudevanms@gmail.com

Date of Submission: 11/10/2014.
Date of Peer Review: 13/10/2014.
Date of Acceptance: 29/10/2014.
Date of Publishing: 03/11/2014.