

A radiographic analysis of external apical root resorption of maxillary incisors during active orthodontic treatment

Hooman Mohandesan*, Hossein Ravanmehr* and Nasser Valaei**

*Dental Research Center, Faculty of Dentistry, Tehran University of Medical Sciences and **Shahid Beheshti University of Medical Sciences, Tehran, Iran

SUMMARY External apical root resorption (EARR) is an undesirable consequence of orthodontic treatment. The purpose of this study was to measure the amount of EARR and to examine its clinical significance in maxillary incisors, during a 12-month active treatment period. A further aim was to examine the contribution of gender, treatment technique, treatment duration, and extraction of maxillary first premolars to EARR.

The sample comprised 151 maxillary incisor teeth in 40 patients (16 males, 24 females) aged 12–22 years, with different malocclusions. Standard periapical radiographs, using the long-cone paralleling technique, were obtained before and 6 and 12 months after the start of treatment. Quantitative measurements for 80 central and 71 lateral maxillary incisors were performed separately and corrected for image distortion. Root length reduction was calculated in millimetres and in terms of the percentage of the original root length. Resorption of more than 1 mm at 12 months of active treatment was considered to be clinically significant.

On average, the degree of EARR for the maxillary central incisors was 0.77 ± 0.42 and 1.67 ± 0.64 mm, respectively, during the 6- and 12-month follow-up ($P < 0.001$). For the lateral incisors, the degree of EARR was 0.88 ± 0.51 and 1.79 ± 0.66 mm, respectively ($P < 0.001$). Clinically significant resorption was found for 74 per cent of the centrals and 82 per cent of the laterals. No significant correlation was observed between EARR and treatment technique. EARR was found to be correlated with gender for the lateral incisors. The effect of treatment duration ($P < 0.001$) and premolar extraction ($P < 0.001$) was statistically significant for both tooth groups.

Introduction

External apical root resorption (EARR) is an undesirable sequela of orthodontic therapy that in some cases may compromise the results of successful treatment. It has been of concern to clinicians since the early report of Ottolengui (1914).

Root resorption associated with orthodontic treatment is more apparent in subjects where the applied forces are strong and of extended duration, delivered to the tooth in unfavourable directions, or when the tooth is unable to withstand normal forces due to a weakened support system (Reitan, 1974; Blake *et al.*, 1995; Harris *et al.*, 1997). Several factors have been implicated in the initiation and progression of EARR during orthodontic treatment. These can be divided into biological, mechanical, or a combination of the two (Brezniak and Wasserstein, 1993).

Controversy exists in the reports of clinical and laboratory investigations of root resorption, regarding the incidence and amount of EARR. The mean degree of resorption varies from 0.2 (Costopoulos and Nanda, 1996) to 2.93 mm (Copeland and Green, 1986), whereas the prevalence of radiographically detectable resorption varies from 0 to 100 per cent (Vlaskalic and Boyd, 2001). Such controversies may be attributed to considerable differences in the type of teeth examined, sample sizes (Linge and Linge, 1983;

Goldin, 1989), duration of follow-up (Sharpe *et al.*, 1987; Costopoulos and Nanda, 1996), type of tooth movement, measurement methods, and patient characteristics. Therefore, comparison of the studies cited in the literature is difficult.

Some investigators have assessed EARR qualitatively from periapical radiographs and described its severity based on subjective scoring systems (Malmgren *et al.*, 1982; Sharpe *et al.*, 1987; Levander and Malmgren, 1988; Beck and Harris, 1994; Levander *et al.*, 1998b; Janson *et al.*, 2000; Harris *et al.*, 2001), whereas in other studies, EARR has been defined quantitatively from cephalometric images (Copeland and Green, 1986; Goldin, 1989; Harris and Baker, 1990; Katsaros and Berg, 1993; Harris *et al.*, 1997; Horiuchi *et al.*, 1998; Parker and Harris, 1998; Taner *et al.*, 1999) or from standard periapical radiographs with the long-cone paralleling technique in which any image distortion between the pre- and post-treatment radiographs is corrected using the crown length registrations. This method was originally introduced by Linge and Linge (1983) and has since been modified by others (Dermaut and De Munck, 1986; McFadden *et al.*, 1989; Linge and Linge, 1991; Blake *et al.*, 1995; Baumrind *et al.*, 1996; Mavragani *et al.*, 2000).

The main objective of the present study was to measure the amount of EARR of maxillary incisor teeth and to

evaluate its clinical significance during a 12-month period of active treatment. In addition, the contribution of gender, treatment technique, treatment duration, and extraction of first premolars to maxillary incisor EARR was examined.

Subjects and materials

Subjects

This investigation was performed in the Department of Orthodontics, Tehran University of Medical Sciences. Forty patients were selected for the study, age range 12.2–21.8 years, 16 males (mean age 15.4 years) and 24 females (mean age 14.7 years). None of the selected patients presented with a history of genetic or developmental abnormalities, systemic disorders, hormonal imbalance, periodontal disease, trauma, impacted maxillary canines, endodontic treatment of maxillary incisors, previous orthodontic treatment, or crown fracture or incisal edge abrasion of the upper incisors. Informed consent was obtained from each patient or his/her guardian prior to obtaining the radiographs. From the total of 160 incisor teeth, nine were excluded due to the poor quality of the radiographs or apparent root resorption at the pre-treatment stage. The amount of EARR for the remaining 151 teeth, including 80 central and 71 maxillary lateral incisors, was examined (Table 1).

Standardized periapical radiographs were obtained by a single operator with the long-cone paralleling technique (Trophy 94 Vincennes, Minorex, France) prior to initiation of treatment. Agfa Dentus M2 films were used, and the angles were obtained by an intraoral XCP film holder (Rinn Corporation, Elgin, Illinois, USA). The radiographs were developed with Dent-X automatic dental film processor and were scanned at a resolution of 1000 dpi and viewed on a large monitor. Necessary modifications were made to the images in order to improve image interpretation as well as the accuracy of landmark identification. The root apex, incisal edge, and cemento-enamel junction (CEJ) of each maxillary incisor were demarcated on the scanned images. For the CEJ, the most distinct landmark either mesial or distal was used, but once selected, the same side was used for all of the follow-up radiographs. The longitudinal axis of each tooth was constructed from the root apex to the

incisal edge following the root canal as accurately as possible. The marked CEJ was then projected perpendicular to this axis (Microsoft Adobe Photoshop 7.0 ME). Crown length was measured from the incisal edge to the projected CEJ, and root length from the projected CEJ to the apex on the constructed longitudinal axis. All measurements were performed for each tooth separately, within an accuracy of 0.01 mm (Microsoft Autodesk Cad Over Lay R14).

Treatment protocol consisted of the standard edgewise or straight-wire techniques. The appliances used in the ‘standard’ group were 0.022-inch standard brackets (torque: 0 degrees, angulation: 0 degrees, rotation: 0 degrees; Dentarum standard edgewise Ultratrim, Ispringen, Germany) and for the ‘straight-wire’ group 0.022-inch brackets (torque: +12 degrees, angulation: +5 degrees, rotation: 0 degrees for the centrals and torque: +8 degrees, angulation: +9 degrees, rotation: 0 degrees for the laterals; American Orthodontics Roth system, Master series, Sheboygan, Wisconsin, USA).

Follow-up radiographs were obtained 6 and 12 months after the start of treatment, and the crown and root lengths of the maxillary incisors were measured using the method described. Any image distortion between the pre-treatment and follow-up radiographs was corrected using the crown length registrations, assuming the crown lengths to be unchanged over the observation period. A correction factor (CF) was calculated using the following formula:

$$CF = C1/C2 \text{ or } C1/C3,$$

where C1 is the crown length on the pre-treatment radiograph, C2 on the 6-month follow-up radiograph, and C3 on the 12-month follow-up radiograph. EARR per tooth in millimetres was calculated using the following formula:

$$EARR = R1 - (R2 \times CF) \text{ or } R1 - (R3 \times CF),$$

where R1 is the root length on the pre-treatment radiograph, R2 on the 6-month follow-up radiograph, and R3 on the 12-month follow-up radiograph. EARR was also expressed as a percentage of the original root length:

$$EARR \times 100/R1.$$

EARR of 1 mm or more during the 12-month active treatment period was considered as clinically significant (Copeland and Green, 1986; Proffit, 1991). The percentage of teeth with clinically significant EARR is presented for each maxillary incisor group.

Data analysis

Changes in root length that occurred between 6 and 12 months for the central and lateral tooth groups were determined with a paired-samples *t*-test. EARR of more or less than 1 mm at 12 months after treatment initiation (clinically significant EARR), were assessed using the McNemar test.

Table 1 Treatment variables and sample size.

Variables	Central incisors (n = 80)	Lateral incisors (n = 71)
Gender		
Male (n = 16)	32	30
Female (n = 24)	48	41
Treatment technique		
Standard edgewise	46	40
Straight-wire	34	31
Treatment plan		
Extraction	40	37
Non-extraction	40	34

The generalized estimating equations (GEE) analysis was used to determine the regression parameters and to account for the correlation between each patient's observations (EARR values for left and right central and lateral incisors of each patient). A multiple regression model was constructed for each tooth group separately to evaluate the effect of gender, treatment technique, and maxillary first premolar extraction on the amount of EARR at the 12-month follow-up. The Statistical Package for Social Sciences (version 11.5, SPSS Inc., Chicago, Illinois, USA) was used to obtain the descriptive statistics and to perform the paired-samples *t*-test and McNemar's test. In addition, the SAS software (version 9.1, SAS Institute, Cary, North Carolina, USA) was utilized to perform the GEE analysis. *P*-values less than 0.05 were considered statistically significant.

Results

For the 80 central incisors examined, the pre-treatment root length was 17.09 ± 1.93 mm, range 14.11–21.51 mm. All examined teeth showed EARR at 6 months after active treatment. On average, EARR was 0.77 ± 0.42 mm (4.5 per cent of the initial root length; $P < 0.001$). At 12 months, the amount of resorption increased to 1.67 ± 0.64 mm (9.8 per cent of the original root length; $P < 0.001$). At this follow-up, the 95 per cent confidence interval of EARR ranged from 1.54 to 1.85 mm.

For the 71 lateral incisors examined, the pre-treatment root length was 15.55 ± 1.84 mm, range 12.27–19.64 mm. All the lateral incisors showed a mean amount of EARR of 0.88 ± 0.51 mm (5.6 per cent of the initial root length; $P < 0.001$) at the 6-month follow-up. At 12 months, this increased to 1.79 ± 0.66 mm (11.5 per cent of the original root length; $P < 0.001$). The 95 per cent confidence interval ranged from 1.64 to 1.95 mm at this follow-up, with 74 per cent of the central and 82 per cent of the lateral incisors showing clinically significant EARR ($P < 0.001$). At both follow-up points, the amount of EARR was greater for the maxillary lateral incisors than for the central incisors, but the difference was not statistically significant.

A significant difference was found between the 6- and 12-month EARR values in millimetres and in terms of the percentage of the original root length for both tooth groups ($P < 0.001$; Figure 1).

For both the central and lateral groups, the amount of EARR was greater in the extraction group than in the non-extraction group at the 12-month follow-up (Table 2). Regression analysis revealed that the difference was statistically significant for both groups ($P < 0.001$; Table 3).

The amount of EARR was greater for females at 12 months for both tooth groups (Table 4); however, regression analysis showed that the difference between genders was only statistically significant for the lateral incisors ($P < 0.03$; Table 3).

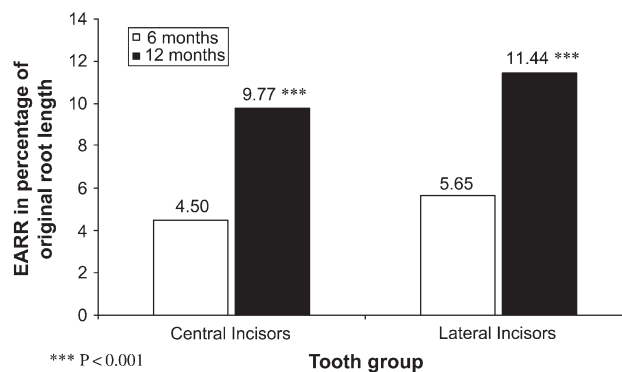


Figure 1 External apical root resorption (EARR) in terms of the percentage of original root length at the 6- and 12-month follow-ups for the maxillary central and lateral incisors.

Although the subjects treated with the straight-wire technique showed greater EARR than those treated with the standard technique for both tooth groups (Table 5), the difference was not statistically significant (Table 3).

Discussion

Maxillary incisors were selected as representatives of EARR as these teeth are more susceptible to the iatrogenic consequences of orthodontic forces (Brezniak and Wasserstein, 1993; Blake *et al.*, 1995; Kjær, 1995; Mavragani *et al.*, 2000; Sameshima and Sinclair, 2001a). The selection of 12 years, as the lower age limit of the sample was to exclude the undesirable effect of residual root growth (Linge and Linge, 1983, 1991; Horiuchi *et al.*, 1998). The higher age limit of 22 years was chosen in order to eliminate the unfavourable effect of age that may lead to increased EARR due to creation of more hyalinized areas, longer hyalinization duration, and lower healing activity in adults (Reitan, 1974; Harris and Baker, 1990; Brezniak and Wasserstein, 1993; Mirabella and Årtun, 1995a). Crown and root lengths were measured separately for each of the four maxillary incisors on scanned periapical radiographs taken using the long-cone paralleling technique, similar to the method of Linge and Linge (1983). Using a CF increased the accuracy of the measurement by eliminating any dimension or angulation difference between exposures (McFadden *et al.*, 1989; Blake *et al.*, 1995; Mavragani *et al.*, 2000).

There have been few reports devoted to the clinical consequences of EARR associated with orthodontic treatment. In some cases, the amount of EARR might be statistically significant but with no discernible clinical importance (Blake *et al.*, 1995; Proffit, 2000). However, some patients may experience root structure loss to the point where the treatment plan needs to be reviewed in order to avoid excessive tooth mobility and eventual tooth

Table 2 External apical root resorption in millimetres and in percentage of original root length for tooth groups at 12 months subdivided by treatment plan.

Treatment plan	Central incisors		Lateral incisors	
	mm	%	mm	%
Extraction	1.90 ± 0.67 n = 40	11.1	1.97 ± 0.63 n = 37	12.7
Non-extraction	1.44 ± 0.50 n = 40	8.4	1.43 ± 0.49 n = 34	9.2

loss (Vlaskalic and Boyd, 2001). Therefore, in the present study, EARR of 1 mm at 12 months of active treatment period was used as the cut-off to determine the clinical significance of EARR (Copeland and Green, 1986; Proffit, 1991).

At the 12-month follow-up, all maxillary central incisors showed EARR which was, on average, 1.67 ± 0.64 mm (10 per cent of the original root length). In total, 74 per cent of these teeth exhibited clinically significant EARR. The amount of EARR for the lateral incisors was, on average, 1.79 ± 0.66 mm (11 per cent of the initial root length). For 82 per cent of the laterals, root shortening was clinically significant.

The degree of EARR was correlated with treatment duration, as the amount of resorption per tooth group increased significantly from 6 to 12 months. Previous studies have supported the significance of treatment time in EARR (Linge and Linge, 1983; Levander and Malmgren, 1988; McFadden *et al.*, 1989; Baumrind *et al.*, 1996; Levander *et al.*, 1998a; Sameshima and Sinclair, 2001b), although a few have not (Beck and Harris, 1994; Mirabella and Årtun, 1995b). This correlation may be attributed to the fact that longer durations of consecutive stress on the periodontal ligament could cause more hyalinization and

less repair activity in the compressed area, followed by increased damage to the root surface (McFadden *et al.*, 1989; Brezniak and Wasserstein, 1993). Moreover, the longer patients are treated, the further the teeth and their apices are likely to be displaced and therefore more resorptive activity is required at the pressure site. Nevertheless, the amount and pattern of EARR may vary with longer treatment durations; thus, further studies with longer follow-up periods may reveal different findings.

The maxillary incisor teeth of the patients for whom first premolar extractions were carried out demonstrated significantly more EARR compared with the non-extraction group. Previous studies have reported a significant correlation following premolar extraction (Blake *et al.*, 1995; McNab *et al.*, 2000; Harris *et al.*, 2001). Extraction subjects generally require larger tooth movement and apical displacement to correct malocclusions (Sharpe *et al.*, 1987; Beck and Harris, 1994). This results in more resorptive activity at the apical region which may cause greater amounts of EARR and a higher percentage of teeth with clinically significant resorption.

The maxillary incisors of female patients showed more EARR than those of male patients but the effect of gender was found only for the maxillary lateral incisors. The findings are consistent with some previous studies (Levander and Malmgren, 1988; Kjær, 1995; Horiuchi *et al.*, 1998); however, others have found no correlation between EARR and gender (Linge and Linge, 1991; Harris *et al.*, 1997; Parker and Harris, 1998).

No statistically significant correlation was found between EARR and appliance system at the 12-month follow-up. The findings are in accordance with earlier observations (Parker and Harris, 1998; Reukers *et al.*, 1998; Janson *et al.*, 2000; Mavragani *et al.*, 2000; Sameshima and Sinclair, 2001b).

Table 3 Results of generalized estimating equations analysis for the central and lateral incisors at the 12-month follow-up.

Covariate	Central incisors				Lateral incisors			
	Coefficient	SE	Z	P	Coefficient	SE	Z	P
Gender								
Male	-0.153	0.143	-1.07	0.283	-0.317	0.141	-2.25	0.024
Female	Reference category				Reference category			
Treatment technique								
Standard edgewise	0.106	0.149	0.71	0.477	0.011	0.140	0.08	0.938
Straight-wire	Reference category				Reference category			
Treatment plan								
Extraction	0.489	0.150	3.26	0.001	0.700	0.144	4.87	0.001
Non-extraction	Reference category				Reference category			

SE, standard error.

Table 4 External apical root resorption in millimetres and in percentage of original root length for tooth groups at 12 months subdivided by gender.

Gender	Central incisors		Lateral incisors	
	mm	%	mm	%
Male (<i>n</i> = 16)	1.62 ± 0.50 <i>n</i> = 32	9.4	1.64 ± 0.53 <i>n</i> = 30	10.5
Female (<i>n</i> = 24)	1.71 ± 0.71 <i>n</i> = 48	10	1.91 ± 0.73 <i>n</i> = 41	12.3

Table 5 External apical root resorption in millimetres and in percentage of original root length for tooth groups at 12 months subdivided by treatment technique.

Treatment technique	Central incisor		Lateral incisor	
	mm	%	mm	%
Standard edgewise	1.66 ± 0.57 <i>n</i> = 46	9.8	1.75 ± 0.67 <i>n</i> = 40	11.2
Straight-wire	1.68 ± 0.72 <i>n</i> = 34	10.0	1.85 ± 0.67 <i>n</i> = 31	12.2

The small sample size and relatively short follow-up period are the limitations of this study which should be taken into account.

Conclusion

EARR remains an important concern during orthodontic treatment. All the maxillary incisors in this investigation showed degrees of EARR at the follow-up periods and a considerable percentage of the sample had clinically significant resorption.

Caution should be exercised with patients who have been in treatment for a longer than the usual period of time and in those who have undergone premolar extractions. Standardized monitoring radiographs of the maxillary incisors at more frequent intervals could help in early registration of EARR in orthodontic patients and identification of those who may become severely affected. Considering the clinical significance of EARR may help in minimizing the risk of severe root resorption during orthodontic treatment.

Acknowledgments

We are greatly indebted to Dr S. Akhondzadeh, DMD, PhD, and Dr N. Hakoupian, DDS, MSc for their proficient assistance and advice. We wish to express our gratitude to Dr F. Zayeri, PhD, for his generous help in the statistical

analysis. We would like to thank Dr M. S. A. Akhondi, DDS, MSc, for his valuable support.

Address for correspondence

Hooman Mohandesan
Dental Research Center
Faculty of Dentistry
Tehran University of Medical Sciences
Enghelab Street
14176-14411 Tehran
Iran
E-mail: hmohandesan@gmail.com or dentre@tums.ac.ir

References

- Baumrind S, Korn E L, Boyd R L 1996 Apical root resorption in orthodontically treated adults. *American Journal of Orthodontics and Dentofacial Orthopedics* 110: 311–320
- Beck B W, Harris E F 1994 Apical root resorption in orthodontically treated subjects: analysis of edgewise and light wire mechanics. *American Journal of Orthodontics and Dentofacial Orthopedics* 105: 350–361
- Blake M, Woodside D G, Pharoah M J 1995 A radiographic comparison of apical root resorption after orthodontic treatment with the edgewise and Speed appliances. *American Journal of Orthodontics and Dentofacial Orthopedics* 108: 76–84
- Breznjak N, Wasserstein A 1993 Root resorption after orthodontic treatment: part 2. Literature review. *American Journal of Orthodontics and Dentofacial Orthopedics* 103: 138–146
- Copeland S, Green L J 1986 Root resorption in maxillary central incisors following active orthodontic treatment. *American Journal of Orthodontics* 89: 51–55
- Costopoulos G, Nanda R 1996 An evaluation of root resorption incident to orthodontic intrusion. *American Journal of Orthodontics and Dentofacial Orthopedics* 109: 543–548
- Dermaut L R, De Munck A 1986 Apical root resorption of upper incisors caused by intrusive tooth movement: a radiographic study. *American Journal of Orthodontics and Dentofacial Orthopedics* 90: 321–326
- Goldin B 1989 Labial root torque: effect on the maxilla and incisor root apex. *American Journal of Orthodontics and Dentofacial Orthopedics* 95: 209–219
- Harris E F, Baker W C 1990 Loss of root length and crestal bone height before and during treatment in adolescent and adult orthodontic patients. *American Journal of Orthodontics and Dentofacial Orthopedics* 98: 463–469
- Harris E F, Kineret S E, Tolley E A 1997 A heritable component for external apical root resorption in patients treated orthodontically. *American Journal of Orthodontics and Dentofacial Orthopedics* 111: 301–309
- Harris E F, Boggan B W, Wheeler D A 2001 Apical root resorption in patients treated with comprehensive orthodontics. *Journal of the Tennessee Dental Association* 81: 30–33
- Horiuchi A, Hotokezaka H, Kobayashi K 1998 Correlation between cortical plate proximity and apical root resorption. *American Journal of Orthodontics and Dentofacial Orthopedics* 114: 311–318
- Janson G R P, de Luca Canto G, Rodrigues Martins D, Castanha Henriques J F, de Freitas M R 2000 A radiographic comparison of apical root resorption after orthodontic treatment with 3 different fixed appliance techniques. *American Journal of Orthodontics and Dentofacial Orthopedics* 118: 262–273
- Katsaros C, Berg R 1993 Anterior open bite malocclusion: a follow-up study of orthodontic treatment effects. *European Journal of Orthodontics* 15: 273–280

- Kjær I 1995 Morphological characteristics of dentitions developing excessive root resorption during orthodontic treatment. *European Journal of Orthodontics* 17: 25–34
- Levander E, Malmgren O 1988 Evaluation of the risk of root resorption during orthodontic treatment: a study of upper incisors. *European Journal of Orthodontics* 10: 30–38
- Levander E, Bajka R, Malmgren O 1998a Early radiographic diagnosis of apical root resorption during orthodontic treatment: a study of maxillary incisors. *European Journal of Orthodontics* 20: 57–63
- Levander E, Malmgren O, Stenback K 1998b Apical root resorption during orthodontic treatment of patients with multiple aplasia: a study of maxillary incisors. *European Journal of Orthodontics* 20: 427–434
- Linge B O, Linge L 1983 Apical root resorption in upper anterior teeth. *European Journal of Orthodontics* 5: 173–183
- Linge L, Linge B O 1991 Patient characteristics and treatment variables associated with apical root resorption during orthodontic treatment. *American Journal of Orthodontics and Dentofacial Orthopedics* 99: 35–43
- Malmgren O, Goldson L, Hill C, Orwin A, Petrini L, Lundberg M 1982 Root resorption after orthodontic treatment of traumatized teeth. *American Journal of Orthodontics* 82: 478–491
- Mavragani M, Vergari A, Selliseth N J, Bøe O E, Wisth P J 2000 A radiographic comparison of apical root resorption after orthodontic treatment with a standard edgewise and straight-wire edgewise technique. *European Journal of Orthodontics* 22: 665–674
- McFadden W M, Engström C, Engström H, Anholm J M 1989 A study of the relationship between incisor intrusion and root shortening. *American Journal of Orthodontics and Dentofacial Orthopedics* 96: 390–396
- McNab S, Battistutta D, Taverne A, Symons A L 2000 External apical root resorption following orthodontic treatment. *The Angle Orthodontist* 70: 227–232
- Mirabella A D, Årtun J 1995a Prevalence and severity of apical root resorption of maxillary anterior teeth in adult orthodontic patients. *European Journal of Orthodontics* 17: 93–99
- Mirabella A D, Årtun J 1995b Risk factors for apical root resorption of maxillary anterior teeth in adult orthodontic patients. *American Journal of Orthodontics and Dentofacial Orthopedics* 108: 48–55
- Ottolengui R 1914 The physiological and pathological resorption of tooth roots. *Dental Items of Interest* 36: 322–362
- Parker R J, Harris E F 1998 Directions of orthodontic tooth movements associated with external apical root resorption of the maxillary central incisor. *American Journal of Orthodontics and Dentofacial Orthopedics* 114: 677–683
- Proffit W R 1991 Treatment planning: the search for wisdom. In: Proffit W R, White R P (eds) *Surgical orthodontic treatment*. C.V Mosby Co., St Louis, pp. 164–169
- Proffit W R 2000 Malocclusion and dentofacial deformity in contemporary society. In: Proffit W R, Fields H W (eds) *Contemporary orthodontics*. C.V Mosby Co., St Louis, pp. 15–22
- Reitan K 1974 Initial tissue behavior during apical root resorption. *The Angle Orthodontist* 44: 68–82
- Reukers E A J, Sanderink G C H, Kuijpers-Jagtman A M, van 't Hof M A 1998 Radiographic evaluation of apical root resorption with 2 different types of edgewise appliances. Results of a randomized clinical trial. *Journal of Orofacial Orthopedics* 59: 100–109
- Sameshima G T, Sinclair P M 2001a Predicting and preventing root resorption: part I. Diagnostic factors. *American Journal of Orthodontics and Dentofacial Orthopedics* 119: 505–510
- Sameshima G T, Sinclair P M 2001b Predicting and preventing root resorption: part II. Treatment factors. *American Journal of Orthodontics and Dentofacial Orthopedics* 119: 511–515
- Sharpe W, Reed B, Subtelny J D, Polson A 1987 Orthodontic relapse, apical root resorption, and crestal alveolar bone levels. *American Journal of Orthodontics and Dentofacial Orthopedics* 91: 252–258
- Taner T, Ciger S, Sençift Y 1999 Evaluation of apical root resorption following extraction therapy in subjects with Class I and Class II malocclusions. *European Journal of Orthodontics* 21: 491–496
- Vlaskalic V, Boyd R L 2001 Root resorptions and tissue changes during orthodontic treatment. In: Bishara S E (ed.) *Textbook of orthodontics*. W B Saunders Co., Philadelphia, pp. 463–472