 Open access • Journal Article • DOI:10.1001/ARCHOPHT.1996.01100130490031

## **A rare case of orbital osteogenic sarcoma** — [Source link](#)

Mary G. Trevisani, Constance L. Fry, Richard J. Hesse, Gladden W. Willis

**Institutions:** Ochsner Medical Center

**Published on:** 01 Apr 1996 - Archives of Ophthalmology (American Medical Association)

**Topics:** Ptosis, Sarcoma, Eyelid, Orbit (anatomy) and Bone disease

Related papers:

- [Osteosarcoma of the Orbit](#)

Share this paper:    

View more about this paper here: <https://typeset.io/papers/a-rare-case-of-orbital-osteogenic-sarcoma-2peaob6cr5>

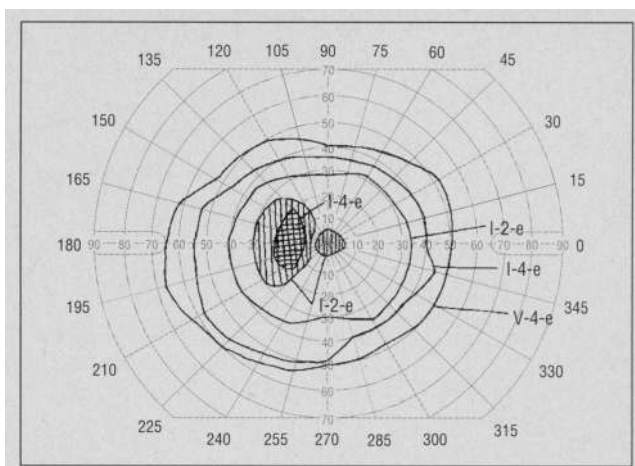


Figure 1. Goldmann visual field 1 month after initial evaluation.

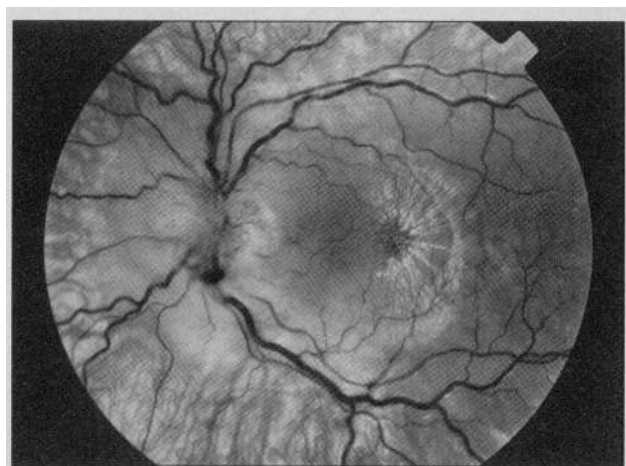


Figure 2. Fundus photograph of macular star formation at 1 month with resolving disc edema.

**Report of a Case.** A 10-year-old girl was examined for decreased vision in the left eye. One month earlier, her 5-month-old household kitten had scratched her face, and about 2 weeks later, a febrile illness that lasted for 5 days developed in the child.

Her visual acuity was 20/20 OD and she counted fingers at 2 ft in the left eye. A 1.8 log unit relative afferent pupillary defect was present in the left eye, and Goldmann perimetry demonstrated a central scotoma in the visual field of that eye and a normal visual field in the right eye. The results of the slit-lamp examination were normal in both eyes. Ophthalmoscopy showed a normal right eye, with the left eye having marked disc edema with peripapillary retinal edema, a macular star, and exudates. *Bartonella henselae* antibody titer was 35 enzyme immunoassay units (>20 units is considered positive). Oral doxycycline hyclate, 100 mg daily for 10 days, was initiated after consultation with the patient's pediatrician.

One month later, visual acuity had improved to 20/200 OS, with a 0.6 log unit left afferent pupillary defect. Goldmann perimetry showed a central scotoma and marked enlargement of the blind spot (Figure 1). Although there was less edema of the left optic disc, the macular star was more pronounced (Figure 2). At 2 months, the optic disc was pale, with only a few macular exudates remaining.

**Comment.** Neuroretinitis is characterized by visual loss, disc edema,

macular exudates, central and cecentral scotomas, and relative afferent pupillary defects; recovery of vision occurs in most, but not all, cases. Reported causative agents have included viruses such as mumps, varicella, and herpes simplex; parasites such as *Toxocara canis* and *Toxoplasma gondii*; and bacteria such as *Borrelia burgdorferi*, *Treponema pallidum*, *Salmonella typhi*, and *B henselae*. The last agent is also implicated in cat-scratch disease. Although *B henselae* is thought to be a common cause of neuroretinitis, diagnosis has required either lymph node or conjunctival biopsies (Warthin-Starry silver impregnation stain to identify the bacilli in tissue) or skin antigen testing (intradermal injection of treated pus from suppurative lymph nodes of patients with cat-scratch disease). The enzyme immunoassay test used in this case is a practical way to determine the cause of neuroretinitis. It is a relatively non-invasive test, and it has high sensitivity and specificity.<sup>2</sup> Although guidelines for treatment of neuroretinitis associated with *B henselae* have not been fully established, the identification of *B henselae* as the presumed causative agent simplifies the diagnostic investigation and offers substantial prognostic information.

Roger W. Newsom, MD  
Timothy J. Martin, MD  
Ben Wasilaukas, MD  
Winston-Salem, NC

Reprint requests to Wake Forest University Eye Center, Medical Center

Boulevard, Winston-Salem, NC 27157  
(Dr Martin).

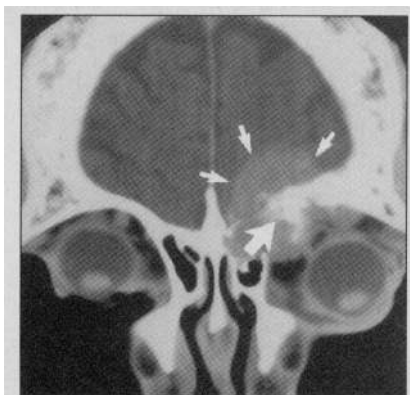1. Regnery RL, Olson JG, Perkins BA, Bibb W. Serological response to 'Rochalimaea henselae' antigen in suspected cat-scratch disease. *Lancet*. 1992;339:1443-1444.
2. Zangwill KM, Hamilton DH, Perkins BA, et al. Cat scratch disease in Connecticut: epidemiology, risk factors, and evaluation of a new diagnostic test. *N Engl J Med*. 1993;329:8-13.
3. Golnik KC, Marotto ME, Fanous MM, et al. Ophthalmic manifestations of *Rochalimaea* species. *Am J Ophthalmol*. 1994;118:145-151.

## A Rare Case of Orbital Osteogenic Sarcoma

Osteogenic sarcoma is a malignant bony tumor of mesenchymal cell origin. The association of osteogenic sarcoma with Paget's disease of the bone (osteitis deformans) is well-known. However, orbital involvement is rare; only two other cases have been reported in all of the literature. Untreated, the tumor is lethal, with death usually occurring from extension into the cranial fossa.

**Report of a Case.** A 58-year-old man was seen for a 1-month history of diplopia, pain on eye movement, and left upper eyelid ptosis. Of significance in his medical history was Paget's disease of the bone for 23 years and no prior radiation therapy. A review of systems was unremarkable.

The ophthalmic evaluation revealed a best-corrected visual acuity of 20/30 OD and 20/80 OS. The left eyelid demonstrated 3 mm of ptosis. Additionally, a 3-mm axial proptosis was present, and the globe was dis-



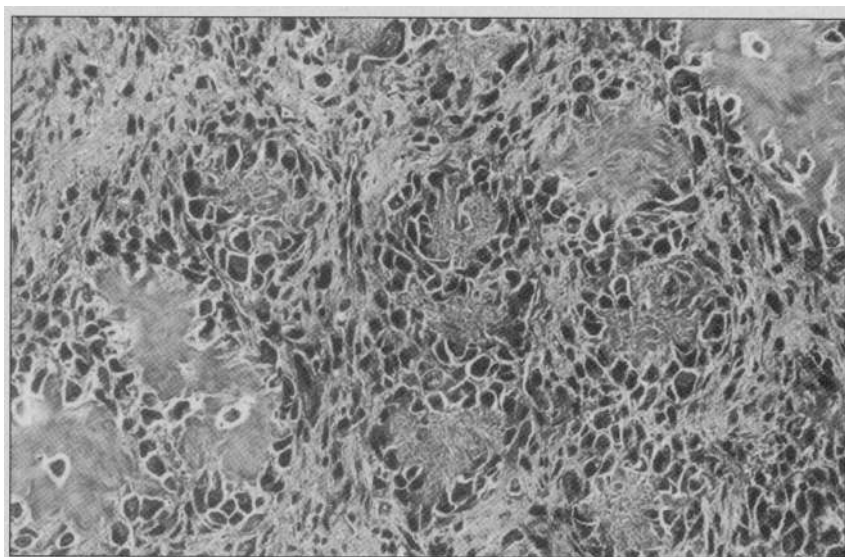
**Figure 1.** Coronal view showing the extent of the lesion (small arrows) and the areas of calcification (large arrow).

placed 8 mm laterally and 4 mm inferiorly. A firm, slightly tender mass, measuring 1.5×1.5 mm, was fixed to the superior orbital rim. The pupils were normal, with no relative afferent defect. Extraocular motility of the left eye was limited in upgaze. Three prism diopters of left hypotropia were present. Other examination findings were unremarkable.

A plain skull x-ray film revealed bony erosion of the left orbital roof and the frontal and ethmoidal sinuses, as well as diffuse changes throughout the calvarium, consistent with Paget's disease. A contrast-enhanced computed tomography scan of the brain and orbits outlined an osteolytic lesion with dystrophic calcification. The lesion involved the entire orbital roof, from the orbital rim to the apex, and extended into the left frontal and ethmoidal sinuses and into the cribriform plate (**Figure 1**). The mass extended to the dura of the frontal lobe without associated cerebral edema. Bony changes throughout the calvarium were consistent with Paget's disease.

Significant results of a complete diagnostic workup included a markedly elevated alkaline phosphatase of 1587 U/L (normal, 55 to 135 U/L), and a normal chest x-ray film. An incisional biopsy was performed.

Microscopic examination of the sections, which were stained with hematoxylin-eosin, revealed a tumor composed of neoplastic cells forming osteoid, the histologic criterion for a diagnosis of osteosarcoma. The osteoblasts were pleomorphic and hyperchromatic and the amorphous islands of osteoid, formed by surrounding osteoblasts, did not polarize and stained negatively with Alcian blue and mu-



**Figure 2.** Pleomorphic and hyperchromatic osteoblasts forming amorphous islands of osteoid that do not polarize and stained negatively with Alcian blue and mucicarmine (hematoxylin-eosin, ×400 oil immersion).

cicarmine (**Figure 2**). Further electron microscopic studies indicated the tumor cells were producing masses of tangled collagen fibers consistent with unmineralized osteoid. These findings indicated osteogenic sarcoma in this patient.

Results of a subsequent systemic evaluation, including a computed tomographic scan of the chest, were normal. The patient was treated with radiation and chemotherapy, but was unavailable for follow-up 7 months after the diagnosis was made.

**Comment.** Osteogenic sarcoma is typically classified into two subtypes: primary and secondary. The primary tumors arise de novo, typically in developing bones, and account for 70% of all cases. Secondary osteosarcomas develop in bones with preexisting fractures or disease such as Paget's disease, in regions previously exposed to a carcinogenic influence such as radiation therapy, and in patients with hereditary retinoblastoma.

Only one case of orbital osteogenic sarcoma concurrent with Paget's disease has been reported in the literature. The patient described by Blodi<sup>1</sup> in 1969 is strikingly similar to our patient. Osteogenic sarcoma of the orbit developed in this 69-year-old patient after a 24-year history of Paget's disease. He had painless exophthalmos and a mass in the superior orbit and died 6 months after surgical excision, radiation therapy, and chemotherapy.

In his textbook of orbital diseases, Henderson<sup>2</sup> described a patient with osteogenic sarcoma that developed 10 years after the onset of Paget's disease.

Osteogenic sarcoma occurring with osteitis deformans is a well-recognized, yet uncommon disease that is difficult to treat. The tumor causes extensive local destruction and is spread hematogenously. Aggressive multimodal therapy, including surgical resection followed by chemotherapy and irradiation, is usually necessary.<sup>3</sup> Despite aggressive intervention, the prognosis remains guarded, particularly when Paget's disease is also present.

Mary G. Trevisani, MD  
Constance L. Fry, MD  
Richard J. Hesse, MD  
Gladden W. Willis, MD  
New Orleans, La

We thank Alan Girch, MD, Vanderbilt University Medical Center, Nashville, Tenn, for performing and interpreting the electron microscopy.

Reprint requests to Ochsner Clinic, 1516 Jefferson Hwy, New Orleans, LA 70121 (Dr Hesse).

1. Blodi FC. Pathology of orbital bones. *Am J Ophthalmol.* 1976;81:1-26.
2. Henderson JW. Fibro-osseous, osseous, and cartilaginous tumors of orbital bone. In: Henderson JW, ed. *Orbital Tumors*. New York, NY: Raven Press; 1994:166.
3. Abramson DH, Ellsworth RM, Kitchin FD, Tung G. Second nonocular tumors in retinoblastoma survivors: are they radiation induced? *Ophthalmology.* 1984;91:1351-1355.