

A rare case of tuberculous salpingitis

ANATOLII ROMANIUK¹, NATALIYA GYRYAVENKO^{1,*}, MYKOLA LYNDIN¹,
SOFIIA ROMANIUK², MIROSLAV STARKIV³, GALINA SLOBODYAN⁴

¹Department of Pathology, Sumy State University, Sumy, Ukraine

²Internal Medicine Department of Postgraduation Education, Sumy State University, Sumy, Ukraine

³Medical Center Floris, Sumy, Ukraine

⁴Sumy State University, Sumy, Ukraine

*Corresponding author: Nataliya Gyryavenko; Department of Pathology, Sumy State University, 31, st. Privokzalnaya, Sumy, Ukraine; Phone: +380 997466578; E-mail: natasha-gir@mail.ru

(Received: June 17, 2016; Revised manuscript received: July 6, 2016; Accepted: July 9, 2016)

Abstract: The objective of this study was to give an overview of a rare case of tuberculosis of the left fallopian tube in postmenopausal women. It is known that the isolated tuberculous salpingitis without spreading to the endometrium is extremely rare case. In our case, it simulated a cancer of appendages at the late stages that were proved by the increased level of CA-125. This fact as well as the macroscopic image of the left fallopian tube was incorrectly considered by the clinicians as a malignant neoplasm of fallopian tube. However, after pathomorphological examination of postoperative samples during histological study, the main method of verification of the diagnosis, revealed the specific granulomas in the samples that indicate the tubercular inflammation. It was considered by clinical and laboratory as data secondary focus.

Keywords: tuberculosis, fallopian tubes, clinical case, histology, Langhans giant cells

Introduction

The incidence of genital tuberculosis (TB) is 1–2% among female population suffering from TB [1]. But the actual incidence of genital TB cannot be calculated accurately due to accidental determination of the disease and asymptomatic course [2, 3]. Morgagni, an Italian anatomist, was the first who described the genital TB in women in 1774. He described a case of TB inflammation in fallopian tubes and ovaries in a 20-year-old woman who died from peritonitis [4]. Female genital TB is a rare case and generally occurs secondary to other affected organs [5].

Tuberculous salpingitis is an infection in human's body, which develops hematogenously from the primary lesions (lung and intestine) to the reproductive system [6]. Various chronic diseases that reduce the non-specific resistance of the body and severe psychological and physical stress increase the pathogen spreading. Genital TB is difficult to diagnose, because in most cases it is asymptomatic [7].

We considered the case of genital TB without primary lung lesion.

Case

A 56-year-old female patient was hospitalized to Regional Clinical Oncology Center with constant pain in the lower part of abdomen, appeared approximately a year before. No history of TB was observed in the past. It was revealed from the anamnesis that a right-side tubectomy was carried out due to the extrauterine pregnancy (at the age of 26) and subtotal resection of the thyroid gland was made due to the diffuse toxic goiter (at the age of 43). At the age of 30, the childbirth ended with the birth of a healthy child. The gynecological examination revealed that the uterus was not enlarged, mobile; the uterine appendages were palpable as cystic formations. Any abnormalities were not detected by chest X-ray examination. The laboratory blood tests revealed the mild anemia (Hb = 110 g/l); the other indicators were normal. The biochemical parameters of blood were also normal. Ovarian tumor marker (CA-125) level was 24.3 IU/ml (normal: 0–16.3 IU/ml). The Wassermann test was negative.

This is an open-access article distributed under the terms of the Creative Commons Attribution License, which permits unrestricted use, distribution, and reproduction in any medium for non-commercial purposes, provided the original author and source are credited.

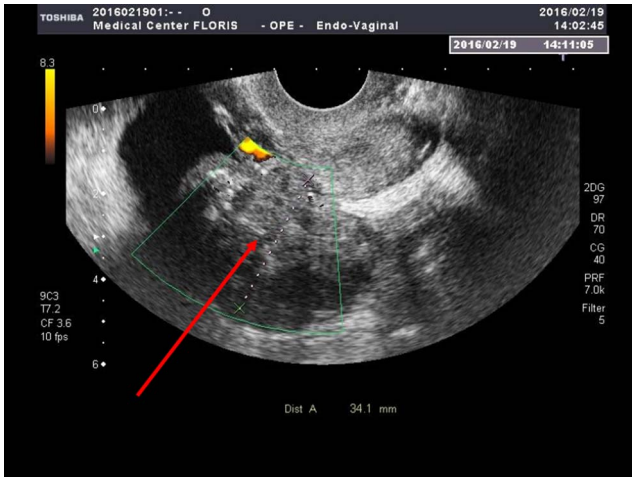


Fig. 1. Ultrasound investigation of female genitals. Arrow shows the tumor

Transvaginal ultrasound

On the anterior wall of the uterus, the intramural subserous myoma node revealed, size $9 \times 5.7 \times 5.8$ mm, heterogeneous consistency. The size of the left ovary was $54.8 \times 29 \times 42.8$ mm and the right was $100 \times 75 \times 68$ mm. They looked as solid-cystic formations with irregular lining, heterogeneous with low echoicity, fibrous areas, and single small calcifications, moderately vascularized, the lymph nodes were not visualized (*Fig. 1*).

The patient was diagnosed with the following conditions: small uterine myoma and two-sided malignant growth of ovaries. Planned surgical removal was carried out: extirpation of uterus and appendages, and resection of the greater omentum. During the surgery it was revealed that the uterus was not enlarged, and the endometrium was normal. Right ovary was cystous, size $4.5 \times 4.0 \times 2.5$ cm, filled with serous fluid, and right fallopian tube was absent. The left ovary was fibrous, and the left fallopian tube was sacular tumor-like, size $4.0 \times 4.0 \times 3.5$ cm. On the cut, the affected tube was presented as a cavity, filled with friable masses that marked with a pointer (*Fig. 2*). No pathological changes were revealed in lymph nodes, minimum free fluid in abdomen was present. The malignant neoplasm of the left fallopian tube was diagnosed in postoperative period, stage 1, group 2. The postoperative period proceeded without any complications.

Histological features of the tissues were studied using serial and stepped sections stained with hematoxylin and eosin. The morphological pictures of chronic endocervicitis were presented, in the cervix, the endometrium had cystous atrophic changes. Right ovary had simple cysts. The age-related changes were revealed in the left ovary. Specific inflammatory microscopic changes were found in the left fallopian tube, which were characterized by the presence of caseous necrosis, surrounded by

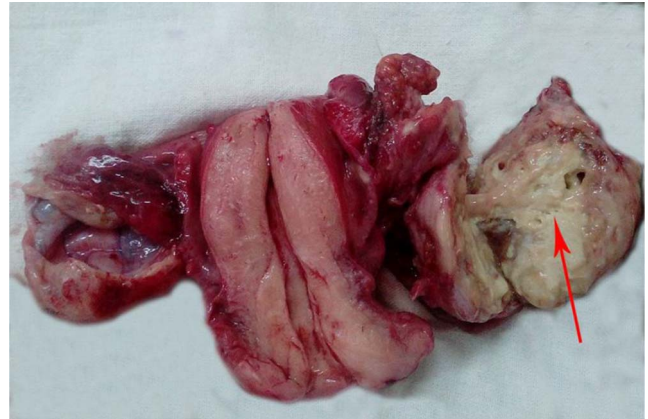


Fig. 2. Uterus appendages. Left fallopian tube with a growth presented as a cavity filled with friable masses (marked with a pointer)

epithelioid cells, lymphocytes, and Langhans giant cells (*Fig. 3*). The lesions affected all the layers of thickened fallopian tube. The infiltration by lymphocytes and necrotic areas as well as fibrosis – proliferation of connective tissues – was observed (*Fig. 4*). The abovementioned morphological picture corresponds to a relatively late stage of TB inflammation. This case is considered a secondary tuberculous salpingitis due to the absence of TB lymphadenitis. The treatment by anti-TB drugs for 6 months in a specialized institution was recommended.

Written informed consent was obtained from the patient for publication of this case report and any accompanying images.

Discussion

TB is a long-term chronic infectious disease. It is still a global epidemic problem. Recently, Ukrainian doctors expressed their concern about female genital TB because

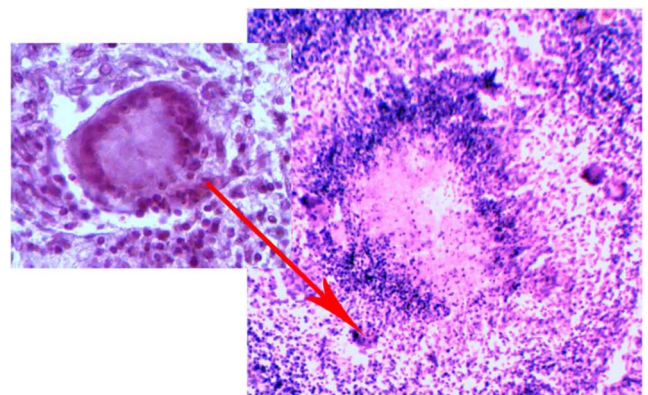


Fig. 3. Left fallopian tube. Area of caseous necrosis surrounded by epithelioid cells, lymphocytes, and Langhans giant cells. Stained with hematoxylin and eosin (Magnification 400 \times)

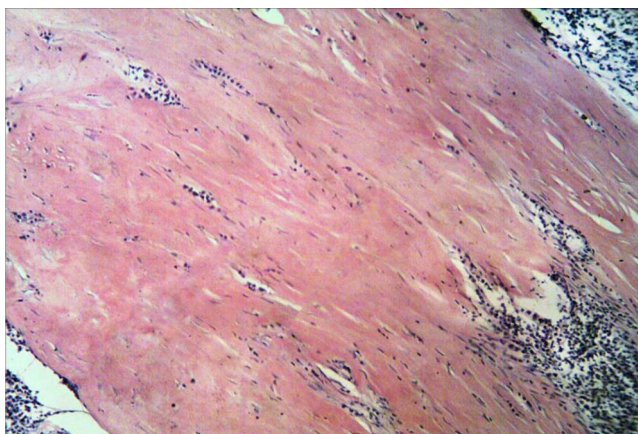


Fig. 4. Nonspecific changes in left fallopian tube – proliferation of connective tissue with a large number of fibroblasts, fibrocytes, and histiocytes. Stained with hematoxylin and eosin (Magnification 100×)

the rate of incidence increases rapidly. In 2015, 23,896 patients were diagnosed with active TB in Ukraine, including 134 cases of TB of the genitourinary system.

According to the literature, the lesions in genitourinary system are highly ranked among extrapulmonary TB types [1, 6]. Genital TB in women is a rare case and usually occurs secondary to the other lesions [5]. It spreads mostly hematogenously, in rare cases – directly from the upper genital tract or sexually transmitted [2, 8]. The lesion of genitals mostly occurs during the reproductive age, and in 10–40% of cases causes the infertility [9, 10]. Fallopian tube (95–100%), endometrium (50–60%), ovaries (20–30%), cervix (5–15%), uterus muscle (2.5%), and vulva/vagina (1%) are more often affected [11, 12]. Salpingitis is a form of inflammation in women, usually asymptomatic [13]. General symptoms include low-grade fever, abdominal pain, and infertility [5, 9].

The atypical clinical case of TB of fallopian tube in postmenopausal women was considered in this study. In our case, it simulated a cancer of appendages at the late stages that were proved by the increased level of CA-125. This fact as well as the macroscopic image of the left fallopian tube was incorrectly considered by the clinicians as a malignant neoplasm of fallopian tube. However, the histological study, the main method of verification of the diagnosis [14], revealed the specific granulomas in the samples that indicate the tubercular inflammation. In this case, the differential diagnostics with syphilitic granuloma needs to be carried out. The presence of caseous necrosis with a significant number of lymphocytes, plasma cells, and fibroblasts is typical for both diseases. The rapid formation of connective tissue with many blood vessels with proliferating endothelium (endovasculitis) around the lesion of necrosis is typical for the syphilitic gumma, but it was not observed in our case. Also in our case Wassermann test was negative. For sarcoidosis, the lesion in the fallopian tubes is extremely rare case [15]. Caseous

necrosis is more typical for TB than for sarcoidosis granulomas; in some granulomas, the fibrinoid necrosis may appear. These granulomas consist mainly of epithelioid cells mixed with lymphoid cells and Langhans giant cells.

This TB inflammation in the fallopian tube may be both the result of an infection, spreading hematogenously, or primary lesion caused by the microbacterium that was sexually transmitted from a partner with urogenital TB. No evidence of TB in men was observed that indicates the secondary nature of inflammation in the fallopian tube.

Given the atypical course of the disease, the presence of elevated levels of CA-125 test results, it was not possible to establish the correct diagnosis without morphological examination.

Conclusion

Nowadays, the genital TB is an extremely important medical and social problem because it affects the women of reproductive age. Gynecologists should be aware that it can be asymptomatic or with atypical symptoms. Such case of tuberculous salpingitis we showed in our article. Its course had atypical character and simulated a malignant tumor. TB inflammation of fallopian tubes requires complex examination, including clinical and X-ray, ultrasonic, bacteriological, and histological together with the tuberculin tests that allow to determine the specific inflammatory nature of the disease.

* * *

Funding sources: No financial support was received for this study.

Authors' contribution: AR: preparation and revision of manuscript; NG and SR: acquisition of data and preparation of manuscript; GS and ML: preparation of manuscript; MS: ultrasound investigation of female genitals.

Conflict of interest: The authors declare no conflict of interest.

References

1. Asmolov AK, Pavlova OV: Genital tuberculosis in women. *Ukrainian Med J* 4, 110–114 (2001)
2. Schaefer G: Female genital tuberculosis. *Clin Obstet Gynecol* 19, 223–239 (1976)
3. Bapna N, Swarankar M, Kotia N: Genital tuberculosis and its consequences on subsequent fertility. *J Obstet Gynecol India* 55, 534–537 (2005)
4. Morgagni JB: De Sedibus et Causis morborum. *Epistola* 38, 34 (1744)
5. Mondal SK, Dutta TK: A ten year clinicopathological study of female genital tuberculosis and impact on fertility. *JNMA J Nepal Med Assoc* 48, 52–57 (2009)

6. Zhuchenko OG, Stepanova TV, Gulua IR: Genital tuberculosis and surgical treatment of it. *Probl Tuberk* 9, 53–56 (2001)
7. Jassawalla MJ: Genital tuberculosis – A diagnostic dilemma. *J Obstet Gynecol India* 56, 203–204 (2006)
8. Chaudhary NN: Overview of tuberculosis of the female genital tract. *J Indian Med Assoc* 94, 345–346 (1996)
9. Kayukova SI, Makarov OV, Demikhova OV (2011): Problems of modern diagnostics of tuberculosis of female genitals. *Tuberculosis and illnesses of lungs*, pp. 49–51
10. Kolesnikov LI, Leshchenko OY, Popov NV: Modern view on problem of genital tuberculosis. *Materials XIII of the All-Russian Scientific Forum “Mother and Child”*, 278–279 (2011)
11. Simon HB, Weinstein AJ, Pasternak MS, Swartz MN, Kunz LJ: Genitourinary tuberculosis: Clinical features in a general hospital population. *Am J Med* 63, 410–420 (1977)
12. Qureshi RN, Sammad S, Hamd R, Lakha SF: Female genital tuberculosis revisited. *J Pak Med Assoc* 51, 16–18 (2001)
13. Botha MH, Van der Merwe FH: Female genital tuberculosis. *SA Fam Pract* 50, 12 (2008)
14. Goel G, Khatuja R, Radhakrishnan G, Agarwal R, Agarwal S, Kaur I: Role of newer methods of diagnosing genital tuberculosis in infertile women. *Indian J Pathol Microbiol* 56, 155–157 (2013)
15. Boakye K., Omalu B., Thomas L: Fallopian tube and pulmonary sarcoidosis. A case report. *J Reprod Med* 42, 533–535 (1997)