

A study of histopathological features of medullary carcinoma of the thyroid: Cases from a single institute in India

Desai Saral S, Sarkar Suchana, Borges Anita M

Department of Pathology, Tata Memorial Hospital, Dr. Ernest Borges Road, Parel, Mumbai - 400 012, India

Correspondence to: Dr. Saral Desai, E-mail: saraldesai@hotmail.com

Abstract

BACKGROUND: The microscopic features of medullary carcinoma have been described in world literature, together with its behavior and molecular biology. However, no large study has been reported from India. **AIMS:** This study aims to analyse the clinical, and especially the pathological features of medullary carcinoma of the thyroid, and the surrounding thyroid. **MATERIALS AND METHODS:** In this study a total of 234 cases of medullary thyroid carcinoma (MTC) were gathered over a period of 3 decades. The clinical presentation, the microscopic features and the clinical outcome were analyzed. **RESULTS:** MTC was found to be twice as common in men as in women and for some reason it occurred 10 years earlier in women. The histology revealed certain interesting features like the presence of apoptosis in over half of the tumors, in addition to the other common and not so common histological findings (encapsulated variant, small cell variants, follicular pattern, rosettes, oncocytic change, osteosarcoma-like pattern, and cribriform pattern). The adjacent thyroid in about 19% of the cases showed optically clear nuclei in the follicles that were close to the tumor cells. These features were similar to those seen in papillary thyroid carcinoma. **CONCLUSIONS:** The thyroid adjacent to MTC showed nuclear changes, which are also found in papillary carcinoma of the thyroid. The occasional concurrent occurrence of these two tumors and the involvement of the RET gene in both medullary and papillary carcinomas, makes this observation worth discussing and studying further.

Key Words: Medullary carcinoma, papillary carcinoma, thyroid, RET, apoptosis, clear

Introduction

Medical literature is swamped with articles on medullary carcinoma of the thyroid describing its clinical picture, the histology, the etiology, and its molecular biology. The aim of this study was to examine the histological and clinical aspects of medullary carcinoma as it pertains to India. This study aims to confirm the histopathological features already discussed in the literature, and to find any other morphological characteristics of this tumor.

Materials and Methods

This is a retrospective analysis of the cases diagnosed as Medullary Thyroid Carcinoma (MTC) over a period of 30 years (1971-2000). A total of 234 cases were accrued. The demographic data, clinical details, and the treatment modalities were studied. The period of follow-up ranged from 1 month to 20 years and the data was analyzed with reference to the outcome (using Kaplan Meier survival analysis). The modes of arriving at the diagnosis of MTC were also evaluated.

The histological criteria for calling a tumor medullary carcinoma included the pattern of growth seen in neuroendocrine tumors, the cytological features of a neuroendocrine tumor, and amyloid deposition. Immunohistochemistry was used for confirmation or in doubtful cases. The pathology material comprised the surgical specimen, paraffin blocks or glass slides. The nature of material depended on where the primary excision was performed. Usually the consultation cases (sent for confirmation or when in doubt) were sent as either paraffin blocks or glass slides. The tissues were routinely processed i.e. formalin fixed, paraffin embedded, and stained with hematoxylin and eosin. Certain histochemical stains like Congo-red for amyloid and Mayer's mucicarmine for the presence of mucin were performed where indicated. Immunohistochemical tests were also employed using antibodies against calcitonin, carcinoembryonic antigen, chromogranin, synaptophysin, neuron specific enolase, thyroglobulin, cytokeratin, epithelial membrane antigen and vimentin.

Results

A total of 234 cases of MTC were identified and investigated. The male to female ratio was 1:0.45. The age of the patients ranged from 16 to 77 years, with a mean of 46.7 years. Interestingly, the mean age of the female patients was 39.67 years, and that of the male patients was 49.16 years. Thus women presented with MTC a decade earlier than the men. The patients presented with a variety of symptoms. In the descending order of frequency they were neck swelling, cervical nodes, dysphagia/hoarseness, metastasis, and diarrhea.

Only two patients had history of MEN IIA. The rest of the cases either did not have features of MEN or were not investigated for MEN. They (MEN IIA cases) did not behave any differently than the rest of the cases.

The tumors on gross examination were firm, gray-white, with occasional areas of hemorrhage and necrosis. The size of the tumors ranged from 0.5 to 11 cm in the greatest dimensions. Twenty-four tumors were multicentric (10%).

The histology showed that the tumor could be circumscribed (29%) or infiltrative (71%). The tumor cells were arranged in a variety of patterns viz. classical (39%) where the cells were present in sheets separated by stroma that was highly vascular, often hyalinized, and contained amyloid. The other common pattern was insular (26%) where the cells seemed to be grouped

into islands surrounded by vascular stroma. Trabecular arrangement of the tumor cells was noted in 9% of the cases, while 6% of the cases were rich in amyloid. The various other interesting patterns noted were: pseudopapillary - 8 cases; microglandular - 7 cases; small-cell carcinoma-like pattern - 7 cases; cribriform appearance - 5 cases; follicular pattern - 4 cases; squamous differentiation - 4 cases; rosettes - 3 cases; oncocytic change - 2 cases; and 1 case each of hemangioendotheliomatous appearance, osteogenic sarcoma-like, glomeruloid, cystic, whorled, and encapsulated.

The typical medullary carcinoma cells were polygonal cells with granular amphophilic cytoplasm and a nucleus with fine chromatin. Nucleoli were generally inconspicuous. This typical appearance was noted in almost all the tumors. Various other cell types were noted in addition to the typical MTC cell. These were plasmacytoid - 46.5%, spindly - 20.5%, and lymphocyte-like - 11.5%. Nucleoli were seen in 5.5% of the cases.

Mitoses were not easy to find, and frequent mitoses were noted in only 17 cases.

Necrosis was noted in 26 cases. In 10 cases the necrosis was focally present, while in the remaining 16 cases the necrosis was of the comedo-type (Figure 1). Calcification was noted in 19% of the cases. In 4 cases psammomatous type of calcification was observed. Ossification was present in 5 cases. Eight per cent of the cases revealed areas of hemorrhage and another 8% of the cases showed hemorrhage in the form of blood-lakes.

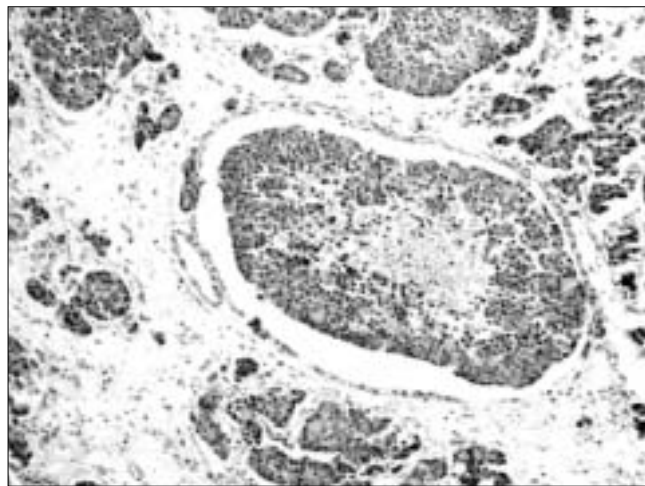


Figure 1: Photomicrograph showing islands of tumor cells with central necrosis. This type of necrosis is very much like the comedo-type of necrosis seen in breast carcinoma (H/E, x100)

Lymphovascular emboli were noted in 15% of the cases of MTC.

Apoptosis is infrequently mentioned in the literature and in this study large areas of apoptosis were seen in 54% of the cases. The apoptotic cells were surrounded by histiocyte-like, cytoplasmically clear tumor cells (Figure 2).

The stain for mucin was positive in 22% of the cases. The tumor cells were positive for calcitonin in all but one case where immunohistochemistry was employed (37 cases). Carcinoembryonic antigen was also positive in the MTC cells, as was chromogranin, neuron specific enolase, and synaptophysin in varying frequencies (Table 1). The tumor was positive for cytokeratin, wherever it was employed.

The adjacent thyroid was available for study in 114 cases. It appeared normal in 57% of the cases. Lymphocytic thyroiditis was seen in 11% of the cases, while 2 cases revealed Hashimoto's thyroiditis. Other thyroid neoplasms were seen in some cases – papillary thyroid carcinoma - 7 cases, follicular adenoma - 3 cases, follicular carcinoma - 1 case, and anaplastic carcinoma - 1 case.

Papillary thyroid carcinoma (PTC) was the most common thyroid neoplasm associated with medullary carcinoma.

An interesting and intriguing observation was the presence of optically clear nuclei in the adjacent thyroid in 19.2% of the cases. This change was particularly noted in cases with infiltrative medullary carcinoma, where the tumor cells and the normal thyroid follicular cells mingled intimately (Figures 3, 4). Nuclear clearing can be seen in Hashimoto's thyroiditis, but none of

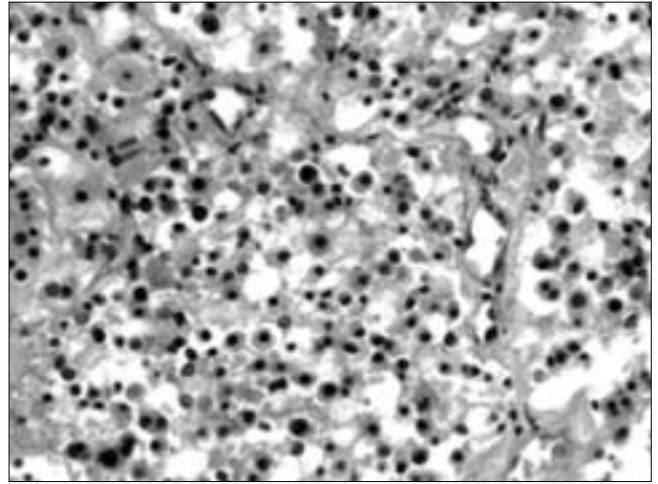


Figure 2: Photomicrograph demonstrating apoptotic cells. These cells are surrounded by cells that look like macrophages, but are in fact tumor cells (H/E, x400)

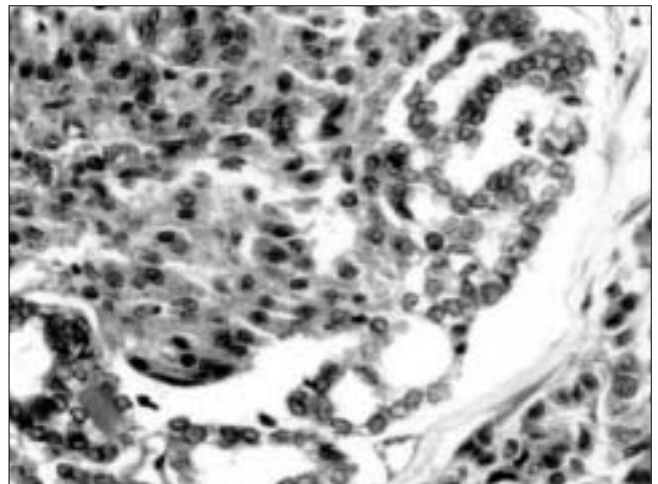


Figure 3: Seen in this illustration is medullary carcinoma (left) in close proximity to the native thyroid follicle (right-center). The cells of the thyroid follicles appear to have optically clear nuclei (H/E, x200)

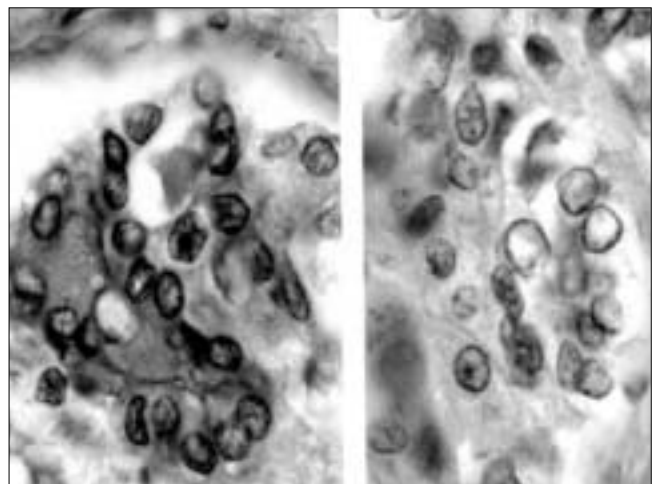


Figure 4: On higher magnification, the adjacent thyroid showed features that are noted in a papillary carcinoma of thyroid. Left—nuclear grooves, and right - optically clear 'orphan Annie-eye' nuclei (both H/E, x1000)

Table 1: Data on immunohistochemical staining with the results

Antibody	Company	Dilution	Positive reaction
1. Calcitonin	DAKO	1:50	36 / 37
2. Carcino-Embryonic Antigen	DAKO	1:400	11 / 11
3. Chromogranin	DAKO	1:100	22 / 24
4. Synaptophysin	DAKO	1:50	1 / 2
5. Neuron Specific Enolase	DAKO	1:50	3 / 3
6. Cytokeratin (MNF 116)	DAKO	1:100	4 / 4
7. Epithelial Membrane Antigen	DAKO	1:100	3 / 6
8. Vimentin	DAKO	1:50	1 / 3

these cases had this condition.

Though C-cell hyperplasia was noted in a few cases, the pathology material was inadequate to comment comprehensively on whether C-cell hyperplasia was present or not.

Of the 143 cases in which the neck nodes were dissected or information was available, 138 showed metastasis of MTC. In cases where the nodes were specifically labeled, the nodes of the central compartment were involved in 8 of 10 cases, tracheal and paratracheal nodes in 9 of 10 cases, and mediastinal nodes in 14 of 15 cases.

In 4.1% of the patients, there was tumor metastasis. The secondary site included lungs, liver, and bones.

As this study spans 30 years and our institute is a tertiary reporting center, various modalities of treatment were employed. In the later period of the study, patients treated per primum at our institute received total thyroidectomy with meticulous clearance of the central compartment and tracheo-esophageal nodes as minimum treatment. Since this is a retrospective study, the impact of different treatment modalities cannot be assessed.

Most of the patients were treated with surgery, which included thyroidectomy (partial, hemi, subtotal, or total), with or without cervical lymph node dissection. Adjuvant therapy in the form of radiation was given in 20% of the cases, and this was combined with chemotherapy in 5% of the cases.

The patients were followed up for a period 1 month to 20 years. Twenty-two per cent of the patients died due to disease, 16% are living with metastatic disease and in half of the patients there is no evidence of any residual disease. About 12% of the patients were lost to follow-up. The five-year survival rates were calculated. In men they were 50% and in women 62.5%. In patients less than 40 years of age the survival rate was 68.3%, while in patients more than 40 years it was 42.85%. Patients that were seen at an earlier stage had better survival. The histology however, did not appear to influence the disease course or survival. The follow-up data was available in only a third of the cases with distant metastasis, wherein the disease had been controlled.

There was no difference in the outcome of patients with histological variants of MTC.

The management of MTC is such that the

concomitantly present other thyroid tumors, were also treated (excised with primary tumor). Hence there was no change in the behavior of these tumors.

Discussion

Hazard et al^[1] first described medullary carcinoma of the thyroid. Over the years there has been a torrent of articles in the English language literature on MTC, detailing their morphologic diversities, clinical behavior, and molecular biology.

This is a descriptive study on the histological features of MTC, from one institute in India.

In the present study we noted that MTC was twice as common in men than in women, while the literature states that these tumors are more common in women when sporadic.^[2] But the women in this study presented a decade earlier with this cancer, as compared to the men. We have not seen a similar observation in the literature on MTC. In a country where presentation and treatment of a disease in men precedes that of women, this is an interesting observation.

A wide variety of patterns was noted in this study. These included the encapsulated type, follicular type, oncocytic type, squamous type, cribriform type, rosette formation, osteogenic sarcoma type, and pseudopapillary types. The histology did not seem to influence the course of the disease.

Apoptotic cells were noted in 54% of the cases. The presence of apoptotic cells has not been stressed much in the literature. Their presence was not associated with either aggressive disease or any other clinicomorphologic entity. MTC has been shown to express bcl-2 and c-myc immunoreactivity.^[3] A study by Wang et al^[4] has demonstrated that immunoreactivity to bcl-2 had a higher rate in disease-free individuals than in those with recurrent disease.

The occurrence of papillary carcinoma of the thyroid with MTC has been well recorded. This association may not be incidental as the figures suggest.^[5,6] It is intriguing that although a synchronous PTC was found in only 7 cases in the present study, three times this number (22 cases) showed foci of nuclear clearing, indistinguishable from the characteristic nuclear changes seen in PTC, in thyroid follicles adjacent to the medullary carcinoma or in-between the infiltrating medullary carcinoma cells. These foci were distinct, did not form localized masses and were similar to changes seen in some benign thyroid lesions.^[7-9] Cells with

nuclear clearing in benign and malignant thyroid diseases have been previously investigated for the over-expression of the RET oncogene.^[7] It is significant that even in benign conditions only those cells that showed nuclear clearing were shown to express RET.^[7] The *rearrangement* of the RET gene (RET/PTC) is the most common genetic alteration in PTC resulting from the fusion of the tyrosine kinase domain of RET to the 5' portion of different genes.^[10] Medullary carcinoma is associated with *mutations* of the RET oncogene which affects the residues in the cysteine-rich extracellular and in the intracellular tyrosine kinase domains.^[11] However, a study describes that point *mutations* in RET can drive the generation of PTC.^[12]

It is intriguing therefore to speculate on the possible reasons for the higher frequency of association of medullary carcinoma with PTC, and the hitherto unreported finding of benign thyroid follicles in the vicinity of MTC showing nuclear changes of PTC. Further investigations to confirm our observations and probe the affected cells for RET alterations would be needed to elucidate the underlying mechanisms for this relationship.

This study is retrospective and suffers from lack of adequate material, follow-up and treatment details. Nonetheless, it forms the baseline for other investigations on MTC from India, in the years to follow. Future studies from India can be on: the reason for low incidence of MEN, incidence of MTC syndrome, a study on C-cell hyperplasia in thyroid, the frequency of mixed tumors in thyroid, behavioral characteristics of MTC, and determination of RET oncogene in MTC and PTC.

References

1. Hazard JB, Hawk WA, Crile G Jr. Medullary (solid) carcinoma of the thyroid. A clinico-pathologic entity. *J Clin Endocrinol Metab* 1959;19:152-61.
2. Williams ED, Brown CL, Doniach I. Pathological and clinical findings in a series of 67 cases of medullary carcinoma of the thyroid. *J Clin Pathol* 1966;19:103-13.
3. Wang DG, Liu WH, Johnston CF, Sloan JM, Buchanan KD. Bcl-2 and c-Myc, but not bax and p53, are expressed during human medullary thyroid tumorigenesis. *Am J Pathol* 1998;152:1407-13.
4. Wang W, Johansson H, Bergholm U, Wilander E, Grimelius L. Apoptosis and Expression of the Proto-Oncogenes bcl-2 and p53 and the Proliferation Factor Ki-67 in Human Medullary Thyroid Carcinoma. *Endocr Pathol* 1996;7:37-45.
5. Albores-Saavedra J, Gorraez de la Mora T, de la Torre-Rendon F, Gould E. Mixed medullary-papillary carcinoma of the thyroid. A previously unrecognized variant of thyroid carcinoma. *Hum Pathol* 1990;21:1151-5.
6. Matias-Guiu X, Caixas A, Costa I, Cabezas R, Prat J. Compound medullary-papillary carcinoma of the thyroid. True mixed tumor. *Histopathology* 1994;25:183-4.
7. Fusco A, Chiappetta G, Hui P, Garcia-Rostan G, Golden L, Kinder BK, et al. Assessment of RET/PTC Oncogene Activation and Clonality in Thyroid Nodules with Incomplete Morphological Evidence of Papillary Carcinoma. A Search for the Early Precursors of Papillary Cancer. *Am J Pathol* 2002;160:2157-67.
8. Sheils OM, O'early JJ, Uhlmann V, Lattich K, Sweeney EC. ret/PTC-1 Activation in Hashimoto Thyroiditis. *Int J Surg Pathol* 2000;8:185-9.
9. Inaba M, Umemura S, Satoh H, Abe Y, Kurokawa K, Sakai H, et al. Expression of RET in follicular cell-derived tumors of the thyroid gland: Prevalence and implication of morphological type. *Pathol Int* 2003;53:146-53.
10. Nikiforov YE. RET/PTC rearrangement in thyroid tumors. *Endocr Pathol* 2002;13:3-16.
11. Takahashi M. Oncogenic activation of the ret protooncogene in thyroid cancer. *Crit Rev Oncog* 1995;6:35-46.
12. Melillo RM, Cirafici AM, De Falco V, Bellantoni M, Chiappetta G, Fusco A, et al. The oncogenic activity of RET point mutants for follicular thyroid cells may account for the occurrence of papillary thyroid carcinoma in patients affected by familial medullary thyroid carcinomas. *Am J Pathol* 2004;165:511-21.