

# A Systematic Approach to the Differential Diagnosis and Management of the Complications of Monochorionic Twin Pregnancies

E. Gratacós<sup>a</sup> J.U. Ortiz<sup>a, b</sup> J.M. Martínez<sup>a</sup>

<sup>a</sup>Maternal-Fetal Medicine Department, Institut Clínic de Ginecologia, Obstetrícia i Neonatologia (ICGON), Hospital Clínic, Institut d'Investigacions Biomèdiques Augusto Pi i Sunyer (IDIBAPS), University of Barcelona, and Centro de Investigación Biomédica en Red de Enfermedades Raras (CIBERER), Barcelona, Spain; <sup>b</sup>Frauenklinik und Poliklinik, Technische Universität München, Munich, Germany

## Key Words

Monochorionic twin pregnancy · Twin-twin transfusion syndrome · Twin anemia-polycythemia sequence · Acute feto-fetal transfusion · Selective intrauterine growth restriction · Discordant malformation

## Abstract

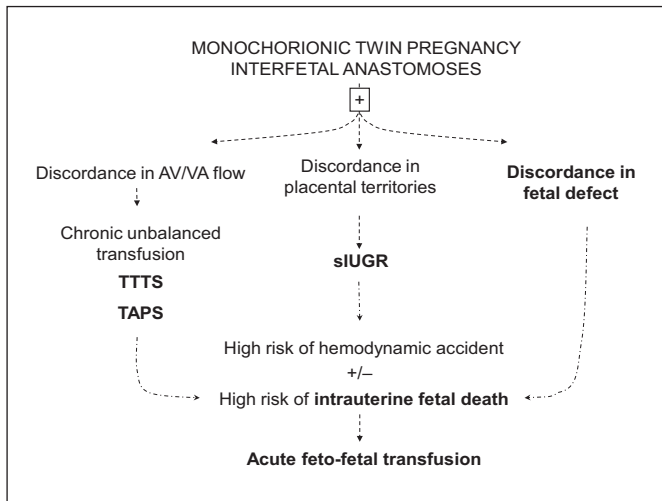
Monochorionic (MC) twins represent a significant proportion of perinatal morbidity and mortality. Overall, 1 of 3 MC twin pregnancies will develop complications in relation to the MC placenta and the presence of interfetal placental anastomoses. From a clinical standpoint, these complications can be grouped into four main types of clinical problems: chronic transfusion, acute transfusion, growth discordance, and discordant malformation. Differential diagnosis of MC twin complications is still challenging due to frequent overlap of their clinical signs and the complex relationships between them. Clinical experience demonstrates that most instances of wrong management derive from failure to comply with a basic set of rules for diagnosis and management. In this review, we propose a simplified approach to the understanding of MC twin pregnancy, its potential complications, and the key concepts allowing adequate differential diagnosis and targeted management.

Copyright © 2012 S. Karger AG, Basel

## Introduction and Goals of This Review

A monochorionic (MC) twin pregnancy occurs in 1 of 250 pregnancies, in about 20% of twin pregnancies and 70% of monozygotic twins [1, 2]. MC pregnancies account for a significant proportion of perinatal morbidity and mortality in twins [3–5]. The perinatal mortality rate is around twice and 4 times as high as in dichorionic twins and single pregnancies, respectively [6]. Neurological morbidity is 4–5 times as high as in dichorionic pregnancies and therefore 25–30 times as high as in singletons. Overall, 1 of 3 MC pregnancies can have complications [7, 8].

Optimal management of MC twins entails early classification of chorionicity and close follow-up. Chorionicity diagnosis should be performed at the 11- to 14-week ultrasound scan demonstrating the presence of T-sign (direct binding of the two thin amniotic membranes) which is possible in almost all cases [9, 10]. Early diagnosis and timely management can substantially improve the prognosis of MC twin complications. However, for the average fetal medicine specialist, differential diagnosis of the complications of MC twins is still challenging. This is due to the frequent overlap of clinical signs and complex relationships between the different potential complications. However, differential diagnosis and ensuing de-



**Fig. 1.** Schematic representation of the main groups of complications in MC twins and their common relationship with the presence of placental anastomosis.

cisions are based on relatively simple rules. While some MC cases may be really intricate, clinical experience demonstrates that in most instances proper classification and management can be achieved by systematic application of relatively simple concepts.

#### *The Unique Characteristics of the MC Placenta*

The main feature of MC twins is the existence of placental anastomoses which can be arterioarterial (AA), venovenous (VV) or arteriovenous (AV) [11]. Vascular placental connections result in the existence of bilateral fetofetal transfusion, a sort of third circulatory system between two individuals which is unique in human pathology. Anastomoses are the ever-present factor which underlies all the particularities of MC twin pathology. They can cause problems by themselves or in combination with other problems, namely discordant placental territories and/or fetal malformations [12].

As mentioned above, one of the difficulties in the clinical management of MC twins is that the existence of one complication does not exclude others. There is often an overlap, particularly between transfusion syndromes and growth restriction. However, a systematic approach must allow establishing the prevailing diagnosis in each particular case, which will mandate the mode of management. In this review, we propose to group the complications of MC twins into four main types of clinical problems: chronic transfusion, acute transfusion, growth discordance, and discordant malformation. The relation-

ship of these complications with placental anastomoses and among each other is illustrated in figure 1.

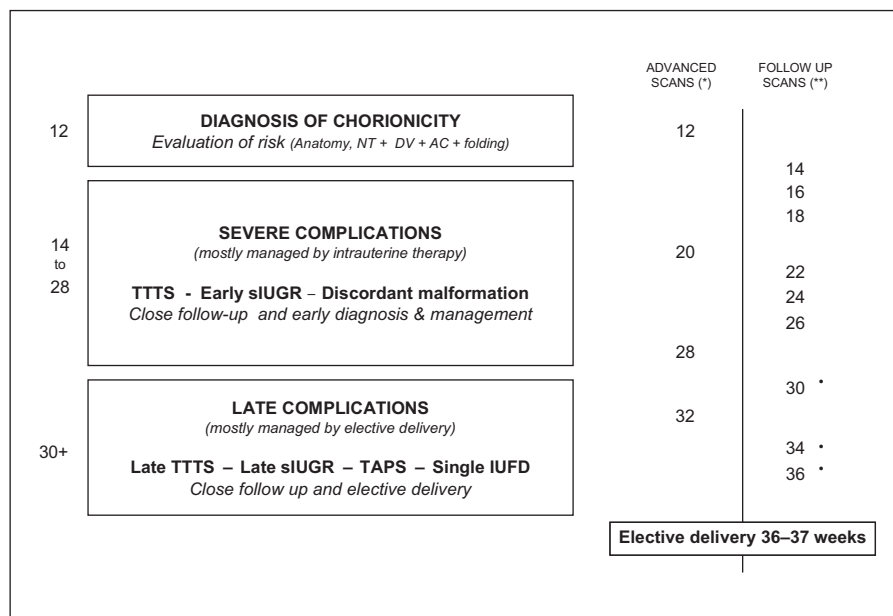
#### *A Very Brief Summary of the Main Moments of MC Twin Pregnancies and the Rationale for Follow-Up Schemes*

Management of MC pregnancy is challenging. The prevalence of MC twins is low (1 in 250 pregnancies) and adequate assessment requires advanced skills. We consider that it is not wise to conduct follow-up of these pregnancies in a non-specialized environment, at least not entirely. A minimum of critical scans should be performed at specialized units. Using a simplifying approach, MC twin pregnancy could be split into three main phases where the main goals of management differ (fig. 2):

- 12–14 weeks: early diagnosis of chorionicity and ruling out most obvious structural malformations.
- 15–28 weeks: early detection and treatment of serious complications mainly amenable to fetal therapy [twin-to-twin transfusion syndrome (TTTS) and early selective intrauterine growth restriction (sIUGR)].
- 29–36 weeks: early detection of complications mainly (not exclusively) amenable to elective delivery [late-onset TTTS, late IUGR, and twin anemia polycythemia sequence (TAPS)].

Regardless of these main phases, follow-up of MC pregnancies must be done at 2-week intervals. The main reason is to detect TTTS cases as early as possible, which may appear days after a normal exam. Use of predictors such as ductus venosus Doppler, nuchal translucency, membrane folding, and abdominal circumference discordance at 12 weeks may assist in identifying high-risk cases [13–15]. However, the sensitivity of these signs is not extremely high, and from a practical point of view, all MC twins must anyway be followed up every 2 weeks [16]. Standard complete ultrasound evaluations should be performed, ideally by specialists with experience in MC twins, at 12, 20, 28, and 32 weeks. In the time between these critical scans, 2-weekly follow-up could be limited to subjective assessment of amniotic fluid (AF) and fetal abdominal circumferences. Although the likelihood of serious complications is lower beyond 28 weeks, these may still occur and progress rapidly. Considering the low prevalence of MC pregnancies, we believe that continuing the 2-week follow-up scheme until the end of gestation is the most reasonable approach. The risk of intrauterine fetal death (IUFD) in apparently uncomplicated MC twins seems to be very low, but the consequences can be devastating [17, 18]. Consequently, there is a certain

**Fig. 2.** A proposed schematic representation of the three main stages in the follow-up of MC twin pregnancies. Follow-up should be performed every 2 weeks until term to allow early identification of TTTS. NT = Nuchal translucency; DV = ductus venosus; AC = abdominal circumference. \* Advanced scans should be performed by high-level fetal medicine specialists and include anatomy, fetal biometry, and Doppler. Echocardiographic assessment should be included, considering the higher prevalence of fetal and cardiac defects in this population. \*\* Follow-up scans could be performed in clinics equipped with an ultrasound machine, ideally by personnel with experience in the follow-up of MC twins. Follow-up scans can be limited to assessment of AF and abdominal circumferences and, from the third trimester, MCA Doppler to rule out TAPS. • Peak systolic velocity of MCA.



consensus that for uncomplicated MC twins, elective delivery around 36–37 weeks is a reasonable approach [19–21].

#### Goals of This Review

This review does not intend to provide comprehensive descriptions of the complications of MC twins and their variants. This aim would exceed by large the extent of a single review. Our main goal is to provide a relatively alternative approach, which essentially focuses on the global picture. Thus, we hope to help the average clinician achieve a more integrated understanding of MC twin pregnancy, its potential complications, and the key concepts allowing adequate differential diagnosis and targeted management.

#### Chronic Feto-Fetal Transfusion Syndromes: TTTS and TAPS

Chronic intertwin transfusions, particularly TTTS, are the best known complications of MC twins. Both TTTS and TAPS result from unbalanced AV net blood flow from one twin to the other, however, with remarkable differences in the magnitude of blood flow exchange and, consequently, in the pathophysiology, clinical presentation, and prognosis.

#### Twin-to-Twin Transfusion Syndrome

TTTS occurs in 10–15% of all MC twins [22, 23]. The basis for the development of TTTS is the development of AV/VA discordant flow [24]. In most cases, TTTS results from a predominance in the number and/or diameter of AV anastomoses from the donor to the recipient fetus [25]. It seems very likely that the unbalance in AV anastomoses combines with other factors such as fetal weight discordance, relative placental growth, cord insertions or other fetal factors (i.e. cardiac defects), which may help triggering the disease in individual cases. TTTS is a severe hemodynamic disorder which leads to a progressive sequence characterized by hypovolemia, oliguria, and oligohydramnios in the donor, and hypervolemia, polyuria, and polyhydramnios in the recipient [26, 27]. Additionally, release of vasoactive substances and sustained oliguria lead to hypertension and renal tubular damage in the donor, while transfer of these substances to the recipient is thought to produce hypertension and contribute further to hypertrophic cardiomyopathy [28–30]. Irrespective of the complex pathophysiology underlying this syndrome, there is universal agreement that TTTS is invariably associated with massive changes in fetal diuresis that lead to very obvious differences in AF deepest pocket and bladder size.

While there remain some differences in AF cutoff values used above 20 weeks, there is virtually universal consensus on the diagnostic criteria (table 1). These are es-

**Table 1.** Diagnostic criteria and staging of severity of TTTS [31, 32]

---

Diagnostic criteria	
-	Confirmed MC pregnancy
-	Polyhydramnios in the recipient with a deepest vertical pocket of $\geq 8$ cm*
-	Oligohydramnios in the donor with a deepest vertical pocket $< 2$ cm
-	Discordant fetal bladders with markedly enlarged bladder in the recipient and very small or non-visible bladder in the donor during most of the examination

---

Severity staging	
I	The bladder is still visible in the donor twin
II	The bladder is no longer visible in the donor twin
III	Critically abnormal Doppler in either twin: absent/reverse diastolic flow in the umbilical artery of the donor or recipient and/or absent/reverse flow in the ductus venosus or pulsatile flow in the umbilical vein of the recipient
IV	Hydrops in either fetus
V	Demise of one or both twins

---

\* The cutoff above 20 weeks is still a subject of debate. A cutoff of  $\geq 10$  cm beyond 20 weeks has been used in randomized trials and is commonly used by European groups, while a unique cutoff of 8 cm is more commonly used in the United States. Both cutoffs are considered to be acceptable for the diagnosis.

---

**Table 2.** Diagnostic criteria for TAPS [48]

---

Prenatal	MCA-PSV $> 1.50$ MoM in the donor and MCA-PSV $< 0.80$ MoM in the recipient
Postnatal	Intertwin hemoglobin difference $> 8.0$ g/dl and Intertwin reticulocyte count ratio (donor/recipient) $> 1.7$

---

MCA-PSV = Middle cerebral artery peak systolic velocity as measured with spectral Doppler.

---

essentially based on the use of AF differences and bladder sizes as key signs for the diagnosis of TTTS. There is also consensus that strict criteria must be used to define (and treat) a case as TTTS [31]. Importantly, the diagnosis of TTTS does not consider differences in fetal weight nor Doppler information. From a clinical point of view, a substantial number of cases of TTTS are combined with selective IUGR, more commonly the donor twin. However, this is irrelevant for management decisions. Once the diagnosis is established, TTTS can be staged in degrees of

severity. The most widely used is the Quintero staging system (table 1) [32].

TTTS is always a severe condition with a high rate of perinatal morbidity (neurological handicap 40–80%) and mortality (100% before 20 weeks, 80% between 21 and 26 weeks) if left untreated. It always requires urgent therapy because it may progress abruptly and even lead to fetal death in very early stages [33]. The treatment of choice for TTTS between 15 and 28 weeks is fetoscopic laser coagulation of placental anastomosis. This therapy reverts the manifestations of the syndrome and it is associated with overall survival rates of 80–90% for at least one fetus [34–37]. In cases where laser is not possible, amniodrainage is a second-line palliative therapy to prolong pregnancy and improve survival (at least one fetus in 50–60% of cases) [34, 38], at the cost of a much higher rate of neurological handicap (29–35 vs. 11–16% with laser) [39, 40].

#### *Twin Anemia Polycythemia Sequence*

TAPS occurs spontaneously in 3–5% of MC twins, normally as a third-trimester complication [41]. TAPS occurs in placentas where interfetal anastomoses are very small. If there is a discordance in the size/diameter of these vessels, discordant AV interfetal flow occurs, but with a much lower magnitude than in TTTS [42]. Chronic subtle transfusion leads to anemia-polycythemia, but the severe hemodynamic fetal disturbances as in TTTS do not take place.

TAPS may also occur as a complication of incomplete coagulation after TTTS treatment in around 2–6% of cases, depending on the definitions and center experience [43, 44].

Either in non-complicated MC twins or after laser therapy, TAPS must be actively searched by means of routine middle cerebral artery (MCA) Doppler since, normally, there are no other manifestations [43, 45, 46]. In a remarkable proportion of cases, TAPS is diagnosed postnatally. Neonatal diagnostic criteria are based on the presence of severe hemoglobin and reticulocyte discordance [47, 48]. The prenatal and postnatal diagnostic criteria are summarized in table 2.

The prognosis in spontaneous cases is normally good and most cases can be managed expectantly [49]. TAPS after treatment of TTTS is usually more aggressive and requires therapy. Therapy is normally indicated if MCA Doppler discordance progresses rapidly or prehydropic signs are observed in the donor. The only causative treatment is laser therapy. In post-laser cases, technical challenges, such as normal AF in the donor and stained fluid due to previous laser may hamper or prevent this option

[50]. Alternatively, repeat transfusions to the donor, preferably intraperitoneally to minimize rapid passage of blood to the recipient, often achieve good outcomes [51] and therefore constitute an acceptable management scheme.

### Acute Feto-Fetal Transfusion

Acute transfusion occurs in MC twins when there is a sudden drop in pressure and/or heart rate at one fetal end. This leads to unidirectional transfusion and acute exsanguination of the co-twin – which behaves as an ‘acute donor’ – into the circulation of the fetus suffering the drop [52]. The consequences depend on the magnitude of the flow and duration of the blood transfer. In turn, the magnitude of flow depends on the size, type, and direction of interfetal anastomoses [53]. Fetuses with few and small anastomoses are much less exposed to serious damage than those with large AV or AA connections. Thus, the consequences are highly variable and may range from nothing to severe brain injury or death of the ‘acute donor’. Acute transfusion is highly associated with fetal death of one fetus, but the relation is variable. Hence, acute transfusion may be caused by a single fetal death, but in turn acute transfusion may *cause* fetal death.

Acute feto-fetal transfusion may occur in two situations:

- After single IUFD: transfusion occurs from the surviving twin to the dead fetus. The surviving twin has a risk of 18–34% of brain injury and about 15% of fetal death as a consequence of acute exsanguination [54, 55]. Single fetal death may occur as a final stage in TTTS and sIUGR, and this justifies that its prevention is a major goal in the management of these cases. In addition, fear of IUFD and its consequences in late pregnancy is normally the reason to recommend elective delivery between 36 and 37 weeks in MC pregnancies.
- With both fetuses alive: these accidents are thought to be the cause of unexplained postnatal brain lesions in apparently uncomplicated MC twin pregnancies [56, 57], and they are one of the typical complications of sIUGR type III cases [58] (see below). The most likely cause is the occurrence of a transient episode of bradychardia in one twin. The consequences are particularly devastating if the fetuses are connected by large AA anastomoses, which favor quick passage of large amounts of blood over minutes. Doppler has allowed to confirm cases of massive acute feto-fetal

transfusion during transient fetal bradychardia in the presence of large AA anastomoses [59]. The ‘acute donor’ fetus will be exposed to a high risk of brain injury or death. In turn, the ‘acute recipient’ may survive the sudden transfusion or die out of cardiovascular overload.

Therefore, as stated above, the combinations are multiple. Fetal death can be both the cause and the consequence of acute feto-fetal transfusion. Consequently, on discovering a single or double fetal death in MC twins, it is normally impossible to know what happened first.

*Intrapartum Acute Feto-Fetal Transfusion.* This is a rare accident with an incidence of 1.8–5.5% which may occur in the second twin after delivery of the first twin [60]. It may lead to very discordant hemoglobin levels. The differential diagnosis with TAPS is made by reticulocyte count, which in intrapartum transfusion is normal due to the acute nature of the accident. While there are no large series, clinical experience suggests that the prognosis is normally good. However, anecdotal cases of death of the co-twin have been reported [61, 62].

### sIUGR in MC Twins

#### *Early sIUGR*

Early sIUGR affects 10% of MC twins, with a similar frequency as observed in dichorionic twins [63]. sIUGR is diagnosed by an estimated fetal weight (EFW) of less than the 10th percentile in one fetus [64]. An EFW discordance  $\geq 25\%$  is a common feature of this entity. The main reason for the development of sIUGR in twins is the existence of a discrepancy in the placental territory [65]. However, the main feature of sIUGR in MC pregnancies is the co-existence of interfetal anastomoses [66], which strongly interfere in the natural history of growth restriction. As part of interfetal blood flow interchange, the IUGR twin receives well-oxygenated blood from its co-twin. This has been called ‘rescue transfusion’ because it generally induces a clearly beneficial effect on the IUGR fetus.

The amount and type of blood flow interchange changes according to the number and type of anastomoses, and this determines a wide variation in the clinical behavior of sIUGR. However, from a practical point of view, the type of Doppler in the umbilical artery of the IUGR fetus corresponds, in the vast majority of cases, with three relatively well-defined clinical patterns (table 3) [67].

**Table 3.** Type of sIUGR in MC twins according to the characteristics of umbilical artery Doppler in the small twin, and main clinical and placental features of each type [67]

Type	Clinical features	Placental features
Type I: normal Doppler (positive diastolic flow)	<ul style="list-style-type: none"> <li>– Benign course with smaller degree of weight discordance</li> <li>– Very low risk of IUFD and co-twin brain damage</li> <li>– IUGR evolves well (normally &gt;34 weeks' GA)</li> </ul>	<ul style="list-style-type: none"> <li>– Unequally shared placenta</li> <li>– High anastomotic diameter which largely compensates for placental territory imbalance</li> <li>– No or small AA anastomosis</li> </ul>
Type II: absent/reverse end-diastolic flow (constantly)	<ul style="list-style-type: none"> <li>– High risk of deterioration and IUFD of IUGR twin (predictable by Doppler evolution in most cases)</li> <li>– Very low risk of intrauterine brain injury of normal co-twin</li> <li>– Mean GA at delivery (due to deterioration of IUGR) 29 weeks</li> </ul>	<ul style="list-style-type: none"> <li>– Very unequally shared placenta</li> <li>– Smaller anastomotic diameter, which compensates for severe placental territory imbalance, but for a shorter time</li> <li>– No or small AA anastomosis</li> </ul>
Type III Intermittent absent/reverse end-diastolic flow	<ul style="list-style-type: none"> <li>– Low risk of hypoxic deterioration of IUGR twin which commonly survives until 32 weeks' GA and beyond</li> <li>– 10–15% risk of unexpected IUFD of IUGR twin (non-predictable)</li> <li>– 10–15% risk of brain injury in normal co-twin</li> </ul>	<ul style="list-style-type: none"> <li>– Very unequally shared placenta</li> <li>– A large AA anastomosis which largely compensates for unequal sharing and allows long in utero survival of IUGR twin, but carries high risk of acute feto-fetal transfusion accidents</li> </ul>

GA = Gestational age.

From the point of view of prognosis, the types described in table 3 can be divided in two, those with fairly good prognosis (type I) and those with high risk of serious complications (type II and III). Indeed, sIUGR type II and III are both at high risk of very-preterm delivery, intrauterine fetal death, and neurological sequelae [68, 69]. Aside from these common features, type III pregnancies are distinguished by the presence of large AA anastomosis. Large AA connecting vessels determine the appearance of the typical intermittent flow in the umbilical artery, a longer in utero survival of the IUGR twin [70, 71], and a higher risk of neurological injury rates in the large twin, which are thought to be caused by episodes of acute transfusion through the large AA anastomosis as discussed above [72, 73].

The management of sIUGR in MC twins is beyond the scope of this review. The main ideas behind clinical decisions should be that sIUGR type I has generally a good prognosis and, consequently, expectant management until 34–35 weeks seems reasonable. On the contrary, type II and III are generally associated with a poor prognosis. However, unlike TTTS, the prognosis and evolution of sIUGR II and III may be largely conditioned by the gestational age at presentation and the severity of IUGR. In addition, parents' wishes and expectations in relation to the outcome of the sIUGR twin and the risks for the normal twin will heavily influence their decisions. Therefore, different options ranging from expectant management to active therapy may be equally acceptable. Cord occlusion and laser therapy can be offered as options to protect intact survival of the larger twin and prolong the duration of pregnancy.

#### *Late sIUGR*

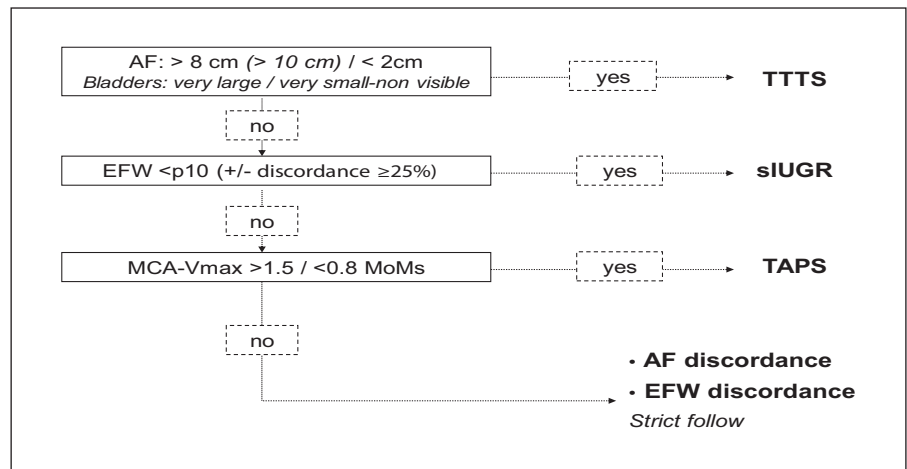
A subgroup of MC twins with apparently concordant growth in the second trimester will show progressive signs of discordance from the third trimester onwards. This has been described to occur in about 5% of cases within a large cohort of MC twins. Placental angioarchitecture and clinical outcome were described to be different from early sIUGR and these cases have generally a good prognosis [74].

#### **Differential Diagnosis between TTTS and Early sIUGR and the Management of 'Nothing for the Moment'**

The differential diagnosis between these two complications of MC twins has been a source of historical confusion. A substantial number of the earlier series of MC twin complications, particularly those dealing with TTTS, were likely to merge cases of TTTS and sIUGR according to current criteria. This is responsible for the remarkable differences in clinical behavior and outcomes that one can find on reviewing the literature. From the point of view of research, the situation has largely improved in studies published over the last decade.

From a clinical standpoint, difficulties in the differentiation between TTTS and sIUGR may remain in specific cases. In addition, the average clinician may find the 'high-risk-but-nothing-for-the-moment' cases particularly challenging. Indeed, on following up MC twins, it is relatively common to find cases with subjective differ-

**Fig. 3.** Algorithm for differential diagnosis in MC twins with apparent discrepancy in AF or fetal size.



ences in AF or fetal size, but with intermediate or overlapping features. The correct classification of such cases can be challenging, and a systematic approach is key to reach the adequate decision. Briefly, and once structurally normal fetuses are confirmed, one must remember that there can only be four scenarios: TTTS, sIUGR, TAPS or non-specific AF discordance. A structured algorithm will lead to accurate classification and adequate management in virtually all cases. We propose to use a sequence of questions, the order of which is determined by the importance and urgency of treatment (fig. 3). The first entity to rule out is always TTTS, since the prognosis is invariably poor and urgent treatment is mandatory. If TTTS is diagnosed, co-existence or not of IUGR is irrelevant; it does not change the need of urgent laser therapy. The second and third questions determine whether there is sIUGR and TAPS. The order of questions 2 and 3 is not so relevant, although in real practice, TAPS is extremely rare during the second trimester.

Finally, if all these conditions are excluded, we are left with a subjective discordance which does not meet any diagnostic criteria. These cases are normally referred to in the literature as ‘discordant for AF’, although it is common that some degree of fetal weight discordance also coexists. We recommend describing exactly the observations in the report, with a clear remark that ‘currently diagnostic criteria for TTTS (or sIUGR) are not met’. Having discordant AF represents a specific situation by itself and requires a change in the follow-up schemes. The risk of developing any complication over time, either TTTS or sIUGR, has been reported to be nearly 50% [75]. A weekly follow-up, or closer if the suspicion is high, should allow timely treatment if required in most cases.

**Table 4.** Basic principles for the management of MC twins

- 1 Early diagnosis (at 11- to 14-week scan) and ruling out malformations
  - 2 Follow-up every 2 weeks (EFW, AF, and MCA) by a fetal medicine specialist
  - 3 If suspicious: weekly follow-up
  - 4 If polyhydramnios/oligohydramnios sequence and diagnostic criteria are met = TTTS: immediate treatment
  - 5 If EFW <10th percentile in one fetus = sIUGR: umbilical artery Doppler
    - a Normal: expectant management
    - b Abnormal: discuss options with parents
- If no complications: elective delivery at 36–37 weeks of gestation

Obviously, a higher risk of unexpected rapid evolution and/or fetal demise will remain, and this should be made clear during counseling. However, parents must be reassured that this risk is in principle much lower than that of invasive therapy and that in 50% of cases, there will be a normal evolution and outcome. Therefore, according to current evidence, discordant AF should never be treated.

### MC Twins Discordant for Fetal Defects

MC twins discordant for fetal anomaly represent one of the characteristic and relatively common clinical situations in the management of MC twins. Fetal structural abnormalities affect up to 3% of cases, 3 times higher as compared with dichorionic twins or singletons [76]. Fetal structural anomalies affect only one twin in >80% of the

instances [77, 78]. Much more rarely, MC twins can be discordant for fetal karyotypes [79, 80].

One particularly common instance of discordant anomaly (up to 1% of MC twins) is the presence of an acardiac fetus, which survives thanks to twin reverse arterial perfusion (TRAP) sequence [81, 82]. While many cases may progress well until the third trimester, pregnancy loss may be as high as 50% due to cord entanglement, cardiac failure of the normal twin, also called 'pump twin', and complications related with polyhydramnios [83]. The survival rates with cord occlusion – and section in monoamniotic pregnancies – range from 80 to 90% [84].

Discordant MC twins entail two problems, the anxiety of parents and the fear of intrauterine death with its known complications. In reality, the number of cases in which the malformation is associated with a high risk of intrauterine death of the affected twin is small. Therefore, the problem is normally the parents' anxiety of carrying a fetus with a serious malformation. Obviously, selective feticide by any technique will threaten the whole pregnancy and consequently survival of the structurally normal fetus. In spite of these risks, a proportion of parents will request selective interruption of pregnancy where legally available. Cord occlusion by means of laser or bipolar coagulation is the option of choice for most of these cases. Radiofrequency is also a therapeutic option [85, 86]. This technique is particularly suited for the management of TRAP pregnancies, but success rate may be compromised in cases with one live fetus, especially in

advanced pregnancies [87]. Regardless of the technique used, survival rates in experienced hands for the normal twin with any technique for selective feticide in MC twins range from 80 to 90% [88]. While these figures may suggest a high rate of pregnancy loss, the cumulative rate of fetal loss or pre-viable preterm birth has been reported to be in the range of 10–15% in dichorionic twins [89].

## Conclusions

Adequate follow-up and management of MC twins can be accomplished by means of an integrated view of the main groups of complications and should be guided by very basic principles. The complexity and the uncountable number of combined complications that MC twin pregnancies can present may often blur clinical decisions in a way that such basic principles are forgotten. We propose a simplified (but clinically useful) approach to follow-up and management of MC twins (table 4), which in essence contains the obvious principles of early diagnosis, proper follow-up, and timely intervention. The rules proposed here might look too simplistic to condense the vast knowledge behind MC twin pregnancy. Of course, there will always be exceptional cases of high difficulty which are not covered by these rules. However, clinical experience of more than 15 years demonstrates that, still today, most instances of poor or suboptimal management derive from failure to comply with one or more of this basic set of principles.

## References

- 1 Lewi L, Gucciardo L, Van Mieghem T, de Koninck P, Beck V, Medek H, Van Schoubroeck D, Devlieger R, De Catte L, Deprest J: Monochorionic diamniotic twin pregnancies: natural history and risk stratification. *Fetal Diagn Ther* 2010;27:121–133.
- 2 Tchirikov M: Monochorionic twin pregnancy: screening, pathogenesis of complications and management in the era of microinvasive fetal surgery. *J Perinat Med* 2010;38:451–459.
- 3 Oldenburg A, Rode L, Bødker B, Ersbak V, Holmskov A, Jørgensen FS, Larsen H, Larsen T, Laursen L, Mogensen H, Petersen OB, Rasmussen S, Skibsted L, Sperling L, Stornes I, Zingenberg H, Tabor A: Influence of chorionicity on perinatal outcome in a large cohort of Danish twin pregnancies. *Ultrasound Obstet Gynecol* 2012;39:69–74.
- 4 Morikawa M, Yamada T, Yamada T, Sato S, Cho K, Minakami H: Prospective risk of stillbirth: monochorionic diamniotic twins vs. dichorionic twins. *J Perinat Med* 2012;40: 245–249.
- 5 Nakayama S, Ishii K, Kawaguchi H, Hayashi S, Hidaka N, Murakoshi T, Mitsuda N: Perinatal outcome of monochorionic diamniotic twin pregnancies managed from early gestation at a single center. *J Obstet Gynaecol Res* 2012;38:692–697.
- 6 Lewi L, Van Schoubroeck D, Gratacós E, Witters I, Timmerman D, Deprest J: Monochorionic diamniotic twins: complications and management options. *Curr Opin Obstet Gynecol* 2003;15:177–194.
- 7 Acosta-Rojas R, Becker J, Munoz-Abellana B, Ruiz C, Carreras E, Gratacós E, Catalunya and Balears Monochorionic Network: Twin chorionicity and the risk of adverse perinatal outcome. *Int J Gynaecol Obstet* 2007;96:98–102.
- 8 Ortibus E, Lopriore E, Deprest J, Vandembussche FP, Walther FJ, Diemert A, Hecher K, Lagae L, De Cock P, Lewi PJ, Lewi L: The pregnancy and long-term neurodevelopmental outcome of monochorionic diamniotic twin gestations: a multicenter prospective cohort study from the first trimester onward. *Am J Obstet Gynecol* 2009;200:494.e1–e8.
- 9 Carroll SG, Soothill PW, Abdel-Fattah SA, Porter H, Montague I, Kyle PM: Prediction of chorionicity in twin pregnancies at 10–14 weeks of gestation. *BJOG* 2002;109:182–186.
- 10 Dias T, Arcangeli T, Bhide A, Napolitano R, Mahsud-Dornan S, Thilaganathan B: First-trimester ultrasound determination of chorionicity in twin pregnancy. *Ultrasound Obstet Gynecol* 2011;38:530–532.



- 11 Denbow ML, Cox P, Taylor M, Hammal DM, Fisk NM: Placental angioarchitecture in monochorionic twin pregnancies: relationship to fetal growth, fetofetal transfusion syndrome, and pregnancy outcome. *Am J Obstet Gynecol* 2000;182:417–426.
- 12 Lewi L, Cannie M, Blickstein I, Jani J, Huber A, Hecher K, Dymarkowski S, Gratacós E, Lewi P, Deprest J: Placental sharing, birthweight discordance, and vascular anastomoses in monochorionic diamniotic twin placentas. *Am J Obstet Gynecol* 2007;197:587.e1–e8.
- 13 Lewi L, Lewi P, Diemert A, Jani J, Gucciardo L, Van Mieghem T, Doné E, Gratacós E, Huber A, Hecher K, Deprest J: The role of ultrasound examination in the first trimester and at 16 weeks' gestation to predict fetal complications in monochorionic diamniotic twin pregnancies. *Am J Obstet Gynecol* 2008;199:493.e1–e7.
- 14 Maiz N, Nicolaides KH: Ductus venosus in the first trimester: contribution to screening of chromosomal, cardiac defects and monochorionic twin complications. *Fetal Diagn Ther* 2010;28:65–71.
- 15 Kagan KO, Gazzoni A, Sepulveda-Gonzalez G, Sotiriadis A, Nicolaides KH: Discordance in nuchal translucency thickness in the prediction of severe twin-to-twin transfusion syndrome. *Ultrasound Obstet Gynecol* 2007;29:527–532.
- 16 Maiz N, Staboulidou I, Leal AM, Minekawa R, Nicolaides KH: Ductus venosus Doppler at 11–13 weeks of gestation in the prediction of outcome in twin pregnancies. *Obstet Gynecol* 2009;113:860–865.
- 17 Southwest Thames Obstetric Research Collaborative (STORK): Prospective risk of late stillbirth in monochorionic twins: a regional cohort study. *Ultrasound Obstet Gynecol* 2012;39:500–504.
- 18 Hack KE, Derks JB, Elias SG, van Mameren FA, Koopman-Esseboom C, Mol BW, Lopriore E, Schaap AH, Arabin B, Duvekot JJ, Go AT, Wieselmann E, Eggink AJ, Willekes C, Vandenbussche FP, Visser GH: Perinatal mortality and mode of delivery in monochorionic diamniotic twin pregnancies  $\geq 32$  weeks of gestation: a multicentre retrospective cohort study. *BJOG* 2011;118:1090–1097.
- 19 Breathnach FM, McAuliffe FM, Geary M, Daly S, Higgins JR, Dornan J, Morrison JJ, Burke G, Higgins S, Dicker P, Manning F, Carroll S, Malone FD, Perinatal Ireland Research Consortium: Optimum timing for planned delivery of uncomplicated monochorionic and dichorionic twin pregnancies. *Obstet Gynecol* 2012;119:50–59.
- 20 Hack KE, Derks JB, Elias SG, Franx A, Roos EJ, Voerman SK, Bode CL, Koopman-Esseboom C, Visser GH: Increased perinatal mortality and morbidity in monochorionic versus dichorionic twin pregnancies: clinical implications of a large Dutch cohort study. *BJOG* 2008;115:58–67.
- 21 Robinson BK, Miller RS, D'Alton ME, Grobman WA: Effectiveness of timing strategies for delivery of monochorionic diamniotic twins. *Am J Obstet Gynecol* 2012;207:53.e1–e7.
- 22 Stirnemann JJ, Mougeot M, Proulx F, Nasr B, Essaoui M, Fouron JC, Ville Y: Profiling fetal cardiac function in twin-twin transfusion syndrome. *Ultrasound Obstet Gynecol* 2010;35:19–27.
- 23 Ville Y: Twin-to-twin transfusion syndrome: time to forget the Quintero staging system? *Ultrasound Obstet Gynecol* 2007;30:924–927.
- 24 Bermúdez C, Becerra CH, Bornick PW, Allen MH, Arroyo J, Quintero RA: Placental types and twin-twin transfusion syndrome. *Am J Obstet Gynecol* 2002;187:489–494.
- 25 Quintero RA, Martínez JM, López J, Bermúdez C, Becerra C, Morales W, Arroyo J: Individual placental territories after selective laser photocoagulation of communicating vessels in twin-twin transfusion syndrome. *Am J Obstet Gynecol* 2005;192:1112–1118.
- 26 Van Mieghem T, Lewi L, Gucciardo L, Dekoninck P, Van Schoubroeck D, Devlieger R, Deprest J: The fetal heart in twin-to-twin transfusion syndrome. *Int J Pediatr* 2010;2010: pii: 379792.
- 27 Habli M, Michelfelder E, Livingston J, Harmon J, Lim FY, Polzin W, Crombleholme T: Acute effects of selective fetoscopic laser photocoagulation on recipient cardiac function in twin-twin transfusion syndrome. *Am J Obstet Gynecol* 2008;199:412.e1–e6.
- 28 Mercanti I, Boivin A, Wo B, Vlieghe V, Le Ray C, Audibert F, Fouron JC, Leduc L, Nuyt AM: Blood pressures in newborns with twin-twin transfusion syndrome. *J Perinatol* 2011;31:417–424.
- 29 Van Mieghem T, Doné E, Gucciardo L, Klaritsch P, Allegaert K, Van Bree R, Lewi L, Deprest J: Amniotic fluid markers of fetal cardiac dysfunction in twin-to-twin transfusion syndrome. *Am J Obstet Gynecol* 2010;202:48.e1–e7.
- 30 Van Mieghem T, Klaritsch P, Doné E, Gucciardo L, Lewi P, Verhaeghe J, Lewi L, Deprest J: Assessment of fetal cardiac function before and after therapy for twin-to-twin transfusion syndrome. *Am J Obstet Gynecol* 2009;200:400.e1–e7.
- 31 WAPM Consensus Group on Twin-to-Twin Transfusion, Baschat A, Chmait RH, Deprest J, Gratacós E, Hecher K, Kontopoulos E, Quintero R, Skupski DW, Valsky DV, Ville Y: Twin-to-twin transfusion syndrome (TTTS). *J Perinat Med* 2011;39:107–112.
- 32 Quintero RA, Morales WJ, Allen MH, Bornick PW, Johnson PK, Kruger M: Staging of twin-twin transfusion syndrome. *J Perinatol* 1999;19:550–555.
- 33 O'Donoghue K, Cartwright E, Galea P, Fisk NM: Stage I twin-twin transfusion syndrome: rates of progression and regression in relation to outcome. *Ultrasound Obstet Gynecol* 2007;30:958–964.
- 34 Senat MV, Deprest J, Boulvain M, Paupe A, Winer N, Ville Y: Endoscopic laser surgery versus serial amnioreduction for severe twin-to-twin transfusion syndrome. *N Engl J Med* 2004;351:136–144.
- 35 Lewi L, Jani J, Blickstein I, Huber A, Gucciardo L, Van Mieghem T, Doné E, Boes AS, Hecher K, Gratacós E, Lewi P, Deprest J: The outcome of monochorionic diamniotic twin gestations in the era of invasive fetal therapy: a prospective cohort study. *Am J Obstet Gynecol* 2008;199:514.e1–e8.
- 36 Rossi AC, D'Addario V: Laser therapy and serial amnioreduction as treatment for twin-twin transfusion syndrome: a metaanalysis and review of literature. *Am J Obstet Gynecol* 2008;198:147–152.
- 37 Roberts D, Gates S, Kilby M, Neilson JP: Interventions for twin-twin transfusion syndrome: a Cochrane review. *Ultrasound Obstet Gynecol* 2008;31:701–711.
- 38 Hecher K, Plath H, Bregenzer T, Hansmann M, Hackelöer BJ: Endoscopic laser surgery versus serial amniocenteses in the treatment of severe twin-twin transfusion syndrome. *Am J Obstet Gynecol* 1999;180:717–724.
- 39 Maschke C, Diemert A, Hecher K, Bartmann P: Long-term outcome after intrauterine laser treatment for twin-twin transfusion syndrome. *Prenat Diagn* 2011;31:647–653.
- 40 Rossi AC, Vanderbilt D, Chmait RH: Neurodevelopmental outcomes after laser therapy for twin-twin transfusion syndrome: a systematic review and meta-analysis. *Obstet Gynecol* 2011;118:1145–1150.
- 41 Lopriore E, Deprest J, Slaghekke F, Oepkes D, Middeldorp JM, Vandenbussche FP, Lewi L: Placental characteristics in monochorionic twins with and without twin anemia-polycythemia sequence. *Obstet Gynecol* 2008;112:753–758.
- 42 Slaghekke F, Kist WJ, Oepkes D, Paskan SA, Middeldorp JM, Klumper FJ, Walther FJ, Vandenbussche FP, Lopriore E: Twin anemia-polycythemia sequence: diagnostic criteria, classification, perinatal management and outcome. *Fetal Diagn Ther* 2010;2:181–190.
- 43 Robyr R, Lewi L, Salomon LJ, Yamamoto M, Bernard JP, Deprest J, Ville Y: Prevalence and management of late fetal complications following successful selective laser coagulation of chorionic plate anastomoses in twin-to-twin transfusion syndrome. *Am J Obstet Gynecol* 2006;194:796–803.
- 44 Weingertner AS, Kohler A, Kohler M, Bouffet N, Hunsinger MC, Mager C, Hornecker F, Neumann M, Schmerber E, Tanghe M, Viville B, Favre R: Clinical and placental characteristics in four new cases of twin anemia-polycythemia sequence. *Ultrasound Obstet Gynecol* 2010;35:490–494.

- 45 Gucciardo L, Lewi L, Vaast P, Debska M, De Catte L, Van Mieghem T, Done E, Devlieger R, Deprest J: Twin anemia polycythemia sequence from a prenatal perspective. *Prenat Diagn* 2010;30:438–442.
- 46 Klaritsch P, Deprest J, Van Mieghem T, Gucciardo L, Doné E, Jani J, Lewi P, Rasmussen S, Lewi L: Reference ranges for middle cerebral artery peak systolic velocity in monochorionic diamniotic twins: a longitudinal study. *Ultrasound Obstet Gynecol* 2009;34:149–154.
- 47 Lopriore E, Slaghekke F, Oepkes D, Middeldorp JM, Vandenbussche FP, Walther FJ: Hematological characteristics in neonates with twin anemia-polycythemia sequence (TAPS). *Prenat Diagn* 2010;30:251–255.
- 48 Slaghekke F, Kist WJ, Oepkes D, Pasma SA, Middeldorp JM, Klumper FJ, Walther FJ, Vandenbussche FP, Lopriore E: Twin anemia-polycythemia sequence: diagnostic criteria, classification, perinatal management and outcome. *Fetal Diagn Ther* 2010;27:181–190.
- 49 Lopriore E, Slaghekke F, Oepkes D, Middeldorp JM, Vandenbussche FP, Walther FJ: Clinical outcome in neonates with twin anemia-polycythemia sequence. *Am J Obstet Gynecol* 2010;203:54.e1–e5.
- 50 Groussolles M, Sartor A, Connan L, Vaysière C: Evolution of middle cerebral artery peak systolic velocity after a successful laser procedure for iatrogenic twin anemia-polycythemia sequence. *Ultrasound Obstet Gynecol* 2012;39:354–356.
- 51 Herway C, Johnson A, Moise K, Moise KJ Jr: Fetal intraperitoneal transfusion for iatrogenic twin anemia-polycythemia sequence after laser therapy. *Ultrasound Obstet Gynecol* 2009;33:592–594.
- 52 Evans MI, Lau TK: Making decisions when no good choices exist: delivery of the survivor after intrauterine death of the co-twin in monochorionic twin pregnancies. *Fetal Diagn Ther* 2010;28:191–195.
- 53 Bajoria R, Wee LY, Anwar S, Ward S: Outcome of twin pregnancies complicated by single intrauterine death in relation to vascular anatomy of the monochorionic placenta. *Hum Reprod* 1999;14:2124–2130.
- 54 Hillman SC, Morris RK, Kilby MD: Co-twin prognosis after single fetal death: a systematic review and meta-analysis. *Obstet Gynecol* 2011;118:928–940.
- 55 Hillman SC, Morris RK, Kilby MD: Single twin demise: consequence for survivors. *Semin Fetal Neonatal Med* 2010;15:319–326.
- 56 Pharoah PO: Twins and cerebral palsy. *Acta Paediatr Suppl* 2001;90:6–10.
- 57 Pharoah PO: Neurological outcome in twins. *Semin Neonatol* 2002;7:223–230.
- 58 Hack KE, Kaandorp JJ, Derks JB, Elias SG, Pistorius L, Visser GH: The value of umbilical artery Doppler velocimetry in the antenatal surveillance of uncomplicated monochorionic twin pregnancies. *Ultrasound Obstet Gynecol* 2008;31:662–668.
- 59 Gratacós E, Lewi L, Carreras E, Becker J, Higuera T, Deprest J, Cabero L: Incidence and characteristics of umbilical artery intermittent absent and/or reversed end-diastolic flow in complicated and uncomplicated monochorionic twin pregnancies. *Ultrasound Obstet Gynecol* 2004;23:456–460.
- 60 Skupski DW, Sylvestre G, Di Renzo GC, Grunebaum A: Acute twin-twin transfusion syndrome in labor: pathophysiology and associated factors. *J Matern Fetal Neonatal Med* 2012;25:456–460.
- 61 Sherer DM, Sinkin RA, Metlay LA, Woods JR Jr: Acute intrapartum twin-twin transfusion. A case report. *J Reprod Med* 1992;37:184–186.
- 62 Uotila J, Tammela O: Acute intrapartum fetoplacental transfusion in monochorionic twin pregnancy. *Obstet Gynecol* 1999;94:819–821.
- 63 Muñoz-Abellana B, Hernandez-Andrade E, Figueroa-Diesel H, Ferrer Q, Acosta-Rojas R, Cabero L, Gratacós E: Hypertrophic cardiomyopathy-like changes in monochorionic twin pregnancies with selective intrauterine growth restriction and intermittent absent/reversed end-diastolic flow in the umbilical artery. *Ultrasound Obstet Gynecol* 2007;30:977–982.
- 64 Valsky DV, Eixarch E, Martínez JM, Gratacós E: Selective intrauterine growth restriction in monochorionic diamniotic twin pregnancies. *Prenat Diagn* 2010;30:719–726.
- 65 Chang YL, Chang SD, Chao AS, Hsieh PC, Wang CN, Wang TH: Clinical outcome and placental territory ratio of monochorionic twin pregnancies and selective intrauterine growth restriction with different types of umbilical artery Doppler. *Prenat Diagn* 2009;29:253–256.
- 66 Valsky DV, Eixarch E, Martínez JM, Crispi F, Gratacós E: Selective intrauterine growth restriction in monochorionic twins: pathophysiology, diagnostic approach and management dilemmas. *Semin Fetal Neonatal Med* 2010;15:342–348.
- 67 Gratacós E, Lewi L, Muñoz B, Acosta-Rojas R, Hernandez-Andrade E, Martínez JM, Carreras E, Deprest J: A classification system for selective intrauterine growth restriction in monochorionic pregnancies according to umbilical artery Doppler flow in the smaller twin. *Ultrasound Obstet Gynecol* 2007;30:28–34.
- 68 Ishii K, Murakoshi T, Takahashi Y, Shinno T, Matsushita M, Naruse H, Torii Y, Sumie M, Nakata M: Perinatal outcome of monochorionic twins with selective intrauterine growth restriction and different types of umbilical artery Doppler under expectant management. *Fetal Diagn Ther* 2009;26:157–161.
- 69 Gratacós E, Carreras E, Becker J, Lewi L, Enríquez G, Perapoch J, Higuera T, Cabero L, Deprest J: Prevalence of neurological damage in monochorionic twins with selective intrauterine growth restriction and intermittent absent or reversed end-diastolic umbilical artery flow. *Ultrasound Obstet Gynecol* 2004;24:159–163.
- 70 Hecher K, Jauniaux E, Campbell S, Deane C, Nicolaides K: Artery-to-artery anastomosis in monochorionic twins. *Am J Obstet Gynecol* 1994;171:570–572.
- 71 Wee LY, Taylor MJ, Vanderheyden T, Talbert D, Fisk NM: Transmitted arterio-arterial anastomosis waveforms causing cyclically intermittent absent/reversed end-diastolic umbilical artery flow in monochorionic twins. *Placenta* 2003;24:772–778.
- 72 Gratacós E, Antolin E, Lewi L, Martínez JM, Hernandez-Andrade E, Acosta-Rojas R, Enríquez G, Cabero L, Deprest J: Monochorionic twins with selective intrauterine growth restriction and intermittent absent or reversed end-diastolic flow (type III): feasibility and perinatal outcome of fetoscopic placental laser coagulation. *Ultrasound Obstet Gynecol* 2008;31:669–675.
- 73 Ishii K, Murakoshi T, Hayashi S, Saito M, Sago H, Takahashi Y, Sumie M, Nakata M, Matsushita M, Shinno T, Naruse H, Torii Y: Ultrasound predictors of mortality in monochorionic twins with selective intrauterine growth restriction. *Ultrasound Obstet Gynecol* 2011;37:22–26.
- 74 Lewi L, Gucciardo L, Huber A, Jani J, Van Mieghem T, Doné E, Cannie M, Gratacós E, Diemert A, Hecher K, Lewi P, Deprest J: Clinical outcome and placental characteristics of monochorionic diamniotic twin pairs with early- and late-onset discordant growth. *Am J Obstet Gynecol* 2008;199:511.e1–e7.
- 75 Van Mieghem T, Eixarch E, Gucciardo L, Done E, Gonzales I, Van Schoubroeck D, Lewi L, Gratacós E, Deprest J: Outcome prediction in monochorionic diamniotic twin pregnancies with moderately discordant amniotic fluid. *Ultrasound Obstet Gynecol* 2011;37:15–21.
- 76 Rustico MA, Baietti MG, Coviello D, Orlandi E, Nicolini U: Managing twins discordant for fetal anomaly. *Prenat Diagn* 2005;25:766–771.
- 77 Gul A, Cebeci A, Aslan H, Polat I, Sozen I, Ceylan Y: Perinatal outcomes of twin pregnancies discordant for major fetal anomalies. *Fetal Diagn Ther* 2005;20:244–248.
- 78 Weber MA, Sebire NJ: Genetics and developmental pathology of twinning. *Semin Fetal Neonatal Med* 2010;15:313–318.
- 79 Nieuwint A, Van Zalen-Sprock R, Hummel P, Pals G, Van Vugt J, Van Der Harten H, Heins Y, Madan K: 'Identical' twins with discordant karyotypes. *Prenat Diagn* 1999;19:72–76.

- 80 Lewi L, Blickstein I, Van Schoubroeck D, Gloning KP, Casteels M, Brandenburg H, Fryns JP, Deprest J: Diagnosis and management of heterokaryotypic monochorionic twins. *Am J Med Genet A* 2006;140:272–275.
- 81 Hartge DR, Weichert J: Prenatal diagnosis and outcome of multiple pregnancies with reversed arterial perfusion (TRAP-sequence). *Arch Gynecol Obstet* 2012;286:81–88.
- 82 Sogaard K, Skibsted L, Brocks V: Acardiac twins: pathophysiology, diagnosis, outcome and treatment. Six cases and review of the literature. *Fetal Diagn Ther* 1999;14:53–59.
- 83 Lewi L, Valencia C, Gonzalez E, Deprest J, Nicolaides KH: The outcome of twin reversed arterial perfusion sequence diagnosed in the first trimester. *Am J Obstet Gynecol* 2010;203:213.e1–e4.
- 84 Valsky DV, Martinez-Serrano MJ, Sanz M, Eixarch E, Acosta ER, Martinez JM, Puerto B, Gratacós E: Cord occlusion followed by laser cord transection in monochorionic monoamniotic discordant twins. *Ultrasound Obstet Gynecol* 2011;37:684–648.
- 85 Roman A, Papanna R, Johnson A, Hassan SS, Moldenhauer J, Molina S, Moise KJ Jr: Selective reduction in complicated monochorionic pregnancies: radiofrequency ablation vs. bipolar cord coagulation. *Ultrasound Obstet Gynecol* 2010;36:37–41.
- 86 Paramasivam G, Wimalasundera R, Wiechec M, Zhang E, Saeed F, Kumar S: Radiofrequency ablation for selective reduction in complex monochorionic pregnancies. *BJOG* 2010;117:1294–1298.
- 87 Bebbington MW, Danzer E, Moldenhauer J, Khalek N, Johnson MP: Radiofrequency ablation vs. bipolar umbilical cord coagulation in the management of complicated monochorionic pregnancies. *Ultrasound Obstet Gynecol* 2012;40:319–324.
- 88 Lewi L, Gratacos E, Ortibus E, Van Schoubroeck D, Carreras E, Higuera T, Perapoch J, Deprest J: Pregnancy and infant outcome of 80 consecutive cord coagulations in complicated monochorionic multiple pregnancies. *Am J Obstet Gynecol* 2006;194:782–789.
- 89 Evans MI, Goldberg JD, Horenstein J, Wapner RJ, Ayoub MA, Stone J, Lipitz S, Achiron R, Holzgreve W, Brambati B, Johnson A, Johnson MP, Shalhoub A, Berkowitz RL: Selective termination for structural, chromosomal, and Mendelian anomalies: international experience. *Am J Obstet Gynecol* 1999;181:893–897.