

A Systematic Review and Meta-Analysis of Endocrine-Related Adverse Events Associated with Immune Checkpoint Inhibitors

Authors

Jeroen de Filette¹, Corina Emilia Andreescu¹, Filip Cools², Bert Bravenboer¹, Brigitte Velkeniers¹

Affiliations

- 1 Department of Endocrinology, Universitair Ziekenhuis Brussel, Vrije Universiteit Brussel, Brussels, Belgium
- 2 Department of Neonatology, Universitair Ziekenhuis Brussel, Vrije Universiteit Brussel, Brussels, Belgium

Key words

hypophysitis, thyroiditis, CTLA-4, PD-1, PD-L1

received 11.06.2018

accepted 22.01.2019

Bibliography

DOI <https://doi.org/10.1055/a-0843-3366>

Horm Metab Res 2019; 51: 145–156

© Georg Thieme Verlag KG Stuttgart · New York

ISSN 0018-5043

Correspondence

Jeroen de Filette

Department of Endocrinology

Universitair Ziekenhuis Brussel

Vrije Universiteit Brussel

Laarbeeklaan 101

1090 Brussels

Belgium

Tel.: +32 2 477 60 01, Fax: +32 2 477 68 00

jdefilette@vub.ac.be



Supplementary Material for this article is available online at <http://www.thieme-connect.de/products>.

ABSTRACT

Monoclonal antibodies targeting cytotoxic T-lymphocyte antigen-4 (CTLA-4), programmed cell death 1 (PD-1), or its ligand (PD-L1) have become the mainstay for advanced malignancies. The incidence of endocrine adverse events provoked by these immune checkpoint inhibitors (ICI) is based on data from randomized controlled trials, which have their drawbacks. PubMed was searched through August 22nd, 2017, by 2 reviewers independently (J.d.F. and C.E.A.). Early phase I/II, phase III experimental trials, prospective and retrospective observational studies were included. The weighted incidence and risk ratio were estimated for hypophysitis, primary thyroid disease, primary adrenal insufficiency, and diabetes mellitus. Their management is discussed in a systematic review. A total of 101 studies involving 19 922 patients were included. Ipilimumab-treated patients experienced hypophysitis in 5.6% (95% CI, 3.9–8.1), which was higher than nivolumab (0.5%; 95% CI, 0.2–1.2) and pembrolizumab (1.1%; 95% CI, 0.5–2.6). PD-1/PD-L1 inhibitors had a higher incidence of thyroid dysfunction – particularly hypothyroidism (nivolumab, 8.0%; 95% CI, 6.4–9.8; pembrolizumab, 8.5%; 95% CI, 7.5–9.7; PD-L1, 5.5%; 95% CI, 4.4–6.8; ipilimumab, 3.8%; 95% CI, 2.6–5.5). Combination therapy was associated with a high incidence of hypothyroidism (10.2–16.4%), hyperthyroidism (9.4–10.4%), hypophysitis (8.8–10.5%), and primary adrenal insufficiency (5.2–7.6%). Diabetes mellitus and primary adrenal insufficiency were less frequent findings on monotherapy. Our meta-analysis shows a high incidence of endocrine adverse events provoked by single agent checkpoint blockade, further reinforced by combined treatment.

Introduction

Immune checkpoint inhibitors (ICI) are revolutionizing the management of advanced malignancies. The importance of this new generation of cancer therapy through immune modulation will only expand in the near future, given their recent extended approval [1]. These novel antibodies release the brakes of the immune system and potentiate antitumor immune responses through the inhibition of receptors on immune and cancer cells such as cytotoxic T-lymphocyte antigen 4 (CTLA-4) or programmed cell death 1 (PD-1) and its ligand (PD-L1), whose function is to maintain self-tolerance [2].

Their side effects are equally fascinating as immune-related adverse events (irAE) have been described in almost all organs including the endocrine system. The anti-CTLA-4 agent ipilimumab is associated with the otherwise rare phenomenon of hypophysitis, while PD-1 inhibitors nivolumab and pembrolizumab often provoke primary thyroid dysfunction [3]. Notwithstanding, cases of primary adrenal insufficiency, fulminant diabetes mellitus, and hypoparathyroidism associated with checkpoint blockade have also been reported. The aim of the present study is to perform a systematic review and meta-analysis of immune checkpoint inhibitors

and endocrine side effects, including their incidence, evaluation, and management.

Materials and Methods

Literature search

The PubMed database was searched through August 22nd, 2017, for relevant articles on the subject of endocrinopathies and ICI, by 2 reviewers independently (J.d.F. and C.E.A.). Search terms were included for the various endocrinopathies, adverse events and the currently available ICI: 'ipilimumab', 'tremelimumab', 'nivolumab', 'pembrolizumab', 'atezolizumab', 'avelumab' and 'durvalumab'. These were combined with the Boolean logical operators AND/OR. The authors also checked recently published literature [3–7] and identified 2 additional studies. (► **Table 1, 2**)

Study selection

Early phase I/II, phase III experimental trials, and prospective as well as retrospective observational studies were included. Study subjects had to be adults with any type of advanced, metastatic, or unresectable malignancy. Studies with regimens combining ICI with radiotherapy, cell vaccines, small molecule inhibitors or immunotherapy with IL-2 or interferon were omitted. Language was restricted to English or French. The investigators used the title and abstract for manuscript selection. Articles were categorized as follows: Clinical Study, Case Report, Review (of endocrine adverse events), Systematic Review or Meta-Analysis, Mechanism (of checkpoint blockade toxicity), Basic or Translational Research, Combination Therapy, Economic or Health-Care, Language, Pediatric, Off Topic. After initial selection, full texts were reviewed and further excluded if no endocrine adverse events were reported or if the safety data were inadequate. Duplicates or studies on the same population were identified through their trial registry number and excluded as well. Any discrepancies were discussed by all authors and resolved by consensus. Supplemental (► **Table 1S**) provides an overview of all included studies [8–108].

Data analysis and extraction

The following elements were extracted from each included study: author and year of publication, study design, median follow-up time, treatment and placebo/chemotherapy arms, dosing and frequency of drug administration, endocrine adverse events (hypothyroidism, hyperthyroidism, thyroiditis, hypophysitis, primary adrenal insufficiency, and diabetes mellitus), trial registration number, and trial name. When available, supplementary data and appendices were also methodically explored.

Statistical analysis

For each study, the incidence of a specific endocrine adverse event was calculated by dividing the number of observed events by the total number of patients that were followed-up during the study period. A meta-analysis of incidence estimates was performed using an inverse variance method to weigh the studies. Summary estimates of incidence are reported with their 95 % confidence interval (CI). For randomized controlled trials, a relative risk and 95 % CI were calculated using the number of observed adverse events

and the total number of patients in each group. If possible, relative risks from individual trials for the same adverse event were combined in a meta-analysis. Heterogeneity was assessed using the Q and I² statistics. The random-effects model was a priori selected based on the expected study heterogeneity. All analyses were performed with Comprehensive Meta-Analysis v3.0 (Biostat, Inc.).

Results

Study characteristics

Our search identified a total of 1169 articles, of which 959 were excluded based on title and abstract. Of the 210 full texts that were reviewed, 101 were finally included (► **Fig. 1**). These included 7 phase II, 1 phase II/III, 17 phase III randomized trials, 64 prospective, and 12 retrospective studies. Within the 101 included articles, a total of 152 study arms were identified. The main tumor types were melanoma (69/152, 45 %), non-small cell lung carcinoma (31/152, 20 %), and renal cell carcinoma (11/152, 7 %). A total of 19 922 patients were analyzed (ipilimumab, n = 4430; tremelimumab, n = 1171; nivolumab, n = 3317; pembrolizumab, n = 4485; atezolizumab, n = 998; avelumab, n = 316; durvalumab, n = 191; combination, n = 1078; placebo/chemotherapy, n = 3936). The regimens were classified as monotherapy with anti-CTLA-4 (41/152, 27 %), anti-PD-1 (68/152, 45 %), anti-PD-L1 (8/152, 5 %), combination of anti-CTLA-4 with anti-PD-1 (13/152, 9 %) or anti-PD-L1 (3/152, 2 %), and placebo/chemotherapy (19/152, 13 %).

Incidence of hypophysitis

The CTLA-4 inhibitor ipilimumab had a 5.6 % (95 % CI, 3.9–8.1) pooled estimated incidence of hypophysitis vs. 1.8 % (95 % CI, 1.1–2.9) for tremelimumab. Nivolumab and pembrolizumab had a lower incidence at 0.5 % (95 % CI, 0.2–1.2) and 1.1 % (95 % CI, 0.5–2.6), respectively. The highest estimated incidence was noted on combination therapy, ranging from 8.8 % (95 % CI, 6.2–12.4) to 10.5 % (95 % CI, 6.5–16.4). No data on hypophysitis were available for anti-PD-L1 agents. Compared to patients not receiving immunotherapy, ipilimumab-treated patients had a higher risk of developing hypophysitis (RR, 9.26; 95 % CI, 0.51–169.66; p = 0.134). This was lower for nivolumab (RR, 2.06; 95 % CI, 0.22–19.68; p = 0.531) and for pembrolizumab (RR, 2.89; 95 % CI, 0.46–18.27; p = 0.259). These results were, however, not statistically different.

Incidence of primary thyroid disease

Checkpoint blockade with PD-1 or PD-L1 inhibitors was particularly associated with primary thyroid dysfunction. Hypothyroidism was most frequent, followed by hyperthyroidism and thyroiditis. The summary estimated incidence of hypothyroidism was 8.0 % (95 % CI, 6.4–9.8) for nivolumab, 8.5 % (95 % CI, 7.5–9.7) for pembrolizumab, 6.0 % (95 % CI, 4.2–8.4) for atezolizumab, 5.5 % (95 % CI, 3.5–8.7) for avelumab, and 4.7 % (95 % CI, 2.5–8.8) for durvalumab. Ipilimumab had a lower estimated incidence of 3.8 % (95 % CI, 2.6–5.5) while clear data on tremelimumab were missing. Regardless, one study reported up to 5.2 % of thyroid disorders on tremelimumab [41]. Combination therapy had the highest estimated incidence of hypothyroidism with 10.2 % (95 % CI, 5.6–17.9) for durvalumab with tremelimumab, 15.1 % (95 % CI, 10.6–21.8) for

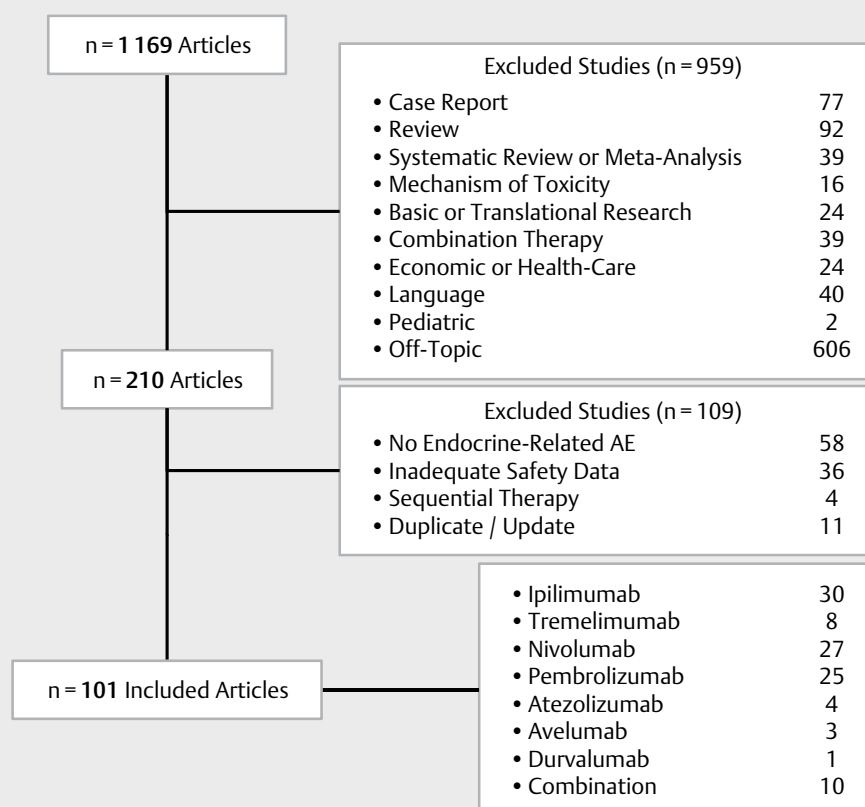
► **Table 1** Summary estimated incidence of endocrine adverse events on immune checkpoint inhibitors.

Target	Treatment	Total patients n	Hypothyroidism		Hyperthyroidism		Thyroiditis		Hypophysitis		PAI		DM	
			Analyzed patients n (%)	Summary incidence % (95% CI)	Analyzed patients n (%)	Summary incidence % (95% CI)	Analyzed patients n (%)	Summary incidence % (95% CI)	Analyzed patients n (%)	Summary incidence % (95% CI)	Analyzed patients n (%)	Summary incidence % (95% CI)	Analyzed patients n (%)	Summary incidence % (95% CI)
CTLA-4	Ipilimumab	4430	3614 (82%)	3.8 (2.6–5.5)	2147 (48%)	1.4 (0.8–2.4)*	1708 (39%)	2.1 (1.1–4.1)	3534 (80%)	5.6 (3.9–8.1)	1690 (38%)	1.4 (0.9–2.2)	NR	NR
	Tremelimumab	1171	N/A	up to 5.2%†	N/A	up to 5.2%†	N/A	up to 5.2%†	1037 (89%)	1.8 (1.1–2.9)	705 (60%)	1.3 (0.7–2.4)	NR	NR
PD-1	Nivolumab	3317	3317 (100%)	8.0 (6.4–9.8)	1710 (52%)	2.8 (2.1–3.8)	650 (20%)	1.6 (0.2–10.2)	1103 (33%)	0.5 (0.2–1.2)	979 (30%)	2.0 (0.9–4.3)*	619 (19%)	2.0 (0.7–5.8)*
	Pembrolizumab	4485	4461 (99%)	8.5 (7.5–9.7)*	3757 (84%)	3.7 (2.8–4.7)*	1916 (43%)	2.3 (1.2–4.6)	1381 (31%)	1.1 (0.5–2.6)	1691 (38%)	0.8 (0.3–2.0)*	941 (21%)	0.4 (0.2–1.3)
PD-L1	Atezolizumab	998	998 (100%)	6.0 (4.2–8.4)*	NR	NR	NR	NR	NR	NR	NR	NR	70 (7%)	1.4 (0.2–9.4)
	Avelumab	316	316 (100%)	5.5 (3.5–8.7)	88 (28%)	2.3 (0.6–8.6)	NR	NR	NR	NR	184 (58%)	1.1 (0.3–4.2)	88 (28%)	1.1 (0.2–7.6)
Combined	Durvalumab	191	191 (100%)	4.7 (2.5–8.8)	NR	NR	NR	NR	NR	NR	NR	NR	NR	NR
	Ipilimumab + Nivolumab	816	739 (91%)	16.4 (11.7–22.5)	520 (64%)	9.4 (7.1–12.3)	147 (18%)	3.8 (1.4–9.4)*	524 (64%)	8.8 (6.2–12.4)*	339 (42%)	5.2 (2.9–9.2)*	NR	NR
	Ipilimumab + Pembrolizumab	163	163 (100%)	15.1 (10.6–21.8)	163 (100%)	10.4 (6.6–16.1)	153 (94%)	4.6 (2.2–9.3)	153 (94%)	10.5 (6.5–16.4)	163 (100%)	7.6 (1.2–36.8)	153 (94%)	2.0 (0.6–5.9)
	Durvalumab + Tremelimumab	99	99 (100%)	10.2 (5.6–17.9)	NR	NR	NR	NR	NR	NR	NR	NR	NR	NR

The number of analyzed patients (%) is also reported. Clear data on tremelimumab were missing; * p for heterogeneity <0.10; † Ribas et al. [41] reported up to 5.2% thyroid disorders; DM: Diabetes mellitus; N/A: Not applicable; NR: Not reported; PAI: Primary adrenal insufficiency.

► **Table 2** Summary of relative risk for endocrine adverse events.

	Hypothyroidism		Hyperthyroidism		Thyroiditis		Hypophysitis	
Treatment	% (95 % CI)	p-value	% (95 % CI)	p-Value	% (95 % CI)	p-Value	% (95 % CI)	p-Value
Ipilimumab vs. placebo/chemo	6.51 (3.37–12.58)	<0.001	6.83 (0.81–57.83)	0.078	5.08 (0.25–105.29)	0.293	9.26 (0.51–169.66)	0.134
Nivolumab vs. placebo/chemo	11.19 (4.31–29.08)	<0.001	4.20 (1.12–15.84)	0.034	2.56 (0.28–23.08)	0.402	2.06 (0.22–19.68)	0.531
Pembrolizumab vs. placebo/chemo	7.41 (4.06–13.52)	<0.001	8.52 (3.66–19.84)	<0.001	6.56 (0.80–53.61)	0.079	2.89 (0.46–18.27)	0.259

► **Fig. 1** Flow chart of study selection.

ipilimumab with pembrolizumab and 16.4 % (95 % CI, 11.7–22.5) for ipilimumab with nivolumab. Compared to placebo/chemotherapy, the risk of hypothyroidism was significantly increased by all immunotherapies. The PD-1 inhibitor nivolumab (RR, 11.19; 95 % CI, 4.31–29.08; $p < 0.001$) had a higher risk than pembrolizumab (RR, 7.41; 95 % CI, 4.06–13.52; $p < 0.001$) or ipilimumab (RR, 6.51; 95 % CI, 3.37–12.58; $p < 0.001$).

Predictions for hyperthyroidism were lower with a pooled incidence of 2.8 % (95 % CI, 2.1–3.8) for nivolumab, 3.7 % (95 % CI, 2.8–4.7) for pembrolizumab, 2.3 % (95 % CI, 0.6–8.6) for avelumab, and 1.4 % (95 % CI, 0.8–2.4) for ipilimumab. No data were available for

atezolizumab and durvalumab. For combination therapy, the estimated incidence was 9.4 % (95 % CI, 7.1–12.3) for ipilimumab with nivolumab and 10.4 % (95 % CI, 6.6–16.1) for ipilimumab with pembrolizumab. As compared to placebo/chemotherapy, the risk of developing hyperthyroidism increased with nivolumab (RR, 4.20; 95 % CI, 1.12–15.84; $p = 0.034$), pembrolizumab (RR, 8.52; 95 % CI, 3.66–19.84, $p < 0.001$), and ipilimumab (RR, 6.83; 95 % CI, 0.81–57.83; $p = 0.078$), although the latter was not significant.

Few data on thyroiditis were available. Estimations ranged from 1.6 % (95 % CI, 0.2–0.2) for nivolumab, 2.3 % (95 % CI, 1.2–4.6) for pembrolizumab, 2.1 % (95 % CI, 1.1–4.1) for ipilimumab, 3.8 % (95 %

CI, 1.4–9.4) for ipilimumab with nivolumab to 4.6 % (95 % CI, 2.2–9.3) for ipilimumab with pembrolizumab. Nivolumab (RR, 2.56; 95 % CI, 0.28–23.08; $p = 0.402$), pembrolizumab (RR, 6.56; 95 % CI, 0.80–53.61; $p = 0.079$), and ipilimumab (RR, 5.08; 95 % CI, 0.25–105.29; $p = 0.293$) presented a higher risk, although not significantly.

Incidence of diabetes mellitus and primary adrenal insufficiency

Primary adrenal insufficiency had a predicted incidence of 1.4 % (95 % CI, 0.9–2.2) on ipilimumab, 1.3 % (95 % CI, 0.7–2.4) on tremelimumab, 2.0 % (95 % CI, 0.9–4.3) on nivolumab, and 0.8 % (95 % CI, 0.3–2.0) on pembrolizumab monotherapy. For combination therapy, estimations ranged from 5.2 % (95 % CI, 2.9–9.2) to 7.6 % (95 % CI, 1.2–36.8) for ipilimumab with nivolumab, or pembrolizumab, respectively.

Diabetes mellitus was mainly PD-1/PD-L1 related without cases observed on CTLA-4 therapy. The incidence was 2.0 % (95 % CI, 0.7–5.8) for nivolumab and 0.4 % (95 % CI, 0.2–1.3) for pembrolizumab. No further analyses were performed due to the rarity of these side effects.

Discussion

Our meta-analysis shows a high incidence of all-grade endocrine adverse events related to immune checkpoint therapy, which is further enhanced by combined treatment. The highest incidence of hypophysitis on monotherapy is noted on anti-CTLA-4 therapy with ipilimumab (but not with tremelimumab) although hypophysitis also develops during PD-1 blockade. The incidence of hypothyroidism on monotherapy is highest for PD-1 inhibitors, followed by PD-L1 and CTLA-4 blockade. Hyperthyroidism and thyroiditis occur less frequently. Primary adrenal insufficiency and diabetes mellitus are less frequent, with no cases of diabetes mellitus reported on anti-CTLA-4 therapy. Combined ICI shows a remarkably higher incidence of hypothyroidism, hyperthyroidism, hypophysitis, and primary adrenal insufficiency.

Hypophysitis

Our analysis indicates an higher incidence of all-grade hypophysitis in patients treated with ipilimumab. Anti-CTLA-4-induced hypophysitis usually occurs after 4 to 10 weeks of treatment (usually after the third infusion). In one report, hypophysitis was more frequent among patients receiving a higher dose of ipilimumab (10 mg/kg) with a 2-fold risk increase compared to patients treated with lower dose (3 mg/kg) [8]. Hypophysitis was more frequent among older and male patients [18, 25]. Anti-PD-1 or PD-L1 treatment rarely induced hypophysitis or hypopituitarism. These findings extend the data of previous reviews [6, 8, 109–111]. Hypophysitis may be life threatening due to the abrupt onset of central adrenal failure. The initial presentation is indolent and includes symptoms such as headache and fatigue. Hormonal and radiological evaluation of the pituitary should be performed. The pituitary is often diffusely enlarged in the acute phase, with or without stalk thickening. Homogeneous or heterogeneous pituitary gland enhancement is possible. This is followed by a gradual decrease in size of the pituitary with partial or complete loss of pituitary function [25, 27, 112]. Hence, normal imaging of the pituitary does not ex-

clude its diagnosis [27]. Corticotrophic, thyrotrophic and gonadotrophic functions are mostly affected, but long term failure of the corticotrophic axis is paramount [10, 25, 112]. High-dose glucocorticoids are proposed for those with mass effect symptoms, such as severe headache or visual-field disturbance [27, 113, 114]. Their role in the prevention of secondary adrenal failure has, however, been challenged and it is possible that physiological corticosteroid substitution suffices [18, 25, 112]. The potential benefit of high-dose glucocorticoid treatment should be balanced against the loss of efficacy resulting from the anti-cancer immunotherapy, although this issue is controversial. Why ACTH, TSH, and gonadotrophic cells are particularly vulnerable to destruction with anti-CTLA-4 mAb is not fully elucidated. The expression of CTLA-4 on ACTH- and TSH-secreting cells has been implicated through immunohistochemistry [115, 116]. Radiological mimicry with lymphocytic hypophysitis favors the hypothesis of a lymphocytic destruction of the pituitary [27] as a result of T cell-mediated cytotoxicity, but an anti-pituitary antibody mediated process cannot be excluded. Iwama et al. found that all 7 patients with hypophysitis developed antibodies recognizing predominantly TSH- (7/7), FSH- (5/7), and ACTH-secreting (3/7) cells [115]. The diagnostic accuracy of these pituitary antibodies is not yet known. An autopsy study suggests that administration of CTLA-4 blocking antibodies to patients who express high levels of pituitary CTLA-4 antigen causes a necrotizing form of hypophysitis through type II (IgG dependent) and type IV (T-cell dependent) immune mechanisms [116]. The difference in incidence between ipilimumab (IgG1) and tremelimumab (IgG2) is probably due to their different immunological subclasses. In humans, polymorphisms in the CTLA4 gene confer increased susceptibility to a variety of autoimmune diseases, including Hashimoto's thyroiditis, type 1 diabetes mellitus, and Addison's disease [117, 118]. This polymorphism has not been analyzed in patients developing hypophysitis on CTLA-4 blockade. Some data associate the endocrine and other immune-related adverse events to a better outcome of anti-cancer immunotherapy [25]. In one study, ipilimumab 10 mg/kg resulted in significantly longer overall survival against ipilimumab 3 mg/kg but with increased treatment-related adverse events including hypophysitis [111]. In summary, patients who receive immune checkpoint inhibitors, particularly anti-CTLA-4 therapy, should be carefully evaluated to detect pituitary-related side effects. In case of hypophysitis, adequate hormone replacement therapy should be initiated. Failure of the corticotrophic axis is usually permanent and requires continuous glucocorticoid substitution therapy, while failure of thyrotrophic and gonadotrophic axes may be transient.

Thyroid dysfunction

Checkpoint blockade with PD-1 or PD-L1 inhibitors is particularly associated with primary thyroid dysfunction. The spectrum of thyroid side effects includes primary hypo-, hyperthyroidism, and painless thyroiditis. The authors define painless thyroiditis as thyrotoxicosis followed by euthyroidism or hypothyroidism, with negative TRAB, reduced or absent tracer uptake on technetium scan and/or increased ^{18}F fluorodeoxyglucose uptake on positron emission tomography (^{18}F FDG-PET). The authors define hyperthyroidism as a suppressed TSH with an elevated fT4 and/or fT3 level, and hypothyroidism as an elevated TSH with a decreased fT4 level. Importantly, a preceding phase

of hyperthyroidism cannot be excluded in case of hypothyroidism, unless thyroid function tests were systematically followed. Painless thyroiditis can occur early-on, within the first weeks of checkpoint blockade therapy [83, 119, 120]. The initial phase of thyrotoxicosis (suppressed TSH and high fT4) evolves within 3–6 weeks to hypothyroidism (high TSH and low fT4) [75, 83, 119, 120]. Symptoms of thyrotoxicosis are rarely severe. The underlying process is likely to be a destructive, inflammatory thyroiditis. Thyroglobulin (Tg) levels, while not specific, were elevated during thyrotoxicosis and normalized with subsequent hypothyroidism in 5 patients with nivolumab-induced thyroiditis [120]. Diffuse increased uptake of the inflammatory tracer ^{18}F FDG in the thyroid gland was observed in pembrolizumab-induced thyroiditis [75, 83] and in 2 transiently thyrotoxic patients on nivolumab [121]. The differential diagnosis of thyroid dysfunction on checkpoint blockade might be difficult. Hypothyroidism secondary to pituitary failure should be excluded as thyroid substitution therapy could precipitate adrenal failure. A low to normal TSH with low fT4 should prompt the suspicion of hypopituitarism. Euthyroid sick syndrome is also possible in the setting of advanced malignancy. Hyperthyroidism usually results from destructive thyroiditis but cases of Graves' disease on ipilimumab and tremelimumab have been described [122–124]. Iodine contamination due to frequent radiological investigations and subsequent iodine-induced hyperthyroidism is another possibility in this patient population. Measurement of TSH-receptor stimulating antibodies, thyroid scintigraphy and Doppler flow ultrasonography have their use in distinguishing thyroiditis (low uptake on scintigraphy and low blood flow on ultrasound) from Graves' disease (high uptake on scan and high blood flow on ultrasound). Of course, recent administration of iodine-containing contrast media could suppress the uptake measured in thyroid scintigraphy [125]. Symptomatic treatment with non-selective beta-blockers could be required. The duration of hyperthyroidism due to thyroiditis is usually short and no additional therapy is required. Antithyroid drugs (e. g., methimazole, propylthiouracil) should be started on suspicion of Graves' disease or in high-grade hyperthyroidism while awaiting further investigations. Glucocorticosteroids have been used in a patient with thyroid storm [126]. As in hypophysitis, their use is controversial and should only be considered in the most severe cases. Thyroid hormone substitution is usually required for the subsequent phase of hypothyroidism, although a select number of cases were reversible [75, 127].

Why anti-PD-1/PD-L1 therapy favors thyroid dysfunction is not known. The expression of PD-L1 and PD-L2 in normal thyroid tissue has only been analyzed recently [128] and suggests a distinct immunomodulatory role in the thyroid gland. Increased PD-L1 expression has been identified in papillary [129] and anaplastic thyroid carcinoma [130] as a plausible mechanism to evade antitumor immune responses. Polymorphisms in the genes encoding PD-1 and its ligand are related to Graves' disease, but their association is weak [131, 132]. It remains to be defined whether the subpopulation with preexisting subclinical autoimmune thyroid disease is at any particular risk. The absence of pretreatment thyroid function and antithyroid antibody levels is a limitation in establishing the baseline susceptibility of these patients. Thyroperoxidase antibodies (TPOAb), identified after anti-PD-1 treatment in patients with thyroid dysfunction, have also been identified at baseline in some studies [75, 83, 119, 120]. These findings have only recently been verified in a prospective study, wherein the presence of thy-

roid autoantibodies seems to increase the risk for thyroid dysfunction [133].

As a side note, treatment with L-T3 may be a better choice than L-T4. The presence of hypothyroidism could have beneficial effects on tumor behavior. As pointed out in a review by Moeller et al. [134], observations in mouse models suggest that hypothyroidism induced by propylthiouracil suppresses tumor growth, whereas T4 administration had the opposite effect [135, 136]. In a murine model of lung carcinoma, treatment with T3 suppressed metastatic tumor growth and prolonged survival while T4 enhanced tumor growth [137]. In humans, hypothyroidism induced by treatment with IL-2 or the tyrosine-kinase inhibitor sunitinib was associated with a prolonged progression-free survival [138, 139] or response to treatment [140]. In an observational study of 23 patients, euthyroid hypothyroxinemia was achieved by the administration of methimazole with the addition of L-T3, while preexisting hypothyroid patients were treated with T3 for T4 replacement. Most of these patients (19 of 23) had a prolonged survival when compared to epidemiological data [141]. It is currently unknown if and how these findings should be implemented in routine clinical practice. There is an urgent need for prospective evaluation of tumor burden with L-T3 compared to L-T4 replacement and to define the optimal level of thyroid hormone substitution balancing the quality of life and the stimulatory effects on tumor growth.

Diabetes mellitus

While hypophysitis and thyroid disorders are predominant, checkpoint-blockade associated diabetes mellitus deserves further notice. Its presentation is often severe with fulminant diabetes and ketoacidosis [142]. Its onset ranges from a few weeks [143] up to one year after initiating therapy [144]. The clinical presentation consists of classic symptoms with polyuria, polydipsia, fatigue, weight loss, and dehydration. The C-peptide level is low or undetectable while HbA1c levels are not always very elevated (e. g., <53 mmol/mol). Diagnostic antibodies found in type 1 diabetes are detected in only half of cases [142, 145]. This could be due to the acute onset of beta cell inflammation. Dysregulation of PD-1 is implied in both checkpoint-blockade and conventional type 1 diabetes, as peripheral CD4⁺ and regulatory T cells of type 1 diabetes patients show a reduced PD-1 expression [146, 147]. Interestingly, a low CTLA-4 expression on CD4⁺ and regulatory T cells is also found in type 1 diabetes [148, 149], suggesting that patients receiving CTLA-4 blocking mAb are also susceptible. Hyperreactivity of the immune system is suspected as some patients experience thyroiditis before the onset of diabetes [143, 145]. This could be in part explained by HLA haplotypes associated with type 1 diabetes and perhaps also with checkpoint-blockade induced diabetes mellitus. The reverse could also be true as one Japanese patient, carrier of an HLA allele resistant to type 1 diabetes, was less severely affected, without ketoacidosis nor complete insulin deficiency [142]. Long-term treatment consists of insulin therapy. The beta-cell destruction induced by checkpoint inhibitors is unlikely to be reversible. However, longer follow-up is required. Screening measures should include routine measurement of blood glucose and HbA1c. Chronic complications should be monitored in those with a survival lasting more than 5 years.

Primary adrenal insufficiency

Checkpoint-blockade associated adrenal insufficiency is a potentially life-threatening complication, caused by hypophysitis or adrenalitis in this patient population. Symptoms are non-specific and include nausea, fatigue, anorexia, abdominal pain, weight loss, hypotension and hypoglycemia. Low early morning serum cortisol is abnormal and the concomitant presence of a high serum ACTH is suggestive of primary adrenal insufficiency, while low serum ACTH is suggestive of secondary adrenal insufficiency. These findings should prompt dynamic testing. The identification of primary adrenal insufficiency can be difficult however by the concomitant use of corticosteroids in the treatment of other irAE. The incidence of combined primary and secondary adrenal insufficiency is also unknown. Primary adrenal insufficiency is probably mediated by adrenalitis. Adrenal autoantibodies were detected in one case of pembrolizumab-induced adrenal failure [150] while bilateral adrenal gland enlargement [151] and increased bilateral ^{18}F FDG activity [152] have also been observed. Routine screening of pituitary function tests is advisable before each dosing of immune checkpoint therapy. Patients should be informed about the potential danger of cortisol deficiency. In case of primary adrenal insufficiency, patients should not only receive gluco- but also mineralocorticosteroids.

Other endocrine events

Few data are available on the gonadal and parathyroid function during checkpoint blockade therapy. In one retrospective review, 9 ipilimumab-treated patients were identified with low testosterone levels in the absence of hypophysitis [27]. Hypogonadism is difficult to interpret in this patient population because of the severe illness in malignancy and associated secondary hypogonadotropic hypogonadism as well as the use of exogenous corticosteroids for the treatment of irAE. Human fertility could potentially be impaired in the event of hypophysitis leading to persistently low FSH and LH levels. Incidental hypercalcemia with low PTH levels was found in 2 patients [27], perhaps due to hypercalcemia of malignancy. Primary hypoparathyroidism with acute hypocalcemia was described in one case [153], while hypoparathyroidism with no information on serum calcium was detected in one other patient [154].

Study design and limitations

This is a comprehensive analysis of endocrine adverse events on immune checkpoint inhibitors, and the first to include retrospective, prospective, and randomized clinical trials. We chose this approach because adverse events are generally underestimated in randomized clinical trials [155]. The term 'thyroiditis' was not routinely used. Patients with painless thyroiditis can be detected both in the phase of hyperthyroidism or hypothyroidism, further complicating correct reporting. Furthermore, the interpretation of thyroid dysfunction depends of the definition used in each individual study. While the Common Terminology Criteria for Adverse Events (CTCAE) are in widespread use [156], they are imprecise for endocrine disorders, as these do not include a description of the hormone levels nor the separate entity of painless thyroiditis. We are aware that our study has its limitations. The analysis was performed at the study level and did not include individual patient data. Human error cannot be excluded in case of missing studies or duplicates. The analyses of the relative risks were not significant for

thyroiditis and hypophysitis, and were generally associated with large confidence intervals. This could be due to the smaller number of patients as prospective and retrospective studies were not included for these investigations. Finally, trials were excluded if the endocrine adverse events were not reported and this may overestimate our final results.

Conclusions

Hypophysitis is a frequent endocrine adverse event triggered by anti-CTLA-4 mAb, while thyroid dysfunction is commonly observed with anti-PD-1/PD-L1 therapy. Combined checkpoint blockade shows a remarkably higher incidence. Symptoms are often non-specific and may be related to the disseminated cancer or the use of checkpoint inhibitors itself. A high suspicion of endocrine adverse events is therefore warranted as timely diagnosed and treated, one can avoid life-threatening complications. Our knowledge regarding the pathophysiology in the setting of immune checkpoint inhibitors remains limited, but new data start to unravel the mechanisms of immune dysregulation. This could not only be of value to better understand these adverse events, but also the autoimmune endocrine disorders in general.

Funding

This research did not receive any grant from any funding agency in the public, commercial, or non-profit sector.

Conflict of Interest

The authors declare that they have no conflict of interest.

References

- [1] U.S. Food and Drug Administration. Hematology/Oncology (Cancer) Approvals & Safety Notifications. May 26 2017 Available at <https://www.fda.gov/drugs/informationondrugs/approveddrugs/ucm279174.htm> Accessed June 5, 2017
- [2] Abbas AK, Lichtman AH, Pillai S. Cellular and Molecular Immunology. 8th Edition Philadelphia, PA: Elsevier Saunders; 2015
- [3] Byun DJ, Wolchok JD, Rosenberg LM et al. Cancer immunotherapy - immune checkpoint blockade and associated endocrinopathies. *Nat Rev Endocrinol* 2017; 13: 195–207
- [4] Barroso-Sousa R, Barry WT, Garrido-Castro AC et al. Incidence of endocrine dysfunction following the use of different immune checkpoint inhibitor regimens: A systematic review and meta-analysis. *JAMA Oncol* 2018; 4: 173–182
- [5] Wang PF, Chen Y, Song SY et al. Immune-related adverse events associated with anti-PD-1/PD-L1 treatment for malignancies: A meta-analysis. *Front Pharmacol* 2017; 8: 730
- [6] Shang YH, Zhang Y, Li JH et al. Risk of endocrine adverse events in cancer patients treated with PD-1 inhibitors: A systematic review and meta-analysis. *Immunotherapy* 2017; 9: 261–272
- [7] Abdel-Rahman O, ElHalawani H, Fouad M. Risk of endocrine complications in cancer patients treated with immune check point inhibitors: A meta-analysis. *Future Oncol* (London, England) 2016; 12: 413–425

- [8] Ascierto PA, Del Vecchio M, Robert C et al. Ipilimumab 10 mg/kg versus ipilimumab 3 mg/kg in patients with unresectable or metastatic melanoma: A Randomised, double-blind, multicentre, phase 3 trial. *Lancet Oncol* 2017; 18: 611–622
- [9] Bang YJ, Cho JY, Kim YH et al. Efficacy of sequential ipilimumab monotherapy versus best supportive care for unresectable locally advanced/metastatic gastric or gastroesophageal junction cancer. *Clin Cancer Res* 2017; 23: 5671–5678
- [10] Brilli L, Danielli R, Ciuli C et al. Prevalence of hypophysitis in a cohort of patients with metastatic melanoma and prostate cancer treated with ipilimumab. *Endocrine* 2017; 58: 535–541
- [11] Jung M, Lee J, Kim TM et al. Ipilimumab real-world efficacy and safety in Korean melanoma patients from the Korean named-patient program cohort. *Cancer Res Treat* 2017; 49: 44–53
- [12] Schachter J, Ribas A, Long GV et al. Pembrolizumab versus ipilimumab for advanced melanoma: Final overall survival results of a multicentre, randomised, open-label phase 3 study (KEYNOTE-006). *Lancet (London, England)* 2017; 390: 1853–1862
- [13] Wen X, Ding Y, Li J et al. The experience of immune checkpoint inhibitors in Chinese patients with metastatic melanoma: A retrospective case series. *Cancer Immunol Immunother* 2017; 66: 1153–1162
- [14] Boudewijns S, Koornstra RH, Westdorp H et al. Ipilimumab administered to metastatic melanoma patients who progressed after dendritic cell vaccination. *Oncoimmunology* 2016; 5: e1201625
- [15] Eggermont AM, Chiarion-Sileni V, Grob JJ et al. Prolonged survival in stage III melanoma with ipilimumab adjuvant therapy. *N Engl J Med* 2016; 375: 1845–1855
- [16] Hodi FS, Chesney J, Pavlick AC et al. Combined nivolumab and ipilimumab versus ipilimumab alone in patients with advanced melanoma: 2-year overall survival outcomes in a multicentre, randomised, controlled, phase 2 trial. *Lancet Oncol* 2016; 17: 1558–1568
- [17] Larkin J, Chiarion-Sileni V, Gonzalez R et al. Combined Nivolumab and Ipilimumab or Monotherapy in Untreated Melanoma. *N Engl J Med* 2015; 373: 23–34
- [18] Min L, Hodi FS, Giobbie-Hurder A et al. Systemic high-dose corticosteroid treatment does not improve the outcome of ipilimumab-related hypophysitis: A retrospective cohort study. *Clin Cancer Res* 2015; 21: 749–755
- [19] Yamazaki N, Kiyohara Y, Uhara H et al. Phase II study of ipilimumab monotherapy in Japanese patients with advanced melanoma. *Cancer Chemother Pharmacol* 2015; 76: 997–1004
- [20] Yamazaki N, Uhara H, Fukushima S et al. Phase II study of the immune-checkpoint inhibitor ipilimumab plus dacarbazine in Japanese patients with previously untreated, unresectable or metastatic melanoma. *Cancer Chemother Pharmacol* 2015; 76: 969–975
- [21] Zimmer L, Eigentler TK, Kiecker F et al. Open-label, multicenter, single-arm phase II DeCOG-study of ipilimumab in pretreated patients with different subtypes of metastatic melanoma. *J Transl Med* 2015; 13: 351
- [22] Zimmer L, Vaubel J, Mohr P et al. Phase II DeCOG-study of ipilimumab in pretreated and treatment-naïve patients with metastatic uveal melanoma. *PLoS One* 2015; 10: e0118564
- [23] Alexander M, Mellor JD, McArthur G et al. Ipilimumab in pretreated patients with unresectable or metastatic cutaneous, uveal and mucosal melanoma. *Med J Australia* 2014; 201: 49–53
- [24] Chiarion-Sileni V, Pigozzo J, Ascierto PA et al. Ipilimumab retreatment in patients with pretreated advanced melanoma: The expanded access programme in Italy. *Brit J Cancer* 2014; 110: 1721–1726
- [25] Faje AT, Sullivan R, Lawrence D et al. Ipilimumab-induced hypophysitis: A Detailed longitudinal analysis in a large cohort of patients with metastatic melanoma. *J Clin Endocrinol Metab* 2014; 99: 4078–4085
- [26] Kwon ED, Drake CG, Scher HI et al. Ipilimumab versus placebo after radiotherapy in patients with metastatic castration-resistant prostate cancer that had progressed after docetaxel chemotherapy (CA184-043): A multicentre, randomised, double-blind, phase 3 trial. *Lancet Oncol* 2014; 15: 700–712
- [27] Ryder M, Callahan M, Postow MA et al. Endocrine-related adverse events following ipilimumab in patients with advanced melanoma: A comprehensive retrospective review from a single institution. *Endocr Relat Cancer* 2014; 21: 371–381
- [28] Altomonte M, Di Giacomo A, Queirolo P et al. Clinical experience with ipilimumab 10 mg/kg in patients with melanoma treated at Italian centres as part of a European expanded access programme. *J Exp Clin Cancer Res* 2013; 32: 82
- [29] Delyon J, Mateus C, Lefeuvre D et al. Experience in daily practice with ipilimumab for the treatment of patients with metastatic melanoma: An early increase in lymphocyte and eosinophil counts is associated with improved survival. *Ann Oncol* 2013; 24: 1697–1703
- [30] Luke JJ, Callahan MK, Postow MA et al. Clinical activity of ipilimumab for metastatic uveal melanoma: A retrospective review of the Dana-Farber Cancer Institute, Massachusetts General Hospital, Memorial Sloan-Kettering Cancer Center, and University Hospital of Lausanne experience. *Cancer* 2013; 119: 3687–3695
- [31] Postow MA, Luke JJ, Bluth MJ et al. Ipilimumab for patients with advanced mucosal melanoma. *Oncologist* 2013; 18: 726–732
- [32] Robert C, Thomas L, Bondarenko I et al. Ipilimumab plus dacarbazine for previously untreated metastatic melanoma. *N Engl J Med* 2011; 364: 2517–2526
- [33] Hodi FS, O'Day SJ, McDermott DF et al. Improved survival with ipilimumab in patients with metastatic melanoma. *N Engl J Med* 2010; 363: 711–723
- [34] Ku GY, Yuan J, Page DB et al. Single-institution experience with ipilimumab in advanced melanoma patients in the compassionate use setting: Lymphocyte count after 2 doses correlates with survival. *Cancer* 2010; 116: 1767–1775
- [35] Royal RE, Levy C, Turner K et al. Phase 2 trial of single agent Ipilimumab (anti-CTLA-4) for locally advanced or metastatic pancreatic adenocarcinoma. *J Immunother (Hagerstown, Md)* 1997; 2010; 33: 828–833
- [36] Downey SG, Klapper JA, Smith FO et al. Prognostic factors related to clinical response in patients with metastatic melanoma treated by CTL-associated antigen-4 blockade. *Clin Cancer Res* 2007; 13: 6681–6688
- [37] Maker AV, Yang JC, Sherry RM et al. Inpatient dose escalation of anti-CTLA-4 antibody in patients with metastatic melanoma. *Journal of immunotherapy (Hagerstown, Md)* 1997; 2006; 29: 455–463
- [38] Maio M, Scherpereel A, Calabro L et al. Tremelimumab as second-line or third-line treatment in relapsed malignant mesothelioma (DETERMINE): A multicentre, international, randomised, double-blind, placebo-controlled phase 2b trial. *Lancet Oncol* 2017; 18: 1261–1273
- [39] Joshua AM, Monzon JG, Mihalciou C et al. A phase 2 study of tremelimumab in patients with advanced uveal melanoma. *Melanoma Res* 2015; 25: 342–347
- [40] Aglietta M, Barone C, Sawyer MB et al. A phase I dose escalation trial of tremelimumab (CP-675,206) in combination with gemcitabine in chemotherapy-naïve patients with metastatic pancreatic cancer. *Ann Oncol* 2014; 25: 1750–1755
- [41] Ribas A, Kefford R, Marshall MA et al. Phase III randomized clinical trial comparing tremelimumab with standard-of-care chemotherapy in patients with advanced melanoma. *J Clin Oncol* 2013; 31: 616–622
- [42] Chung KY, Gore I, Fong L et al. Phase II study of the anti-cytotoxic T-lymphocyte-associated antigen 4 monoclonal antibody, tremelimumab, in patients with refractory metastatic colorectal cancer. *J Clin Oncol* 2010; 28: 3485–3490

- [43] Kirkwood JM, Lorigan P, Hersey P et al. Phase II trial of tremelimumab (CP-675,206) in patients with advanced refractory or relapsed melanoma. *Clin Cancer Res* 2010; 16: 1042–1048
- [44] Camacho LH, Antonia S, Sosman J et al. Phase I/II trial of tremelimumab in patients with metastatic melanoma. *J Clin Oncol* 2009; 27: 1075–1081
- [45] Ribas A, Camacho LH, Lopez-Berestein G et al. Antitumor activity in melanoma and anti-self responses in a phase I trial with the anti-cytotoxic T lymphocyte-associated antigen 4 monoclonal antibody CP-675,206. *J Clin Oncol* 2005; 23: 8968–8977
- [46] Carbone DP, Reck M, Paz-Ares L et al. First-Line Nivolumab in Stage IV or Recurrent Non-Small-Cell Lung Cancer. *N Engl J Med* 2017; 376: 2415–2426
- [47] El-Khoueiry AB, Sangro B, Yau T et al. Nivolumab in patients with advanced hepatocellular carcinoma (CheckMate 040): An open-label, non-comparative, phase 1/2 dose escalation and expansion trial. *Lancet (London, England)* 2017; 389: 2492–2502
- [48] Larkin J, Minor D, D'Angelo S et al. Overall survival in patients with advanced melanoma who received nivolumab versus investigator's choice chemotherapy in checkmate 037: A randomized, controlled, open-label phase III trial. *J Clin Oncol* 2018; 36: 383–390
- [49] Maruyama D, Hatake K, Kinoshita T et al. A multicenter phase II study of nivolumab in Japanese patients with relapsed or refractory classical Hodgkin lymphoma. *Cancer Sci* 2017; 108: 1007–1012
- [50] Morris VK, Salem ME, Nimeiri H et al. Nivolumab for previously treated unresectable metastatic anal cancer (NCI9673): A multicentre, single-arm, phase 2 study. *Lancet Oncol* 2017; 18: 446–453
- [51] Overman MJ, McDermott R, Leach JL et al. Nivolumab in patients with metastatic DNA mismatch repair-deficient or microsatellite instability-high colorectal cancer (CheckMate 142): An open-label, multicentre, phase 2 study. *Lancet Oncol* 2017; 18: 1182–1191
- [52] Sharma P, Retz M, Siefker-Radtke A et al. Nivolumab in metastatic urothelial carcinoma after platinum therapy (CheckMate 275): A multicentre, single-arm, phase 2 trial. *Lancet Oncol* 2017; 18: 312–322
- [53] Yamazaki N, Kiyohara Y, Uhara H et al. Efficacy and safety of nivolumab in Japanese patients with previously untreated advanced melanoma: A phase II study. *Cancer Sci* 2017; 108: 1223–1230
- [54] Yamazaki N, Kiyohara Y, Uhara H et al. Cytokine biomarkers to predict antitumor responses to nivolumab suggested in a phase II study for advanced melanoma. *Cancer Sci* 2017; 108: 1022–1031
- [55] Antonia SJ, Lopez-Martin JA, Bendell J et al. Nivolumab alone and nivolumab plus ipilimumab in recurrent small-cell lung cancer (CheckMate 032): A multicentre, open-label, phase 1/2 trial. *Lancet Oncol* 2016; 17: 883–895
- [56] Choueiri TK, Fishman MN, Escudier B et al. Immunomodulatory activity of nivolumab in metastatic renal cell carcinoma. *Clin Cancer Res* 2016; 22: 5461–5471
- [57] Ferris RL, Blumenschein G Jr., Fayette J et al. Nivolumab for recurrent squamous-cell carcinoma of the head and neck. *N Engl J Med* 2016; 375: 1856–1867
- [58] Gettinger S, Rizvi NA, Chow LQ et al. Nivolumab monotherapy for first-line treatment of advanced non-small-cell lung cancer. *J Clin Oncol* 2016; 34: 2980–2987
- [59] Rizvi NA, Hellmann MD, Brahmer JR et al. Nivolumab in combination with platinum-based doublet chemotherapy for first-line treatment of advanced non-small-cell lung cancer. *J Clin Oncol* 2016; 34: 2969–2979
- [60] Sharma P, Callahan MK, Bono P et al. Nivolumab monotherapy in recurrent metastatic urothelial carcinoma (CheckMate 032): A multicentre, open-label, two-stage, multi-arm, phase 1/2 trial. *Lancet Oncol* 2016; 17: 1590–1598
- [61] Weber J, Gibney G, Kudchadkar R et al. Phase I/II Study of metastatic melanoma patients treated with nivolumab who had progressed after ipilimumab. *Cancer Immunol Res* 2016; 4: 345–353
- [62] Ansell SM, Lesokhin AM, Borrello I et al. PD-1 blockade with nivolumab in relapsed or refractory Hodgkin's lymphoma. *N Engl J Med* 2015; 372: 311–319
- [63] Borghaei H, Paz-Ares L, Horn L et al. Nivolumab versus docetaxel in advanced nonsquamous non-small-cell lung cancer. *N Engl J Med* 2015; 373: 1627–1639
- [64] Brahmer J, Reckamp KL, Baas P et al. Nivolumab versus docetaxel in advanced squamous-cell non-small-cell lung cancer. *N Engl J Med* 2015; 373: 123–135
- [65] Hamanishi J, Mandai M, Ikeda T et al. Safety and antitumor activity of anti-pd-1 antibody, nivolumab, in patients with platinum-resistant ovarian cancer. *J Clin Oncol* 2015; 33: 4015–4022
- [66] McDermott DF, Drake CG, Sznol M et al. Survival, durable response, and long-term safety in patients with previously treated advanced renal cell carcinoma receiving nivolumab. *J Clin Oncol* 2015; 33: 2013–2020
- [67] Motzer RJ, Rini BI, McDermott DF et al. Nivolumab for metastatic renal cell carcinoma: results of a randomized phase ii trial. *J Clin Oncol* 2015; 33: 1430–1437
- [68] Rizvi NA, Mazieres J, Planchard D et al. Activity and safety of nivolumab, an anti-PD-1 immune checkpoint inhibitor, for patients with advanced, refractory squamous non-small-cell lung cancer (CheckMate 063): A phase 2, single-arm trial. *Lancet Oncol* 2015; 16: 257–265
- [69] Robert C, Long GV, Brady B et al. Nivolumab in previously untreated melanoma without BRAF mutation. *N Engl J Med* 2015; 372: 320–330
- [70] Weber JS, D'Angelo SP, Minor D et al. Nivolumab versus chemotherapy in patients with advanced melanoma who progressed after anti-CTLA-4 treatment (CheckMate 037): A Randomised, controlled, open-label, phase 3 trial. *Lancet Oncol* 2015; 16: 375–384
- [71] Topalian SL, Sznol M, McDermott DF et al. Survival, durable tumor remission, and long-term safety in patients with advanced melanoma receiving nivolumab. *J Clin Oncol* 2014; 32: 1020–1030
- [72] Baum J, Seiwert TY, Pfister DG et al. Pembrolizumab for platinum- and cetuximab-refractory head and neck cancer: results from a single-arm, phase ii study. *J Clin Oncol* 2017; 35: 1542–1549
- [73] Bellmunt J, de Wit R, Vaughn DJ et al. Pembrolizumab as Second-Line Therapy for Advanced Urothelial Carcinoma. *N Engl J Med* 2017; 376: 1015–1026
- [74] Chen R, Zinzani PL, Fanale MA et al. Phase II study of the efficacy and safety of pembrolizumab for relapsed/refractory classic hodgkin lymphoma. *J Clin Oncol* 2017; 35: 2125–2132
- [75] Delivanis DA, Gustafson MP, Bornschlegel S et al. Pembrolizumab-induced thyroiditis: comprehensive clinical review and insights into underlying involved mechanisms. *J Clin Endocrinol Metab* 2017; 102: 2770–2780
- [76] Ott PA, Piha-Paul SA, Munster P et al. Safety and antitumor activity of the anti-PD-1 antibody pembrolizumab in patients with recurrent carcinoma of the anal canal. *Ann Oncol* 2017; 28: 1036–1041
- [77] Ott PA, Elez E, Hirt S et al. Pembrolizumab in patients with extensive-stage small-cell lung cancer: results from the phase ib keynote-028 study. *J Clin Oncol* 2017; 35: 3823–3829
- [78] Yamazaki N, Takenouchi T, Fujimoto M et al. Phase 1b study of pembrolizumab (MK-3475; anti-PD-1 monoclonal antibody) in Japanese patients with advanced melanoma (KEYNOTE-041). *Cancer Chemother Pharmacol* 2017; 79: 651–660
- [79] Zinzani PL, Ribrag V, Moskowitz CH et al. Safety and tolerability of pembrolizumab in patients with relapsed/refractory primary mediastinal large B-cell lymphoma. *Blood* 2017; 130: 267–270

- [80] Armand P, Shipp MA, Ribrag V et al. Programmed Death-1 Blockade With Pembrolizumab in Patients With Classical Hodgkin Lymphoma After Brentuximab Vedotin Failure. *J Clin Oncol* 2016; 34: 3733–3739
- [81] Chatterjee M, Turner DC, Filip E et al. Systematic evaluation of pembrolizumab dosing in patients with advanced non-small-cell lung cancer. *Ann Oncol* 2016; 27: 1291–1298
- [82] Chow LQ, Haddad R, Gupta S et al. Antitumor activity of pembrolizumab in biomarker-unselected patients with recurrent and/or metastatic head and neck squamous cell carcinoma: results from the phase Ib keynote-012 expansion cohort. *J Clin Oncol* 2016; 34: 3838–3845
- [83] de Filette J, Jansen Y, Schreuer M et al. Incidence of thyroid-related adverse events in melanoma patients treated with pembrolizumab. *J Clin Endocrinol Metab* 2016; 101: 4431–4439
- [84] Langer CJ, Gadgil SM, Borghaei H et al. Carboplatin and pemetrexed with or without pembrolizumab for advanced, non-squamous non-small-cell lung cancer: A Randomised, phase 2 cohort of the open-label KEYNOTE-021 study. *Lancet Oncol* 2016; 17: 1497–1508
- [85] Muro K, Chung HC, Shankaran V et al. Pembrolizumab for patients with PD-L1-positive advanced gastric cancer (KEYNOTE-012): A multicentre, open-label, phase 1b trial. *Lancet Oncol* 2016; 17: 717–726
- [86] Nanda R, Chow LQ, Dees EC et al. Pembrolizumab in patients with advanced triple-negative breast cancer: Phase Ib KEYNOTE-012 Study. *J Clin Oncol* 2016; 34: 2460–2467
- [87] Reck M, Rodriguez-Abreu D, Robinson AG et al. Pembrolizumab versus Chemotherapy for PD-L1-Positive Non-Small-Cell Lung Cancer. *N Engl J Med* 2016; 375: 1823–1833
- [88] Ribas A, Hamid O, Daud A et al. Association of pembrolizumab with tumor response and survival among patients with advanced melanoma. *JAMA* 2016; 315: 1600–1609
- [89] Seiwert TY, Burtress B, Mehra R et al. Safety and clinical activity of pembrolizumab for treatment of recurrent or metastatic squamous cell carcinoma of the head and neck (KEYNOTE-012): An open-label, multicentre, phase 1b trial. *Lancet Oncol* 2016; 17: 956–965
- [90] Herbst RS, Baas P, Kim DW et al. Pembrolizumab versus docetaxel for previously treated, PD-L1-positive, advanced non-small-cell lung cancer (KEYNOTE-010): A Randomised controlled trial. *Lancet (London, England)* 2016; 387: 1540–1550
- [91] Garon EB, Rizvi NA, Hui R et al. Pembrolizumab for the treatment of non-small-cell lung cancer. *N Engl J Med* 2015; 372: 2018–2028
- [92] Patnaik A, Kang SP, Rasco D et al. Phase I study of pembrolizumab (MK-3475; Anti-PD-1 monoclonal antibody) in patients with advanced solid tumors. *Clin Cancer Res* 2015; 21: 4286–4293
- [93] Ribas A, Puzanov I, Dummer R et al. Pembrolizumab versus investigator-choice chemotherapy for ipilimumab-refractory melanoma (KEYNOTE-002): A Randomised, controlled, phase 2 trial. *Lancet Oncol* 2015; 16: 908–918
- [94] Robert C, Ribas A, Wolchok JD et al. Anti-programmed-death-receptor-1 treatment with pembrolizumab in ipilimumab-refractory advanced melanoma: A Randomised dose-comparison cohort of a phase 1 trial. *Lancet (London, England)* 2014; 384: 1109–1117
- [95] Balar AV, Galsky MD, Rosenberg JE et al. Atezolizumab as first-line treatment in cisplatin-ineligible patients with locally advanced and metastatic urothelial carcinoma: A Single-arm, multicentre, phase 2 trial. *Lancet (London, England)* 2017; 389: 67–76
- [96] Peters S, Gettinger S, Johnson ML et al. Phase II Trial of Atezolizumab As First-Line or Subsequent Therapy for Patients With Programmed Death-Ligand 1-Selected Advanced Non-Small-Cell Lung Cancer (BIRCH). *J Clin Oncol* 2017; 35: 2781–2789
- [97] Fehrenbacher L, Spira A, Ballinger M et al. Atezolizumab versus docetaxel for patients with previously treated non-small-cell lung cancer (POPLAR): A multicentre, open-label, phase 2 randomised controlled trial. *Lancet (London, England)* 2016; 387: 1837–1846
- [98] McDermott DF, Sosman JA, Sznol M et al. Atezolizumab, an Anti-Programmed Death-Ligand 1 Antibody, in Metastatic Renal Cell Carcinoma: Long-Term Safety, Clinical Activity, and Immune Correlates From a Phase Ia Study. *J Clin Oncol* 2016; 34: 833–842
- [99] Apolo AB, Infante JR, Balmanoukian A et al. Avelumab, an Anti-Programmed Death-Ligand 1 Antibody, in Patients With Refractory Metastatic Urothelial Carcinoma: Results From a Multicenter, Phase Ib Study. *J Clin Oncol* 2017; 35: 2117–2124
- [100] Gulley JL, Rajan A, Spigel DR et al. Avelumab for patients with previously treated metastatic or recurrent non-small-cell lung cancer (JAVELIN Solid Tumor): Dose-expansion cohort of a multicentre, open-label, phase 1b trial. *Lancet Oncol* 2017; 18: 599–610
- [101] Kaufman HL, Russell J, Hamid O et al. Avelumab in patients with chemotherapy-refractory metastatic Merkel cell carcinoma: A multicentre, single-group, open-label, phase 2 trial. *Lancet Oncol* 2016; 17: 1374–1385
- [102] Powles T, O'Donnell PH, Massard C et al. Efficacy and safety of durvalumab in locally advanced or metastatic urothelial carcinoma: updated results from a phase 1/2 open-label study. *JAMA Oncol* 2017; 3: e172411
- [103] Hellmann MD, Rizvi NA, Goldman JW et al. Nivolumab plus ipilimumab as first-line treatment for advanced non-small-cell lung cancer (CheckMate 012): results of an open-label, phase 1, multicohort study. *Lancet Oncol* 2017; 18: 31
- [104] Hammers HJ, Plimack ER, Infante JR et al. Safety and efficacy of nivolumab in combination with ipilimumab in metastatic renal cell carcinoma: The CheckMate 016 Study. *J Clin Oncol* 2017; 35: 38513858
- [105] Shoushtari AN, Friedman CF, Navid-Azarbaijani P et al. Measuring toxic effects and time to treatment failure for nivolumab plus ipilimumab in melanoma. *JAMA Oncol* 2018; 4: 98–101
- [106] Wolchok JD, Kluger H, Callahan MK et al. Nivolumab plus ipilimumab in advanced melanoma. *N Engl J Med* 2013; 369: 122–133
- [107] Long GV, Atkinson V, Cebon JS et al. Standard-dose pembrolizumab in combination with reduced-dose ipilimumab for patients with advanced melanoma (KEYNOTE-029): an open-label, phase 1b trial. *Lancet Oncol* 2017; 18: 1202–1210
- [108] Antonia S, Goldberg SB, Balmanoukian A et al. Safety and antitumour activity of durvalumab plus tremelimumab in non-small cell lung cancer: a multicentre, phase 1b study. *Lancet Oncol* 2016; 17: 299–308
- [109] Araujo PB, Coelho MC, Arruda M et al. Ipilimumab-induced hypophysitis: Review of the literature. *J Endocrinol Invest* 2015; 38: 1159–1166
- [110] Corsello SM, Barnabei A, Marchetti P et al. Endocrine side effects induced by immune checkpoint inhibitors. *J Clin Endocrinol Metab* 2013; 98: 1361–1375
- [111] Bertrand A, Kostine M, Barnette T et al. Immune related adverse events associated with anti-CTLA-4 antibodies: Systematic review and meta-analysis. *BMC Medicine* 2015; 13: 211
- [112] Albarel F, Gaudy C, Castinetti F et al. Long-term follow-up of ipilimumab-induced hypophysitis, a common adverse event of the anti-CTLA-4 antibody in melanoma. *Eur J Endocrinol* 2015; 172: 195–204
- [113] Blansfield JA, Beck KE, Tran K et al. Cytotoxic T-lymphocyte-associated antigen-4 blockage can induce autoimmune hypophysitis in patients with metastatic melanoma and renal cancer. *J Immunother (Hagerstown, Md: 1997)* 2005; 28: 593–598
- [114] Dillard T, Yedinak CG, Alumkal J et al. Anti-CTLA-4 antibody therapy associated autoimmune hypophysitis: Serious immune related adverse events across a spectrum of cancer subtypes. *Pituitary* 2010; 13: 29–38

- [115] Iwama S, De Remigis A, Callahan MK et al. Pituitary expression of CTLA-4 mediates hypophysitis secondary to administration of CTLA-4 blocking antibody. *Sci Transl Med* 2014; 6: 230ra245
- [116] Caturegli P, Di Dalmazi G, Lombardi M et al. Hypophysitis secondary to cytotoxic t-lymphocyte-associated protein 4 blockade: insights into pathogenesis from an autopsy series. *Am J Pathol* 2016; 186: 3225–3235
- [117] Blomhoff A, Lie BA, Myhre AG et al. Polymorphisms in the cytotoxic T lymphocyte antigen-4 gene region confer susceptibility to Addison's disease. *J Clin Endocrinol Metab* 2004; 89: 3474–3476
- [118] Ueda H, Howson JM, Esposito L et al. Association of the T-cell regulatory gene CTLA4 with susceptibility to autoimmune disease. *Nature* 2003; 423: 506–511
- [119] Orlov S, Salari F, Kashat L et al. Induction of painless thyroiditis in patients receiving programmed death 1 receptor immunotherapy for metastatic malignancies. *J Clin Endocrinol Metab* 2015; 100: 1738–1741
- [120] Alhusseini M, Samantray J. Hypothyroidism in cancer patients on immune checkpoint inhibitors with anti-PD1 Agents: Insights on underlying mechanisms. *Exp Clin Endocrinol Diabetes* 2017; 125: 267–269
- [121] van Kooten MJ, van den Berg G, Glaudemans A et al. Transient thyrotoxicosis during nivolumab treatment. *Netherl J Med* 2017; 75: 204–207
- [122] Azmat U, Liebner D, Joehlin-Price A et al. Treatment of ipilimumab induced graves' disease in a patient with metastatic melanoma. *Case Rep Endocrinol* 2016; 2087525
- [123] Min L, Vaidya A, Becker C. Thyroid autoimmunity and ophthalmopathy related to melanoma biological therapy. *Eur J Endocrinol* 2011; 164: 303–307
- [124] Gan EH, Mitchell AL, Plummer R et al. Tremelimumab-Induced Graves Hyperthyroidism. *Eur Thyr J* 2017; 6: 167–170
- [125] Andersen TB, Aleksyniemi R, Gormsen LC et al. Effect of recent contrast-enhanced CT and patient age on image quality of thyroid scintigraphy. *Clin Nucl Med* 2015; 40: 297–302
- [126] McMillen B, Dhillon MS, Yong-Yow S. A rare case of thyroid storm. *BMJ Case Rep* 2016, 2016; doi:10.1136/bcr-2016-214603
- [127] Morganstein DL, Lai Z, Spain L et al. Thyroid abnormalities following the use of cytotoxic T-lymphocyte antigen-4 and programmed death receptor protein-1 inhibitors in the treatment of melanoma. *Clin Endocrinol* 2017; 86: 614–620
- [128] Yamauchi I, Sakane Y, Fukuda Y et al. Clinical features of nivolumab-induced thyroiditis: A case series study. *Thyroid* 2017; 27: 894–901
- [129] Angell TE, Lechner MG, Jang JK et al. BRAF V600E in papillary thyroid carcinoma is associated with increased programmed death ligand 1 expression and suppressive immune cell infiltration. *Thyroid* 2014; 24: 1385–1393
- [130] Chintakuntlawar AV, Rumilla KM, Smith CY et al. Expression of PD-1 and PD-L1 in Anaplastic Thyroid Cancer Patients Treated With Multimodal Therapy: Results From a Retrospective Study. *J Clin Endocrinol Metab* 2017; 102: 1943–1950
- [131] Newby PR, Roberts-Davies EL, Brand OJ et al. Tag SNP screening of the PDCD1 gene for association with Graves' disease. *Clin Endocrinol* 2007; 67: 125–128
- [132] Hayashi M, Kouki T, Takasu N et al. Association of an A/C single nucleotide polymorphism in programmed cell death-ligand 1 gene with Graves' disease in Japanese patients. *Eur J Endocrinol* 2008; 158: 817–822
- [133] Kobayashi T, Iwama S, Yasuda Y et al. Patients with antithyroid antibodies are prone to develop destructive thyroiditis by nivolumab: A prospective study. *J Endocr Soc* 2018; 2: 241–251
- [134] Moeller LC, Fuhrer D. Thyroid hormone, thyroid hormone receptors, and cancer: a clinical perspective. *Endocr Relat Cancer* 2013; 20: R19–R29
- [135] Theodosiou C, Skrepnik N, Robert EG et al. Propylthiouracil-induced hypothyroidism reduces xenograft tumor growth in athymic nude mice. *Cancer* 1999; 86: 1596–1601
- [136] Fabian ID, Rosner M, Fabian I et al. Low thyroid hormone levels improve survival in murine model for ocular melanoma. *Oncotarget* 2015; 6: 11038–11046
- [137] Kinoshita S, Sone S, Yamashita T et al. Effects of experimental hyper- and hypothyroidism on natural defense activities against Lewis lung carcinoma and its spontaneous pulmonary metastases in C57BL/6 mice. *Tokushima J Exp Med* 1991; 38: 25–35
- [138] Baldazzi V, Tassi R, Lapini A et al. The impact of sunitinib-induced hypothyroidism on progression-free survival of metastatic renal cancer patients: A prospective single-center study. *Urol Oncol* 2012; 30: 704–710
- [139] Clemons J, Gao D, Naam M et al. Thyroid dysfunction in patients treated with sunitinib or sorafenib. *Clin Genitourin Cancer* 2012; 10: 225–231
- [140] Weijl NI, Van der Harst D, Brand A et al. Hypothyroidism during immunotherapy with interleukin-2 is associated with antithyroid antibodies and response to treatment. *J Clin Oncol* 1993; 11: 1376–1383
- [141] Herbergs A, Johnson RE, Ashur-Fabian O et al. Medically induced euthyroid hypothyroxinemia may extend survival in compassionate need cancer patients: An Observational study. *Oncologist* 2015; 20: 72–76
- [142] Matsumura K, Nagasawa K, Oshima Y et al. Aggravation of diabetes, and incompletely deficient insulin secretion in a case with type 1 diabetes-resistant HLA DRB1 * 15:02 treated with nivolumab. *J Diabetes Invest* 2017; 9: 438–441
- [143] Hughes J, Vudattu N, Sznol M et al. Precipitation of autoimmune diabetes with anti-PD-1 immunotherapy. *Diabetes Care* 2015; 38: e55–e57
- [144] Okamoto M, Okamoto M, Gotoh K et al. Fulminant type 1 diabetes mellitus with anti-programmed cell death-1 therapy. *J Diabetes Invest* 2016; 7: 915–918
- [145] Lowe JR, Perry DJ, Salama AK et al. Genetic risk analysis of a patient with fulminant autoimmune type 1 diabetes mellitus secondary to combination ipilimumab and nivolumab immunotherapy. *J Immunother Cancer* 2016; 4: 89
- [146] Fujisawa R, Haseda F, Tsutsumi C et al. Low programmed cell death-1 (PD-1) expression in peripheral CD4(+) T cells in Japanese patients with autoimmune type 1 diabetes. *Clin Exp Immunol* 2015; 180: 452–457
- [147] Perri V, Russo B, Crino A et al. Expression of pd-1 molecule on regulatory t lymphocytes in patients with insulin-dependent diabetes mellitus. *Int J Mol Sci* 2015; 16: 22584–22605
- [148] Luczynski W, Wawrusiewicz-Kurylonek N, Stasiak-Barmuta A et al. Diminished expression of ICOS, GITR and CTLA-4 at the mRNA level in T regulatory cells of children with newly diagnosed type 1 diabetes. *Acta Biochim Pol* 2009; 56: 361–370
- [149] Haseda F, Imagawa A, Murase-Mishiba Y et al. Low CTLA-4 expression in CD4+ helper T-cells in patients with fulminant type 1 diabetes. *Immunol Lett* 2011; 139: 80–86
- [150] Paepegaey AC, Lheure C, Ratour C et al. Polyendocrinopathy resulting from pembrolizumab in a patient with a malignant melanoma. *J Endocr Soc* 2017; 1: 646–649
- [151] Min L, Ibrahim N. Ipilimumab-induced autoimmune adrenalitis. *Lancet Diabetes Endocrinol* 2013; 1: e15

- [152] Trainer H, Hulse P, Higham CE et al. Hyponatraemia secondary to nivolumab-induced primary adrenal failure. *Endocrinol Diabetes Metab Case Reps* 2016; 2016: pii 16–0108 [Epub 2016 Nov 1]
- [153] Win MA, Thein KZ, Qdaisat A et al. Acute symptomatic hypocalcemia from immune checkpoint therapy-induced hypoparathyroidism. *Am J Emerg Med* 2017; 35: 1039 e1035–1039 e1037
- [154] Horinouchi H, Yamamoto N, Fujiwara Y et al. Phase I study of ipilimumab in phased combination with paclitaxel and carboplatin in Japanese patients with non-small-cell lung cancer. *Invest New Drugs* 2015; 33: 881–889
- [155] Wahab IA, Pratt NL, Kalisch LM et al. The detection of adverse events in randomized clinical trials: Can we really say new medicines are safe? *Curr Drug Safety* 2013; 8: 104–113
- [156] National Cancer Institute. Common Terminology Criteria for Adverse Events (CTCAE). Version 4.03.; June 14 2010 Available at https://ctep.cancer.gov/protocoldevelopment/electronic_applications/docs/CTCAE_4.03.xlsx Accessed March 27, 2018