

A Systematic Review of 639 Patients with Biopsy-confirmed Nephrogenic Systemic Fibrosis

Hanieh Attari, MD • Yan Cao, MD • Tina R. Elmholt, MD, PhD • Yize Zhao, PhD • Martin R. Prince, MD, PhD

From the Department of Radiology, Weill Cornell Medical College & New York Presbyterian Hospital, 416 E 55th St, New York, NY 10022 (H.A., Y.Z., M.R.P.); Department of Radiology, Wayne State University/Detroit Medical Center, Detroit, Mich (Y.C.); Department of Children and Adolescent Psychiatry, Aarhus University Hospital, Aarhus, Denmark (T.R.E.); and Department of Radiology, Columbia University College of Physicians and Surgeons, New York, NY (M.R.P.). Received December 21, 2018; revision requested February 25, 2019; revision received April 25; accepted May 6. Address correspondence to M.R.P. (e-mail: map2008@med.cornell.edu).

Conflicts of interest are listed at the end of this article.

See also the editorial by Davenport in this issue.

Radiology 2019; 292:376–386 • <https://doi.org/10.1148/radiol.2019182916> • Content codes: **HP** **MR**

Background: Although nephrogenic systemic fibrosis (NSF) affects the use of gadolinium-based contrast agents (GBCAs) in MRI, there continues to be limited knowledge because of the small number of patients with NSF.

Purpose: To perform a systematic review of NSF.

Materials and Methods: PubMed database was searched by using the term “Nephrogenic systemic fibrosis” from January 2000 to February 2019. Articles reporting details on individual patients with NSF diagnosis on the basis of both clinical presentations and biopsy confirmation were included. Data were pooled and authors were contacted for clarifications. Rates of NSF were compared through 2008 versus after 2008 and for group I versus group II GBCAs, assuming equal market share.

Results: Included were 639 patients from 173 articles. Data regarding sex were found for 295 men and 254 women. Age at NSF symptom onset was reported for 177 patients (mean, 49 years \pm 16 [standard deviation]; age range, 6–87 years). There were 529 patients with documented exposure to GBCAs including gadodiamide ($n = 307$), gadopentetate dimeglumine ($n = 49$), gadoverseamide ($n = 6$), gadobutrol ($n = 1$), gadobenate dimeglumine ($n = 1$), multiple ($n = 41$), and unknown ($n = 120$). Among patients with previous exposure, only seven patients were administered GBCA after 2008, yielding a lower rate of NSF after 2008 ($P < .001$). There were motion limitations in 70.8% (296 of 418) of patients, indicating a more serious debilitation. Associated factors reported for NSF included exposure to GBCA group I ($P < .001$), dialysis, proinflammatory conditions, hyperphosphatemia, β -blockers, and epoetin. For 341 patients with follow-up, 12 patients were cured and 72 patients partially improved including one during pregnancy. Among those 84 patients reported as cured or improved, in 34 patients cure or improvement occurred after renal function restoration. Four deaths were attributed to NSF.

Conclusion: Although 639 patients with biopsy-confirmed nephrogenic systemic fibrosis were reported, only seven were after gadolinium-based contrast agent exposure after 2008, indicating that regulatory actions and practice changes have been effective preventive measures. Improvement and sometimes cure with renal function restoration are now possible.

©RSNA, 2019

Nephrogenic systemic fibrosis (NSF) is a systemic disorder characterized by fibrosis and sclerotic-myxedematous skin lesions occurring in individuals with chronic kidney disease stage 4 or 5 (estimated glomerular filtration rate [GFR; eGFR] < 30 mL/min/1.73 m²) or acute renal failure. It was described by Cowper et al in 2000 (1), and in 2006 (2) it was linked with previous exposure to gadolinium-based contrast agents (GBCAs), mostly the nonionic linear GBCA administered at high doses (3). Warnings from the U.S. Food and Drug Administration, European Medical Agency, and other organizations led to widespread screening for renal dysfunction in individuals undergoing GBCA-enhanced MRI and the use of less or no high-risk GBCA when the patient's eGFR was less than 30 mL/min/1.73 m². High-risk group I GBCA per the American College of Radiology contrast media manual includes gadodiamide, gadopentetate dimeglumine, and gadoversetamide.

Since 2008, there have been few reports of NSF related to GBCA exposure, which suggests that the

regulations have been effective. However, there has been relaxation of the requirements for renal function screening with the American College of Radiology manual on contrast media, indicating the assessment of renal function is now optional before administration of low-risk group II GBCAs, including gadoteridol, gadobutrol, gadoterate meglumine, and gadobenate dimeglumine. To learn as much as possible to maintain vigilance against NSF to avoid a resurgence, it is useful to collate data from all prior reported cases. In our study, we performed a systematic review evaluating risk factors and features of NSF.

Materials and Methods

Institutional review board approval was not needed because all data were reported in the literature. One author reported conflicts of interest (Bayer, Bracco, GE Healthcare, Guerbet/Mallinckrodt, and Lantheus). All other authors had no conflicts of interest; therefore, they assessed the data and information.

This copy is for personal use only. To order printed copies, contact reprints@rsna.org

Abbreviations

eGFR = estimated GFR, GBCA = gadolinium-based contrast agent, GFR = glomerular filtration rate, NSF = nephrogenic systemic fibrosis

Summary

A systematic search of PubMed identified 639 patients with biopsy-confirmed nephrogenic systemic fibrosis and patient-specific details available for each individual, showing that only seven involved reported exposure to a gadolinium-based contrast agent after 2008.

Key Points

- Per a systematic search of PubMed, only seven patients with biopsy-confirmed nephrogenic systemic fibrosis (NSF) were reported related to exposures to gadolinium-based contrast agents (GBCAs) that occurred after 2008.
- Infants and toddlers younger than 6 years have no reported diagnoses of NSF and adults older than 80 years have only seven reported diagnoses of NSF despite a growing occurrence of reduced glomerular filtration rate in older patients, which suggests that younger and older patients have a reduced risk of NSF.
- Follow-up of patients with NSF shows symptomatic improvements with renal function restoration and with β -blocker cessation, pregnancy, extracorporeal photopheresis, and thiosulfate disodium; cure was reported in 12 patients.

Literature Search Strategy

Two radiology research fellows (H.A. and Y.C., with 4 and 6 years of experience, respectively) independently searched PubMed from January 2000 to February 2019 by using the search terms “Nephrogenic systemic fibrosis,” “Nephrogenic fibrosing dermatopathy,” and “NSF.” Our inclusion criteria included articles that reported patients with NSF diagnosed on the basis of clinical features with biopsy confirmation and articles that reported individual patient details. Retrieved articles were screened and additional manual citation searching was performed on relevant references within each article that met the inclusion criteria after duplicates were removed. Comments, letters, reviews, and articles that did not report individual patients with NSF were excluded on the basis of reviewing titles and abstracts. In total, 639 patients from 173 articles were included (Fig 1), which is nearly double the number of patients in a previous review (4) from 2011 that reported 370 patients from 98 articles.

Bias Assessment

We assessed risk of bias by using A Cochrane Risk of Bias Assessment Tool: for Non-Randomized Studies of Interventions, or ACROBAT-NRSI. Patient selection bias was considered severe for case reports, moderate for case series, and low when authors described performing systematic searches of dermatology, pathology, and radiology databases to ensure identification of all patients. Missing data bias was low when reports included age, sex, GBCA type and dose, GFR and/or dialysis status at the time of GBCA exposure, and interval to onset of NSF symptoms; it was considered moderate when up to two parameters were missing; and data bias was severe when more than two parameters were missing. A spreadsheet detailing our extracted data was sent to corresponding authors with a request to verify it and to provide any additional available details.

Outcomes bias was low for articles with final outcomes reported (eg, death, immobility, cure), moderate with some follow-up, and serious with no follow-up. Conflict of interest was graded as low when disclosed as none and moderate when conflict of interest was not disclosed in the study. Serious conflict of interest occurred when an author served as an expert witness in GBCA-related litigation (5) or received support from GBCA manufacturers for the research (6).

Data Extraction

Two authors (H.A. and Y.C.) independently read each article that met inclusion criteria and extracted the data. Laboratory data had to be reported as obtained around the time of GBCA exposure. Additional data extracted included patient age (at time of GBCA exposure, at time of NSF symptom onset, and at time of NSF diagnosis), patient sex, patient ethnicity, motion limitation, internal organ involvement, skin plaques, skin thickening and/or hardening, calcifications, scleral plaque, edema, retroperitoneal fibrosis, thrombosis, imaging studies, MRI indication, history of exposure to gadolinium, and gadolinium type and dose (assuming patients undergoing MR angiography received a double-dose GBCA of 30 mL). Other data included chronic or acute renal failure at the time of GBCA exposure, underlying reason for renal dysfunction, dialysis at the time of GBCA exposure, type of dialysis, interval between GBCA exposure and next dialysis, interval between GBCA exposure and onset of symptoms attributed to NSF, blood urea nitrogen and/or creatinine, eGFR, calcium, phosphorus, acidosis, sedimentation rate, epoetin treatment, kidney transplant, any improvement after transplantation or renal function restoration, and liver disease and/or transplant; proinflammatory conditions including autoimmune disease, diabetes, recent surgical procedure, infection, shock, malignancy, myocardial infarction, gout, and vasculitis; and treatments and outcomes including improvement, progression, or death. All discrepancies and differences in the data extractions between the two observers were resolved by consensus.

Statistical Analysis

Data were reported as mean \pm standard deviation when normally distributed or as median, mode, and interquartile range when not normally distributed. Incidence of NSF associated with group I versus group II GBCA was calculated by assuming equal market share. Sensitivity of the significance of the difference to this market share assumption was assessed by varying market share over a broad range. Incidence of NSF through 2008 versus after 2008 was calculated by assuming equal GBCA utilization for those two periods (ie, before vs after the black box warning and implementation of GBCA regulatory restrictions that occurred in 2008) and compared with χ^2 . The effect of cumulative GBCA dose, dialysis status at GBCA exposure, type of dialysis, acute versus chronic renal failure, and GBCA exposure to NSF symptom onset interval on the incidence of motion limitations reported with NSF was assessed by multivariate regression analysis including parameters found to be significant at univariate analysis. Statistical analysis was performed by using statistical software (R version 3.5.3; R Core Team, Vienna, Austria) and the α level was set to .05.

Results

Study and Patient Selection

The database search identified 1073 articles. By screening titles or abstracts, 841 articles were removed. The other 232 articles were assessed at the full-text level. Of these, 59 articles were excluded because of the following: no biopsy confirmation ($n = 2$), duplicate reporting ($n = 21$), no patient with NSF in study ($n = 20$), summary data ($n = 15$, which summarized 82 patients), and lack of author response to a letter challenging the diagnosis ($n = 1$) (7,8). From the remaining 173 articles (3,5,6,9–178) reporting 794 patients, 155 patients were excluded for the following reasons (Fig 1): no biopsy confirmation ($n = 59$), overlap with other articles ($n = 49$), no details ($n = 46$), and change of diagnosis ($n = 1$) (9), yielding 639 patients from which data could be pooled.

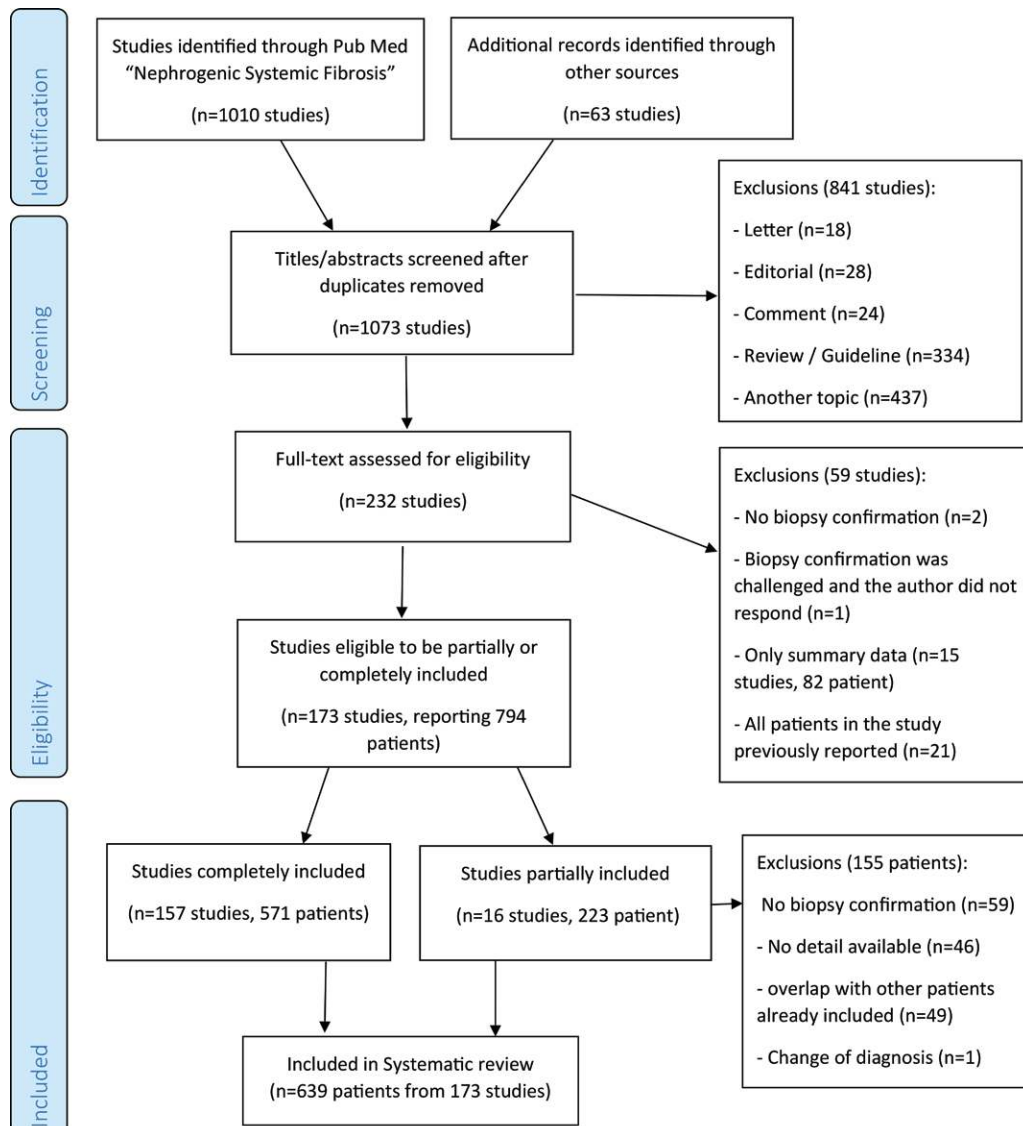


Figure 1: Flowchart of study and patient selection process.

Bias Assessment

We found a moderate risk of bias because of missing data in 85 articles and severe risk in 28 articles. Authors were contacted to resolve these biases and 72 authors provided additional information. Two articles had serious conflicts of interest (7,8) and 65 disclosed no conflict. For all of the articles, severe confounding bias was present because all patients had renal dysfunction and other comorbidities, which may have contributed to many reported symptoms and findings. Selection bias was severe for 126 case reports and moderate for six case series. Outcome bias was low for 101 articles that reported final outcomes and severe for 37 articles with no follow-up (Table 1).

Data Extraction Results

Patient demographics.—Among 549 patients for whom data on sex were available, 295 were men and 254 were women.

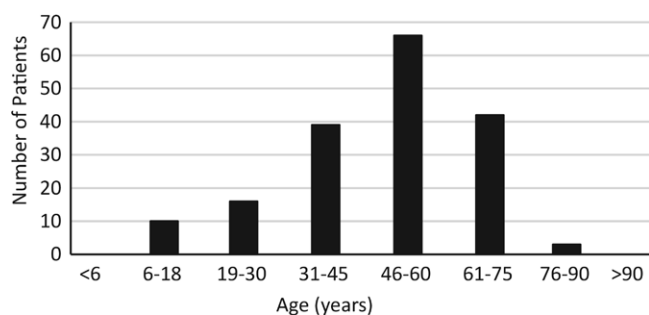
Ethnicity was reported for 351 patients, and it included the following: white, 228 patients; black or African American, 68 patients; Hispanic, 15 patients; Japanese, 20 patients; Chinese, four patients; Malay, one patient; Vietnamese, two patients; Taiwanese, three patients; unspecified Asian, three patients; Indian, four patients; Middle Eastern, one patient; and Maori, two patients. Data regarding patient age were available for 130 patients at GBCA exposure (mean age, 49 years \pm 16), 177 patients at NSF symptom onset (mean age, 49 years \pm 16) (Fig 2), and 414 patients at diagnosis (mean age, 51 years \pm 16). There were no reports of NSF in neonates or toddlers; the youngest age reported was 6 years. There were only seven reports in older patients (>80 years); the oldest patient reported was 87 years.

Extent of disease.—Dermatologic manifestations without motion limitations were reported for 29.2% (122 of 418) of

Table 1: Bias Risk for Data in Patients with Nephrogenic Systemic Fibrosis

Type of Bias	Low	Moderate	Severe
Confounding	0/0	0/0	173/639
Selection of patients	41/458	6/26	126/155
Missing data	60/241	85/349	28/49
Measurement of outcomes	101/295	35/161	37/183
Conflict of interest	65/250	106/364	2/25

Note.—Data are number of articles/number of patients. Data includes 173 studies that reported a total of 639 patients.

**Figure 2:** Age at onset of nephrogenic systemic fibrosis symptoms for 177 patients with nephrogenic systemic fibrosis.

patients with data, which indicated a milder form of the disease. Three patients had peau d'orange involving the breast that reportedly resembled inflammatory breast cancer (10–12). Although NSF generally spares the face, three reports described bilateral firm papules or lesions on the lateral canthal area (13,14). Motion limitations developed in 70.8% (296 of 418) of patients, and this represented a more debilitating disease. Internal organ involvement was reported in 56% (51 of 91; Table 2) and autoimmune disease in 47.5% (68 of 143; Table 3). Characteristics of the disease and reported contributing factors are summarized in Table 4.

GBCA.—For 539 patients with data, 97.4% (525 of 539) were exposed to GBCA before they developed NSF but only seven underwent administration of GBCA after 2008 (15–17,126,141,164,179). NSF occurred in 14 patients without evidence of prior GBCA exposure in spite of searching. Ninety-eight articles ($n = 405$) reported the type of GBCA (Table 5), showing that 362 patients were administered only group I GBCAs. Group II GBCA exposure was reported in 23 patients, but only two were unconfounded (17,18) and two additional patients were administered gadoterate with another unknown GBCA, precluding an assessment of confounding (19). Accuracy and completeness of these data were sometimes questioned (3,8).

The interval between GBCA exposure and NSF was available for 336 patients, ranging from the same day to approximately 10 years (median, 42 days; mode, 30 days; interquartile range, 19–90 days). For patients in whom GBCA dose was reported or could be estimated from the examination type, 6.7% (19 of 282) of patients were administered a standard dose (0.1 mmol/kg) or lower, and 93.3% (263 of 282)

Table 2: Internal Organ Involvement in Patients with Nephrogenic Systemic Fibrosis

Involved Internal Organ	No. of Patients*
Heart (muscle, valves, pericardium)	19
Lung (parenchyma, pleura)	12
GI (pancreas, adrenal glands, esophagus, liver, intestines)	9
CNS (dura mater, meninges)	8
Kidneys	7
Muscle	5
Diaphragm	3
Vessels	3
Thyroid	1
Not specified	11
Total no. with involvement	51
No internal organ involvement	40

Note.—There were a total of 91 patients with nephrogenic systemic fibrosis. CNS = central nervous system, GI = gastrointestinal.

* Twelve patients had more than one internal organ involved with nephrogenic systemic fibrosis.

of patients were administered a greater than standard dose. Multiple exposures occurred in 173 patients. The mean cumulative dose was estimated to be 63 mL.

Dialysis and renal failure.—Of 322 patients with data, 278 (86.3%) were on dialysis around the time of GBCA exposure. For 89 patients, interval between GBCA exposure and dialysis could be determined; 27 patients underwent dialysis the same day, 23 patients underwent dialysis 1 day later, 10 patients underwent dialysis 2 days later, and 29 patients underwent dialysis 3 or more days later. Among patients not on dialysis with eGFR data (mean, 14.3 mL/min/1.73 m² ± 8), three had eGFR greater than 30 mL/min/1.73 m² but all three had acute renal failure resulting in eGFR overestimation (20–22). Another two patients were reported to have creatinine clearances of 37 and 51 mL/min (23). However, both had a body mass index greater than 25 kg/m², indicating that their GFR was actually lower (180). The underlying causes of renal failure are shown in Table 6.

Type of MRI.—MRI examination type (Table 7) was reported for 239 patients, including 46.4% (111 of 239) undergoing MR angiography, which likely reflected the common use of high doses for this examination until 2008. Abdominal MRI was the second most common examination (22.2%; 53 of 239), which also likely reflects the tendency to have administered high doses for liver MRI before 2008. Interestingly, there were only four patients who underwent cardiac MRI reported to be temporally correlated with developing NSF in spite of the common use of double-dose GBCA and high incidence of renal disease in these patients. Imaging features reported include soft-tissue activity at bone scintigraphy ($n = 6$), skin thickening at mammography ($n = 5$), and inflammatory changes on CT scans ($n = 15$).

Table 3: Autoimmune Disease Assessed in Patients with Nephrogenic Systemic Fibrosis

Type of Autoimmune Disease	No. of Patients
Systemic lupus erythematosus	39
Antiphospholipid syndrome	12
IgA nephropathy	4
Rheumatoid arthritis	2
Wegner granulomatosis	1
Multiple sclerosis	1
Henoch-Schonlein purpura	1
Good pasture syndrome	2
Goiter	1
Unspecified	5
Total	68

Note.—IgA = immunoglobulin A.

Outcomes.—For those with follow-up, 24.6% (84 of 341) had partial ($n = 72$) or complete ($n = 12$) resolution of NSF symptoms, and 40% (34 of 84) of resolutions of symptoms occurred after restoration of renal function. Improvement was also reported during pregnancy (22); however, a confounding variable in that patient was implementation of dialysis five times per week. Five patients who were administered high-dose β -blockers had symptomatic improvement at cessation of β -blockers (23). Another patient in the same study improved by switching from subcutaneous administration of darbepoetin to intravenous administration of darbepoetin.

The clinical course was stable in 61 patients and progressive in 20 patients. Four patients were dependent on a walker, 20 patients were wheelchair bound, and 10 patients were described as severely disabled. Death was noted in 110 patients, but only four attributed death to NSF after administration of 20, 32, 50, and 75 mL of linear GBCA (Table 8).

Data Analysis

By assuming equal market share for groups I and II GBCAs, the rate of NSF per million exposures to group I was 1.52 (95% confidence interval: 1.37, 1.68) versus 0.008 (95% confidence interval: 0.001, 0.032) for group II ($P < .001$). A market share sensitivity analysis showed the rate of NSF per million exposures was still significantly (ie, 20-fold) higher for group I GBCA by assuming 90% market share of 0.84 (95% confidence interval: 0.76, 0.93) versus group II with 10% market share of 0.04 (95% confidence interval: 0.006, 0.16; $P < .001$).

By assuming equal use of GBCA before versus after the implementation of black box warnings and implementation of GBCA regulatory restrictions, the rate of NSF per million exposures was 2.07 (95% confidence interval: 1.90, 2.26) through 2008 versus 0.028 (95% confidence interval: 0.012, 0.060) after 2008 ($P < .001$). No statistically significant effects were observed regarding developing motion limitations during the course of the disease with cumulative GBCA dose, dialysis, type of dialysis, acute or chronic renal failure, and GBCA exposure to NSF interval.

Table 4: Patient Demographics and Nephrogenic Systemic Fibrosis Characteristics

Parameter	No. of Patients
Demographic	
Mean age at onset of NSF symptoms (y)*	49 \pm 16 (6–87) [177]
No. of men	295/549 (53.7)
No. of women	254/549 (46.3)
Features of NSF	
Skin plaques	403/418 (96.4)
Skin thickening/hardening	398/418 (95.2)
Edema	297/418 (71.0)
Scleral plaque/injection	41/418 (9.8)
Only dermatologic manifestation without motion limitation	29
Motion limitation	296/418 (70.8)
Joint contractures	211/296 (71.3)
Stiffness	19/296 (6.4)
Unspecified	66/296 (22.3)
Internal organ involvement	51/91 (56)
Contributing factors	
Dialysis at time of GBCA	309/377 (82.0)
Hemodialysis	243/309 (78.6)
Peritoneal dialysis	35/309 (11.3)
CVVH	4/309 (1.3)
Unspecified dialysis	27/309 (8.7)
Renal failure	
Acute	109/556 (19.6)
Chronic	449/556 (80.8)
Kidney transplant	143/631 (22.7)
Failing renal transplant	86/143 (60.1)
Liver disease	43
Transplant	23
Proinflammatory events	363/380 (95.5)
Recent major surgery	103
Diabetes	115
Acute thrombosis	80
Infection	71
Autoimmune disease	68/143 (47.6)
Malignancy	36
Other (ie, gout, myocardial infarction, vasculitis, shock)	34
Acidosis	38/55 (69)
Hyperphosphatemia [†]	75/103 (72.8)
Epoetin	79/128 (61.7)
β -blockers	22/55 (40)

Note.—Unless otherwise indicated, data are total number of patients/number of patients with nephrogenic systemic fibrosis for whom it was determined that the given feature was assessed; data in parentheses are percentages. CVVH = continuous venovenous hemofiltration, GBCA = gadolinium-based contrast agent, NSF = nephrogenic systemic fibrosis.

* Data in parentheses are range; data in brackets are the number of patients with these data.

[†] Mean serum phosphorus level, 5.6 mg/dL \pm 2 (healthy range, 2.5–4.5 mg/dL).

Table 5: Type of GBCA Used in Patients with Nephrogenic Systemic Fibrosis

Type of GBCA	GBCA Structure	No. of Patients
Gadodiamide	Nonionic Linear	307/405 (75.8)
Gadoversetamide	Nonionic Linear	6/405 (1.5)
Gadopentetate dimeglumine	Ionic Linear	49/405 (12.1)
Gadobutrol	Macrocytic	1/405 (0.2)
Gadoterate meglumine	Macrocytic	0–2*/405 (0–0.5)
Gadoteridol	Macrocytic	0/405 (0)
Gadoxetic disodium	Ionic Linear	0/405 (0)
Gadobenate dimeglumine	Ionic Linear	1/405 (0.2)
Multiple agents including gadodiamide		33/405 (8.1)
Multiple not including gadodiamide		8/405 (2.0)
Unknown		120

Note.—Data are numerator/denominator; data in parentheses are percentages. Data are from 405 patients with nephrogenic systemic fibrosis. GBCA = gadolinium-based contrast agent.

* Two patients were exposed to gadoterate and another unknown GBCA.

Discussion

We identified 639 patients with biopsy-confirmed nephrogenic systemic fibrosis (NSF) and sufficient details for each individual that showed almost all were administered gadolinium-based contrast agents (GBCAs), primarily nonionic linear, at high doses (>0.1 mmol/kg). This supports the hypothesis that GBCA can trigger NSF, but there may be other triggers because 14 patients with NSF were not administered GBCA. Proinflammatory events, epoetin, hyperphosphatemia, acidosis, and β -blockers were all reported as contributing factors. Among patients on dialysis, some may have had poor quality dialysis because of failing dialysis fistula, use of peritoneal or continuous venovenous hemofiltration approaches, or delay longer than 3 days between GBCA and dialysis. This further supports the recommendations to administer the GBCA just before a regular dialysis session in patients on hemodialysis (181).

After dialysis, the most common clinical situation was a kidney transplant that failed in a patient who underwent GBCA-enhanced MR angiography. Fortunately, it is possible to evaluate transplant arteries without GBCA by using ferumoxytol-enhanced or noncontrast-enhanced renal MR angiography (182). MR angiography with standard or lower than standard dose group II GBCAs, contrast-enhanced CT, and Doppler US are additional options (183,184).

A large number of patients were administered nonionic linear GBCAs (gadodiamide, gadoversetamide), which tend to have lower in vitro stability compared with the ionic linear and macrocyclic agents; this supports the hypothesis that lower chelate stability contributes to greater risk of NSF (24,25,185). However, this does not necessarily translate into greater overall risk, especially in patients with normal renal function, because

Table 6: Cause of Underlying Renal Disease in Patients with NSF

Underlying Renal Disease	No. of Patients
Diabetic nephropathy	48
Glomerulonephritis	37
Hypertensive nephropathy	35
Chronic kidney disease	29
Autoimmune nephropathy	19
Acute kidney injury	17
FSGS*	16
Genetic renal abnormalities	14
Hepatorenal syndrome	10
Renovascular disease	9
ESRD* from unknown reason	8
Pyelonephritis	8
Reflux nephropathy	7
Drug-induced nephropathy	6
Malignancy	5
IgA nephropathy	3
Nephrolithiasis	3
Eclampsy	2
Interstitial nephritis	3
Ischemia	2
HELLP syndrome	1
Obstructive nephropathy	1
Osteodystrophy	1
Postpartum HUS*	1
Sarcoidosis	1
Other	16

Note.—Data are from 287 patients with nephrogenic systemic fibrosis. ESRD = end stage renal disease; FSGS = focal segmental glomerulonephritis; HELLP = hemolysis, elevated liver enzymes, low platelet count; HUS = hemolytic uremic syndrome; IgA = immunoglobulin A; NSF = nephrogenic systemic fibrosis.

* Some patients had more than one underlying kidney disease.

nonionic agents have fewer serious allergic-type adverse events and deaths (26,186).

The near elimination of new patients since 2008 indicates that regulatory recommendations to avoid GBCAs in patients with GFR less than 30 mL/min/1.73 m² are preventing NSF and preserving access to the benefits of GBCAs for most patients. Because macrocyclic GBCAs have been used in Europe without renal function screening, it would appear these do not cause NSF. Indeed, because the risk is sufficiently low or possibly nonexistent, American College of Radiology contrast media manual suggests that renal function assessment before group II GBCA administration is not necessary. As in all instances, it should be administered at the lowest dose possible and only if they are deemed necessary. The single patient who develops NSF related to macrocyclic GBCA (18) may be a rare exception, may have had another GBCA exposure, or may have developed NSF from a cause unrelated to GBCA.

NSF risk appears to be related to age. No patients younger than 6 years developed NSF, despite babies with immature kidneys and low GFR who were administered GBCAs, sometimes at high doses (eg, for congenital heart disease workups). We do

Table 7: Gadolinium-based Contrast Agent-enhanced Imaging Studies Preceding Nephrogenic Systemic Fibrosis

GBCA Examination Type	No. of Patients
MR angiography	111
Abdomen	53
Head	31
Radiographic angiography	29
Extremities	14
Unspecified	13
Pelvis	29
Spine	15
Cardiac	4

Note.—GBCA = gadolinium-based contrast agent.

Table 8: Outcomes

Outcome	No. of Patients
Cure (ie, complete resolution of symptoms)	12/341 (3.5)
Improvement (ie, partial resolution of symptoms)	72/341 (21.1)
Improvement or cure after renal function restoration	34/341 (10.0)
Dependent on walker	4/341 (1.2)
Wheelchair bound	21/341 (6.2)
Worsening and severely disabled	30/341 (8.8)
Stable	61/341 (17.9)
Alive (without further details)	31/341 (9.1)
Death*	110/341 (32.3)

Note.—Data are numerator/denominator; data in parentheses are percentages. Data are from 341 patients with nephrogenic systemic fibrosis who had follow-up information.

* Four of these deaths were attributed to nephrogenic systemic fibrosis.

not know why the young immune system is not susceptible to gadolinium triggering of NSF. The paucity of older patients (age > 80 years), in spite of a high prevalence of renal insufficiency in this population, suggests that their immune systems may not respond as vigorously to the NSF trigger as that of younger adults. Alternatively, these patients may somehow have been less likely to have been administered group I GBCAs or their NSF symptoms are less evident.

Unlike 10 years ago, when to our knowledge there were no treatment options, there are now reports of symptomatic improvement and even cure following normal renal function restoration (eg, via transplantation or resolution of acute renal failure), pregnancy, cessation of β -blockers, administration of sodium thiosulfate, and extracorporeal photopheresis.

Our study had limitations. The limitations include severe confounding bias in all articles and substantial number with selection bias, missing data bias, limited outcomes, and conflicts of interest. However, these biases are balanced against the large total number, which may average out the effects of opposing biases. Incomplete information from 72 studies was mitigated by contacting authors. However, authors who depend on their clinical

expertise tended to focus on reporting different aspects of NSF. In particular, most case reports were exploratory and did not systematically indicate the absence of positive findings. Also, we did not correct numbers of NSF reports for each GBCA according to market share or for the tendency toward over-reporting by academic centers. Thus, high market share of gadopentetate and gadodiamide at academic centers before 2008 may have resulted in larger numbers of NSF reports compared with the other group I GBCA, gadoversetamide. One hospital reported the same rate of NSF after switching to gadoversetamide that they noticed previously with gadodiamide. Finally, these data are limited by the absence of a control population, although some individual reports did include control patients.

This information from 639 biopsy-confirmed patients with nephrogenic systemic fibrosis can help to continue preventing new patients. Group I gadolinium-based contrast agents (GBCAs) need to be avoided in patients with a glomerular filtration rate less than 30 mL/min/1.73 m²; however, there is no need for screening of renal function if the patient is exposed to GBCA group II. For patients on regular hemodialysis, GBCA-enhanced MRI should be scheduled for just before the next dialysis session.

Author contributions: Guarantor of integrity of entire study, H.A.; study concepts/study design or data acquisition or data analysis/interpretation, all authors; manuscript drafting or manuscript revision for important intellectual content, all authors; approval of final version of submitted manuscript, all authors; agrees to ensure any questions related to the work are appropriately resolved, all authors; literature research, H.A., Y.C., M.R.P.; clinical studies, T.R.E.; statistical analysis, H.A., Y.C., Y.Z.; and manuscript editing, H.A., T.R.E., Y.Z., M.R.P.

Disclosures of Conflicts of Interest: H.A. disclosed no relevant relationships. Y.C. disclosed no relevant relationships. T.R.E. disclosed no relevant relationships. Y.Z. disclosed no relevant relationships. M.R.P. Activities related to the present article: disclosed no relevant relationships. Activities not related to the present article: disclosed money paid to author for consultancy from GE and Bracco; disclosed money paid to author for MR angiography patent agreements from Bayer, Bracco, GE, Guerbet/Mallinckrodt, and Lantheus. Other relationships: disclosed no relevant relationships.

References

- Cowper SE, Robin HS, Steinberg SM, et al. Scleromyxoedema-like cutaneous diseases in renal-dialysis patients. *Lancet* 2000;356(9234):1000–1001.
- Grobner T. Gadolinium—a specific trigger for the development of nephrogenic fibrosing dermopathy and nephrogenic systemic fibrosis. *Nephrol Dial Transplant* 2006;21(4):1104–1108.
- Prince MR, Zhang H, Morris M, et al. Incidence of nephrogenic systemic fibrosis at two large medical centers. *Radiology* 2008;248(3):807–816.
- Zou Z, Zhang HL, Roditi GH, Leiner T, Kucharczyk W, Prince MR. Nephrogenic systemic fibrosis: review of 370 biopsy-confirmed cases. *JACC Cardiovasc Imaging* 2011;4(11):1206–1216.
- Barker-Griffith A, Goldberg J, Abraham JL. Ocular pathologic features and gadolinium deposition in nephrogenic systemic fibrosis. *Arch Ophthalmol* 2011;129(5):661–663.
- Becker S, Walter S, Witzke O, et al. The German registry for nephrogenic systemic fibrosis: findings from 23 patients. *Clin Nephrol* 2010;73(6):426–430.
- Wollanka H, Weidenmaier W, Giersig C. NSF after Gadovist exposure: a case report and hypothesis of NSF development. *Nephrol Dial Transplant* 2009;24(12):3882–3884.
- Collidge T, Thomson P, Mark P, Willinek W, Roditi G. Is this really a true case of NSF following Gadovist exposure alone? *Nephrol Dial Transplant* 2010;25(4):1352–1353; author reply 1353–1354.
- The PLOS ONE Staff. Correction: Nephrogenic Systemic Fibrosis in Denmark—A Nationwide Investigation. *PLoS One* 2014;9(6):e100407.
- Halteh P, Huang J, Wildman HF, Magro CM. Gadolinium-Naive Nephrogenic Systemic Fibrosis of Breast Mimicking Inflammatory Breast Carcinoma. *Am J Dermatopathol* 2017;39(4):322–324.

11. Choi J, Ha R, Wynn R. Nephrogenic Systemic Fibrosis on Mammography. *Curr Probl Diagn Radiol* 2015;44(6):517–520.
12. Solomon GJ, Wu E, Rosen PP. Nephrogenic systemic fibrosis mimicking inflammatory breast carcinoma. *Arch Pathol Lab Med* 2007;131(1):145–148.
13. Ross C, De Rosa N, Marshman G, Astill D. Nephrogenic systemic fibrosis in a gadolinium-naïve patient: successful treatment with oral sirolimus. *Australas J Dermatol* 2015;56(3):e59–e62.
14. Introcaso CE, Elenitsas R, Xu X, James WD. Periocular papules in nephrogenic systemic fibrosis. *J Am Acad Dermatol* 2008;59(3):536–537.
15. Chuang K, Kaneshiro C, Betancourt J. Nephrogenic Systemic Fibrosis in a Patient With Multiple Inflammatory Disorders. *Fed Pract* 2018;35(6):40–43.
16. Fuah KW, Lim CTS. Erythema nodosum masking nephrogenic systemic fibrosis as initial skin manifestation. *BMC Nephrol* 2017;18(1):249.
17. Lohani S, Golenbiewski J, Swami A, Halalau A. A unique case of nephrogenic systemic fibrosis from gadolinium exposure in a patient with normal eGFR. *BMJ Case Rep* 2017;2017:bcr-2017-221016.
18. Elmholdt TR, Jørgensen B, Ramsing M, Pedersen M, Olesen AB. Two cases of nephrogenic systemic fibrosis after exposure to the macrocyclic compound gadobutrol. *NDT Plus* 2010;3(3):285–287.
19. Elmholdt TR, Olesen AB, Jørgensen B, et al. Nephrogenic systemic fibrosis in Denmark—a nation-wide investigation. *PLoS One* 2013;8(12):e82037.
20. Sadowski EA, Bennett LK, Chan MR, et al. Nephrogenic systemic fibrosis: risk factors and incidence estimation. *Radiology* 2007;243(1):148–157.
21. Wiginton CD. Implications of NSF-active and NSF-inert in nephrogenic systemic fibrosis. *AJR Am J Roentgenol* 2008;191(6):1864–1866.
22. Khurana A, Nickel AE, Greene JF Jr, Narayanan M, High WA, Foulks CJ. Successful pregnancy in a hemodialysis patient and marked resolution of her nephrogenic systemic fibrosis. *Am J Kidney Dis* 2008;51(6):e29–e32.
23. Lemy AA, del Marmol V, Kolivras A, et al. Revisiting nephrogenic systemic fibrosis in 6 kidney transplant recipients: a single-center experience. *J Am Acad Dermatol* 2010;63(3):389–399.
24. Wertman R, Altun E, Martin DR, et al. Risk of nephrogenic systemic fibrosis: evaluation of gadolinium chelate contrast agents at four American universities. *Radiology* 2008;248(3):799–806.
25. Reilly RF. Risk for nephrogenic systemic fibrosis with gadoteridol (ProHance) in patients who are on long-term hemodialysis. *Clin J Am Soc Nephrol* 2008;3(3):747–751.
26. Prince MR, Zhang H, Zou Z, Staron RB, Brill PW. Incidence of immediate gadolinium contrast media reactions. *AJR Am J Roentgenol* 2011;196(2):W138–W143.
27. Kallen AJ, Jhung MA, Cheng S, et al. Gadolinium-containing magnetic resonance imaging contrast and nephrogenic systemic fibrosis: a case-control study. *Am J Kidney Dis* 2008;51(6):966–975.
28. Lauenstein TC, Salman K, Morreira R, et al. Nephrogenic systemic fibrosis: center case review. *J Magn Reson Imaging* 2007;26(5):1198–1203.
29. Evenepoel P, Zeegers M, Segar S, et al. Nephrogenic fibrosing dermopathy: a novel, disabling disorder in patients with renal failure. *Nephrol Dial Transplant* 2004;19(2):469–473.
30. Abraham JL, Thakral C, Skov L, Rossen K, Marckmann P. Dermal inorganic gadolinium concentrations: evidence for in vivo transmetallation and long-term persistence in nephrogenic systemic fibrosis. *Br J Dermatol* 2008;158(2):273–280.
31. Auron A, Shao L, Warady BA. Nephrogenic fibrosing dermopathy in children. *Pediatr Nephrol* 2006;21(9):1307–1311.
32. Grobner T. Gadolinium—a specific trigger for the development of nephrogenic fibrosing dermopathy and nephrogenic systemic fibrosis? *Nephrol Dial Transplant* 2006;21(4):1104–1108.
33. Introcaso CE, Hivnor C, Cowper S, Werth VP. Nephrogenic fibrosing dermopathy/nephrogenic systemic fibrosis: a case series of nine patients and review of the literature. *Int J Dermatol* 2007;46(5):447–452.
34. Jiménez SA, Artlett CM, Sandorfi N, et al. Dialysis-associated systemic fibrosis (nephrogenic fibrosing dermopathy): study of inflammatory cells and transforming growth factor beta1 expression in affected skin. *Arthritis Rheum* 2004;50(8):2660–2666.
35. Kim RH, Ma L, Hayat SQ, Ahmed MM. Nephrogenic fibrosing dermopathy/nephrogenic systemic fibrosis in 2 patients with end-stage renal disease on hemodialysis. *J Clin Rheumatol* 2006;12(3):134–136.
36. Kucher C, Steere J, Elenitsas R, Siegel DL, Xu X. Nephrogenic fibrosing dermopathy/nephrogenic systemic fibrosis with diaphragmatic involvement in a patient with respiratory failure. *J Am Acad Dermatol* 2006;54(2 Suppl):S31–S34.
37. Marckmann P, Skov L, Rossen K, et al. Nephrogenic systemic fibrosis: suspected causative role of gadodiamide used for contrast-enhanced magnetic resonance imaging. *J Am Soc Nephrol* 2006;17(9):2359–2362.
38. Mendoza FA, Artlett CM, Sandorfi N, Latinis K, Piera-Velazquez S, Jimenez SA. Description of 12 cases of nephrogenic fibrosing dermopathy and review of the literature. *Semin Arthritis Rheum* 2006;35(4):238–249.
39. Moreno-Romero JA, Segura S, Masclaró JM Jr, et al. Nephrogenic systemic fibrosis: a case series suggesting gadolinium as a possible aetiological factor. *Br J Dermatol* 2007;157(4):783–787.
40. Thakral C, Alhariri J, Abraham JL. Long-term retention of gadolinium in tissues from nephrogenic systemic fibrosis patient after multiple gadolinium-enhanced MRI scans: case report and implications. *Contrast Media Mol Imaging* 2007;2(4):199–205.
41. Ting WW, Stone MS, Madison KC, Kurtz K. Nephrogenic fibrosing dermopathy with systemic involvement. *Arch Dermatol* 2003;139(7):903–906.
42. Wahba IM, Simpson EL, White K. Gadolinium is not the only trigger for nephrogenic systemic fibrosis: insights from two cases and review of the recent literature. *Am J Transplant* 2007;7(10):2425–2432.
43. Aires NB, Sotto MN, Nico MM. Nephrogenic fibrosing dermopathy: report of two cases. *Acta Derm Venereol* 2007;87(6):521–524.
44. Anavekar NS, Chong AH, Norris R, Dowling J, Goodman D. Nephrogenic systemic fibrosis in a gadolinium-naïve renal transplant recipient. *Australas J Dermatol* 2008;49(1):44–47.
45. Boyd AS, Zic JA, Abraham JL. Gadolinium deposition in nephrogenic fibrosing dermopathy. *J Am Acad Dermatol* 2007;56(1):27–30.
46. Broome DR, Girguis MS, Baron PW, Cottrell AC, Kjellin I, Kirk GA. Gadodiamide-associated nephrogenic systemic fibrosis: why radiologists should be concerned. *AJR Am J Roentgenol* 2007;188(2):586–592.
47. Caccetta T, Chan JJ. Nephrogenic systemic fibrosis associated with liver transplantation, renal failure and gadolinium. *Australas J Dermatol* 2008;49(1):48–51.
48. Chao CC, Yang CC, Hsiao CH, Pan MK, Lin CH, Hsieh ST. Nephrogenic systemic fibrosis associated with gadolinium use. *J Formos Med Assoc* 2008;107(3):270–274.
49. Cheung PP, Dorai Raj AK. Nephrogenic fibrosing dermopathy: a new clinical entity mimicking scleroderma. *Intern Med J* 2007;37(2):139–141.
50. Clorius S, Technau K, Watter T, et al. Nephrogenic systemic fibrosis following exposure to gadolinium-containing contrast agent. *Clin Nephrol* 2007;68(4):249–252.
51. Collidge TA, Thomson PC, Mark PB, et al. Gadolinium-enhanced MR imaging and nephrogenic systemic fibrosis: retrospective study of a renal replacement therapy cohort. *Radiology* 2007;245(1):168–175.
52. Deng AC, Bilu Martin D, Sina B, Gaspari A. Localized nephrogenic fibrosing dermopathy: Aberrant dermal repairing? *J Am Acad Dermatol* 2008;58(2):336–339.
53. Deo A, Fogel M, Cowper SE. Nephrogenic systemic fibrosis: a population study examining the relationship of disease development to gadolinium exposure. *Clin J Am Soc Nephrol* 2007;2(2):264–267.
54. Kalb RE, Helm TN, Sperry H, Thakral C, Abraham JL, Kanal E. Gadolinium-induced nephrogenic systemic fibrosis in a patient with an acute and transient kidney injury. *Br J Dermatol* 2008;158(3):607–610.
55. Keyrouz S, Rudnicki SA. Neuromuscular involvement in nephrogenic systemic fibrosis. *J Clin Neuromuscul Dis* 2007;9(2):297–302.
56. Khurana A, Runge VM, Narayanan M, Greene JF Jr, Nickel AE. Nephrogenic systemic fibrosis: a review of 6 cases temporally related to gadodiamide injection (omniscan). *Invest Radiol* 2007;42(2):139–145.
57. Lim YL, Lee HY, Low SC, Chan LP, Goh NS, Pang SM. Possible role of gadolinium in nephrogenic systemic fibrosis: report of two cases and review of the literature. *Clin Exp Dermatol* 2007;32(4):353–358.
58. Matsumoto Y, Mitsuhashi Y, Monma F, et al. Nephrogenic systemic fibrosis: a case report and review on Japanese patients. *J Dermatol* 2012;39(5):449–453.
59. Naylor E, Hu S, Robinson-Bostom L. Nephrogenic systemic fibrosis with septal panniculitis mimicking erythema nodosum. *J Am Acad Dermatol* 2008;58(1):149–150.
60. Panesar M, Banerjee S, Barone GW. Clinical improvement of nephrogenic systemic fibrosis after kidney transplantation. *Clin Transplant* 2008;22(6):803–808.
61. Pryor JG, Poggioli G, Galaria N, et al. Nephrogenic systemic fibrosis: a clinicopathologic study of six cases. *J Am Acad Dermatol* 2007;57(1):105–111.
62. Richmond H, Zwerner J, Kim Y, Fiorentino D. Nephrogenic systemic fibrosis: relationship to gadolinium and response to photopheresis. *Arch Dermatol* 2007;143(8):1025–1030.
63. Sausseureau E, Lacroix C, Cattaneo A, Mahieu L, Goulle JP. Hair and fingernail gadolinium ICP-MS contents in an overdose case associated with nephrogenic systemic fibrosis. *Forensic Sci Int* 2008;176(1):54–57.
64. Swartz RD, Crofford LJ, Phan SH, Ike RW, Su LD. Nephrogenic fibrosing dermopathy: a novel cutaneous fibrosing disorder in patients with renal failure. *Am J Med* 2003;114(7):563–572.
65. Todd DJ, Kagan A, Chibnik LB, Kay J. Cutaneous changes of nephrogenic systemic fibrosis: predictor of early mortality and association with gadolinium exposure. *Arthritis Rheum* 2007;56(10):3433–3441.

66. Tsai CW, Chao CC, Wu VC, Hsiao CH, Chen YM. Nephrogenic fibrosing dermopathy in a peritoneal dialysis patient. *Kidney Int* 2007;72(10):1294.
67. Weenig RH, Gibson LE, el-Azhary R. The role of the hospital dermatologist in the diagnosis and treatment of calciphylaxis and nephrogenic systemic fibrosis. *Semin Cutan Med Surg* 2007;26(3):163–167.
68. Weiss AS, Lucia MS, Teitelbaum I. A case of nephrogenic fibrosing dermopathy/nephrogenic systemic fibrosis. *Nat Clin Pract Nephrol* 2007;3(2):111–115.
69. Yerram P, Saab G, Karuparthi PR, Hayden MR, Khanna R. Nephrogenic systemic fibrosis: a mysterious disease in patients with renal failure—role of gadolinium-based contrast media in causation and the beneficial effect of intravenous sodium thiosulfate. *Clin J Am Soc Nephrol* 2007;2(2):258–263.
70. Othersen JB, Maize JC, Woolson RF, Budisavljevic MN. Nephrogenic systemic fibrosis after exposure to gadolinium in patients with renal failure. *Nephrol Dial Transplant* 2007;22(11):3179–3185.
71. Wahba IM, White K, Meyer M, Simpson EL. The case for ultraviolet light therapy in nephrogenic fibrosing dermopathy—report of two cases and review of the literature. *Nephrol Dial Transplant* 2007;22(2):631–636.
72. Aggarwal A, Froehlich AA, Essah P, Brinster N, High WA, Downs RW. Complications of nephrogenic systemic fibrosis following repeated exposure to gadolinium in a man with hypothyroidism: a case report. *J Med Case Reports* 2011;5(1):566.
73. Al Habeeb A, Partington S, Rosenthal D, Salama S. Skin thickening in a hemodialysis patient: a case of nephrogenic fibrosing dermopathy. *J Cutan Med Surg* 2009;13(2):110–114.
74. Aluma MS, Restrepo R, Gaviira M. Nephrogenic fibrosing dermopathy: first Colombian case. *Dermatol Online J* 2007;13(3):24.
75. Artunc F, Schanz S, Metzke D, Heyne N. Nephrogenic systemic fibrosis [in German]. *Dtsch Med Wochenschr* 2008;133(Suppl):F1.
76. Bainotti S, Rota E, Bertrero M, Tamburrini O, Balducci A, Formica M. Nephrogenic systemic fibrosis: the first Italian gadolinium-proven case. *Clin Nephrol* 2008;70(6):514–517.
77. Becker S, Walter S, Witzke O, Kreuter A, Kribben A, Mitchell A. Application of gadolinium-based contrast agents and prevalence of nephrogenic systemic fibrosis in a cohort of end-stage renal disease patients on hemodialysis. *Nephron Clin Pract* 2012;121(1–2):c91–c94.
78. Bhawan J, Swick BL, Koff AB, Stone MS. Sclerotic bodies in nephrogenic systemic fibrosis: a new histopathologic finding. *J Cutan Pathol* 2009;36(5):548–552.
79. Boyd AS, Sanyal S, Abraham JL. Tissue gadolinium deposition and fibrosis mimicking nephrogenic systemic fibrosis (NSF)—subclinical nephrogenic systemic fibrosis? *J Am Acad Dermatol* 2010;62(2):337–342.
80. Bremmer M, Deng A, Martin DB. Spontaneous eruptive keloid-like cutaneous lesions in a renal transplant patient: a form of nephrogenic systemic fibrosis? *J Dermatolog Treat* 2009;20(1):63–66.
81. Bridges MD, St Amant BS, McNeil RB, Cernigliaro JG, Dwyer JP, Fitzpatrick PM. High-dose gadodiamide for catheter angiography and CT in patients with varying degrees of renal insufficiency: Prevalence of subsequent nephrogenic systemic fibrosis and decline in renal function. *AJR Am J Roentgenol* 2009;192(6):1538–1543.
82. Cassis TB, Jackson JM, Sonnier GB, Callen JP. Nephrogenic fibrosing dermopathy in a patient with acute renal failure never requiring dialysis. *Int J Dermatol* 2006;45(1):56–59.
83. Chan KH, Tang WY, Hau KC, et al. Nephrogenic systemic fibrosis in a Chinese renal-transplant recipient. *Clin Exp Dermatol* 2009;34(2):244–246.
84. Chen W, Huang SL, Huang CS, et al. Nephrogenic systemic fibrosis in advanced chronic kidney disease: a single hospital's experience in Taiwan. *Eur J Dermatol* 2009;19(1):44–49.
85. Concha MR, Vera CK, Jara AC, Atabales FA, González SB. Nephrogenic fibrosing dermopathy. Report of two cases [in Spanish]. *Rev Med Chil* 2007;135(5):640–646.
86. Cuffy MC, Singh M, Formica R, et al. Renal transplantation for nephrogenic systemic fibrosis: a case report and review of the literature. *Nephrol Dial Transplant* 2011;26(3):1099–1101.
87. Daram SR, Cortese CM, Bastani B. Nephrogenic fibrosing dermopathy/nephrogenic systemic fibrosis: report of a new case with literature review. *Am J Kidney Dis* 2005;46(4):754–759.
88. Deng A, Martin DB, Spillane A, et al. Nephrogenic systemic fibrosis with a spectrum of clinical and histopathological presentation: a disorder of aberrant dermal remodeling. *J Cutan Pathol* 2010;37(2):204–210.
89. Dewan A, Zwerner J, Abraham JL, Boyd A, Zic J. Chronic, dusky, indurated plaques on the legs of a 31-year-old woman. *Clin Exp Dermatol* 2016;41(3):328–330.
90. Dhungel A, Lattupalli R, Topf J. Nephrogenic fibrosing dermopathy. *ScientificWorldJournal* 2008;8:164–165.
91. DiCarlo JB, Gupta EA, Solomon AR. A pediatric case of nephrogenic fibrosing dermopathy: improvement after combination therapy. *J Am Acad Dermatol* 2006;54(5):914–916.
92. Digby S, Macduff E, Blessing K, Holmes S. Nephrogenic systemic fibrosis: a histopathological study of eight cases of a recently described entity. *Histopathology* 2008;52(4):531–534.
93. Do JG, Kim YB, Lee DG, Hwang JH. A case of delayed onset nephrogenic systemic fibrosis after gadolinium based contrast injection. *Ann Rehabil Med* 2012;36(6):880–886.
94. Edgar E, Woltjer R, Whitham R, Gultekin SH, Watnick S, Cupler EJ. Nephrogenic systemic fibrosis presenting as myopathy: a case report with histopathologic correlation. *Neuromuscul Disord* 2010;20(6):411–413.
95. Firoz BF, Hunzeker CM, Soldano AC, Franks AG Jr. Nephrogenic fibrosing dermopathy. *Dermatol Online J* 2008;14(5):11.
96. Foss C, Smith JK, Ortiz L, Hanevold C, Davis L. Gadolinium-associated nephrogenic systemic fibrosis in a 9-year-old boy. *Pediatr Dermatol* 2009;26(5):579–582.
97. Freed L, Hill J, Gooch D. Nephrogenic systemic fibrosis in the podiatric patient. *J Am Podiatr Med Assoc* 2012;102(5):419–421.
98. Garovic VD, Helgen KE. Images in clinical medicine. Nephrogenic fibrosing dermopathy. *N Engl J Med* 2007;357(2):e2.
99. George DE, Lu R, George SJ, Hsu S. Nephrogenic fibrosing dermopathy: case report and review. *Dermatol Online J* 2006;12(3):7.
100. Gharacholou SM, Maleszewski JJ, Borlaug BA, et al. “Carcinoid-like” tricuspid valvulopathy associated with nephrogenic systemic fibrosis. *Echocardiography* 2011;28(3):E46–E49.
101. Gibson SE, Farver CF, Prayson RA. Multiorgan involvement in nephrogenic fibrosing dermopathy: an autopsy case and review of the literature. *Arch Pathol Lab Med* 2006;130(2):209–212.
102. Gilliet M, Cozzio A, Burg G, Nestle FO. Successful treatment of three cases of nephrogenic fibrosing dermopathy with extracorporeal photopheresis. *Br J Dermatol* 2005;152(3):531–536.
103. Gist RS, Miller DW, Warren T. A difficult airway in a patient with nephrogenic sclerosing fibrosis. *Anesth Analg* 2010;110(2):555–557.
104. Goddard DS, Magee CC, Lazar AJ, Miller DM. Nephrogenic fibrosing dermopathy with recurrence after allograft failure. *J Am Acad Dermatol* 2007;56(5 Suppl):S109–S111.
105. Grekin SJ, Holcomb MJ, Modi GM, Huttenbach YT, Poythress EL, Diwan AH. Lollipop lesions in nephrogenic systemic fibrosis mimicking a deep fungal infection. *J Cutan Pathol* 2012;39(11):981–984.
106. Gulati A, Harwood CA, Raftery M, Cerio R, Ashman N, Proby CA. Magnetic resonance imaging with gadolinium enhancement in renal failure: a need for caution. *Int J Dermatol* 2008;47(9):947–949.
107. Hauser C, Kaya G, Chizzolini C. Nephrogenic fibrosing dermopathy in a renal transplant recipient with tubulointerstitial nephritis and uveitis. *Dermatology* 2004;209(1):50–52.
108. He A, Kwatra SG, Zampella JG, Loss MJ. Nephrogenic systemic fibrosis: fibrotic plaques and contracture following exposure to gadolinium-based contrast media. *BMJ Case Rep* 2016;2016:bcr2016214927.
109. Heinz-Peer G, Neruda A, Watschinger B, et al. Prevalence of NSF following intravenous gadolinium-contrast media administration in dialysis patients with endstage renal disease. *Eur J Radiol* 2010;76(1):129–134.
110. Hershko K, Hull C, Etefagh L, et al. A variant of nephrogenic fibrosing dermopathy with osteoclast-like giant cells: a syndrome of dysregulated matrix remodeling? *J Cutan Pathol* 2004;31(3):262–265.
111. Holzem KE, Nardone B, Lomasney JW, et al. Superior vena cava obstruction associated with nephrogenic systemic fibrosis. *J Drugs Dermatol* 2014;13(5):615–618.
112. Hope TA, Herfkens RJ, Denianke KS, LeBoit PE, Hung YY, Weil E. Nephrogenic systemic fibrosis in patients with chronic kidney disease who received gadopentetate dimeglumine. *Invest Radiol* 2009;44(3):135–139.
113. Hoppe H, Spagnuolo S, Froehlich JM, et al. Retrospective analysis of patients for development of nephrogenic systemic fibrosis following conventional angiography using gadolinium-based contrast agents. *Eur Radiol* 2010;20(3):595–603.
114. Jain SM, Wesson S, Hassanein A, et al. Nephrogenic fibrosing dermopathy in pediatric patients. *Pediatr Nephrol* 2004;19(4):467–470.
115. Jan F, Mahboob H, Schwartz AB. Quiz page February 2008: A hemodialysis patient with thickened skin. Nephrogenic fibrosing dermopathy. *Am J Kidney Dis* 2008;51(2):A33–A34.
116. Jan F, Segal JM, Dyer J, LeBoit P, Siegfried E, Frieden IJ. Nephrogenic fibrosing dermopathy: two pediatric cases. *J Pediatr* 2003;143(5):678–681.
117. Kadiyala D, Roer DA, Perazella MA. Nephrogenic systemic fibrosis associated with gadoversetamide exposure: treatment with sodium thiosulfate. *Am J Kidney Dis* 2009;53(1):133–137.

118. Kartono F, Basile A, Roshdih B, Schwimer C, Shitabata PK. Findings of osseous sclerotic bodies: a unique sequence of cutaneous bone formation in nephrogenic systemic fibrosis. *J Cutan Pathol* 2011;38(3):286–289.
119. Kay J, Czárják L. Gadolinium and systemic fibrosis: guilt by association. *Ann Rheum Dis* 2010;69(11):1895–1897.
120. Kendrick-Jones JC, Voss DM, De Zoysa JR. Nephrogenic systemic fibrosis, in patients with end-stage kidney disease on dialysis, in the greater Auckland region, from 2000–2006. *Nephrology (Carlton)* 2011;16(2):243–248.
121. Khor LK, Tan KB, Loi HY, Lu SJ. Nephrogenic systemic fibrosis in a patient with renal failure demonstrating a “reverse superscan” on bone scintigraphy. *Clin Nucl Med* 2013;38(3):203–204.
122. Kintossou R, D’Incan M, Chauveau D, et al. Nephrogenic fibrosing dermatopathy treated with extracorporeal photopheresis: role of gadolinium? [in French]. *Ann Dermatol Venereol* 2007;134(8-9):667–671.
123. Knapp BA, Sepahpanah F. Nephrogenic systemic fibrosis in a patient with spinal cord injury: a unique case presentation. *PMR* 2010;2(12):1141–1144.
124. Koratala A, Bhatti V. Nephrogenic systemic fibrosis. *Clin Case Rep* 2017;5(7):1184–1185.
125. Koreishi AF, Nazarian RM, Saenz AJ, et al. Nephrogenic systemic fibrosis: a pathologic study of autopsy cases. *Arch Pathol Lab Med* 2009;133(12):1943–1948.
126. Kreuter A, Gambichler T, Weiner SM, Schieren G. Limited effects of UV-A1 phototherapy in 3 patients with nephrogenic systemic fibrosis. *Arch Dermatol* 2008;144(11):1527–1529.
127. Kroshinsky D, Kay J, Nazarian RM. Case records of the Massachusetts General Hospital. Case 37-2009. A 46-year-old woman with chronic renal failure, leg swelling, and skin changes. *N Engl J Med* 2009;361(22):2166–2176.
128. Krous HF, Breisch E, Chadwick AE, Pinckney L, Malicki DM, Benador N. Nephrogenic systemic fibrosis with multiorgan involvement in a teenage male after lymphoma, Ewing’s sarcoma, end-stage renal disease, and hemodialysis. *Pediatr Dev Pathol* 2007;10(5):395–402.
129. Larson KN, Gagnon AL, Darling MD, Patterson JW, Cropley TG. Nephrogenic Systemic Fibrosis Manifesting a Decade After Exposure to Gadolinium. *JAMA Dermatol* 2015;151(10):1117–1120.
130. Levine JM, Taylor RA, Elman LB, et al. Involvement of skeletal muscle in dialysis-associated systemic fibrosis (nephrogenic fibrosing dermatopathy). *Muscle Nerve* 2004;30(5):569–577.
131. Lu CF, Hsiao CH, Tjiu JW. Nephrogenic systemic fibrosis developed after recovery from acute renal failure: gadolinium as a possible aetiological factor. *J Eur Acad Dermatol Venereol* 2009;23(3):339–340.
132. Maloo M, Abt P, Kashyap R, et al. Nephrogenic systemic fibrosis among liver transplant recipients: a single institution experience and topic update. *Am J Transplant* 2006;6(9):2212–2217.
133. Martin DR, Krishnamoorthy SK, Kalb B, et al. Decreased incidence of NSF in patients on dialysis after changing gadolinium contrast-enhanced MRI protocols. *J Magn Reson Imaging* 2010;31(2):440–446.
134. Nagai Y, Hasegawa M, Shinmi K, et al. Nephrogenic systemic fibrosis with multiple calcification and osseous metaplasia. *Acta Derm Venereol* 2008;88(6):597–600.
135. Nakai K, Takeda K, Kimura H, Miura S, Maeda A. Nephrogenic systemic fibrosis in a patient on long-term hemodialysis. *Clin Nephrol* 2009;71(2):217–220.
136. Nardone B, Saddleton E, Laumann AE, et al. Pediatric nephrogenic systemic fibrosis is rarely reported: a RADAR report. *Pediatr Radiol* 2014;44(2):173–180.
137. Nguyen CV, Boyle AM, Lee RA. Perforating osteoma cutis in the setting of longstanding nephrogenic systemic fibrosis. *Int J Dermatol* 2015;54(5):571–572.
138. Nowack R, Wachtler P. Scleroderma-like syndrome triggered by gadolinium. *Nephrol Dial Transplant* 2006;21(11):3344.
139. Ozkur E, Kvanç Altunay I, Erdem Y, Özçelik G, Tuncel D. Nephrogenic systemic fibrosis: in a child with primary hyperoxaluria. *Clin Exp Dermatol* 2019;44(1):70–72.
140. Pao VY, Chang S, Shoback DM, Bikle DD. Hypercalcemia and overexpression of CYP27B1 in a patient with nephrogenic systemic fibrosis: clinical vignette and literature review. *J Bone Miner Res* 2009;24(6):1135–1139.
141. Perez-Rodriguez J, Lai S, Ehsht BD, Fine DM, Bluemke DA. Nephrogenic systemic fibrosis: incidence, associations, and effect of risk factor assessment—report of 33 cases. *Radiology* 2009;250(2):371–377.
142. Plamondon I, Samson C, Watters AK, et al. Nephrogenic systemic fibrosis: more hard times for renal failure patients [in French]. *Nephrol Ther* 2007;3(4):152–156.
143. Provenzale JM. Nephrogenic systemic fibrosis: some considerations on the debate regarding its cause. *AJR Am J Roentgenol* 2008;191(6):1867–1869.
144. Raciti P, Sokoloff A, Husain S, Horst BA. Patient with a history of indurated plaques and renal disease. *Int J Dermatol* 2014;53(9):1070–1072.
145. Reddy IS, Somani VK, Swarnalata G, Maitra S. Nephrogenic systemic fibrosis following hair-dye ingestion induced acute renal failure. *Indian J Dermatol Venereol Leprol* 2010;76(4):400–403.
146. Rodríguez Jornet A, Andreu Navarro FJ, Orellana Fernández R, Ibeas López J, Fortuño Andrés JR. Gadolinium-induced systemic fibrosis in advanced kidney failure [in Spanish]. *Nefrología* 2009;29(4):358–363.
147. Ruiz-Genao DP, Pascual-Lopez MP, Fraga S, Aragüés M, García-Diez A. Osseous metaplasia in the setting of nephrogenic fibrosing dermatopathy. *J Cutan Pathol* 2005;32(2):172–175.
148. Saenz A, Mandal R, Kradin R, Hedley-Whyte ET. Nephrogenic fibrosing dermatopathy with involvement of the dura mater. *Virchows Arch* 2006;449(3):389–391.
149. Sanchez-Ross M, Snyder R, Colome-Grimmer MI, Blumberg M, Huttenbach Y, Raimer S. Nephrogenic fibrosing dermatopathy in a patient with systemic lupus erythematosus and acute lupus nephritis. *Pediatr Dermatol* 2007;24(5):E36–E39.
150. Sanyal S, Marckmann P, Scherer S, Abraham JL. Multiorgan gadolinium (Gd) deposition and fibrosis in a patient with nephrogenic systemic fibrosis—an autopsy-based review. *Nephrol Dial Transplant* 2011;26(11):3616–3626.
151. Schroeder JA, Weingart C, Coras B, et al. Ultrastructural evidence of dermal gadolinium deposits in a patient with nephrogenic systemic fibrosis and end-stage renal disease. *Clin J Am Soc Nephrol* 2008;3(4):968–975.
152. Sego S. Nephrogenic fibrosing dermatopathy: a case study. *Nephrol Nurs J* 2008;35(1):67–68.
153. Shabana WM, Cohan RH, Ellis JH, et al. Nephrogenic systemic fibrosis: a report of 29 cases. *AJR Am J Roentgenol* 2008;190(3):736–741.
154. Sharma J, Mongia A, Schoenaman M, Chang S, D’Angelo A, Rao M. Nephrogenic fibrosing dermatopathy, cardiac calcification and pulmonary hypertension in an adolescent on chronic hemodialysis. *Indian J Nephrol* 2008;18(2):70–73.
155. Shin K, Granter SR, Coblyn JS, Gupta S. Progressive arm and leg stiffness in a patient with chronic renal impairment. *Nat Clin Pract Rheumatol* 2008;4(10):557–562.
156. Singh M, Davenport A, Clatworthy I, et al. A follow-up of four cases of nephrogenic systemic fibrosis: is gadolinium the specific trigger? *Br J Dermatol* 2008;158(6):1358–1362.
157. So K, Macquillan GC, Adams LA, et al. Malignant fibrous histiocytoma complicating nephrogenic systemic fibrosis post liver transplantation. *Intern Med J* 2009;39(9):613–617.
158. Song J, Volkov S, Shea CR, et al. Nephrogenic systemic fibrosis associated with stromal and vascular calcification, report of two cases. *J Cutan Pathol* 2009;36(Suppl 1):31–34.
159. Streams BN, Liu V, Liégeois N, Moschella SM. Clinical and pathologic features of nephrogenic fibrosing dermatopathy: a report of two cases. *J Am Acad Dermatol* 2003;48(1):42–47.
160. Su HS, Nazarian RM, Scott JA. Case report. Appearance of nephrogenic fibrosing dermatopathy on a bone scan. *Br J Radiol* 2009;82(974):e35–e36.
161. Swaminathan S, Arbiser JL, Hiatt KM, et al. Rapid improvement of nephrogenic systemic fibrosis with rapamycin therapy: possible role of phospho-70-ribosomal-S6 kinase. *J Am Acad Dermatol* 2010;62(2):343–345.
162. Tammara A, Narcisi A, Tuchinda P, Sina B. Nephrogenic systemic fibrosis following gadolinium administration. *Cutis* 2015;96(1):E23–E25.
163. Tan AW, Tan SH, Lian TY, Ng SK. A case of nephrogenic fibrosing dermatopathy. *Ann Acad Med Singapore* 2004;33(4):527–529.
164. Thomson LK, Thomson PC, Kingsmore DB, et al. Diagnosing nephrogenic systemic fibrosis in the post-FDA restriction era. *J Magn Reson Imaging* 2015;41(5):1268–1271.
165. Tushima Y, Kanal E, Thomsen HS. Nephrogenic systemic fibrosis: risk factors suggested from Japanese published cases. *Br J Radiol* 2010;83(991):590–595.
166. Ustuner P, Kose OK, Gulec AT, Ozen O. A moderate response to plasmapheresis in nephrogenic systemic fibrosis. *Clin Pract* 2011;1(4):e124.
167. Varela CU, Prieto-Rayó JC. Causal relationship between the use of gadolinium based contrast media and nephrogenic systemic fibrosis [in Spanish]. *Rev Med Chil* 2014;142(12):1565–1574.
168. Vollnberg B, Knebel F, Böhm M, Brockmöller S, Dewey M. A difficult nasogastric tube in a patient with nephrogenic systemic fibrosis. *Rof* 2013;185(9):877–878.
169. Weigle JP, Broome DR. Nephrogenic systemic fibrosis: chronic imaging findings and review of the medical literature. *Skeletal Radiol* 2008;37(5):457–464.
170. Wiedemeyer K, Kutzner H, Abraham JL, et al. The evolution of osseous metaplasia in localized cutaneous nephrogenic systemic fibrosis: a case report. *Am J Dermatopathol* 2009;31(7):674–681.

171. Wilford C, Fine JD, Boyd AS, Sanyal S, Abraham JL, Kantrow SM. Nephrogenic systemic fibrosis: report of an additional case with granulomatous inflammation. *Am J Dermatopathol* 2010;32(1):71–75.
172. Wilson J, Gleghorn K, Seigel Q, Kelly B. Nephrogenic systemic fibrosis: A 15-year retrospective study at a single tertiary care center. *J Am Acad Dermatol* 2017;77(2):235–240.
173. Yoldez H, Ahlem B, Abderrahim E, Faten Z, Soumaya R. Nephrogenic fibrosing dermatosis: From clinic to microscopy [in French]. *Nephrol Ther* 2018;14(1):47–49.
174. Zelasko S, Hollingshead M, Castillo M, Bouldin TW. CT and MR imaging of progressive dural involvement by nephrogenic systemic fibrosis. *AJNR Am J Neuroradiol* 2008;29(10):1880–1882.
175. Zhang R, Rose WN. Photopheresis Provides Significant Long-Lasting Benefit in Nephrogenic Systemic Fibrosis. *Case Rep Dermatol Med* 2017;2017:3240287.
176. Koo TH, Lee DH, Baek HK, et al. A case of nephrogenic systemic fibrosis following gadolinium exposure in a peritoneal dialysis patient [in Korean]. *Korean J Med* 2010;78(4):507–511.
177. Hong MH, Koo HM, Choi J, et al. A case of nephrogenic systemic fibrosis after gadolinium-based contrast agent injection [in Korean]. *Korean J Med* 2010;78(1):127–131.
178. Berk DR, Miller A, Scarlett D, Wippold FJ 2nd, Bayliss SJ, Lu D. Osseous metaplasia late in the course of nephrogenic systemic fibrosis. *Dermatol Online J* 2010;16(8):3.
179. Mitkov M, Fosko S, Sluzevich J. Nephrogenic systemic fibrosis complicated by extensive dystrophic calcification. *Journal of the American Academy of Dermatology*. 2018;79:AB203.
180. Cirillo M, Anastasio P, De Santo NG. Relationship of gender, age, and body mass index to errors in predicted kidney function. *Nephrol Dial Transplant* 2005;20(9):1791–1798.
181. American College of Radiology. *ACR Manual on Contrast Media*. Reston, Va: American College of Radiology, 2018.
182. Fananapazir G, Bashir MR, Corwin MT, Lamba R, Vu CT, Troppmann C. Comparison of ferumoxytol-enhanced MRA with conventional angiography for assessment of severity of transplant renal artery stenosis. *J Magn Reson Imaging* 2017;45(3):779–785.
183. Murphy DJ, Aghayev A, Steigner ML. Vascular CT and MRI: a practical guide to imaging protocols. *Insights Imaging* 2018;9(2):215–236.
184. Galgano SJ, Lockhart ME, Fananapazir G, Sanyal R. Optimizing renal transplant Doppler ultrasound. *Abdom Radiol (NY)* 2018;43(10):2564–2573.
185. Broome DR. Nephrogenic systemic fibrosis associated with gadolinium based contrast agents: a summary of the medical literature reporting. *Eur J Radiol* 2008;66(2):230–234.
186. Behzadi AH, Zhao Y, Farooq Z, Prince MR. Immediate Allergic Reactions to Gadolinium-based Contrast Agents: A Systematic Review and Meta-Analysis. *Radiology* 2018;286(2):471–482.