

Ability of Oblique Foot Radiographs to Detect Erosions in Early Arthritis: Results in the ESPOIR Cohort

VALERIE DEVAUCHELLE-PENSEC,¹ THIERRY JOSSEAUME,¹ ISABELLE SAMJEE,¹
MAXIME DOUGADOS,² BERNARD COMBE,³ AND ALAIN SARAUX¹

Objective. To assess the usefulness of using oblique foot radiographs in addition to posteroanterior radiographs of the hands and feet for detecting erosions in patients with recent-onset arthritis.

Methods. We included 813 patients from the prospective French ESPOIR cohort with arthritis of <6 months' duration and ≥2 swollen joints. Baseline standardized posteroanterior radiographs of the hands and feet and oblique radiographs of the feet were assessed by 2 blinded readers for erosions typical for rheumatoid arthritis (ETRA) and the Sharp score as modified by van der Heijde.

Results. A total of 715 complete sets were available. Mean ± SD total Sharp scores were 3.6 ± 6.6, 2.5 ± 6.3, and 1.8 ± 5 for the hand and wrist, foot, and oblique foot, respectively. ETRA were visible in 160 (22.4%) of 715 patients (95% confidence interval [95% CI] 19.4–25.6). They were seen on hand radiographs in 86 (53.7%) of 160 patients (95% CI 45.7–61.6), on posteroanterior foot radiographs in 91 (56.9%) of 160 patients (95% CI 48.8–64.6), and on oblique foot radiographs in 84 (52.5%) of 160 patients (95% CI 44.5–60.4). ETRA were visible at the feet, but not at the hands, in 74 (46%) of 160 patients (95% CI 38.4–54.3), among whom 22 (30%) had erosions only on the posteroanterior view, 16 (21%) only on the oblique view, and 36 (48.6%) on both.

Conclusion. ETRA were found in 22.4% of patients. Adding an oblique foot radiograph identified 16 (10%) of 160 additional patients (95% CI 6–16), compared with 27.5% and 13.8% identified by adding posteroanterior radiographs of the hands and feet, respectively.

INTRODUCTION

Diagnosing early rheumatoid arthritis (RA) is a challenging task that rests on a set of converging data from physical examinations, radiographs, and multiple laboratory tests. The 1987 American College of Rheumatology (ACR; formerly the American Rheumatism Association) classifica-

tion criteria for RA (1) are used routinely by clinicians for classifying patients with arthritis. The radiographic criterion (item 7) is based on examination of the hands and wrists, but does not require foot radiographs. However, the high rate of radiographic foot lesions in patients with early RA is well documented, and several studies (2–6) suggest that including foot radiographs in the 1987 ACR criteria may significantly improve the sensitivity of item 7.

The numerous scoring methods for radiographic abnormalities include global assessments per patient (i.e., the Steinbrocker staging system), global assessments per joint (i.e., the Larsen score), and separate evaluations of erosions and joint space narrowing (JSN; i.e., Sharp score) (7,8). Although most of these tools were designed for the hand, scoring methods for radiographic foot lesions have been developed. Therefore, the 1971 Sharp score for the hand was modified in 1985 to include the foot.

Radiographic abnormalities included in the 1987 ACR criteria for RA and in radiographic scores consist of erosions, bony decalcification, and JSN. However, our group and others demonstrated that bony decalcification was unreliable, and that erosions were the abnormality most strongly associated with RA (3,9,10).

In everyday practice, investigations obtained in patients

An unrestricted grant from Merck, Sharp, & Dohme was allocated for the first 5 years of the study. Two additional grants from INSERM were obtained to support part of the biologic database. The French Society of Rheumatology, Abbott, Amgen, and Wyeth also supported the ESPOIR cohort study.

¹Valerie Devauchelle-Pensec, MD, PhD, Thierry Josseaume, MD, Isabelle Samjee, MD, Alain Saraux, MD, PhD: Brest Teaching Hospitals, BP 814, Brest Cedex, France; ²Maxime Dougados, MD, PhD: Cochin Teaching Hospital, Paris, France; ³Bernard Combe, MD, PhD: Lapeyronie Teaching Hospital, University I Montpellier, Montpellier Cedex, France.

Address correspondence to Alain Saraux, MD, PhD, Rheumatology Unit, Hôpital de la Cavale Blanche, BP 824, F 29609 Brest Cedex, France. E-mail: alain.saraux@chu-brest.fr.

Submitted for publication December 26, 2007; accepted in revised form July 25, 2008.

with recent-onset arthritis usually include posteroanterior radiographs of the hands and wrists, and both posteroanterior and oblique radiographs of the feet. We reported previously that adding posteroanterior foot radiographs to hand radiographs significantly improved the detection of radiographic erosions typical for RA (ETRA) (11). Whether adding oblique foot radiographs also improves ETRA detection in patients with recent-onset arthritis has not been evaluated.

The primary objective of this study was to determine whether adding oblique foot radiographs to posteroanterior hand and foot radiographs improved the detection of ETRA in a cohort of patients with recent-onset arthritis. In addition, we determined which sites were most commonly affected with erosions at the feet.

PATIENTS AND METHODS

Study population. The French Society for Rheumatology established a nationwide, longitudinal, prospective cohort known as the ESPOIR cohort (12) to enable investigations of the diagnosis, outcome markers, epidemiology, pathogenesis, and medico-economics of early arthritis and RA. The cohort was constituted by having general practitioners and rheumatologists refer patients with early arthritis to hospitals participating in the ESPOIR cohort project. Patients were eligible for inclusion in the cohort if they had a definitive or probable clinical diagnosis of RA or a diagnosis of undifferentiated arthritis with a potential for progressing to RA. Patients were included if they met the following criteria: age >18 years and <70 years, swelling of ≥ 2 joints for 6 weeks, symptom duration of <6 months, and no prior treatment with disease-modifying antirheumatic drugs or glucocorticoids; however, the use of glucocorticoids for no longer than 2 weeks with a mean dosage of no greater than 20 mg/day and discontinuation at least 2 weeks earlier did not prevent study inclusion. Patients who were included in the cohort were evaluated every 6 months for 2 years and then once a year for at least 10 years.

The study was approved by the Institutional Review Board of the Montpellier University Hospital, which was the coordinating center for this nationwide study. Prior to inclusion, all patients gave their written informed consent to participate in this prospective followup study.

Study design. The baseline assessment included a standardized interview, a general physical examination, laboratory tests (standard blood and urine parameters; enzyme-linked immunosorbent assay for IgM, IgG, and IgA rheumatoid factors; tests for antinflaggrin and antinuclear antibodies; and HLA-DR phenotype determination), and radiographs of the chest, pelvis, hands, and feet in the posteroanterior view, and feet in the oblique view. Each patient was asked to undergo an evaluation by an office-based rheumatologist every 6 months for 2 years and once a year thereafter. These evaluations were free of charge.

Radiographic evaluation. For each patient, a set of radiographs was obtained at baseline and then every 6 months at each evaluation by the rheumatologist. The




Figure 1. Medial oblique forefoot radiograph. The lateral part of the foot is angled at 45° using a pad.

radiographs included posteroanterior views of the hands and wrists and of the feet, as well as oblique views of the feet. They were read by the patient's office-based rheumatologist and then sent to the coordinating center. For this study, all baseline radiographs were examined independently by 2 radiologists (IS and TJ) who had no information about the patients. The readers followed a standardized procedure for each radiograph to assess the following points: 1) the technical quality of the radiographs (including joint positioning and exposure, each of which was rated from 1–3, where 1 = excellent, 2 = moderate, and 3 = poor), and 2) the number of erosions and severity of JSN, scored according to the Sharp score as modified by van der Heijde for the hands and feet on posteroanterior views (13,14). The location of each abnormality was recorded. The readers indicated whether the erosions were typical of RA. Disagreements between the 2 readers were resolved by a third reader (VD-P).

Oblique radiographs of each foot were obtained with the patient seated, the sole of the foot placed on the film, and the central beam directed vertically toward the middle of the forefoot. A pad was used to lift the lateral edge of the foot at a 45° angle. With this method, the metatarsophalangeal (MTP) joints are seen without superimpositions of adjacent bone structures (Figure 1). Oblique views were considered to be of good quality when the fifth MTP joint was clearly visible and all the MTP joints were free of superimpositions. Oblique views were scored using the

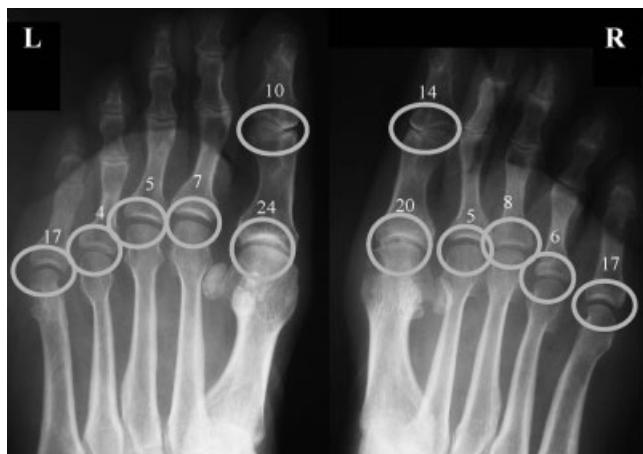

Figure 2. Localizations of foot joint abnormalities on oblique view. The circles represent the sites evaluated for radiographic abnormalities. Each number represents the number of patients with typical erosions at each site.

system developed by van der Heijde for posteroanterior views of the feet (15) to assess the 10 MTP joints and the 2 interphalangeal (IP) joints of the great toes. For both feet, the erosion score could range from 0–120, and the JSN score from 0–48. ETRA were evaluated by both readers (Figure 2), and disagreements between the 2 readers were resolved by a third reader (VD-P).

Statistical analysis. Data were inputted and then analyzed using the Statistical Package for the Social Sciences, version 15.0 (SPSS, Chicago, IL). For sample size calculation, we relied on evidence that 50% of patients with early arthritis have RA, that 20% have erosions on the posteroanterior radiographs of the hands and wrists and/or feet, and that 10% have erosions on the posteroanterior radiographs of the feet (11). To detect an at least 4% improvement in the number of patients with identified erosions obtained by adding oblique foot radiographs, with a confidence interval of $\pm 2\%$ and with the alpha risk set at 5%, 700 patients, each with a full set of radiographs, were required.

The kappa coefficient was determined to evaluate the reliability of categorical variables, and the intraobserver and interobserver correlation coefficients were determined to evaluate the reliability of quantitative variables. Interobserver and intraobserver variabilities were assessed by computing the intraclass correlation coefficients for repeated readings of 60 pairs of hand radiographs. For the evaluation of intraobserver variability, the 2 observers read the same radiographs twice at an interval of 1–3 months, using a blinded procedure. The mean \pm SD Sharp scores for eroded patients were evaluated by both readers. For clinical data, analyses were performed on the whole cohort population.

The data were analyzed using the chi-square test (or Fisher's exact test where appropriate) and the Mann-Whitney U test. *P* values less than 0.05 were considered significant.

Table 1. Baseline features of patients in the ESPOIR cohort (n = 813)*

| Feature | Value |
|-----------------------------|-----------------|
| No. females/males | 624/189 |
| Age, years | 48 \pm 12.5 |
| Disease duration, days | 103 \pm 52 |
| Swollen joint count | 7.2 \pm 5.4 |
| Tender joint count | 8.4 \pm 7 |
| DAS28 | 5.1 \pm 1.3 |
| ESR, mm/hour | 29.5 \pm 24.5 |
| Abnormal CRP level, no. (%) | 316 (38.9) |
| IgM RF, no. (%) | 359 (44.2) |
| Anti-CCP, no. (%) | 315 (38.7) |
| Meets ACR criteria, no. (%) | 578 (71.3) |

* Values are the mean \pm SD unless otherwise indicated. DAS28 = Disease Activity Score for 28 joints; ESR = erythrocyte sedimentation rate; CRP = C-reactive protein; RF = rheumatoid factor; anti-CCP = anti-cyclic citrullinated peptide; ACR = American College of Rheumatology.

RESULTS

Study population. A total of 813 patients were included, 624 (77%) of whom were women (Table 1). The mean \pm SD time from symptom onset to rheumatologist referral was 75 \pm 77 days. HLA-DRB1*01 or *04 were present in 56.67% of patients.

Radiographs were obtained for 795 patients, 722 of whom had oblique foot radiographs. The full set of 3 radiographs was available for 715 patients, who form the basis for this study. No differences were detected between these 715 patients and the entire cohort of 813 patients. Evaluation of the ACR criteria was available for 707 patients. The tender or swollen hand joint count, tender foot joint count, and foot squeeze test result was available for 709 patients.

Validity of the method. *Technical quality of the radiographs.* The exposure criterion was rated excellent for 96.5% of radiographs, moderate for 2.5%, and poor for 1%. The joint positioning criterion was rated excellent for 98% of radiographs, moderate for 1%, and poor for 1%.

Radiograph assessment by the blinded readers. For 1 of the 2 readers, the intraobserver correlation coefficients were 0.98 for the total Sharp score, 0.99 for the Sharp JSN score, and 0.86 for the Sharp erosion score; corresponding values for the other reader were 0.98, 0.98, and 0.81, respectively. Interobserver correlations were 0.98, 0.98, and 0.80 for the 3 scores, respectively.

Radiographic findings at baseline. At baseline, 160 (22.4%) of 715 patients (95% confidence interval [95% CI] 19.4–25.6) had at least 1 ETRA on at least 1 radiographic view, 12% (86 of 715) on the radiograph of the hands and wrists, 13% (91 of 715) on the posteroanterior radiograph of the feet, and 11.7% (84 of 715) on the oblique radiographs of the feet (Table 2).

The mean \pm SD total, erosion, and JSN Sharp scores were 3.6 \pm 6.6, 1.2 \pm 3, and 2.4 \pm 5.1, respectively, at the hands and wrists; 2.5 \pm 6.3, 1.2 \pm 4.4, and 1.3 \pm 3,

Table 2. Numbers of patients with erosions at the feet among patients with erosions at the hands and wrists (n = 86), at baseline

| Foot, posteroanterior | Foot, oblique | |
|-----------------------|----------------------|-------------------|
| | No erosions (n = 54) | Erosions (n = 32) |
| No erosions (n = 53) | 44 | 9 |
| Erosions (n = 33) | 10 | 23 |

respectively, on the posteroanterior radiographs of the feet; and 1.8 ± 5 , 0.91 ± 3.4 , and 0.9 ± 2.5 , respectively, on the oblique radiographs of the feet.

Ability of each view to detect erosions. *Erosion detection on posteroanterior radiographs of the hands and wrists.* Of the 160 patients with ETRA, 86 (53.7%; 95% CI 45.7–61.6) had erosions at the hands and wrists. Of these 86 patients, 42 also had ETRA at the feet, whereas 44 had ETRA only at the hands and wrists (Table 2). Therefore, omitting the posteroanterior radiograph of the hands and wrists would have missed 44 (27.5%) of 160 (95% CI 20.9–35.2) of the patients who had ETRA.

Erosion detection on both posteroanterior and oblique radiographs of the feet. Of the 160 patients with ETRA, 116 (73%) had ETRA on 1 or both views of the feet. Of these 160 patients, 74 (46%; 95% CI 38.4–54.3) had foot ETRA (on 1 or both views) without hand erosions (Table 3).

Erosion detection on posteroanterior radiographs of the feet. Of the 91 (56.9%) of 160 (95% CI 48.8–64.6) patients with foot ETRA on the posteroanterior view, 32 had no foot ETRA on the oblique view. Of the 74 patients with foot ETRA but no hand ETRA, 22 had ETRA on the posteroanterior foot radiograph but not on the oblique foot radiograph. Therefore, omitting the posteroanterior foot radiograph would have missed 22 (13.8%) of 160 (95% CI 9–20.3) of the patients with erosive disease.

Erosion detection on oblique radiographs of the feet. ETRA were seen on oblique foot radiographs in 84 (52.5%) of 160 patients (95% CI 44.5–60.4). Sixteen of them had no erosions on the posteroanterior radiographs of the hands or feet. Therefore, omitting the oblique foot views would have missed 16 (10%) of 160 (95% CI 6–16) of the patients who had ETRA.

Localization of foot abnormalities on the oblique views.

The 2 readers examined the 722 sets of oblique foot radiographs to determine the numbers of patients with erosions

Table 3. Numbers of patients with erosions at the feet among patients without erosions at the hands and wrists (n = 629), at baseline

| Foot, posteroanterior | Foot, oblique | |
|-----------------------|-----------------------|-------------------|
| | No erosions (n = 577) | Erosions (n = 52) |
| No erosions (n = 571) | 555 | 16 |
| Erosions (n = 58) | 22 | 36 |

at the first IP joint and each of the MTP joints of each foot. Both readers found that the most commonly affected joints were the first IP joint and the first and fifth MTP joints (Figure 2). The lesions were considered typical for RA, and no evidence of osteoarthritis was found. The distribution of the erosions was not different between the right and left feet (Figure 2). The Sharp scores indicated that the most severely affected joints were, in decreasing order, the first MTP joint, the fifth MTP joint, and the first IP joint (Table 4), where the mean \pm SD total Sharp scores were 0.24 ± 0.08 , 0.20 ± 0.097 , and 0.17 ± 0.065 , respectively. The Sharp erosion scores were also higher in the same joints.

Detection of erosions on oblique foot radiographs according to baseline clinical features. Erosions on oblique foot radiographs were reported at baseline in 83 patients (Table 5). They were not significantly associated with the tender joint count at the feet, nor to swollen hand joint, tender hand joint, or the presence of ACR criteria at baseline. In contrast, they were significantly associated with a positive squeeze test at the feet ($P = 0.03$).

DISCUSSION

Conventional radiography is still regarded as the reference imaging technique for the diagnosis of RA. Nevertheless, technical factors can impair the quality and reproducibility of conventional radiographs. In our cohort, the strictly standardized technical procedure led to good quality radiographs with little information lost. However, over- or underexposure can hinder the evaluation of structural changes, most notably the detection of erosions, which are strongly associated with RA. Since 1990, other imaging techniques have been developed, but remain incompletely evaluated regarding their ability to detect erosions or JSN. Digitized or high-resolution radiographs may be more sensitive for detecting erosions compared with conventional radiographs (16), but also raise specific quality problems due to the effects of scale reduction (17).

Joint destruction due to RA can be quantified by determining standardized scores. The severity of joint destruction correlates well with functional disability over time. The ACR classification criteria include typical radiographic changes on hand and wrist radiographs, but do not require foot radiographs. Similarly, the initial versions of the Sharp score and the Larsen score were based only on hand and wrist radiographs (13,18). However, several studies subsequently established that erosions in the MTP joints often antedated erosions at the hands and wrists in patients with early RA (2,19–22). Obtaining radiographs of both the hands and feet as part of the evaluation of recent arthritis is now strongly recommended (23,24). The radiographic scores were therefore modified for use at the feet (25). Studies of magnetic resonance imaging findings also showed evidence of forefoot arthritis in patients without hand abnormalities, and the score initially designed for the hand was therefore adapted to the foot (26,27). At the feet, the tarsal bones are not included in scoring systems because they are difficult to visualize. However, the MTP joints are frequently affected and may be visible on the posteroanterior view. Given that cortical disruption is a defining characteristic of erosions, using additional views

Table 4. Mean \pm SD total Sharp scores on oblique foot radiographs for each reader on the right and left sides*

| | Right side | | Left side | |
|------------------|----------------|----------------|----------------|----------------|
| | Reader 1 | Reader 2 | Reader 1 | Reader 2 |
| First IP joint | 0.2 \pm 0.4 | 0.14 \pm 0.3 | 0.1 \pm 0.3 | 0.11 \pm 0.3 |
| First MTP joint | 0.2 \pm 0.4 | 0.26 \pm 0.5 | 0.3 \pm 0.4 | 0.33 \pm 0.5 |
| Second MTP joint | 0.05 \pm 0.2 | 0.05 \pm 0.2 | 0.1 \pm 0.3 | 0.06 \pm 0.2 |
| Third MTP joint | 0.07 \pm 0.2 | 0.1 \pm 0.4 | 0.05 \pm 0.2 | 0.06 \pm 0.2 |
| Fourth MTP joint | 0.06 \pm 0.2 | 0.05 \pm 0.2 | 0.04 \pm 0.2 | 0.06 \pm 0.5 |
| Fifth MTP joint | 0.19 \pm 0.4 | 0.2 \pm 0.5 | 0.18 \pm 0.4 | 0.2 \pm 0.4 |

* IP = interphalangeal; MTP = metatarsophalangeal.

may improve the ability of radiographs to detect erosions. Several views (i.e., tangential, 45°, and 65°) have been evaluated at the hand (28,29), and these studies suggest an improvement in the detection of metacarpophalangeal erosions. In the same way, at the forefoot, oblique views facilitate the visualization of erosions at the IP and metacarpophalangeal joints. Each patient in the ESPOIR cohort routinely underwent a posteroanterior radiograph of the hands and wrists, a posteroanterior radiograph of the feet, and oblique radiographs of the feet. These radiographs showed erosions considered typical for RA by both readers in 160 (22%) patients. Of these 160 patients, 44 (27%) had erosions at the hands but not at the feet, whereas 58 (36%) had erosions on the posteroanterior foot radiographs but not at the hands. Nearly half of the patients with erosive disease had erosions only at the feet at baseline. Furthermore, 12% of all patients without hand erosions had foot erosions. Similarly, in other studies (2,3,19), 15–18% of patients with recent-onset RA had normal hand radiographs and abnormal foot radiographs, and 16–66% of joint erosions were located at the forefeet (4,6,19,22).

In a previous study, the most common sites of erosions using magnetic resonance imaging on the foot were the first IP joint and the first and fifth MTP joints (30). However, osteoarthritis may frequently affect the first MTP joint, inducing nonspecific radiographic erosions (31). In our cohort, the most common sites of erosions, which had

the highest total Sharp score and the highest Sharp erosion score on oblique radiographs of the forefeet, were also the first and fifth MTP joints and the first IP joint, without osteoarthritis.

The presence of erosions on the oblique foot radiographs was not correlated with the tender joint count, but correlated strongly with a positive squeeze test at the feet. One explanation might be the low reproducibility of tender and swollen joint counts at the feet. According to the difficulty of the physical examination of the feet, the squeeze test is probably more sensitive than the tender or swollen joint count for detecting inflammation of the forefoot.

The aim of our study was to assess the usefulness of oblique foot radiographs for detecting erosions. We found that 116 (73%) of 160 patients with erosive disease had foot ETRA visible on the posteroanterior view (91 [57%] of 160) and/or the oblique view (84 [53%] of 160). Seventy-four patients, i.e., 46% of patients with erosive disease, had no hand or wrist erosions. Of the 74 patients with ETRA at the feet only, 22 (i.e., 14% of all patients with erosive disease) had ETRA on the posteroanterior view only and 16 (i.e., 10% of all patients with erosive disease) had ETRA on the oblique view only. The presence of erosive disease is strongly associated with the diagnosis and prognosis of RA (9,32,33). Therefore, improving the sensitivity of the radiographic workup for detecting erosions is a key goal. Our findings suggest that adding oblique foot radiographs to posteroanterior radiographs of the hands and wrists and of the feet assists in establishing the early diagnosis of RA.

Table 5. Associations between the presence of erosions on the oblique view and patient characteristics at baseline*

| Patient characteristics | No erosions (n = 626) | Erosions (n = 83) | P |
|---|--------------------------|----------------------|------|
| ACR criteria (n = 509) | 443 (71) | 66 (79) | 0.1 |
| Tender hand joint (n = 671) | 594 (95) | 77 (93) | 0.16 |
| Swollen hand joint (n = 675) | 594 (95) | 81 (97) | 0.41 |
| Tender foot joint (n = 445) | 386 (62) | 59 (71) | 0.12 |
| Foot squeeze test positive on 1 or both sides (n = 408) | 351 (56) | 57 (70) | 0.03 |

* Values are the number (percentage). ACR = American College of Rheumatology.

ACKNOWLEDGMENTS

We thank the French rheumatologists for referring their patients to the ESPOIR cohort in the following rheumatology departments: Amiens (P. Fardellone), Bordeaux (T. Schaeferbecke), Brest (A. Sarau), Lille (R. M. Flipo), Montpellier (B. Combe, H. Cholvy-Nicolas), Paris-Bicêtre (X. Mariette, F. Desmoulins), Paris-Bichat (O. Meyer, G. Hayem), Paris-Cochin (M. Dougados), Paris-La Pitié (B. Fautrel, B. Banneville), Paris-St. Antoine (F. Berenbaum, S. Le Gars), Rouen (X. Le Loët, O. Vittecoq), Strasbourg (J. Sibilia), Toulouse (A. Cantagrel), and Tours (P. Goupille, S. Mammou). We are grateful to N. Rincheval for data management and expert monitoring, to D. Colin for radio-

graphic advice, and to S. Martin, who did all the central dosages of C-reactive protein, IgA and IgM rheumatoid factor, and anti-cyclic citrullinated peptide antibodies.

AUTHOR CONTRIBUTIONS

Dr. Saraux had full access to all of the data in the study and takes responsibility for the integrity of the data and the accuracy of the data analysis.

Study design. Dougados, Combe, Saraux.

Acquisition of data. Devauchelle-Pensec, Josseume, Samjee.

Analysis and interpretation of data. Devauchelle-Pensec, Dougados, Combe, Saraux.

Manuscript preparation. Devauchelle-Pensec, Dougados, Combe, Saraux.

Statistical analysis. Saraux.

ROLE OF THE STUDY SPONSOR

The investigators were in charge of all data collection, analysis, and writing of the manuscript without any constraints exerted from Merck, Sharp, & Dohme, Abbott, Amgen, or Wyeth.

REFERENCES

- Arnett FC, Edworthy SM, Bloch DA, McShane DJ, Fries JF, Cooper NS, et al. The American Rheumatism Association 1987 revised criteria for the classification of rheumatoid arthritis. *Arthritis Rheum* 1988;31:315–24.
- Thould AK, Simon G. Assessment of radiological changes in the hands and feet in rheumatoid arthritis: their correlation with prognosis. *Ann Rheum Dis* 1966;25:220–8.
- Okubo S, Lehtinen K, Isomaki H. Sensitivity of radiographic changes of hand and foot joints as a diagnostic criterion in patients with rheumatoid arthritis. *Scand J Rheumatol* 1992; 21:145–7.
- Devauchelle Pensec V, Saraux A, Berthelot JM, Alapetite S, Jousse S, Chales G, et al. Ability of foot radiographs to predict rheumatoid arthritis in patients with early arthritis. *J Rheumatol* 2004;31:66–70.
- Van der Heijde DM, van Leeuwen MA, van Riel PL, Koster AM, van 't Hof MA, van Rijswijk MH, et al. Biannual radiographic assessments of hands and feet in a three-year prospective followup of patients with early rheumatoid arthritis. *Arthritis Rheum* 1992;35:26–34.
- Priolo F, Bacarini L, Cammisa M, Cerase A, Ferrara R, Della Casa-Alberighi O, and GRISAR (Gruppo Reumatologi Italiani Studio Artrite Reumatoide). Radiographic changes in the feet of patients with early rheumatoid arthritis. *J Rheumatol* 1997; 24:2113–8.
- Sharp JT, Lidsky MD, Collins LC, Moreland J. Methods of scoring the progression of radiologic changes in rheumatoid arthritis: correlation of radiologic, clinical and laboratory abnormalities. *Arthritis Rheum* 1971;14:706–20.
- Larsen A, Dale K, Eek M. Radiographic evaluation of rheumatoid arthritis and related conditions by standard reference films. *Acta Radiol Diagn (Stockh)* 1977;18:481–91.
- Devauchelle-Pensec V, Saraux A, Berthelot JM, Alapetite S, Chales G, Le Henaff C, et al. Ability of hand radiographs to predict a further diagnosis of rheumatoid arthritis in patients with early arthritis. *J Rheumatol* 2001;28:2603–7.
- Van der Heijde D. How to read radiographs according to the Sharp/van der Heijde method. *J Rheumatol* 1999;26:743–5.
- Devauchelle-Pensec V, Berthelot JM, Jousse S, Samjee I, Josseume T, Colin D, et al. Performance of hand radiographs in predicting the diagnosis in patients with early arthritis. *J Rheumatol* 2006;33:1511–5.
- Combe B, Benessiano J, Berenbaum F, Cantagrel A, Daures JP, Dougados M, et al. The ESPOIR cohort: a ten-year follow-up of early arthritis in France. Methodology and baseline characteristics of the 813 included patients. *Joint Bone Spine* 2007; 74:440–5.
- Sharp JT, Young DY, Bluhm GB, Brook A, Brower AC, Corbett M, et al. How many joints in the hands and wrists should be included in a score of radiologic abnormalities used to assess rheumatoid arthritis? *Arthritis Rheum* 1985;28:1326–35.
- Van der Heijde DM, van Riel PL, Nuver-Zwart IH, Gribnau FW, van de Putte LB. Effects of hydroxychloroquine and sulphasalazine on progression of joint damage in rheumatoid arthritis. *Lancet* 1989;1:1036–8.
- Van der Heijde D. How to read radiographs according to the Sharp/van der Heijde method. *J Rheumatol* 2000;27:261–3.
- Britton CA, Gabriele OF, Chang TS, Towers JD, Rubin DA, Good WF, et al. Subjective quality assessment of computed radiography hand images. *J Digit Imaging* 1996;9:21–4.
- Forestier R, Morteau R. Radiography scale in rheumatology: state of the art and consequences for clinical practice. *J Radiol* 2000;81:1633–8. In French.
- Larsen A, Thoen J. Hand radiography of 200 patients with rheumatoid arthritis repeated after an interval of one year. *Scand J Rheumatol* 1987;16:395–401.
- Brook A, Corbett M. Radiographic changes in early rheumatoid disease. *Ann Rheum Dis* 1977;36:71–3.
- Mottonen TT. Prediction of erosiveness and rate of development of new erosions in early rheumatoid arthritis. *Ann Rheum Dis* 1988;47:648–53.
- Isomaki H, Kaarela K, Martio J. Are hand radiographs the most suitable for the diagnosis of rheumatoid arthritis? [letter]. *Arthritis Rheum* 1988;31:1452–3.
- Paimela L. The radiographic criterion in the 1987 revised criteria for rheumatoid arthritis: reassessment in a prospective study of early disease. *Arthritis Rheum* 1992;35:255–8.
- Taouli B, Guermazi A, Sack KE, Genant HK. Imaging of the hand and wrist in RA. *Ann Rheum Dis* 2002;61:867–9.
- Gossec L, Fautrel B, Pham T, Combe B, Flipo RM, Goupille P, et al. Structural evaluation in the management of patients with rheumatoid arthritis: development of recommendations for clinical practice based on published evidence and expert opinion. *Joint Bone Spine* 2005;72:229–34.
- Van der Heijde DM, van Leeuwen MA, van Riel PL, van de Putte LB. Radiographic progression on radiographs of hands and feet during the first 3 years of rheumatoid arthritis measured according to Sharp's method (van der Heijde modification). *J Rheumatol* 1995;22:1792–6.
- Ostergaard M, Peterfy C, Conaghan P, McQueen F, Bird P, Ejlberg B, et al. OMERACT Rheumatoid Arthritis Magnetic Resonance Imaging Studies: core set of MRI acquisitions, joint pathology definitions, and the OMERACT RA-MRI scoring system [published erratum appears in *J Rheumatol* 2004;31: 198]. *J Rheumatol* 2003;30:1385–6.
- Ostendorf B, Scherer A, Modder U, Schneider M. Diagnostic value of magnetic resonance imaging of the forefeet in early rheumatoid arthritis when findings on imaging of the metacarpophalangeal joints of the hands remain normal. *Arthritis Rheum* 2004;50:2094–102.
- Norgaard F. Earliest roentgenological changes in polyarthritis of the rheumatoid type: rheumatoid arthritis. *Radiology* 1965; 85:325–9.
- Brewerton DA. A tangential radiographic projection for demonstrating involvement of metacarpal heads in rheumatoid arthritis. *Br J Radiol* 1967;40:233–4.
- Boutry N, Larde A, Lapegue F, Solau-Gervais E, Flipo RM, Cotten A. Magnetic resonance imaging appearance of the hands and feet in patients with early rheumatoid arthritis. *J Rheumatol* 2003;30:671–9.
- Muehleman C, Bareither D, Huch K, Cole AA, Kuettner KE. Prevalence of degenerative morphological changes in the joints of the lower extremity. *Osteoarthritis Cartilage* 1997;5:23–37.
- Bukhari M, Lunt M, Harrison BJ, Scott DG, Symmons DP, Silman AJ. Rheumatoid factor is the major predictor of increasing severity of radiographic erosions in rheumatoid arthritis: results from the Norfolk Arthritis Register Study, a large inception cohort. *Arthritis Rheum* 2002;46:906–12.
- Combe B, Cantagrel A, Goupille P, Bozonnet MC, Sibilia J, Eliaou JF, et al. Predictive factors of 5-year Health Assessment Questionnaire disability in early rheumatoid arthritis. *J Rheumatol* 2003;30:2344–9.