

UC San Diego

UC San Diego Previously Published Works

Title

Abnormalities of the corpus callosum in children prenatally exposed to alcohol.

Permalink

<https://escholarship.org/uc/item/04794698>

Journal

Alcoholism, clinical and experimental research, 19(5)

ISSN

0145-6008

Authors

Riley, EP
Mattson, SN
Sowell, ER
et al.

Publication Date

1995-10-01

DOI

10.1111/j.1530-0277.1995.tb01600.x

Peer reviewed

Abnormalities of the Corpus Callosum in Children Prenatally Exposed to Alcohol

Edward P. Riley, Sarah N. Mattson, Elizabeth R. Sowell, Terry L. Jernigan, David F. Sobel, and Kenneth Lyons Jones

For 20 years, it has been known that fetal alcohol syndrome (FAS) is associated with abnormal brain development. Early autopsy studies point to the corpus callosum as one area affected by heavy alcohol exposure. Little is known, however, about the integrity of the brain in alcohol-exposed children who survive the perinatal period. This study was designed to assess the corpus callosum in living children exposed to high doses of alcohol prenatally. Thirteen children with histories of significant prenatal alcohol exposure and 12 normal control children were evaluated using magnetic resonance imaging. Using the midsagittal section, images were measured for the area of the corpus callosum using a computer-assisted measurement technique. In addition to the overall area, five equiangular regions were determined for each corpus callosum. Of the 13 alcohol-exposed children assessed, two had agenesis of the corpus callosum. The remaining alcohol-exposed children had significantly smaller overall callosal areas, as well as smaller regional areas of four of the five callosal regions, when compared with the normal control children. Importantly, when corrected for brain size, three of the five callosal regions were still smaller in the alcohol-exposed children, although overall area of the corpus callosum was no longer significantly different. These results suggest that prenatal exposure to high levels of alcohol is associated with abnormalities of the corpus callosum. They verify callosal agenesis in children with FAS, which previously had only been noted in autopsy reports. The current findings further document selective reductions in the area of certain regions of the corpus callosum after in utero alcohol exposure, extending our current understanding of alcohol's teratogenic effects on brain development. There is also some indication that the selective reduction in the area of the corpus callosum is similar to that reported in attention deficit disorder.

Key Words: Fetal Alcohol Syndrome, MRI, Corpus Callosum, Brain, Prenatal Alcohol Exposure.

From the Department of Psychology (E.P.R., S.N.M.), San Diego State University; San Diego State University/University of California—San Diego Joint Doctoral Program in Clinical Psychology (E.R.S.); Departments of Psychiatry and Radiology (T.L.J.), University of California—San Diego School of Medicine and Psychology Service, San Diego Department of Veterans Affairs Medical Center; Division of Neuroradiology (D.F.S.), Scripps Clinic and Research Foundation; and the Division of Dymorphology and Teratology (K.L.J.), Department of Pediatrics, University of California—San Diego School of Medicine, San Diego, California.

Received for publication February 28, 1995; accepted May 10, 1995

This study was supported in part by National Institute on Alcohol Abuse and Alcoholism Research Grants AA10417 (to E.P.R.) and AA06420 (to the Scripps Alcohol Research Center); by National Institutes of Health Grant 5P50NS22343-09 (to the Center for Developmental Cognitive Neuroscience); and by funding from the Medical Research Service of the Department of Veterans Affairs (to T.L.J.).

Reprint requests: Edward P. Riley, Ph.D., Center for Behavioral Teratology, 6363 Alvarado Court, Suite 209, San Diego, CA 92120.

Copyright © 1995 by The Research Society on Alcoholism.

EARLY REPORTS of fetal alcohol syndrome (FAS) documented significant brain abnormalities in children of chronic alcoholic women.¹ The first brain of an infant with FAS to be studied on autopsy evidenced complete absence, or agenesis, of the corpus callosum (ACC), as well as numerous other anomalies.^{2,3} There have also been other reports of callosal abnormalities after prenatal exposure to alcohol. Peiffer et al.⁴ and Wisniewski et al.⁵ reported separate cases of agenesis in infant girls with FAS who died before 1 year of age. Jeret et al.⁶ listed nine occurrences of callosal agenesis, including those documented by Jones and Smith,² Peiffer et al.,⁴ and Wisniewski et al.⁵ Finally, we recently reported⁷ a case of ACC in a 16-year-old boy with FAS who had undergone a magnetic resonance imaging (MRI) examination as part of a larger study. Another child in that case report had an abnormal, although fully formed, corpus callosum.

The corpus callosum is a tract of fibers that runs between the two cerebral hemispheres and forms the roof of the lateral ventricles. It develops relatively early during gestation, beginning between the sixth and eighth gestational weeks. At that time, the dorsal end of the rostral wall of the telencephalon increases in thickness and forms the lamina reuniens of His. This region is the future site of the cerebral commissures, wherein axons from the developing hemispheres will enter. The ventral end of the rostral wall of the telencephalon becomes the lamina terminalis, forming the anterior wall of the third ventricle. During the eighth week, the sulcus medianus telencephali medii (SMTM), a median groove in the dorsal lamina reuniens, is formed. Cells from the lamina reuniens migrate into the SMTM (week 9) and the groove closes (week 10). The cells inside the SMTM form the massa commissuralis, wherein pioneer callosal fibers enter (weeks 11–12). A definite corpus callosum is formed during weeks 12–13, and growth continues in a caudal direction over the next 5–7 weeks. First, the genu is formed, followed by the body and the splenium. The exception to the rostral-caudal growth is the rostrum, the rostral portion of the corpus callosum that curves underneath, which develops last, ~18–20 weeks of gestation. The corpus callosum is fully formed at this time, but axons continue to cross between the hemispheres as the brain develops.^{8,9} It has been postulated that the corpus callosum is one of the latest maturing structures of the brain, and growth is not actually complete until the third decade of life.¹⁰

Callosal abnormalities caused by in utero insults can be distinguished from perinatal or postnatal insults by considering the nature of the abnormality. Formation of the SMTM or the massa commissuralis seem to be key steps in the development of the corpus callosum.⁸ An insult before or during their formation will likely result in complete ACC. An insult shortly after the genesis of the SMTM, however, may result in partial agenesis, with only the genu of the callosum present. Thus, the amount of corpus callosum present might be taken as an indication of when the insult occurred. If however, the corpus callosum is fully formed, but shows focal abnormalities, degeneration of the crossing fibers is suggested. In addition, the presence of the bundles of Probst, formed by thwarted crossing fibers, suggests primary ACC rather than some secondary insult after initial development. Therefore, ACC is probably independent from any later callosal abnormalities.⁸

The incidence of callosal agenesis is estimated at 1–3/1,000 (0.1–0.3%) in normal unselected hospital populations.⁶ In developmentally disabled populations, estimates are considerably higher, at ~2.3%.^{6,11} Four syndromes are characterized by total or partial ACC: Aicardi syndrome, Andermann syndrome, Shapiro syndrome, and acrocallosal syndrome, whereas others, including FAS, have been “sporadically” associated with ACC.⁶ Other disorders that have occasionally been associated with ACC include the Apert syndrome¹² and the Dandy-Walker malformation.⁶

Abnormalities of the corpus callosum have been found in children with Attention Deficit Hyperactivity Disorder (ADHD),¹³ mental retardation,¹⁴ Down syndrome,¹⁵ XXXY syndrome,¹⁶ learning disabilities,¹⁷ and various malformative syndromes with mental retardation.^{18,19} The apparent increase in prevalence of callosal anomalies in developmentally abnormal children may be an artifact of the increased scrutiny of such children. Some believe, however, that this increased incidence is indicative of the correlation of brain abnormality to other deficits or dysfunctions and not simply a normal variant of development (e.g., see Ref. 14).

In the current study, we used MRI to evaluate 13 children with histories of heavy prenatal alcohol exposure. The area of the midsagittal section was assessed for corpus callosum area. Quantification of the corpus callosum should allow a more detailed and exact view of callosal morphology in alcohol-exposed children and hopefully allow additional insight into some of the behavioral and cognitive disturbances in such children.

METHODS

Subjects

Thirteen children and adolescents (9 males, 4 females) ranging in age from 8 to 18 (mean = 13 years) participated in this study. Informed consent was obtained from the parent or guardian of each child before participation. All children had histories of significant prenatal alcohol exposure and behavior/cognitive difficulties. Two diagnostic categories were used: FAS ($n = 11$) and prenatal exposure to alcohol (PEA) ($n = 2$).

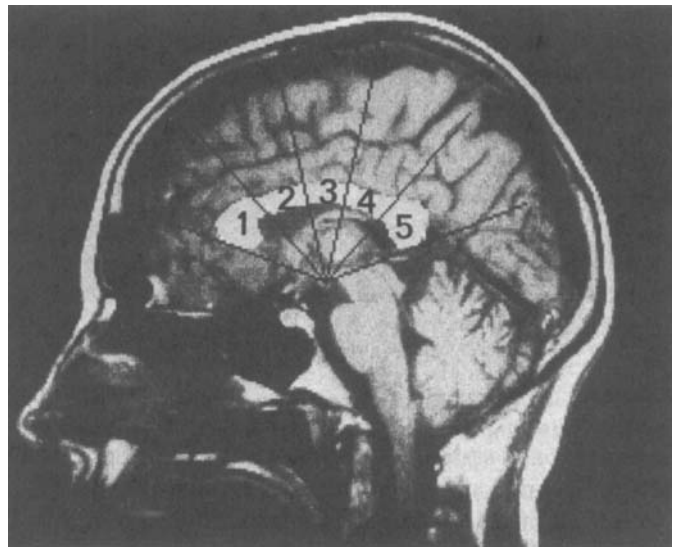


Fig. 1. Example of the five equiangular regions of the corpus callosum computed using the mammillary body as the center point.

The children with FAS ranged from mild to severe, based on physical and cognitive criteria such as facial dysmorphism, growth retardation, and IQ (range = <40–92). The two PEA children had confirmed histories of heavy gestational alcohol exposure, but lacked sufficient features for a confirmed diagnosis of FAS. In addition to the group of alcohol-exposed children (the ALC group), magnetic resonance images for a normal control group (the NC group) were selected from a large research MRI database. The NC subjects in this database were recruited for previous studies of young people with developmental disorders. The NC group was matched for age and sex, and consisted of 12 developmentally normal children (8 males, 4 females), who ranged in age from 8 to 19 (mean = 14 years).

MRI Procedure and Analysis

All children were evaluated using MRI. Sagittal images were obtained using T₁-weighted images (repetition time = 600 msec; echo time = 20 msec). Slice thickness was 5 mm, with a 2.5 mm gap between slices. A 256 × 256 matrix and 24-cm field of view were used in all examinations. All magnetic resonance images were acquired with a 1.5 T superconducting magnet (Signa, General Electric, Milwaukee, WI).

The corpus callosum was measured from the midsagittal section, as defined as the most midsagittal view of the genu and splenium. If this midsagittal view was absent or the mammillary bodies were not visible, the scan was excluded from the analysis. One ALC and one NC subject were excluded for this reason. In addition, two ALC subjects were excluded because of complete ACC (remaining ALC subjects = 10). A computerized analysis system was used for all area measurements. The operator was blind to subject diagnosis, age, and sex. Using a stylus-controlled cursor, a trained operator manually traced the outer perimeter of the corpus callosum. The operator then placed a line that passed through the most anterior point in the genu and the most posterior point in the splenium. Next, a point was selected in the middle of the mammillary body. Equidistant radial lines then divided the callosum into five regions using the mammillary body point and the genu and splenium endpoints. The total area of the corpus callosum was computed from the sum of the pixels within the traced perimeter. Similarly, five regional areas were computed. Region 1 was designated as the most anterior region containing the genu, and region 5 included the splenium (Fig. 1).

Two independent operators completed this analysis to establish the reliability of this method, although only one set of results was used for subsequent analysis. The interrater reliabilities for all regional areas and the total area of the corpus callosum were $r > 0.9$.

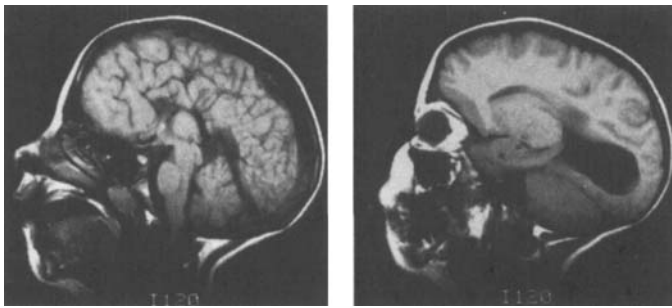


Fig. 2. Midsagittal view (left) showing ACC and a view 12.5 mm from the midsagittal (right) showing colpocephaly in a 9-year-old female with FAS.

RESULTS

As previously stated, two children in the ALC group had ACC. We previously described one of these children, a 14-year-old male, in a recent case report.⁷ The other child is a 9-year-old female whose mother reported heavy daily alcohol ingestion during the first 5 months of pregnancy and then binge drinking for the remainder of her pregnancy. In addition to the ACC, MRI revealed colpocephaly, a characteristic feature often associated with callosal agenesis. She had a Full-Scale IQ below the estimates available using the Wechsler Intelligence Scale for Children-Revised (<40), although her Verbal IQ was 46. The MRI midsagittal view for this child is shown in Fig. 2.

After excluding the two cases of agenesis and the two cases in which the midsagittal view or mammillary body were absent, the area measures were analyzed by analysis of variance (ANOVA), with repeated measures with Group (ALC versus NC) as a between-subjects factor and corpus callosum region (1–5) as the within-subject variable. In addition, Newman-Keuls tests were used to clarify further any group differences. The mean corpus callosum areas for the children in the ALC group were smaller than those of the NC group, although this was dependent on the specific region of the corpus callosum measured. This was supported by a significant Group \times Region interaction [$F(4,76) = 5.09$; $p < 0.01$]. Subsequent Newman-Keuls test indicated that the mean areas for regions 1, 3, 4, and 5 were significantly smaller (p 's < 0.01) in the ALC group, compared with the NC group (Fig. 3). Furthermore, significant overall main effects of Group [$F(1,19) = 10.61$; $p < 0.01$] and Region [$F(4,76) = 116.16$; $p < 0.001$] were indicated by the ANOVA.

A decrease in brain size often results from prenatal alcohol exposure and such was the case in the current study. The mean area of the midsagittal section was reduced 14% in the ALC group, compared with the NC group [$F(1,19) = 12.75$; $p < 0.002$]. To control for this decreased brain size, proportional callosal areas were computed using the area of the midsagittal section from which the corpus callosum was measured. An analysis of this proportional callosal area again indicated a significant interaction between Group and Region [$F(4,76) = 2.80$; $p < 0.05$]. These data are presented in Fig. 4. Newman-Keuls tests indicated that the

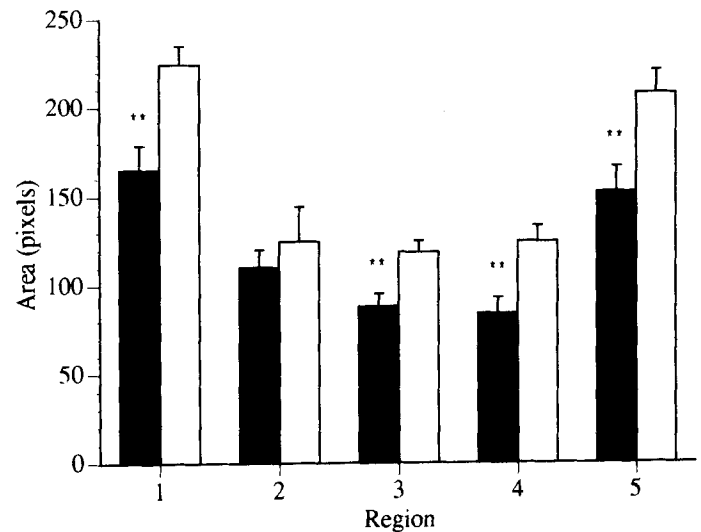


Fig. 3. Mean area (\pm SE) of five equiangular regions of the corpus callosum in alcohol-exposed and control children. * $p < 0.05$; ** $p < 0.01$. ■, ALC group; □, NC group.

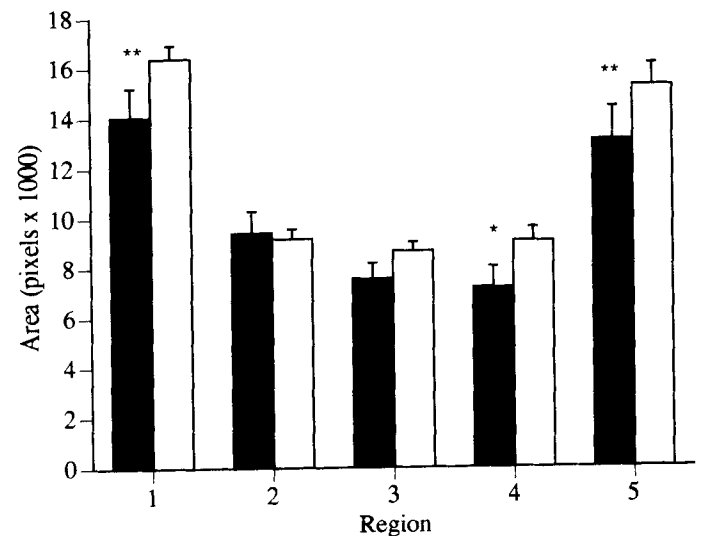


Fig. 4. Mean proportional area (\pm SE) of five equiangular regions of the corpus callosum in alcohol-exposed and control children. * $p < 0.05$; ** $p < 0.01$. ■, ALC group; □, NC group.

ALC group had smaller mean proportional areas for regions 1 ($p < 0.01$), 4 ($p < 0.05$), and 5 ($p < 0.01$). In addition, an overall effect of Region [$F(4,76) = 119.30$; $p < 0.001$] was indicated by the ANOVA, although the main effect of Group did not reach significance [$F(1,19) = 2.25$; $p = 0.15$].

Although there are too few subjects in the ALC group to make distinctions related to callosal size between the different diagnostic categories (FAS versus PEA), some observations may be relevant. The most severely affected in terms of both midsagittal area and callosal size were the cases of FAS. In fact, 5 of the 8 FAS cases had callosal areas and proportional callosal areas less than the smallest NC case. The two PEA cases were more disparate. One of these subjects had a callosal area that was similar to that

seen in the most affected FAS cases. Relative to the NC group, this child's callosal area was in the 1st percentile. The other case had an average-sized corpus callosum (54th percentile).

DISCUSSION

The major purpose of this study was to evaluate the area of the corpus callosum in children exposed to alcohol prenatally. The results indicated that the callosal area in these children was significantly smaller than that of NC children. When the corpus callosum was divided into five equiangular regions, regions 1, 3, 4, and 5 (numbered from anterior to posterior) were significantly smaller than controls. Even when we controlled for brain size by using proportional area, although there was no longer a significant main effect for Group, there was still a significant interaction of Region and Group. In this analysis, proportional areas of regions 1, 4, and 5 were significantly smaller in the ALC children. It is tempting to speculate based on these data that the developing corpus callosum might be especially sensitive to prenatal alcohol exposure relative to the brain in general. For example, in our small sample, 7 of the 10 ALC children who underwent the quantitative analysis of the MRI data had greater proportional loss in the corpus callosum than the midsagittal area. In addition, two other ALC children had ACC and therefore had to be excluded from the quantitative analysis. However, two of the ALC children, one FAS and one PEA, had normal-sized callosa, despite having extremely small midsagittal areas. Further work on the sensitivity of the developing corpus callosum to alcohol insult, perhaps as relates to critical periods of exposure, is obviously needed.

This reduction in size of specific regions of the corpus callosum is interesting, because similar results have been found in children with ADHD.¹³ Although the method used by Hynd et al.¹³ to delineate callosal regions was not identical to that used here, a similar pattern of results was found. The greatest difference between ADHD children and controls was in the regions of the genu, the area anterior to the splenium, and the splenium (corresponding to our regions 1, 4, and 5). The similarity between the ADHD children and the ALC children, in terms of regions showing the greatest reduction in callosal area, suggests a possible relationship between alcohol exposure and the common occurrence of attentional deficits and hyperactivity in such children.

Hyperactivity and attentional deficits are often present in children with FAS or histories of prenatal alcohol exposure.²⁰ Although an explicit comparison of the corpus callosa of children with FAS and ADHD needs to be completed before any definite conclusions can be drawn, there seems to be a similarity between the regional areas affected in both conditions. Children with ADHD are thought to have deficient frontal systems, which may be related to the decrease in corpus callosum size in the area of the genu.¹³

Behavioral manifestations of frontal system abnormalities that occur in ADHD children include inhibition deficits and motor persistence, which are also common in children and animals with prenatal exposure to alcohol.²¹ This may be related to the finding of decreased corpus callosum size in our region 1. At this point, it is unclear whether a decreased corpus callosum area is caused by fewer axons or decreased axonal diameter possibly related to deficient myelination. Further studies, using the various animal models of FAS, may help to clarify this question.

As previously described, two subjects in this sample were eliminated from analyses because of complete callosal agenesis. We are also aware of one other child in our larger sample of alcohol-exposed children who has callosal agenesis, as documented on a previous computerized tomography scan. This child was not included in this study because of his young age. At the time of this study, our larger sample consisted of 44 children with histories of heavy in utero exposure to alcohol. Although not all children in our larger sample have received MRI examinations, the present incidence of ACC in this sample is 3 of 44 or 6.8%, which is considerably higher than the rate of 0.3% in the general population and even the rate of 2.3% in developmentally disabled populations. We are not suggesting that ACC is common in FAS, but that it should be considered when discussing brain abnormalities related to prenatal alcohol exposure. Of note is that the three children with ACC are among the most severely affected in terms of their clinical presentations in our entire sample. Two of these three children have been assessed behaviorally as part of our project and have an average Full-Scale IQ of ~40 (according to the Wechsler Intelligence Scale for Children-Revised). Thus, it may be that only in the most severe cases of alcohol embryopathy is such a significant defect as ACC found.

In summary, 13 children with histories of prenatal alcohol exposure were evaluated using MRI. Two children had complete ACC. In the remaining children, the area of the corpus callosum was significantly smaller than that of the comparison group, and certain regions were more affected than others. Even when brain size was accounted for, several callosal regions were still smaller in the alcohol-exposed children when compared with controls. One consequence of these alterations might be that interhemispheric functions would be compromised, and we are currently in the process of assessing this possibility. However, the results of this study do emphasize alcohol's effect on the developing brain and suggest that callosal anomalies should be considered in the etiology of the behavioral teratology of alcohol.

REFERENCES

1. Jones KL, Smith DW: The fetal alcohol syndrome. *Teratology* 12:1-10, 1975
2. Jones KL, Smith DW: Recognition of the fetal alcohol syndrome in early infancy. *Lancet* 2:999-1001, 1973

3. Clarren SK, Alvord EC, Sumi SM, Streissguth AP, Smith DW: Brain malformations related to prenatal exposure to ethanol. *J Pediatr* 92:64-67, 1978
4. Peiffer J, Majewski F, Fischbach H, Bierich JR, Volk B: Alcohol embryo- and fetopathy: Neuropathology of 3 children and 3 fetuses. *J Neurol Sci* 41:125-137, 1979
5. Wisniewski K, Damska M, Sher JH, Qazi Q: A clinical neuropathological study of the fetal alcohol syndrome. *Neuropediatrics* 14:197-201, 1983
6. Jeret JS, Serur D, Wisniewski KE, Lubin RA: Clinicopathological findings associated with agenesis of the corpus callosum. *Brain Dev* 9:225-264, 1987
7. Mattson SN, Riley EP, Jernigan TL, et al: Fetal alcohol syndrome: A case report of neuropsychological, MRI, and EEG assessment of two children. *Alcohol Clin Exp Res* 16:1001-1003, 1992
8. Barkovich AJ, Norman D: Anomalies of the corpus callosum: Correlation with further anomalies of the brain. *AJNR* 9:493-501, 1988
9. Ramaekers G: Embryology and anatomy of the corpus callosum, in Ramaekers G, Njikiktjen C (eds): *Pediatric Behavioural Neurology*, vol 3: *The Child's Corpus Callosum*. Amsterdam, Suyi Publications, 1991, pp 24-39
10. Pujol J, Vendrell P, Junqué C, Marti-Vilalta JL, Capdevila A: When does human brain development end? Evidence of corpus callosum growth up to adulthood. *Ann Neurol* 34:71-75, 1993
11. Jeret JS, Serur D, Wisniewski K, Fisch C: Frequency of agenesis of the corpus callosum in the developmentally disabled population as determined by computerized tomography. *Pediatr Neurosci* 12:101-103, 1986
12. de León GA, de León G, Grover WD, Zaeri N, Alburger PD: Agenesis of the corpus callosum and limbic malformation in Apert syndrome (type I acrocephalosyndactyly). *Arch Neurol* 44:979-982, 1987
13. Hynd GW, Semrud-Clikeman M, Lorys AR, Novey ES, Eliopoulos D, Lyytinen H: Corpus callosum morphology in attention deficit-hyperactivity disorder: Morphometric analysis of MRI. *J Learning Disabilities* 24:141-146, 1991
14. Schaefer GB, Bodensteiner JB, Thompson JN, Wilson DA: Clinical and morphometric analysis of the hypoplastic corpus callosum. *Arch Neurol* 48:933-936, 1991
15. Wang PP, Doherty S, Hesselink JR, Bellugi U: Callosal morphology concurs with neurobehavioral and neuropathological findings in two neurodevelopmental disorders. *Arch Neurol* 49:407-411, 1992
16. Haeusler G, Frisch H, Guchev Z, Hadziselimovic F, Neuhold A, Vormittag W: Hypoplasia of the corpus callosum and growth hormone deficiency in a boy with the XXXXY syndrome. *Clin Genet* 40:249-250, 1991
17. Njikiktjen C, de Sonnevile L, Vaal J: Callosal size in children with learning disabilities. *Behav Brain Res* 64:213-218, 1994
18. Gabrielli O, Salvolini U, Coppa GV, Catassi C, Rossi R, Manca A, Lanza R, Giorgi, PL: Magnetic resonance imaging in the malformative syndromes with mental retardation. *Pediatr Radiol* 21:16-19, 1990
19. Gabrielli O, Salvolini U, Bonifazi V, Ciferri L, Lanza R, Coppa GV, Giorgi, PL: Morphological studies of the corpus callosum by MRI in children with malformative syndromes. *Neuroradiology* 35:109-112, 1993
20. Nanson JL, Hiscock M: Attention deficits in children exposed to alcohol prenatally. *Alcohol Clin Exp Res* 14:656-661, 1990
21. Driscoll CD, Streissguth AP, Riley EP: Prenatal alcohol exposure: Comparability of effects in humans and animal models. *Neurotoxicol Teratol* 12:231-237, 1990