

# Absence of penile erections during paradoxical sleep. Peculiar penile events during wakefulness and slow wave sleep in the armadillo

JORGE M. AFFANNI<sup>1,2</sup>, CLAUDIO O. CERVINO<sup>2</sup>  
and HERNAN J. ALDANA MARCOS<sup>2</sup>

<sup>1</sup>Instituto de Neurociencia (CONICET-UBA), Departamento de Ciencias Biológicas, Universidad de Buenos Aires, Buenos Aires, Argentina;

<sup>2</sup>Facultad de Medicina, Universidad de Morón, Morón, Argentina

Accepted in revised form 18 May 2001; received 2 March 2000

**SUMMARY** The electroencephalogram (EEG) together with electromyogram (EMG) of the ischiocavernosus, bulbocavernosus and levator penis muscles were chronically monitored across behavioral states of the armadillo *Chaetophractus villosus*. This animal has a very long penis, which exhibits remarkable phenomena during wakefulness (W), slow wave sleep (SWS) and paradoxical sleep (PS). During W it remains retracted within a skin receptacle. During SWS penile protrusion can be observed together with very complex movements. Protrusion is a non erectile event during which the penis remains out of its receptacle but without rigidity. Penile erections are observed only during SWS. Contrasting with other mammals, no erections occur during PS. During this phase the penile muscles share the atonia of the body musculature characteristic of that phase. Some reflections on mechanisms of those penile events are presented.

**KEYWORDS** armadillo, paradoxical sleep, penile erections, slow wave sleep, voluntary erections, wakefulness

## INTRODUCTION

The comparative approach of somatic and vegetative manifestations of sleep offers the possibility of observing variations leading to new findings. The comparative study of penile behavior during sleep in different species might be particularly rewarding for the understanding of the functional organization of the brain in that physiological state.

Reports on sleep related penile erections in mammalian species different from humans are extremely scanty. The first demonstration of paradoxical sleep (PS) erection with experimental methods was made by Schmidt *et al.* (1994) in the rat. As experimental data are lacking the question remains open whether PS erections are a generalized phenomenon of mammalian physiology.

In this paper we use the South American armadillo *Chaetophractus villosus* as an experimental animal. The

principal wakefulness and sleep characteristics of this species were reported by Affanni *et al.* (1968) and García Samartino *et al.* (1974). A peculiar wakefulness rhythm of the olfactory bulbs and olfactory tubercles was described in this mammal (Affanni and García Samartino 1984; Cervino 1997; García Samartino *et al.* 1987). Behavioral research on this species was reported by Papini *et al.* (1984 and 1985). The brain structure was studied by Benítez *et al.* (1994). A remarkable characteristic is the absence of pineal gland (Benítez *et al.* 1994). The rectal temperature varies between  $35.1 \pm 0.4$  °C in the morning and  $36.1 \pm 0.4$  °C in the afternoon (Casanave and Affanni 1994).

The aim of the present paper is to report the absence of penile erections during PS and the presence of peculiar penile phenomena during wakefulness (W) and slow wave sleep (SWS) in this armadillo.

## METHODS

Ten adult male armadillos, *C. villosus* (Xenarthra, Dasypodidae) weighing 3–4 kg were used. Data on geographical

*Correspondence:* Jorge M. Affanni, Instituto de Neurociencia (INE-UCI), Facultad de Ciencias Exactas y Naturales, Pab. II. Ciudad Universitaria, Av. Cantilo s./n. (1428), Buenos Aires, Argentina. Tel./fax: 00541 576 3327; e-mail: jorgeaffanni@fibertel.com.ar

distribution, morphological features and behavior of this nocturnal species will be found in Cabrera *et al.* (1940), Grassé (1955) and Walker (1968).

An additional group of five animals solely implanted for electroencephalogram (EEG) recording was submitted to one 24 h continuous study. This was performed to ascertain by simple visual observation, during the dark period, the occurrence of the penile phenomena observed in the 8 h sessions. We also used this group for determining the 24 h percentage of time spent in W, SWS and SP. Three animals belonging to this group were submitted to 30 °C of ambient temperature. The observation of penile movements and erections during the dark period was made under infra-red light. The arrangement for the observation was as follows: an array of 49 infra-red light-emitting diodes (LEDs) fed by a 12-V DC source was placed in the roof of the cage at a distance of 50 cm from the animals. The DC current went on exactly when the visible light went off (at 7 PM). A picture CD camera, model ICD-31 was focused on the animals and the images were observed by means of a monitor model PM-9304 (Band W). The camera and the monitor were obtained from Ikegami Tsushinki Co. Ltd., Utsunomiya, Japan.

#### Recording of brain electrical activity

The electrode implantation was made under ketamine hydrochloride (40 mg kg<sup>-1</sup>, *i.m.*) and sodium pentobarbital (35 mg kg<sup>-1</sup>, *i.p.*). The skull bones were exposed by removing a piece of the carapace with a saw. The bones were then drilled over the rostral and caudal parts of the dorsal neocortex. Pairs of small stainless steel screws were inserted into the drilled holes, their tips lying on the dura. Neocortical electrical activity was bipolarly recorded by means of those screws.

Bioelectrical signals were digitized with sampling frequency at 256 Hz. The EEG signals were filtered through bandpass 1.6–55 Hz. The bioelectrical signals were recorded and analysed using Harmonie and Sensa Software (Stellate Systems-Quebec, Canada-1997).

#### Recording of EMG activity of penile muscles

Levator penis (LP), bulbocavernosum (BC), ischiocavernosum (IC) and neck muscles electromyogram (EMG) activity was recorded by means of electrodes implanted according to the method described by Holmes *et al.* (1991), under ketamine and pentobarbital anesthesia. The electrodes were placed at the sites indicated in Fig. 1. The EMG of penile muscles was filtered through bandpass 25–110 Hz. Penile erection events and penile movements were defined according to polygraphic and video recordings.

#### Surgical section of both LP

Both LP muscles were sectioned at the level indicated in Fig. 1, in animals anesthetized as described above.

#### General procedures adopted for this study

Following the implantation, the animals were allowed to recover for 1 week, during which oxitetracycline (7–10 mg kg<sup>-1</sup>) was administered to prevent infections under the carapace. Then, EEG recordings and the study of penile behavior together with the EMG of penile muscles were made. For those recordings, each armadillo was kept in a cage provided with a glass window. The cage remained inside a sound proof room built as a Faraday cage. Room temperature was 24 ± 1 °C during the observation period. The animals were maintained on a 12:12 light–dark with lights on at 07:00. They were fed with Purina dog chow and water *ad libitum*. Food and water renewal plus cleaning of the cage was made at 6 PM.

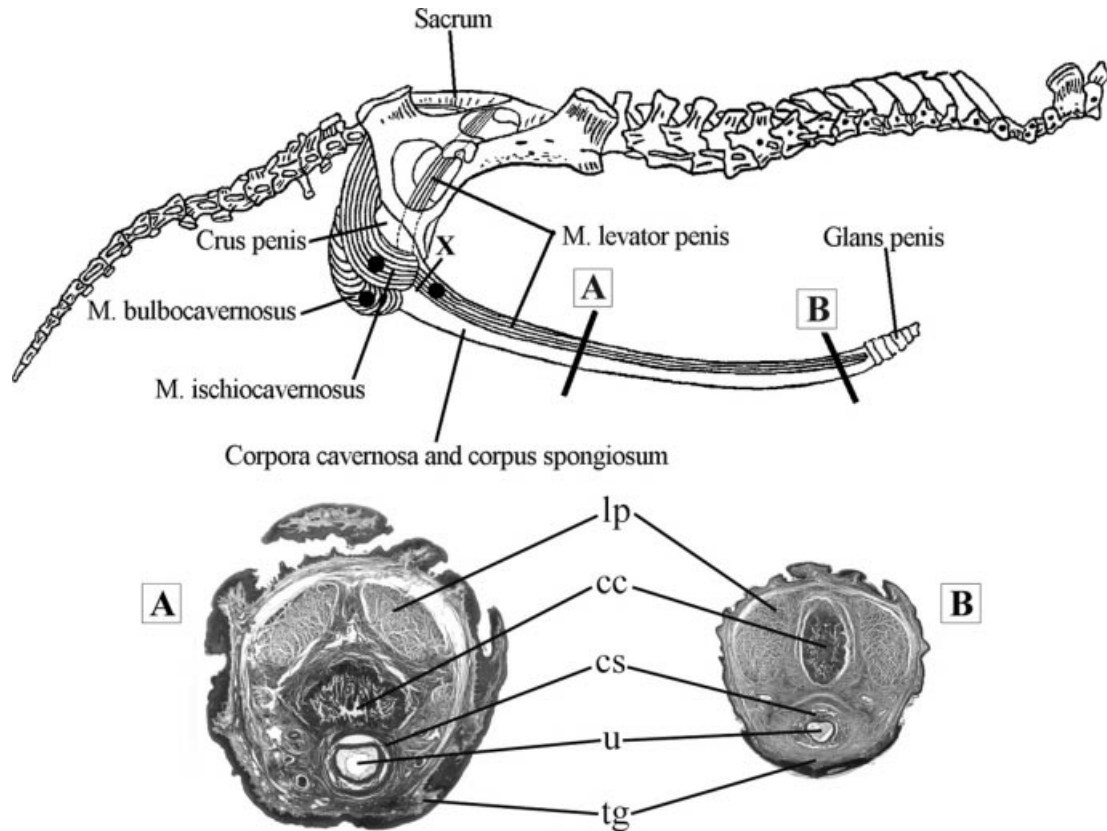
In the 10 animals, except the additional group, the observation and recording of penile events, EEG tracings and EMG of penile muscles were made between 8:00 AM and 4:00 PM. Each animal was recorded during one 8 h session. Their strong tendency to sleep in dorsal decubitus greatly facilitates the observation and monitoring of the penis. Penile events were continuously observed and recorded on videotapes. The animals were observed through a video camera and a television monitor in order to avoid disturbances elicited by the presence of the experimenter. The most significant events were photographed.

## RESULTS

#### Brief anatomical description of the penis

This description is necessary in order to understand the results. The protruded penis (Fig. 1) is very long and in specimens measuring 35 cm in length, excluding the tail, is approximately 19 cm long. When the animal is awake the penis remains completely withdrawn and concealed from view within a skin receptacle which is big enough to entirely contain the penis (Fig. 2A). When erected, it projects outside in rostral direction.

A general view of the penile structures is shown in Fig. 1. This figure shows a schematic view of the striate penile musculature which is composed of the ischiocavernosus muscle (IC), the bulbocavernosus muscle (BC) and the levator penis muscle (LP). The IC and BC converge caudo-medially to join the radix penis. The IC has its origin on the ramus of the ischium and is inserted on the crus penis. The BC consists of two symmetrical parts united in a median tendinous raphe. It arises from the ventral surface of the median raphe. Both parts encircle the urethral bulb and appear reinserted on the dorsal surface of the median raphe. The LP is an extraordinarily long striated muscle which runs over a long way from the sacrum up to the vicinity of the glans. It arises from the sacrum, whereas its fibers descend through the pelvic cavity and converge at the level of pubic symphysis, passing forwards to the corpus of the penis. The fibers run dorsomedially along the dorsum of each corpus cavernosum ending by an aponeurosis 1 cm before the glans. The penile extremity forms an angle with the penile



**Figure 1.** Upper part of the figure. Schematic drawing of penile muscles. Note the levator penis (LP) running over a long way from the ventral aspect of the sacrum up to the penile tip. The relationship between ischiocavernosus, bulbocavernosus and the radix penis can be appreciated. Black circles indicate the electrode positions. X shows the level of the surgical sections of both LP muscles. Lower part of the figure. Transverse sections of the penis at the level of A (photograph A) and B (photograph B). Note the two levator penis muscles (lp), corpus cavernosum (cc), corpus spongiosum (cs), urethra (u) and tegument (tg). Note also that at the level of B the corpus cavernosum is greatly reduced (Masson trichrome and H-E, respectively, 7X).

body, an anatomical detail which is relevant for understanding some phenomena occurring during PS (Fig. 1).

The corpus penis is composed of three elongated masses: two dorsally located consisting of right and left corpora cavernosa and another ventrally located represented by the corpus spongiosum (Fig. 1). The corpus spongiosum is small along the penile shaft but enlarges distally forming the bulk of the glans. A thick penile fascia surrounds the erectile tissue and the two LP muscles.

#### Brief description of sleep in the armadillo *ChaetophRACTUS villosus*

As little is known of sleep in this species, we give here a summary of its most salient features.

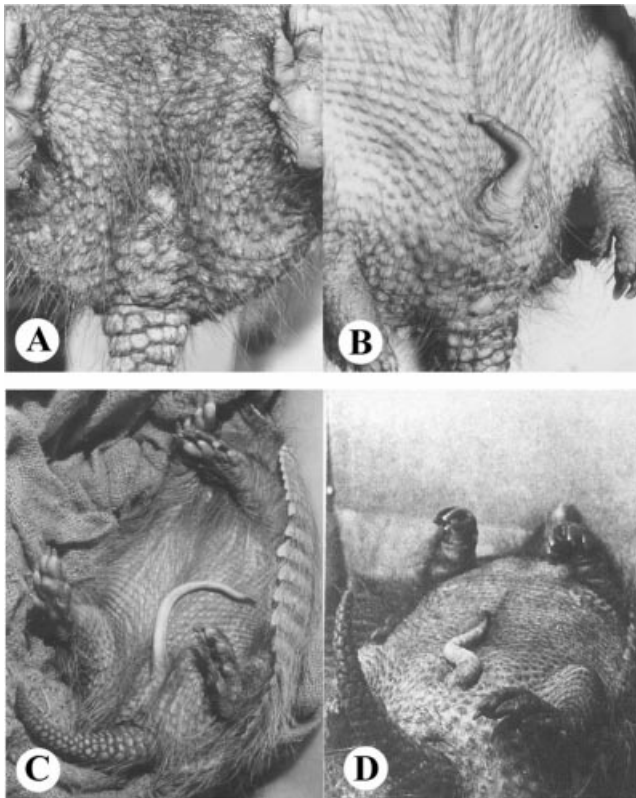
The dominant sleep posture in the laboratory is in dorsal or lateral decubitus. This permits an easy observation of the penis.

The most striking feature of the sleep pattern in laboratory conditions is the high percentage and low variability of total sleep time per day. The percentages of W, SWS and PS of five animals submitted to 24 h recordings is shown in Table 1. Periods of uninterrupted sleep of more than 6 h are frequently seen.

The EEG tracings of W, SWS and PS were described by Affanni *et al.* (1968) and by Cervino (1997). Their general characteristics during W, SWS and PS are similar to those of other mammals (Affanni *et al.* 1972) (see Figs 3, 4, 5 and 7). PS episodes are easily identified by the EEG tracings and the classical rapid eye movements, muscle atonia, irregular respiration, muscular twitches and movements of the vibrissae. Theta rhythm is clearly observed in the hippocampus.

A striking characteristic observed during variable periods of several minutes after the initiation of SWS is the intense tremor of the four limbs. After those initial minutes, the tremor disappears. This contrasts with the tremor of the giant armadillo *Priodontes giganteus* in which it persists throughout the entire SWS episodes (Affanni *et al.* 1972). In our species, tremor occurs only when the ambient temperature is below 28 °C. It is not continuous and immediately disappears if arousing stimuli are presented. It also disappears when the ambient temperature is above 28 °C.

For SWS, it is possible to discriminate three stages namely: (a) SWS1, showing tremor and small slow EEG waves with very scarce or complete absence of spindles. The slow EEG waves persist even if the ambient temperature is above 28 °C; (b) SWS2, showing abundant EEG spindles without tremor;



**Figure 2.** (A) Penis within the skin receptacle during wakefulness, (B–D) different postures of the protruded penis during SWS as a consequence of penile movements.

**Table 1** Time percentages spent in W, SWS and PS in five animals submitted to one 24 h continuous EEG recordings

ARMADILLO	11	12	13	14	15
W %	19.80	15.10	9.00	14.60	16.20
SWS %	59.0	67.2	73.8	66.7	65.3
PS %	21.2	17.7	17.2	18.7	18.5

(c) SWS3, with large delta waves and without tremor.

When the ambient temperature is low (less than 15 °C) these animals have high arousal thresholds. However, at the ambient temperature adopted in this paper (24 ± 1 °C) they are very easily aroused.

**Penile behavior and EMG activity of penile muscles**

Table 2 shows the different penile events during SWS and PS episodes with their quantitative features. Before describing the peculiarities of penile phenomena, a distinction must be made between penile protrusions and penile erections. Protrusion is a non erectile phenomenon during which the penis is out from the skin receptacle remaining in a flaccid state without rigidity. Rigidity is attained only during erection. The latter is always preceded by protrusion.

**Table 2** Penile events during slow wave sleep (SWS) and paradoxical sleep (PS). Each of the 10 animals was submitted to one 8 h session. Values are expressed in mean ± SD. Note that erections and penile movements are only seen during SWS. Note the total absence of penile erections during PS. TFPT: twitching flexion of penile tip

ARMADILLO	1	2	3	4	5	6	7	8	9	10
<i>Slow wave sleep</i>										
No. of episodes	28	16	18	12	16	20	16	16	22	14
Avg. episode	10.10 ± 5.40	20.50 ± 9.30	14.00 ± 9.00	20.00 ± 7.23	17.00 ± 6.30	12.40 ± 5.00	20.30 ± 7.40	15.62 ± 6.90	12.32 ± 4.93	18.57 ± 8.43
Duration (min)	35.71	20.00	77.77	33.33	100.00	50.00	60.00	62.50	36.36	57.14
SWS episodes with erection (%)	4.13	0.75	6.84	2.00	5.86	5.38	2.75	4.61	3.42	3.57
No. of erections per h SWS <sup>-1</sup>	2.61 ± 0.34	2.73 ± 0.52	2.00 ± 0.25	2.51 ± 0.30	2.72 ± 0.28	1.98 ± 0.23	2.53 ± 0.19	2.61 ± 0.33	1.88 ± 0.28	2.80 ± 0.51
Avg. erection Duration (s)	100	100	100	100	100	100	100	100	100	100
Movements (%)	10.46	5.23	7.80	14.32	4.61	9.56	7.21	12.33	15.03	6.00
No. of movements per h SWS <sup>-1</sup>	4.14 ± 2.00	2.36 ± 1.51	5.63 ± 2.11	4.51 ± 2.16	7.54 ± 2.51	2.25 ± 1.61	8.31 ± 3.00	5.63 ± 2.61	2.49 ± 0.75	4.69 ± 2.11
Avg. movement Duration (s)	18	14	16	12	14	18	12	10	18	12
<i>Paradoxical sleep</i>										
No. of episodes	5.60 ± 2.40	6.78 ± 2.02	7.13 ± 2.61	7.41 ± 2.23	8.20 ± 3.19	5.16 ± 1.92	2.75 ± 2.71	12.13 ± 3.51	5.94 ± 1.92	8.33 ± 3.12
Avg. episode duration (min)	0	0	0	0	0	0	0	0	0	0
Episodes with erection (%)	88.88	71.42	87.50	83.33	57.14	77.77	66.66	80.00	77.77	66.66
Episodes with TFPT (%)										

Before the implantation of the electrodes and in five different animals, we observed total penile protrusion when a female was introduced in the cage. In one of them, the protruded penis appeared completely flaccid lying on the cage's floor. In the other four, the penis was first completely protruded and flaccid but afterwards an erection in which it adopted the form of an arch (concavity dorsalwards) was seen. In these cases, attempts at mounting were observed. The most outstanding fact of these erections is that they appear and disappear almost instantaneously several times during the attempts, while the penis is orientated in different directions in search of the vagina. The erections were quite similar to those seen during SWS (Fig. 2).

### In normal animals submitted to 8 h sessions of EMG and EEG recordings

#### Wakefulness

*Penile behavior.* The penis was always entirely within the skin receptacle and it was never visible to the observer (Fig. 2A), except after the introduction of a female. We could always observe a slight penile protrusion (about 0.5–1 cm long) during urination.

*EMG of penile muscles.* The LP EMG permanently showed very intense continuous activity. The EMG bursts were seen in the IC and BC muscles (Fig. 3).

#### Slow wave sleep

Three different types of remarkable penile phenomena were observed: protrusions without movements, protrusions with movements and erections.

#### Protrusions

*Penile behavior.* As soon as the first EEG slow waves and spindles were seen, a previously flaccid penis began to protrude (Fig. 2B). The degree of protrusion varied in different animals and in one and the same animal at different times but it was always observed. Two ways of reaching the maximal protrusion were seen: (i) by a series of discrete penile elongations. This was the most frequent one; (ii) by an almost continuous process during which the penis adopted different postures. These facts are shown in Fig. 2 (B–D). Both modalities could be seen in one and the same animal within a single SWS episode or in different episodes. While the penis was protruding or after the completion of its way out from the skin receptacle, peculiar penile movements could be observed. An overall examination of those movements in the animals studied permits to classify them in two categories:

#### (A) Spontaneous movements:

- (a) Curving movements (Fig. 2B);
- (b) Undulant movements (Fig. 2C);
- (c) Flagellum-like movements.

However, those movements appear as a continuum in which no one is a discrete event. For example, the penis shows a curving movement that evolves into a flagellum-like or into an undulant one. Within SWS episodes the movements are more frequent than erections and appear separated by periods of complete penile immobility. On the other hand, they are seen in all the sleep episodes. This is shown in Table 2 together with the duration and number of movements per hour of SWS.

#### (B) Evoked events

(a) *Partial retraction provoked by mechanical stimulation:* A slight touch to the penis often provoked a partial retraction, without EEG arousal.

(b) *Effect of arousing stimuli:* When an arousing sound was applied during SWS or PS, an immediate EEG arousal response appeared (Fig. 5). In this case, the penis rapidly retracted, twisting itself into its skin receptacle.

(c) *Effects of general anesthesia:* When sodium pentobarbital (35 mg kg<sup>-1</sup>, *i.p.*) was administered, the following phenomenon was observed: as soon as the animals began to show relaxation, the penis went entirely out of its receptacle remaining flaccid. No movements were observed. The EMG activity disappeared from all the muscles. As the armadillos began to recover from anesthesia, the penis retracted into its receptacle little by little or at one stroke, rolling up into a curl.

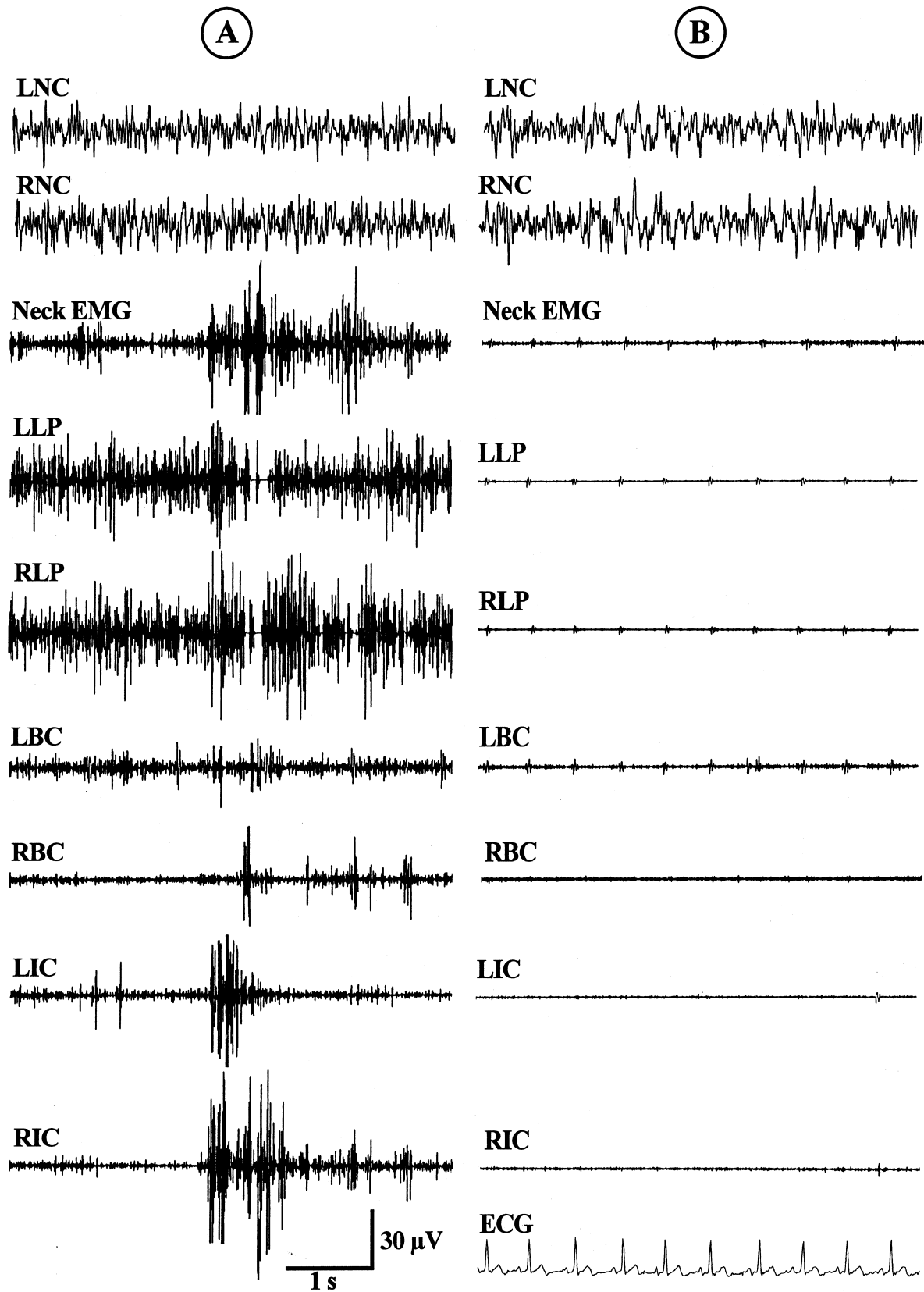
*EMG of penile muscles.* When the penis was protruded but immobile, the EMG activity disappeared in all penile muscles (Fig. 4A). Intense LP, BC and IC activity was observed during penile movements (Fig. 4B). The LP activity was more continuous than those of the other muscles.

Immediately after the application of the stimulus the EMG activity increased in all the muscles. However, it was of higher amplitude and more continuous in the LP (Fig. 5).

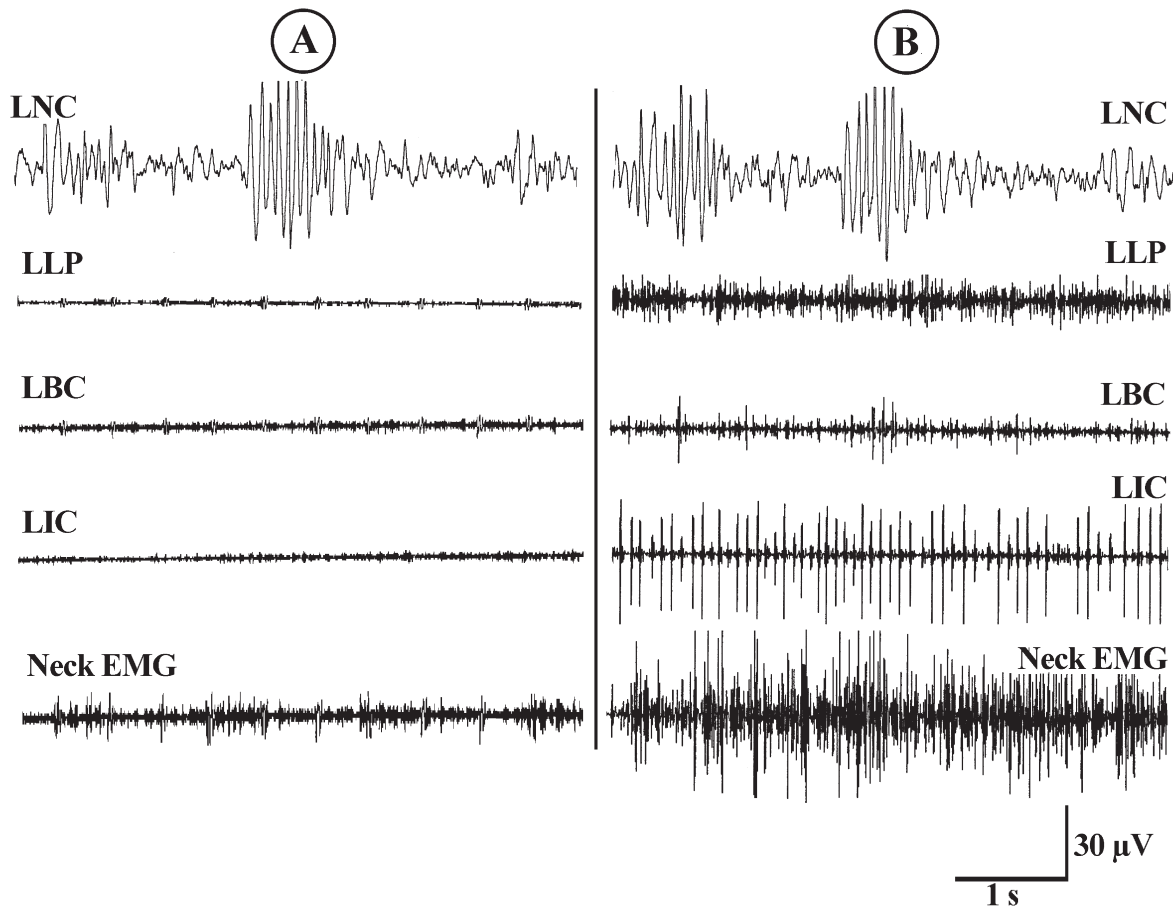
#### Erections

*Penile behavior.* *Arch-like erections* occur. These are the most impressive phenomena. They were always accompanied by transient extensions of the four limbs together with slight changes in body posture. The penis adopted the form of an arch (concavity downwards when the animal slept in dorsal decubitus) (Fig. 6). They were similar to those observed during waking states in sight of females. A characteristic feature was their short duration, lasting no more than 3 s (Table 2). Another peculiarity is that they always begin or cease almost instantaneously. When they cease, the penis falls flaccid and protruded on the abdominal wall. On the other hand, erections did not occur in every SWS episode (Table 2). They occur in any of the SWS stages within each episode. Systematic occurrence directly before or after PS was never observed. They appear as 'all or none' events with absence of incomplete erections. Table 2 shows the percentage of SWS episodes with erections together with the number of erections per hour of SWS and the erection duration.

*EMG of penile muscles.* During the erections LP, BC and IC increased their activity. The IC muscle showed characteristic bursts (Fig. 7).



**Figure 3.** (A) Neocortical and EMG activity of penile muscles during W. (B) Neocortical and EMG activity of penile muscles during PS. Note total absence of EMG activity. The electrocardiogram (ECG) contaminates the tracings. LNC, left neocortex; RNC, right neocortex; EMG, electromyogram; LLP, left levator penis; RLP, right levator penis; LBC, left bulbocavernosus; RBC, right bulbocavernosus; LIC, left ischiocavernosus; RIC, right ischiocavernosus.



**Figure 4.** Neocortical and EMG activity of penile muscles during SWS. (A) Protruded penis without movements, (B) Protruded penis while performing movements. LNC: Left neocortex; LLP: Left levator penis; LBC: Left bulbocavernosus; LIC: Left ischiocavernosus; EMG: Electromyogram.

#### *Paradoxical sleep*

**Penile behavior.** The penis remained protruded and flaccid throughout all PS episodes. We never observed erections during PS episodes (Table 2). Additionally, we never observed erections in the hundreds of PS episodes recorded from the five animals visually monitored during the 24 h continuous recordings. All movements of the corpus penis disappeared completely. Only one kind of movement was observed from time to time: a twitching flexion of the penile tip (TFPT) occurring simultaneously with the myoclonic jerks of limbs and body typically seen during PS episodes (Table 2). Those flexions were seen only during PS and their presence constitutes an additional sign of PS episodes.

One outstanding fact is that the penile posture displayed at the moment of PS initiation persisted unaltered throughout the PS episode. If, for example, the transition from SWS to PS occurs when the penis is in a curved posture such as shown in Fig. 2D it will remain frozen in that posture.

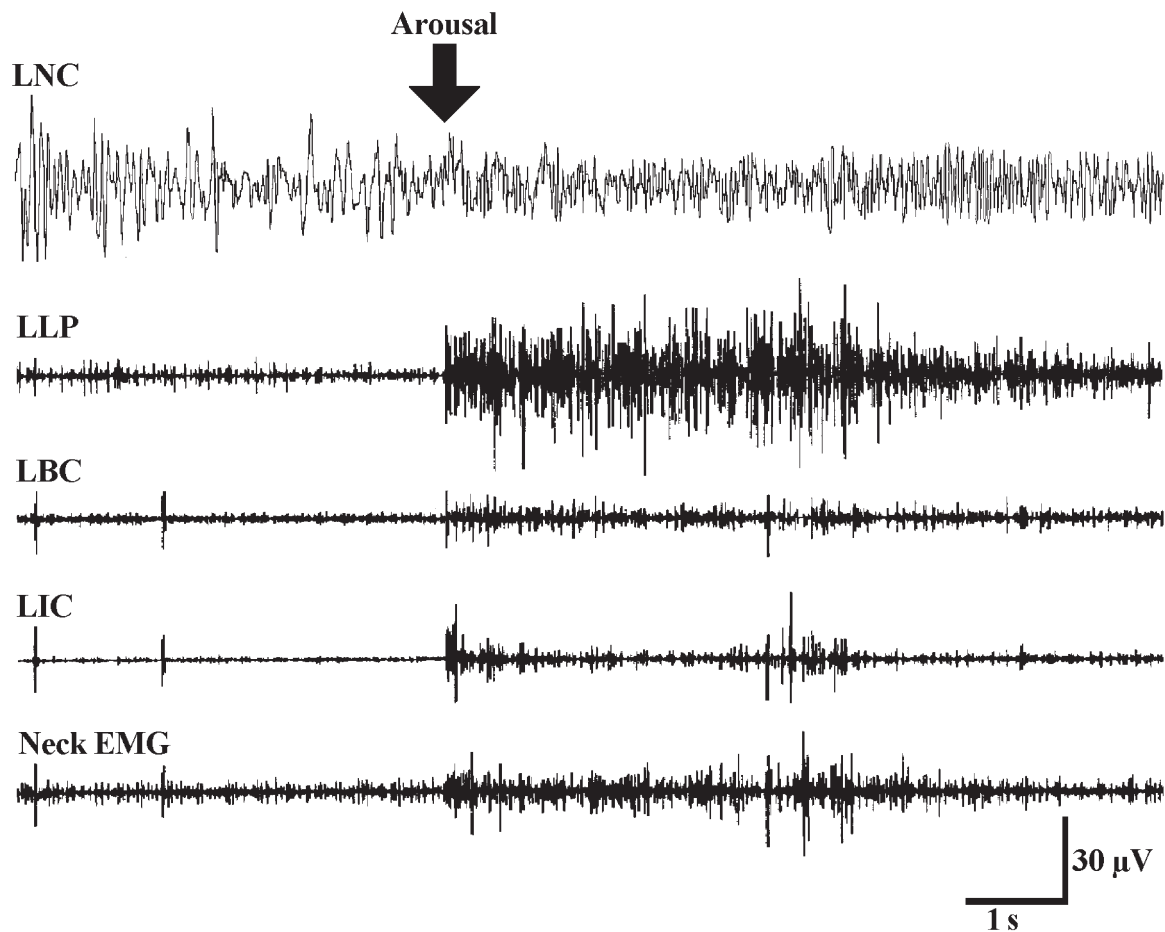
In one exceptional case, a dramatic demonstration of the absence of penile erection was provided when an observer took gently the middle part of the penis between his fingers. On this

occasion the penis remained hanging in sharp acute angle between the finger tips.

**EMG of penile muscles.** It was permanently absent from all penile muscles showing that they share the generalized PS atonia (Fig. 3).

#### **Animals submitted to LP bilateral section**

After the LP section, the penis remained permanently out of the skin receptacle. It was seen hanging immobile across the different states wakefulness and sleep. This is represented by: (i) disappearance of the retraction seen during W or when sensory stimuli are presented; (ii) neither movements nor SWS erections appeared whereas the limb extensions accompanying erections in intact animals continue to occur. However, during the extensions, the EMG of the remaining intact muscles (IC and BC) continues to exhibit the increase seen during erections in normal animals. Those changes became permanent and were still observed 2 months after the operation. Near the end of this period, one of the animals showed ulcers and edema in the penile skin. This animal was immediately sacrificed to avoid suffering.



**Figure 5.** Effect of an arousing sound during SWS. Note the immediate activation of the EEG and of all penile muscles. LNC: Left neocortex; LLP: Left levator penis; LBC: Left bulbocavernosus; LIC: Left ischiocavernosus; EMG: Electromyogram.

#### Animals submitted to 24 h EEG recordings with visual observation of the penis

In the five animals submitted to continued 24 h recordings (Table 1) we could ascertain by visual observation, during the dark period, the presence of all the penile phenomena found in the animals with 8 h sessions with lights on. Three of these animals, were submitted to 30 °C of ambient temperature. This temperature suppresses the tremor and in this case, the penile phenomena were still equally present.

#### DISCUSSION

Our results show several interesting penile phenomena during W, SWS and PS. During W, the contracted LP maintains the penis within its receptacle. This presumably protects the penis from trauma. This interpretation is supported by the effect of LP bilateral section. In one of the animals, the penile skin became edematous and showed ulcers. This was probably because of erosion by rubbing against the floor or by the animals walking over their penis.

Penile non erectile protrusion was continuously seen throughout SWS and PS. The retention of the organ within

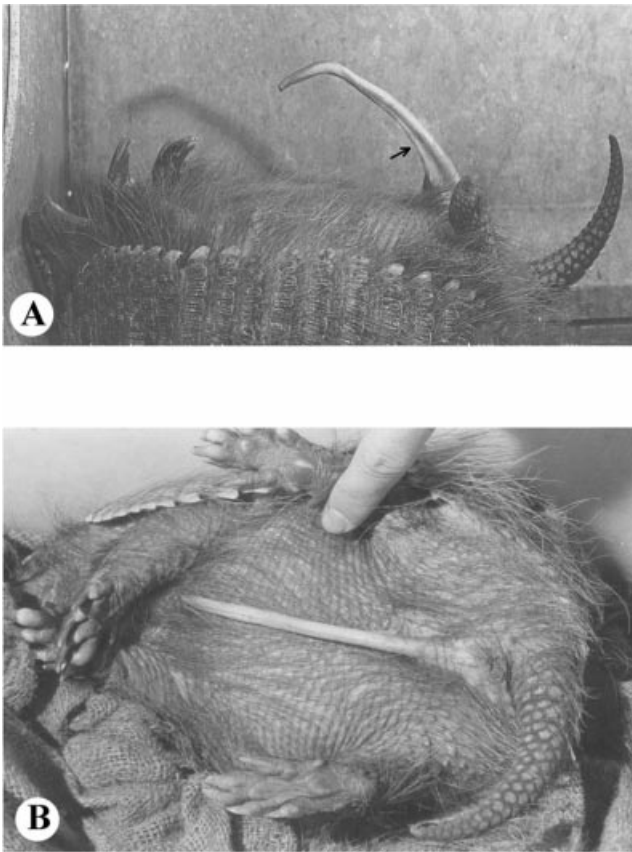
its receptacle never occurs during sleep. A great decrease of LP EMG was observed simultaneously with protrusions. This suggests that muscular relaxation is at least one of the factors determining that phenomenon. This interpretation is supported by the effect of pentobarbital anesthesia. However a participation of penile blood engorgement cannot be excluded if we consider that the penis possesses erectile structures.

Concerning the variety of complex penile movements with undulatory, curving and flagellum-like components, alternate LP relaxations and contractions might explain it.

One may wonder if the tremor of the limbs observed during the initial minutes of SWS might influence the penile movements and erections. This possibility must be excluded because of the following facts: (i) movements and erections are equally observed when SWS attains stages SWS2 and SWS3. During these stages, the tremor is not observed. (ii) when the animals with 24 h recordings were submitted to 30 °C of ambient temperature, movements and erections were equally seen, in spite of the absence of tremor.

We point out the occurrence of the same high LP muscle activity during erection as during waking. This requires an explanation since during W the penis is completely retracted within the skin receptacle. Regarding this fact, we think that



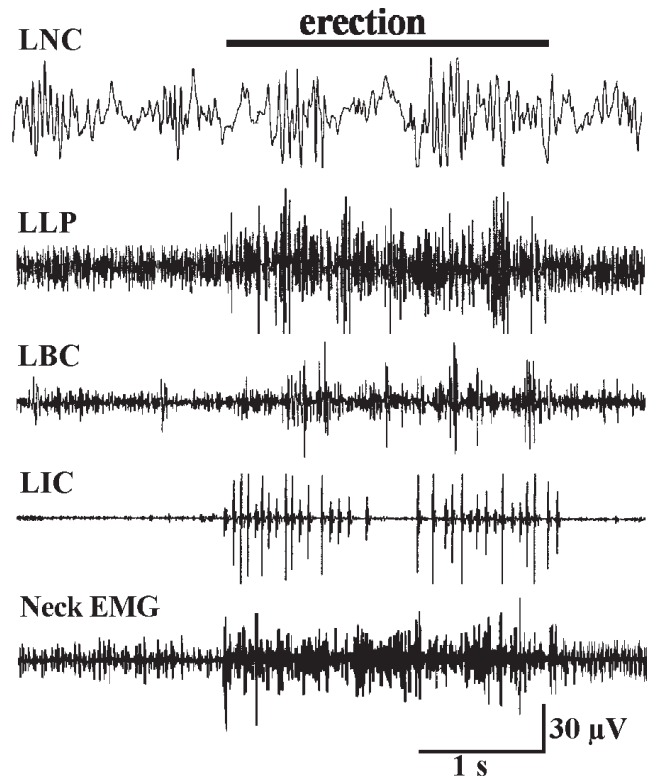


**Figure 6.** Arch-like erection during SWS. (A) Lateral view. Note the bulging of contracted LP (arrowhead), (B) Photograph from above during erection.

EMG activity is explained by the active nature of the penile retraction and permanence in the skin receptacle. The LP plays a very important role both in retraction and erection. The LP role in maintaining the penis within the skin receptacle is strongly suggested by the high EMG activity observed as long as the penis remains there. This is further supported by the effect of general anesthesia, SWS (in the periods of penile immobility) or LP transverse section, which determine permanent protrusion. On the other hand, the role in erection is indicated by the effect of LP sections, which permanently suppress erections.

The continued neck EMG high activity during SWS penile movements (Fig. 4) also requires an explanation, since the animal is sleeping on its back. We think that this is explained by the strong curvature of the almost rigid carapace that never permits the head to be laid down on the floor.

The precise mechanism of the erectile events is not known and only further investigations will elucidate it. We think that this might be caused by the harmonic interplay of muscular actions and vascular engorgement in corpora cavernosa. In fact, penile erection in mammals takes place with the participation of both kinds of phenomena (Creed *et al.* 1991; Deysach 1939; Korenman 1992; Kelly 1999). However, in our case, no erection takes place without LP action. This



**Figure 7.** Neocortical and EMG activity of penile muscles during SWS erections. Note the short EMG activation concomitant with the changes in body posture and the bursts of ischiocavernosus muscles. LNC, left neocortex; LLP, left levator penis; LBC, left bulbocavernosus; LIC, left ischiocavernosus.

indicates that the latter is the most important factor. There are three additional facts supporting this interpretation: (i) the almost instantaneous erectile onsets and offsets, strongly suggesting a muscular action; (ii) the bulging of the contracted muscles which can be directly seen by the observer (see Fig. 6); (iii) the instantaneous onsets and offsets of increased LP EMG (see Fig. 7). It must be admitted that, in spite of the essential role of LP muscles, a participation of some degree of penile engorgement cannot be excluded. This is suggested by the presence of erectile structures. Presumably this point could be clarified by EMG and simultaneous pressure monitoring of the erectile tissues in future experiments. However, that participation, if any, cannot produce, by itself, the erectile episodes. This is indicated by their permanent disappearance after the bilateral LP section. Penile engorgement probably only helps to add penile consistency while the organ is being directed by the LP. Additionally, after LP section, the increase of EMG activity in the remaining intact penile muscles, persist during the limb extensions accompanying the erections. We interpret this fact as a further indirect support to the LP role.

In view of the occurrence of complex penile movements and powerful erections one may wonder if it suggests dreaming activity during SWS. Perhaps this possibility must not be underestimated.

The most salient feature of PS is the total absence of penile erections and movements. The penis remains completely protruded, flaccid and immobile throughout that phase. Only the twitching flexion of the penile tip is observable from time to time, coinciding with the jerks of body muscles characteristic of PS. We think that this flexion is simply an expression of those jerks in that tip.

The absence of PS erectile events indicates that during the PS atonia no vascular engorgement is capable of inducing them. This is indicated by the fact that curved or flexed penile postures displayed at the moment of PS initiation persisted unaltered throughout the PS episode. This is an important fact because it demonstrates absence of penile rigidity. In brief, the absence of PS erections appears because of: (i) atonia of penile muscles which share the generalized PS atonia; (ii) lack of vascular phenomena capable of producing penile rigidity by themselves.

According to our results, it is evident that PS erectile events are not a universal phenomenon of mammalian physiology. Without doubt, PS mechanisms are not linked to the neural system controlling the erections. This fact might lead to important heuristic consequences.

The repeated instantaneous onsets and offsets of erections separated by repeated protrusions in animals submitted to contact with females strongly suggest that they are voluntary phenomena. Therefore, they should be under the control of brain motor areas.

Schmidt *et al.* (1994) gave the first experimental evidence of penile erections during PS in the rat. These authors demonstrated that BC and IC muscles showed EMG characteristic bursts during PS. This means that those muscles are spared from the general PS atonia. In sharp contrast with the rat, BC, IC and LP muscles of this armadillo exhibit complete atonia during PS. Presumably, this is related to its peculiar erectile mechanisms depending upon somatic muscles under the control of brain and spinal motor areas. The absence of penile erection might be simply because of the fact that penile muscles share the generalized PS atonia.

Lastly, we wish to point out that the visual observation of animals with 24 h EEG recordings showed the occurrence of penile movements and erections during SWS as well as the complete absence of erections during PS. This indicates that the penile phenomena reported for the 8 h sessions are also observed in the 24 h recordings, which include the dark period.

## REFERENCES

Affanni, J. and García Samartino, L. Comparative study of electrophysiological phenomena in the olfactory bulb of some South

- American marsupials and edentates. In: L. Bolis, R. Keynes and S. Maddrell (Eds) *Comparative Physiology of Sensory Systems*. Cambridge University Press, New York, 1984, 315–332.
- Affanni, J., García Samartino, L. and Morita, M. Observaciones sobre la actividad eléctrica del neocortex, paleocortex y bulbo olfatorio de *ChaetophRACTUS villosus*. *Rvta. Soc. Argentina Biol.*, 1968, 44: 189–196.
- Affanni, J., Lisogorsky, E. and Scaravilli, A. Sleep in the giant South American armadillo *Priodontes giganteus* (edentata, mammalia). *Experientia*, 1972, 28: 1046–1047.
- Benítez, I., Aldana Marcos, H. and Affanni, J. M. The most salient features of the encephalon of the Armadillo *ChaetophRACTUS villosus*. *Com. Biol.*, 1994, 12: 57–73.
- Cabrera, A., and Yepes, J. *Mamíferos Sudamericanos*. Comp. Argentina de Editores, Buenos Aires, 1940, 248–250.
- Casanave, E. and Affanni, J. M. Body temperature of the armadillo *ChaetophRACTUS villosus* (Mammalia, Dasypodidae). *Arch. Int. Physiol. Biochim. Bioph.*, 1994, 102: 243–246.
- Cervino, C. *Estudio cuantitativo de dos nuevos ritmos bioeléctricos de los bulbos olfatorios registrados en el armadillo sudamericano ChaetophRACTUS villosus* (Mammalia, Dasypodidae). MS Doctoral Thesis. Facultad de Ciencias Exactas y Naturales, Universidad de Buenos Aires, Buenos Aires, 1997, 529, pp.
- Creed, K. E., Carati, C. J. and Kreogh, E. J. The physiology of penile erection. In: S. R. Milligan (Ed.) *Oxford Reviews of Reproductive Biology*, Vol. 13. Oxford University Press, New York, 1991.
- Deysach, L. J. The comparative morphology of erectile tissue of the penis with special emphasis on the probable mechanism of erection. *Am. J. Anat.*, 1939, 64: 111–131.
- García Samartino, L., Affanni, J., Casanave, E., Ferrari, R. and Iodice, O. On the presence of a peculiar alpha rhythm in the olfactory tubercle of waking armadillos. *Electroenceph. Clin. Neurophysiol.*, 1987, 66: 185–190.
- García Samartino, L., Scaravilli, A., Affanni, J. and Cinto, R. Estudio cuantitativo de la vigilia y el sueño en *ChaetophRACTUS villosus* (Mammalia, Dasypodidae). *Physis*, 1974, 33C: 145–150.
- Grassé, P. *Traité de Zoologie*. Masson y Cie, Paris, 1955, TS XVII, F, 1182.
- Holmes, G., Chapple, W., Leipheimer, R. and Sachs, B. Electromyographic analysis of male rat perineal muscles during copulation and reflexive erections. *Physiol. Behav.*, 1991, 49: 1235–1246.
- Kelly, D. A. Expansion of the tunica albuginea during penile inflation in the nine banded armadillo *Dasypus novemcinctus*. *J. Exp. Biol.*, 1999, 202: 253–265.
- Korenman, S. G. Sexual dysfunction. In: J. D. Wilson and D. W. Foster (Eds) *Williams Textbook of Endocrinology*. W.B. Saunders Co., Philadelphia, 1992, 1033–1048.
- Papini, M., Mustaca, A. and Affanni, J. Discrimination learning in the Armadillo (*ChaetophRACTUS villosus*). A study of positional strategies. *J. Gen. Psychol.*, 1985, 112: 119–127.
- Papini, M., Mustaca, A. and Affanni, J. Spatial learning in South American opossums and armadillos. *J. Gen. Psychol.*, 1984, 111: 45–55.
- Schmidt, M., Valatx, J., Schmidt, H., Wauquier, A. and Jouvet, M. Experimental evidence of penile erections during paradoxical sleep in the rat. *Neuroreport*, 1994, 5: 561–564.
- Walker, E. *Mammals of the World*, 2nd edn. J. Hopkins Press, Baltimore, 1968, 482–503.