

Accuracy of Diagnostic Tests for *Schistosoma mansoni* Infection in Asymptomatic Eritrean Refugees: Serology and Point-of-Care Circulating Cathodic Antigen Against Stool Microscopy

Afona Chernet^{1,2}, Kerstin Kling^{1,2}, Véronique Sydow^{1,2}, Esther Kuenzli^{1,2}, Christoph Hatz^{1,2}, Jürg Utzinger^{1,2}, Lisette van Lieshout³, Hanspeter Marti^{1,2}, Beatrice Nickel^{1,2}, Niklaus D. Labhardt^{1,2}, Andreas Neumayr^{1,2}

¹Swiss Tropical and Public Health Institute and ²University of Basel, Switzerland; and ³Department of Parasitology, Leiden University Medical Center, The Netherlands

Background. The unprecedented increase in number of African refugees arriving in Europe is confronting clinicians and general practitioners with the question of whether or not and how to screen migrants from endemic regions for *Schistosoma mansoni* infection.

Methods. We assessed the accuracy of 3 different diagnostic tests for *S. mansoni* infection (stool microscopy [samples prepared by sedimentation technique], serology, and point-of-care circulating cathodic antigen [POC-CCA] urine cassette test) in 107 newly arrived asymptomatic Eritrean refugees in Switzerland.

Result. Sixty-three study participants (59%) tested positive by at least 1 of the 3 methods. Thirty-seven participants (35%) were considered to have active schistosomiasis, either due to the detection of parasite eggs in stool and/or the presence of a concordant positive serology and urine POC-CCA test, which we consider to be a suitable surrogate marker of active infection. Of 23 microscopy-positive participants, 22 were positive by serology (95.7% sensitivity) and 21 were positive by the urine POC-CCA test (91.3% sensitivity). The combination of serology and urine POC-CCA testing detected all 23 microscopy-positive study participants (100% sensitivity).

Conclusions. With a sensitivity of 100% (95% confidence interval, 82.2%–100%), the combination of serology plus urine POC-CCA testing appears to be the most sensitive screening option for asymptomatic *S. mansoni* infection in Eritrean refugees, compared with stool sedimentation microscopy.

Keywords. Eritrea; POC-CCA; refugees; schistosomiasis; screening.

More than 250 million people are affected by schistosomiasis, a snail-borne parasitic disease with an estimated global burden of 2.6 million disability-adjusted life years [1, 2]. Schistosomiasis is endemic in tropical and subtropical countries with >90% of cases concentrated in Africa [3, 4]. Recently, an outbreak of urogenital schistosomiasis occurred in Corsica, France, with >120 confirmed cases among local people and tourists [5]. Although often asymptomatic, chronic long-standing infections may lead to significant morbidity and mortality.

In recent years, the unprecedented increase in number of African refugees arriving in Europe [6] is confronting

clinicians and general practitioners with the question of whether or not to screen migrants from endemic regions for schistosomiasis [7, 8], especially as early recognition and treatment of asymptomatic patients offers the opportunity to prevent progression to symptomatic disease and considerable downstream sequelae [9].

The most widely used diagnostic tests for schistosomiasis are microscopy for the detection of parasite eggs in stool or urine, serological assays for the detection of *Schistosoma*-specific antibodies in blood, and a commercially available point-of-care (POC) test for the detection of circulating cathodic antigen (CCA) in urine [10]. As CCA is produced by live developing and adult worms only, its detection is, like the detection of eggs, considered to be indicative for active infection [11].

We assessed the accuracy of the aforementioned tests for the diagnosis of *Schistosoma mansoni* among asymptomatic Eritrean refugees who had arrived in Switzerland <24 months ago. Our objective was to identify a practical and accurate way of screening this special risk group for *S. mansoni* infection.

Received 24 January 2017; editorial decision 31 March 2017; accepted 17 April 2017; published online April 19, 2017.

Correspondence: A. Neumayr, Swiss Tropical and Public Health Institute, PO Box, Socinstrasse 57, CH-4002 Basel, Switzerland (andreas.neumayr@unibas.ch).

Clinical Infectious Diseases® 2017;65(4):568–74

© The Author 2017. Published by Oxford University Press for the Infectious Diseases Society of America. All rights reserved. For permissions, e-mail: journals.permissions@oup.com. DOI: 10.1093/cid/cix366

METHODS

This diagnostic accuracy study was conducted as part of a cross-sectional survey, screening Eritrean refugees living in centers for asylum seekers in 2 cantons of northwestern Switzerland (Basel-Stadt and Basel-Landschaft) for the prevalence of infectious diseases (ie, intestinal parasitic infections, schistosomiasis, malaria, syphilis, human immunodeficiency virus, hepatitis B virus, and hepatitis C virus) and noncommunicable health issues (ie, posttraumatic stress disorder, arterial hypertension, dyslipidemia, impaired glucose tolerance, and vitamin D deficiency). Using the cantonal refugee registries, all immigrants registered in these 2 cantons, aged ≥ 16 years who arrived from Eritrea within the past 24 months ($n = 151$), were contacted through invitation letter, followed up by a phone call ($n = 121$). All asymptomatic Eritrean migrants fulfilling the inclusion criteria ($n = 107$) gave written informed consent and were enrolled (Figure 1). Asymptomatic was defined as currently not having any health issue the participant would consider relevant enough to seek medical care.

Recruitment lasted from February to November 2016. After a medical interview and a clinical assessment, all participants underwent blood sampling, provided a urine sample, and received 2 stool containers to be filled on 2 different days with at least 10 g of stool. To maximize the yield of microscopic detection of helminth eggs, the full amount of stool of each sample was processed using a sedimentation technique (note: no quantitative assessment/egg count of the positive samples was conducted). The samples were suspended in 0.9% saline (NaCl) and passed through a double layer of gauze into a conical sedimentation cup. The sedimentation cup was then filled with saline and left standing for an hour to let the heavier eggs

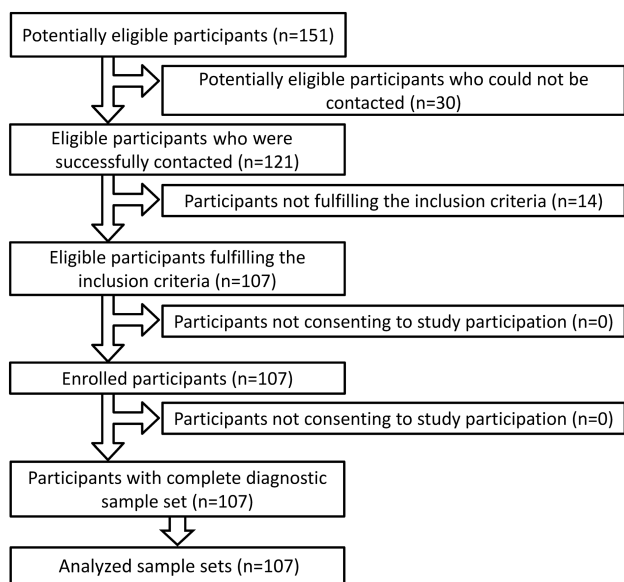


Figure 1. Flow of recruitment of study participants.

settle on the bottom. After 1 hour, the supernatant was poured off and one-half of the sediment was examined under a microscope. With the other half, an ether concentration method was performed [12, 13]. Each microscopic investigation was independently read by 2 senior laboratory technicians, without having knowledge of the results of the other tests. The results of the microscopic examinations were pooled for each patient. Analysis of stool sediments was performed by well-trained and highly experienced staff from the Diagnostic Center of the Swiss Tropical and Public Health Institute (Swiss TPH), which serves as the national reference laboratory for human parasitic diseases in Switzerland.

Schistosoma-specific serology consisted of a panel of 3 in-house assays (2 enzyme-linked immunosorbent assays [ELISAs] for the detection of antibodies against soluble egg-antigen and antibodies against adult worm antigen, and 1 confirmatory immunofluorescent antibody test [IFAT]) with sections of adult worms used at the diagnostic center of Swiss TPH. These tests are comparable to commercial available tests using the same antigens [14]. The panel has been validated to have an overall sensitivity and specificity for *S. mansoni* infections of 98% and 96%, respectively [15, 16]. Infections by other *Schistosoma* species are detected as well with a slightly lower sensitivity. The results of the ELISAs and the IFAT were interpreted according to the cutoffs previously determined by receiver operating characteristic analysis with 50 sera from healthy Swiss blood donors, 20 sera from *S. mansoni*-infected patients, and 120 sera of other helminth infections [15]. The final interpretation for *Schistosoma* serology based on the results of all 3 tests was reported according to the following criteria: “negative” if all tests were negative or if 2 tests were negative and 1 test was inconclusive, and “positive” if at least 2 of 3 tests were positive; all other combinations were reported as inconclusive.

Potential serological cross-reactivity among tissue parasites was assessed by parallel testing for *Echinococcus* species, *Fasciola hepatica*, *Filaria* species, *Strongyloides stercoralis*, *Toxocara* species, and *Trichinella* species-specific antibodies by routine ELISA testing at the Diagnostic Center of Swiss TPH.

Urine analysis included POC dipstick testing for protein, glucose, ketones, hemoglobin, bilirubin, urobilinogen, acetone, nitrite, leukocytes, and pH (Combur-9 test, Roche Diagnostics, Basel, Switzerland) and testing for the presence of *Schistosoma*-specific CCA by using the immunochromatographic POC-CCA cassette test (Rapid Medical Diagnostics, Pretoria, South Africa). This test has been commercially available since 2008 and has, according to the manufacturer’s information, a sensitivity of 100% if infection intensity is >400 eggs per gram of stool (EPG), decreasing to about 70% if infection intensity is low (<100 EPG). The specificity in nonendemic populations is reported to be around 95% [10]. POC-CCA test was performed according to the manufacturer’s instructions. Although the POC-CCA test is primarily considered a qualitative test, we additionally assessed the

test results semiquantitatively. Any visible pink band on the POC-CCA urine cassette test was documented according to its intensity as “weak positive” or “clearly positive.” The absence of a band or a faint grayish background band was interpreted and documented as “negative.” POC-CCA test results were independently read by 2 laboratory technicians, without having knowledge of the results of the other tests. In case of discrepancies, a third person was consulted to obtain a majority consensus. The presence of blood eosinophilia, defined as a cell count of ≥ 400 eosinophils/ μL , was assessed by manually performed differential blood count.

The sensitivity, specificity, and negative predictive value of the index tests serology and POC-CCA, as well as their combination, were compared to stool microscopy as reference standard. As we consider a conservative approach reasonable when relying on indirect parasitological tests and deciding on whether or not to treat a person, all “inconclusive” serology results were counted as “positive” in the analysis.

The correlation between the results of the 3 evaluated diagnostic test methods and the presence of blood eosinophilia and concomitant intestinal helminth infection, as well as the correlation between POC-CCA test intensity and the results of serology and stool microscopy and the presence of eosinophilia, was assessed by χ^2 or Fisher’s exact test, as appropriate, using Stata version 13 software (StataCorp, College Station, Texas).

The study protocol was approved by the institutional research commission of Swiss TPH (reference number FK 120) and the ethics committee of Northwest and Central Switzerland (reference number EKNZ 2015–353).

RESULTS

A total of 107 asymptomatic Eritrean refugees (95 men, 12 women; median age, 25 years [range, 19–29 years]) were enrolled into the study (Figure 1). Sixty-three of the 107 study

participants (59%) tested positive for schistosomiasis by at least 1 of the 3 performed diagnostic tests.

The results of the 3 diagnostic tests are shown in Figure 2. The concordance and discordance of the positive test results of the 3 different diagnostic tests are depicted in Figure 3. The sensitivity, specificity, and negative predictive value of serology, POC-CCA, and the combination of serology and POC-CCA compared to stool microscopy as the diagnostic reference standard are shown in Table 1. From the 23 participants where *Schistosoma* eggs were detected by microscopy, 22 were positive in serology and 21 were positive in the POC-CCA test. The calculated sensitivity was 95.7% and 91.3% for the serological test and the POC-CCA urine cassette test, respectively. The combination of both tests detected all 23 samples, which were also positive in microscopy (100% sensitivity).

All *Schistosoma* eggs detected by stool microscopy were *S. mansoni* eggs. The only other helminth species detected by stool microscopy was *Hymenolepis nana*, with eggs found in 11 of the 107 (10%) study participants.

Blood eosinophilia was present in 16 of the 107 (15%) participants (Table 2). In 10 of these 16 cases, at least 1 of the 3 schistosomiasis diagnostic tests was positive. In the remaining 6 cases, no cause of blood eosinophilia was identified by any of the performed tests.

The correlation between the results of the 3 schistosomiasis diagnostic tests and the presence of blood eosinophilia as well as the presence of *H. nana* infection is shown in Table 2. The correlation between the presence of blood eosinophilia and *H. nana* infection is shown in Table 3. Table 4 shows the correlation between the intensity of POC-CCA test results and serology and microscopy results as well as the presence of blood eosinophilia. Table 5 shows the kappa (κ)

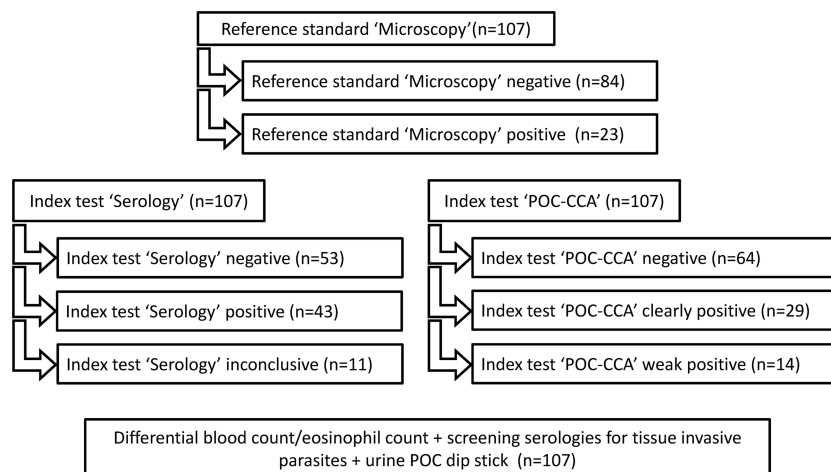


Figure 2. Number of complete sample sets and results of reference standard and index tests. Abbreviation: POC-CCA, point-of-care circulating cathodic antigen.

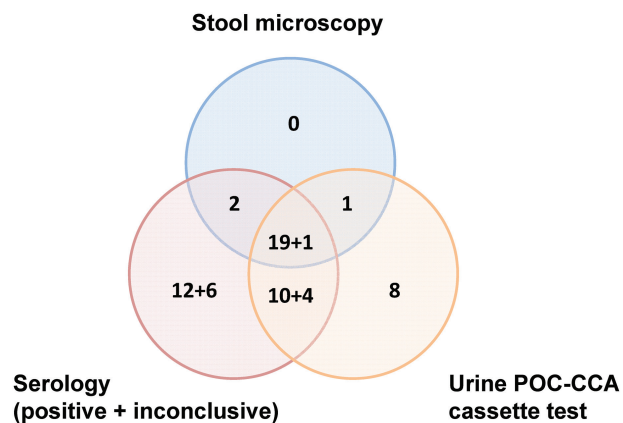


Figure 3. Concordance and discordance of positive screening results for *Schistosoma mansoni* in 63 of 107 tested asymptomatic Eritrean refugees, stratified by 3 diagnostic tests. Abbreviation: POC-CCA, point-of-care circulating cathodic antigen.

analysis, assessing the degree of agreement among performed diagnostic tests.

The parallel testing of all 107 serum samples for potential cross-reactivity to other concomitantly or previously present tissue-invasive helminth infections did not yield any positive result for the tested helminth infections (data not shown). The urine dipstick test for protein, glucose, ketones, hemoglobin, bilirubin, urobilinogen, acetone, nitrite, leukocytes, and pH was unremarkable in all 107 cases.

DISCUSSION

Diagnosing schistosomiasis can be challenging as the validity and reliability of currently available diagnostic tests are, especially if used separately, limited [17]. The demonstration of eggs in stool or urine by microscopy can be difficult as the day-to-day variation of egg excretion may be considerable and the

Table 1. Sensitivity, Specificity, and Negative Predictive Value of Serology, Point-of-Care Circulating Cathodic Antigen (POC-CCA), and the Combination of Serology and POC-CCA, Compared to Stool Microscopy as Reference Standard for Screening of *Schistosoma mansoni* Among 107 Eritrean Refugees

Diagnostic Test	Result	Stool Microscopy ^a	
		Positive	Negative
Serology	Positive ^b	22	32
	Negative	1	52
	Sensitivity	95.7%	(95% CI, 76.0%–99.8%)
	Specificity	61.9%	(95% CI, 50.6%–72.1%)
	NPV	98.1%	(95% CI, 88.6%–99.9%)
POC-CCA	Positive	21	22
	Negative	2	62
	Sensitivity	91.3%	(95% CI, 70.5%–98.5%)
	Specificity	73.8%	(95% CI, 62.9%–82.5%)
	NPV	96.9%	(95% CI, 88.2%–99.5%)
Serology and/or POC-CCA	Positive ^b	23	40
	Negative	0	44
	Sensitivity	100%	(95% CI, 82.2%–100%)
	Specificity	52.4%	(95% CI, 41.3%–63.3%)
	NPV	100%	(95% CI, 90.0%–100%)

Abbreviations: CI, confidence interval; NPV, negative predictive value; POC-CCA, point-of-care circulating cathodic antigen.

^aMicroscopy of sediment of 2 stool samples (≥ 10 g stool/sample).

^b“Inconclusive” serology results were counted as positive.

detection of eggs in individuals with a low worm burden may even be impossible [18, 19]. Although not perfect, microscopy is generally considered the “gold standard” reference method when evaluating the accuracy of diagnostic assays for schistosomiasis. In this regard, it deserves to be highlighted that our used stool preparation technique, using at least 10 g of stool, is considerably more sensitive than the widely used Kato-Katz technique. Indeed, a single Kato-Katz thick smear only examines 41.7 mg of stool [20] and, hence, the total volume of duplicate or

Table 2. Correlation Between the Results of 3 Different *Schistosoma mansoni* Screening Methods and the Presence of Blood Eosinophilia ($n = 16$) and *Hymenolepis nana* Infection ($n = 11$) Among 107 Eritrean Refugees

Diagnostic Test	Result	Eosinophilia		PValue ^a	<i>Hymenolepis nana</i>		PValue
		Present	Absent		Present	Absent	
Serology	Positive ^c	10	44	.297	6	48	.775 ^a
	Negative	6	47		5	48	
POC-CCA	Positive	9	34	.155	5	37	.657 ^a
	Negative	7	57		6	59	
Serology + POC-CCA ^d	Positive ^c	9	25	.023	8	55	.519 ^b
	Negative	7	66		3	41	
Stool microscopy	Positive	8	15	.003	3	20	NA
	Negative	8	76		8	76	

Abbreviations: NA, not applicable; POC-CCA, point-of-care circulating cathodic antigen.

^a χ^2 test.

^bFisher's exact test.

^c“Inconclusive” serology results were counted as positive.

^dConcordant positive test results with both methods.

Table 3. Correlation Between the Presence of Blood Eosinophilia and the Detection of *Hymenolepis nana* Eggs by Stool Microscopy in 107 Eritrean Refugees

Stool Microscopy	Result	Eosinophilia		PValue ^a
		Present	Absent	
<i>Hymenolepis nana</i>	Positive	1	10	.332
	Negative	15	81	

^aFisher's exact test.

triplicate Kato-Katz thick smears is still 2 orders of magnitude lower than what has been examined in the current study. Yet, multiple Kato-Katz thick smears are frequently utilized as reference standard in studies evaluating the accuracy of diagnostic tests in *S. mansoni* and soil-transmitted helminth infections [21, 22]. A limitation of the applied sedimentation method compared to Kato-Katz is that Kato-Katz allows estimating the intensity of infection, as expressed by EPG.

A limitation of serology is that, compared to microscopy and antigen detection, *Schistosoma*-specific antibodies may remain detectable for several years after successful medical treatment or the natural death of the parasite, and that such "serological scars" cannot be differentiated from active infection [14]. In addition, cross-reactivity of assays in the case of previous or concomitant infection with other parasites may be a problem. Our performed serological screening for other tissue-invasive helminth infections (*Echinococcus* species, *Fasciola hepatica*, *Filaria* species, *S. stercoralis*, *Toxocara* species, and *Trichinella* species) did not reveal any evidence of false-positive *Schistosoma* serology or POC-CCA testing due to the presence of these helminth infections. There was no evidence that intestinal *H. nana* infection may lead to false-positive *Schistosoma* serology (Table 2).

The downside of the POC-CCA test is that false-positive results have been described, in particular if traces in band intensity are classified as being positive [23]. False-positive results also seem to be associated with urinary tract infection, hematuria, and pregnancy [10, 24]. This is primarily attributed to the fact that the polysaccharide structure of CCA contains

Table 4. Correlation Between the Intensity of Point-of-Care Circulating Cathodic Antigen Results and Serology and Microscopy Results as Well as the Presence of Eosinophilia

Diagnostic Test	Result	POC-CCA		PValue ^a
		Clearly Positive	Weak Positive	
Serology	Positive	22	7	.199
	Inconclusive	2	3	
	Negative	5	4	
Microscopy	Positive	18	3	.022
	Negative	11	11	
Eosinophilia	Present	7	1	1.0
	Absent	11	2	

Abbreviation: POC-CCA, point-of-care circulating cathodic antigen.

^aFisher's exact test.

repeating units of Lewis-X trisaccharide, a molecule that is a common epitope on human cells (especially anti-inflammatory cells like granulocytes) [23]. There was no evidence that intestinal *H. nana* infection may lead to false-positive POC-CCA results (Table 2).

Owing to the aforementioned limitations, a currently unresolved issue is how to interpret test results if only serology or only POC-CCA testing is positive. In this regard, the 3 cases in which eggs were found by microscopy even though serology and POC-CCA results were discordant (Figure 3) warrants attention. These cases illustrate that discordant serology and POC-CCA results should not generally be discarded as false-negative. Nevertheless, it is conceivable that some of the cases which tested positive by serology depict "serological scars" and that some of the cases which only tested positive by POC-CCA depict false-positive results.

As we observed a considerable variability in intensity of the visible band of the POC-CCA test strip, we performed a subgroup analysis and found that clearly positive POC-CCA test results show a statistically significant correlation to the microscopic detection of eggs (Table 4). For samples being positive in 1 or >1 test, the majority of samples with positive serology or microscopy are also clearly positive in POC-CCA, 76% (22/29)

Table 5. Assessing the Degree of Agreement Among Performed Diagnostic Tests by Kappa Coefficient

Diagnostic Test	Result	Stool Microscopy		Kappa			
		Positive	Negative	κ Coefficient	SE	95% CI	Interpretation ^a
Serology	Positive	22	32	0.297	0.073	.24-.53	Fair
	Negative	1	52				
POC-CCA	Positive	21	22	0.155	0.082	.34-.66	Moderate
	Negative	2	62				
Serology and/or POC-CCA	Positive	23	40	0.023	0.062	.20-.44	Fair
	Negative	0	44				

Abbreviations: CI, confidence interval; POC-CCA, point-of-care circulating cathodic antigen; SE, standard error.

^aInterpretation of κ coefficient, reflecting the degree of agreement among diagnostic tests: ≤0, chance/less than chance; 0.01–0.20, slight; 0.21–0.40, fair; 0.41–0.60, moderate; 0.61–0.80, substantial; 0.81–0.99, almost perfect.

and 86% (18/21), respectively. In contrast, inconclusive or negative serology samples or negative microscopy samples yield in approximately 50% clearly positive and in approximately 50% weakly positive POC-CCA result, most likely reflecting the lower intensity of infection. This finding suggests that weakly positive POC-CCA test results largely represent infections with low egg output not readily detectable by microscopy. This observation is supported by data from a recent field study in Tanzania, where digital software-supported reading of the POC-CCA cassette test revealed an improved differentiation between weakly positive “true” bands and nonspecific traces, thereby improving the correlation between test intensity and egg count [25].

In our study, the ratio of POC-CCA-positive cases to microscopy-positive cases (43 to 23) is 1.9 and thus in line with a recently published systematic review concluding that below 50% prevalence by Kato-Katz, the prevalence by POC-CCA assay is between 1.5- and 6-fold higher [26]. The observation that the ratio in our study is at the lower end of the reported range may reflect the comparable high sensitivity of our stool microscopy method. The ratio of serology-positive and inconclusive cases to microscopy-positive cases (54 to 23) is 2.4 and most likely reflects the anticipated high prevalence of “serological scars” in a high-endemicity population [4].

An interesting observation is that the presence of blood eosinophilia shows a statistically significant correlation with the detection of *Schistosoma* eggs by microscopy, whereas no correlation between blood eosinophilia and positive POC-CCA testing is seen (Table 2). Considering that blood eosinophilia is clinically regarded as a supportive surrogate marker for the presence of an active parasite infection, the observation may be interpreted in 2 ways. It may suggest that blood eosinophilia is only seen in the presence of a high parasite burden, resulting in high egg excretion and thus in cases more reliably identified by microscopy. Consequently, it could be argued that POC-CCA testing may be capable of detecting cases with a low parasite burden not leading to blood eosinophilia. However, the lack of correlation between blood eosinophilia and POC-CCA could also be interpreted as an indirect surrogate marker for false-positive results and might reflect the test’s limited specificity. The lack of correlation between blood eosinophilia and positive serology is anticipated in a high-endemicity population due to the high prevalence of “serological scars” [4].

Despite the shortcomings of indirect diagnostic assays, we considered it reasonable to assume that, owing to the test assays’ different operating modes, cases that concordantly tested positive by serology and POC-CCA depict true cases of active infection and that concordant false-positive results are rather unlikely. This assumption is also supported by the observed statistically significant correlation between blood eosinophilia and concordant positive results of serology and POC-CCA testing (Table 2). An auxiliary finding worth mentioning is that we did not find any correlation between blood eosinophilia and the

presence of *H. nana* infection, although a relationship between this intestinal cestode infection and blood eosinophilia is frequently referenced in the literature [27, 28].

A limitation of our study worth mentioning is that we did not perform urine microscopy to rule out *S. haematobium* infection, which could have possibly led to positive serology as well as positive POC-CCA results. However, as no microhematuria has been detected in any of the urine samples and considering that a recent review concluded that in urogenital schistosomiasis CCA test performance is inferior to urine strips for detecting blood [29], we do not consider this issue to possibly have impacted the POC-CCA results of our study.

In conclusion, our data suggest that the combination of serology and POC-CCA is superior to stool microscopy when screening asymptomatic Eritrean refugees for *S. mansoni* infection and that stool microscopy does not contribute to diagnostic accuracy. The presence of blood eosinophilia is supportive of active schistosomiasis, but its absence does not exclude active infection. All cases having a concordant positive serology and POC-CCA test should be considered to have active *S. mansoni* infection. However, considering that untreated chronic schistosomiasis may lead to significant morbidity downstream and considering that treatment with praziquantel is generally well tolerated and inexpensive, the threshold to treat any positive test result should be very low. This conclusion holds, even though some patients may receive unnecessary treatment due to false-positive serology or POC-CCA results.

Note

Potential conflicts of interest. All authors: No reported conflicts of interest. All authors have submitted the ICMJE Form for Disclosure of Potential Conflicts of Interest. Conflicts that the editors consider relevant to the content of the manuscript have been disclosed.

References

- Hotez PJ, Alvarado M, Basañez MG, et al. The Global Burden of Disease study 2010: interpretation and implications for the neglected tropical diseases. *PLoS Negl Trop Dis* 2014; 8:e2865.
- GBD 2015 DALYs and HALE Collaborators. Global, regional, and national disability-adjusted life-years (DALYs) for 315 diseases and injuries and healthy life expectancy (HALE), 1990–2015: a systematic analysis for the Global Burden of Disease Study 2015. *Lancet* 2016; 388:1603–58.
- Colley DG, Bustinduy AL, Secor WE, King CH. Human schistosomiasis. *Lancet* 2014; 383:2253–64.
- Lai YS, Biedermann P, Ekpo UF, et al. Spatial distribution of schistosomiasis and treatment needs in sub-Saharan Africa: a systematic review and geostatistical analysis. *Lancet Infect Dis* 2015; 15:927–40.
- Boissier J, Grech-Angelini S, Webster BL, et al. Outbreak of urogenital schistosomiasis in Corsica (France): an epidemiological case study. *Lancet Infect Dis* 2016; 16:971–9.
- European Commission. Refugee crisis in Europe. Available at: http://ec.europa.eu/echo/refugee-crisis_en. Accessed 30 December 2016.
- Deniaud F, Rouessé C, Collignon A, Domingo A, Rigal L. Failure to offer parasitology screening to vulnerable migrants in France: epidemiology and consequences [in French]. *Sante* 2010; 20:201–8.
- Theuring S, Friedrich-Jänicke B, Pörtner K, et al. Screening for infectious diseases among unaccompanied minor refugees in Berlin, 2014–2015. *Eur J Epidemiol* 2016; 31:707–10.
- Richter J, Bode JG, Blondin D, et al. Severe liver fibrosis caused by *Schistosoma mansoni*: management and treatment with a transjugular intrahepatic portosystemic shunt. *Lancet Infect Dis* 2015; 15:731–7.

10. Rapid Medical Diagnostics. Bilharzia (schistosomiasis). Available at: http://rapid-diagnostics.com/downloads/RMD%20Pamphlet%202011_06_13%20.pdf. Accessed 30 December 2016.
11. van Dam GJ, Bogitsh BJ, van Zeyl RJ, Rotmans JP, Deelder AM. *Schistosoma mansoni*: in vitro and in vivo excretion of CAA and CCA by developing schistosomula and adult worms. *J Parasitol* **1996**; 82:557–64.
12. Marti H, Escher E. SAF—an alternative fixation solution for parasitological stool specimens [in German]. *Schweiz Med Wochenschr* **1990**; 120:1473–6.
13. Utzinger J, Botero-Kleiven S, Castelli F, et al. Microscopic diagnosis of sodium acetate-acetic acid-formalin-fixed stool samples for helminths and intestinal protozoa: a comparison among European reference laboratories. *Clin Microbiol Infect* **2010**; 16:267–73.
14. Hinz R, Schwarz NG, Hahn A, Frickmann H. Serological approaches for the diagnosis of schistosomiasis: a review. *Mol Cell Probes* **2017**; 31:2–21.
15. Nickel B, Sayasone S, Vonghachack Y, Odermatt P, Marti H. *Schistosoma mansoni* antigen detects *Schistosoma mekongi* infection. *Acta Trop* **2015**; 141:310–4.
16. Ampah KA, Nickel B, Asare P, et al. A sero-epidemiological approach to explore transmission of *Mycobacterium ulcerans*. *PLoS Negl Trop Dis* **2016**; 10:e0004387.
17. Utzinger J, Becker SL, van Lieshout L, van Dam GJ, Knopp S. New diagnostic tools in schistosomiasis. *Clin Microbiol Infect* **2015**; 21:529–42.
18. de Vlas SJ, Gryseels B. Underestimation of *Schistosoma mansoni* prevalences. *Parasitol Today* **1992**; 8:274–7.
19. Utzinger J, Booth M, N’Goran EK, Müller I, Tanner M, Lengeler C. Relative contribution of day-to-day and intra-specimen variation in faecal egg counts of *Schistosoma mansoni* before and after treatment with praziquantel. *Parasitology* **2001**; 122:537–44.
20. Katz N, Chaves A, Pellegrino J. A simple device for quantitative stool thick-smear technique in *Schistosomiasis mansoni*. *Rev Inst Med Trop Sao Paulo* **1972**; 14:397–400.
21. Leuenberger A, Nassoro T, Said K, et al. Assessing stool quantities generated by three specific Kato-Katz thick smear templates employed in different settings. *Infect Dis Poverty* **2016**; 5:58.
22. Knopp S, Mgeni AF, Khamis IS, et al. Diagnosis of soil-transmitted helminths in the era of preventive chemotherapy: effect of multiple stool sampling and use of different diagnostic techniques. *PLoS Negl Trop Dis* **2008**; 2:e331.
23. Polman K, Diakhate MM, Engels D, et al. Specificity of circulating antigen detection for schistosomiasis mansoni in Senegal and Burundi. *Trop Med Int Health* **2000**; 5:534–7.
24. Greter H, Krauth SJ, Ngandolo BN, Alfaroukh IO, Zinsstag J, Utzinger J. Validation of a point-of-care circulating cathodic antigen urine cassette test for *Schistosoma mansoni* diagnosis in the Sahel, and potential cross-reaction in pregnancy. *Am J Trop Med Hyg* **2016**; 94:361–4.
25. Casacuberta M, Kinunghi S, Vennervald BJ, Olsen A. Evaluation and optimization of the circulating cathodic antigen (POC-CCA) cassette test for detecting *Schistosoma mansoni* infection by using image analysis in school children in Mwanza Region, Tanzania. *Parasite Epidemiol Control* **2016**; 1:105–15.
26. Kittur N, Castleman JD, Campbell CH Jr, King CH, Colley DG. Comparison of *Schistosoma mansoni* prevalence and intensity of infection, as determined by the circulating cathodic antigen urine assay or by the Kato-Katz fecal assay: a systematic review. *Am J Trop Med Hyg* **2016**; 94:605–10.
27. Neumayr A. Antiparasitic treatment recommendations—a practical guide to clinical parasitology. 1st ed. Hamburg: Tredition GmbH, **2016**.
28. Willcocks B, McAuliffe GN, Baird RW. Dwarf tapeworm (*Hymenolepis nana*): characteristics in the Northern Territory 2002–2013. *J Paediatr Child Health* **2015**; 51:982–7.
29. Ochodo EA, Gopalakrishna G, Spek B, et al. Circulating antigen tests and urine reagent strips for diagnosis of active schistosomiasis in endemic areas. *Cochrane Database Syst Rev* **2015**; 3:CD009579.