

Letters

RESEARCH LETTER

Active Surveillance in Thyroid Microcarcinoma in a Latin-American Cohort

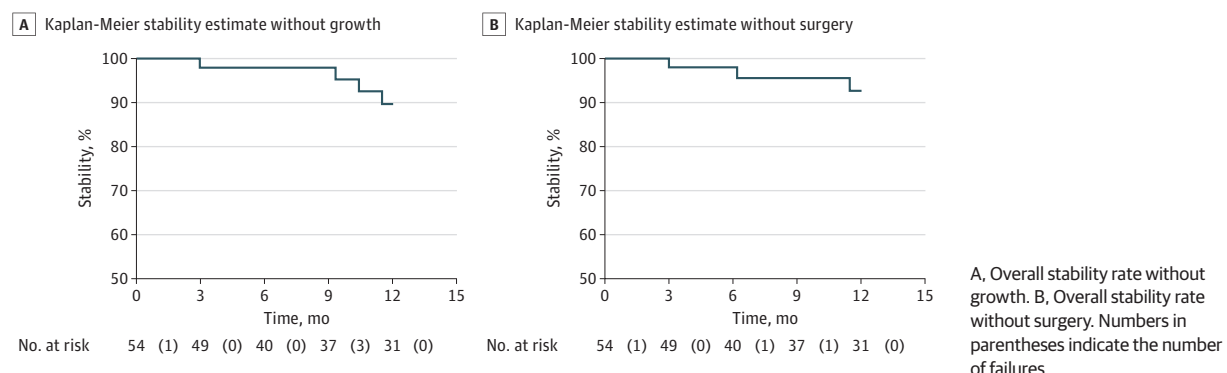
The incidence of thyroid carcinoma is growing worldwide owing to overdiagnosis.¹ Japanese authors have shown that active surveillance of patients with papillary thyroid microcarcinoma is possible.² Some case series have recently been published in Western countries,³ but there are no reports from Latin America. The aim of this study is to report and describe a cohort of patients with thyroid nodules classified as Bethesda categories V to VI and who are under active surveillance.

Methods | This is a report of a prospective cohort from a head and neck cancer center in Medellín, Colombia. All patients were referred to the author as potential candidates for thyroidectomy. Local institutional review board authorization was provided, and written informed consent was waived due to the descriptive character of the study. All had thyroid nodules found in ultrasonographic imaging with fine-needle aspiration biopsy results classified as Bethesda categories V to VI. An active surveillance trial was proposed to patients with low-risk microcarcinoma (<1.5 cm, encapsulated, without evidence of lymph node metastasis) following Japanese and American recommendations^{2,3} (periodic evaluation with ultrasound, immediate consultation if clinical symptoms or lymph nodes appeared, centralized management of the disease, immediate surgery if a significant growth occurred, patient preference). Only patients who accepted the strategy are reported in this study. Data on age, sex, reason for an ultrasound examination, ultrasound risk by American Thyroid Association (ATA) classification, size of the nodule, reason to consider active surveillance and follow-up ultrasounds, and surgical decision were recorded prospectively. A Kaplan-Meier graph was built for stability of the nodule without any growth, without growth more than 3 mm, and need of operation.

Results | A total of 57 patients were analyzed since September 2013. Mean (SD) age was 51.9 (14.5) years (range, 24-85 years). Forty-eight (84%) of the 57 patients were women, and in 55 (96%) the nodule was incidentally discovered. Mean (SD) and median nodule size was 9.7 (4.3) mm and 9 mm (range, 3-26 mm), respectively. Only 9 of 57 (16%) nodules were classified as ATA low risk, whereas 36 (61%) nodules were classified as Bethesda category V. Of the 57 patients, 14 (25%) explicitly expressed the desire for surveillance, and in 36 (63%) patients the proposal of surveillance was based on a nodule size smaller than 1 cm. The median number of follow-up visits was 2 (range, 0-6). Median follow-up was 13.3 months (range, 0-54 months). Of 57 nodules, 16 (28%) grew a mean (SD) of 2 (1.3) mm, but only 2 (3.5%) grew more than 3 mm. Five of 57 (9%) patients underwent surgery (3 owing to nodule growth and 2 for other reasons). All of them had a papillary carcinoma treated with lobectomy. The overall stability rate without growth (Figure, A), without growth more than 3 mm, and without surgery (Figure, B) at 12 months was 90%, 98%, and 92.5%, respectively.

Discussion | Overdiagnosis in thyroid cancer is an important problem.⁴ As the number of incident cases increases, the possibility of harm related to treatment also increases. Most of the new cases are subcentimeter nodules incidentally found by an imaging test, which are biopsied and have high malignancy suspicion.¹ Most of these nodules will not have any detrimental effect on survival, but today, such patients often undergo thyroidectomy. As an alternative, active surveillance protocols are safe in selected cases, avoiding the risks associated with surgery. There are studies on patients in Asia and the United States, but not in Latin America to our knowledge. Some authors have suggested that there are obstacles to surveillance, including physician responsibility (surgeons are not able to do it), physician reimbursement, and patient anxiety,⁵ that are frequent in developing countries, but these may be solved with education, new health policies, and training. Major barriers to implementation of surveillance of

Figure. Kaplan-Meier Survival Curves of Malignant and Suspicious Thyroid Nodules Under Active Surveillance



patients include home located in remote rural areas and lack of insurance, which together impede routine imaging and medical follow-up; patients' low educational level, which impedes understanding of risks and benefits of surveillance; fear on the part of physicians of future legal actions; and resistance to change. This cohort study demonstrates that this approach is feasible in Latin America.

Alvaro Sanabria, PhD

Author Affiliations: Department of Surgery, School of Medicine, Universidad de Antioquia, Medellín, Colombia; Centro de Excelencia en Cirugía de Cabeza y Cuello, CEXCA, Medellín, Colombia.

Corresponding Author: Alvaro Sanabria, PhD, Department of Surgery, School of Medicine, Universidad de Antioquia, Cra 51d, 62-29, Medellín, Antioquia 050010, Colombia (alvarosanabria@gmail.com).

Accepted for Publication: May 27, 2018.

Published Online: August 30, 2018. doi:10.1001/jamaoto.2018.1663

Conflict of Interest Disclosures: The author has completed and submitted the ICMJE Form for Disclosure of Potential Conflicts of Interest and none were reported.

1. Davies L, Welch HG. Current thyroid cancer trends in the United States. *JAMA Otolaryngol Head Neck Surg*. 2014;140(4):317-322. doi:10.1001/jamaoto.2014.1
2. Ito Y, Miyauchi A, Oda H. Low-risk papillary microcarcinoma of the thyroid: a review of active surveillance trials. *Eur J Surg Oncol*. 2018;44(3):307-315. doi:10.1016/j.ejso.2017.03.004
3. Tuttle RM, Fagin JA, Minkowitz G, et al. Natural history and tumor volume kinetics of papillary thyroid cancers during active surveillance. *JAMA Otolaryngol Head Neck Surg*. 2017;143(10):1015-1020. doi:10.1001/jamaoto.2017.1442
4. Sanabria A, Kowalski LP, Shah JP, et al. Growing incidence of thyroid carcinoma in recent years: Factors underlying overdiagnosis. *Head Neck*. 2018; 40(4):855-866. doi:10.1002/hed.25029
5. Haymart MR, Miller DC, Hawley ST. Active surveillance for low-risk cancers—a viable solution to overtreatment? *N Engl J Med*. 2017;377(3):203-206. doi:10.1056/NEJMp1703787

OBSERVATION

Cricopharyngeal Muscle Dysfunction Following Hypoglossal Nerve Stimulator Placement

Hypoglossal nerve stimulation (HGNS) is an alternative treatment to positive airway pressure (PAP) therapy for patients with moderate or severe obstructive sleep apnea (OSA) who cannot tolerate PAP.¹ The implantable HGNS system is comprised of a stimulator lead, implantable pulse generator, and breathing sensor lead. The stimulator lead silicone cuff is placed around distal hypoglossal nerve branches, targeting innervation of intrinsic tongue musculature and the genio-glossus (protrusor muscle), while excluding the styloglossus and hyoglossus (retractor muscles). Activation of these muscles stiffens and protrudes the tongue to open and stabilize the pharyngeal airway. It is considered favorable to include the first cervical spinal nerve (C1) branch to the geniohyoid muscle traveling with the hypoglossal nerve. Geniohyoid activation moves the hyoid and larynx anteriorly and superiorly, assisting in stabilizing the pharyngeal airway to relieve upper airway obstruction.²

Geniohyoid activation also facilitates bolus transfer through the pharyngeoesophageal segment (PES) during swallowing. The PES is a high-pressure zone comprised of the cricopharyn-

geus muscle (CP), inferior pharyngeal constrictor, and proximal esophageal fibers. During swallowing, PES distension occurs from geniohyoid and thyrohyoid traction forces, swallowed bolus weight, and tonic neural input cessation.³ The first cervical spinal nerve and other cervical plexus branches provide innervation, facilitating swallowing coordination.⁴

We present a case of new-onset CP muscle dysfunction after activation of HGNS therapy. We hypothesize that varying PES pressures from repeated geniohyoid contraction during HGNS therapy may have contributed to increased tonic PES pressure and subsequent CP muscle dysfunction.

Report of a Case | A woman in her 50s with OSA underwent uncomplicated HGNS system placement, with the C1 geniohyoid branch included in the stimulator cuff. Her medical history included gastroesophageal reflux disease (GERD) with no dysphagia or extraesophageal reflux complaints.

The HGNS therapy began 1 month later, and the patient noted snoring and sleep quality improvement. Following device activation, the patient developed solid and liquid dysphagia. A videofluoroscopic swallow study (VFSS) 6 weeks after activation identified vallecular residue and C5-C6 region narrowing with a posterior wall soft tissue protrusion (Figure, A) on maximum distension, suggesting CP muscle dysfunction. Symptoms persisted after swallow therapy with a speech language pathologist. The HGNS therapy was discontinued for 1 month and symptoms resolved. A repeated VFSS 4 weeks following HGNS discontinuation (Figure, B) found normal results.

With swallowing complaint resolution, HGNS therapy was restarted with similar sleep improvement. A titration polysomnogram demonstrated successful OSA treatment. However, her dysphagia returned 6 weeks after resuming HGNS therapy. Another VFSS 12 weeks after resuming HGNS therapy (Figure, C) suggested CP muscle dysfunction (Table). The patient stopped using the HGNS device, which was later explanted, and had complete dysphagia resolution.

Discussion | To our knowledge, this is the first report suggesting an association between HGNS therapy and CP muscle dysfunction. Correlation between HGNS therapy, symptoms, VFSS findings, and dysphagia resolution following HGNS discontinuation suggests a link between HGNS therapy and dysphagia.

Inclusion of the C1 nerve branch in the stimulator cuff is considered favorable for stabilizing the upper airway. However, repeated stimulation of this nerve may have contributed to development of dysphagia in this patient. We theorize that geniohyoid contraction during HGNS therapy may have induced PES dysfunction. The presence of GERD could also be a contributing factor given repeated increases in contractile PES pressure expected with reflux events.

Because this is a singular case observation, further investigation into PES pressure variations with HGNS use is warranted. As traction forces on the CP muscle occur with HGNS therapy, PES pressures likely increase to limit potential reflux. With repeated stimulation, these tonic contractile PES pressure increases may contribute to CP muscle dysfunction. As HGNS therapy for OSA expands, understanding of second-