

Acute Interstitial Nephritis

DONNA M. MICHEL and CAROLYN J. KELLY

Department of Medicine, University of California, San Diego, and Veterans Affairs Medical Center, San Diego, California.

Acute interstitial nephritis (AIN) is an important cause of acute renal failure. In addition, most forms of acute glomerulonephritis associated with significant decrements in renal function exhibit inflammation within the tubulointerstitium as well. In this article, we summarize the epidemiology, etiology, clinical presentation, and approach to diagnosis and treatment for AIN. In the final portion of the article, we discuss experimental work pertinent to the pathogenesis and treatment of interstitial nephritis.

Epidemiology

AIN has been reported to occur in approximately 1% of total biopsy material (1). In a series of male military personnel in Finland undergoing renal biopsy for evaluation of hematuria and/or proteinuria, approximately 1% were found to have interstitial nephritis (2). In examining patients biopsied for evaluation of acute renal failure, however, interstitial nephritis accounted for 15% of lesions (3).

Etiology of AIN

The causes of AIN can be classified into five general categories: drug hypersensitivity reactions, infection, immune-mediated diseases, glomerular disease, and idiopathic.

Drug hypersensitivity reactions are the most common cause of AIN in the antibiotic era. Although many drugs have been implicated in clinical cases of AIN, the frequency with which individual drugs are implicated varies widely. The prototype agent for drug-induced AIN is methicillin (4–6). As a result of its propensity to cause AIN, it is rarely used anymore in clinical practice. Medication groups most commonly implicated in drug-induced AIN include penicillins, cephalosporins, sulfonamides, and nonsteroidal anti-inflammatory agents (NSAIDs). Table 1 provides a more detailed listing of drugs that have been associated with AIN.

Numerous infections have been reported to cause AIN, but infection-associated AIN has become increasingly uncommon in areas of the world with ready access to antibiotics (7). Reported causative agents include bacteria, viruses, and other miscellaneous organisms such as *Toxoplasma*, *Leishmania*,

and *Rickettsia*. Table 2 provides a more detailed list of infectious agents associated with AIN.

AIN can occur in association with either kidney-limited or systemic autoimmune processes. It can occur as an isolated renal lesion in systemic lupus erythematosus, although most commonly interstitial nephritis in systemic lupus erythematosus occurs accompanying glomerular lesions. AIN may be found as a manifestation of sarcoidosis, Sjögren's syndrome, essential cryoglobulinemia, primary biliary cirrhosis, or as a defining component of the "tubulointerstitial nephritis-uveitis" syndrome (7). In some cases, AIN presents as an isolated finding in the absence of a defined illness, so-called idiopathic interstitial nephritis. In a small number of such cases, renal biopsies exhibit anti-tubular basement membrane antibodies in conjunction with mononuclear cell infiltration of the interstitium. These cases are presumably autoimmune in etiology.

Tubulointerstitial nephritis is frequently seen on renal biopsies from patients with various forms of glomerulonephritis (8). Although this pathologic finding is usually described in the pathologist's biopsy report, it does not typically contribute to the classification of the glomerular lesion. Because renal functional deterioration correlates more closely with interstitial pathology than with the extent of glomerular pathology, we believe it is important to formally include "glomerulonephritis" as a cause of interstitial nephritis.

Clinical Presentation and Diagnosis of AIN

The unifying presentation in AIN is that of an abrupt onset of renal dysfunction. Many physicians who have not received training in nephrology believe that AIN only occurs 2 to 3 wk after initiation of therapy with an offending drug, that it is invariably associated with fever, rash, and eosinophilia/eosinophiluria, and that prior tolerance of a medication eliminates that drug as a potential cause of AIN. All of these assumptions are false. AIN is a heterogeneous disorder not only in etiology, but also in presentation, laboratory findings, and outcomes.

The diagnosis is most commonly considered in hospitalized patients who experience a progressive rise in serum creatinine. The etiology of acute renal failure in such patients is frequently unclear, especially if they are infected, receiving multiple medications, undergoing diuresis, and/or exhibiting hemodynamic instability. In such complex settings, interstitial nephritis is frequently placed low on the differential diagnosis of acute renal failure if there is no concomitant fever, skin rash, eosinophilia, or eosinophiluria. Although these accompanying signs suggest AIN when present, their absence is not helpful in excluding the diagnosis. In some series, the triad of rash, fever,

Correspondence to Dr. Carolyn J. Kelly, University of California, San Diego and Veterans Affairs Medical Center 111-H, 3350 La Jolla Village Drive, San Diego, CA 92161.

1046-6673/0903-0506\$03.00/0

Journal of the American Society of Nephrology

Copyright © 1998 by the American Society of Nephrology

Table 1. Drugs associated with AIN^a

Beta-lactam antibiotics
methicillin
ampicillin
penicillin
oxacillin
nafcillin
cephalosporins
Other antibiotics/anti-infectives
sulfonamides
rifampin
polymyxin
ethambutol
tetracycline
vancomycin
erythromycin
ciprofloxacin
acyclovir
indinavir
alpha-interferon
NSAIDs
fenoprofen
indomethacin
naproxen
ibuprofen
tolmetin
diflunisal
piroxicam
ketoprofen
diclofenac
Diuretics
thiazides
furosemide
chlorthalidone
triamterene
Other drugs
diphenylhydantoin
cimetidine
sulfapyrazone
allopurinol
aspirin
carbamazepine
phenindione
clofibrate
phenylpropanolamine
aldomet
phenobarbital
azathioprine
diazepam
captopril

^a AIN, acute interstitial nephritis; NSAIDs, nonsteroidal anti-inflammatory agents.

Table 2. Infections associated with AIN

Bacteria
<i>Streptococci</i>
<i>Staphylococci</i>
diphtheria
<i>Brucella</i>
legionella
<i>Campylobacter</i>
Viruses
cytomegalovirus
Epstein-Barr virus
Hantaan virus
HIV
rubeola
Other
<i>Toxoplasma</i>
<i>Mycoplasma</i>
<i>Rickettsia</i>
<i>Leishmania</i>
syphilis
leptospirosis

tial nephritis and, in particular, beta lactam-associated AIN (10,11).

In the original reports on methicillin-associated AIN, onset of renal dysfunction typically occurred after 10 to 20 d of drug therapy. It is now recognized that in addition to this "classic" time course, the onset of AIN can exhibit other types of kinetics. For example, it can occur rapidly (within 2 to 3 days) after rechallenge with a drug to which an individual has been previously sensitized. It can also occur *de novo* in response to a medication previously tolerated by the individual. For example, many people who develop AIN in association with NSAID use have been taking the medications for months to years. AIN has been described to occur more frequently in response to some drugs when they are taken discontinuously (*e.g.*, interrupted therapy with rifampin for tuberculosis).

In addition to exhibiting heterogeneous kinetics, drug-associated AIN can also display varied clinicopathologic presentations. For example, NSAID-associated AIN frequently (up to 80% of the time) presents with nephrotic-range proteinuria in association with renal insufficiency. Extrarenal signs (fever, rash, eosinophilia) are uncommon with NSAID-associated AIN (12). In addition to the atypical time course noted above, patients with NSAID-induced AIN are usually older, although this may reflect the prevalence of NSAID usage. The association of acute renal failure and nephrotic syndrome with NSAID-induced AIN is strong and should prompt the physician to take a careful history regarding NSAID usage in patients with consistent clinical presentations. Given the wide availability of a variety of NSAIDs over the counter, many patients will not report NSAID usage when questioned about their medication history, but rather limit their report to prescribed medications. Although most patients will recover after discontinuation of NSAIDs, relapses have been reported after

and eosinophilia was seen in less than 30% of patients (9). These symptoms are most common in drug-associated intersti-

reinitiation of therapy with different NSAIDs in either the same or different class of compounds (12).

AIN can also occur in patients with chronic renal failure. In such patients, one should suspect AIN if a patient exhibits a more rapid than expected decline in renal function. Because these patients are on many medications, they may be at increased risk for this complication. We have seen patients with chronic renal failure and superimposed AIN (presumably related to drug hypersensitivity) who presented with accelerated renal dysfunction and no other physical or laboratory findings suggestive of AIN. In particular, there were no urinary leukocytes. It is possible that in the setting of chronic interstitial fibrosis and thickened tubular basement membranes, leukocyturia is less likely.

Many nephrologists have commented on how infrequently AIN was diagnosed in HIV-infected patients within the first decade of the epidemic in this country, despite the high rate of hospitalization and drug exposure. A possible explanation for this is that their depressed cell-mediated immunity was "protective." In this context, we have recently seen two HIV-infected patients with marked interstitial nephritis that progressed, in one case, over 6 wk to end-stage renal disease. Neither patient was proteinuric. It is possible that with improved antiretroviral therapy and better-maintained "immunocompetence" that the types of renal disease seen in the HIV-infected population will change, and interstitial nephritis may become more prominent. (It is important to point out that Indinavir has been linked to interstitial nephritis as well.)

Another interesting (and rare) subgroup of AIN is that of the tubulointerstitial nephritis-uveitis syndrome. First described in 1975 (13), this syndrome is characterized by acute renal failure caused by a diffuse eosinophilic interstitial nephritis, associated with bone marrow and lymph node granulomas of unknown cause (14). Subsequent to the initial report, other reports of similar cases have appeared in the literature. Pubertal females are most commonly affected. The diagnosis is often preceded by systemic symptoms such as malaise, weight loss, myalgias, and fever. The uveitis may precede, occur concomitantly, or follow the interstitial nephritis. Bone marrow granuloma is not a major diagnostic criterion. Steroids are effective therapy for both the interstitial nephritis and ocular disease, although relapses can occur (14).

AIN accompanying acute glomerulonephritis is typically present in any patient with acute glomerulonephritis and moderate-to-severe renal insufficiency. Its pathogenesis may well differ from AIN due to drug hypersensitivity (see below). In some forms of renal disease, such as the focal glomerular sclerosis seen in HIV-infected patients, the mononuclear cell infiltration of the interstitium can be massive. This correlates well with the rapid decline in renal function exhibited by many such patients. Current approaches to treatment in such cases are usually dictated by the type of glomerular pathology present.

Laboratory Diagnosis of AIN

Although there are clinical and laboratory findings consistent with AIN, no single laboratory test can diagnose AIN, and

renal biopsy remains the "gold standard" for unequivocally establishing the diagnosis. Typically, patients with AIN display progressive increases in blood urea nitrogen and creatinine. The rate at which the creatinine rises is, in our experience, less rapid than with acute renal failure secondary to nephrotoxins (such as aminoglycosides or intravenous contrast), or sepsis. (Obviously, there is a wide variation in the rate at which the creatinine rises in all of these categories.) Patients with AIN can display electrolyte abnormalities related to acute renal failure, but abnormalities characteristic of dysfunction of discrete tubular segments (such as Fanconi's syndrome) are not as prominent in AIN as they are in chronic interstitial nephritis.

The urinalysis in patients with AIN typically displays leukocytes, leukocyte casts, and occasionally free red blood cells (15). Although red blood cell casts have been reported in AIN, they are extremely rare. The urine should be sterile by bacterial culture if one is to implicate urinary leukocytes in an interstitial inflammatory process. Eosinophilia and eosinophiluria can be helpful in the presumptive diagnosis of AIN (15). Eosinophils in the urine can be detected by either Wright's stain or Hansel's stain, the latter being approximately five times more sensitive (16). Although it has been proposed that the finding of eosinophiluria is relatively specific and possibly diagnostic for AIN (16), in comparing its presence in patients with a confirmed diagnosis of AIN to those with other renal diseases, eosinophiluria was found to have a sensitivity of 40%, specificity of 72%, and positive predictive value of only 30% (17). Other conditions in which urine eosinophils were found included prostatitis, rapidly progressive glomerulonephritis, bladder carcinoma, and renal atheroembolic disease. Some nephrologists have abandoned urine eosinophils as a diagnostic test because of the aforementioned test characteristics.

The magnitude of proteinuria may vary considerably in AIN, but most commonly it is less than 1 g/24 h (15), except in cases in which interstitial lesions are associated with glomerular injury, as in the setting of NSAID-induced AIN (12). Isosthenuria is common in AIN. Patients with AIN rarely display a low FeNa^+ (15). Although in early reports of methicillin-associated AIN, oliguria was seen in up to 50% of patients (6), our impression is that less than 20% of AIN patients in contemporary practice are oliguric on presentation.

Some patients with AIN will demonstrate positive skin tests to the offending agent, consistent with hypersensitivity responses. Unfortunately, lack of standardization and limited numbers of drugs available for testing currently prohibit widespread utility of this diagnostic test (10).

Patients with AIN frequently undergo ultrasonic imaging of their kidneys as part of an evaluation of acute renal failure. In AIN, kidney size is typically normal-to-enlarged with increased cortical echogenicity comparable to or higher than that of the liver (15). There are no distinguishing characteristics on ultrasonic imaging that distinguish AIN from other forms of acute renal failure. Some have proposed that gallium scanning may be useful in the diagnosis of AIN, particularly in distinguishing it from acute tubular necrosis (15). In one series, nine patients with AIN had intensely positive gallium scans, but not one of six patients with acute tubular necrosis had a positive

scan (11). The utility of gallium scanning is limited, however, by its unpredictability in cases of subacute or chronic interstitial nephritis, its lack of specificity (in Linton's series, positive scans were also noted in patients with glomerulonephritis, minimal change disease, and pyelonephritis), and the possibility of false positive results in patients with iron overload or severe liver disease (since gallium resembles ferric iron and binds to transferrin and ferritin) (15).

Role of Percutaneous Renal Biopsy in the Diagnosis of AIN

In current practice, the majority of patients with AIN do not undergo a percutaneous renal biopsy. We do not advocate renal biopsy in patients in whom the diagnosis seems likely, and in whom probable precipitants, such as drug use, can be easily eliminated. If patients fail to improve after drug discontinuation, and immunosuppressive therapy is contemplated, we strongly recommend a renal biopsy to establish the diagnosis and determine how much inflammation persists. Renal biopsy is also indicated in patients in whom the diagnosis is unclear and in those in whom the potentially offending drug is critical for therapy. Frequently, patients in whom AIN is contemplated as a diagnosis are not good candidates for percutaneous renal biopsy, either because of ongoing infection, hemodynamic instability, or advanced renal insufficiency. Such circumstances must be dealt with on an individual basis.

Pathology of AIN

The most prominent aspect of the light microscopic pathology in AIN is the inflammatory cell infiltrate within the interstitium. These lesions can be diffuse or patchy. The inflammatory infiltrate is a mixed one, comprised of T lymphocytes, monocytes, and, occasionally, plasma cells and eosinophils (Figure 1, A and B). In the interstitial nephritis associated with glomerular disease, the infiltrate is typically T lymphocytes and monocyte/macrophages. Most of the time, CD4⁺ T cells predominate in the infiltrate in a CD4/CD8 ratio similar to that in blood. In some cases of primary interstitial nephritis, the mononuclear cell infiltrate is accompanied by granulomas. Granulomas can be seen with drug hypersensitivity reactions and need not implicate sarcoidosis or tuberculosis as the etiology. Immunofluorescence staining of the kidney in primary AIN is typically negative. Occasionally, the tubular basement membrane may exhibit positive staining for either IgG or IgM in a linear or granular pattern. Tubular epithelial cells frequently assume an "activated" phenotype in AIN, expressing class II major histocompatibility complex (MHC) glycoproteins, intercellular adhesion molecule-1, and, occasionally, vascular cell adhesion molecule. This is likely secondary to cytokines released from infiltrating cells and may result in heightened recognition of tubular epithelial cells by activated T cells. By electron microscopy, there can be a loss of continuity of the tubular basement membrane as well as other areas of thickened and multilayered basement membrane.

In NSAID-associated AIN, the glomerular-associated pathology is that of nil lesion, *i.e.*, normal glomerular light microscopy and fusion of the foot processes by electron mi-

croscopy. The pathology in "chronic" interstitial nephritis is dominated by interstitial fibrosis and tubular atrophy, although foci of inflammatory cells can remain.

Treatment of AIN

The mainstay of treatment in AIN is supportive therapy. After a presumptive (or biopsy-proven) diagnosis of AIN has been made, potentially offending drugs should be discontinued, or underlying infections treated. If diagnosed promptly, AIN is usually reversible if these guidelines are followed, although it may take weeks for renal function to return to its baseline value (see below). The more difficult clinical situations are those in which the patient is taking multiple potentially offending drugs. In such cases, a reasonable clinical approach should consider the likelihood of each individual agent being the culprit, and whether any suspected drug can be easily substituted for with another medication. If all suspect drugs are easily substituted for, that is a reasonable approach. If multiple agents are potentially suspect, and one (or several) of the less likely suspects can only be substituted for with more toxic, or less efficacious agents, it seems reasonable to first withdraw the agent most commonly associated with AIN and determine, after several days, whether there is evidence of stabilization or improvement in renal function. Between these two scenarios are many variations in clinical decision making familiar to the practicing nephrologist. It is important to emphasize that a suspected drug hypersensitivity reaction needs to be documented well in the patient's medical record and explained to the patient. We have seen several unfortunate cases in which patients were rechallenged with an offending drug and exhibited a rapid deterioration in renal function because these simple steps were not taken.

Treatment of AIN would be much more straightforward if it could be diagnosed with a sensitive and specific noninvasive test, and if one could reliably determine which agent, in the case of drug-induced AIN, is responsible. In some patients, the degree of renal insufficiency may be quite significant, and dialytic therapy may be required as a supportive measure.

In patients in whom drug discontinuation does not produce improvement in renal function, one must consider pharmacologic therapy for AIN. In addition, many nephrologists favor early pharmacologic therapy in patients who have particularly severe interstitial nephritis, as manifested by either a rapidly rising serum creatinine or diffuse involvement on renal biopsy, or both. In forms of interstitial nephritis associated with systemic autoimmune disease and glomerulonephritis, pharmacologic therapy is usually appropriate (see below). It is rarely appropriate in the setting of infection-associated AIN.

There are several important guidelines for pharmacologic therapy in drug-associated AIN. First, we believe that a renal biopsy should be performed before the initiation of immunosuppressive drugs. The purpose of the biopsy is to confirm the diagnosis of AIN and to assess the degree of interstitial fibrosis present. In patients in whom the diagnosis of AIN has been delayed, there may be a substantial degree of interstitial fibrosis. Such patients rarely benefit from treatment with immuno-

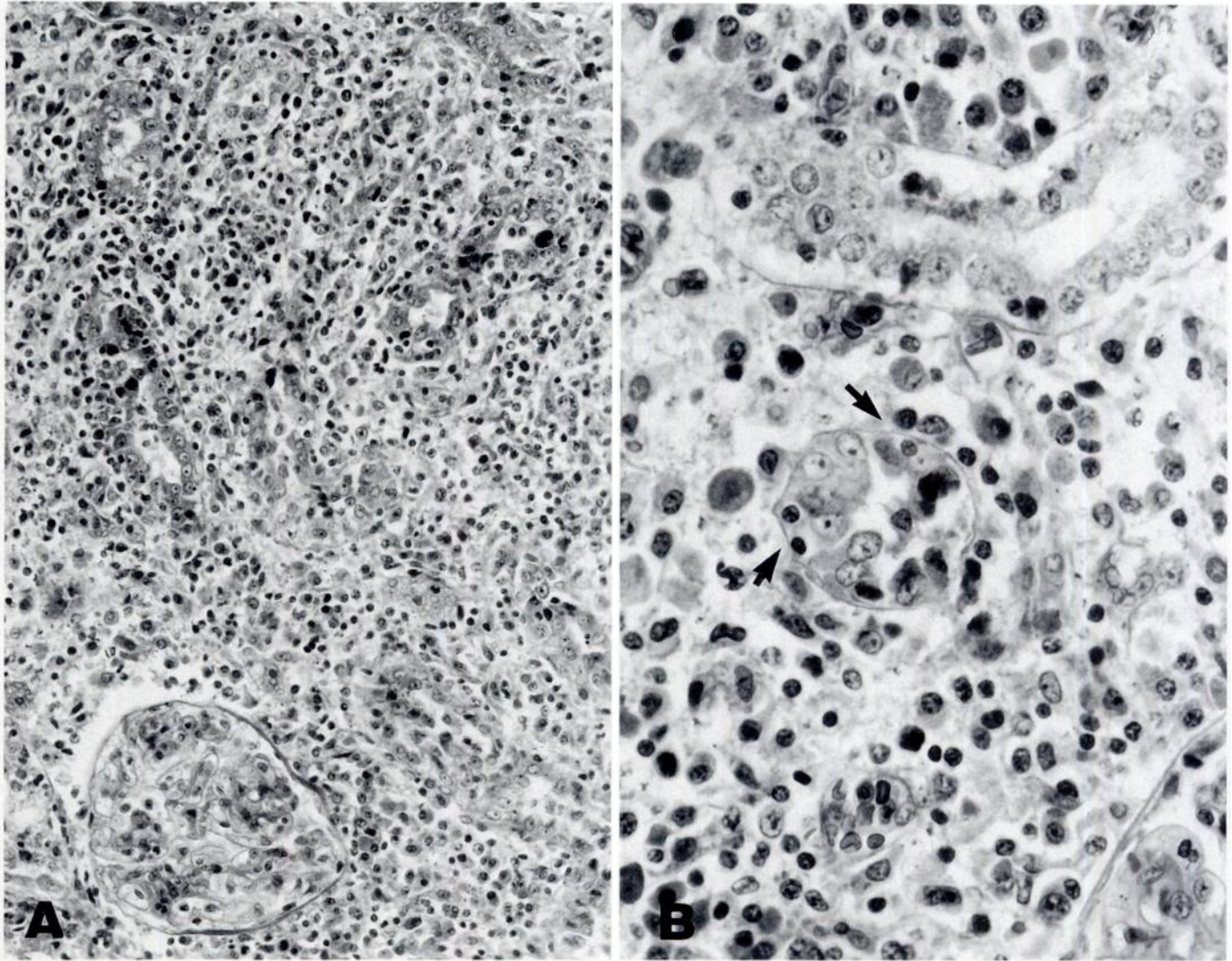


Figure 1. Fatal acute interstitial nephritis in a patient with scarlet fever. (A) The interstitium is edematous and contains a dense mononuclear infiltrate. Glomeruli are normal. Magnification, $\times 246$. (B) The cells are chiefly lymphocytes and plasma cells. Granulocytes, including eosinophils, are rare. Focal tubular invasion by mononuclear cells is present (arrows). Magnification, $\times 615$. (Original slides from case reported in Cabot RC, Hallory TB: Case records of the Massachusetts General Hospital. *N Engl J Med* 200; 142–145, 1929) (Reprinted with permission from Colvin RB, Fang LST: Interstitial nephritis. In: *Renal Pathology with Clinical and Functional Correlations*, edited by Tisher CC, Brenner BM, 1st Ed., Vol. I, Philadelphia, Lippincott, 1989, pp 728–776).

suppressing drugs and are potentially at more risk for side effects.

Second, although corticosteroids are the most commonly used immunosuppressive drugs for AIN, it is important to remember that there have been no prospective, randomized trials performed to assess the efficacy of this treatment. Evidence for efficacy has come from anecdotal case reports and small, uncontrolled, nonrandomized studies (3). In a retrospective analysis of 14 patients with methicillin-induced AIN, eight of 14 patients received prednisone therapy, with an average daily dose of 60 mg for a total mean duration of 9.6 d. Prednisone therapy was associated with a higher percentage of patients returning to their previous serum creatinine level, a lower average serum creatinine at follow-up, and a shorter time from peak serum creatinine to new baseline (9.3 versus 54 d)

(6). Pusey *et al.* retrospectively examined seven patients with biopsy-proven AIN treated with high-dose IV methylprednisolone. All responded with onset of diuresis or a spontaneous fall in serum creatinine within 72 h. In all treated patients, renal function returned to near normal, with creatinine clearances 60 to 90 ml/min. Of the two patients not treated, one recovered renal function slowly, and one progressed to chronic renal insufficiency. There were no detectable adverse effects from the short courses of steroids used in either study (18). There have been no trials that establish the optimum dosing or duration of corticosteroid therapy. Because interstitial fibrosis can be detected 10 to 14 d after onset of interstitial inflammation and a duration of azotemia greater than 1 to 2 wk decreases the likelihood of recovery of renal function, the appropriate window of opportunity, if one is going to treat with steroids, is

probably narrow, *i.e.*, within 7 to 14 d after onset of azotemia (19). Prednisone in an oral dose of approximately 1 mg/kg daily has been recommended, and treatment should be maintained for a period of approximately 4 wk. If there has been no significant response by that time, there probably will not be and the drugs should be discontinued (3).

Some have recommended adjunct therapy with cyclophosphamide at 1 to 2 mg/kg per d if there is no improvement in serum creatinine after a trial of steroid therapy (3). This recommendation is based on anecdotal experience. In our experience, many are hesitant to use cytotoxic agents after the failure of corticosteroids, because the efficacy of any immunosuppressive therapy diminishes with time. Given the potent effects of cyclophosphamide on cell-mediated immune responses, it may well be a more efficacious agent than prednisone as first-line therapy, but this has not been reported on. Usage of both cyclophosphamide and cyclosporin A to treat AIN is supported by investigations in experimental models of interstitial nephritis (20,21).

Plasmapheresis may be considered adjunct therapy along with prednisone or cyclophosphamide in those in whom anti-tubular basement membrane antibodies are demonstrable in the renal biopsy. This is an uncommon occurrence. The use of plasmapheresis in this setting would be analogous to its use in anti-glomerular basement membrane disease. Plasmapheresis using 3- to 4-L exchanges daily for 5 d and then every other day for another week has been recommended (19). Anecdotal reports on its success have been mixed (3).

We are not aware of reports of the use of drug desensitization regimens in patients who have experienced drug-associated interstitial nephritis and who could otherwise benefit from continued therapy with that drug. It may well be feasible.

Prognosis of AIN

Because AIN is associated with diverse etiologies, it is difficult to establish a general prognosis for all causes of AIN. Most of the available information on outcomes is derived from patients with probable drug-associated AIN. In general, if drug-associated AIN is detected early (within 1 wk of the rise in serum creatinine), and the drug is promptly discontinued, the long-term outcome is favorable for a return to baseline serum creatinine. At the other end of the spectrum, if the diagnosis is missed for several weeks, or if a patient is mistakenly rechallenged with a drug and develops a hypersensitivity response rapid in onset and severe in intensity, the patient may be left with significant renal dysfunction or even require renal replacement therapy. The inflammatory lesion of AIN can become a lesion characterized by fibrosis and tubular atrophy, hallmarks of chronic interstitial nephritis, if the inciting factors persist.

Are there clinical or morphologic factors that enable the clinician to predict prognosis for patients with AIN? Laberke and Bohle compared clinical and morphologic findings in 30 cases of AIN, all of which had been confirmed by pathologic specimens, to determine whether histologic findings could provide conclusive information regarding the course and prognosis of AIN (1). Serum creatinine values were used as clinical

criteria for evaluating course and prognosis of disease. Their findings indicate that it is important to differentiate histologically between AIN cases with diffuse infiltration and those with patchy and/or incompletely diffuse infiltration. Prognosis is significantly better for the latter. The presence of 1 to 6% neutrophils in the infiltrate also correlated with an adverse prognosis. Patients with AIN accompanied by acute renal failure of >3 wk duration had a poorer prognosis for complete recovery of renal function. The phenotype of infiltrating cells, degree of tubulitis, and tubular expression of vimentin (as an assessment of tubular damage) were not found to predict outcome (22). The most important prognostic factor is the severity of interstitial fibrosis (22).

Kida *et al.* examined the long-term prognosis of 14 patients with biopsy-proven AIN by analyzing laboratory data, histologic changes, and clinical features both early and late in the disease course (23). They noted two phases to the recovery from AIN: an initial phase of rapid improvement in GFR (the first 6 to 8 wk) followed by slow improvement in GFR over the following year. In their series, half of the patients studied ultimately displayed a higher baseline serum creatinine. Final GFR correlated with the degree of early improvement, suggesting that the latter may be a reliable predictor of long-term prognosis. Age at onset of AIN correlated inversely with final GFR, whereas other indices such as extrarenal manifestations, initial renal symptoms, and gender had no significant relationship to outcome. Severity of the interstitial lesion was noted to correlate closely with final GFR.

Pathogenesis of AIN and Prospects for Therapy Insights from Animal Models

Most of what we know about the pathogenesis of AIN has been culled from experimental work in animal model systems (24,25). Although there is no good model system for drug-induced interstitial nephritis, there are model systems of spontaneous, T cell-mediated interstitial nephritis (26); interstitial nephritis with antibody deposition along the tubular basement membrane and mononuclear cell infiltration of the interstitium (anti-tubular basement membrane disease induced with antigen in adjuvant immunization) (27); interstitial nephritis associated with systemic autoimmunity (MRL-fas^{LPR} mice); and interstitial nephritis associated with glomerular disease/proteinuria (protein-overload proteinuria [28], treatment with aminonucleosides [29], crescentic glomerulonephritis [30]). The availability of a variety of distinct model systems is useful for the study of a human disease that is diverse in both etiology and in immunopathologic phenotype.

The purpose of developing and characterizing model systems is to discover better ways of treating human disease. Identifying the relevant mediators of renal injury in rodent model systems of interstitial nephritis has facilitated testing new types of therapy in such model systems. It is useful to classify the different types of immunopathology seen in different models of interstitial nephritis as either antigen-driven or antigen-nonspecific.

Antigen-driven immunopathology is the end product of an

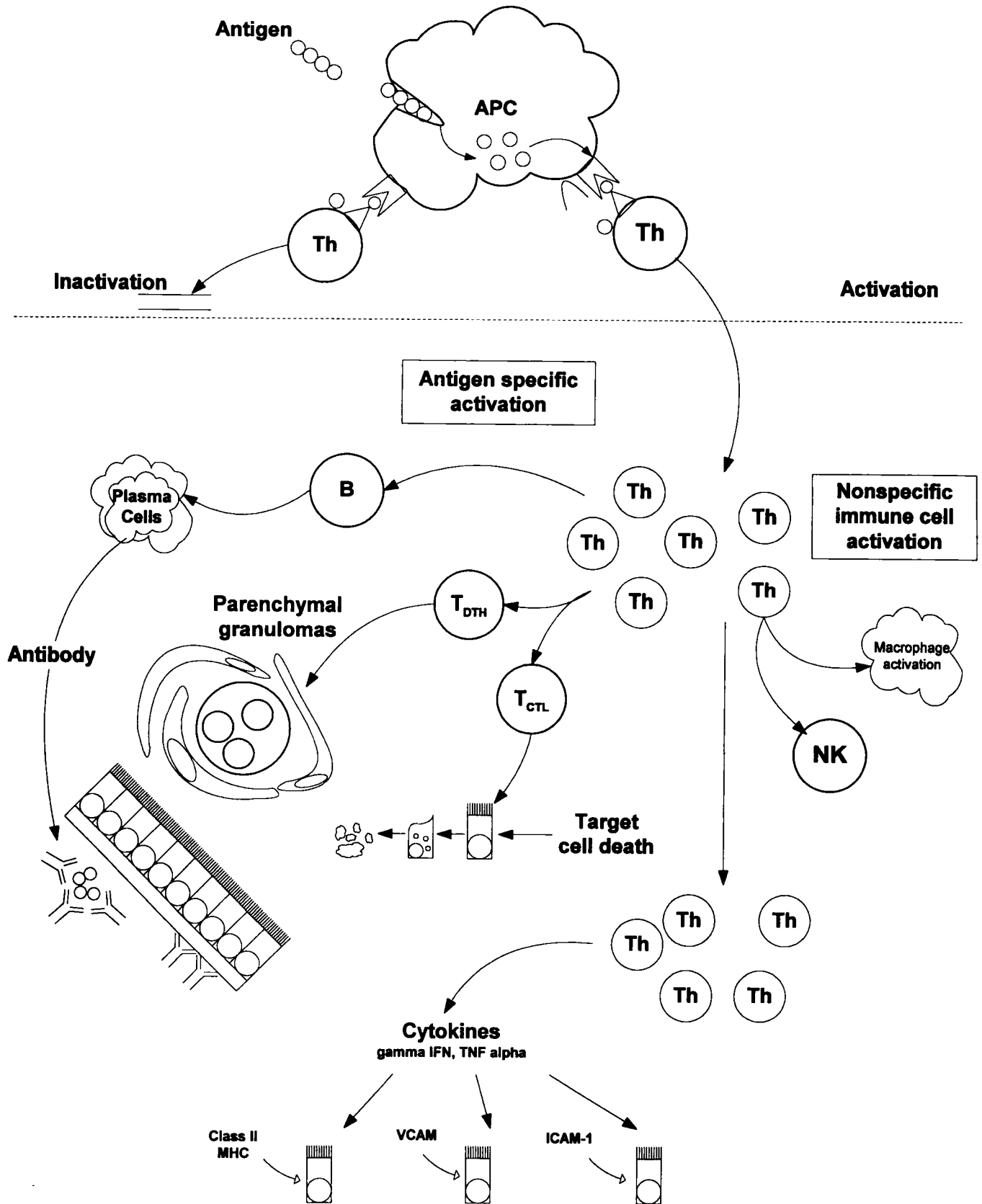


Figure 2. Diagram of mechanisms underlying immune injury in acute interstitial nephritis. The portion of the figure above the dashed line depicts antigen uptake and processing by professional antigen-presenting cells, such as a dendritic cell or macrophage. Peptide fragments of this antigen are presented by cell-surface major histocompatibility complex (MHC) proteins to the antigen receptor on the T helper (Th) cell (depicted as a triangle). For the Th cells to be activated, they must receive a second costimulatory signal (depicted as the circle-ellipse couple).

immune response mounted to a specific antigen(s). The hallmark of such a response is the clonal expansion of immune cells that bear cell-surface receptors for antigen, *i.e.*, T and B lymphocytes. These antigen-specific cells can result in parenchymal organ injury through several mechanisms.

A general framework for understanding tissue-injurious antigen-driven immune responses is summarized in Figure 2. This information is outlined in more detail elsewhere (24,25). First, the target antigen, or one cross reactive with it, must be expressed and presented to T cells in a manner that results in T cell activation. The relevant target antigens in most forms of human interstitial nephritis have not been defined. In drug-related AIN, it seems likely that the relevant drugs behave like haptens, which may bind to serum or cellular proteins and subsequently are processed and presented by MHC molecules as hapten-modified peptides. Alternatively, some drugs, such as sulfamethoxazole, may be able to bind directly to MHC-peptide complexes (31). Once helper T cells are activated, they produce cytokines that have direct effects on target cells and additionally activate nonspecific effector cells, such as natural killer cells and macrophages. Activated T helper cells induce the differentiation of B cells to plasma cells, resulting in the production of specific antibody. Activated T helper cells additionally induce the differentiation of other effector T cells, such as those mediating delayed-type hypersensitivity and cytotoxicity. These responses are ultimately regulated by a variety of mechanisms, including the removal of antigen from the system, the programmed cell death of immune cell populations, idiotypic anti-idiotypic interactions, and the production of antagonistic, inhibitory cytokines.

Anti-tubular basement membrane disease with interstitial nephritis is the most widely studied model system of AIN and represents an antigen-driven model of interstitial nephritis. We will use this model system to briefly summarize mechanisms of disease and then supplement this information with data from other model systems. Anti-tubular basement membrane disease is induced by immunizing susceptible strains of rodents with a renal tubular antigen preparation emulsified in complete Freund's adjuvant. This immunization process results in the activation and differentiation of antigen-specific T and B cells within the host. Within 7 to 10 d after immunization, antigen-specific IgG is detectable both within the circulation and as a linearly deposited antibody along the tubular basement membrane. At these early time points, there additionally may be a diffuse infiltrate of neutrophils within the interstitium. Functional studies performed at this time demonstrate a depressed

single nephron GFR. By 2 to 3 wk after immunization (in the rat), the neutrophils within the interstitium have been replaced with a largely mononuclear cell infiltrate, comprised of T cells, B cells, plasma cells, macrophages, and natural killer cells. At this time point, GFR is significantly depressed. The fall in GFR is the result both of a loss of functioning nephrons and the failure of the remaining nephrons to compensate with hyperfiltration (T. Hammond, S. Thomson, C. Kelly, F. Gabbai. Glomerular hemodynamic changes in autoimmune tubulointerstitial nephritis in the Brown Norway rat, submitted for publication). At these later time points, irreversible injury to the tubulointerstitium results from a combination of antigen-specific and nonspecific effector mechanisms. There is no strong evidence that the anti-tubular basement membrane antibody deposition alone results in injury to renal tubular epithelial cells. However, the deposition of antibody can recruit nonspecific cytotoxic effector cells to the site, via so-called "antibody-dependent cellular cytotoxicity" pathways. Activated macrophages within the interstitium can release a number of potentially harmful secretory products. Among these, the release of enzymes that can degrade basement membrane are likely crucial, because the loss of an intact basement membrane will hamper regeneration of the tubular segment. The release of reactive oxygen species from activated macrophages can result in oxidant injury to epithelial cells. The role of reactive nitrogen species, such as nitric oxide, is currently unresolved. In models of ischemic renal injury, the evidence is convincing that nitric oxide is a critical participant in epithelial cell injury. In anti-tubular basement membrane disease, treatment of immunized animals with selective inhibitors of the cytokine-inducible nitric oxide synthase (such as L-NIL) results in marked augmentation of disease, at both the histologic and functional levels (32). This may be attributable to an augmented immune response in the setting of nitric oxide synthase inhibition, rather than an effect of inducible nitric oxide synthase inhibition within the kidney.

Renal injury can also be initiated by antigen-specific T cells. In the anti-tubular basement membrane disease model, T cells that infiltrate the interstitium recognize the target antigen within the interstitium. This glycoprotein is synthesized by tubular epithelial cells, and under some circumstances tubular epithelial cells can present this antigen to T cells, resulting in the activation of the latter (33). Both CD4⁺ and CD8⁺ T cells are present within the tubulointerstitium. These cells recognize tubular epithelial cells in either a class II MHC (CD4⁺)- or class I MHC (CD8⁺)-restricted manner. These T cells can

In the absence of this second signal, the Th cell is inactivated, as depicted on the left side of the figure. The portion of the figure below the dashed line depicts effector mechanisms of injury that result from Th cell activation. These include antigen-specific and -nonspecific mechanisms. The nonspecific mechanisms include activation of macrophages and natural killer (NK) cells. Antigen-specific mechanisms include activation of both B and T cells. B cells are induced to differentiate into plasma cells and make antibody, which can react with a kidney antigen (as depicted along the tubular basement membrane) or deposit as antigen-antibody complexes. Th cells can induce effector T cells, which may be cytotoxic to tubular epithelial cells (T_{CTL}) leading to necrosis or apoptosis or inflammatory (T_{DTH}) leading to mononuclear cell infiltration and occasionally granuloma formation. Finally, the cytokines produced by infiltrating T cells may induce the expression of a number of cell surface molecules on organ parenchymal cells (such as class II MHC, vascular cell adhesion molecule [VCAM], or intercellular adhesion molecule-1 [ICAM-1]), which amplify the immune response.

Table 3. Experimental therapies in interstitial nephritis

Antigen-Nonspecific	Ref.	Antigen-Specific	Ref.
Protein-calorie restriction	40	Anti-idiotypic immunity	42
Cyclophosphamide	20	Antigen-specific regulatory T cells	43
Cyclosporin A	21	Antigen feeding	44
PGE1	41	Antigen in incomplete Freund's adjuvant	45

initiate delayed-type hypersensitivity reactions to the target antigen, and they can be cytotoxic to tubular epithelial cells (34–36). These two functional capabilities may result in lesions that display both granulomas and giant cell formation, along with tubular epithelial cell drop-out and atrophy. Most forms of interstitial nephritis likely have infiltrating T cells with a variety of functional profiles. These T cells express a variety of cytokines, including γ -interferon, interleukin-2, interleukin-4, and tumor necrosis factor- α . In addition, the cytotoxic cells express granzymes and perforin, putative effector proteins of cytotoxicity (34,36).

In forms of interstitial nephritis associated with glomerulonephritis, or even a noninflammatory glomerular lesion with proteinuria and lipiduria, the interstitial pathology is somewhat different. The infiltrate in these settings is probably initiated by nonspecific immune cells such as macrophages, rather than T cells. How immune cell populations are recruited to the interstitium in the setting of proteinuria, lipiduria, or glomerulonephritis is an area of active investigation. Attention has been focused on the role of chemokines (30,37), lipid chemoattractants (38), and osteopontin (39). These chemoattractant mechanisms suggest that even if T cells are recruited to the site, they will not have specificity for locally expressed antigens. When macrophages are the dominant effector cell present, the mediators of tissue injury are likely quite different than with T cell-dominated infiltrates. This may have important implications for therapy.

A number of therapies have been explored in anti-tubular basement membrane disease. These include both antigen-specific and antigen-nonspecific forms of treatment. These are enumerated in Table 3. In general, it is much easier in model systems to block the induction of immune responses than it is to turn off ongoing immune responses. Antigen-specific therapy has not yet become a reality in the treatment of human autoimmune disease. Even the recent enthusiasm over orally administered target antigens appears to be waning as results from clinical trials emerge. Research continues into modalities that are relatively selective, nontoxic, yet efficacious.

References

1. Laberke H-G, Bohle A: Acute interstitial nephritis: Correlations between clinical and morphological findings. *Clin Nephrol* 14: 263–273, 1980
2. Pettersson E, von Bonsdorff M, Tornroth T: Nephritis among young Finnish men. *Clin Nephrol* 22: 217–222, 1984
3. Neilson EG: Pathogenesis and therapy of interstitial nephritis. *Kidney Int* 35: 1257–1270, 1989
4. Baldwin D, Levin B, McCluskey R: Renal failure and interstitial nephritis due to penicillin and methicillin. *N Engl J Med* 279: 1245, 1968
5. Border WA, Lehman DH, Egan JD, Sass HJ, Glode JE, Wilson CB: Antitubular basement membrane antibodies in methicillin-associated interstitial nephritis. *N Engl J Med* 291: 381–384, 1974
6. Galpin JE, Shinaberger JH, Stanley TM, Blumenkrantz MJ, Bayer AS, Friedman GS, Montgomerie JZ, Guze LB, Cuburn JW, Glasscock RJ: Acute interstitial nephritis due to methicillin. *Am J Med* 65: 756–765, 1978
7. Cameron JS: Allergic interstitial nephritis: Clinical features and pathogenesis. *Q J Med* 66: 97–115, 1988
8. Jones CL, Eddy AA: Tubulointerstitial nephritis. *Pediatr Nephrol* 6: 572–586, 1992
9. Eapen SS, Hall PM: Acute tubulointerstitial nephritis. *Cleveland Clin J Med* 59: 27–32, 1992
10. Murray KM, Keane WR: Review of drug-induced acute interstitial nephritis. *Pharmacotherapy* 12: 462–467, 1992
11. Linton AL, Clark WF, Driedger AA, Turnbull DI, Lindsay RM: Acute interstitial nephritis due to drugs: Review of the literature with a report of nine cases. *Ann Intern Med* 93: 735–741, 1980
12. Kleinknecht D: Interstitial nephritis, the nephrotic syndrome, and chronic renal failure secondary to nonsteroidal anti-inflammatory drugs. *Semin Nephrol* 15: 228–235, 1995
13. Dobrin R, Vernier R, Fish A: Acute eosinophilic interstitial nephritis and renal failure with bone marrow-lymph node granulomas and anterior uveitis: A new syndrome. *Am J Med* 59: 325–333, 1975
14. Steinman TI, Silva P: Acute interstitial nephritis and iritis: Renal-ocular syndrome. *Am J Med* 77: 189–191, 1984
15. Ten RM, Torres VE, Milliner DS, Schwab TR, Holley KE, Gleich GJ: Acute interstitial nephritis: Immunologic and clinical aspects. *Mayo Clin Proc* 63: 921–930, 1988
16. Nolan C, Angel M, Kelleher A: Eosinophiluria: A new method of detection and definition of the clinical spectrum. *N Engl J Med* 315: 1516–1519, 1986
17. Ruffing KA, Hoppes P, Blend D, Cugino A, Jarjoura D, Whittier FC: Eosinophils in urine revisited. *Clin Nephrol* 41: 163–166, 1994
18. Pusey CD, Saltissi D, Bloodworth L, Rainford DJ, Christie JL: Drug associated acute interstitial nephritis: Clinical and pathological features and the response to high dose steroid therapy. *Q J Med* 52: 194–211, 1983
19. Heeger PS, Neilson EG: Acute hypersensitivity interstitial nephritis: Acute interstitial nephritis. In: *Current Therapy in Nephrology and Hypertension*, edited by Glasscock RJ, 3rd Ed., St. Louis, Mosby-Year Book, 1992, pp 108–113
20. Agus D, Mann R, Clayman M, Kelly C, Michaud L, Cohn D, Neilson EG: The effects of daily cyclophosphamide administration on the development and extent of primary experimental interstitial nephritis in rats. *Kidney Int* 29: 635–640, 1986
21. Shih W, Hines W, Neilson E: Effects of cyclosporin A on the development of immune-mediated interstitial nephritis. *Kidney Int* 33: 1113–1118, 1988
22. Ivanyi B, Hamilton-Dutoit SJ, Hansen HE, Olsen S: Acute tubulointerstitial nephritis: Phenotype of infiltrating cells and prognostic impact of tubulitis. *Virchows Arch* 428: 5–12, 1996
23. Kida H, Abe T, Tomosugi N, Koshino Y, Yokoyama H, Hattori

- N: Prediction of the long-term outcome in acute interstitial nephritis. *Clin Nephrol* 22: 55–60, 1984
24. Kelly CJ, Roth DA, Meyers CM: Immune recognition and response to the renal interstitium. *Kidney Int* 39: 518–531, 1991
 25. Kelly CJ, Tomaszewski JE, Neilson EG: Immunopathogenesis of tubulointerstitial injury. In: *Renal Pathology*, edited by Brenner BM, Tisher CC, 2nd Ed., Philadelphia, Lippincott, 1993, pp 699–722
 26. Neilson EG, McCafferty E, Feldman A, Clayman MD, Zakheim B, Korngold R: Spontaneous interstitial nephritis in kdkd mice. I. An experimental model of autoimmune renal disease. *J Immunol* 133: 2560–2565, 1984
 27. Neilson EG, Phillips SM: Murine interstitial nephritis. I. Analysis of disease susceptibility and its relationship to pleiomorphic gene products defining both immune response genes and restrictive requirement for cytotoxic T cells at H-2K. *J Exp Med* 155: 1075–1085, 1982
 28. Eddy AA: Interstitial nephritis induced by protein-overload proteinuria. *Am J Pathol* 135: 719–733, 1989
 29. Eddy AA, Michael AF: Acute tubulointerstitial nephritis associated with aminonucleoside nephrosis. *Kidney Int* 33: 14–23, 1988
 30. Lloyd C, Minto A, Dorf M, Proudfoot A, Wells T, Salant D, Gutierrez-Ramos J: RANTES and monocyte chemoattractant protein-1 (MCP-1) play an important role in the inflammatory phase of crescentic nephritis, but only MCP-1 is involved in crescent formation and interstitial fibrosis. *J Exp Med* 185: 1371–1380, 1997
 31. Schnyder B, Mauri-Hellweg D, Zanni M, Bettens F, Pichler W: Direct, MHC-dependent presentation of the drug sulfamethoxazole to human alpha beta T cell clones. *J Clin Invest* 100: 136–141, 1997
 32. Gabbai F, Boggiano C, Peter T, Khang S, Archer C, Gold D, Kelly C: Inhibition of inducible nitric oxide synthase intensifies injury and functional deterioration in autoimmune interstitial nephritis. *J Immunol* 159: 6266–6275, 1997
 33. Hines WH, Haverty TP, Elias JA, Neilson EG, Kelly CJ: T cell recognition of epithelial self. *Autoimmunity* 5: 37–47, 1989
 34. Meyers CM, Kelly CJ: Effector mechanisms in organ-specific autoimmunity. I. Characterization of a CD8⁺ T cell line that mediates murine interstitial nephritis. *J Clin Invest* 88: 408–416, 1991
 35. Heeger PS, Smoyer WE, Saad T, Albert S, Kelly CJ, Neilson EG: Molecular analysis of the helper T cell response in murine interstitial nephritis: T cells recognizing an immunodominant epitope use multiple TCR Vbeta genes with similarities across CDR3. *J Clin Invest* 94: 2084–2092, 1994
 36. Meyers CM, Kelly CJ: Inhibition of murine nephritogenic effector T cells by a clone-specific suppressor factor. *J Clin Invest* 94: 2093–2104, 1994
 37. Tang W, Qi M, Warren JS, Van GY: Chemokine expression in experimental tubulointerstitial nephritis. *J Immunol* 159: 870–876, 1997
 38. Kees-Folts D, Sadow JL, Schreiner GF: Tubular catabolism of albumin is associated with the release of an inflammatory lipid. *Kidney Int* 45: 1697–1709, 1994
 39. Pichler R, Giachelli C, Lombardi D, Pippin J, Gordon K, Alpers C, Schwartz S, Johnson R: Tubulointerstitial disease in glomerulonephritis: Potential role of osteopontin (uropontin). *Am J Pathol* 144: 915–926, 1994
 40. Agus D, Mann R, Cohn D, Michaud L, Kelly C, Clayman M, Neilson E: Inhibitory role of dietary protein restriction on the development and expression of immune-mediated antitubular basement membrane-induced tubulointerstitial nephritis in rats. *J Clin Invest* 76: 930–936, 1985
 41. Kelly C, Zurier R, Krakauer K, Blanchard N, Neilson E: Prostaglandin E1 inhibits effector T cell induction and tissue damage in experimental murine interstitial nephritis. *J Clin Invest* 79: 782–789, 1987
 42. Clayman MD, Sun MJ, Michaud L, Brill-Dashoff J, Riblet R, Neilson EG: Clonotypic heterogeneity in experimental interstitial nephritis: Restricted specificity of the anti-tubular basement membrane B cell repertoire is associated with a disease-modifying crossreactive idotype. *J Exp Med* 167: 1296–1312, 1988
 43. Neilson E, McCafferty E, Mann R, Michaud L, Clayman M: Tubular antigen derivatized cells induce a disease-protective, antigen-specific, and idotype-specific suppressor T cell network restricted by I-J and Igh-V in mice with experimental interstitial nephritis. *J Exp Med* 162: 215–230, 1985
 44. Pham K, Smoyer W, Archer D, Gabbai F, Kelly C: Oral feeding of renal tubular antigen abrogates interstitial nephritis and renal failure in Brown Norway rats. *Kidney Int* 52: 725–732, 1997
 45. Kelly CJ, Clayman MD, Neilson EG: Immunoregulation in experimental interstitial nephritis: Immunization with renal tubular antigen in incomplete Freund's adjuvant induces major histocompatibility complex restricted OX8⁺ suppressor T cells which are antigen specific and inhibit the expression of disease. *J Immunol* 136: 903–907, 1986