

This is an Open Access article licensed under the terms of the Creative Commons Attribution-NonCommercial-NoDerivs 3.0 License (www.karger.com/OA-license), applicable to the online version of the article only. Distribution for non-commercial purposes only.

Adult Coats' Disease Successfully Managed with the Dexamethasone Intravitreal Implant (Ozurdex®) Combined with Retinal Photocoagulation

Sebastián Martínez-Castillo^a Roberto Gallego-Pinazo^a
Rosa Dolz-Marco^a Cristina Marín-Lambías^a
Manuel Díaz-Llopis^{a, b}

^aDepartment of Ophthalmology, University and Polytechnic Hospital La Fe, and

^bFaculty of Medicine, University of Valencia, Valencia, Spain

Key Words

Coats' disease · Retinal telangiectasis · Retinal vasoproliferative tumor · Dexamethasone intravitreal implant (Ozurdex®)

Abstract

Purpose: To report a case of Coats' disease managed with the dexamethasone intravitreal implant Ozurdex® (Allergan, Inc., Irvine, Calif., USA) combined with retinal photocoagulation.

Methods: A 46-year-old female with 20/200 visual acuity was diagnosed with Coats' disease with secondary retinal vasoproliferative tumor. An initial approach was performed with an intravitreal injection of the sustained-release dexamethasone implant Ozurdex. After reattachment of the retina, the telangiectatic vessels were treated with laser photocoagulation.

Results: The patient's visual acuity improved to 20/25 after the intravitreal Ozurdex. No further recurrences of exudation were evident through the 12-month follow-up.

Conclusions: Ozurdex may be an effective initial therapeutic approach for Coats' disease with immediate anatomical response and visual improvement.

Introduction

Coats' disease is a unilateral, idiopathic retinal vascular abnormality characterized by telangiectatic retinal vessels in association with lipid exudation [1]. Although most cases are diagnosed before the age of 20 years, Coats' disease may also be diagnosed in

adult patients [2]. Current therapeutic strategies include observation, ablation of abnormal retinal telangiectasis by photocoagulation – or cryotherapy – and surgery for retinal detachment. Recent publications regarding the off-label use of triamcinolone [3, 4] or vascular endothelial growth factor inhibitors [5–7] have been published with inconclusive outcomes, requiring several rounds of retreatment in most cases. The purpose of any treatment for Coats' disease is to establish a prompt and long-standing visual recovery, with the safest profile for patients.

Case Report

A 46-year-old female was referred to our department with a 3-week history of progressive vision loss in her left eye. The best corrected visual acuity (BCVA) was 20/20 in her right eye and 20/200 in her left eye. Anterior segment examination was unremarkable.

Whereas the right eye fundus did not show any significant change, in the left eye massive exudation within the inferior-temporal quadrant of the retina was evident, with posterior pole involvement and intraretinal lipid accumulation. In addition, a grayish mass was observed in the inferior peripheral retina (fig. 1). Spectral-domain optical coherence tomography (SD-OCT) confirmed the presence of exudative retinal detachment with macular involvement (fig. 1). Numerous hyperreflective intraretinal lesions corresponding to lipids were evident. An echography showed an intraretinal mass (4.1 × 1.9 mm) located in the inferior periphery, associated with the exudative retinal detachment (fig. 1). Fluorescein angiography (fig. 1) revealed the presence of telangiectatic vessels scattered all over the inferior-temporal retinal quadrant; the peripheral inferior mass was identified as a retinal vasoproliferative tumor (RVT) with clearly defined afferent and efferent vessels.

With the presumptive diagnosis of Coats' disease with exudative inferior-temporal retinal detachment and secondary RVT, the patient was treated with an intravitreal injection of the sustained-release dexamethasone implant Ozurdex® (Allergan, Inc., Irvine, Calif., USA). One week later, her BCVA improved to 20/40 and SD-OCT revealed a complete resolution of the exudative retinal detachment (fig. 2). The telangiectatic vessels were treated with laser photocoagulation guided by fluorescein angiography in 3 consecutive sessions with 15-day intervals. The volume of the RVT decreased progressively until complete retinographic and echographic disappearance.

Through the follow-up, no further recurrences of the exudative retinal detachment were found, and the extensive lipid exudation progressively regressed. One year after initial treatment with intravitreal Ozurdex, the patient's BCVA was 20/25 (fig. 3).

Discussion

The pathogenesis of Coats' disease includes impairment of the blood-retinal barrier resulting in both intraretinal and subretinal fluid, and blood and lipid accumulation. In addition, weakening of the retinal vessel walls leads to the formation of telangiectasis, aneurysms and progressive leakage, resulting in exudative retinal detachment [8]. One of the possible complications of Coats' disease is the development of secondary RVT [9], as evidenced in our patient's case.

Intravitreal injection of dexamethasone has been shown to attenuate leukostasis and vascular leakage [10]. This fact may be of great help in the management of Coats' disease, given the underlying inflammatory component [11]. Ozurdex is a novel, biodegradable, sustained-release dexamethasone delivery system approved for the treatment of macular edema following retinal vein occlusion [12]. Recently published clinical trials expand the efficacy of Ozurdex to the management of diabetic macular edema [13] and uveitic macular edema [14].

In our patient's case, a single injection of Ozurdex was able to dramatically improve visual acuity and resolve the exudative retinal detachment. Further photocoagulation may lead to closure of telangiectasis; no further recurrence of exudation was seen through a 12-month follow-up. Further studies are warranted in order to confirm the high efficacy of Ozurdex in the initial management of Coats' disease.

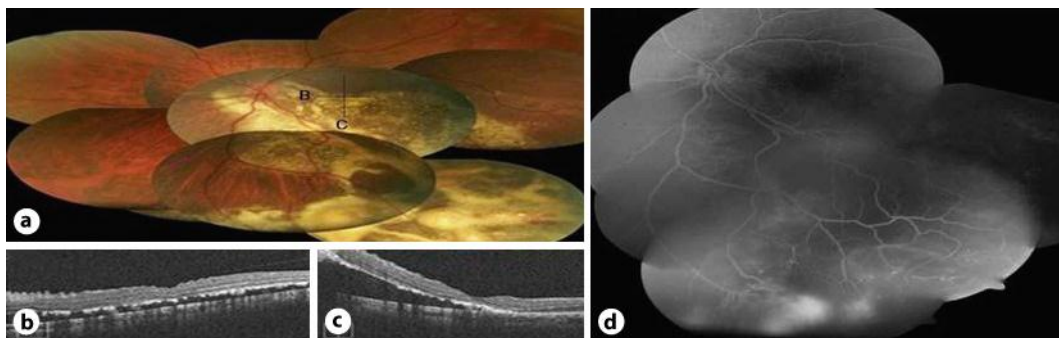


Fig. 1. **a** Retinography of the left eye reveals massive exudation within the inferior-temporal quadrant of the retina. **b** Horizontal and vertical (**c**) OCT scans (indicated as B and C, respectively, in **a**) centered in the fovea confirm the presence of exudative retinal detachment with macular involvement. **d** Fluorescein angiography shows the presence of telangiectatic vessels scattered all over the inferior-temporal retinal quadrant.

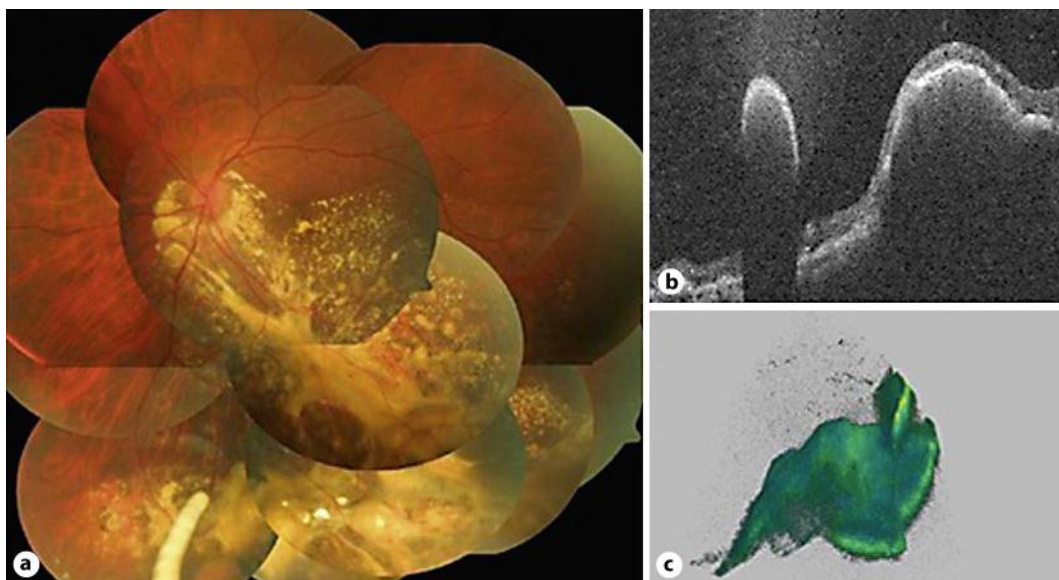


Fig. 2. **a** Retinography shows the presence of the Ozurdex® device 1 week after its implantation. **b** Horizontal OCT scan and 3-dimensional reconstruction (**c**) show the presence of the implant adjacent to the retinal vasoproliferative tumor.

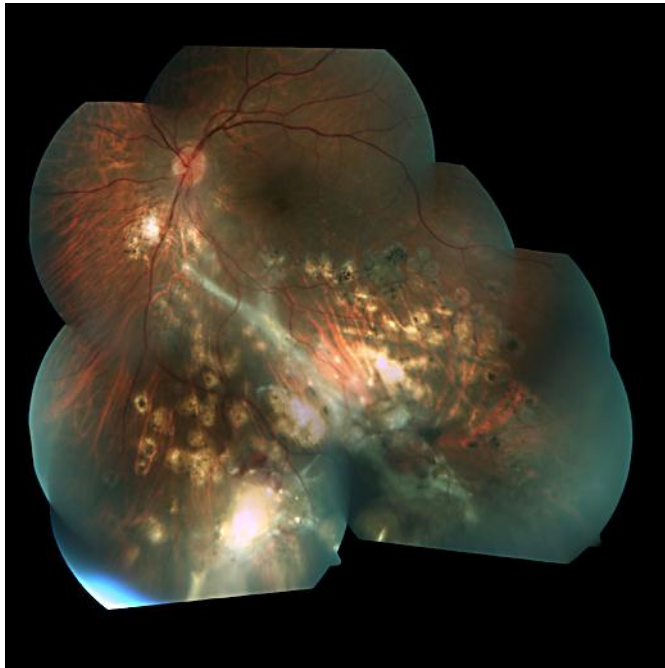


Fig. 3. Retinography after 12 months of follow-up reveals regression of lipid exudation and retinal scars from photocoagulation.

References

- 1 Coats G: Forms of retinal diseases with massive exudation. *Roy Lond Ophthalmol Hosp Rep* 1908;17:440–525.
- 2 Smithen LM, Brown GC, Brucker AJ, Yannuzzi LA, Klais CM, Spaide RF: Coats' disease diagnosed in adulthood. *Ophthalmology* 2005;112:1072–1078.
- 3 Bergstrom CS, Hubbard GB 3rd: Combination intravitreal triamcinolone injection and cryotherapy for exudative retinal detachments in severe Coats disease. *Retina* 2008;28(3 suppl):S33–S37.
- 4 Othman IS, Moussa M, Bouhaimed M: Management of lipid exudates in Coats disease by adjuvant intravitreal triamcinolone: effects and complications. *Br J Ophthalmol* 2010;94:606–610.
- 5 Venkatesh P, Mandal S, Garg S: Management of Coats disease with bevacizumab in 2 patients. *Can J Ophthalmol* 2008;43:245–246.
- 6 Goel N, Kumar V, Seth A, Raina UK, Ghosh B: Role of intravitreal bevacizumab in adult onset Coats' disease. *Int Ophthalmol* 2011;31:183–190.
- 7 Diago T, Valls B, Pulido JS: Coats' disease associated with muscular dystrophy treated with ranibizumab. *Eye (Lond)* 2010;24:1295–1296.
- 8 Woods AC, Duke JR: Coats' disease. I. Review of literature, diagnostic criteria, clinical findings and plasma lipid studies. *Br J Ophthalmol* 1963;47:385–412.
- 9 Shields JA, Shields CL, Honavar SG, Demirci H: Clinical variations and complications of Coats disease in 150 cases. The 2000 Sanford Gifford Memorial Lecture. *Am J Ophthalmol* 2001;131:561–571.
- 10 Tamura H, Miyamoto K, Kiryu J, Miyahara S, Katsuta H, Hirose F, Musashi K, Yoshimura N: Intravitreal injection of corticosteroid attenuates leukostasis and vascular leakage in experimental diabetic retina. *Invest Ophthalmol Vis Sci* 2005;46:1440–1444.
- 11 Lim WK, Nussenblatt RB, Chan CC: Immunopathologic features of inflammatory coats disease. *Arch Ophthalmol* 2005;123:279–281.

- 12 Haller JA, Bandello F, Belfort R Jr, Blumenkranz MS, Gillies M, Heier J, Loewenstein A, Yoon YH, Jacques ML, Jiao J, Li XY, Whitcup SM; OZURDEX GENEVA Study Group: Randomized, sham-controlled trial of dexamethasone intravitreal implant in patients with macular edema due to retinal vein occlusion. *Ophthalmology* 2010;117:1134–1146.e3.
- 13 Boyer DS, Faber D, Gupta S, Patel SS, Tabandeh H, Li XY, Liu CC, Lou J, Whitcup SM; for the Ozurdex CHAMPLAIN Study Group: Dexamethasone intravitreal implant for treatment of diabetic macular edema in vitrectomized patients. *Retina* 2011;31:915–923.
- 14 Lowder C, Belfort R Jr, Lightman S, Foster CS, Robinson MR, Schiffman RM, Li XY, Cui H, Whitcup SM; Ozurdex HURON Study Group: Dexamethasone intravitreal implant for noninfectious intermediate or posterior uveitis. *Arch Ophthalmol* 2011;129:545–553.