

Adverse reactions to targeted and non-targeted chemotherapeutic drugs with emphasis on hypersensitivity responses and the invasive metastatic switch

Brian A. Baldo · Nghia H. Pham

Published online: 17 September 2013
© Springer Science+Business Media New York 2013

Abstract More than 100 drugs are used to treat the many different cancers. They can be divided into agents with relatively broad, non-targeted specificity and targeted drugs developed on the basis of a more refined understanding of individual cancers and directed at specific molecular targets on different cancer cells. Individual drugs in both groups have been classified on the basis of their mechanism of action in killing cancer cells. The targeted drugs include proteasome inhibitors, toxic chimeric proteins and signal transduction inhibitors such as tyrosine kinase (non-receptor and receptor), serine/threonine kinase, histone deacetylase and mammalian target of rapamycin inhibitors. Increasingly used targeted vascular (VEGF) and platelet-derived endothelial growth factor blockade can provoke a range of pathological consequences. Many of the non-targeted drugs are cytotoxic, suppressing haematopoiesis as well as provoking cutaneous eruptions and vascular, lung and liver injury. Cytotoxic side effects of the targeted drugs occur less often and usually with less severity, but they show their own unusual adverse effects including, for example, a lengthened QT interval, a characteristic papulopustular rash, nail disorders and a hand–foot skin reaction variant. The term hypersensitivity is widely used across a number of disciplines but not always with the same definition in mind, and the

terminology needs to be standardised. This is particularly apparent in cancer chemotherapy where anti-neoplastic drug-induced thrombocytopenia, neutropenia, anaemia, vascular disorders, liver injury and lung disease as well as many dermatological manifestations sometimes have an immune basis. The most insidious of all adverse consequences of targeted therapies, however, are tumour adaptation, increased malignancy and the invasive metastatic switch seen with anti-angiogenic drugs that inhibit the VEGF-A pathway. Adverse reactions to 44 non-targeted and 33 targeted, frequently used, chemotherapeutic drugs are presented together with discussions of diagnosis, premedications, desensitizations and importance of understanding the mechanisms underlying the various drug-induced reactions. There is need for wide-ranging acceptance of what constitutes a hypersensitivity reaction and for allergists to be more involved in the diagnosis, treatment and prevention of chemotherapeutic drug-induced hypersensitivity reactions.

Keywords Chemotherapy-induced hypersensitivities · Cancer drug hypersensitivities · Cancer drug adverse effects · Hypersensitivities to chemotherapy drugs · Drug allergies · Drug hypersensitivities · Drugs and metastatic switch

Authors are retired.

B. A. Baldo · N. H. Pham
Molecular Immunology Unit, Kolling Institute of Medical Research,
Royal North Shore Hospital of Sydney, Sydney,
New South Wales, Australia

B. A. Baldo · N. H. Pham
Department of Medicine, University of Sydney, Sydney,
New South Wales, Australia

B. A. Baldo (✉)
11 Bent Street, Lindfield, New South Wales 2070, Australia
e-mail: babaldo@iinet.net.au

1 Adverse reactions to drugs

Forty years ago, The World Health Organization [1] defined an adverse drug reaction (ADR) as ‘a response to a drug that is noxious and unintended and occurs at doses normally used in man for the prophylaxis, diagnosis or therapy of disease, or for modification of physiological function’. This often-quoted definition and some others subsequently advanced have not always been universally accepted without criticisms especially with regard to the term ‘noxious’, the narrow use of ‘drug’, queries on just how minor an adverse reaction can be and other alleged ambiguities. While universal agreement on a

definition is unlikely, that proposed by Edwards and Aronson [2] seems adequate: ‘An appreciably harmful or unpleasant reaction, resulting from an intervention related to the use of a medicinal product, which predicts hazard from future administration and warrants prevention or specific treatment, or alteration of the dosage regimen, or withdrawal of the product’. Meanwhile, the US Food and Drug Administration (FDA) defines an adverse event as ‘any undesirable experience associated with the use of a medical product in a patient’ and states that any such serious event should be reported to the FDA [3]. A patient event is regarded as ‘serious’ when the outcome is death, life-threatening, hospitalisation, disability or permanent damage, congenital anomaly/birth defect, required intervention to prevent permanent impairment or damage (devices) and other serious important medical events (for example, allergic bronchospasm, serious blood dyscrasias or seizures or convulsions that do not result in hospitalisation).

ADRs have been classified into seven different reaction types A to G with group A termed augmented pharmacologic effects; B, bizarre; C, chronic (or continuous effects); D, delayed effects; E, end-of-treatment (or withdrawal) effects; F, failure of therapy and G, genetic reactions [2, 4]. For our purposes, types A and B, distinguished primarily on the basis of dose-related and non-dose-related reactions, respectively, are the reactions of main concern. Type A reactions are said to account for ~80 % of ADRs; reactions are predictable, can be anticipated from the drug’s pharmacological actions and are dose-dependent and resolve when the dose is reduced or withdrawn. Type B, or unpredictable reactions, sometimes called idiosyncratic drug reactions, are generally unrelated to the drug’s pharmacological actions and are independent of dose and usually (but not always) resolve when treatment is stopped. Type B reactions can be divided into immune-mediated or true allergic responses and non-immune, non-allergic sensitivities (Table 1). The immune-based category is made up of the true hypersensitivities defined by Gell and Coombs: type I, IgE antibody-mediated reactions; type II, cytotoxic reactions; type III, immune-complex-mediated hypersensitivities and type IV, delayed, cell-mediated responses [5]. Three type B non-immune drug sensitivities are recognized: pseudoallergy, idiosyncratic reactions and type B intolerances. Examples of the four allergic and three non-allergic sensitivities of type B ADRs are summarized side by side in Table 1. Many drugs that cause ADRs are not limited to one type of reaction, and some, such as the penicillins and non-steroidal anti-inflammatory drugs (NSAIDs), may be involved in up to four (including all four types of hypersensitivities) or even more different adverse responses.

2 Hypersensitivity reactions to drugs

The term hypersensitivity is a much misused term even within its ‘home’ discipline of allergy/immunology. In 2001, the

European Academy of Allergology and Clinical Immunology (EAACI) published a EAACI Position Statement entitled, in part, ‘A revised nomenclature for allergy’ [6]. Following this lead, the World Allergy Organization (WAO) set about promoting what was described as acceptable nomenclature for allergic diseases with the stated ultimate goal of improving communication in the field of allergy. In 2003, the WAO Nomenclature Review Committee defined ‘hypersensitivity’ as ‘objectively reproducible symptoms and signs initiated by exposure to a defined stimulus at a dose tolerated by normal persons’ [7]. Far from improving communication (and apart from the absence of any reference to the adverse nature of a reaction), this definition creates confusion in the mind of workers familiar with the accepted Gell and Coombs classification based on four types of hypersensitivities. It is also difficult for those reading and attempting to understand the existing allergy/immunology literature where ‘hypersensitivity’ is generally taken to mean adverse signs and symptoms initiated by an antigenic stimulus that is tolerated by a ‘normal’ person and which has an immune component or basis. Long-term usage of the terms immediate, delayed, cell-mediated and types I, II, III and IV hypersensitivity has become ingrained and synonymous with immune reactions. Reactions to some drugs show features of a hypersensitivity response even though no immune mechanism has yet been identified. Examples include some (not all) reactions to contrast media [8] and NSAIDs where, in the latter case, drug-induced redirection of mediator synthesis in the arachidonic acid cascade from the cyclooxygenase to the lipoxygenase pathway occurs [9]. In these cases, such reactions can be described as ‘sensitivities’ or ‘intolerances’ rather than ‘non-allergic hypersensitivity’ recommended by the WAO. In terms of the Gell and Coombs definitions and classifications [5], ‘non-allergic hypersensitivity’ is essentially a contradiction in terms.

2.1 Use of the term ‘hypersensitivity’ in relation to chemotherapeutic drugs

Across all medical disciplines, and in the community at large, it is well-known that drugs used to treat cancers cause a range of detrimental side effects ranging from mild (e.g. appetite suppression) to severe (e.g. bone marrow suppression) and even death. Unfortunately, and for a number of reasons, medical/scientific classification of these reactions is often deficient, and this is particularly apparent for many adverse reactions incorrectly described as ‘hypersensitivities’ [10] and for others where that description was not applied when it was clearly appropriate. In the area of side effects of chemotherapeutic drugs then, the picture is confusing and in need of standardisation in both definitions and the use of terms. The term ‘hypersensitivity’ remains widely used, for example in the oncology literature, clinical trial reports, pharmaceutical

Table 1 Classification of immune (hypersensitivity) and non-immune type B adverse drug reactions

Immune (allergic; hypersensitivity)		Non-immune (non-allergic sensitivities)	
Hypersensitivity type ¹	Drug examples	Sub-types	Examples of sensitivities
Type I ² (IgE antibody-mediated)	Penicillins; cephalosporins; neuromuscular blockers; quinolones; pyrazolones; ppi; L-asparaginase; mAbs	Pseudoallergy ³	Most reactions to NSAIDs. Direct mast cell degranulation (neuromuscular blockers; opioids; contrast media; vancomycin)
Type II ⁴ (antibody [IgG, IgM]-mediated cytotoxic reactions)	Penicillins; cephalosporins; quinine; quinidine; sulphonamides; thiouracil; gold salts; oxaliplatin; fludarabine; irinotecan; suramin; mAbs	Idiosyncratic reactions ⁵	Halothane hepatitis; malignant hypothermia; drug-induced anaemia in Glu-6-PO ₄ dehydrogenase deficient individuals (antimalarials, sulphonamides, dapsone)
Type III ⁶ (immune complex-mediated via IgG, IgM)	Penicillins; cephalosporins; sulphonamides; tetracycline; NSAIDs; carbamazepine; allopurinol; mAbs; oxaliplatin	Intolerance	Tinnitus induced by small doses aspirin. Some reactions to contrast media and NSAIDs ⁷
Type IV ⁸ (delayed; T cell-mediated)	NSAIDs; penicillins; other antimicrobials; anticonvulsants (carbamazepine); local anaesthetics; sulphonamides; hydroxychloroquine; cytarabine; tamoxifen; imatinib; mAbs		

Type B are so-called ‘bizarre’ reactions. Uncommon relative to type A (‘augmented’, pharmacologic effects) reactions, unpredictable, rarely dose-dependent and unrelated to drug’s pharmacologic action. Reactions show high mortality relative to other categories of ADRs

ppi proton pump inhibitors, *NSAIDs* non-steroidal anti-inflammatory drugs

¹ Defined and classified according to Gell and Coombs [5]

² e.g. anaphylaxis, bronchospasm, cardiovascular collapse, urticaria, angioedema

³ May closely resemble true type I reactions—termed anaphylactoid.

⁴ e.g. drug-induced haemolytic anaemia, immune thrombocytopenia, immune form of agranulocytosis

⁵ May be unrelated or related to dose. Uncommon, unpredictable, unrelated to drug’s pharmacologic action

⁶ e.g. serum sickness, drug-induced vasculitis

⁷ Reactions that are clearly not hypersensitivity responses, pseudoallergic or idiosyncratic in nature

⁸ e.g. allergic contact dermatitis, psoriasis, maculopapular exanthema, acute generalized exanthematous pustulosis, drug reaction with eosinophilia and systemic symptoms, erythema multiforme, fixed drug eruption, Stevens–Johnson syndrome, toxic epidermal necrolysis

company drug descriptions and pharmacological studies but clearly it does not always mean the same thing—no common definition has been adopted within and between disciplines. The word is often used to cover reactions that clearly have no immune basis and which are otherwise not easy to classify [11]. On the other hand, since mechanisms for many drug reactions are not known, generally not investigated and appropriate tests are either not at hand or even developed, some true hypersensitivities remain unrecognised and therefore incorrectly classified.

3 Chemotherapeutic drugs and their classification on the basis of mechanism of action

The number of drugs used for the treatment of the many different cancers is in excess of 100 and growing [12, 13] and this is

reflected in the numbers approved by the FDA, those awaiting approval, entries in the National Cancer Institute (NCI) drug dictionary and new drugs being assessed in clinical trials [13, 14]. Many of the compounds used in chemotherapy for many years have cytotoxic properties arising from a limited number of different mechanisms of action. These drugs represent a wide range of chemical structures and include, amongst other actions, alkylating agents, antimetabolites, cytoskeletal disruptors and drugs that directly affect DNA or protein synthesis [15]. These are all agents with relatively broad, rather than targeted and specific, modes of action. Alkylating agents like busulfan, nitrogen mustards and the platinum-based agent cisplatin that cross-link DNA; antimetabolite nucleoside analogues like gemcitabine; inhibitors of mitotic cell division by taxanes and *Vinca* alkaloids; drugs that intercalate with DNA like actinomycin D; pyrimidine analogues including 5-fluorouracil and folate antimetabolites such as pemetrexed are typical examples of non-targeted drugs

that contrast with drugs developed from current strategies based on a more refined understanding of individual cancers and a research focus on selected molecular targets for specific types of cancers [15]. Signal transduction inhibitors which include tyrosine kinase and mammalian target of rapamycin (mTOR) and proteasome inhibitors are examples of the latter approach [16]. The literature contains a number of different classifications of chemotherapeutic agents based on chemical structure (e.g. alkylsulphonates, anthracyclines, diterpines, organoplatinum agents), mechanisms of action, broad pharmacological categories (e.g. antibiotics, hormones), plant origin (taxanes, *Vinca* alkaloids) and where drugs act in the cell cycle (S, M, G1 or G2 phase). In many published classifications, these different categories are mixed together, for example, as divisions into alkylating agents, antibiotics, topoisomerase inhibitors, drugs derived from plants etc. (see, for example, [17]) rather than a division based on a single criterion such as mechanism of action or chemical class. Of course, any classification based on a single shared factor/property for all chemotherapeutic drugs is not straight forward. Many of the drugs show more than one mechanism of action, chemical structures even within one group can be quite diverse (e.g. alkylating agents) and some features (e.g. being plant-derived) are seen in only a few compounds. The classification selected here is based firstly on the division into non-targeted (Table 2) and targeted drugs (Table 3) and then on what is currently known of each drug's mechanism(s) of action.

3.1 Non-targeted drugs

The anti-cancer action of traditional drugs used for chemotherapy depends on their capacities to destroy rapidly dividing uncontrolled cancer cells via their cytotoxic properties or by causing the cells to undergo apoptosis. However, these drugs also harm normal rapidly dividing cells such as those in the gastrointestinal tract, bone marrow and hair follicles causing well-known side effects like mucositis, stomatitis, myelosuppression and alopecia. This absence of targeted specificity contrasts with the current strategy of selectively killing a particular type of cancer cell. Some of the earliest anti-neoplastic drugs were alkylating agents that act by damaging DNA. A number of chemically different types of alkylating chemicals such as nitrogen mustards (e.g. chlorambucil), alkyl sulphonates (busulfan), nitrosoureas (carmustine), triazines (dacarbazine) and ethylenimines (altretamine) (Table 2) are still administered to cancer patients. Anti-metabolites made up essentially of pyrimidine analogues (e.g. 5-fluorouracil), nucleoside analogues (gemcitabine) and anti-folates (methotrexate) form a second large group of what are still the most widely used cytostatic/cytotoxic drugs in cancer therapy. A third group, the mitotic inhibitors containing the important taxanes docetaxel and paclitaxel, inhibit mitotic cell division by binding to microtubules while L-asparaginase is an important example of a small number of drugs that affect leukemic cells by

disrupting protein synthesis. A chemically diverse variety of structures comprising many different drugs is used for chemotherapy by virtue of the direct drug effects on DNA (Table 2). This group includes inhibitors of DNA synthesis such as hydroxyurea, a number of structurally different compounds (organoplatinum agents, the antibiotic mitomycin C and pyrrolbenzodiazepines [132]) that cross-link DNA, topoisomerase I and II inhibitors, drugs such as the antibiotic mitomycin C that intercalate between DNA base pairs, inhibitors of DNA methylation (azacitidine), bleomycin which induces breaks in DNA and inhibitors of the poly-ADP ribose polymerase (PARP) family of enzymes that are critical in the maintenance of DNA integrity and repair [133]. PARP inhibitors appear to trap PARP1 and PARP2 enzymes at damaged DNA sites. These trapped enzyme–DNA complexes block DNA replication and are highly toxic to cells. In fact, it has been suggested that PARP inhibitors should be assessed on their potency to trap PARP as well as on their capacities to inhibit the enzymes. As shown in Table 2, some chemotherapeutic drugs demonstrate more than one anti-tumour activity. For example, the platinum drugs which cross-link DNA and are sometimes classified along with the alkylating agents and the anthracycline antibiotics daunorubicin (or daunomycin) and doxorubicin (adriamycin) show both topoisomerase II inhibitory activity and also intercalate between base pairs in the DNA helix thus preventing DNA replication and protein synthesis. Lenalidomide [134], listed in Table 2 in the ‘miscellaneous’ group, is related to the teratogenic drug thalidomide. It has a number of different activities suggesting its application to a range of haematological and solid tumours.

3.2 Targeted drugs

Specific and effective targeting of tumour cells without accompanying toxicity has always been desired in cancer therapy, and this has started to be realized with the introduction of monoclonal antibodies (mAbs) and signal transduction therapies. The former proteinaceous agents, unlike pharmacologically active ‘small’ molecules, utilize precise immunological targeting of cancer cells and are not considered here. The principle of signal transduction therapies is shown diagrammatically in Fig. 1. Signal transduction [16] involves the utilization of biochemically induced signals generated by a range of large and small molecules such as growth factors, neurotransmitters, hormones, cytokines, chemokines and ATP into a wide variety of cell responses like cell division, metabolic changes, gene expression and cell death. Signal transduction therapy then depends on identifying signalling proteins and their altered pathways. The original employment of this approach for cancer therapy goes back to the use of tamoxifen as an oestrogen receptor antagonist in treating some forms of breast cancer that are dependent on oestrogen for their growth [135]. Since this early breakthrough with

Table 2 Classification of non-targeted chemotherapeutic drugs used for cancers and their hypersensitivity/adverse reactions

Drug generic and trade names and classification ¹ on the basis of mechanism	Cancer indications	Mechanism(s) ¹ of action	Hypersensitivity ² /adverse ³ reactions		References
			Systemic	Cutaneous	
Alkylating agents					
Alkyl sulphonates					
Busulfan (Myleran®, Busulfex®)	CML. May be given prior to bone marrow/stem cell transplantation	Alkylation producing guanine-adenine cross-links	Interstit pneumonia; pulm fibrosis; thrombocytopenia; leukopenia; anaemia veno-occlusive disease	Urticaria; mer; hyper pigm; alopecia; erythema multiforme; xerosis	[18, 19]
Nitrogen mustard					
Chlorambucil (Leukeran®)	CLL; NHL; WM	Alkylation of guanine at N-7 and cross-linking of DNA	Fever; thrombocytopenia; anaemia; neutropenia; iha; interstit pneumonitis; GI; hepatotox	Urticaria; contact dermatitis; exanthems; neh; erythema multiforme; stomatitis; ten	[19–21]
Cyclophosphamide (Cytosar®, Endoxan®, Neosar®)	Lymphomas; brain; leukemia	Alkylation of guanine at N-7 and cross-linking of DNA	Anaphylaxis; bronchospasm; bms; GI; haemorrhagic cystitis	Urticaria; angioedema; acral erythema; erythema multiforme; pigm (skin, nails); stomatitis;	[19, 21–24]
Ifosfamide (Ifex®)	Breast; brain; bone; cervical; lung; ovarian; lymphomas	Alkylation and cross-linking of DNA	Bronchospasm; myelosuppression; thrombocytopenia; encephalopathy; nephrotoxicity; GI	Erythema; stomatitis; alopecia; hyper pigm	[21, 25]
Mechlorethamine (Mustargen®)	CML; CLL; CTCL; HL; NHL; brain	Alkylation of guanine at N-7 and cross-linking of DNA	Anaphylaxis; lymphocytopenia; GI	Urticaria; angioedema; acd; hyper pigm; pruritus; erythema multiforme; sjs	[26]
Melphalan (Alkeran®)	MM; ovarian	Alkylation of guanine at N-7 and cross-linking of DNA	Anaphylaxis; interstit pneumonitis; pulm fibrosis; bms	Rash; urticaria; angioedema; pruritus; stomatitis; scleroderma; erythema; alopecia	[27, 28]
Nitrosoureas					
Carbustine ⁴ (BiCNU®)	Brain; MM; lymphomas	Alkylates DNA and RNA and cross-links DNA	Thrombocytopenia; leukopenia; anaemia; pulm fibrosis infiltrates; GI	Flush; erythema; isr; dermatitis; alopecia; hyper pigm	[19]
Streptozocin ⁵ (Zanosar®)	Brain; HL; islet cells pancreas ⁶	Transported into pancreas β-cells via GLUTZ. Damages DNA and activates poly ADP-riboseylation	Renal toxicity; fever; pulm fibrosis; bms	Urticaria; isr; alopecia; stomatitis	[29]
Triazines					
Dacarbazine (DTIC-Dome®)	Malign melanoma ⁷ ; HL; sarcoma; islet cells pancreas; neuroblastoma	3 hypotheses: Forms carbonium ions that attack DNA; acts as purine analogue and inhibits DNA and RNA synth.; interacts with SH groups	Anaphylaxis ⁷ ; fever; hyper eosinophilia; allergic hepatitis ⁸ ; bms; GI	Rash; photosensitivity; isr; urticaria	[19, 30]
Temozolomide (Temodar®, Temodal®)	Brain; melanoma	Alkylates DNA at N-7 or O-6 of guanine	Anaphylaxis; fever; peripheral oedema; pneumonitis; GI; thrombocytopenia; neutropenia	Rash; pruritus; photosensitivity; acral erythema; urticaria; pigm; mpr; sjs; ten; alopecia	[31, 32]
Ethyl/enamines					
Altretamine (Hexalen®)	Ovarian	N-Demethylation gives intermediates (e.g. formaldehyde and iminium species) that react with and damage DNA	Thrombocytopenia; anaemia; leukopenia; sensory neuropathy; CNS symptoms	Rash and alopecia rare; itching	[33]
ThioTEPA (Thioplex®)	Ovarian; breast; CNS; bladder; leukemia; MM	Ethylimine cross-links DNA ⁹	Fever; anaphylaxis; wheeze; bms; thrombocytopenia; anaemia; leukopenia; GI	Rash; urticaria; angioedema; pruritus; pigm; isr; alopecia; dermatitis	[21, 34]
Antimetabolites					
Pyrimidine ¹⁰ analogues					
Capecitabine (Xeloda®)	Colorectal; pancreatic; metastatic breast; stomach	Prodrug converted to 5-fluorouracil (see below)	Lymphopenia; thrombocytopenia; neutropenia; anaemia; CV symptoms; GI	Acral erythema; erythema; exfol. dermatitis; ppk; stomatitis; photosensitivity; hyper pigm; mpr; arak	[21, 35, 36]

Table 2 (continued)

Drug generic and trade names and classification ¹ on the basis of mechanism		Cancer indications	Mechanism(s) ¹ of action	Hypersensitivity ² /adverse ³ reactions		References
				Systemic	Cutaneous	
Cytarabine (Cytosar-U®), Tarabine PFS®; AraC®)	AML; NHL; ALL	Cytosine arabinoside similar to deoxycytosine—competitively incorporated into DNA	Anaphylaxis; thrombocytopenia; leucopenia; fever; dyspnea; ards; GI; hepatotox; bleeding	Urticaria; angioedema; acral erythema; pruritus; ten; vasculitis; agep; neh; mpr ¹¹	[19, 21, 24, 37]	
5-Fluorouracil (Efidex®, Adrucil®)	Colorectal; breast; pancreatic	Inhibition of thymidylate synthase	Anaphylaxis; myelosuppression; GI; mucositis	Acral erythema; mpr; pigm; photo-sensitivity; stomatitis; contact dermatitis; isr; alopecia ¹²	[19, 21, 38]	
Gemcitabine (Gemzar®)	NSCL; pancreatic; breast; ovarian; bladder	Nucleoside analogue—replaces cytidine during DNA replication	Fever; hypersens pneumonitis; flu-like symptoms; GI; leukopenia; neutropenia; anaemia; thrombocytopenia	mp; pruritus; acral erythema; bullous dermatitis; vasculitis; stomatitis; sjs; ten; rrr	[21, 39, 40]	
Purines						
Cladribine (Liotac®, Movectro®)	HSL; pediatric AML	Inhibits adenosine deaminase and processing of DNA	Fever; DIHA ¹³ ; increased risk virus (e.g. herpes) infection; fall in blood count; periph neuropathy; GI; tds; lid	Exanthems; oedema; skin eruptions with cosmophil infiltrates; isr; sjs; ten	[21, 41, 42]	
Fludarabine (Fludara®)	CLL; AML; NHL	Inhibits ribonucleotide reductase and DNA polymerase	Lymphopenia; DIHA ¹³ ; thrombocytopenia; neutropenia; alat; GI; ards	mp; acral erythema; oedema; psoriasis; stomatitis	[21, 43]	
6-Mercaptopurine (Purinethol®)	ALL; pediatric NHL	Inhibits purine nucleotide synthesis and metabolism	Myelosuppression—toxic to bone marrow; pancreatitis; fever; GI	Rashi; itching; hyper pigm; ulcerative stomatitis	[44]	
Pentostatin ^{14,15} (Nipent®)	HSL; CLL	Inhibits adenosine deaminase and processing of DNA	Anaphylaxis; fever; flushing ¹⁶ ; GI; leucopenia; thrombocytopenia; anaemia	Rash; mpr; purpura; stomatitis; hypersens vasculitis; oedema; photosensitivity; xerosis; pruritus	[21, 45, 46]	
Folate antagonists						
Methotrexate ¹⁷ (formerly Ammethopterin) (Trexall®)	Breast; head; neck; lung; bladder; leukemia; lymphoma	Inhibits dihydrofolate reductase	Anaphylaxis; bronchospasm; pulm infiltrates; haemolytic anaemia; agranulocytosis; myelosuppression; hepatotox; GI ¹⁷	Acral erythema; rash; pruritus; urticaria; vasculitis; erythema multiforme; photosensitivity; stomatitis; psoriasis; pigm; sjs; ten; alopecia ¹⁷	[19, 21, 24, 38, 47]	
Pemetrexed (Alimta®)	NSCL; mesothelioma	Inhibits enzymes in purine and pyrimidine synthesis	Neutropenia; thrombocytopenia; anaemia; intersti pneum; dyspnea; GI; mucositis	Rash; pruritus; vasculitis; mucositis; stomatitis; ten; alopecia ¹⁸	[48, 49]	
Mitotic inhibitors						
Taxanes						
Docetaxel (Taxotere®)	Breast; NSCL; ovarian; prostate	Binds to microtubules and inhibits mitotic cell division	Anaemia; neutropenia; leukopenia; bronchospasm; dyspnea; back pain; GI	Acral erythema; scleroderma-like; cle; stomatitis; rrr; isr; nail abnormalities; ten	[19, 21, 24]	
Paclitaxel (Abraxane®, Taxol®)	Lung; breast; ovarian; head and neck; bladder; testicular; Kaposi's	Binds to β -tubulin subunits; suppresses microtubule function; blocks mitosis	bms; neutropenia; hypersens pneumonitis; dyspnea; back pain; GI; neurotox ¹⁹	Acral erythema; isr; erythema multiforme; rr; agep-like; sjs; alopecia ⁹	[19, 21, 24]	
Vinca alkaloids						
(a) Vinblastine, (b) vincristine, (c) vindesine, (d) vinorelbine (Velban®, Oncovin®, Eldisine®, Navelbine®)	(a) HL; NSCL; head and neck; NHL; breast. (b) HL; WT; leukemia. (c) Melanoma; lung; breast; leukemia. (d) Breast; bone; NSCL	Binds to tubulin, prevents spindle formation and cell division	Anaphylaxis; fever; bronchospasm; arf; pulm oedema; pleural effusion; intersti pneumonitis	Acral erythema; rash; phlebitis; cellulitis; stomatitis; nail lesions; alopecia; Raynaud's phenomenon	[21, 50–52]	

Table 2 (continued)

Drug generic and trade names and classification ¹ on the basis of mechanism	Cancer indications	Mechanism(s) ¹ of action	Hypersensitivity ² /adverse ³ reactions		References
			Systemic	Cutaneous	
Drugs that interact with or otherwise directly affect DNA ²⁰					
Inhibitors of DNA synthesis					
Hydroxyurea (Hydrea®, Droxia®)	CML; myeloproliferative disorders	Prevents reduction of ribonucleotides to deoxyribonucleotides ²¹	Fever; hypersens pneumonitis; bms; GI	Cutaneous-mucosal oral and leg ulcers; acral erythema; hyper pigm; keratoderma; keratosis; stomatitis; dermatomyositis-like; xerosis; lichen-plamus-like; nail alterations; alopecia ²²	[21, 53, 54]
DNA cross-linkers					
Carboplatin (Paraplatin®), Paraplatin-AQ®)	Ovarian; lung; breast; head and neck; testicular; brain (children)	Cross-links DNA following formation of an aqua ligand (Cl displaced by H ₂ O) which binds to bases, preferably guanine As for carboplatin	Anaphylaxis; bms; GI; bronchospasm; dyspnea; periph neuropathy	Rash; pruritus; urticaria; angioedema; erythema; oedema	[19, 21, 55–57]
Cisplatin (Platinol®)	Sarcomas; ovarian; lymphomas; lung; germ cell	As for carboplatin	Anaphylaxis; bronchospasm; dyspnea; haemolytic anaemia; sens neuropathy; GI; renal tox	Flushing; rash; urticaria; pruritus	[19, 21, 24, 57]
Oxaliplatin (Eloxatin®)	Colorectal ²³ ; ovarian; gastric	As for carboplatin	Anaphylaxis; fever; dyspnea; wheezing; sens neuropathy; GI; types II and III hypersens ²⁴	Flushing; erythema; urticaria; angioedema; pruritus; rash; acral erythema; rr	[21, 24, 57, 58]
Mitomycin C ²⁵ (Mutamycin®), Mitozytrex®)	Oesophageal; bladder; breast; stomach; pancreas	Cross-links DNA by two N-alkylations of guanosine nucleoside. Specific for 5'-CpG-3'. Inhib'n of thioedoxin reductase	Bone marrow toxicity; iid; eosinophilic cystitis; hus	accl; icd; dermatitis of hands, feet and/or genitals; cellulitis ²⁶	[19, 21, 59]
Cross-linkers of opposite DNA strands					
Pyrimobenzodiazepine dimers (e.g. SIG-136, NSC 694501) ²⁹	Ovarian ²⁷	In minor groove of DNA, the two imines react with and link N-2 positions on guanines on opposite DNA strands	Thrombocytopenia; vls (oedema, dyspnea, hypoalbuminemia, pleural effusion, ascites); dlt	– ²⁸	[60, 61]
Topoisomerase inhibitors					
Topoisomerase I inhibitors					
Topotecan (Hycamtin®)	Ovarian; cervical; SCL	Stabilizes topo-I complexes inhibiting re-ligation of single strand breaks and leading to lethal double-strand breaks Prodrug. Metabolite (SN-38) inhibits topo-I leading to DNA breaks	bms; alveolar damage; cop; GI	mp; pruritus; neh; stomatitis; alopecia	[62, 63]
Irinotecan (Camptosar®)	Colon	Prodrug. Metabolite (SN-38) inhibits topo-I leading to DNA breaks	Anaphylaxis; neutropenia; anaemia; dyspnea	Rash; alopecia	[64, 65]
Topoisomerase II inhibitors					
Daunorubicin (Cenubidine®)	AML; ALL; neuroblastoma	Intercalates between base pairs in DNA helix (see below). Inhibits topo-II and prevents ligation of nucleotide strand after double strand breaks As for daunorubicin	bms; anaphylaxis; fever; cardiac tox; GI	Rash; urticaria; angioedema; hyper pigm	[19, 21, 24, 66]
Doxorubicin (Doxil®)	HL; haematological; ovarian; breast; lung; bladder; Kaposi's	As for daunorubicin	Anaphylaxis; myelosuppression; bronchospasm; hir; cardiotoxicity; GI	Rash; acral erythema; isr; pruritus; urticaria; angioedema; neh; rr	[19, 21, 24, 67]

Table 2 (continued)

Drug generic and trade names and classification ¹ on the basis of mechanism	Cancer indications	Mechanism(s) ¹ of action	Hypersensitivity ² /adverse ³ reactions		References
			Systemic	Cutaneous	
Etoposide (Etopophos®)	SCL; germ cell; Kaposi's and ES	Inhibits topo-II and ligation of cleaved DNA leading to single and double-stranded DNA breaks	Myelosuppression; fever; hypotension; tachycardia; bronchospasm; dyspnea; GI	Flushing; exanthema; urticaria; alopecia; pruritus; hyper pigm	[19, 21, 24]
Teniposide (Vumon®, Vohem®)	ALL	Complexes with topo-II and DNA causing single and double-stranded breaks in DNA and inhibition of strand re-ligation	bms; fever; hypotension; bronchospasm; wheeze; intravascular haemolysis ³⁰ ; GI	Stomatitis; alopecia; rash; facial oedema; urticaria ³⁰	[19, 21, 24]
Mitoxantrone (Novantrone®)	Breast; AML; NHL; ALL	Intercalates with DNA and inhibits topo-II disrupting DNA repair and synthesis	Anaphylaxis; myelosuppression; GI; CV effects	isr; rash; purpura; nail discoloration; stomatitis; alopecia; dress	[21, 68]
Intercalation with DNA					
Actinomycin D ³¹ (Cosmegen®)	WT; ES; testicular; trophoblastic	Intercalates between adjacent base pairs of DNA; prevents elongation of RNA by RNA polymerase; stabilizes complexes of topo-I and topo-II with DNA	Leukopenia; anaemia; GI; hepatotox	Rash; isr; stomatitis; rr; alopecia; photosens	[69–71]
Daunorubicin	AML; ALL; neuroblastoma	Intercalates between base pairs in DNA helix preventing DNA replication and protein synthesis.	bms; anaphylaxis; fever; cardiac tox; GI	Rash; urticaria; angioedema; hyper pigm	[19, 21, 24, 66]
Doxorubicin	HL; haematological; ovarian; breast; lung; bladder; Kaposi's	See also topoisomerase II inhibitors (above)	Anaphylaxis; myelosuppression; bronchospasm; hir; cardiotoxicity; GI	Rash; acral erythema; isr; pruritus; urticaria; angioedema; neh; rr	[19, 21, 24, 67]
Inducers of DNA breaks					
Bleomycin ³² (Blenoxane®)	HL; NHL; SCC; testicular; squamous cell	Causes breaks in DNA by unresolved mechanism (may chelate metal ions producing superoxide and hydroxide radicals; blocks uptake of thymidine by DNA). Mediates oxidative degradation of cellular RNA	Hypotension; interstit pneumonitis; pulm fibrosis; fever ³³	Rash; pruritus; angioedema; scleroderma-like; Raynaud's syndrome; sjs; alopecia erythema; hyper pigm	[19, 21, 72]
Inhibitors of DNA methylation					
Azacitidine (Vidaza®)	MDS; AML	Inhibition of DNA methyltransferase which prevents DNA synthesis; cytotoxic to abnormal haematopoietic cells in bone marrow via incorporation into DNA and RNA	bms; thrombocytopenia; anaemia; neutropenia; GI; pyrexia; periph oedema; dyspnea; cough; anaphylaxis	Rash; isr; ecchymoses; xerosis; petechiae; erythema; urticaria; pruritus; Sweet's syndrome	[73, 74]
Inhibitors of DNA repair					
PARP inhibitors (e.g. Iniparib, Olaparib, Niraparib, Rucaparib, Veliparib)	In clinical trials for breast, lung and ovarian cancers and metastatic melanoma	Block repair of DNA single strand breaks (ssb); trap PARPs 1 and 2 at damaged DNA sites—trapped DNA-PARP complexes more cytotoxic than unrepaired ssb	Myelosuppression	Drugs still in clinical trials with little definite information on adverse reactions available	[75, 76]
Disruption of protein synthesis					
L-Asparaginase ³⁴ (Elspar®)	ALL; AML	Hydrolyses L-asparagine to L-aspartic acid and NH ₃ . Some leukemia cells cannot synthesize L-asparagine resulting in inhibition of protein synthesis	Anaphylaxis ³⁵ ; laryngospasm; bms (transient); GI; pancreatitis	Urticaria; angioedema; rash; pruritus; stomatitis; ten	[19, 21, 24]

Table 2 (continued)

Drug generic and trade names and classification ¹ on the basis of mechanism	Cancer indications	Mechanism(s) ¹ of action	Hypersensitivity ² /adverse ³ reactions		References
			Systemic	Cutaneous	
Miscellaneous group					
Lenalidomide (Revlimid®)	MM; MDS	Multiple actions: Inhibits proliferation and apoptosis of tumour cells; activates immune T and NK cells; induces cytokine prod'n; anti-angiogenic prop's	Thrombocytopenia; anaemia; neutropenia; hypersens pneumonitis; thrombosis; pulm embolism; hepatotoxicity; GI; respiratory effects	Rash (morbilliform, urticarial, dermatitic, acneiform); pruritus; sjs; xerosis; erythema; ecchymosis; erythema multiforme	[21, 77]
<p><i>act</i> allergic contact dermatitis; <i>agep</i> acute generalized exanthematous pustulosis; <i>ALL</i> acute lymphocytic leukemia; <i>AML</i> acute myeloid leukemia; <i>anrk</i> acute respiratory distress syndrome; <i>arf</i> acute respiratory failure; <i>bms</i> bone marrow suppression; <i>cdc</i> cutaneous lupus erythematosus; <i>CLL</i> chronic lymphocytic leukemia; <i>CMF</i> chronic myeloid leukemia; <i>cop</i> cryptogenic organising pneumonia; <i>CTCL</i> cutaneous T cell lymphoma; <i>difl</i> drug-induced disease flare (tumour flare effect); <i>DHHA</i> drug-induced immune haemolytic anaemia; <i>dlc</i> delayed liver toxicity; <i>drxs</i> drug reaction (rash) with eosinophilia and systemic symptoms; <i>ed</i> eosinophilic lung disease; <i>ES</i> Ewing's sarcoma; <i>GI</i> gastrointestinal symptoms, e.g. one or more of nausea, vomiting, diarrhoea, constipation, appetite reduction, dyspepsia etc.; <i>hr</i> hypersensitivity infusion reaction; <i>HLL</i> Hodgkin's lymphoma; <i>HCL</i> hairy cell leukemia; <i>hns</i> haemolytic uremic syndrome; <i>icd</i> irritant contact dermatitis; <i>ila</i> immune haemolytic anaemia; <i>ild</i> interstitial lung disease; <i>isr</i> injection site reaction; <i>MDS</i> myelodysplastic syndrome; <i>MM</i> multiple myeloma; <i>mpr</i> maculopapular rash; <i>nec</i> neutrophilic eccrine hidradenitis; <i>NHL</i> non-Hodgkin lymphoma; <i>NSCL</i> non-small cell lung cancer; <i>pigm</i> pigmentation; <i>ppk</i> palm-plantar keratoderma; <i>rps</i> relapsing polychondritis cutaneous symptoms; <i>rrr</i> radiation recall reaction (dermatitis); <i>SCC</i> squamous cell carcinoma; <i>SCL</i> small cell lung cancer; <i>sjs</i> Stevens-Johnson syndrome; <i>ten</i> toxic epidermal necrolysis; <i>u6</i> vascular leak syndrome; <i>WAM</i> Waldenström's macroglobulinaemia; <i>WT</i> Wilms' tumour</p> <p>¹ Some drugs exert their action(s) by more than one mechanism and might therefore be classified into more than one category. The classification shown is deemed to be the most appropriate one</p> <p>² Reactions known or suspected of having an immunological basis</p> <p>³ Reactions such as weakness, fatigue, headache etc. and symptoms like nausea, vomiting, diarrhoea, constipation, appetite suppression etc. are not listed since they are common to so many of the drugs. Where a latter symptom(s) (i.e. nausea etc.) is important, it is referred to as 'GI'</p> <p>⁴ Allergic reactions ~1 %</p> <p>⁵ Antibiotic from <i>Streptomyces</i> achromogenes</p> <p>⁶ Streptozocin toxic to pancreas β cells</p> <p>⁷ Twenty percent patients with metastatic malignant melanoma are hypersensitive</p> <p>⁸ Hepatic veno-occlusive disease (Budd-Chiari syndrome)</p> <p>⁹ Precise mechanism not known</p> <p>¹⁰ Approximately 28 % of population dithydropyrimidine dehydrogenase deficient, i.e. genetic inability to metabolize pyrimidine-based drugs</p> <p>¹¹ Up to 73 % patients have rash. Type I reaction rare</p> <p>¹² Palm-plantar dermatitis a risk factor for hypersensitivity reactions</p> <p>¹³ Drug may induce autoantibodies without becoming bound to red cells</p> <p>¹⁴ Antibiotic from <i>Streptomyces antibioticus</i></p> <p>¹⁵ Concomitant use of allopurinol a risk of hypersensitivity reactions</p> <p>¹⁶ Incidence of hypersensitivity 0.5–1 %</p> <p>¹⁷ Implicated in type I (anaphylaxis, urticaria, angioedema), type II (haemolytic anaemia) and type III (pneumonitis, cutaneous vasculitis) hypersensitivity reactions</p> <p>¹⁸ Incidence of cutaneous reactions ~14 %</p> <p>¹⁹ Reaction 10–16 % without premedication</p> <p>²⁰ Inhibits DNA synthesis/repair or methylates or damages DNA</p> <p>²¹ Acis in S phase but detailed mechanism of action remains uncertain</p> <p>²² Cutaneous manifestations in up to 35 % patients</p> <p>²³ Administered in combination with 5-fluorouracil, folic acid and leucovorin—FOLFOX</p> <p>²⁴ Type II thrombocytopenia and type III immune complex-mediated urticaria hypersensitivities occur</p> <p>²⁵ Antibiotic from <i>Streptomyces caespitosus</i> or <i>Streptomyces lavendulae</i></p> <p>²⁶ Cutaneous reactions in 9 % patients after intravascular administration</p> <p>²⁷ Now in phase 2 trial</p> <p>²⁸ Insufficient data available yet</p> <p>²⁹ In development</p> <p>³⁰ Reactions in ~41 % children with ALL treated with teniposide and other chemotherapy drugs</p> <p>³¹ Antibiotic from <i>Streptomyces parvulus</i>. Also known as dactinomycin</p> <p>³² Glycopeptide antibiotic from <i>Streptomyces verticillus</i></p> <p>³³ Fever in up to 25 % patients and fulminant reactions in up to 8 %</p> <p>³⁴ Enzyme from <i>Escherichia coli</i> or <i>Erwinia carotovora</i></p> <p>³⁵ Frequency of antibodies to L-asparaginase up to 79 % in adults and 70 % in children. Hypersensitivity to <i>E. coli</i> L-asparaginase up to 45 %. <i>Erwinia</i> enzyme used in patients allergic to <i>E. coli</i> enzyme</p>					

tamoxifen, aromatase inhibitors such as exemestane [136] and anastrozole that prevent the conversion of androgens to oestrogens and some hormone analogues (goserelin) [137] and anti-androgens (bicalutamide, flutamide) have been part of the targeted therapeutic approach to breast and prostate cancers [138] (Table 3). The first signalling proteins to be utilized as targets for a new generation of unique anti-cancer drugs were protein kinases. The strategy adopted was based on the instability of the cancer genome compared to the normal cell. The Philadelphia translocation t(9;22)(q34;q11) is a chromosomal defect resulting in gene fusion of the BCR gene on chromosome 22 (region q11) and ABL tyrosine kinase gene on chromosome 9 (region q34), producing the BCR-ABL oncogene. The Philadelphia chromosome abnormality is seen in 95 % of chronic myeloid leukemia (CML) patients and 15 to 30 % of adults with acute lymphoblastic leukemia (ALL). CML cells show absolute dependence ('oncogene addiction') on the kinase activity of protein Bcr-Abl [139], and this dependence was first exploited by the development of the drug imatinib (Gleevec®) which inhibits the tyrosine kinase. In CML cases resistant to imatinib, broader spectrum tyrosine kinases such as dasatinib (Sprycel®), which blocks both Bcr-Abl and Src tyrosine kinases, may be used [140] (Table 3). Nilotinib is another protein tyrosine kinase inhibitor targeting Bcr-Abl. Inhibitors of receptor tyrosine kinases targeting epidermal growth factor receptor (EGFR; ErbB1; HER1; a member of the ErbB family of receptors), vascular endothelial growth factor receptors (VEGFRs) and platelet-derived growth factor receptors (PDGFRs) have also found use in the clinic as effective targeted anti-tumour drugs [96]. Some receptor tyrosine kinase inhibitors include gefitinib and erlotinib (both inhibitors of EGFR), lapatinib (inhibits ErbB1 and ErbB2), vatalanib (VEGFR-1 and VEGFR-2), sorafenib (VEGFR, PDGFR and c-Kit) and sunitinib (VEGFR, PDGFR and c-Kit). Other targeting strategies summarized in Table 3 that interfere with signal transduction and which have entered, or are about to enter the clinic, include the more recently introduced mTOR serine/threonine kinase inhibitors that target the Raptor complex [141] (drug examples include everolimus and temsirolimus), histone deacetylase (HDAC) inhibitors (e.g. romidepsin and vorinostat) that arrest the cell cycle [142], targeting the PML-RAR α oncoprotein (arsenic trioxide) [143] and drugs (e.g. bexarotene) binding to retinoid receptors [144]. Still other targeting strategies are represented by pralatrexate, a folate analogue that accumulates in cancer cells over-expressing protein RFC-1 [145] and the cytotoxic chimeric proteins denileukin diftitox [146] and ziv-aflibercept [147, 148] (Table 3). Finally, proteasome inhibitors such as bortezomib and carfilzomib work against the cells of multiple myeloma and mantle cell lymphomas in perhaps the most fascinating of all the current targeted mechanisms [149, 150]. These drugs inhibit proteasomes by binding to proteolytic catalytic sites in

the 20S proteasome core (Fig. 2). This is thought to prevent degradation of pro-apoptotic factors permitting killing of cancer cells.

4 Side effects of chemotherapeutic drugs

Adverse reactions to important examples from the main groups of non-targeted and molecularly targeted agents are numerous and often diverse, and with the large number of drugs currently employed in cancer therapy, the task of conveying a succinct, informative and accurate picture of adverse reactions at the level of both individual drugs and different categories of drugs with common features is a formidable one. From information obtained from the published medical/scientific literature, research studies and FDA and drug company data, Table 2 summarizes the most important systemic and cutaneous adverse reactions of the non-targeted anti-cancer drugs. With the exception of only one drug, lenalidomide which has multiple actions, the other drugs have been arranged in different categories based on common mechanisms of action. It has been claimed that the problem of hypersensitivity reactions to these chemotherapeutic drugs is often not reported by oncologists and therefore underestimated and that they can be divided into three groups with high, intermediate or low potential for causing hypersensitivity reactions [24]. Drugs included in the high group are platinum compounds, taxanes, epipodophyllotoxin topoisomerase II inhibitors, L-asparaginase and procarbazine. The anthracyclines (daunorubicin, doxorubicin and epirubicin), 6-mercaptopurine and methotrexate are in the intermediate division while cytarabine, cyclophosphamide and ifosfamide make up the low potential group. Antimetabolites such as capecitabine, gemcitabine and 5-fluorouracil commonly provoke acral erythema syndrome (Fig. 3) [153], and in common with cyclophosphamide and doxorubicin, hyperpigmentation may occur. Mitotic inhibitors, the taxanes and *Vinca* alkaloids, often produce alopecia and nail abnormalities and radiation recall reactions are seen (Table 2). With some drugs such as the PARP inhibitors that are still in clinical trials, little information is available yet on adverse, let alone hypersensitivity, reactions (Table 2).

The inclusion of reactions to 16 kinase inhibiting drugs demonstrates the current importance of tyrosine and serine/threonine kinase inhibitors for the targeted treatment of an expanding range of tumours (Table 3). While the aim of signal transduction therapy is to kill the cancer cells with minimal collateral damage (Fig. 1), even a quick glance at the catalogue of side effects in the table shows that, just as with the non-targeted drugs (but less so), cutaneous, gastrointestinal and haematopoietic cells are often still affected. Cytotoxic effects such as anaemia, thrombocytopenia and neutropenia occur less often and usually with less severity than with, say, antimetabolites and alkylating agents, but a number of the

Table 3 Classification of targeted chemotherapeutic drugs used for cancers and their hypersensitivity/adverse reactions

Drug generic and trade names and classification ¹ on the basis of mechanism	Cancer indications	Mechanism(s) ¹ of action	Hypersensitivity ² /adverse ³ reactions		References
			Systemic	Cutaneous	
Signal transduction inhibitors					
Non-receptor tyrosine kinase inhibitors					
Bosutinib (Bosulif®)	Ph+CML	Targets Abl and Src kinases inhibiting autophosphorylation of both	Anaphylaxis; thrombo; neutro; anaemia; oedema; hepatotox; pneumonia; pyrexia; cough; GI	Rash; pruritus	[78, 79]
Crizotinib (Xalkori®)	NSCL (Trials: ALCL; neuroblastoma; solid tumours)	Inhibits tyr kinase activity of fusion protein EML4-ALK	Pneumonitis; oedema; neuropathy; arthralgia; vision disorders; cough; dyspnea; QT prolongation; GI	Rash; pruritus; stomatitis	[80, 81]
Dasatinib (Sprycel®)	CML; Ph+ALL	Inhibits Ber-Abl, Src, c-Kit ⁴ , ephrin (EphA2) and other tyr kinases (PDGFRβ)	Abnormal platelets; neutro; anaemia; peripheral oedema; pleural effusion; psh; GI; CV; QT prolongation; dyspnea	Rash; pruritus; xerosis; alopecia; urticaria; nail disorders; pigm; panniculitis; dermatitis	[82, 83]
Imatinib (Gleevec®)	Ph+CML; Ph+ALL; GI; stromal; some CEL	Blocks Ber-Abl tyr kinase from phosphorylating	Thrombo; neutro; anaemia; oedema; hypersens pneum; hepatotox; tls; CV; GI	Rash; pruritus; angioedema; vasculitis; hyper-pigm; dress; agep; sjs; erythema multiforme	[84–86]
Nilotinib (Tasigna®)	CML	Inhibits Ber-Abl, c-Kit ⁴ , EphA3 ⁵ , EphA8 ⁵ , PDGFRβ and other tyr kinases	Thrombo; neutro; leuko; anaemia; oedema; hepatotox; GI; pneumonia; dyspnea; QT prolongation	Rash; pruritus; erythema; eczema; urticaria; alopecia; xerosis; ecchymosis	[87]
Ponatinib ⁶ (Iclusig®)	CML; Ph+ALL	Targets pan Ber-Abl	Thrombo; neutro; anaemia; leuko; thrombosis; hepatotox; CV; tls; pancreatitis; GI; arthralgia/myalgia	Rash; xerosis	[88]
Receptor tyrosine kinase inhibitors					
Erlotinib (Tarceva®)	NSCL; pancreatic	EGFR inhibitor—binds to ATP binding site of receptor interrupting signal cascade	ild; hepatotox; thrombo; anaemia; GI; renal disorders; ocular disorders	Rash; pruritus; ppr; xerosis; hyper-pigm; hfsr; digital fissures; alopecia; paronychia; eyelid/brow changes; bullous reactions	[89, 90]
Gefitinib (Iressa®)	NSCL; breast	EGFR inhibitor	GI; ild; renal/urinary disorders; haemorrhage	hfsr; ppr; pruritus; xerosis; nail disorders; and hair disorders; stomatitis	[90, 91]
Lapatinib (Tykerb®)	Breast; other solid tumours	Inhibits tyr kinase activity of HER2 and EGFR	Anaphylaxis; cardiac tox; hepatotox; ild; GI; QT prolongation	Rash; hfsr; pruritus; xerosis; nail disorders; paronychia; alopecia	[92]
Pazopanib (Votrient®)	RCC; STS; (ovarian; NSCL?)	Inhibits several tyr kinases incl VEGFRs, PDGFRs, FGFR2, c-Kit	Hepatotox; hypertension; GI; QT prolongation; haemorrhage; hypothyroidism; rpls	hfsr; hair/skin depigm; exfol rash; nail disorders; xerosis; stomatitis; alopecia; mucositis	[93]
Regorafenib (Stivarga®)	Colorectal; GIST	Inhibits multi kinases incl VEGFRs 2 and 3, PDGFR, c-Kit, RET, RAF ⁷ , TIE2 ⁸	Hepatotox; hypertension; haemorrhage; GI; dysphonia	hfsr; rash; xerosis; mucositis; desquamation; pruritus	[94, 95]
Sorafenib (Nexavar®)	RCC; HCC	Inhibits VEGFR2 and PDGFRβ signalling blocking tumour angiogenesis. Blocks RAF kinase involved in cell growth and proliferation	Haemorrhage; cardiac tox; hypertension; GI; flushing; thrombo; neutro; anaemia; leuko; lympho; rpls	hfsr ⁹ ; rash; desquamation; erythema; xerosis; pruritus; alopecia; ssh; facial acne; stomatitis; bullous eruptions	[96–99]
Sunitinib (Sutent®)	RCC; GIST; PNET	Inhibits VEGFR2, PDGFR3 and c-Kit, inhibiting angiogenesis and cell proliferation. Inhibits phosphorylation of FLT3 ¹⁰	Hepatotox; hypertension; CV; GI; QT prolongation; haemorrhage; thyroid dysfunction; fever; periph oedema; dyspnea; cough	hfsr ¹¹ ; yellow skin; rash; xerosis; hair depigm; alopecia; erythema; pruritus; stomatitis	[96, 98–100]
Vandetanib (Caprelsa®)	MTC	Inhibits cell receptor tyr kinases VEGFR, EGFR and RET	Hypertension; cardiac tox; QT prolongation; haemorrhage; ild; rpls; cough	Rash and acne (? ppr); xerosis; pruritus; dermatitis; hfsr; erythema; photosens; sjs	[101]

Table 3 (continued)

Drug generic and trade names and classification ¹ on the basis of mechanism	Cancer indications	Mechanism(s) ¹ of action	Hypersensitivity ² /adverse ³ reactions		References
			Systemic	Cutaneous	
mTOR serine/threonine kinase inhibitors					
Everolimus (Afinitor®)	RCC; breast; PNET; SEGA	Binds FK-binding protein FKBP12 and drug-protein complex inhibits mTOR. This blocks binding of regulatory-associated protein of mTOR causing dephosphorylation of S6K1 and apoptosis of cancer cells	Pneumonitis infections; ↓ platelets, neutrophils, Hb and lymphocytes; renal failure; oedema; oral ulcers; GI; fever; dyspnea	Acneiform rash (? ppr); erythema; stomatitis; nail disorders; xerosis	[102]
Temsirolimus (Torisel®)	RCC	Binds FK-binding protein FKBP12 and drug-protein complex inhibits mTOR. This blocks binding of regulatory-associated protein of mTOR causing dephosphorylation of S6K1 and apoptosis of cancer cells. Also inhibits tumour angiogenesis by reduced synthesis of VEGF	hir ¹² ; ild; renal failure; thrombo; leuko; anaemia; oedema; GI; bowel perforation; eye disorders ¹³	Rash (mpr; exfoliative dermatitis); nail disorders; pruritus; xerosis; acne (? ppr); stomatitis	[103]
Histone deacetylase inhibitors					
Romidepsin (Istodax®)	CTCL	Inhibits histone deacetylase altering gene expression and causing cell cycle arrest and apoptosis	Thrombo; neutro; lympho; anaemia; QT prolongation; GI; dysgeusia; pyrexia	Exfol dermatitis; itching; pale skin	[104]
Vorinostat (Zolinza®)	CTCL	Induces growth arrest, differentiation or apoptosis due to accumulation of acetylated proteins incl BCL6, p53 and Hsp90 ¹⁴	Thrombo; anaemia; pulm embolism; thrombosis; GI; dysgeusia	Exfol dermatitis; pruritus; alopecia	[105, 106]
Drugs that target the PML-RAR α oncoprotein					
Tretinoin (ATRA) (Vesanoid®)	APL	APL results from expression by NB4 cells of PML-RAR α oncoprotein which increases cell surface levels of plasminogen receptor S100A10 and fibrinolytic activity. ATRA down regulates S100A10 blocking fibrinolytic activity (and hence haemorrhage)	Retinoid acid syndrome (dyspnea, fever, periph oedema, weight gain); c/s; retinoid tox; respiratory and ear disorders	Erythema; xeroderma; photosens; itch; increased risk sunburn	[107]
Arsenic trioxide (Trisenox®)	APL	As ₂ O ₃ binds to oncogenic fusion protein PML-RAR α , induces increased interaction with a ubiquitin-like protein-modifier SUMO-conjugating enzyme UBC9, enhanced SUMOylation and degradation	Thrombo; neutro; hyperleukocytosis; anaemia; hypertension; vasculitis; differentiation syndrome; dyspnea; QT prolongation; GI	Rash; erythema; pruritus; facial oedema; ecchymosis	[108]
Drugs binding to retinoid receptors					
Bexarotene (Targretin®)	CTCL	Synthetic retinoid acid deriv. Binds and activates retinoid X receptors inducing changes in gene expression, decreased cell proliferation, apoptosis of some cancer cell types and tumour regression	Lipid abnormalities; pancreatitis; leuko; anaemia; periph oedema; GI; hypothyroidism; infection; chills; fever	ppr; mpr; acne; vesicular bullous rash; keratitis; conjunctivitis; corneal lesions; alopecia; skin nodules; photosens; xerosis	[109]
Proteasome inhibitors					
Bortezomib (Velcade®)	MM; MCL; NHL	Inhibits proteasomes by binding via its β atom to β -subunit chymotrypsin and caspase catalytic sites—may suppress degradation of pro-apoptotic factors allowing for killing of neoplastic cells	Periph neuropathy; GI; thrombo; neutro; leuko; anaemia; hypotension; cardiac disorders; ards; rpl/s; l/s; hepatic events; pyrexia; dyspnea; pneumonia	Rash ¹⁵ ; pruritus; erythema; urticaria; facial oedema; eczema; vasculitis; ten; Sweet s-like syndrome	[110–112]

Table 3 (continued)

Drug generic and trade names and classification ¹ on the basis of mechanism	Cancer indications	Mechanism(s) ¹ of action	Hypersensitivity ² /adverse ³ reactions		References
			Systemic	Cutaneous	
Carfilzomib (Kyprolis®)	MM	Binds to and inhibits chymotrypsin-like activity of the 20S proteasome	Cardiac disorders; pulm hypertension; dyspnea; infusion reactions; t/s; thrombo; anaemia; neutro; hepatotox; periph neuropathy	Rash; urticaria; itch ¹⁶	[113]
Hormones, hormone analogues and hormone antagonists					
Inhibitors of hormone synthesis					
Aromatase inhibitors					
Anastrozole (Arimidex®)	Breast	Binds reversibly to aromatase preventing conversion of androgens to oestrogens	Hot flushes; arthritis; arthralgia; dyspnea; osteoporosis; hypertension; GI	Rashes; pruritus; mpr; lupus erythematosis; erythema nodosum; cutaneous vasculitis; erythema multiforme; sjs	[114–117]
Exemestane (Aromasin®)	Breast	Irreversible aromatase inactivator. Permanently binds the enzyme preventing conversion of androgens to oestrogens	Anaphylaxis; hot flushes; arthralgia; dyspnea	Rash; urticaria; pruritus; cutaneous vasculitis; erythema multiforme; agep; alopecia; dermatitis	[117–119]
Letrozole (Femara®)	Breast	As for anastrozole	Anaphylaxis; flushing; dyspnea; diaphoresis; arthralgia; hypertension; periph oedema; GI	Angioedema; rash; erythema multiforme; ten; alopecia	[120]
Gnadorelin ¹⁷ -releasing hormone analogues (GnRH agonists)					
Goserelin (Zoladex®)	Prostate; breast	Synthetic analogue of GnRH. Binds to receptors for GnRH leading to initial increase in Gn and then receptor down-regulation and reduction in hormone levels	Anaphylaxis; hot flushes; didf; anaemia; osteoporosis; vaginitis	Rash; itching; ipes; acne; seborrhea; alopecia	[121]
Leuprorelin (Lupron®)	Prostate; breast	As for goserelin	Anaphylaxis; hot flushes; didf; thrombo; anaemia; leuko; periph oedema	Rash; injection site granuloma; pruritus; xerosis; ecchymosis; photosens; pigm	[122, 123]
Hormone receptor antagonists					
Selective oestrogen receptor modulators (SERMS)					
Tamoxifen ¹⁸ (Nolvadex®), Valodex®, Istubal®)	Breast (oestrogen receptor-positive) and post-menopausal women	Competitive antagonist of oestrogen receptor, inhibiting breast cancer cells requiring oestrogen to grow; anti-angiogenic effect	Hot flushes; vaginal discharge; endometriosis; reduced vision; thrombosis; interstit pneumonitis	Pruritus vulvae; urticaria; angioedema; vasculitis ¹⁹ ; erythema multiforme; bullous pemphigoid; sjs	[124, 125]
Androgen blockade (anti-androgens)					
Bicalutamide (Casodex®)	Prostate; being assessed for ovarian and metastatic breast	Binds to androgen receptor preventing its activation and accelerates degradation of the receptor	Hot flushes; thrombo; interstit pneumonitis; gynecomastia	Urticaria; angioedema; pruritus; alopecia	[126]
Hormone supplementation					
Androgens, oestrogens, progestogens, somatostatin (see text)					
Targeted anti-folate drug					
Pralatrexate (Foloty®)	PTCL	Folate analogue antimetabolite accumulates in cancer cells which overexpress the protein RFC-1 and interferes with DNA synthesis and leading to cell death	Thrombo; febrile neutro; anaemia; mucositis; pyrexia; dyspnea; foetal harm; t/s	Rash; pruritus; exfoliation; ulceration; ten	[127]

Table 3 (continued)

Drug generic and trade names and classification ¹ on the basis of mechanism	Cancer indications	Mechanism(s) ¹ of action	Hypersensitivity ² /adverse ³ reactions		References
			Systemic	Cutaneous	
Targeted cytotoxic chimeric proteins					
Denileukin difitox (Ontak®)	CTCL	Modified diphtheria toxin and IL-2 receptor fused to give recombinant toxin. Toxin released intracellularly causes ADP-ribosyltransferase-mediated inhibition of protein synthesis and cell death	Infusion reactions; pyrexia; els; vision disturbances; periph oedema; dyspnea; cough; GI	Pruritus; ten	[128–130]
Ziv-Aflibercept (Zaltrap®)	MCRC	Fusion protein of Fc portion of IgG ₁ and ligand-binding domains of VEGFR1 and VEGFR2. Acts as a soluble decoy VEGF receptor and angiogenesis inhibitor	leuko; neutro; thrombo; haemorrhage; GI perforation; proteinuria; hypertension; venous thromboembolism	Acral erythema; skin hyper pigm; stomatitis; compromised wound healing	[131]

agep acute generalized exanthematous pustulosis, *ALCL* anaplastic large cell lymphoma, *ALK* anaplastic lymphoma kinase—an activity that contributes to carcinogenesis and appears to drive the malignant phenotype, *APL* acute myelocytic leukemia, *ards* acute (adult) respiratory distress syndrome, *ATRA* all transretinoic acid, *CEL* chronic eosinophilic leukemia, *cls* capillary leak syndrome, *CTCL* cutaneous T cell lymphoma, *CV* cardiovascular disorders, *didf* drug-induced disease flare (tumour flare effect), *dress* drug reaction (rash) with eosinophilia and systemic symptoms, *EGFR* epidermal growth factor receptor, *EMLA-ALK* echinoderm microtubule-associated protein-like 4, *FGFR2* fibroblast growth factor receptor 2, *G1* gastrointestinal adverse events, *GIST* gastrointestinal stromal tumour, *HCC* hepatocellular carcinoma, *hepatotox* hepatotoxicity, *HER2* human epidermal growth factor receptor 2 (also known as Neu, Erb-2, CD340, p185), *h/sr* hand-foot skin reaction, *hir* hypersensitivity infusion reaction, *Hsp90* heat shock protein 90, *ild* interstitial lung disease, *leuko* leukopenia, *lympho* lymphopenia, *MCL* mantle cell lymphoma, *MCR* metastatic colorectal cancer, *MM* multiple myeloma, *mpr* maculopapular rash, *MTC* medullary thyroid cancer, *neutro* neutrocytopenia, *p53* tumour protein 53, *pah* pulmonary arterial hypertension, *PDGFR* platelet-derived growth factor receptor, *Ph+* Philadelphia chromosome-positive, *pigm* pigmentation changes, *PML-RAR α* promyelocytic leukemia retinoic acid receptor α oncogene fusion protein, *PNET* pancreatic neuroendocrine tumour, *pneum* pneumonitis, *PTCL* peripheral T cell lymphoma, *ppr* papulopustular rash, *RCC* renal cell carcinoma, *RET* (rearranged during transfection) proto-oncogene on chromosome 10, *RFC-1* reduced folate carrier type 1, *rpcs* relapsing polycondritis cutaneous symptoms, *rpls* reversible posterior leukoencephalopathy syndrome, *SEGA* subependymal giant cell astrocytoma, *sjs* Stevens–Johnson syndrome, *ssh* subungual splinter haemorrhage, *STS* soft tissue sarcoma, *ten* toxic epidermal necrosis, *thrombo* thrombocytopenia, *ts* tumour lysis syndrome, *VEGFR* vascular endothelial growth factor receptor

¹ Some drugs exert their action(s) by more than one mechanism and might therefore be classified into more than one category. The classification shown is deemed to be the most appropriate one

² Reactions known, or suspected, of having an immunological basis

³ Reactions such as weakness, fatigue, headache etc. and GI symptoms like nausea, vomiting, diarrhoea, constipation, appetite reduction, dyspepsia etc. are not recorded here since they are common to so many of the drugs. Where such reactions are important, they are referred to collectively as ‘GI’

⁴ Proto-oncogene c-Kit, mast/stem cell growth factor receptor. Also called tyrosine-protein kinase kit or CD117

⁵ Belongs to ephrin receptor family of tyrosine kinases

⁶ Ponatinib used to treat refractory CML including patients with T3151 ‘gatekeeper’ mutation

⁷ The enzyme RAF proto-oncogene ser/threo-protein kinase (also called c-Raf or Raf-1). Functions in MAPK/ERK signal transduction pathway

⁸ TIE2, angiopoietin receptor that binds angiopoietin growth factor required for angiogenesis

⁹ Thirty to 60 % of patients

¹⁰ FLT3, CD135; Fms-like tyrosine kinase; receptor-type tyrosine protein kinase FLT3

¹¹ Fifteen to 20 % of patients

¹² May occur on first and subsequent infusions. Reactions include flushing, chest pain, dyspnea, hypotension, apnoea and anaphylaxis. Allergic/hypersensitivity reactions occur in ~9 % of patients (FDA)

¹³ Seven percent of patients

¹⁴ BCL6 protein—zinc finger transcription factor, a sequence-specific repressor of transcription. p53 is a tumour suppressor protein that regulates the cell cycle. Hsp90 is a molecular chaperone assisting protein folding and stabilizes some proteins in tumour growth

¹⁵ Incidence 8–18 %

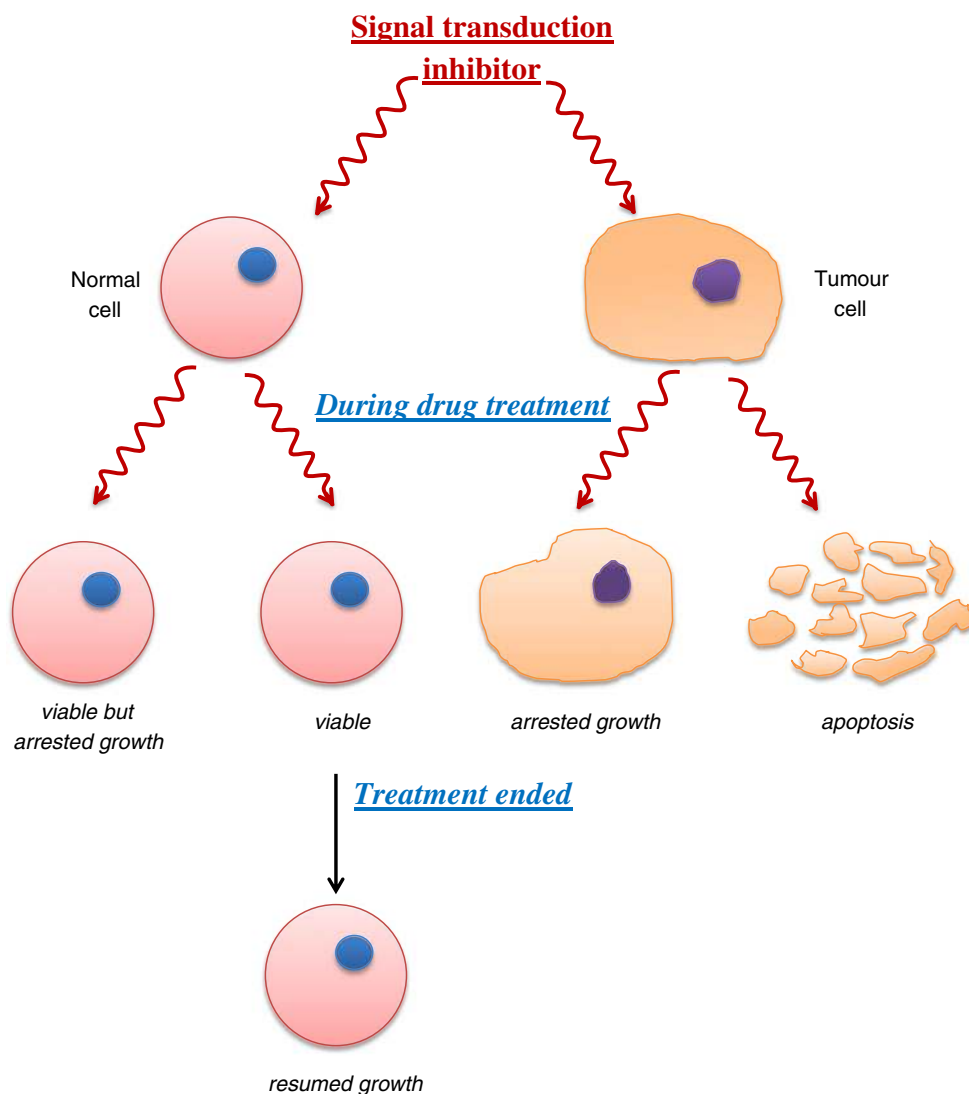
¹⁶ Skin and subcutaneous tissue adverse events in phase 2 trial on 526 patients with MM=36 %. Discontinuations due to these adverse events=1 %

¹⁷ Also called luteinizing hormone

¹⁸ In 2006, NCI stated that raloxifene was as effective as tamoxifen in reducing the incidence of breast cancer in post-menopausal women at increased risk

¹⁹ Nineteen percent of treated patients experience skin reactions

Fig. 1 Diagrammatic representation of the aim of signal transduction therapy. Interference with signalling arrests growth of tumour cells irreversibly and promotes apoptosis of many cells. Growth of some normal cells may be arrested, but many retain viability and resume growth once treatment is stopped



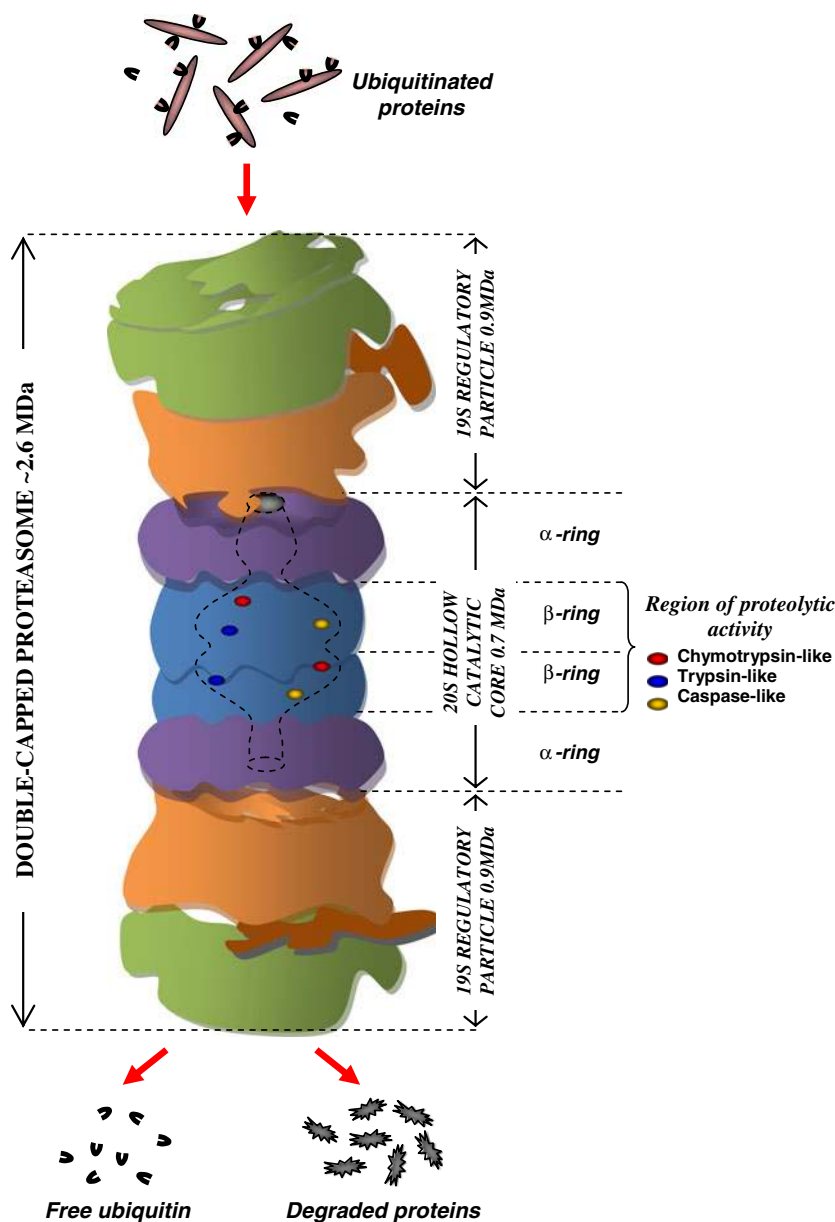
targeted agents show their own fairly unusual effects including, for example, a lengthened QT interval, a hand–foot skin reaction (Fig. 4) ([151]; see later) significantly different from the well-known drug-induced acral erythema (compare Figs. 3 and 4) and a characteristic papulopustular rash (Fig. 5) [154]. Inhibition of the EGFR in skin often produces xerosis, skin fissures, nail alterations, paronychia and periungual ulcers. Multikinase inhibitors like sorafenib [151] and sunitinib frequently exhibit skin toxicity and produce fever, oedema and occasionally inflammatory actinic keratosis and bullous manifestations (Table 3).

5 Hypersensitivity reactions of chemotherapeutic drugs

Amongst anti-neoplastic drugs, methotrexate and oxaliplatin, for example, can provoke types I, II and III hypersensitivities. Some drugs and what at first sight appear to be ‘allergic’ drug reactions do not fit easily into the four Gell and Coombs

categories. As mentioned, some reactions to contrast media and NSAIDs are two examples [8, 9] that readily spring to mind as well as skin reactions such as alopecia, folliculitis and hyperpigmentation. The situation where the mechanism of a drug-induced adverse response remains un-investigated or poorly understood is often seen in reactions to chemotherapy drugs where the haematological system, liver, lungs and skin are frequently affected (Tables 2 and 3). It has been said that so-called idiosyncratic drug reactions most often manifest as cutaneous reactions, haemato- and hepato-toxicities and less frequently as anaphylaxis and autoimmunity, but some investigators believe that most idiosyncratic reactions are hypersensitivities occurring via an immune-mediated response [156]. Cytotoxic chemotherapy typically suppresses haematopoiesis causing thrombocytopenia, neutropenia and anaemia, and drug-induced hepatotoxicity is a well-known cause of liver injury. However, all four conditions can be instigated by drugs via an immune mechanism, and this possible difference in the underlying mechanisms of these most

Fig. 2 Diagrammatic representation of the proteasome and its role in protein degradation via the ubiquitin–proteasome pathway. Proteins tagged with ubiquitin and unfolded for degradation on the 19S regulatory particles are degraded into small peptide fragments in the 20S catalytic core, a region of $\beta 1$ caspase-, $\beta 2$ trypsin- and $\beta 5$ chymotrypsin-like activities. Ubiquitin molecules are liberated and recycled



serious drug side effects frequently remains unexplored. In fact, autoimmune forms of haemolytic anaemia and thrombocytopenia are well-known complications of lymphoproliferative diseases and occur predominantly in patients with lymphocytic leukemias [157]. Specific aspects, including the special relevance and significance of chemotherapy drug-induced thrombocytopenia, neutopenia (and agranulocytosis), anaemia, liver injury, lung disease and cutaneous reactions, are considered below.

5.1 Type I hypersensitivity reactions to chemotherapeutic drugs

Type I, IgE antibody-mediated hypersensitivity, also known as immediate, or sometimes anaphylactic hypersensitivity, can

affect a single organ such as the nasopharynx (allergic rhinitis), eyes (conjunctivitis), mucosa of mouth/throat/tongue (angioedema), bronchopulmonary tissue (asthma), gastrointestinal tract (gastroenteritis) and skin (urticaria, eczema), or multiple organs (anaphylaxis), causing symptoms ranging from minor itching and inflammation to death. Symptoms of a drug-induced pseudo-allergic or anaphylactoid reaction resulting from the direct release of histamine and producing flushing, rash, pruritus, urticaria, hypotension and mucous secretion can sometimes make it difficult to distinguish these symptoms from a true, IgE-mediated type I hypersensitivity reaction. To do this, investigations designed to look for an immune basis of the reactions are necessary. Symptoms of drug-induced anaphylaxis generally include cardiovascular collapse, bronchospasm, urticaria, angioedema, erythema,

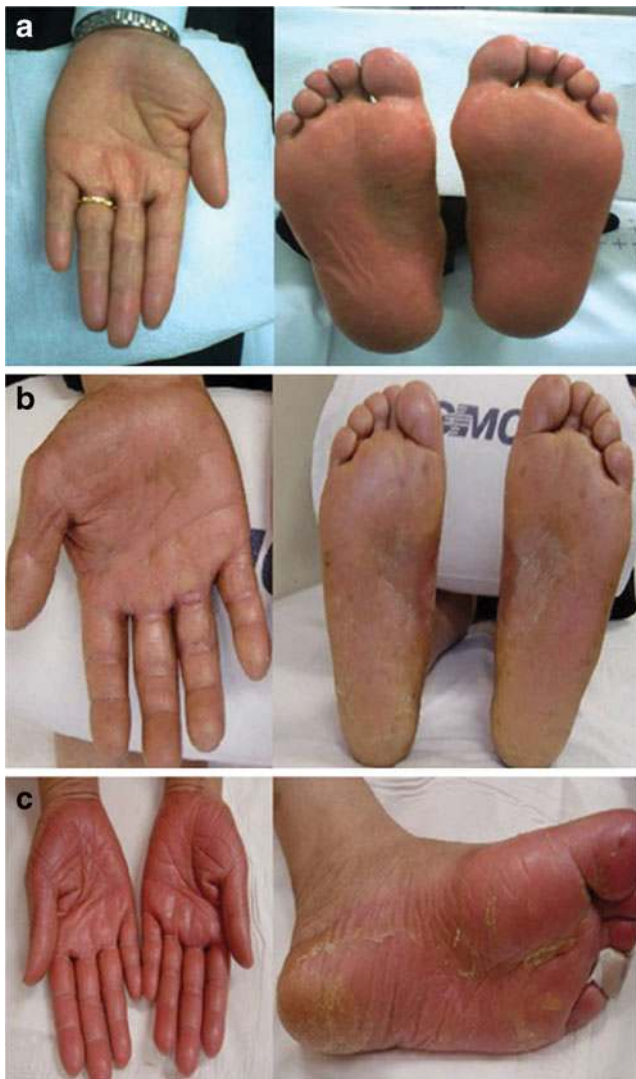

Fig. 3 Acral erythema (palmar–plantar erythrodysesthesia; hand–foot syndrome) may manifest as erythema, swelling and desquamation of the palms and soles following treatment with cytotoxic drugs such as capecitabine. Note that acral erythema is a distinct entity from hand–foot skin reaction seen following treatments with some targeted tyrosine kinase inhibitors such as lapatinib, regorafenib, sorafenib (see Fig. 4) and sunitinib [151, 152]. Examples of hand–foot syndrome scored as a severity grade 1. **b** Grade 2 or moderate severity with characteristic erythema. **c** Grade 3 severity associated with desquamation, pain and debilitating effects on the patient (reproduced from Son et al. [153], an Open Access article distributed under the terms of the Creative Commons Attribution License)

gastrointestinal symptoms (abdominal pain, vomiting, diarrhoea, haematemesis, melena) and pulmonary oedema [158, 159]. Symptoms are generally more severe in anaphylactic than in anaphylactoid reactions with cardiovascular collapse and bronchospasm occurring more frequently in the former and cutaneous manifestations seen more often in the latter [160–162]. In fact, the appearance of bronchospasm indicates that a drug reaction is more likely to be anaphylactic than anaphylactoid [163].

It is uncommon to find a drug, even those used with only moderate frequency, that has not provoked anaphylaxis, urticaria and/or angioedema in at least one rare individual so it is not surprising to see type I hypersensitivity responses well represented in the lists of adverse reactions to the many chemotherapeutic drugs. Such reactions remain rare but are seen more often with the platinum agents, L-asparaginase and methotrexate. Although there has been no clear and unequivocal demonstration of the existence of IgE antibodies to the platinum drugs, sensitizations only after multiple infusions, positive skin tests and anaphylactic-like reactions are all taken as evidence in support of a type I hypersensitivity mechanism with these agents [24]. This conclusion is supported by positive oxaliplatin [164, 165] and carboplatin [166] skin tests that show a sensitivity of 75 to 100 %. L-Asparaginase seems to be the drug with the highest risk of provoking a type I response with an allergic reaction occurring in up to 43 % and serious anaphylaxis in a little less than 10 % of treated patients. One study employing skin and Prausnitz–Küstner tests indicated an IgE-mediated mechanism in five anaphylactic patients [167], whereas anaphylaxis to L-asparaginase in seven of eight cases was concluded to be due to complement activation induced by immune complexes of the drug with IgG and IgM antibodies [168]. Reactions are also well-known to procarbazine; the alkylating agents cyclophosphamide, melphalan, mechlorethamine, dacarbazine, temozolomide and thioTEPA; antimetabolites cytarabine and 5-fluorouracil; the *Vinca* alkaloid mitotic inhibitors; topoisomerase inhibitors irinotecan, daunorubicin, doxorubicin and mitoxantrone; aromatase inhibitors exemestane and letrozole; some hormones and hormone analogues and antagonists goserelin, leuprolide and tamoxifen; and targeted drugs such as the tyrosine kinase inhibitor bosutinib and mTOR inhibitor everolimus [18, 19, 21, 24]. Although some reactions that resemble type I reactions are dismissed as not true immediate, IgE-mediated responses because they occurred on first exposure, it should be remembered that many such drug reactions do occur on first exposure, for example, to neuromuscular blockers, contrast media, proton pump inhibitors, quinolones and others [169, 170]. Examples of some anti-cancer drugs that may provoke anaphylactoid reactions include 5-fluorouracil and the topoisomerase II inhibitors teniposide and etoposide which induce erythema, chills, fever, tachycardia, hypotension and urticaria/angioedema in up to 10 % of patients often during the first infusion

5.2 Type II reactions

Anti-neoplastic drugs may cause a number of type II antibody-mediated cytotoxic hypersensitivity reactions, but such reactions are often not referred to by this title in the oncology and some other medical specialty literatures.

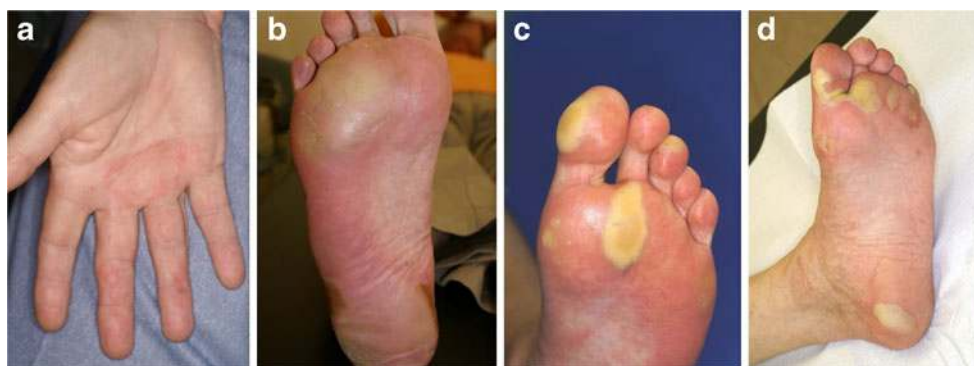

Fig. 4 Hand-foot skin reaction caused by the multikinase inhibitor sorafenib (compare with Fig. 3). Hyperkeratosis, manifesting as painful yellowish plaques on pressure areas of the soles (**b–d**) and a defining feature of the condition, usually develops after formation of blisters. The

reaction appears to be dose-dependent. The photographs show increasing degrees of severity from grade I (**a**) to grade II (**b**) and grade III (**c** and **d**) (reproduced with permission from Degen et al. [151])

5.2.1 Drug-induced thrombocytopenia

In adults, a normal platelet count is $\sim 150\text{--}400 \times 10^3/\mu\text{l}$, and if this drops to $\sim 50 \times 10^3/\mu\text{l}$, most patients experience thrombocytopenia. For patients with drug-induced thrombocytopenia (DIT), the condition is invariably severe at counts around $20 \times 10^3/\mu\text{l}$. Many anti-neoplastic drugs such as alkylating agents, mitotic inhibitors and anti-metabolites cause a dose-dependent bone marrow suppression of platelets and all of the other haematopoietic cell lines. Some haematopoietic cells, including platelets, can be affected by drug-induced type II hypersensitivity reactions. Immune-mediated, drug-dependent destruction of platelets may occur via a number of different mechanisms, including production of a new antigen after covalent binding of drug to platelet membrane glycoprotein, binding of drug to the platelet GPIIb/IIIa complex inducing a conformational change and a new antigenic determinant, non-covalent binding to platelet membrane glycoprotein forming a drug-glycoprotein complex that reacts with antibody, binding of the Fab fragment of the chimeric human-mouse monoclonal antibody abciximab to the platelet glycoprotein receptor GPIIb/IIIa followed by subsequent recognition by antibody, production of drug-induced autoantibody that reacts with the platelet surface glycoprotein and, lastly, reaction of heparins with platelet factor 4 producing an antibody-reactive antigen, immune complexes bound to the platelet Fc receptor and platelet activation [171, 172].

Data from 2000 to 2007 on 75,243 chemotherapy regimens of associated anaemia and thrombocytopenia contained in medical records of 47,159 US patients [173] with lung, breast, ovarian, head and neck or colorectal cancers treated with platinum-, anthracycline-, gemcitabine- or taxane-based regimens were assessed in an effort to determine the prevalence of thrombocytopenia in patients undergoing chemotherapy for solid tumours. The prevalence of thrombocytopenia ranged from 21.9 % in patients treated with taxane-based regimens to 64.2 % in the gemcitabine-based treatment groups. During the

same time, from 46.4 to 59 % of the patients developed anaemia. In a similar retrospective hospital-based cohort study from the Netherlands on the frequency and relative risk of chemotherapy-induced thrombocytopenia in 614 patients receiving one of 37 different regimens, the overall frequency of thrombocytopenia was 21.8 % [174]. The highest frequencies were seen in patients receiving carboplatin (81.8 %) and combination therapies that included carboplatin (58.2 %), gemcitabine (64.4 %) or paclitaxel (59.3 %). The overall incidence of thrombocytopenia without other cytopenias was 6.2 % although this was higher for combination therapies that included oxaliplatin (28.6 %) or gemcitabine (28.9 %). The highest relative risks of thrombocytopenia were for combination therapies of carboplatin/gemcitabine and carboplatin/paclitaxel/etoposide. These findings demonstrate that chemotherapy-induced thrombocytopenia is an important problem in clinical practice and that further research is needed to increase understanding of its clinical consequences. Importantly, some of the findings show that a number of chemotherapeutic drugs cause immune-mediated thrombocytopenia.

Based on mechanisms, there are two main categories of DIT: drug-induced marrow suppression and platelet removal by immune processes. Immune DIT generally tends to precipitate a more severe reaction than the non-immune form induced by myelosuppressive drugs, and while thrombocytopenia caused by the latter agents is often anticipated, not surprising, and even expected with some of the drugs, there will be occasions when there is a need to distinguish the two different forms. The time course of each is generally different, and this is a valuable diagnostic distinction. Non-immune marrow suppression is usually slow, often developing over weeks whereas the time for immune DIT is of the order of 1 to 2 weeks although the delay for a few patients may be only a few hours [171, 172]. Besides the mAbs rituximab and trastuzumab [175] used for cancer therapy, numerous cases involving oxaliplatin ([58, 176] and references therein), fludarabine [177], irinotecan [65], actinomycin D [178],

cyclophosphamide [179], pentostatin [44] and suramin [180] have already been shown to induce immune thrombocytopenia. Evan's syndrome (acute thrombocytopenia with haemolysis) to oxaliplatin has also been described [181, 182]. Early onset following previous drug exposure and the detection of antibodies and complement on erythrocytes indicated a type II hypersensitivity reaction [182].

An interesting new mechanism involving splenic sequestration of platelets during oxaliplatin-induced liver damage has recently been identified in some cases of oxaliplatin-related thrombocytopenia [183]. The capacities of the older anti-neoplastic drugs to induce dose-dependent thrombocytopenia are generally well-known—those that do not lead to platelet reduction or do so only weakly include L-asparaginase, bleomycin, cisplatin, flutamide, goserelin, luproside, megestrol, streptozocin, tamoxifen and vincristine; drugs causing moderate thrombocytopenia include actinomycin D, cyclophosphamide, 5-fluorouracil, 6-mercaptopurine, methotrexate and procarbazine and drugs that induce the condition in severe form include busulfan, chlorambucil, cytosine arabinoside, melphalan, nitrogen mustard, nitrosourea compounds and vinblastine. The propensities and relative potencies of many of the more recently introduced anti-neoplastic drugs (especially many used in targeted therapies such as signal transduction and proteasome inhibitors) to cause both non-immune and immune thrombocytopenia do not appear to have been widely studied as yet, and little comparative data are available. Clearly this is important information to know since while dose-dependent non-immune thrombocytopenia can often be controlled or avoided by a reduction in dose, drugs causing immune-mediated thrombocytopenia must be avoided.

5.2.2 Chemotherapy-induced neutropenia

Drug-induced neutropenia (DIN) is probably the most frequent cause of neutropenia. Neutropenia is the most common adverse response induced by anti-cancer drugs, and neutropenia with fever is a major dose-limiting effect [184] of many of these drugs. Febrile neutropenia is generally defined as a rise in axillary temperature to more than 38.5 °C for more than 1 h with a neutrophil count of $<0.5 \times 10^9/l$. The lower limit of the absolute neutrophil count is generally taken as $1.5\text{--}1.8 \times 10^9/l$ (1,500–1,800/ μ l). Mild, moderate and severe neutropenia are said to be present when the absolute neutrophil counts are 1,000–1,500, 500–1,000 and less than 500 cells/ μ l, respectively. Although the term granulocytopenia is often used synonymously with neutropenia, the term applies to blood granulocytes, namely neutrophils, eosinophils and basophils. Strictly therefore, agranulocytosis should refer to depletion of the granulocytes, but when used in relation to neutrophils, it generally refers to the virtual absence of neutrophils (<100 cells/ μ l) in the peripheral blood. The pathogenesis of

DIN is poorly understood [185, 186]. Two main types of DIN are recognized: One is a dose-related, non-selective toxicity interfering with cell replication caused by, for example, anti-thyroid drugs, chloramphenicol, clozapine and cytotoxic anti-neoplastic drugs; the other is not dose-related, more often seen in women, older and allergic patients and is thought to be immunologic in origin being mediated by drug-dependent or drug-independent antibodies [187]. All patients undergoing cancer chemotherapy are at risk of neutropenic complications, but those with haematologic malignancies are at greater risk because of the particular disease processes and the usual intensity of the required treatments. The chemotherapy regimen is important in relation to the risk of neutropenia. Chemotherapy drugs well-known for their association with neutropenia include busulfan, carboplatin, *cis*-diamminedichloroplatinum, cisplatin, cyclophosphamide, doxorubicin, etoposide, melphalan, methotrexate, paclitaxel and vinorelbine. Combined treatment with cyclophosphamide, 5-fluorouracil and methotrexate is less toxic than cyclophosphamide and doxorubicin or combined cyclophosphamide, 5-fluorouracil and doxorubicin [188]. The risk of chemotherapy-induced neutropenia is also related to the phase of therapy with the highest risk usually associated with the earliest cycles. For example, in patients with advanced breast cancer treated with docetaxel and doxorubicin, approximately 75 % of episodes of febrile neutropenia occurred during the first cycle of therapy [188]. Concurrent with the risk of neutropenia is the susceptibility to bacterial and fungal infections that cause substantial morbidity and mortality. Such infections are commonly seen in the oral cavity and on mucous membranes presenting as pharyngitis, oral ulcers and periodontitis, sometimes together with stomatitis and mucositis. Infections of the gastrointestinal tract, lungs, blood stream and especially the skin also occur. Again, detailed information on mechanisms underlying many cases of anti-neoplastic DIN, especially for the targeted drugs, is currently lacking, but as these therapies continue to be used, this information is likely to be accumulated slowly. The distinct possibility remains that some chemotherapy-induced haematotoxicities (especially for the newer targeted drugs used to treat haematological malignancies) are in fact immune-mediated drug reactions.

5.2.3 Drug-induced haemolytic anaemia

The well-known immune cytotoxic reaction to penicillin resulting from binding of the drug to red cells, reaction of IgM and IgG antibodies with the drug–cell membrane protein complex and activation of the classical complement pathway causing cell lysis and death is the prototype drug-induced type II hypersensitivity. Another example of a type II cytotoxic antibody-mediated drug reaction, commonly seen with some cephalosporins, is drug-induced immune haemolytic anaemia (DIIHA) where the drug appears to form an antigenic complex

with the red cell surface [189]. In the analysis of 75,243 chemotherapy regimens of associated anaemia and thrombocytopenia mentioned above, from 46.4 to 59 % of treated patients developed anaemia [173]. DIIHA can also be associated with red cell autoantibodies without the drug participating in the antigen–antibody reaction. The anti-neoplastic drug fludarabine is an example of such a drug [43, 190, 191], and other purine analogues, cladribine [41, 192] and pentostatin [46], have also caused DIIHA. The closely related platinum drugs cisplatin, carboplatin and oxaliplatin are known to cause immune-mediated haemolysis with or without associated immune thrombocytopenia [193–196]. It is not fully understood why some drugs sometimes induce antibodies to red cells or what mechanism(s) is involved [189]. A possible immune basis for any anti-neoplastic drug that induces anaemia should always be kept in mind. The autoimmune disease bullous pemphigoid [197], classified as a type II hypersensitivity, can be caused by a number of drugs including the selective oestrogen receptor modulator (SERM) tamoxifen.

5.3 Type III reactions

These hypersensitivity reactions to chemotherapeutic drugs involving immune complex formation occur less often than type I, II or IV reactions, but it seems they also go unrecognised more often.

5.3.1 Drug-induced vasculitis

Drug-induced vasculitis (DIV) usually occurs in the skin and sometimes in subcutaneous tissue, kidneys and the lungs. The most common clinical symptoms at onset include skin rash, arthralgia and myalgia. For anti-neoplastic drugs, small vessel vasculitis is the most frequently seen form of a type III reaction. Cutaneous vasculitis (CV) is a small vessel systemic vasculitis manifesting as palpable purpura and ranging in severity from being benign and self-limiting to life-threatening with multiple organ failure. CV seen in malignancy may be drug- or infection-induced or paraneoplastic in origin. Approximately 60 % of patients with DIV present as CV [198]. Mechanisms underlying DIV are still incompletely understood, but cellular as well as humoral immune processes appear to be involved. A proportion of small-vessel vasculitis patients have anti-neutrophil cytoplasmic antibodies (ANCA) which are used as a diagnostic marker. In ANCA-positive DIV patients where neutrophil damage may occur, antibodies to myeloperoxidase, cathepsin G, human leukocyte elastase and lactoferrin may be found [199]. These antibodies can be indicative of severe disease. Because of the presence of the many different autoantibodies and low complement C4 levels, DIV may be confused with lupus [200]. Chemotherapy drugs implicated in CV include aromatase inhibitors (e.g. anastrozole) [115], SERMs such as tamoxifen [200, 201],

EGFR inhibitors including erlotinib which has been involved in at least 14 cases [202] and cyclophosphamide [203].

Paraneoplastic vasculitis, an inflammatory reaction of the vessels induced by malignant cells [204], represents about 5 % of cases of CV. Ninety percent of cases occur in haematological malignancies. The reactions appear to be the result of paraproteinemia (usually cryoglobulins), but the pathogenesis is unclear. One suggestion is that immune complexes form with tumour antigens leading to release of lymphokines and other vasoactive substances that damage vascular endothelium [205].

5.3.2 Other drug-induced type III reactions

Oxaliplatin has been associated with type III immune complex-mediated urticaria, joint pain and proteinuria [206] and idiosyncratic reactions including pulmonary fibrosis and cytokine release syndrome where it is speculated that it may act as a superantigen [207]. A reaction consisting of fever, myalgia, bone pain, conjunctivitis, chest pain and maculopapular rash induced by cytarabine in patients with NHL or ALL and termed cytarabine syndrome [208] has been suggested to be a type III hypersensitivity response on the basis of the detection of immune complexes and successful treatment with corticosteroids. Procarbazine has been said to induce a type III reaction with immune complex deposition ‘manifesting as a toxic epidermal necrolysis’ [209], a reaction normally considered to be a type IV response. A possible type III hypersensitivity reaction was also the tentative conclusion in each case from studies of procarbazine-induced interstitial pneumonia with eosinophilia improved by corticosteroid administration, viz. patients with diffuse pulmonary infiltrates, alveolar damage and eosinophilia after receiving gemcitabine; haemolytic anaemia and a Henoch–Schonlein-type purpura each associated with immune complexes following mitomycin C administration; and pneumonitis with features of a type III response provoked by methotrexate [21]. A further discussion of possible lung hypersensitivities to chemotherapeutic drugs is set out below under drug-induced lung disease (DILD). An unusual example of a possible type III hypersensitivity reaction to a chemotherapeutic drug was demonstrated by bronchial challenge testing an asthmatic nurse occupationally exposed to mitoxantrone in an oncology ward. The patient responded to the drug with a biphasic reaction and an increase in eosinophils, neutrophils and lymphocytes 6 to 18 h post-challenge [21].

5.4 Type IV reactions

Less often seen cutaneous reactions to chemotherapeutic drugs include maculopapular exanthemas, allergic contact dermatitis, psoriasis, acute generalized exanthematous pustulosis (AGEP), drug reaction (rash) with eosinophilia and systemic

symptoms (DRESS; also termed drug-induced hypersensitivity syndrome), fixed drug eruptions, erythema multiforme, Stevens–Johnson syndrome (SJS) and toxic epidermal necrolysis (TEN). These are now generally considered to be immune-based, delayed type IV hypersensitivities mediated by antigen-specific effector T cells. Type IV reactions generally begin from about 7 to 21 days after contact with the drug, and subsequent reactions may appear only 1 or 2 days after re-exposure. Identification and specificity of the culprit drug is established by oral challenge, patch and intradermal tests (IDT) read after a delay of at least 48 h [170]. Investigations are proceeding to relate different T cell subsets and cytokine and chemokine profiles with different skin reactions although cytokine overlap occurs [210]. There are many more examples of type IV cutaneous reactions to non-targeted than to targeted anti-neoplastic drugs although this might reflect, at least in part, the more recent introduction and so far smaller number of recipients of the latter drugs. The main drugs involved in eliciting delayed skin reactions include alkylating agents, particularly the nitrogen mustards; some anti-metabolites, e.g. cytarabine, gemcitabine, some purines; the folate antagonist methotrexate and the taxanes. Tamoxifen, used for many years, has been implicated in erythema multiforme and SJS. Other targeted drugs so far implicated in the induction of type IV skin reactions include imatinib and vandetanib in SJS, bortezomib, imatinib, letrozole and pralatrexate in TEN, exemestane, imatinib and letrozole in erythema multiforme, exemestane and imatinib in AGEP, imatinib in DRESS and bexarotene, erlotinib and sorafenib in reactions defined as ‘bullous’ eruptions (Table 3).

5.5 Other drug-induced reactions showing some evidence of hypersensitivity responses

Some adverse reactions provoked by chemotherapeutic drugs, for example, in the skin, liver, vasculature and lungs, show features of antibody and/or cellular involvement that suggest a possible contribution of type II, III and/or IV hypersensitivity mechanisms but, for a number of reasons, clear and definitive indications to establish such classifications one way or the other are often lacking. In addition to the lack of research so far, at least part of the problem in defining some of these adverse reactions is due to the lack of a generally accepted definition of hypersensitivity, the frequent absence of tests to identify or discount allergic recognition and the often vague classifications of reactions without any apparent consideration of the possible involvement of types II, III and IV hypersensitivity responses. These factors are discussed further below. Some of the more important drug-induced reactions that show at least some features of true hypersensitivity reactions but which are not routinely included in the Gell and Coombs classification of hypersensitivities will now be considered from both immune and allergological perspectives.

5.5.1 Some drug-induced cutaneous reactions

As already discussed, cutaneous reactions to anti-neoplastic drugs are common and may range from mild rashes and urticaria to severe type IV cell-mediated toxidermias such as erythema multiforme, SJS and TEN. Examples of antibody-mediated cutaneous reactions are seen in drug-induced cutaneous vasculitis, a type III hypersensitivity reaction, and some cases of urticaria are true type I IgE antibody-mediated hypersensitivities. Other cutaneous reactions where a hypersensitivity mechanism is less obvious include site-specific toxicities involving the hair, nails, mouth, hands and feet all of which are commonly seen. While the aim of chemotherapy is to kill rapidly growing cancer cells, normal rapidly growing cells in the skin, nails and hair follicles are also inhibited. It is not surprising therefore that adverse reactions such as alopecia, simple macular rash, xerosis cutis, pruritus, hand–foot skin reaction, pigmentary changes and nail dystrophies occur often in patients undergoing cancer chemotherapy.

Apart from the well-known types I, II, III and IV hypersensitivity reactions, major cutaneous and mucocutaneous reactions associated with chemotherapy include stomatitis and mucositis, acral erythema, alopecia, cutaneous eruption of lymphocyte recovery, eccrine squamous syringometaplasia (ESS), extravasation reactions (including chemical cellulitis), hyperpigmentation, inflammation of keratosis, nail reactions, neutrophilic eccrine hidradenitis (NEH), photosensitivity and radiation associated (recall and enhancement) reactions [209, 211]. Mechanisms underlying most of these reactions remain to be determined. Cytotoxic chemotherapeutic drugs are the most common cause of stomatitis and mucositis. Although these terms are often used synonymously, stomatitis (oral mucositis) is restricted to the oral mucous membranes while mucositis affects the GI tract from mouth to anus. Approximately 40 % of patients receiving chemotherapy experience stomatitis. The most stomatotoxic agents include alkylating agents busulfan, chlorambucil and cyclophosphamide, anti-metabolites cytarabine, 5-fluorouracil and methotrexate, antibiotics bleomycin, actinomycin D, doxorubicin and mitomycin C, *Vinca* alkaloids and the taxanes [212]. Cytotoxic anti-neoplastic drugs destroy the rapidly dividing cells of the oral mucosa at a faster rate than most other normal healthy cells, but the detailed pathogenetic mechanism of stomatitis is still to be worked out. The pathogenesis of acral erythema (palmar–plantar erythrodysesthesia; hand–foot syndrome) [153] is not known, but it may be a direct cytotoxic effect. Some suggested mechanisms to explain the palms–soles location (Figs. 3 and 4) of reactions are based on vascular anatomy, temperature gradients, rapidly dividing epidermal cells and high concentration of eccrine glands [209]. Cutaneous eruptions of lymphocyte recovery is seen as a sharp, transient rise in temperature accompanied by macular and papular eruptions during the earliest recovery in peripheral lymphocyte numbers

following chemotherapy for leukemia [213]. The observed rash is thought to indicate the return of immunocompetent lymphocytes to the circulation suggesting an immune pathogenesis. ESS is a benign cutaneous reaction not associated with any particular cytotoxic chemotherapeutic drug which manifests as erythematous macules, plaques or vesicles on the intertriginous areas of the palms and soles. The reaction is thought to be a direct cytotoxic effect of the drugs. Extravasation reactions occur when chemotherapeutic drugs are inadvertently allowed to contact the tissues during their IV administration. Reactions may be irritant or vesicant, the former appearing as phlebitis and an erythematous reaction along the vein or at the IV site; urticarial flare reactions exhibited by anthracyclines are an example. A well-known drug eliciting vesicant reactions (called chemical cellulitis) is the antibiotic mitomycin C. Several drugs, including suramin, cytarabine and 5-fluorouracil, provoke inflammation in pre-existing skin reactions such as actinic keratoses. A suggested mechanism is increased DNA synthesis and uptake of drug by the affected tissues [214]. NEH [215], associated with cytarabine, bleomycin, chlorambucil, cyclophosphamide, mitoxantrone, vincristine and a number of other cytotoxic anti-cancer drugs, appears as fever, oedema and skin eruptions such as erythematous macules, papules, plaques and pustules. Necrosis of eccrine epithelial cells together with neutrophils around eccrine sweat glands and ducts and the presence of drug in the sweat of patients suggest that direct toxicity of the sweat glands is the cause of NEH [216].

Although modern targeted anti-cancer therapies such as tyrosine kinase and proteasome inhibitors have seen reductions in common systemic toxicities (e.g. nausea, vomiting, asthenia, diarrhoea etc.) and some of the more severe cutaneous and gastrointestinal effects occurring with some myelosuppressant drugs, it has become apparent that the targeted agents are responsible for multiple mild to moderate dermatological adverse effects (Table 3) [152, 155]. The most commonly reported effects are hand–foot skin reaction [151] (Fig. 4) (a distinct entity from hand–foot syndrome or acral erythema seen with cytotoxic drugs such as capecitabine (Fig. 3), 5-fluorouracil and doxorubicin [152]), papulopustular rash (Fig. 5), xerosis, fissures on fingertips and toes, pruritus, pigmentary changes and abnormalities of the mouth (stomatitis, mucositis), hair, scalp (alopecia), nails (e.g. paronychia) and on the eyelids (trichomegaly of the lashes). Some of the main features that can be used to distinguish the two hand–foot reactions relate to the type of lesion and their location on the hands and feet. The cytotoxic drugs cause diffuse and symmetric erythematous lesions with oedema and fissuring while in hand–foot skin reactions, tender, localized lesions appear as blisters and hyperkeratosis [152]. Lesions are seen on the palmar (ventral) surfaces of the hands following administration of both types of drugs. They are diffuse in the case of the cytotoxic agents but occur on the digit tips, over the

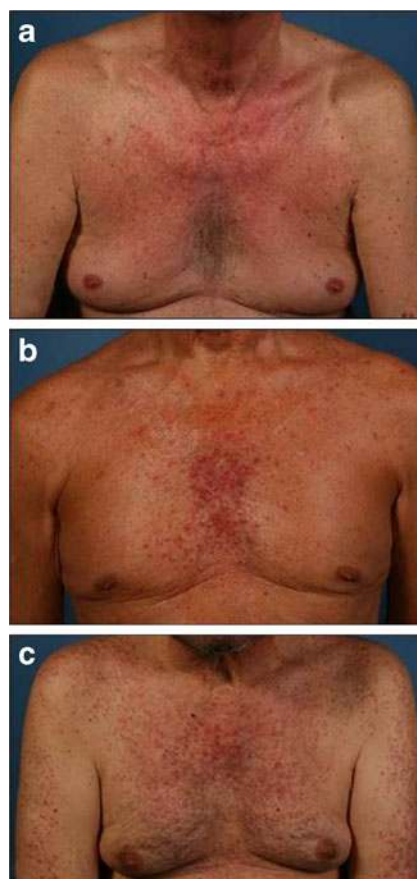


Fig. 5 Small molecule EGFR tyrosine kinase inhibitors such as erlotinib, gefitinib and sorafenib often provoke characteristic inflammatory papulopustular exanthemas described as acneiform or rosaceaform rashes. These are the most frequently seen cutaneous reactions to these drugs occurring in more than 90 % of patients in the first days–weeks of therapy [152, 154, 155]. The photographs show increasing degrees of severity of rashes based on a scoring system that takes into account colour and distribution of erythema, papulation, pustulation and scaling/crusts: **a** mild rash; **b** moderate rash; **c** severe rash (reproduced from Gerber et al. [154], an Open Access article distributed under the terms of the Creative Commons Attribution License)

interphalangeal joints and on the thenar area following the kinase inhibitors. On the feet, lesions are again ventrally located—diffuse over the sole with the cytotoxics but they may be on the heel and/or forefoot in cases of hand–foot skin reaction [151] (Fig. 4).

5.5.2 Drug-induced liver injury

Hepatotoxicity is the most common life-threatening drug reaction, perhaps the main cause of failure in drug development and a leading reason for regulatory warnings, modifications and withdrawals at the post marketing stage [217]. Hepatic injuries are said to account for 5.9 % of all ADRs, 14.7 % of lethal ADRs [218] and 13–17 % of acute liver failures. At least 1,000 registered drugs have been implicated in causing liver disease on more than one occasion. Drug-induced liver injury (DILI) mimics all forms of acute and chronic liver

disease and is seen predominantly as hepatitis and/or cholestasis [217]. Most cases of DILI fall into three main clinical patterns: acute hepatocellular injury with jaundice similar to hepatitis and increased serum transaminase; acute cholestatic injury with jaundice, marked elevation of serum alkaline phosphatase and moderate increases in transaminases and a mixture of these two patterns showing elevations of both alkaline phosphatase and transaminases [217]. The mechanism of DILI can be divided into direct, sometimes called intrinsic, hepatotoxicity (as seen with, for example, paracetamol (acetaminophen)) and unpredictable and rare liver injury which in turn can be classified into immune-mediated hypersensitivity and idiosyncratic reactions [217, 219]. The latter reactions are only seen in susceptible individuals and may be due to idiosyncratic metabolism producing harmful metabolites. Allergic hepatitis is associated with fever and rash and when caused by drugs, as in for example, DRESS, the reaction is generally a type IV hypersensitivity response involving CD4+ cells, CD8+ cytotoxic lymphocytes and NK, Kupffer and dendritic cells. Type II hypersensitivities may also sometimes occur. There are currently two main hypotheses for the mechanism of immune-mediated DILI. In perhaps the most supported model, the drug or active metabolite(s) as hapten is said to bind to endogenous proteins forming immunogenic conjugates that generate antibody- and/or T cell-mediated injury. Another view is that most individuals are tolerant to immune injury of the liver and reactions occur only when tolerance is in some way overcome [220–222]. Knowledge of mechanisms underlying idiosyncratic DILI remains limited. Direct hepatotoxicity usually manifests as necrotic reactions with little inflammation while idiosyncratic reactions show injury with clear inflammation. Anti-neoplastic drugs associated with an acute hepatitis injury pattern include L-asparaginase, azathioprine, carmustine, cyclophosphamide, 6-mercaptopurine, mithramycin and vincristine.

In considering DILI based on histological patterns and differential diagnoses, Ramachandran and Kakar [219] have distinguished and classified the involvement of a number of different commonly used chemotherapeutic drugs. In chronic hepatitis lacking autoimmune markers, 5-fluorouracil, its prodrug tegafur and tamoxifen have been implicated. Progression to fibrosing cholestatic hepatitis was reported in a hepatitis C patient given cyclophosphamide and corticosteroids [223]. In autoimmune hepatitis accompanied by hypersensitivity, rash, eosinophilia and arthralgia, long-term use of the tetracycline minocycline may lead to autoimmune hepatitis or hepatitis that mimics lupus-related hepatitis. The risk of methotrexate-induced liver toxicity is exacerbated by high dosage, existing liver disease and heavy alcohol use. The alkylating agent procarbazine, metabolised and activated in the liver, may cause granulomatous hepatitis. Methotrexate, 5-fluorouracil, cisplatin and tamoxifen have been associated

with macrovesicular steatosis while the topoisomerase I inhibitor irinotecan has a direct effect in steatohepatitis. Such an effect, sometimes referred to as chemotherapy-associated steatohepatitis, has also been reported for oxaliplatin. Tamoxifen, oestrogen and diethylstilbestrol can lead to hepatic steatosis but rarely steatohepatitis. Oxaliplatin may injure sinusoidal endothelial and hepatic stellate cells; thiopurine chemotherapeutic drugs have been implicated in peliosis hepatis and dacarbazine in hepatic vein thrombosis presenting clinically as Budd–Chiari syndrome [219].

5.5.3 Drug-induced lung disease

The term DILD covers a heterogeneous group of lung diseases. Patients most likely to develop DILD are those receiving chemotherapy with up to about 10 % of such patients experiencing injury although the incidence for individual drugs is different. The anti-neoplastic drugs most commonly involved in DILD are bleomycin, methotrexate, cyclophosphamide and busulfan, but many chemically and mechanistically different anti-cancer agents demonstrate pulmonary toxicity including mitomycin C, chlorambucil, melphalan, 6-mercaptopurine, cytarabine, gemcitabine, fludarabine, carmustine, lomustine, etoposide, the taxanes, irinotecan, procarbazine, vinblastine, zidovudine and the tyrosine kinase inhibitors imatinib and gefitinib. In general, mechanisms involved in the drug-induced lung injuries have not been elucidated making it difficult to effect classifications on the basis of pathogenesis. Chemotherapeutic drugs can be grouped into four main divisions: those producing interstitial pneumonitis and fibrosis, hypersensitivity reactions, acute respiratory distress syndrome (ARDS) and bronchiolitis obliterans organizing pneumonia (BOOP) [224]. Interstitial pneumonia and fibrosis, often provoked by bleomycin, is an inflammation of the lung interstitium and the most commonly occurring DILD. Other drugs involved include busulfan, chlorambucil, cyclophosphamide, melphalan, methotrexate and paclitaxel [225]. DILD hypersensitivity reactions result from interaction of drug with the immune system. Signs of interstitial pneumonia with lymphocytes and plasma cells infiltrating the interstitial space are seen. Immune-mediated damage to the lung in DILD may be due to drug-specific antibodies or, more usually, drug-specific T cells. Eosinophilic pneumonia showing eosinophils in the peripheral blood and bronchoalveolar lavage (BAL) fluid can be caused by almost any medication. Hypersensitivity pneumonitis is a combined types III and IV reaction in a Th1/Th17 response [226]. Reports of drug-induced hypersensitivity pneumonitis are increasing particularly to anti-neoplastic drugs [226]. No single diagnostic test is sufficient for a diagnosis, rather a combination of careful history, imaging (e.g. high-resolution computed tomography (CT)), examination of BAL fluid (positive signs include lymphocytic alveolitis with an increase in CD8+ lymphocytes), serum

drug-specific antibody tests, lung biopsy and perhaps inhalation challenge and the lymphocyte transformation test (LTT). Corticosteroids appear to hasten resolution of symptoms in both drug-induced hypersensitivity and eosinophilic pneumonia. In ARDS, inflammation of the lungs leads to impaired gas exchange and release of mediators causing further inflammation, hypoxia and ultimately organ failure. All trans-retinoic acid (ATRA) and mitomycin C are examples of chemotherapeutic drugs causing ARDS. In BOOP, organized polypoid granulation inflammatory tissue is seen in the distal bronchiole airways, respiratory bronchioles, alveoli and alveolar ducts [227, 228]. Bleomycin, cyclophosphamide and methotrexate are common causes.

The lack of definitive diagnostic tests for suspected chemotherapy-associated hypersensitivities makes it difficult to definitively identify some lung reactions thought to have an immune or hypersensitivity basis (see below), but some reactions appear to be true hypersensitivity responses. One such example is an acute onset form of bleomycin pneumonitis with fever and peripheral blood and BAL eosinophilia reversed by corticosteroids. Other examples include methotrexate-associated pneumonitis, an acute hypersensitivity reaction with bronchospasm to gemcitabine, procarbazine pneumonitis and pulmonary infiltrates and interstitial pneumonitis following docetaxel and paclitaxel [229, 230]. Some mitomycin C-treated adenocarcinoma patients with an unusual haemolytic-uraemic-like syndrome and pulmonary oedema develop ARDS. Circulating immune complexes with antibodies to carcinoembryonic antigen, platelets and gastric carcinoma cell surface antigens detected in a few of the patients suggest that the syndrome may be initiated by tumour cells or cell products released as a result of chemotherapy [231–233].

6 Cytokine-release and tumour lysis syndromes

Cytokine-release syndrome (CRS), sometimes called acute infusion reaction, is different from a hypersensitivity reaction, but the two may share some signs and symptoms, for example, nausea, fever, cough, dyspnea, bronchospasm, hypotension, rash, itching and urticaria. CRS usually develops during or soon after drug infusion with symptoms resolving within about 24 h [234]. Destruction of target and immune effector cells is thought to release cytokines such as TNF and interleukins into the circulation producing symptoms similar to a type I hypersensitivity response. Oxaliplatin, for example, has been implicated in the release of TNF- α and IL-6 in five colorectal cancer patients experiencing the signs and symptoms of CRS after infusion of the drug [235]. Symptom regression in the patients paralleled the decrease in serum cytokine concentrations. Prompt interruption of infusion and/or therapy with antihistamines, IV fluids, NSAIDs and

narcotics is required for CRS, and it should be continued prophylactically for at least 24 h [234].

Tumour lysis syndrome (TLS) occurs 48–72 h after initiation of cancer therapy when large numbers of tumour cells are killed in a short time, releasing intracellular contents into the circulation. This rapidly results in an ionic imbalance involving hyperkalaemia, hyperphosphatemia, hypocalcaemia and hyperuricaemia which may progress to acute renal failure, cardiac arrhythmias, seizures and death [236]. TLS occurs most often in ALL and lymphoma patients but is also seen with solid cancers particularly small-cell cancer and neuroblastoma. Anti-neoplastic drugs known to cause TLS include etoposide, fludarabine, paclitaxel, hydroxyurea, zoledronic acid, thalidomide and bortezomib. Unlike CRS, TLS is not difficult to differentiate from drug-induced hypersensitivity responses.

7 Diagnostic approaches and methods

7.1 Skin testing with chemotherapeutic drugs

The skin prick test (SPT) and IDT may be used to detect both immediate and delayed reactions to drugs, but these tests have not been widely and routinely applied, being used to diagnose hypersensitivities to only a relatively few drugs including platins, taxanes, cyclophosphamide, ifosfamide, cytarabine, 5-fluorouracil, methotrexate, mitomycin C and epirubicin [18, 19, 21]. Given the many non-targeted anti-cancer agents, let alone the ever-expanding range and variety of new targeted drugs, it is obvious that skin testing remains significantly under investigated and under utilized for diagnosis of drug hypersensitivities in oncology. Patch testing is said to be rarely, if ever, positive and not considered useful [24] (see, however, section 7.2.7).

Skin testing has been employed more often with the platins than any other anti-neoplastic agent but, even with these drugs, the procedure has not been widely used as a routine diagnostic test. ID testing with 100–240 μg of carboplatin showed that while only 13 of 47 patients (28 %) with ovarian or peritoneal cancer had a positive reaction, a negative skin test correctly predicted the absence of hypersensitivity in 166 of 168 courses of chemotherapy (658 of 668 patients or 98.5 %) [237]. A follow-up study confirmed the association between a negative carboplatin skin test and absence of hypersensitivity, but the significance of a positive test remained less certain [238]. Positive test results were obtained more often in a group of 60 patients referred for reactions to carboplatin. Fifty-three patients were skin test-positive, one patient showed a delayed positive reaction, four responded with a hypersensitivity reaction during drug infusion and two proved positive after several more infusions [166]. In a more recent study, positive skin tests to carboplatin were obtained in 64 % of 58 patients, leading the authors to conclude that the

test is not a reliable predictor of carboplatin hypersensitivity [239]. Skin test concentrations generally employed for carboplatin are 10 mg/ml in the SPT and 0.02 ml of 0.1 or 1 mg/ml in the IDT increasing in ten-fold concentration steps to a maximum of 10 mg/ml. For oxaliplatin, concentrations of 1–5 mg/ml have been used in the SPT and maximums of 0.1–5 mg/ml in the intradermal test [165, 240]. In summary, it has been claimed that skin tests are positive in more than 80 % of the platinum drug-treated patients tested, and when the skin test to platinum drugs is negative, the risk of a hypersensitivity reaction is reduced sevenfold or even eliminated [57]. This has led to the recommendation that skin testing should be performed on every patient before the eighth drug infusion. For the diagnosis of hypersensitivity to oxaliplatin, skin testing is said to be positive in 75 to 100 % of patients [164, 165]. Skin testing may also help in ruling out possible cross-reactions when seeking to substitute one platinum drug for another [241]. Employment of skin testing in everyday oncology practice remains controversial, principally because of lack of prior experience, the need for controls subjects and the fact that reactions may still occur in patients with a negative test [57]. This draws attention to the need for some allergy training in clinicians administering chemotherapy (see below)

7.2 Testing for types I, II, III and IV hypersensitivities

In general, diagnosis of type I hypersensitivities to chemotherapeutic drugs is based on clinical assessment and only sometimes with the aid of skin testing and rarely challenge testing. Specific assays for the detection of chemotherapeutic drug-specific IgE antibodies are usually not available, and when occasionally used, they are generally not validated. The basophil activation test is yet to be systematically investigated and applied for mechanistic studies or diagnosis.

7.2.1 Drug-induced thrombocytopenia

As mentioned above in relation to drug-induced thrombocytopenia, anaemia and neutropenia, it is important to distinguish immune-based suppression of haematopoietic cell lines from the dose-dependent bone marrow cytotoxicities shown by many anti-neoplastic drugs, but this is not always easily done. Since thrombocytopenia in response to chemotherapy is commonly the result of marrow suppression of megakaryocytopoiesis, a well-recognized side effect of anti-neoplastic drugs, immune-mediated DIT is not always considered in the diagnosis. Diagnosis, even harder if the patient is taking multiple medications, often tends to be based on the temporal relationship between drug administration and symptoms and/or on one-at-a-time drug withdrawal along with examination for a possible rebound in the platelet count. *In vitro* tests in the form of immunoassays that detect platelet-reactive serum antibodies are available [242,

243], but while they are an aid in the diagnosis of idiopathic thrombocytopenic purpura and autoimmune DIT, the tests are not standardized, often present technical difficulties (such as poor aqueous solubility of the drug and questions of the involvement of metabolites) and do not generally detect the drug-dependent antibodies. Specific tests in the form of enzyme-linked immunoassays (ELISAs) and cytometric procedures for drug-dependent antibodies in individual patients' sera are available at a few reference laboratories, but limited access to them and the time taken to obtain the result in an urgent situation are major drawbacks. Also, in some cases, a false negative result may result if the patient's own platelets are not employed in the test. Recommendations for the implementation of platelet autoantibody testing for immune thrombocytopenia have been published [243].

7.2.2 Drug-induced neutropenia and agranulocytosis

In addition to a complete blood count and differential and manual examinations of peripheral blood smears, anti-neutrophil antibody tests may be utilized to help diagnose immune-mediated neutropenia and agranulocytosis. Anti-neutrophil antibodies to neutrophil glycoproteins are detected by several different immunoassays [186]. The neutrophil antigens involved in immune neutropenia have been given the nomenclature HNA-1a, HNA-1b and HNA-1c (glycoprotein Fc γ IIIb; CD16), HNA-2a (gp50–64; CD177), HNA-3a (gp70–95), HNA-4a (CD11a) and HNA-5a (CD11b). Immunoassays employed include a granulocyte agglutination test, direct and indirect granulocyte immunofluorescence tests, ELISAs and, perhaps the most specific of the tests, the monoclonal antibody immobilization of granulocyte antigens (MAIGA) assay [244]. Unfortunately, tests for neutrophil antibodies are not widely performed and available, there are a number of technical difficulties including the detection and distinguishing of autoantibodies and drug-dependent antibodies [187], Fc receptors on neutrophils can produce false positive results, cells show fragility, aggregate and lyse and test results are not always easy to interpret. Taken together, these factors help to explain why ready detection of antibodies to neutrophils and hence easy diagnosis of cases of immune-mediated drug-induced neutropenia/agranulocytosis is not necessarily easy and sometimes not achievable.

7.2.3 Drug-induced anaemia

Tests for drug-induced anaemias are not as problematic as those for platelets and neutrophils, but the situation can be more complicated than it appears at first sight. Haemolytic anaemia (HA) resulting from high doses of penicillin is the classical cytotoxic type II hypersensitivity. Binding of drug to erythrocytes causes the cells to be recognized as foreign resulting in IgM and IgG antibodies reacting with the drug–

cell membrane protein complex, activation of the classical complement pathway, cell lysis and death. DIIHA [189] is another example of a type II cytotoxic antibody-mediated drug reaction. It can be associated with red cell autoantibodies that are drug-independent, that is, detected *in vitro* without adding drug or with drug-dependent antibodies that only react *in vitro* in the presence of drug. Some drugs bind covalently to the erythrocyte membrane proteins, antibodies bind to the surface-bound drug and following interaction with macrophages, Fc-mediated destruction of red cells occurs. The mechanism with other drugs remains controversial. Fludarabine is the most common drug causing drug-independent red cell autoantibodies, but other anti-neoplastic purine analogues, cladribine and pentostatin and the platinum-based chemotherapeutics have also caused DIIHA. Drugs already in use or newly introduced and not yet known to cause anaemia will be implicated in the future. Detailed mechanistic studies of most cases of anti-neoplastic drug-induced HA are generally not routinely undertaken so it is possible that interesting and surprising findings may be revealed with some of the many drugs now employed, as the following example serves to illustrate. In a study of 300 CLL patients given fludarabine, cyclophosphamide and rituximab, 5.8 % developed HA but 82.4 % of these patients showed a negative direct antiglobulin test suggesting that the drug combination treatment led to antiglobulin test-negative autoimmune HA [245].

7.2.4 Drug-induced vasculitis

Diagnosis of DIV can be difficult since there are no clearly well-established clinical or laboratory markers that can distinguish the condition from other vasculitidis. Anaemia is common in patients with DIV, pulmonary symptoms may correlate poorly with the disease and CT scanning of the chest, an ANCA screen (see section 5.3.1) and tissue biopsy may be necessary to reach a definitive diagnosis [246]. Some patients may also have antibodies to phospholipids and/or histones.

7.2.5 Drug-induced liver injury

As mentioned earlier, most cases of DILI fall into three main patterns [217] which may be used along with histological patterns [219] for differential diagnoses. Individual drugs often tend to have their own pattern signature that is characteristic of the drug [217]. Injury features such as rash, eosinophilia and a rapid response on re-challenge suggest that so-called idiosyncratic cholestatic liver injury is allergic in nature [217]. Accurate diagnosis of DILI, especially immune-mediated DILI together with identification of the causative drug, remains difficult. Specific tests are not available and there are no relevant experimental models to confidently establish mechanisms and devise potential diagnostic procedures. Current assessment of DILI is therefore largely

dependent on serum concentration of total bilirubin and tests for liver damage namely, measurements of serum alkaline phosphatase and liver transaminases alanine transaminase and aspartate transaminase. For immunological tests, LTT has been used for the detection of T cell proliferation, but the test is not always reliable and not always regarded with confidence if only because of doubts about antigen presentation of different drugs [221].

7.2.6 Drug-induced lung disease

Diagnosis of immune-mediated DILD provoked by chemotherapeutic drugs is similar to the situation with DILI. Although both an *in vivo* and *in vitro* approach would seem to be applicable, neither is totally satisfactory in practice. As discussed earlier, chemotherapeutic drugs can elicit four main types of lung reactions. High-resolution CT scanning, pulmonary function testing and bronchoscopy with BAL can be used along with the patient's history of drug exposure, histological evidence of lung damage and exclusion of other causes [224, 227]. In CT scans, interstitial pneumonitis and fibrosis (e.g. caused by bleomycin) tend to involve the lower lung zones, hypersensitivity reactions may be seen as ground-glass opacities with centrilobular nodules, bilateral ground-glass opacities involving dependent lung regions may be seen in ARDS and peribronchial or subpleural areas of consolidation are seen in BOOP [224]. *In vitro*, the LTT has been quite widely used in the attempted diagnosis of DILD in Japan where it has been said that 'compelling data as to the sensitivity and specificity of the (test) is currently lacking' [247]. For methotrexate, the LTT has been shown to be inadequate for confirming DILD. Positive results have been claimed for a leukocyte migration test designed to identify cytokines or chemokines produced by drug-stimulated lymphocytes from patients with methotrexate- or paclitaxel-induced pneumonitis. However, the sample numbers are so far small [247]. *In vivo* drug provocation testing is generally considered too risky since pulmonary damage may be irreversible and the utility of skin testing with drugs in DILD does not appear to have been carefully and systematically investigated.

7.2.7 Cutaneous reactions

As discussed, anti-cancer drug therapies are associated with multiple and various dermatological effects some of which are clearly immune-mediated, usually type IV hypersensitivities, and others which are less well understood mechanistically, especially those associated with targeted therapies such as EGFR inhibitors. With the latter drugs, cutaneous eruptions such as hand-foot skin reaction, papulopustular rash, lichenoid drug eruptions and palmoplantar hyperkeratosis [86, 152, 248] are in need of investigations to identify underlying mechanisms and to establish whether or not immune

processes have any role at all in drug-induced dry skin, pruritus and mouth, scalp, hair and nail changes.

Patch testing with drugs, in both pure and commercial form, is used to determine the cause of drug-induced cutaneous drug reactions and for studying the underlying pathophysiological mechanisms. The test is both a screening test for hypersensitivity and a provocation test in the target organ [170], the skin, where it can be seen as reproducing the disease. Patch testing is valuable for investigating a number of skin reactions including eczema, contact dermatitis, maculopapular rash, photosensitivity, fixed drug eruption, lichenoid rash and acute generalized exanthematous pustulosis. It seems to be less useful for investigating urticaria, SJS and TEN. Patch testing with anti-neoplastic drugs is generally considered to be of no value in diagnosing systemic reactions (see section 7.1), and it remains unclear how useful the test is for helping in the diagnosis of chemotherapeutic drug-induced cutaneous reactions. The LTT measures a memory T cell response and may identify a causative drug in cases of drug eruptions, but it is important to perform the test at the right time. The time varies and depends on the reaction—for example, with DRESS, patients should be tested 5 to 8 weeks after the onset of reactions while for maculopapular drug eruptions, SJS and TEN, testing should take place within 1 week of skin rashes. Other promising *in vitro* approaches for diagnosing and studying immune-mediated, in particular type IV, cutaneous reactions to drugs include application of the local lymph node assay for identifying contact allergens, ELISPOT cytokine assays for the detection of drug-reactive T cells and monitoring cutaneous lymphocyte-associated antigen and levels of the skin-associated chemokine CCL27 and its interaction with its receptor CCR10 [170].

8 Premedication and desensitization for chemotherapy

There is a risk of hypersensitivity reactions following administration of some drugs used in chemotherapy, and to minimize the risk and reactions, premedication may be undertaken. Taxane therapy, for example, requires premedication but premedication does not prevent true type I reactions to the platin drugs [24]. Reactions to taxanes may be IgE antibody-mediated or due to direct mast cell/basophil or complement activation. Corticosteroids and antihistamines are generally employed in premedication protocols. Patients given paclitaxel require IV H₁ (diphenhydramine 50 mg) and H₂ (cimetidine 300 mg, ranitidine 50 mg, famotidine 20 mg) antagonists prior to infusion commencing and an oral steroid (dexamethasone 20 mg) 12 and 6 h prior to 1-, 3- and 24-h-long infusions. For patients on docetaxel, dexamethasone 8 mg is given twice daily for 3 days starting 24 h prior to the commencement of infusion [249]. Premedication does not seem to be required for infusions extending over 96 h or more. In one protocol for docetaxel given weekly, oral dexamethasone 4.5–7.5 mg is

administered twice daily on the day before, the day of and the day after commencement of infusion, together with IM promethazine 25 mg and IV cimetidine 600 mg 30 min before docetaxel. For paclitaxel, the protocol is: dexamethasone 2.25–7.5 mg orally 12 h and 2 h before and promethazine 25 mg IM and cimetidine 600 mg IV 30 min before the taxane.

Only immediate type hypersensitivity drug reactions involving IgE antibodies and/or a mast cell-mediated mechanism are considered eligible for desensitization. Administering increasing amounts of drug in an incremental and stepwise manner can provide a safe and effective means of continuing vital therapy while avoiding, or largely preventing, the adverse reactions. For carboplatin hypersensitivity, Lee *et al.* [250] administered a cumulative dose of 38.935 mg of drug in 11, 15-min steps followed by a final infusion over 184.4 min administering 461.065 mg (92 %). The total final cumulative dose of 500 mg was given over a ~6-h period. In a rapid desensitization protocol for carboplatin, oxaliplatin, docetaxel and paclitaxel, Gastaminza *et al.* [240] employed five delivery stages in procedures lasting from 2 to 5 h with 89 % of the total dose delivered in 1 h in the last step. Once again, apart from data on the platins and taxanes, there is little pertinent information on desensitization for most other anti-cancer drugs. A successful desensitization protocol for the receptor tyrosine kinase inhibitor sunitinib involved ten escalating doses starting with 0.05 mg following premedication with prednisone and promethazine [251]. Examples of desensitization to imatinib have also been reported. Successes were achieved with gradual dose escalation over 10 weeks and, in another case, over 5 days starting with a dose of 0.005 mg and building up to a total of 400 mg [252]. In a 4-h outpatient oral procedure beginning with a 10-ng dose of imatinib, the drug was administered in increasing dosage every 15 min to ten patients, only two of whom ultimately proved unable to continue therapy [253].

9 The most insidious of all adverse consequences of targeted therapies: tumour adaptation, increased malignancy and the invasive metastatic switch

Over the last 15 years, molecularly targeted approaches involving innovative anti-angiogenic strategies, particularly drugs inhibiting the VEGF-A pathway, for example, the mAb bevacizumab and VEGFR tyrosine kinase inhibitors sorafenib and sunitinib [254], have brought about a revolution in the treatment of cancer. However, it has become increasingly clear that the complexities of tumour-induced angiogenesis and our understanding of its many interrelated processes and opposing effects on tumour resistance, growth and metastasis [255, 256] have produced outcomes that are often disappointing and more modest than originally expected [257]. From studies in tumour-bearing mice, the realization that anti-angiogenic therapy that initially exerts an antitumour

effect by inhibiting vascularization may also lead on to the opposing effects of enhanced tumour growth, invasiveness and distal metastasis has brought into focus the questions of how tumour resistance develops and how it can be overcome [257, 258]. A number of possible explanations have been advanced such as the involvement of pro-angiogenic cytokines and growth factors, e.g. granulocyte colony-stimulating factor (G-CSF), stromal cell-derived factor 1 α (SDF-1 α ; CXCL12), osteopontin [259]; absence of VEGF or VEGFRs in metastatic tumours; tumours utilizing blood vessels in vascular-rich tissues; selection and growth of tumour cells resistant to hypoxia and a number of other suggestions [258, 260]. Tumour blood vessels are abnormal [261], and poor oxygenation is a well-known feature of solid tumours leading to tumour invasiveness that is due, in part at least, to increased expression of hypoxia-inducible factor-1 α (HIF-1 α) [262]. Several studies have highlighted the importance of improving oxygenation of cancer cells by demonstrating differentiation, vascular normalization and reduced metastasization following pO₂ increases [263, 264] after promotion of the so-called invasive metastatic switch [265] in a hypoxic tumour environment [266, 267]. In findings that seem to offer one of the most promising early strategies to overcome the invasive and metastatic effects seen during resistance to anti-angiogenic drugs, the endogenous anti-angiogenic chemorepulsive protein semaphorin 3A normalized the vasculature and blocked tumour growth when re-expressed in mouse pancreatic neuroendocrine tumours and cervical carcinomas [268, 269]. HIF-1 α which regulates cellular adaptation to oxygen deprivation is often associated with treatment failure [267], and its expression in human tumours has been shown to correlate with metastasis [270]. Treatment of tumour-bearing mice with sunitinib and semaphorin 3A demonstrated a marked reduction in HIF-1 α levels that were previously elevated in animals treated with the anti-angiogenesis drug. Administration of semaphorin 3A together with sunitinib also reduced NF- κ B and counteracted sunitinib-induced activation of c-Met (Met tyrosine kinase receptor; hepatocyte growth factor (HGF) receptor) and other signalling pathways active in hypoxia [269, 271]. NF- κ B activates HIF-1 α and cancer invasiveness and may have an important role in the development of resistance to anti-angiogenic resistance [272]. C-Met and its ligand, HGF (scatter factor) are upregulated in a number of different cancers where they contribute to angiogenesis and tumour growth and metastasis [273].

10 Combination therapies with targeted agents: adverse effects as a consequence of overcoming resistance to anti-angiogenic therapy

As summarized above, resistance eventually develops to VEGF inhibition therapy with the occurrence of residual

primary tumour growth and/or metastasis [256]. It seems that restoration of the vasculature is the forerunner of oxygenation of tumour tissue and vascular normalization is critical not only for overcoming resistance to anti-angiogenic therapy but also to achieve success with such therapy together with other chemotherapeutic agents. These findings have ramifications for future targeted therapeutic approaches with anti-angiogenic agents and for consequent adverse events occurring in treated patients. HIF-1 α is overexpressed in many cancers and its role in angiogenesis, tumour growth and metastasis is firmly established [266, 267] making the transcription factor a priority target for drug development [274, 275]. Topotecan, a topoisomerase I inhibitor that inhibits religation of DNA strand breaks (Table 2), independently inhibits HIF-1 α accumulation in human cancer cells [276] while the related drug irinotecan (Table 2) has already been employed in combination with bevacizumab to inhibit HIF-1 α in recurrent glioblastoma [277]. Other non-targeted chemotherapeutic drugs that inhibit HIF-1 α include the aryl hydrocarbon receptor aminoflavone, the peptide antibiotic with anticancer activity echinomycin and anthracyclines such as doxorubicin [278]. Targeted drugs that inhibit HIF-1 α include HDAC and mTOR (everolimus and temsirolimus) inhibitors and the proteasome inhibitor bortezomib (Table 3) [279]. The mTOR inhibitor rapamycin together with irinotecan proved active in a mouse model of human metastatic colon cancer. The drug combination produced a reduction in tumour volume together with cell death under hypoxic but not normoxic conditions indicating a cytotoxic effect mediated via HIF-1 α [280]. Inhibitors that target other pathways, particularly pathways to tumour invasiveness, are also being sought. One such pathway is the HGF/C-Met pathway where preclinical studies with inhibitors that block multiple receptor tyrosine kinases (including VEGF) and c-Met showed amplification of the effects of VEGFR blockade leading to reduced angiogenesis, increased apoptosis and reductions in tumour growth and metastasis [281].

For metastatic carcinoma, e.g. RCC, approved targeted therapies that have become available in recent years for first- and second-line use include sorafenib, sunitinib, pazopanib (Table 3), the VEGF-targeted mAb bevacizumab and mTOR inhibitors everolimus and temsirolimus (Table 3). The main adverse events to bevacizumab comprise GI perforation, haemorrhage, wound healing complications, thrombosis, infusion reactions, hypertension, necrotizing fasciitis, proteinuria and pulmonary events [282]; reactions to the other five drugs are summarized in Table 3. Axitinib (Inlyta[®]) which inhibits multiple receptor tyrosine kinases including VEGFRs, PDGFR and c-KIT was approved by the FDA in January 2012 for patients with advanced RCC after failure of one prior systemic therapy. Adverse reactions to the drug are quite extensive and include hypertension, thrombotic events, haemorrhage, GI perforation and fistula, hypothyroidism,

wound healing complications, proteinuria, reversible posterior leukoencephalopathy syndrome, hepatic impairment, hand–foot skin reaction and exfoliative dermatitis [283]. In addition to the well-known adverse reactions to the drugs used for mono-anti-angiogenic treatment, for example sunitinib or sorafenib, the likely increasing use of combination therapies to overcome the severe adverse consequences of the resistance-promoting targeted anti-angiogenic therapies will see the appearance of adverse responses to cytotoxic, non-targeted drugs like topotecan, irinotecan and anthracyclines with their well-known myelosuppression, cytopenias and occasional type I (anaphylactic) and types II and III hypersensitivity reactions (Table 2). As well as the employment of topoisomerase inhibitors, combination therapies utilizing targeted mTOR, HDAC (e.g. vorinostat) or proteasome (e.g. bortezomib, carfilzomib) inhibitors will give rise to the known systemic and cutaneous reactions evoked by these drugs (Table 3). Drugs that inhibit hypoxia signalling are already being sought and examined [284], and it is certain that each new drug will provoke its own spectrum of adverse effects. Suggested new therapeutic approaches, for example employment of semaphorin A3 [269], to inhibit angiogenesis while assisting the development of the surviving vasculature and thus avoiding ongoing hypoxia are likely to be intensively examined to see whether the observed effects in mice also occur in man. Here it will be necessary to determine if the encouraging effects of inhibition of Met activation, increase in levels of the apparent tumour suppressor and adhesion molecule E-cadherin and reductions in tumour invasiveness and metastasis are not opposed by processes promoting tumour progression. The complexity of the tumour environment with its myriad effector pathways demands investigation of the latter possibility.

Other underlying mechanisms with the promise of possible new therapies currently being examined or under development include a soluble decoy receptor for VEGF [VEGF trap; aflibercept (Zaltrap®)]—for adverse reactions see Table 3 [285], inhibition of VEGF and angiopoietins [286], drugs that inhibit placental growth factor (PlGF) [287], targeting of angiopoietin-Tie2 signalling [288], the possible need to add anti-inflammatory therapy as a result of an inflammatory environment helping to sustain tumour progression [289], the search for inhibitors of matrix-degrading enzymes [e.g. matrix metalloproteinase (MMP)-9] for use as blockers of tumour invasion [290] and study of vascular integrin inhibitors for anti-angiogenic therapy. In relation to this last strategy, cilengitide, a cyclic RGD (Arg-Gly-Asp)-motif-containing pentapeptide (Fig. 6) that binds with high specificity to the $\alpha v \beta 3$ and $\alpha v \beta 5$ vascular integrin heterodimers, targets both tumour cells and the vasculature [291]. Integrins, a family of cell adhesion transmembrane receptors, may be highly expressed in some tumours; for example, $\alpha v \beta 3$ and $\alpha v \beta 5$ are significantly upregulated in human gliomas. Cilengitide,

the first integrin inhibitor to reach phase III clinical development, shows promise for glioblastoma with patients demonstrating good tolerance to what are claimed to be the drug's relatively few side effects. The most common adverse events reported to the FDA during the period 1997–2012 were effects on the white blood cells, viz. neutropenia and thrombocytopenia as well as pulmonary embolism, urinary tract infections, anorexia, joint and bone pain and electrolyte imbalance. A recent announcement from the phase III CENTRIC trial which investigated the efficacy and tolerability of cilengitide in newly diagnosed glioblastoma patients with methylated *O*(6)-methylguanine DNA methyltransferase gene promotor status revealed that the drug did not meet its primary endpoint of significantly increasing overall survival.

It is clear that many currently favoured strategies to elucidate mechanisms and find new and effective anti-cancer agents are leading to targeted 'multi-modal' therapies combining different anti-angiogenic, or anti-angiogenic together with cytotoxic, approaches [292]. It should be anticipated that as the number and variety of therapeutic agents given to a patient increases (and these may ultimately include some unusual choices, e.g. anti-inflammatory drugs), the problem of sorting out and quickly identifying the drug(s) responsible for an adverse reaction inevitably becomes more difficult.

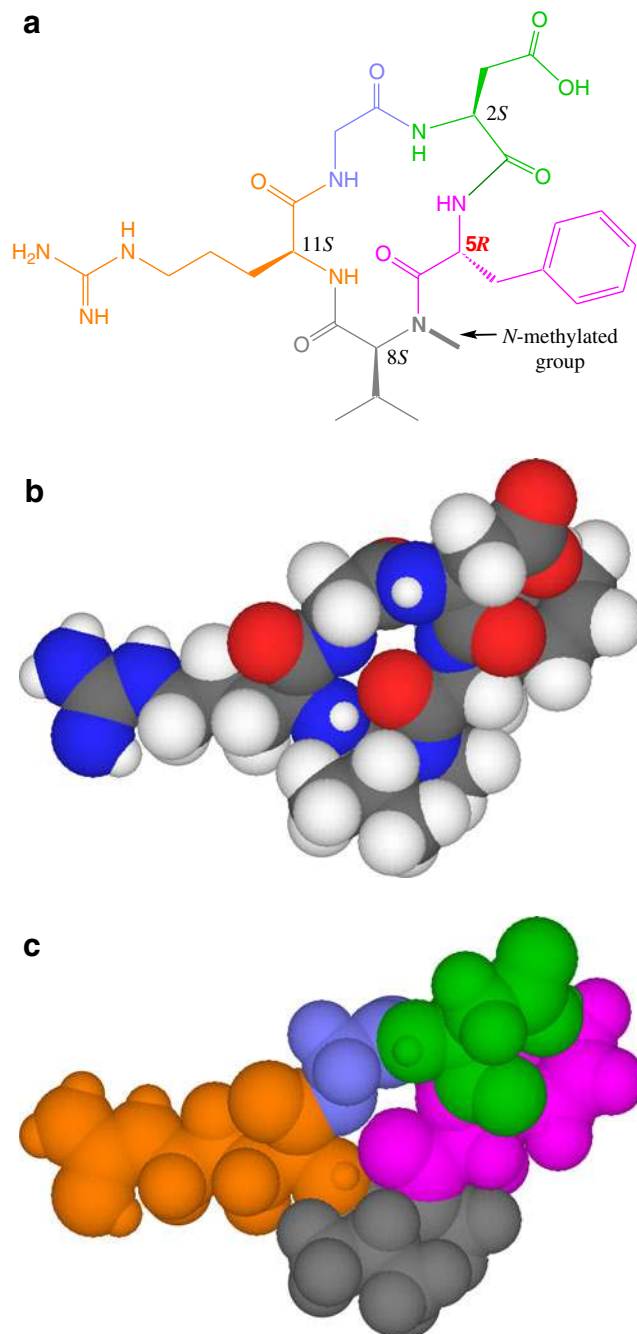
11 Concluding remarks: do some hypersensitivity responses go unrecognised? Towards multi-modal treatment strategies

A consideration of the possibility of hypersensitivity reactions is a necessary part of clinical drug trials, and such reactions are commonly referred to in information released by drug regulatory agencies, drug package inserts, the oncology literature, some pharmacological investigations and toxicology studies. The term hypersensitivity is widely used across a number of disciplines, but it is clear that those using the term do not always have the same definition in mind. Even within its 'home' disciplines of immunology and allergy, there is inconsistency and confusion over both the definition of hypersensitivity and the assignment of the term, and this situation has not been helped by the WAO's so-called 'stringent definition' based, as claimed, on 'the mechanisms that initiate and mediate allergic reactions' without including any reference to allergic and/or immune involvement [7]. With such a definition, it is difficult to see how types I to IV hypersensitivity reactions, distinguished on the basis of humoral and cellular immune mediation, can be separated from a variety of other reactions showing 'objectively reproducible symptoms or signs' initiated by 'a defined stimulus at a dose tolerated by normal persons'. It is not surprising therefore to find that a drug reaction classified as a hypersensitivity response in the absence of any test investigations might be anything from an

Fig. 6 Two-dimensional (a) and three-dimensional CPK space-filling models (b, c) of cilengitide, a cyclic pentapeptide with the structure cyclo(L-arginylglycyl-L- α -aspartyl-D-phenylalanine-N-methyl-L-valyl) (c(RGDf(NMe)V) containing the RGD (Arg-Gly-Asp)-binding motif. Cilengitide is regarded as a promising drug for treatment of glioblastoma and several other tumours. In a and c, the three amino acids of the RGD motif are distinguished by the colours: orange, arginine; blue, glycine and green, aspartic acid. The remaining two amino acids making up the pentapeptide are shown in magenta (phenylalanine) and grey (*N*-methylated valine). The RGD sequence, the most prominent recognition motif involved in cell adhesion, is also found in fibronectin, fibrinogen, vitronectin and osteopontin each of which bind the pro-angiogenic $\alpha v \beta 3$ integrin targeted for cancer therapy. Note that the cilengitide molecule contains the D-isomer of phenylalanine to force adaptation of a β II' turn in the synthesis of the cyclic peptide and one peptide bond (in the linkage with valine) has been *N*-methylated to increase the antagonistic activity of the molecule. The guanidino and carboxyl side chain groups of arginine and aspartic acid, respectively, which point in opposite directions may promote ionic interactions with the receptor [291]

unsurprising collection of respiratory or gastrointestinal symptoms to a full-blown bullous skin eruption. Such inconsistent use of the term hypersensitivity is particularly apparent in the assessment and recording of adverse reactions to chemotherapeutic drugs. Patients sometimes show different and unexpected reactions to the same drug. The question of the possible participation of humoral or cellular immune mechanisms in anti-neoplastic drug-induced thrombocytopenia, neutropenia, anaemia, vascular disorders, liver injury and lung disease as well as in the many dermatological manifestations is obviously fundamental in any attempted assessment of the incidence of true hypersensitivity responses to the increasing battery of drugs used in large numbers of patients for therapy of many different cancers. Even a quick perusal of Tables 2 and 3 reveals that adverse haematological, liver, lung and skin reactions occur across the multitude of chemically diverse drugs, many with vastly different modes of action, but it is frequently not at all clear whether a reaction is a true hypersensitivity response and if any immune process, direct or indirect, is involved. In a recent review of immune haemolytic anaemia associated with drug therapy, Garraty [293] summarized the current situation in words that apply as much to drug-induced reactions to platelets, neutrophils, the vasculature, liver, lung and cutaneous cells as to red cells: ‘With increased knowledge of the immune system...it is a pity that more modern approaches have not been applied to solving the mechanism(s) involved in drug-induced RBC auto antibody formation’.

If widespread acceptance of what constitutes a hypersensitivity reaction is to be achieved, agreement on the definition of such reactions must occur and that will require the acceptance of uniform criteria for some common terminology. In the standard classification and severity grading scale in cancer therapy, clinical trials and other oncology settings published as Common Terminology Criteria for Adverse Events by the US National Institutes of Health and NCI under the US Cancer



Therapy Evaluation Program, ‘hypersensitivity’ is grouped with ‘allergic reaction’ [234], in itself indicating the acceptance of an immune basis for hypersensitivity responses. In recent years, progress has been made in elucidating mechanisms underlying a range of drug-induced cell-mediated type IV cutaneous eruptions (e.g. allergic contact dermatitis, psoriasis, erythema multiforme, AGEP, SJS, TEN) and systemic/cutaneous reactions (e.g. DRESS) [210], and together with our understanding of the mechanisms of types I, II and III hypersensitivities, it should be possible to present clear

guidelines on the criteria necessary to identify a reaction as a true hypersensitivity response. In everyday practice, it will sometimes be difficult to clearly establish an immune basis for a reaction since, as outlined above, suitable tests necessary to define the mechanism of the reaction may not be available or easily accessible. Obtaining the necessary evidence to be sure of a hypersensitivity classification for a particular reaction may be especially difficult in some cases of suspected drug-induced immune lung disease, liver injury and vascular disorders where work needs to be done to develop and apply suitable tests. Even for drug-induced thrombocytopenia and neutropenia, proving immune mediation of reactions will be difficult for some investigators, clinicians and facilities. However, despite the admittedly inadequate testing procedures available, it is likely that systematic application of the existing skin test approaches and *in vitro* assays could significantly improve the discrimination of many haematological, vascular, lung, liver and skin reactions and identify some true types I, II, III and IV drug hypersensitivities that may currently go unidentified because of the present widespread absence of any such testing. Existing assays and procedures for detecting drug-specific/reactive IgE and cytotoxic antibodies, drug-antibody immune complexes and drug-reactive T cells need to be more frequently employed, but further research is needed to improve the range, specificity, ease of use and ready access of procedures for the identification of the four types of hypersensitivities to the many different anti-cancer drugs now so widely used. This area of oncoimmunology research has been neglected, not least by immunologists and allergists, to the detriment of patients, our recognition of the true nature and spectrum of side effects of many anti-neoplastic drugs and our understanding of some important and still poorly researched vascular, lung, liver and cutaneous drug-induced reactions.

Clearly, the terminology used to describe hypersensitivity reactions needs to be standardised, but while the unsatisfactory lack of a common definition of what constitutes a hypersensitivity reaction and hence the resultant misuse of the term are particularly apparent in cancer chemotherapy, the same deficiencies, perhaps to a somewhat lesser extent, also exist in the allergy field. Greater involvement of both clinical and experimental allergists in the assessment of adverse drug responses to neoplastic agents in oncology would be of benefit to both disciplines and, importantly, lead to a more accurate interpretation of adverse events during clinical trials of cancer drugs. Adverse reactions that are serious enough to threaten further administration of drugs vital for therapy of particular cancers occur commonly and fatal outcomes may result in cases of drug withdrawal when this might have otherwise been prevented by skilled desensitization procedures. Given this, the potential value of skin testing in some cases and the need for premedication treatments and desensitizations, it is both surprising and unfortunate that allergists and clinical

immunologists often seem to be so little involved in the management of adverse/hypersensitivity reactions in cancer chemotherapy.

Finally, in relation to the immediate future of cancer chemotherapy, understanding the basis of the resistance that develops to VEGF inhibition therapy by, for example receptor tyrosine kinase inhibitors such as sorafenib and sunitinib, has brought with it the realization of the need to restore normal vasculature and oxygenation of tumour tissue. Arising from this is the desire to identify some fresh therapeutic targets such as the transcription factor HIF-1 α , the expression of which correlates with metastasis. Multi-modal treatment strategies combining anti-angiogenesis and cytotoxic therapies will see the appearance of already known side effects of the ‘older’ cytotoxic drugs topotecan, irinotecan and some anthracyclines, some existing targeted drugs including mTOR, HDAC and proteasome inhibitors but, as well, the yet to be determined reactions to the new therapeutic strategies under investigation/development such as those targeting angiopoietin-Tie2 signalling, semaphorins for angiogenesis inhibition and inhibitors of HIF-1 α , c-Met, E-cadherin, VEGF-angiopoietins, PIGF, MMPs and vascular integrins.

Acknowledgments We thank Professor R. Gutzmer, Hannover Medical School, Germany for his generous provision of the photographs shown in Fig. 4.

Conflict of interest No financial contribution or any other assistance was received by the authors in relation to the preparation and presentation of this work. No potential conflict of interest is, or has been, involved.

References

1. World Health Organization. (1972). International drug monitoring: the role of national centres. *WHO Technical Report Series*, no. 498, pp. 1–25.
2. Edwards, I. R., & Aronson, J. K. (2000). Adverse drug reactions: definitions, diagnosis, and management. *Lancet*, 356(9237), 1255–1259.
3. What is a serious event? <http://www.fda.gov/safety/medwatch/howtoreport/ucm053087.htm>. Accessed 18 February 2013.
4. Meyer, U. A. (2000). Pharmacogenetics and adverse drug reactions. *Lancet*, 356(9237), 1667–1671.
5. Coombs, R. R. A., & Gell, P. G. H. (1975). Classification of allergic reactions responsible for clinical hypersensitivity and disease. In P. G. H. Gell, R. R. A. Coombs, & P. J. Lachmann (Eds.), *Clinical aspects of immunology* (pp. 761–781). Oxford: Blackwell.
6. Johansson, S. G. O., O’B Hourihane, J., Bousquet, J., Brujnzeel-Koomen, C., Dreborg, S., Haahtela, T., et al. (2001). A revised nomenclature for allergy: an EAACI position statement from the EAACI task force. *Allergy*, 56(9), 813–824.
7. Johansson, S. G. O., Bieber, T., Dahl, R., Friedmann, P. S., Lanier, B. Q., Lockey, R. F., et al. (2004). Revised nomenclature for allergy for global use: report of the Nomenclature Review Committee of the World Allergy Organization, October 2003. *The Journal of Allergy and Clinical Immunology*, 113(5), 832–836.

8. Brockow, K., Romano, A., Aberer, W., Bircher, A. J., Barbaud, A., Bonadonna, P., et al. (2009). Skin testing in patients with hypersensitivity reactions to iodinated contrast media—a European multicenter study. *Allergy*, *64*(2), 234–241.
9. Vane, J. R. (1976). The mode of action of aspirin and similar compounds. *The Journal of Allergy and Clinical Immunology*, *58*(6), 691–712.
10. Ardavanis, A., Tryfonopoulos, D., Yiotis, I., Gerasimidis, G., Baziotis, N., & Rigatos, G. (2004). Non-allergic nature of docetaxel-induced acute hypersensitivity reactions. *Anti-Cancer Drugs*, *15*(6), 581–585.
11. Weiss, R. B., & Baker, J. R., Jr. (1987). Hypersensitivity reaction from antineoplastic agents. *Cancer and Metastasis Review*, *6*(3), 413–432.
12. Freter, C. E., & Perry, M. C. (2008). Systemic therapies. In M. D. Abeloff, J. O. Armitage, J. E. Niederhuber, et al. (Eds.), *Clinical oncology*, vol 1 (4th ed., pp. 453–463). Philadelphia: Churchill-Livingstone Elsevier.
13. National Cancer Institute (NCI) Drug Dictionary. Available at www.cancer.gov/drugdictionary. Accessed 18 February 2013.
14. List of anti-cancer drugs approved by the FDA. Available at <http://pharmaknow.com/list-of-anti-cancer-drugs-approved-by-the-fda/> (accessed February 18, 2013).
15. Thurston, D. E. (2007). *Chemistry and pharmacology of anticancer drugs* (pp. 29–156). Boca Raton: CRC.
16. Levitski, A., & Klein, S. (2010). Signal transduction therapy of cancer. *Molecular Aspects Medicine*, *31*(4), 287–329.
17. Maltzman, J. D., & Millar, L. B. (2013). Chemotherapy primer: Why? What? and How? <http://www.oncolink.org/treatment/article.cfm?id=224&s=9&c=2>. Accessed 18 June 2013.
18. Weiss, R. B., & Bruno, S. (1981). Hypersensitivity reactions to cancer chemotherapeutic agents. *Annals of Internal Medicine*, *94*(1), 66–72.
19. Gonzalez, I. D., Saez, R. S., Rodilla, E. M., Yges, E. L., & Toledano, F. L. (2000). Hypersensitivity reactions to chemotherapy drugs. *Alegologia et Immunologia Clinica*, *15*, 161–181.
20. Crestani, B., Jaccard, A., Israel-Biet, D., Couderc, L. J., Frija, J., & Clauvel, J. P. (1994). Chlorambucil-associated pneumonitis. *Chest*, *105*(2), 634–636.
21. Kingsley, C. D. (2008). Hypersensitivity reactions. In M. C. Perry (Ed.), *The chemotherapy source book* (4th ed., pp. 152–173). Philadelphia: Lippincott Williams & Wilkins.
22. Komamura, H., Higashiyama, M., Hashimoto, K., Takeda, K., Kimura, H., Tani, Y., et al. (1995). Three cases of chemotherapy-induced acral erythema. *The Journal of Dermatology*, *22*(2), 116–121.
23. Popescu, N. A., Sheehan, M. G., Kouides, P. A., Loughner, J. E., Condemi, J. A., Looney, R. J., et al. (1996). Allergic reactions to cyclophosphamide: delayed clinical expression associated with positive immediate skin-tests to drug metabolites in five patients. *Journal of Allergy and Clinical Immunology*, *97*(1, pt 1), 26–33.
24. Pagani, M. (2010). The complex clinical picture of presumably allergic side effects to cytostatic drugs: symptoms, pathomechanism, reexposure, and desensitization. *Medical Clinics of North America*, *94*(4), 835–852.
25. Klastersky, J. (2003). Side effects of ifosfamide. *Oncology*, *65*(Suppl 2), 7–10.
26. Estève, E., Bagot, M., Joly, P., Souteyrand, P., Beylot-Barry, M., Vaillant, L., et al. (1999). A prospective study of cutaneous intolerance to topical mechlorethamine therapy in patients with cutaneous T-cell lymphomas. *Archives of Dermatology*, *135*(11), 1349–1353.
27. Cornwell, G. G., Pajak, T. F., & McIntyre, O. R. (1979). Hypersensitivity reactions to iv melphalan during treatment of multiple myeloma: cancer and leukemia group B experience. *Cancer Treatment Reports*, *63*(3), 399–403.
28. Weiss, R. B. (1992). Hypersensitivity reactions. *Seminars in Oncology*, *19*(5), 458–477.
29. Chang, P., Riggs, C. E., Scheerer, M. T., Wiernik, P. H., & Bachur, N. R. (1976). Combination chemotherapy with adriamycin and streptozocin. II. Clinicopharmacologic correlation of augmented adriamycin toxicity caused by streptozocin. *Clinical Pharmacology and Therapeutics*, *20*(5), 611–616.
30. McClay, E., Lusch, C. J., & Mastrangelo, M. J. (1987). Allergy-induced hepatic toxicity associated with dacarbazine. *Cancer Treatment Reports*, *71*(2), 219–220.
31. Koschel, D., Handzhiev, S., Leucht, V., Holotiuk, O., Fisseler-Eckhoff, A., & Höffken, G. (2009). Hypersensitivity pneumonitis associated with the use of temozolomide. *European Respiratory Journal*, *33*(4), 931–934.
32. Alonso-Llamazares, A., Vega-Castro, A., Beitia-Mazuecos, J. M., Mateo-Borrega, B., & Cardenas-Contreras, R. (2012). Rapid desensitization with temozolomide in patients with delayed maculopapular rash. *Journal of Investigational Allergology and Clinical Immunology*, *22*(6), 437–459.
33. National Library Medicine HSDB database (2013). Toxnet toxicology data network. Alretamine. <http://toxnet.nlm.nih.gov/cgi-bin/sis/search/a?dbs+hsdb:@term+@DOCNO+7559>. Accessed 19 February 2013.
34. Lee, M., & Sharifi, R. (1987). Generalized hypersensitivity reaction to intravenous thiotepa and doxorubicin. *Journal of Urology*, *138*(1), 143–144.
35. Liu, C. Y. (2002). Fluorouracil for allergic reactions to capecitabine. *Annals of Pharmacotherapy*, *36*(12), 1897–1899.
36. Mignogna, M. D., Fortuna, G., Falletti, J., & Leuci, S. (2009). Capecitabine-induced stomatitis: a likely pathogenetic mechanism of oral lichenoid mucositis. *European Journal of Clinical Pharmacology*, *65*(10), 1057–1059.
37. Crawford, J. H., Eikelboom, J. W., & McQuillan, A. (2002). Recurrent palmar-plantar erythrodysesthesia following high-dose cytarabine treatment for acute lymphoblastic leukemia. *European Journal of Haematology*, *69*(5–6), 315–317.
38. O'Brien, M. E. R., & Souberbielle, B. E. (1992). Allergic reactions to cytotoxic drugs—an update. *Annals of Oncology*, *3*(8), 605–610.
39. Kudrik, F. J., Rivera, M. P., Molina, P. L., Maygarden, S., & Socinski, M. A. (2002). Hypersensitivity pneumonitis in advanced non-small-cell lung cancer patients receiving gemcitabine and paxitaxel: report of two cases and review of the literature. *Clinical Lung Cancer*, *4*(1), 52–56.
40. Jeter, M. D., Jänne, P. A., Brooks, S., Burstein, H. J., Wen, P., Fuchs, C. S., et al. (2002). Gemcitabine-induced radiation recall. *International Journal of Radiation Oncology, Biology, Physics*, *53*(2), 394–400.
41. Meunier, P., Castaigne, S., Bastie, J. N., Chosidow, O., & Aractingi, S. (1996). Cutaneous reaction after treatment with 2-chlorodeoxyadenosine. *Acta Dermato Venereologica*, *76*(5), 385–386.
42. Robak, T., Blasinska-Morawiec, M., Krykowski, E., Hellmann, A., & Konopka, L. (1997). Autoimmune haemolytic anemia in patients with chronic lymphocytic leukemia treated with 2-chlorodeoxyadenosine (clidribine). *European Journal of Haematology*, *58*(2), 109–113.
43. Longo, G., Gandini, G., Ferrara, L., Torelli, U., & Emilia, G. (1997). Fludarabine and autoimmune hemolytic anemia in chronic lymphocytic leukemia. *European Journal of Haematology*, *59*(2), 124–125.
44. Korelitz, B. I., Zlatanic, J., Goel, F., & Fuller, S. (1999). Allergic reactions to 6-mercaptopurine during treatment for inflammatory bowel disease. *Journal of Clinical Gastroenterology*, *28*(4), 341–344.
45. O'Dwyer, P. J., King, S. A., Eisenhauer, E., Grem, J. L., & Hoth, D. F. (1989). Hypersensitivity reactions to deoxycoformycin. *Cancer Chemotherapy and Pharmacology*, *23*(3), 173–175.
46. Byrd, J. C., Hertler, A. A., Weiss, R. B., Freiman, J., Kweder, S. L., & Diehl, L. F. (1995). Fatal recurrence of autoimmune hemolytic

- anemia following pentostatin therapy in a patient with a history of fludarabine-associated hemolytic anemia. *Annals of Oncology*, 6(3), 300–301.
47. White, D. A., Rankin, J. A., Stover, D. E., Gellene, R. A., & Gupta, S. (1989). Methotrexate pneumonitis. Bronchoalveolar lavage findings suggest an immunological disorder. *The American Review of Respiratory Disease*, 139(1), 18–21.
 48. Lopes, G., Vincek, V., & Racz, L. E. (2006). Pemetrexed-associated urticarial vasculitis. *Lung Cancer*, 51(2), 247–249.
 49. Tummino, C., Barlesi, F., Tchouhadjian, C., Tasei, A. M., Gaudy-Marqueste, C., Richard, M. A., et al. (2007). Severe cutaneous toxicity after pemetrexed as second line treatment for a refractory non small cell lung cancer. [Article in French]. *Revue des Maladies Respiratoires*, 24(5), 635–638.
 50. Dyke, R. W. (1984). Acute bronchospasm after vinca alkaloids in patients previously treated with mitomycin. *The New England Journal of Medicine*, 310(6), 389.
 51. Rivera, M. P., Kris, M. G., Gralla, R. J., & White, D. A. (1995). Syndrome of acute dyspnea related to combined mitomycin plus vinca alkaloid chemotherapy. *American Journal of Clinical Oncology*, 18(3), 245–250.
 52. Imai, C., Uno, K., Kakihara, T., Tanaka, A., & Uchiyama, M. (2001). Vincristine-induced fever in a child with rhabdomyosarcoma: cellular hypersensitivity to vincristine demonstrated by leukocyte migration test. *Journal of Pediatric Hematology/Oncology*, 23(1), 73–74.
 53. Serieix, M. E., Debure, C., Baudot, N., Dubertret, L., Roux, M.-E., Morel, P., et al. (1999). Leg ulcers and hydroxyurea: forty-one cases. *Archives of Dermatology*, 135(7), 818–820.
 54. Sandhu, H. S., Barnes, P. J., & Hernandez, P. (2000). Hydroxyurea-induced hypersensitivity pneumonitis: a case report and literature review. *Canadian Respiratory Journal*, 7(6), 491–495.
 55. Markman, M., Kennedy, A., Webster, K., Elson, P., Peterson, G., Kulp, B., et al. (1999). Clinical features of hypersensitivity reactions to carboplatin. *Journal of Clinical Oncology*, 17(4), 1141–1145.
 56. Randall, J. M., Bharme, A. A., & Bazhenova, L. A. (2012). Hypersensitivity reactions to carboplatin and cisplatin in non-small cell lung cancer. *Journal of Thoracic Disease*. doi:10.3978/j.issn.2072-1439.2012.06.12.
 57. Makrilia, N., Syrigou, E., Kaklamanos, I., Manolopoulos, L., & Wasif Saif, M. (2010). Hypersensitivity reactions associated with platinum antineoplastic agents: a systematic review. *Metal-Based Drugs*, Article ID 207084, 11 pp. doi:10.1155/2010/207084.
 58. Curtis, B. R., Kaliszewski, J., Marques, M. B., Wasif Saif, M., Nabelle, L., Blank, J., et al. (2006). Immune-mediated thrombocytopenia resulting from sensitivity to oxaliplatin. *American Journal of Hematology*, 81(3), 193–198.
 59. Kunkeler, L., Nieboer, C., & Bruynzeel, P. (2000). Type III and type IV hypersensitivity reactions due to mitomycin C. *Contact Dermatitis*, 42(2), 74–76.
 60. Janjigian, Y. Y., Lee, W., Kris, M. G., Miller, V. A., Krug, L. M., Azzoli, C. G., et al. (2010). A phase I trial of SJG-136 (NSC#694501) in advanced solid tumors. *Cancer Chemotherapy and Pharmacology*, 65(5), 833–838.
 61. Puzanov, I., Lee, W., Chen, A. P., Calcutt, M. W., Hachey, D. L., Vermeulen, W. L., et al. (2011). Phase I, pharmacokinetic and pharmacodynamic study of SJG-136, a novel sequence selective minor groove cross-linking agent, in advanced solid tumors. *Clinical Cancer Research*, 17(11), 3794–3802.
 62. Denschlag, D., Watermann, D., Hörig, K., Kissel, C., Tempfer, C., & Gitsch, G. (2004). Topotecan as a continuous infusion over 14 days in recurrent ovarian cancer patients. *AntiCancer Research*, 24(2c), 1267–1269.
 63. Markman, M. (2005). Topotecan as second-line therapy for ovarian cancer: dosage versus toxicity. *The Oncologist*, 10(9), 695–697.
 64. Merrouche, Y., Extra, J. M., Abigeres, D., Bugat, R., Catimel, G., Suc, E., et al. (1997). High dose-intensity of irinotecan administered every three weeks in advanced cancer patients: a feasibility study. *Journal of Clinical Oncology*, 15(3), 1080–1086.
 65. Bozec, L., Bierling, P., Fromont, P., Levi, F., Debat, P., Cvitkovic, E., et al. (1997). Irinotecan-induced immune thrombocytopenia. *Annals of Oncology*, 9(4), 453–455.
 66. Ma, D., & Isbister, J. P. (1980). Cytotoxic-induced fulminant hyperpyrexia. *Cancer*, 45(9), 2249–2251.
 67. Chanan-Khan, A., Szebeni, J., Savay, S., Liebes, L., Rafique, N. M., Alving, C. R., et al. (2003). Complement activation following first exposure to pegylated liposomal doxorubicin (Doxil): possible role in hypersensitivity reactions. *Annals of Oncology*, 14(9), 1430–1437.
 68. Taylor, W. B., Cantwell, B. M., Roberts, J. T., & Harris, A. L. (1986). Allergic reactions to mitoxantrone. *Lancet*, 1(8495), 1439.
 69. Coppes, M. J., Jorgenson, K., & Arlette, J. P. (1997). Cutaneous toxicity following the administration of dactinomycin. *Medical and Pediatric Oncology*, 29(3), 226–227.
 70. Tomesello, A., Piciacchia, D., Mastrangelo, S., Lasorella, A., & Mastrangelo, R. (1998). Venous-occlusive disease of the liver in right-sided Wilms' tumours. *European Journal of Cancer*, 34(8), 1220–1223.
 71. Capelli, C., Fornari, C., De Ioris, M. A., Russo, D., & Cierico, A. (2001). An exceptional case of hypersensitivity to actinomycin D. Case report and review of the literature. [Article in Italian]. *La Clinica Terapeutica*, 152(5), 319–321.
 72. Yamamoto, T. (2006). Bleomycin and the skin. *British Journal of Dermatology*, 155, 869–875.
 73. Kaminskis, E., Farrell, A. T., Wang, Y. C., Sridhara, R., & Pazdur, R. (2005). FDA drug approval summary: azacitidine (5-azacytidine, Vidaza) for injectable suspension. *The Oncologist*, 10(3), 176–182.
 74. Garcia-Manero, G., Gore, S. D., Cogle, C., Ward, R., Shi, T., Macbeth, K. J., et al. (2011). Phase I study of oral azacitidine in myelodysplastic syndromes, chronic myelomonocytic leukemia, and acute myeloid leukemia. *Journal of Clinical Oncology*, 29(18), 2521–2527.
 75. Giaccone, G., Rajan, A., Kelly, R. J., Gutierrez, M., Kummur, S., Yancey, M., et al. (2010). A phase I combination study of olaparib (AZD2281; KU-0059436) and cisplatin (C) plus gemcitabine (G) in adults with solid tumors. *Journal of Clinical Oncology*, 28(Suppl 15), 3027.
 76. Kummur, S., Chen, A., Ji, J., Zhang, Y., Reid, J. M., Ames, M., et al. (2011). Phase I study of ABT-888, a PARP inhibitor, in combination with topotecan hydrochloride in adults with refractory solid tumors and lymphomas. *Cancer Research*, 71(17), 5626–5634.
 77. Lerch, E., Györik, S., Feilchenfeldt, J., Mazzucchelli, L., & Quadri, F. (2010). A case of lenalidomide-induced hypersensitivity pneumonitis. *Onkologie*, 33(5), 249–252.
 78. Bosulif®. FDA: full prescribing information. Adverse reactions. http://www.accessdata.fda.gov/drugsatfda_docs/label/2012/203341lbl.pdf. Accessed 1 July 2013.
 79. Gambacorti-Passerini, C., Cortes, J. E., Kim, D., Kantarjian, H., Khattry, N., Lipton, J. H., et al. (2011). Bosutinib (BOS) versus imatinib (IM) in patients (pts) with chronic phase chronic myeloid leukemia (CP CML) in the BELA trial: 18-month follow-up. *Journal of Clinical Oncology*, 29, abstr 6509.
 80. Xalkori®. FDA: full prescribing information. Adverse reactions. http://www.accessdata.fda.gov/drugsatfda_docs/label/2012/202570s002lbl.pdf. Accessed 1 July 2013.
 81. Bang, Y. J. (2012). Treatment of ALK-positive non-small cell lung cancer. *Archives of Pathology and Laboratory Medicine*, 136(10), 1201–1204.
 82. Sprycel®. FDA: full prescribing information. Adverse reactions. http://www.accessdata.fda.gov/drugsatfda_docs/label/2010/021986s7s8lbl.pdf. Accessed 1 July 2013.

83. Montani, D., Bergot, E., Günther, S., Savale, L., Bergeron, A., Bourdin, A., et al. (2012). Pulmonary arterial hypertension in patients treated by dasatinib. *Circulation*, *125*(17), 2128–2137.
84. Gleevec®. FDA: full prescribing information. Adverse reactions. http://www.accessdata.fda.gov/drugsatfda_docs/label/2012/021588s035lbl.pdf. Accessed 1 July 2013.
85. Kantarjian, H., Sawyers, C., Hochhaus, A., Guilhot, F., Schiffer, C., Gambacorti-Passerini, C., et al. (2002). Hematologic and cytogenetic responses to imatinib mesylate in chronic myelogenous leukemia. *The New England Journal of Medicine*, *346*(9), 645–652.
86. Kuraishi, N., Nagai, Y., Hasegawa, M., & Ishikawa, O. (2010). Lichenoid drug eruption with palmpoplantar hyperkeratosis due to imatinib mesylate: a case report and a review of the literature. *Acta Dermatologica Venereologica*, *90*(1), 73–76.
87. Tasigna®. FDA: full prescribing information. Adverse reactions. http://www.accessdata.fda.gov/drugsatfda_docs/label/2010/022068s004s005lbl.pdf. Accessed 1 July 2013.
88. Iclusig®. FDA: full prescribing information. Adverse reactions. http://www.accessdata.fda.gov/drugsatfda_docs/label/2012/203469lbl.pdf. Accessed 1 July 2013.
89. Tarceva®. FDA: full prescribing information. Adverse reactions. http://www.accessdata.fda.gov/drugsatfda_docs/label/2010/021743s14s16lbl.pdf. Accessed 1 July 2013.
90. Heidary, N., Naik, H., & Burgin, S. (2008). Chemotherapeutic agents and the skin: an update. *Journal of the American Academy of Dermatology*, *58*(4), 545–570.
91. Iressa®. FDA: full prescribing information. Adverse reactions. http://www.accessdata.fda.gov/drugsatfda_docs/label/2005/021399s008lbl.pdf. Accessed 1 July 2013.
92. Tykerb®. FDA: full prescribing information. Adverse reactions. http://www.accessdata.fda.gov/drugsatfda_docs/label/2010/022059s007lbl.pdf. Accessed 13 July 2013.
93. Votrient®. FDA: full prescribing information. Adverse reactions. http://www.accessdata.fda.gov/drugsatfda_docs/label/2012/022465s-010S-012lbl.pdf. Accessed 13 July 2013.
94. Stivarga®. FDA: full prescribing information. Adverse reactions. http://www.accessdata.fda.gov/drugsatfda_docs/label/2012/203085lbl.pdf. Accessed 13 July 2013.
95. Grothey, A., Van Cutsem, E., Sobrero, A., Siena, S., Falcone, A., Ychou, M., et al. (2013). Regorafenib monotherapy for previously treated metastatic colorectal cancer (CORRECT): an international, multicentre, randomised, placebo-controlled, phase 3 trial. *Lancet*, *381*(9863), 303–312.
96. Arora, A., & Scholar, E. M. (2005). Role of tyrosine kinase inhibitors in cancer therapy. *The Journal of Pharmacology and Experimental Therapeutics*, *315*(3), 971–979.
97. Nexavar®. FDA: full prescribing information. Adverse reactions. http://www.accessdata.fda.gov/drugsatfda_docs/label/2010/021923s008s009lbl.pdf. Accessed 13 July 2013.
98. Kamba, T., & McDonald, D. M. (2007). Mechanisms of adverse effects of anti-VEGF therapy for cancer. *British Journal of Cancer*, *96*(12), 1788–1795.
99. Lee, W. J., Lee, J. L., Chang, S. E., Lee, M. W., Kang, Y. K., Choi, J. H., et al. (2009). Cutaneous adverse effects in patients treated with the multitargeted kinase inhibitors sorafenib and sunitinib. *British Journal of Dermatology*, *161*(5), 1045–1051.
100. Sutent®. FDA: full prescribing information. Adverse reactions. http://www.accessdata.fda.gov/drugsatfda_docs/label/2011/021938s13s17s18lbl.pdf. Accessed 15 July 2013.
101. Vandetanib. FDA: full prescribing information. Warnings and precautions; adverse reactions. http://www.accessdata.fda.gov/drugsatfda_docs/label/2011/022405s000lbl.pdf. Accessed 15 July 2013.
102. Afinitor®. FDA: full prescribing information. Adverse reactions. http://www.accessdata.fda.gov/drugsatfda_docs/label/2012/022334s016lbl.pdf. Accessed 15 July 2013.
103. Torisel®. FDA: full prescribing information. Adverse reactions. http://www.accessdata.fda.gov/drugsatfda_docs/label/2011/022088s002s004s005s007s010s012lbl.pdf. Accessed 15 July 2013.
104. Istodax®. FDA: full prescribing information. Adverse reactions. http://www.accessdata.fda.gov/drugsatfda_docs/label/2009/022393lbl.pdf. Accessed 15 July 2013.
105. Zolanza®. FDA: full prescribing information. Adverse reactions. http://www.accessdata.fda.gov/drugsatfda_docs/label/2011/021991s002lbl.pdf. Accessed 15 July 2013.
106. Tan, J., Cang, S., Ma, Y., Petrillo, R. L., & Liu, D. (2010). Novel histone deacetylase inhibitors in clinical trials as anti-cancer agents. *Journal of Hematology and Oncology*, *3*, 5.
107. Vesanoid®. FDA: full prescribing information. Adverse reactions. http://www.accessdata.fda.gov/drugsatfda_docs/label/2004/20438s004lbl.pdf. Accessed 15 July 2013.
108. Trisenox®. FDA: full prescribing information. Adverse reactions. http://www.accessdata.fda.gov/drugsatfda_docs/label/2000/21248lbl.pdf. Accessed 19 July 2013.
109. Targretin®. FDA: full prescribing information. Adverse reactions. http://www.accessdata.fda.gov/drugsatfda_docs/label/2011/021055s006lbl.pdf. Accessed 19 July 2013.
110. Velcade®. FDA: full prescribing information. Adverse reactions. http://www.accessdata.fda.gov/drugsatfda_docs/label/2012/021602s027lbl.pdf. Accessed 30 June 2013.
111. Wu, K. L., Heule, F., Lam, K., & Sonneveld, P. (2006). Pleomorphic presentation of cutaneous lesions associated with the proteasome inhibitor bortezomib in patients with multiple myeloma. *Journal of the American Academy of Dermatology*, *55*(5), 897–900.
112. Thomas, M., Cavelier Balloy, B., Andreoli, A., Briere, J., & Petit, A. (2009). Bortezomib-induced neutrophilic dermatosis with CD30+ lymphocytic infiltration. [Article in French]. *Annales de Dermatologie et de Vénérologie*, *136*(5), 438–442.
113. Kyprolis®. FDA: full prescribing information. Adverse reactions. http://www.accessdata.fda.gov/drugsatfda_docs/label/2012/202714lbl.pdf. Accessed 20 July 2013.
114. Arimidex®. FDA: full prescribing information. Adverse reactions. http://www.accessdata.fda.gov/drugsatfda_docs/label/2011/020541s026lbl.pdf. Accessed 2 July 2013.
115. Shoda, H., Inokuma, S., Yajima, N., Tanaka, Y., & Setoguchi, K. (2005). Cutaneous vasculitis developed in a patient with breast cancer undergoing aromatase inhibition treatment. *Annals of the Rheumatic Diseases*, *64*(4), 651–652.
116. Brevec, T., Demšar, J., Luzar, B., & Pavlović, M. D. (2009). Drug-induced pruritic micropapular eruption: anastrozole, a commonly used aromatase inhibitor. *Dermatology Online Journal*, *15*(7), 14–16.
117. Santoro, S., Santini, M., Pepe, C., Tognetti, E., Cortelazzi, C., Ficarelli, E., et al. (2011). Aromatase inhibitor-induced skin adverse reactions: exemestane-related cutaneous vasculitis. *Journal of the European Academy of Dermatology and Venereology*, *25*(5), 596–598.
118. Aromasin®. FDA: full prescribing information. Adverse reactions. http://www.accessdata.fda.gov/drugsatfda_docs/label/2011/020753s009s011s012lbl.pdf. Accessed 1 July 2013.
119. Gupta, M., Vasudev, M., Thumma, S., Marks, S., Wang, Y., Blust, L., et al. (2004). Acute generalized exanthematous pustulosis (AGEP) with aromatase inhibitor (exemestane). *Journal of Allergy and Clinical Immunology*, *113*(2), S313.
120. Femara®. FDA: full prescribing information. Adverse reactions. http://www.accessdata.fda.gov/drugsatfda_docs/label/2007/020726s014lbl.pdf. Accessed 1 July 2013.
121. Zoladex®. FDA: full prescribing information. Adverse reactions. http://www.accessdata.fda.gov/drugsatfda_docs/label/2011/019726s054,020578s032lbl.pdf. Accessed 1 July 2013.
122. Lupron Depot®. FDA: full prescribing information. Adverse reactions. http://www.accessdata.fda.gov/drugsatfda_docs/label/2012/020011s040lbl.pdf. Accessed 1 July 2013.

123. Shiota, M., Tokuda, N., Kanou, T., & Yamasaki, H. (2007). Incidence rate of injection-site granulomas resulting from administration of luteinizing hormone-releasing hormone analogues for the treatment of prostatic cancer. *Yonsei Medical Journal*, *48*(3), 421–424.
124. Nolvadex[®]. FDA: full prescribing information. Adverse reactions. http://www.accessdata.fda.gov/drugsatfda_docs/label/2005/17970s0531bl.pdf. Accessed 1 July 2013.
125. Baptista, M. Z., Prieto, V. G., Chon, S., Hortobagyi, G. N., & Esteva, F. J. (2006). Tamoxifen-related vasculitis. *Journal of Clinical Oncology*, *24*(21), 3504–3505.
126. Casodex[®]. FDA: full prescribing information. Adverse reactions. http://www.accessdata.fda.gov/drugsatfda_docs/label/2009/020498s019s0211bl.pdf. Accessed 2 July 2013.
127. Folutyn[®]. FDA: full prescribing information. Adverse reactions. http://www.accessdata.fda.gov/drugsatfda_docs/label/2011/022468s003s004s0051bl.pdf. Accessed 2 July 2013.
128. Ontak[®]. FDA: full prescribing information. Adverse reactions. http://www.accessdata.fda.gov/drugsatfda_docs/label/2008/103767s50941bl.pdf. Accessed 2 July 2013.
129. Foss, F. M., Bacha, P., Osann, K. E., Demierre, M. F., Bell, T., & Kuzel, T. (2001). Biological correlates of acute hypersensitivity events with DAB₃₈₉IL-2 (denileukin diftitox, Ontak[®]) in cutaneous T-cell lymphoma: decreased frequency and severity with steroid premedication. *Clinical Lymphoma*, *1*(4), 298–302.
130. Polder, K., Wang, C., Duvic, M., Diwan, A. H., Parks, D., Jankov, A., et al. (2005). Toxic epidermal necrolysis associated with denileukin diftitox (DAB389IL-2) administration in a patient with follicular large cell lymphoma. *Leukemia and Lymphoma*, *46*(12), 1807–1811.
131. Zaltrap[®]. FDA: full prescribing information. Adverse reactions. http://www.accessdata.fda.gov/drugsatfda_docs/label/2012/125418s0001bl.pdf. Accessed 2 July 2013.
132. Hartley, J. A. (2011). The development of pyrrolbenzodiazepines as antitumor agents. *Expert Opinion on Investigational Drugs*, *20*(6), 733–744.
133. Murai, J., Huang, S.-Y. N., Das, B. B., Renaud, A., Zhang, Y., Doroshow, J. H., et al. (2012). Trapping of PARP1 and PARP2 by clinical PARP inhibitors. *Cancer Research*, *72*(21), 5588–5599.
134. Davies, F., & Baz, R. (2010). Lenalidomide mode of action: linking bench and clinical findings. *Blood Reviews*, *24*(Suppl 1), S13–S19.
135. Ward, H. W. C. (1973). Anti-oestrogen therapy for breast cancer: a trial of tamoxifen at two dose levels. *British Medical Journal*, *1*(5844), 13–14.
136. Deeks, E. D., & Scott, L. J. (2009). Exemestane. *Drugs*, *69*(7), 889–918.
137. Kotake, T., Usami, M., Akaza, H., Koiso, K., Homma, Y., Kawabe, K., et al. (1999). Goserelin acetate with or without antiandrogen or oestrogens in the treatment of patients with advanced prostate cancer: a multicenter, randomized, controlled trial in Japan. Zoladex study group. *Japanese Journal of Clinical Oncology*, *29*(11), 562–570.
138. Fradet, Y. (2004). Bicalutamide (Casodex) in the treatment of prostate cancer. *Expert Review of Anticancer Therapy*, *4*(1), 37–48.
139. Weinstein, I. B., & Joe, A. K. (2006). Mechanisms of disease: oncogene addiction—a rationale for molecular targeting in cancer therapy. *Nature Clinical Practice Oncology*, *3*(8), 448–457.
140. Druker, B. J. (2008). Translation of the Philadelphia chromosome into therapy for CML. *Blood*, *112*(13), 4808–4817.
141. Yuan, R. R., Kay, A., Berg, W. J., & Leubwohl, D. (2009). Targeting tumorigenesis: development and use of mTOR inhibitors in cancer therapy. *Journal of Hematology and Oncology*, *2*, 45–56.
142. Acharya, M. R., Sparreboom, A., Venitz, J., & Figg, W. D. (2005). Rational development of histone deacetylase inhibitors as anticancer agents: a review. *Molecular Pharmacology*, *68*(4), 917–932.
143. Zhang, X. W., Yan, X. J., Zhou, Z. R., Yang, F. F., Wu, Z. Y., Sun, H. B., et al. (2010). Arsenic trioxide controls the fate of the PML-RAR α oncoprotein by directly binding PML. *Science*, *328*(5975), 240–243.
144. Gniadecki, R., Assaf, C., Bagot, M., Dummer, R., Duvic, M., Knobler, R., et al. (2007). The optimal use of bexarotene in cutaneous T-cell lymphoma. *British Journal of Dermatology*, *157*(3), 433–440.
145. Zain, J., & O'Connor, O. (2010). Pralatrexate: basic understanding and clinical development. *Expert Opinion on Pharmacotherapy*, *11*(10), 1705–1714.
146. Turturro, F. (2007). Denileukin diftitox: a biotherapeutic paradigm shift in the treatment of lymphoid-derived disorders. *Expert Review of Anticancer Therapy*, *7*(1), 11–17.
147. Lockhart, A. C., Rothenberg, M. L., Dupont, J., Cooper, W., Chevalier, P., Sternas, L., et al. (2010). Phase I study of intravenous vascular endothelial growth factor trap, aflibercept, in patients with advanced solid tumors. *Journal of Clinical Oncology*, *28*(2), 207–214.
148. Tarhini, A., Frankel, P., Margolin, K. A., Chrstensen, S., Ruel, C., Shipe-Spotloe, J., et al. (2011). Aflibercept (VEGF trap) in inoperable stage III or stage IV melanoma of cutaneous or uveal origin. *Clinical Cancer Research*, *17*(20), 6574–6581.
149. Zhao, M., & Vuori, K. (2011). The docking protein p130Cas regulates cell sensitivity to proteasome inhibition. *BMC Biology*, *9*, 73.
150. Kisselev, A. F., van der Linden, W. A., & Overkleeft, H. S. (2012). Proteasome inhibitors: an expanding army attacking a unique target. *Chemistry and Biology*, *19*(1), 99–115.
151. Degan, A., Alter, M., Schenck, F., Satzger, I., Völker, B., Kapp, A., et al. (2010). The hand-foot-syndrome associated with medical tumor therapy—classification and management. *Journal der Deutschen Dermatologischen Gesellschaft*, *8*(9), 652–661.
152. Balagula, Y., Lacouture, M. E., & Cotliar, J. A. (2010). Dermatologic toxicities of targeted anticancer therapies. *The Journal of Supportive Oncology*, *8*(4), 149–161.
153. Son, H.-S., Lee, W. Y., Lee, W.-S., Yun, S. H., & Chun, H.-K. (2009). Compliance and effective management of the hand-foot syndrome in colon cancer patients receiving capecitabine as adjuvant chemotherapy. *Yonsei Medical Journal*, *50*(6), 796–802.
154. Gerber, P. A., Meller, S., Eames, T., Buhren, B. A., Schrupf, H., Hetzer, S., et al. (2012). Management of EGFR-inhibitor associated rash: a retrospective study in 49 patients. *European Journal of Medical Research*, *17*, 4. doi:10.1186/2047-783X-17-4.
155. Lynch, T. J., Kim, E. S., Eaby, B., Garey, J., West, D. P., & Lacouture, M. E. (2007). Epidermal growth factor receptor inhibitor-associated cutaneous toxicities: an evolving paradigm in clinical management. *The Oncologist*, *12*(5), 610–621.
156. Utrecht, J. (2007). Idiosyncratic drug reactions: current understanding. *Annual Review of Pharmacology and Toxicology*, *47*, 513–539.
157. Diehl, L. F., & Ketchum, L. H. (1998). Autoimmune disease and chronic lymphocytic leukemia: autoimmune hemolytic anemia, pure red cell aplasia, and autoimmune thrombocytopenia. *Seminars in Oncology*, *25*(1), 80–97.
158. Fisher, M. M., & Baldo, B. A. (1988). Acute anaphylactic reactions. *Medical Journal of Australia*, *149*(1), 34–38.
159. Fisher, M. M., & Baldo, B. A. (1994). Anaphylaxis during anaesthesia: current aspects of diagnosis and prevention. *European Journal of Anaesthesiology*, *11*(4), 263–284.
160. Fisher, M. M., Harle, D. G., & Baldo, B. A. (1991). Anaphylactoid reactions to narcotic analgesics. *Clinical Reviews in Allergy and Immunology*, *9*(3–4), 309–318.
161. Mertes, P. M., Laxenaire, M. C., & Alla, F. (2003). Anaphylactic and anaphylactoid reactions occurring during anaesthesia in France in 1999–2000. *Anesthesiology*, *99*(3), 536–545.
162. Fisher, M. M., Ramakrishnan, N., Doig, G., Rose, M., & Baldo, B. (2009). The investigation of bronchospasm during induction of anaesthesia. *Acta Anaesthesiologica Scandinavica*, *53*(8), 1006–1011.

163. Baldo, B. A., & Pham, N. H. (2012). Histamine-releasing and allergenic properties of opioid analgesic drugs: resolving the two. *Anaesthesia and Intensive Care*, *40*(2), 216–235.
164. Garufi, C., Cristaudo, A., Vanni, B., Bria, E., Aschelter, A. M., Santucci, B., et al. (2003). Skin testing and hypersensitivity reactions to oxaliplatin. *Annals of Oncology*, *14*(3), 497–498.
165. Pagani, M., Bonadonna, P., Senna, G. E., & Antico, A. (2008). Standardisation of skin tests for diagnosis and prevention of hypersensitivity reactions to oxaliplatin. *International Archives of Allergy and Immunology*, *145*(1), 54–57.
166. Castells, M. C., Tennant, N. M., Sloane, D. E., Hsu, F. I., Barrett, N. A., Hong, D. I., et al. (2008). Hypersensitivity reactions to chemotherapy: outcomes and safety of rapid desensitization in 413 cases. *Journal of Allergy and Clinical Immunology*, *122*(3), 574–580.
167. Khan, A., & Hill, J. M. (1971). Atopic hypersensitivity to L-asparaginase: resistance to immunosuppression. *International Archives of Allergy and Applied Immunology*, *40*(3), 463–469.
168. Fabry, U., Körholz, D., Jurgens, H., Göbel, U., & Wahn, V. (1985). Anaphylaxis to L-asparaginase during treatment for acute lymphoblastic leukemia in children—evidence of a complement-mediated mechanism. *Pediatric Research*, *19*(4), 400–408.
169. Baldo, B. A. (1990). Immunochemical perspectives of allergy: in the steps of Karl Landsteiner. In B. A. Baldo (Ed.), *Monographs in allergy 28. Molecular approaches to the study of allergens* (pp. 1–10). Basel: Karger.
170. Baldo, B. A., & Pham, N. H. (2013). *Drug allergy: Clinical aspects, diagnosis, mechanisms, structure–activity relationships*. New York: Springer.
171. Aster, R. H., & Bougie, D. W. (2007). Drug-induced immune thrombocytopenia. *The New England Journal of Medicine*, *357*(6), 580–587.
172. Kenney, B., & Stack, G. (2009). Drug-induced thrombocytopenia. *Archives of Pathology and Laboratory Medicine*, *133*(2), 309–314.
173. Wu, Y., Aravind, S., Ranganathan, G., Martin, A., & Nalysnyk, L. (2009). Anemia and thrombocytopenia in patients undergoing chemotherapy for solid tumors: a descriptive study of a large outpatient oncology practice database, 2000–2007. *Clinical Therapeutics*, *31*(pt 2), 2416–2432.
174. Ten Berg, M. J., van den Bemt, P. M., Shantakumar, S., Bennett, D., Voest, E. E., Huisman, A., et al. (2011). Thrombocytopenia in adult cancer patients receiving chemotherapy: results from a retrospective hospital-based cohort study. *Drug Safety*, *34*(12), 1151–1160.
175. Parikh, O., Neave, F., & Palmieri, C. (2008). Severe thrombocytopenia induced by a single infusion of trastuzumab. *Clinical Breast Cancer*, *8*(3), 285–286.
176. Bautista, M. A., Stevens, W. T., Chen, C.-S., Curtis, B. R., Aster, R. H., & Hsueh, C.-T. (2010). Hypersensitivity reaction and acute immune-mediated thrombocytopenia from oxaliplatin: two case reports and a review of the literature. *Journal of Hematology and Oncology*, *3*, 12.
177. Leach, M., Parsons, R. M., Reilly, J. T., & Winfield, D. A. (2000). Autoimmune thrombocytopenia: a complication of fludarabine therapy in lymphoproliferative disorders. *Clinical & Laboratory Haematology*, *22*(3), 175–178.
178. Khatua, S., Nair, C. N., & Ghosh, K. (2004). Immune-mediated thrombocytopenia following dactinomycin therapy in a child with alveolar rhabdomyosarcoma: the unresolved issues. *Journal of Pediatric Hematology/Oncology*, *26*(11), 777–779.
179. Mueller-Eckhardt, C., Kuenzlen, E., Kiefel, V., Vahrson, H., & Graubner, M. (1983). Cyclophosphamide-induced immune thrombocytopenia in a patient with ovarian carcinoma successfully treated with intravenous gamma globulin. *Blut*, *46*(3), 165–169.
180. Seidman, A. D., Schwartz, M., Reich, L., & Scher, H. I. (1993). Immune-mediated thrombocytopenia secondary to suramin. *Cancer*, *71*(3), 851–854.
181. Earle, C. C., Chen, W. Y., Ryan, D. P., & Mayer, R. J. (2001). Oxaliplatin-induced Evans syndrome. *British Journal of Cancer*, *84*(3), 441.
182. Sørbye, H., Bruserud, Ø., & Dahl, O. (2001). Oxaliplatin-induced haematological emergency with an immediate severe thrombocytopenia and haemolysis. *Acta Oncologica*, *40*(7), 882–883.
183. Overman, M. J., Maru, D. M., Charnsangavej, C., Loyer, E. M., Wang, H., Pathak, P., et al. (2010). Oxaliplatin-mediated increase in spleen size as a biomarker for the development of hepatic sinusoidal injury. *Journal of Clinical Oncology*, *28*(15), 2549–2555.
184. Schouten, H. C. (2006). Neutropenia management. *Annals of Oncology*, *17*(Suppl 10), 85–89.
185. Bhatt, V., & Saleem, A. (2004). Drug-induced neutropenia—pathophysiology, clinical features, and management. *Annals of Clinical and Laboratory Science*, *34*(2), 131–137.
186. Berliner, N., Horwitz, M., & Loughran, T. P., Jr. (2004). Congenital and acquired neutropenia. *Hematology American Society of Hematology Education Program*, *1*, 63–79.
187. Salama, A., Schütz, B., Kiefel, V., Breithaupt, H., & Mueller-Eckhardt, C. (1989). Immune-mediated agranulocytosis related to drugs and their metabolites: mode of sensitization and heterogeneity of antibodies. *British Journal of Haematology*, *72*(2), 127–132.
188. Crawford, J., Dale, D. C., & Lyman, G. H. (2004). Chemotherapy-induced neutropenia. Risks, consequences, and new directions for its management. *Cancer*, *100*(2), 228–237.
189. Garratty, G. (2009). Drug-induced immune hemolytic anemia. *Hematology American Society of Hematology Education Program*, *2009*, 73–79.
190. Weiss, R. B., Freiman, J., Kweder, S. L., Diehl, L. F., & Byrd, J. C. (1998). Hemolytic anemia after fludarabine therapy for chronic lymphocytic leukemia. *Journal of Clinical Oncology*, *16*(5), 1885–1889.
191. Gonzalez, H., Leblond, V., Azar, N., Sutton, L., Gabarre, J., Binet, J. L., et al. (1998). Severe autoimmune hemolytic anemia in eight patients treated with fludarabine. *Hematology and Cell Therapy*, *40*(3), 113–118.
192. Tetreault, S. A., & Saven, A. (2000). Delayed onset of autoimmune hemolytic anemia complicating cladribine therapy for Waldenström macroglobulinemia. *Leukemia and Lymphoma*, *37*(1–2), 125–130.
193. Getaz, E. P., Beckley, S., Fitzpatrick, J., & Dozier, A. (1980). Cisplatin-induced hemolysis. *The New England Journal of Medicine*, *302*(6), 334–335.
194. Maloisel, F., Kurtz, J. E., Andres, E., Gorodetsky, C., Dufour, P., & Oberling, F. (1995). Platin salts-induced hemolytic anemia: cisplatin and the first case of carboplatin-induced hemolysis. *Anti-Cancer Drugs*, *6*(2), 324–326.
195. Marani, T. M., Trich, M. B., Armstrong, K. S., Ness, P. M., Smith, J., & Minniti, C. (1996). Carboplatin-induced immune hemolytic anemia. *Transfusion*, *36*(11–12), 1016–1018.
196. Garufi, C., Vaglio, S., Brienza, S., Conti, L., D’Attino, R. M., Girelli, G., et al. (2000). Immuno-hemolytic anemia following oxaliplatin administration. *Annals of Oncology*, *11*(4), 497.
197. Bastuji-Garin, S., Joly, P., Picard-Dahan, C., Bernard, P., Vaillant, L., Pauweis, C., et al. (1996). Drugs associated with bullous pemphigoid. A case-control study. *Archives of Dermatology*, *132*(3), 272–276.
198. Carlson, J., Ng, B., & Chen, K. (2005). Cutaneous vasculitis update: diagnostic criteria, classification, epidemiology, etiology, pathogenesis, evaluation and prognosis. *The American Journal of Dermatopathology*, *27*(6), 504–528.
199. Choi, H. K., Merkel, P. A., Walker, A. M., & Niles, J. L. (2000). Drug-associated antineutrophil cytoplasmic antibody-positive vasculitis: prevalence among patients with high titers of antimyeloperoxidase antibodies. *Arthritis & Rheumatism*, *43*(2), 405–413.
200. Wong, M., Grossman, J., Hahn, B. H., & La Cava, A. (2008). Cutaneous vasculitis in breast cancer treated with chemotherapy. *Clinical Immunology*, *129*(1), 3–9.

201. Drago, F., Arditi, M., & Rebora, A. (1990). Tamoxifen and purpuric vasculitis. *Annals of Internal Medicine*, *112*(12), 965–966.
202. Takahashi, Y., Ebi, N., Yamaguchi, O., Fukusho, R., Sugimoto, Y., & Tsuruno, K. (2011). A case of cutaneous vasculitis caused by erlotinib treatment and a review of literature. [Article in Japanese]. *Nihon Kokyūki Gakkai Zasshi*, *49*(9), 663–666.
203. Green, R. M., Schapel, G. J., & Sage, R. E. (1989). Cutaneous vasculitis due to cyclophosphamide therapy for chronic lymphocytic leukemia. *Australian & New Zealand Journal of Medicine*, *19*(1), 55–57.
204. Cabuk, M., Inanir, I., Türkdoğan, P., Ceylan, C., Değirmenci, M., Türel, A., et al. (2004). Cyclic lymphocytic vasculitis associated with chronic lymphocytic leukemia. *Leukemia and Lymphoma*, *45*(4), 811–813.
205. Cohen, P., & Kurzrock, R. (1997). Mucocutaneous paraneoplastic syndromes. *Seminars in Oncology*, *24*(3), 334–359.
206. Liu, A., Fanning, L., Chong, H., Fernandez, J., Sloane, D., Sancho-Serra, M., et al. (2011). Desensitization regimens for drug allergy: state of the art in the 21st century. *Clinical & Experimental Allergy*, *41*(12), 1679–1689.
207. Santini, D., Tonini, G., Salerno, A., Vincenzi, B., Patti, G., Battistoni, F., et al. (2001). Idiosyncratic reaction after oxaliplatin infusion. *Annals of Oncology*, *12*(1), 132–133.
208. Castleberry, R. P., Crist, W. M., Holbrook, T., Malluh, A., & Gaddy, D. (1981). The cytosine arabinoside (Ara-C) syndrome. *Medical and Pediatric Oncology*, *9*(3), 257–264.
209. Apisamthanarax, N., & Duvic, M. (2000). Dermatologic complications of cancer chemotherapy. In R. C. Jr Bast, D. W. Kufe, R. E. Pollock, et al. (Eds.), *Holland–Frei cancer medicine* (5th ed., pp. 2271–2278). Hamilton: Decker.
210. Gonçalves, M., & Bruynzeel, D. P. (2008). Mechanisms in cutaneous drug hypersensitivity reactions. In H. Zhai, K.-P. Wilhelm, & H. I. Maibach (Eds.), *Marzulli and Maibach's dermatotoxicology* (7th ed., pp. 259–268). Boca Raton: CRC.
211. Susser, W. S., Whitaker-Worth, D. L., & Grant-Kels, J. M. (1999). Mucocutaneous reactions to chemotherapy. *Journal of the American Academy of Dermatology*, *40*(3), 367–398.
212. Ailor, S. K., & Miles, S. C. (2008). Dermatologic toxicity. In M. C. Perry (Ed.), *The chemotherapy sourcebook* (4th ed., pp. 136–147). Philadelphia: Lippincott Williams & Wilkins.
213. Horn, T. D., Redd, J. V., Karp, J. E., Beschoner, W. E., Burke, P. J., & Hood, A. F. (1989). Cutaneous eruptions of lymphocyte recovery. *Archives of Dermatology*, *125*(11), 1512–1517.
214. Johnson, T., Rapini, R., & Duvic, M. (1987). Inflammation of actinic keratosis from systemic chemotherapy. *Journal of the American Academy of Dermatology*, *17*(2, pt 1), 192–197.
215. Harrist, T. J., Fine, J. D., Berman, R. S., Murphy, G. F., & Mihm, M. C., Jr. (1982). Neutrophilic eccrine hidradenitis. A distinctive type of neutrophilic dermatosis associated with myelogenous leukemia and chemotherapy. *Archives of Dermatology*, *118*(4), 263–266.
216. Brehler, R., Reimann, S., Bonsmann, G., & Metze, D. (1997). Neutrophilic hidradenitis induced by chemotherapy involves eccrine and apocrine glands. *The American Journal of Dermatopathology*, *19*(1), 73–78.
217. Kaplowitz, N. (2005). Idiosyncratic drug hepatotoxicity. *Nature Reviews Drug Discovery*, *4*(6), 489–499.
218. Friis, H., & Andreasen, P. B. (1992). Drug-induced hepatic injury: an analysis of 1100 cases reported to the Danish Committee on Adverse Drug Reactions between 1978 and 1987. *Journal of Internal Medicine*, *232*(2), 133–138.
219. Ramachandran, R., & Kakar, S. (2009). Histological patterns in drug-induced liver disease. *Journal of Clinical Pathology*, *62*(6), 481–492.
220. Ju, C. (2005). Immunological mechanisms of drug-induced liver injury. *Current Opinion in Drug Discovery & Development*, *8*(1), 38–43.
221. Castell, J. V., & Castell, M. (2006). Allergic hepatitis induced by drugs. *Current Opinion in Allergy and Clinical Immunology*, *6*(4), 258–265.
222. Adams, D. H., Ju, C., Ramaiah, S. K., Uetrecht, J., & Jaeschke, H. (2010). Mechanisms of immune-mediated liver injury. *Toxicological Sciences*, *115*(2), 307–321.
223. Saleh, F., Ko, H. H., Davis, J. E., Apiratpracha, W., Powell, J. J., Erb, S. R., et al. (2007). Fatal hepatitis C associated fibrosing cholestatic hepatitis as a complication of cyclophosphamide and corticosteroid treatment of active glomerulonephritis. *Annals of Hepatology*, *6*(3), 186–189.
224. Ellis, S. J., Cleverley, J. R., & Müller, N. L. (2000). Drug-induced lung disease: high-resolution CT findings. *American Journal of Roentgenology*, *175*(4), 1019–1024.
225. Wong, P., Leung, A. N., Berry, G. J., Atkins, K. A., Montoya, J. G., Ruoss, S. J., et al. (2001). Paclitaxel-induced hypersensitivity pneumonitis: radiographic and CT findings. *American Journal of Roentgenology*, *176*(3), 718–720.
226. Agache, I. O., & Rogozea, L. (2013). Management of hypersensitivity pneumonitis. *Clinical and Translational Allergy*, *3*, 5. doi:10.1186/2045-7022-3-5.
227. Epler, G. (2011). Bronchiolitis obliterans organizing pneumonia (BOOP), 25 years: a variety of causes but what are the treatment options? *Expert Review of Respiratory Medicine*, *5*(3), 353–361.
228. Schwaiblmair, M., Behr, W., Haackel, T., Märkl, B., Foerg, W., & Berghaus, T. (2012). Drug-induced interstitial lung disease. *The Open Respiratory Medicine Journal*, *6*, 63–74.
229. Etienne, B., Pérol, M., Nesme, P., Vuillermoz, S., Robinet, G., & Guérin, J. C. (1998). Acute diffuse interstitial pneumopathy following docetaxel (Taxotère). Apropos of 2 cases. [Article in French]. *Revue des Maladies Respiratoires*, *15*(2), 199–203.
230. Limper, A. H. (2004). Chemotherapy-induced lung disease. *Clinics in Chest Medicine*, *25*(1), 53–64.
231. Kressel, B. R., Ryan, K. P., Duong, A. T., Berenberg, J., & Schein, P. S. (1981). Microangiopathic hemolytic anemia, thrombocytopenia and renal failure in patients treated for adenocarcinoma. *Cancer*, *48*(8), 1738–1745.
232. Zimmerman, S. E., Smith, F. P., Phillips, T. M., Coffey, R. J., & Schein, P. S. (1982). Gastric carcinoma and thrombocytic and thrombocytopenic purpura: association with plasma immune complex concentrations. *British Medical Journal*, *284*(6327), 1432–1434.
233. Sheldon, R., & Slaughter, D. (1986). A syndrome of microangiopathic hemolytic anemia, renal impairment, and pulmonary edema in chemotherapy-treated patients with adenocarcinoma. *Cancer*, *58*(7), 1428–1436.
234. Common terminology criteria for adverse events v3.0, DTC, NCI, NIH, DHHS. Publish date: August 9, 2006. <http://ctep.cancer.gov>
235. Tonini, G., Santini, D., Vincenzi, B., Bortzomati, D., Dicuonzo, G., La Cesa, A., et al. (2002). Oxaliplatin may induce cytokine-release syndrome in colorectal cancer patients. *Journal of Biological Regulators & Homeostatic Agents*, *16*(2), 105–109.
236. Howard, S. C., Jones, D. P., & Pui, C.-H. (2011). The tumor lysis syndrome. *The New England Journal of Medicine*, *364*(19), 1844–1854.
237. Zanotti, K. M., Rybicki, L. A., Kennedy, A. W., Belinson, J. L., Webster, K. D., Kulp, B., et al. (2001). Carboplatin skin testing: a skin-testing protocol for predicting hypersensitivity to carboplatin chemotherapy. *Journal of Clinical Oncology*, *19*(12), 3126–3129.
238. Markman, M., Zanotti, K., Peterson, G., Kulp, B., Webster, K., & Belinson, J. (2003). Expanded experience with an intradermal skin test to predict for the presence or absence of carboplatin hypersensitivity. *Journal of Clinical Oncology*, *21*(24), 4611–4614.
239. Gomez, R., Harter, P., Lück, H. J., Traut, A., Kommos, S., Kandel, M., et al. (2009). Carboplatin hypersensitivity: does introduction of skin test and desensitization reliably predict and avoid the problem?

- A prospective single-center study. *International Journal of Gynecological Cancer*, 19(7), 1284–1287.
240. Gastaminza, G., de la Borbolla, J. M., Goikoetxea, M. J., Escudero, R., Antón, J., Espinós, J., et al. (2011). A new rapid desensitization protocol for chemotherapy agents. *Journal of Investigational Allergology and Clinical Immunology*, 21(2), 108–112.
 241. Meyer, L., Zuberbier, T., Worm, M., Oettle, H., & Riess, H. (2002). Hypersensitivity reactions to oxaliplatin: cross-reactivity to carboplatin and the introduction of a desensitization schedule. *Clinical Oncology*, 20(4), 1146–1147.
 242. Reese, J. A., Li, X., Hauben, M., Aster, R. H., Bougie, D. W., Curtis, B. R., et al. (2010). Identifying drugs that cause acute thrombocytopenia: an analysis using 3 distinct methods. *Blood*, 116(12), 2127–2133.
 243. Arnold, D. M., Santoso, S., Greinacher, A., & on behalf of the Platelet Immunology Scientific Subcommittee of the ISTH. (2012). Recommendations for the implementation of platelet auto-antibody testing in clinical trials of immune thrombocytopenia. *Journal of Thrombosis and Haemostasis*, 10(4), 695–697.
 244. Stroncek, D. F. (1993). Drug-induced immune neutropenia. *Transfusion Medicine Reviews*, 7(4), 268–274.
 245. Borthakur, G., O'Brien, S., Wierda, W. G., Thomas, D. A., Cortes, J. E., Giles, F. J., et al. (2007). Immune anaemias in patients with chronic lymphocytic leukemia treated with fludarabine, cyclophosphamide and rituximab—incidence and predictors. *British Journal of Haematology*, 136(6), 800–805.
 246. Radić, M., Martinović Kaliterna, D., & Radić, J. (2012). Drug-induced vasculitis: a clinical and pathological review. *Netherlands Journal of Medicine*, 70(1), 12–17.
 247. Matsuno, O. (2012). Drug-induced interstitial lung disease: mechanisms and best diagnostic approaches. *Respiratory Research*, 13, 39. doi:10.1186/1465-9921-13-39.
 248. Guilhot, F. (2004). Indications for imatinib mesylate therapy and clinical management. *The Oncologist*, 9(3), 271–281.
 249. Guastalla, J. P., III, & Diéras, V. (2003). The taxanes: toxicity and quality of life considerations in advanced ovarian cancer. *British Journal of Cancer*, 89(Suppl 3), S16–S22.
 250. Lee, C. W., Matulonis, U. A., & Castells, M. C. (2004). Carboplatin hypersensitivity: a 6-h 12-step protocol effective in 35 desensitizations in patients with gynecological malignancies and mast cell/IgE-mediated reactions. *Gynecologic Oncology*, 95(2), 370–376.
 251. Bar-Sela, G., Kedem, E., Hadad, S., Pollack, S., Haim, N., Atrash, F., et al. (2010). Successful desensitization protocol for hypersensitivity reaction caused by sunitinib in a patient with a gastrointestinal stromal tumor. *Japanese Journal of Clinical Oncology*, 40(2), 163–165.
 252. Chou, V., McClelland, S., Resnick, D. J., & Lee-Wong, M. (2005). Successful desensitization of an adult with type I hypersensitivity to imatinib. *Internet Journal of Asthma, Allergy and Immunology*, 4(2). doi:10.5580/1a78.
 253. Nelson, R. P., Jr., Cornetta, K., Ward, K. E., Ramanula, S., Fausel, C., & Cripe, L. D. (2006). Desensitization to imatinib in patients with leukemia. *Annals of Allergy, Asthma & Immunology*, 97(2), 216–222.
 254. Kerbel, R. S. (2000). Tumor angiogenesis: past, present and the near future. *Carcinogenesis*, 21(3), 505–515.
 255. Kerbel, R. S., Yu, J., Tran, J., Man, S., Vilorio-Petit, A., Klement, G., et al. (2001). Possible mechanisms of acquired resistance to anti-angiogenic drugs: implications for the use of combination therapy approaches. *Cancer Metastasis Reviews*, 20(1–2), 79–86.
 256. Bergers, G., & Hanahan, D. (2008). Modes of resistance to anti-angiogenic therapy. *Nature Reviews Cancer*, 8(8), 592–603.
 257. Páez-Ribes, M., Allen, E., Hudock, J., Takeda, T., Okuyama, H., Vinals, F., et al. (2009). Antiangiogenic therapy elicits malignant progression of tumors to increased local invasion and distant metastasis. *Cancer Cell*, 15(3), 220–231.
 258. Ebos, J. M. L., Lee, C. R., Cruz-Munoz, W., Bjarnason, G. A., Christensen, J. G., & Kerbel, R. S. (2009). Accelerated metastasis after short-term treatment with a potent inhibitor of tumor angiogenesis. *Cancer Cell*, 15(3), 232–239.
 259. Ebos, J. M. L., Lee, C. R., Christensen, J. G., Mutsaers, A. J., & Kerbel, R. S. (2007). Multiple circulating proangiogenic factors induced by sunitinib malate are tumor-independent and correlate with antitumor efficacy. *Proceedings of the National Academy of Sciences of the United States of America*, 104(43), 17069–17074.
 260. Kerbel, R. S. (2008). Tumor angiogenesis. *The New England Journal of Medicine*, 358(19), 2039–2049.
 261. Baluk, P., Hashizume, H., & McDonald, D. M. (2005). Cellular abnormalities of blood vessels as targets in cancer. *Current Opinion in Genetics and Development*, 15(1), 102–111.
 262. Semenza, G. L. (2003). Targeting HIF-1 for cancer therapy. *Nature Reviews Cancer*, 3(10), 721–732.
 263. Jain, R. K. (2005). Normalization of tumor vasculature: an emerging concept in antiangiogenic therapy. *Science*, 307(5706), 58–62.
 264. Galluzzo, M., Pennacchietta, S., Rosano, S., Comoglio, P. M., & Michieli, P. (2009). Prevention of hypoxia by myoglobin expression in human tumor cells promotes differentiation and inhibits metastasis. *The Journal of Clinical Investigation*, 119(4), 865–875.
 265. Rapisarda, A., & Melillo, G. (2012). Overcoming disappointing results with antiangiogenic therapy by targeting hypoxia. *Nature Reviews. Clinical Oncology*, 9(7), 378–390.
 266. Harris, A. L. (2002). Hypoxia—a key regulatory factor in tumour growth. *Nature Reviews Cancer*, 2(1), 38–47.
 267. Semenza, G. L. (2007). Hypoxia and cancer. *Cancer Metastasis Reviews*, 26(2), 223–224.
 268. Maione, F., Molla, F., Meda, C., Latini, R., Zentilin, L., Giacca, M., et al. (2009). Semaphorin 3A is an endogenous angiogenesis inhibitor that blocks tumor growth and normalizes tumor vasculature in transgenic mouse models. *The Journal of Clinical Investigation*, 119(11), 3356–3372.
 269. Maione, F., Capano, S., Regano, D., Zentilin, L., Giacca, M., Casanovas, O., et al. (2012). Semaphorin 3A overcomes cancer hypoxia and metastatic dissemination induced by antiangiogenic treatment in mice. *The Journal of Clinical Investigation*, 122(5), 1832–1848.
 270. Rankin, E. B., & Giaccia, A. J. (2008). The role of hypoxia-inducible factors in tumorigenesis. *Cell Death and Differentiation*, 15(4), 678–685.
 271. Muratori, C., & Tamagnone, L. (2012). Semaphorin signals tweaking the tumor microenvironment. In I. O. Daar (Ed.), *Guidance molecules in cancer and tumor angiogenesis. Advances in cancer research*, vol. 114 (pp. 59–87). San Diego: Academic.
 272. Nam, S. Y., Ko, Y. S., Jung, J., Yoon, J., Kim, Y. H., Choi, Y. J., et al. (2011). A hypoxia-dependent upregulation of hypoxia-inducible factor-1 by nuclear factor-κB promotes gastric tumour growth and angiogenesis. *British Journal of Cancer*, 104(1), 166–174.
 273. Birchmeier, C., Birchmeier, W., Gherardi, E., & Vande Woude, G. F. (2003). Met, metastasis, motility and more. *Nature Reviews Molecular Cell Biology*, 4(12), 915–925.
 274. Giaccia, A., Siim, B. G., & Johnson, R. S. (2003). HIF-1α as a target for drug development. *Nature Reviews Drug Discovery*, 2(10), 803–811.
 275. Welsh, S. J., & Powis, G. (2003). Hypoxia inducible factor as a cancer drug target. *Current Cancer Drug Targets*, 3(6), 391–405.
 276. Rapisarda, A., Zalek, J., Hollingshead, M., Braunschweig, T., Uranchimeg, B., Bonomi, C. A., et al. (2004). Schedule-dependent inhibition of hypoxia inducible factor-1 alpha protein accumulation, angiogenesis, and tumor growth by topotecan in U251-HRE glioblastoma xenografts. *Cancer Research*, 64(19), 6845–6848.
 277. Vredenburgh, J. J., Desjardins, A., Herndon, J. E., Marcello, J., Reardon, D. A., Quinn, J. A., et al. (2007). Bevacizumab plus

- irinotecan in recurrent glioblastoma multiforme. *Journal of Clinical Oncology*, 25(30), 4722–4729.
278. Rapisarda, A., & Melillo, G. (2009). Role of the hypoxic tumor microenvironment in the resistance to antiangiogenic therapies. *Drug Resistance Update*, 12(3), 74–80.
279. Rapisarda, A., & Melillo, G. (2012). Role of the VEGF/VEGFR axis in cancer biology and therapy. In I. O. Daar (Ed.), *Guidance molecules in cancer and tumor angiogenesis. Advances in cancer research*, vol. 114 (pp. 237–267). San Diego: Academic.
280. Pencreach, E., Guérin, E., Nicolet, C., Lelong-Rebel, I., Voegeli, A.-C., Oudet, P., et al. (2009). Marked activity of irinotecan and rapamycin combination toward colon cancer cells *in vivo* and *in vitro* is mediated through cooperative modulation of the mammalian target of rapamycin/hypoxia-inducible factor-1 α axis. *Clinical Cancer Research*, 15(4), 1297–1307.
281. You, W.-K., Sennino, B., Williamson, C. W., Falcón, B., Hashizume, H., Yao, L.-C., et al. (2011). VEGF and c-Met blockade amplify angiogenesis inhibition in pancreatic islet cancer. *Cancer Research*, 71(14), 4758–4768.
282. Avastin®. FDA: full prescribing information. Adverse reactions. http://www.accessdata.fda.gov/drugsatfda_docs/label/2012/125085s0238lbl.pdf Accessed August 10, 2013.
283. Inlyta®. FDA: full prescribing information. Adverse reactions. http://www.accessdata.fda.gov/drugsatfda_docs/label/2012/202324lbl.pdf. Accessed August 10, 2013.
284. Miranda, E., Nordgren, I. K., Male, A. L., Lawrence, C. E., Hoakwie, F., Cuda, F., et al. (2013). A cyclic peptide inhibitor of HIF-1 heterodimerization that inhibits hypoxia signaling in cancer cells. *Journal of the American Chemical Society*, 135(28), 10418–10425.
285. Holash, J. (2002). VEGF-Trap: a VEGF blocker with potent antitumor effects. *Proceedings of the National Academy of Sciences of the United States of America*, 99(17), 11393–11398.
286. Koh, Y. J., Kim, H. Z., Hwang, S.-I., Lee, J. E., Oh, N., Jung, K., et al. (2010). Double antiangiogenic protein, DAAP, targeting VEGF-A and angiopoietins in tumor angiogenesis, metastasis, and vascular leakage. *Cancer Cell*, 18(2), 171–184.
287. Fischer, C., Jonckx, B., Mazzone, M., Zacchigna, S., Loges, S., Pattarini, L., et al. (2007). Anti-PlGF inhibits growth of VEGF(R)-inhibitor-resistant tumors without affecting healthy vessels. *Cell*, 131(3), 463–475.
288. Cascone, T., & Heymach, J. V. (2012). Targeting the angiopoietin/Tie2 pathway: cutting tumor vessels with a double-edged sword? *Journal of Clinical Oncology*, 30(4), 441–444.
289. Tamburrino, A., Piro, G., Carbone, C., Tortora, G., & Melisi, D. (2013). Mechanisms of resistance to chemotherapeutic and anti-angiogenic drugs as novel targets for pancreatic cancer therapy. *Frontiers in Pharmacology*, 4, 56. doi:10.3389/fphar.2013.00056.
290. Fingleton, B. (2006). Matrix metalloproteinases. Roles in cancer and metastasis. *Frontiers in Bioscience*, 11, 479–491.
291. Mas-Moruno, C., Rechenmacher, F., & Kessler, H. (2010). Cilengitide: the first anti-angiogenic small molecule drug candidate. Design, synthesis and clinical evaluation. *Anti-Cancer Agents in Medicinal Chemistry*, 10(10), 753–768.
292. Plate, K. H., Scholz, A., & Dumont, D. J. (2012). Tumor angiogenesis and anti-angiogenic therapy in malignant gliomas revisited. *Acta Neuropathologica*, 124(6), 763–775.
293. Garraty, G. (2010). Immune hemolytic anemia associated with drug therapy. *Blood Reviews*, 24(4–5), 143–150.