
CME Article

Airway and respiratory management following non-lethal hanging

Abdullah Kaki MB CHB,
Edward T Crosby MD FRCPC,*
Anne CP Lui MD FRCPC†

Purpose: To review the literature on airway and respiratory management following non-lethal (suicidal) hanging and to describe the anatomy, injury and pathophysiological sequelae and their impact on patient care.

Source: A Medline literature search of English-language and English-abstracted papers for 1990–96. Keywords were: hanging; strangulation; airway obstruction; pulmonary oedema. Filters were applied to limit the search to relevant citations. (i.e., keywords = pulmonary oedema; filters = postobstructive, neurogenic). Citations were then hand-culled to obtain current and relevant papers about an unusual cohort of patients. A hand search of the bibliographies of relevant papers supplemented the Medline search. A review of our experience at the University of Ottawa adult hospitals over the last decade was also undertaken to determine the relevance of the literature to our clinical experiences.

Principal Findings: Most victims are young men and survivors are uncommon. Laryngo-tracheal injuries, although reported in 20–50% of postmortem examinations, are infrequent in survivors and have little impact on airway management. Spinal injuries are rare in survivors but should be excluded. Pulmonary complications including pulmonary oedema and bronchopneumonia are implicated in most in-hospital deaths. Pulmonary oedema is likely due to neurogenic factors or negative intrathoracic pressure. Although neurological injury determines outcome following hanging, initial neurological presentation is of limited prognostic value: a poor initial condition does not exclude a good recovery.

Conclusion: Airway injuries severe enough to interfere with airway management are uncommon after attempted suicide by hanging. Irrespective of the initial neurological assessment, aggressive and early resuscitation to optimize cerebral oxygenation is recommended.

Objectif : Réviser la littérature publiée sur la gestion des voies aériennes et de la respiration après l'échec de suicide par pendaison et décrire l'anatomie, les lésions et les séquelles physiopathologiques consécutives et leur influence sur le traitement.

Source : Une recherche sur *Medline* des articles et des résumés publiés en langue anglaise de 1990 à 1996. Les mots clés recherchés étaient : pendaison ; strangulation ; obstruction des voies aériennes ; oedème pulmonaire. Des «filtres» ont été utilisés pour limiter la recherche aux citations pertinentes (par ex., pour les mots clés : oedème pulmonaire ; les filtres postobstruction et neurogène). Les citations ont alors été triées à la main pour acquérir les articles courants et appropriés au sujet de cette cohorte inhabituelle de patients. Une recherche visuelle dans la bibliographie des articles pertinents a complété la recherche dans *Medline*. L'expérience clinique accumulée dans les hôpitaux d'adultes de l'université d'Ottawa a aussi été analysée pour déterminer sa concordance avec celle de la littérature.

Principales constatations : La plupart des victimes sont des hommes jeunes et les survivants sont rares. Les lésions laryngo-trachéales retrouvées à l'autopsie dans 20 à 50% des cas, sont rares chez les survivants et ont très peu d'impacts sur la gestion des voies aériennes. Les blessures rachidiennes aussi sont rares chez les survivants mais devraient être recherchées. Les complications pulmonaires dont l'oedème et la bronchopneumonie interviennent comme cause dans la plupart des décès hospitaliers. L'oedème pulmonaire est vraisemblablement d'origine neurologique ou barotraumatique par pression négative intrathoracique. Bien qu'après la pendaison, la lésion neurologique détermine l'issue, la condition initiale de l'état neurologique n'a qu'une valeur pronostique limitée ; une condition initiale médiocre n'exclut pas une bonne récupération.

Conclusion : Après une tentative de suicide par pendaison, les lésions des voies aériennes sont rarement assez graves pour nuire à leur contrôle. Indépendamment de l'évaluation neurologique initiale, une réanimation agressive et précoce s'impose pour optimiser l'oxygénation du cerveau.

From the Departments of Anaesthesia, Ottawa General Hospital* and Ottawa Civic Hospital,† University of Ottawa.

Address correspondence to: Dr. Edward T. Crosby, Department of Anaesthesia, Ottawa General Hospital, Room 2600, Tower 3, 501 Smyth Road, Ottawa, Ontario, Canada, K1H 8L6; Phone: 613-737-8187; Fax: 613-737-8189; E-mail: ecrosby@ogh.on.ca

Accepted for publication January 11, 1997.

HANGING is the most common form of strangulation injury.¹ Other forms include manual, postural, and ligature strangulation. Hanging occurs when pressure is exerted on the neck by an external mechanism, usually a rope, and the applied pressure is increased by the suspended weight of the victim's body. Hanging can occur from virtually any position. *Complete hanging* applies to situations in which the victim is fully suspended and the term *incomplete hanging* is used for other positions. The site of placement of the ligature knot is important: *typical hanging* refers to the situation where the point of suspension (knot) is placed over occiput. Typical placement has the greatest ability to result in arterial occlusion.¹ In classic *judicial hanging*, unless the drop was at least equal to the height of the victim, there was usually no injury to the cord, fracture of the spine, or fracture to the base of the skull; death occurred by asphyxiation. In longer judicial drops, the most common spinal injury was disjuncting of the second from the third cervical vertebra and bilateral fractures of the arch of the second vertebra, the *hangman's fracture*. Occasionally, the disjuncting occurred between the third and fourth cervical vertebrae.

Death from hanging may be caused in one of three ways: 1) direct neurological injury; 2) mechanical constriction of the neck structures, principally arteriovenous or airway compression; or 3) cardiac arrest as a result of stimulation of vasoactive centres in the great vessels. Asphyxia from obstruction of the airway is likely the major cause of suicidal hanging. Although fractures and dislocations of the upper cervical spine and resultant cord injury or disruption are common in judicial hanging, they are uncommon in suicidal hangings. Survivors of hanging are not uncommon. However, because anaesthetists may be called upon to assess and provide care to these patients, a review of the relevant anatomy and pathophysiology is offered along with a discussion of some early management issues.

Anatomy

The principle arterial supply to the head and brain is via the carotid arteries. (Figure 1) They are separated from the anterolateral surface of the neck only by the sternomastoid muscles, deep cervical fascia, platysma and skin. Posteriorly, they rest on the transverse processes of the fourth to sixth cervical vertebrae, against which they may be easily compressed. Traction injuries of the carotid arteries can occur at the level of the ligature in about 5% of hanging victims.² Bleeding into the vessel wall or intimal disruption occurs, compromising flow through the vessel. These injuries are

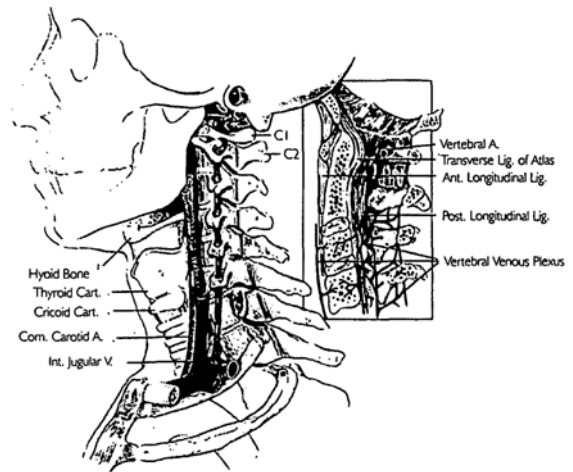


FIGURE 1 Anatomy of the neck structures affected by strangulation. (From Isserson¹), with permission.

described after postmortem examination and may not occur in survivors. The vertebral arteries course through the transverse foramen of the cervical vertebrae and they are relatively protected from external compressive forces. However, flow through the vertebral arteries may be compromised during extreme rotation or flexion. Venous drainage of the head and neck is via the internal and external jugular systems and the venous plexuses of the spinal cord and column. The jugular system is readily compressed by an externally applied force. Venous compression is likely an important factor in non-judicial hanging. It occurs with low applied forces and results in stagnant cerebral hypoxia. This predisposes to a loss of consciousness, decreased neck muscle tone and subsequent compression of the arteries and airway.

The hyoid bone and the superior cornua of the thyroid are linked by the thyrohyoid ligament. One or both structures may be fractured with externally applied forces and the ligamentous linkage may contribute to fractures or injuries to the adjacent structure.¹ Fractures of the thyroid cartilage and hyoid bone are common, occurring in about 50% and 20% of hanging suicides, respectively.² These injuries are more commonly described in victims of manual strangulation than after suicidal hanging. They are also more common in older patients who are more likely to have an ankylosed hyoid bone or an ossified thyroid cartilage. Severe injury to deep neck structures is not common but has been described in the forensic literature. However, because these observations are made on postmortem assessments, the level of reported injury may be more extreme than that expected in sur-

vivors. Most airway injuries are minor: life-threatening airway injuries in survivors of suicidal hanging are uncommon. Injuries to the trachea are also rare.²

The Pathophysiological Consequences of Hanging

In survivors of strangulation injury, haemorrhage may be considerable in the area of the neck subjected to ligation forces. Aphonia, hoarseness or stridor occur as a result of traumatic oedema of the larynx and supraglottic tissues. Pulmonary complications including pulmonary oedema and bronchopneumonia are implicated in most in-hospital deaths. The pulmonary oedema may be from a central-neurogenic origin or secondary to negative intrathoracic pressures generated as the victim attempts inspiration through an obstructed airway. The initial phase of neurogenic pulmonary oedema results from a centrally mediated, massive, sympathetic discharge.³ This discharge produces intense, generalised, but transient, vasoconstriction with a resultant shift of blood from the high-resistance systemic to the low-resistance pulmonary circulation. Pronounced increases in the pulmonary vascular pressures and blood volume then produce pulmonary oedema because of the hydrostatic effect of the increased pulmonary capillary pressure. In addition, the intense hypoxic pulmonary vasoconstriction increases permeability both by increasing intravascular pressures as well as by disrupting the permeability barrier. Neurogenic pulmonary oedema is often recognized after devastating and usually lethal brain injury.³ As such, it is a poor prognostic factor after a neurological insult. Fishman described two cases of adult respiratory distress syndrome (ARDS) following attempted suicide by hanging.⁴ Both had bilateral pulmonary oedema and one was further complicated by pulmonary aspiration. Fishman attributed the pulmonary oedema to a central neurogenic mechanism. The patients were managed with tracheal intubation and positive pressure ventilation: both survived without neurological deficits.

The original report of postobstructive pulmonary oedema included cases of upper airway obstruction due to tumour, strangulation, and near-hanging.⁵ The initiating event in post-obstructive (negative pressure) pulmonary oedema is the markedly negative intrapleural pressure generated by a forceful inspiratory effort against an obstructed extrathoracic airway. The incidence of pulmonary oedema associated with airway obstruction has been estimated at 11% in adults requiring active airway intervention for acute airway obstruction of varying aetiology.⁶ The pathogenesis of pulmonary oedema associated with upper airway obstruction is multifactorial. Markedly negative intrapleural pressure alone can result in pulmonary

oedema. During quiet respiration, intrapleural inspiratory pressures range from -2 to -5 cm H₂O but may increase to -100 cm H₂O during airway obstruction. These extreme negative intrapleural pressures increase venous return, pulmonary blood volume and pulmonary capillary hydrostatic pressures while lowering interstitial hydrostatic pressures, thus increasing the hydrostatic gradient across the capillary membrane.⁵ The increased venous return to the right heart also decreases left ventricular compliance via the mechanism of ventricular interdependence, resulting in elevated left ventricular end-diastolic and pulmonary microvascular hydrostatic pressures. These processes also favour the formation of pulmonary oedema. Although the negative intrapleural pressure is the principal pathological event in the development of pulmonary oedema associated with upper airway obstruction, hypoxia and the resulting hyperadrenergic state also contribute to its development. The hypoxia-induced hyperadrenergic state causes translocation of blood from the systemic to the pulmonary circulation and an increase in both pulmonary vascular resistance and pulmonary capillary permeability.⁶ Hanging represents a fixed airway obstruction (as opposed to a dynamic obstruction) and pulmonary oedema would be expected soon after removal of the ligature and relief of the obstruction.

It is likely that the prognosis for the patient with negative pressure pulmonary oedema after strangulation injury is not as grave as that for the patient with neurogenic pulmonary oedema. Greater brain injury is implied in the context of neurogenic oedema and this would be the major prognostic factor determining the ultimate outcome. Negative pressure oedema may result from transient airway obstruction and, barring brain injury, resolution and recovery would be expected. It is difficult, if not impossible, to determine initially the aetiology of pulmonary oedema in survivors of strangulation injury although good neurological recovery implies a brief episode of obstruction and negative pressure as the cause. The good outcomes achieved by Fishman's patients favours the diagnosis of postobstructive rather than neurogenic pulmonary oedema as was originally postulated.

The Neurological Sequelae of Hanging

Neurological sequelae are the most important aftermath of strangulation. Although initial neurological assessment is of little prognostic value for the individual patient, the cohort of victims who arrive at hospital with absent or agonal respiration, absent vital signs or failed initial resuscitation have a poor prognosis. Survivors of hanging have probably suffered mixed ischaemic-hypoxia rather than simply hypoxia.⁷ Intracranial

pressure (ICP) may be elevated and clinical interventions directed at reducing elevated ICP are warranted. Delayed neurological sequelae are rare after strangulation.^{1,8} When they occur, they follow one of three patterns: 1) the comatose patient, who improves slightly, then deteriorates and dies; 2) the patient who appears to make a considerable recovery, only to progress to an irreversible herniation syndrome and die; and 3) the patient who appears to recover completely, then develops a delayed encephalopathy and dies.

The Ottawa Experience

An automated, computer search of the medical records of the University of Ottawa adult teaching hospitals for the 1984–1994 was carried out. Charts of all patients who survived hanging to be admitted to the hospitals were identified, retrieved and reviewed by the authors. Seventeen charts were reviewed; all were suicidal suspensions. Consistent with Canadian statistics regarding suicidal hanging,⁹ the majority (16 of 17, 94%) of the victims were men <30 yr (average age 31 ± 13 yr). Thirteen patients were persistently unconscious at discovery and six of these received cardiopulmonary resuscitation at the scene. These 13 patients remained comatose on presentation to hospital. Two patients with impaired consciousness at the scene were in a similar condition at presentation to hospital and two patients, fully conscious at the scene, were described as alert and oriented in the emergency room.

Fourteen patients (82%) had their tracheas intubated, most at the referring hospital. Five patients underwent uneventful blind nasal intubation and no airway features were assessed. The tracheas of the remaining nine patients were intubated with direct laryngoscopy. The notes describing the tracheal intubations were reviewed and revealed no intubation difficulty or unusual findings at laryngoscopy. Reports of chest radiographs were reviewed for all patients. Two patients had dense bilateral pulmonary infiltrates consistent with either pulmonary oedema or massive aspiration. However, their clinical courses were more consistent with pulmonary oedema than massive aspiration, with physical and radiological resolution over the next 24 hr. One patient had radiographic evidence of right middle and lower lobe aspirations and one had diffuse bilateral atelectatic changes. On soft tissue cervical radiographs, two patients had minor soft tissue swelling at the hyoid or laryngeal; one had a small haematoma at the hyoid level and one had a non-displaced fracture through the thyroid cartilage. We had anticipated a higher incidence of more severe airway injuries. In fact, only minor injuries with little impact on airway management were found. Our sur-

vey involved only a small number of patients and it is possible that a larger review would have yielded a higher incidence of severe injury. If we were to base our conclusions on our findings alone, we could only be confident that the likelihood of a clinically important airway injury was not greater than about 18%.¹⁰

There was a note in one chart reporting incomplete subluxation of the first on the second cervical vertebrae, but with no instability. Interestingly, there was no radiographic documentation of this injury in the chart and no radiographs were available for review. The patient was treated with a collar and discharged for follow-up at the referring institution. The nature of the spinal injury was not fully elucidated after the review of the patient's chart.

Four patients died; all had required cardiopulmonary resuscitation at the scene. Four were left with severe neurological and cognitive impairment: all were comatose and their tracheas were intubated on arrival. Four patients recovered but had persistent mild to moderate cognitive impairment: all had been comatose on arrival, responding to deep pain only. Five patients recovered fully. Only one of our 13 patients (8%) with poor initial neurological function made a full recovery, although three (23%) were left with only mild cognitive impairment.

Management Issues

Absent or agonal respiration, absent heartbeat or the need for resuscitation in a patient following a hanging, either at the scene or in the emergency room carries a poor prognosis. However, the patient's neurological condition may improve markedly from that seen at presentation and aggressive resuscitation of hanging survivors should be instituted immediately regardless of the initial neurological findings. A primary injury survey should be carried out for other self-inflicted injuries and a toxicology screen done to test for drug ingestion. Although spinal injury is not common, it must be ruled out. The neck should be stabilized at the scene and immobilization maintained until integrity of the spinal column is confirmed. Supplemental oxygen should be provided and an immediate assessment of the adequacy of the airway as well as of both ventilation and oxygenation needs to be made. Appropriate respiratory management should be instituted, including tracheal intubation and mechanical ventilation with positive end-expiratory pressure.¹ Intubation should be carried out in patients who arrive requiring cardiopulmonary resuscitation, in the presence of a compromised airway, or if neurological compromise is evident. If the patient is haemodynamically stable, consideration can be given to the use of intravenous opioids, induction agents or

lidocaine to reduce the hyperdynamic and ICP response to intubation. The technique of intubation should ensure rapid control of the airway while limiting cervical spinal movement. In most practitioner's hands, direct laryngoscopy with in-line immobilization meets these criteria. Mechanical ventilation with positive end expiratory pressure (PEEP) is recommended for ventilatory management of patients in whom adequate oxygenation cannot be maintained despite a patent upper airway and supplemental oxygenation.

The treatment of brain oedema is both controversial and beyond the scope of this article and the interested reader is referred to other reviews for an assessment of the current literature.¹¹⁻⁵ Diuretics are indicated in the presence of pulmonary oedema irrespective of the aetiology. Once the patient's condition is stabilized, they should be transferred to an intensive care setting. Further care will be determined by repeat neurological assessments.

Summary

Survivors of strangulation injury are uncommon. Laryngo-tracheal injuries are reportedly common and spinal injuries are not rare after strangulation injury but most assessments have been made after post-mortem examination of victims.¹ From our review, it appears that similar injuries in survivors, which may have an impact on airway management are uncommon. However, there is inadequate information on this topic and more data are needed before a final conclusion can be drawn. Poor neurological condition at presentation does not necessarily predict poor neurological outcome although the two are associated. Early and aggressive intervention to optimize brain perfusion and oxygenation is warranted irrespective of the initial neurological condition.

Self-assessment Questionnaire

For each of the following questions select the one best answer.

1. The true statement concerning mechanisms of injury or death following hanging is:
 - a) fracture of the cervical spine is the usual cause of death.
 - b) death can be caused by mechanical compression of the airway.
 - c) the "hangman's fracture" described the dis-jointing of the third and fourth cervical vertebrae.
 - d) asphyxiation is a rare cause of death in judicial hanging.
2. Which of the following statements about the blood supply of the head and brain is true?
 - a) the carotid arteries rest posteriorly on the spinous processes of the cervical vertebrae.
 - b) the vertebral arteries are relatively protected during hanging.
 - c) the venous drainage is resistant to compression.
 - d) the jugular system provides the only venous drainage of the head.
3. All of the following are true statements about the pathogenesis of negative pressure pulmonary oedema except one. State the exception.
 - a) increased venous return results in reduction of left ventricular compliance.
 - b) increased adrenergic tone is associated with an increase in pulmonary capillary permeability.
 - c) negative intrapleural pressures can result in an increase in the interstitial hydrostatic pressure.
 - d) intrapleural inspiratory pressure may increase to -50 cm H_2O during airway obstruction.
4. Which of the following statements regarding victims of hanging is true?
 - a) neurological complications are implicated in most in-hospital deaths.
 - b) severe laryngotracheal injuries are common findings in survivors.
 - c) hanging is the most common form of strangulation.
 - d) pulmonary oedema is always of neurogenic origin.
5. All of the following may be associated with strangulation injury with one exception. State the exception.
 - a) delayed encephalopathy is a complication of strangulation injury.
 - b) cardiac arrest may occur secondary to increased vagal stimulation.
 - c) traction injury of the carotid arteries occurs above the level of the ligature.
 - d) fracture of the thyroid cartilage is more common among elderly patients.
6. The following are recommended early management interventions in hanging survivors with one exception. State the exception.
 - a) a toxicology screen should be done.
 - b) an immediate airway assessment should be done.
 - c) direct laryngoscopy can be performed even in the presence of severe airway injury.
 - d) diuretics are routinely indicated in the presence of abnormal chest x-ray findings.

7. Which of the following statements regarding delayed neurological sequelae is true?
 - a) they are the most important sequelae in survivors of strangulation.
 - b) poor initial neurological findings are indicative of a poor prognosis.
 - c) survivors of hanging typically suffer a pure hypoxic brain insult.
 - d) if the victim is conscious and alert at the scene, there is no need for hospital admission.
8. Which of the following statements regarding suicidal hanging is true?
 - a) venous compression is an important early event.
 - b) loss of consciousness generally results from compression of the arterial tree.
 - c) injury to the spinal cord is common.
 - d) a drop of at least two metres is needed to produce strangulation.
9. Regarding the early management of survivors of hanging, the following statements are true with one exception. State the exception.
 - a) the need for resuscitation in an apnoeic patient carries a poor prognosis.
 - b) tracheal intubation should be performed only in the presence of poor ventilation.
 - c) once the patient is stabilized, he should be transferred to the intensive care unit.
 - d) glucose containing solutions should be avoided in the presence of brain injuries.
10. The following statements about neurogenic pulmonary oedema are true with one exception. State the exception.
 - a) the initial phase results from a centrally mediated sympathetic discharge.
 - b) it occurs after devastating brain injury.
 - c) increased hydrostatic pressures result in pulmonary oedema.
 - d) early, aggressive intervention results in an improved outcome.

Answers

1	2	3	4	5	6	7	8	9	10
b	b	c	c	c	d	a	a	b	d

References

- 1 *Iserson KV*. Strangulation: a review of ligature, manual, and postural neck compression injuries. *Ann Emerg Med* 1984; 13: 179–85.
- 2 *Polson CJ, Gee DJ*. The Essentials of Forensic Medicine, 3rd ed. New York: Pergamon Press, 1973: 371–439.
- 3 *Theodore J, Robin ED*. Pathogenesis of neurogenic pulmonary oedema. *Lancet* 1975; 2: 749–51.
- 4 *Fishman CM, Goldstein MS, Gardner LB*. Suicidal hanging. An association with the adult respiratory distress syndrome. *Chest* 1977; 71: 225–7.
- 5 *Timby J, Reed C, Zeilender S, Glauser FL*. “Mechanical” causes of pulmonary edema. *Chest* 1990; 98: 973–9.
- 6 *Lang SA, Duncan PG, Shephard DAE, Ha HC*. Pulmonary oedema associated with airway obstruction. *Can J Anaesth* 1990; 37: 210–8.
- 7 *Senter HJ, Wolf A, Wagner FC Jr*. Intracranial pressure in nontraumatic ischemic and hypoxic cerebral insults. *J Neurosurg* 1981; 54: 489–93.
- 8 *Dooling EC, Richardson EP*. Delayed encephalopathy after strangling. *Arch Neurol* 1976; 33: 196–9.
- 9 *Mortality – Summary List of Causes, 1991*. Canadian Centre for Health Information, Statistics Canada, 1994.
- 10 *Hanley JA, Lippman-Hand A*. If nothing goes wrong, is everything all right? Interpreting zero numerators. *JAMA* 1983; 249: 1743–5.
- 11 *Mayberg TS, Lam AM*. Management of central nervous system trauma. *Current Opinion in Anaesthesiology* 1993; 6: 764–71.
- 12 *Lam AM, Winn HR, Cullen BF, Sundling N*. Hyperglycemia and neurological outcome in patients with head injury. *J Neurosurg* 1991; 75: 545–51.
- 13 *Sieber FE, Traystman RJ*. Special issues: glucose and the brain. *Crit Care Med* 1992; 20: 104–14.
- 14 *Asgeirsson B, Gründe PO, Nordström CH*. A new therapy of post-trauma brain oedema based on haemodynamic principles for brain volume regulation. *Intensive Care Med* 1994; 20: 260–7.
- 15 *Tietjen CS, Hurn PD, Ulatowski JA, Kirsch JR*. Treatment modalities for hypertensive patients with intracranial pathology: options and risks. *Crit Care Med* 1996; 24: 311–22.