

Alvarado Score Between 4 and 6, the Place of the CT Scan

S. Loudjedi¹, M. Bensenane², N. Meziane¹,
F. Ghirane¹ and M. Kherbouche¹

¹Department of Surgery B,

²Department of Radiology,

University of Abu-Bakr Belkaid, Tlemcen,
Algeria

1. Introduction

The appendicitis is the inflammation of the appendix. The appendix is a small tube like pouch that is part of the large intestine. The appendix has no known function, but it can become diseased.

Symptoms vary widely. It can affect all ages and both sexes.

The exact cause is unknown. The appendix may be blocked with faeces from the intestinal tract, which leads to infection. When infected, the appendix becomes swollen, inflamed and filled with pus.

Curable with surgery, people can live a normal life without their appendix.

About 8% of the population may develop acute appendicitis during their lifetime. The clinical diagnosis is evident in 80% of cases, but in the remaining cases the lack of parallelism anatomoclinical sometimes makes the diagnosis very difficult. Since 1986, the clinical and biological Alvarado score is a test used in clinical practice in surgery dealing with pain in the right iliac fossa. We sought to identify the role of computed tomography (CT) in the diagnosis of acute appendicitis in patients with a score of 4 to 6 Alvarado. In this view, it would be disposed to negative laparotomy, which represents between 15% and 30% and also prevents progression to such complications as acute peritonitis. [1]

2. Historical evolution of its diagnosis and treatment

Since the middle Ages, physicians have recognised a clinical entity associated with severe inflammation of the cecal region. Termed "typhlitis" or "paratyphlitis" (from the Greek *typhlos*, meaning "blind" and referring to the anatomy of the first part of the cecum). The disease was for hundreds of years considered fatal. In 1886, Professor Reginald Fitz at Harvard Medical School gave the first clear, logical description of the clinical and pathologic features of the disease by using the term appendicitis. [2]

In 1889, the New York surgeon Charles McBurney advocated prompt diagnosis and early appendectomy and so led the medical profession towards the modern treatment of the disease. [3]

Subsequently, surgical results in patients with an acutely inflamed, non-perforated appendix were satisfactory, but rates of postoperative morbidity and mortality were high among patients for whom delayed diagnosis led to a perforated appendix with peritonitis. [3] Endless debate raged about types of drainage, the best choice of irrigation fluids, the question of whether irrigation of the peritoneal cavity dilutes or spreads infection, and safe offered a way to treat complicated appendicitis and promised to make these ways to clean the contaminated abdominal wound. The development of antibiotic agents questions unnecessary and reduce morbidity and mortality from complicated appendicitis to a rate closer to that of non-perforated appendicitis. The article by Drs Henley and Haugen was an early attempt to understand the benefits of the new drugs.

Five of the fifty-one patients described in the article were treated by the conservative Ochsner method with the addition of sulpha drugs. Results were good : no mortality occurred and the mean length of hospitalisation was 14 days (one patient remained hospitalised for 37 days, but this data point was the sole outlier). Four patients returned for interval appendectomy before recurrence, and one patient was unavailable for follow-up.

The other patients described by Drs Henley and Haugen were treated with surgery when the diagnosis was made. The infection was treated by a sulfathiazole emulsion placed both in the abdominal cavity and in the layers of the wound. Sulfadiazine was given postoperatively, first intravenously and then by mouth. One patient received no sulphonamide, and three patients received sulphonamide only locally to the wound. The 46 patients in the series had 21 septic complications (at a total septic complication rate of about 50%) and a mean postoperative hospital stay of 15 days. This finding should be compared with those that were usual in the pre-antibiotic era: a 75% rate of wound infection in addition to intra-abdominal and chest infections when peritonitis or a gangrenous appendix was found at operation. [3] To the surgeons' and to sulphonamide's credit, no mortality occurred among the patients in the series. Sulphonamide administered at this dosage would thus seem helpful – but not a complete success – in eliminating morbidity from sepsis. Recognising this likelihood, the authors reported that subsequent cases were being treated to raise levels of the drug in the blood. The technique used by the authors for retrograde removal of the retrocecal appendix is described near the end of the article and is still being used regularly to good effect at the KP Oakland Medical Centre.

3. Modern developments

Many antibiotic schedules have been explored in the 57 years that have ensued since the publication of the article by Drs Henley and Haugen, and clinicians have had considerable success in reducing sepsis in patients with complicated appendicitis. Current practice usually includes a regimen of multiple antibiotics begun preoperatively and directed at aerobic and anaerobic bacteria. Use of the drugs is discontinued after several doses if the disease is found to be uncomplicated; if the peritoneum is soiled, the drug regimen is continued as long as clinically appropriate. Adequate preoperative levels of antibiotic agents in the blood help protect against wound infection and the development of peritonitis. Secondary closure of the wound on the second or third postoperative day may prevent infection.

With use of modern antibiotic agents, sepsis nonetheless develops in 5% to 20% of patients with complicated appendicitis. [2] Modern antibiotic regimens have thus reduced – but have

not eliminated – the high cost of treating mixed bacterial infections in the abdominal cavity and surgical wound. In England and Wales, during the pre-antibiotic era, 3000 deaths from appendicitis were reported each year; by 1985, the mortality rate was reduced to 147 deaths per year and is now less than 1%. [2][3]

Modern abdominal imaging and nuclear medicine have led to immeasurably improved treatment of the complications of appendicitis, but the diagnosis of early appendicitis has not been improved since 1944 despite advances in abdominal imaging and laboratory techniques. Diagnosis still depends on a carefully assembled medical history, skilled physical examination and routine laboratory testing. Even when a highly capable physician has made the diagnosis, a normal appendix is found in about 15% of operations. [4] Laparoscopic surgery is well-accepted as the primary operation and is especially beneficial when a normal appendix is found and the rest of the abdomen must be searched so as to establish the postoperative diagnosis.

More than one hundred years have passed since McBurney reported his study of acute appendicitis in eight patients.

Acute appendicitis is the most common cause of acute abdominal pain in young adults. This is one of the most common surgical emergencies, with a lifetime prevalence of about 1 to 7.1 1.5-1.9/1000. Its incidence is for men. [5]

Surgery for acute appendicitis is the most frequently performed operation (10% of all emergency abdominal operations). [6]

The diagnosis of acute appendicitis is based purely on the history of the disease, clinical examination and few laboratory tests (white blood cell count). The morphological examinations were not of great interest for the diagnosis. Definitive diagnosis is obtained only after histological examination of the part of appendicitis. [7] A negative appendectomy rate of 20-40% was reported in the literature[6] and many surgeons accept a rate of 30.6%, as the removal of a healthy appendix is an economic burden on both patients and health resources. Errors or delays in surgery can cause complications such as perforation and finally peritonitis. [8]

Difficulties in diagnosis occur in the very young, elderly women of childbearing age and pregnant women because they generally have an unusual array. [9] Although there is a lot of progress in gastroenterology, there has been no major improvement in the diagnostic accuracy of acute appendicitis, which varies between 25-90% with an optimal rate is 80% (which is lower in women than in men). A number of scoring systems have been advocated to minimise the number of unnecessary interventions performed in emergencies. These rating systems are valuable tools and valid for the discrimination between acute appendicitis and a clear atypical feature. [9] At present many rating systems for the diagnosis of acute appendicitis are available. The Alvarado scoring system is one of these and is based purely on the patient's history, clinical examination and laboratory tests and so is very easy to apply. [10] The Alvarado score includes the left shift of the decision of mature neutrophils.

4. Alvarado score

The Alvarado score is a rating system used in the clinical diagnosis of appendicitis. The score was 6 for clinical and laboratory measurements, with a total of 10 points. Elements of the patient's history, physical examination and laboratory tests are considered:

- Abdominal pain that migrates to the right iliac fossa.
- Anorexia (loss of appetite) or ketones in the urine.
- Nausea or vomiting.
- Pain in the form of pressure in the right iliac fossa.
- Rebound tenderness.
- Fever of 37.3 ° C or more.
- Leukocytosis, with more than 10 000 white cells per microlitre in serum.
- Neutrophilia (or an increase in the percentage of neutrophils in the count of white blood serum).

The two most important defences in the lower right quadrant and leukocytosis are assigned two points, and six other factors are assigned one point each for a possible ten points.

A score of 5 or 6 is compatible with the diagnosis of acute appendicitis. A score of 7 or 8 indicates a probable appendicitis, and a score of 9 or 10 indicates a very probable acute appendicitis.

Between 4 and 6 the diagnosis of appendicitis leads to problems. The aims of our study is how to introduce the role for a CT scan in this situation?

A popular mnemonic used to remember the score factors is MANTRELS: Alvarado - migration to the right iliac fossa, anorexia, nausea/vomiting, tenderness in the right iliac fossa, rebound pain, high temperature (fever), leukocytosis and the movement of leukocytes to the left (factors listed in the same order as presented above). Due to the popularity of this symbol, the score is sometimes called the Alvarado score MANTRELS Alvarado describes the original score of a possible 10 points, but medical facilities who are unable to perform a white blood cell count use a modified Alvarado score with a total of nine points and which might not be as accurate as the original score. A high score of diagnosis was confirmed in a number of studies around the world. The consensus is that the Alvarado score is a non-invasive, safe diagnostic method that is simple, reliable and reproducible and able to guide the clinician in the management of the case.

Migratory right iliac fossa pain 1
Nausea / vomiting 1
Anorexia 1
Signs
Tenderness in right iliac fossa 2
Rebound tenderness in the right iliac fossa 1
High temperatures 1
Laboratory results
Leukocytosis 2
Passage to the left of neutrophils 1
Total 10

Table 1. Symptoms Alvarado scoring system a score

5. Appendicitis and CT scan

Computed tomography (CT) is becoming the preferred imaging modality for suspected acute appendicitis, particularly in adults. CT is more accurate in the diagnosis of acute appendicitis since it is less operator-dependent than ultrasonography (US). [11]

Therefore, the use of CT has been advocated, so far, in the minority of patients with acute appendicitis that present with atypical clinical features.

Although in most cases the diagnosis of acute appendicitis is usually clear on the basis of clinical features, there is a significant negative laparotomy rate. Therefore, some authorities now recommend CT for all patients with suspected acute appendicitis or for those with equivocal acute appendicitis. CT may also be helpful in the preoperative evaluation of patients undergoing laparoscopic appendectomy. [12]

CT seems to be more sensitive (96% vs. 76%) and accurate (94% vs. 91%) than US in diagnosing acute appendicitis, whereas they are almost equal when it comes to specificity (89% vs. 91%). CT imaging tailored to evaluate acute appendicitis has proven to be particularly successful, with a sensitivity of 100%, a specificity of 95%, a positive predictive value of 97%, a negative predictive value of 100%, and accuracy of 98%. [5][6]

Multidetector-row CT (MDCT) currently has an important role in the diagnosis of acute appendicitis and its severity. Some authors suggest that they can diagnose acute appendicitis with an accuracy of 99%. It is also possible to reconstruct the entire form and position of appendices from successive CT findings because of high-resolution thin-slice MDCT images. [13]

CT examination protocol

The patient is prepared with 800–1000 ml of oral contrast medium for bowel opacification 60–90 min prior to scanning. The scan is performed with the patient in the supine position, following an intravenous injection of 100–120 ml of iodinated contrast medium at a rate of 3 ml/s and a scan delay of approximately 60 s. The combination of oral and intravenous contrast medium provides the most information about the inflamed appendix and the surrounding tissues. [14]

It was reported that oral administration of up to 800 ml of the contrast medium at least 1 h before CT scanning enables opacification of both the small bowel and the right colon in most patients. [15]

CT appearance of appendicitis

The appearance of appendicitis on CT depends on the extent and severity of inflammation and the presence or absence of complications. Inflammation of the appendix results from obstruction of its lumen from fecaliths, foreign bodies, lymphoid hyperplasia, parasites or tumours (primary or metastatic). A prompt and accurate diagnosis of acute appendicitis significantly decreases morbidity and mortality. Although in most cases clinical symptoms and signs may strongly suggest a diagnosis of acute appendicitis, the clinical presentation is atypical in 20% of cases, while in another 20% the condition is misdiagnosed. The clinical features in children are often atypical, with generalised rather than localised abdominal pain, whereas in the elderly there is a wider range of differential diagnosis than in the younger population because of the frequency of age-related diseases, such as diverticulitis. The diagnosis may also be delayed in the elderly as they complain less of pain than younger patients do and clinical signs are less pronounced. There is also an increased risk of misdiagnosis in young females because gynaecological diseases can mimic acute appendicitis. Women suspected of having appendicitis benefit mostly from preoperative CT or US, and they have a significantly lower negative appendectomy rate than do women who do not undergo preoperative imaging. [12]

For some female patients, clinicians order pelvic US to be performed within 24 h of a CT study. The diagnosis of acute appendicitis is usually based on clinical symptoms and laboratory tests; however, one third of patients with acute appendicitis show atypical clinical symptoms and physical findings. In this group of patients radiological imaging can play an important clinical role. The inflamed appendix shows a variable degree of distension, has a diameter measuring 6–40 mm and a wall thickness of 1–3 mm. The wall is usually asymmetrically thickened and enhances with an intravenous contrast medium. [16] As the disease progresses, a periappendiceal inflammatory mass called phlegmon may develop.

Thickening and enhancement with an intravenous contrast medium may also be observed in the adjacent wall of the cecum or ileum if they are involved in the inflammatory process. Progression of the inflammatory process may lead to the findings ranging from a sealed abscess to widespread incidence of abdominal inflammatory seeding with multiple abscesses. An abscess with a well-defined border usually indicates chronicity, and the presence of air bubbles or air fluid levels inside indicates the presence of gas-forming organisms or the communication of the abscess with the bowel. If periappendiceal fat is involved in the inflammatory process then it shows an increased haziness, streaky densities and/or fluid collection. In 30% of appendicitis cases the arrowhead sign is present and it has 100% specificity. It describes focal thickening of the cecal wall around the root of the appendix, which funnels toward the point of obstruction of the appendiceal lumen. [17]

6. Patients and methods

We conducted a study that was conducted on 100 consecutive patients admitted to the emergency department of Tlemcen with a clinical diagnosis of suspected acute appendicitis during the period from March to July 2011. Patients of all ages and both sexes presenting to the emergency room with pain in the lower right quadrant of the abdomen were included in the study. Patients with signs of urological, gynaecological and surgical procedures other than appendicitis, particularly patients with right iliac fossa mass, were excluded from the study.

All enrolled patients were hospitalised and first evaluated by surgeons: clinical examination, blood count, urine microscopy and a routine examination, and the abdomen without preparation were all performed. Next, a case was completed for each patient by a student in surgery. These files recorded general information about patients using more than eight variables based on the Alvarado scoring system. From the calculation of the Alvarado score for each patient, stratification was stable and the patients were divided into three groups.

1. An Alvarado between 7-10 (emergency surgery group): these patients were prepared and all underwent an emergency appendectomy.
2. Alvarado between 4-6 (observation group): these patients were admitted and randomly placed into two groups: one group was subjected to repeated clinical examinations for 24 hours and the other to a CT scan. For the first group, the patients were kept under observation for 24 hours with frequent reassessment of the clinical data. The condition of some patients has improved within an hour, as represented by a decrease in the score and – therefore – they came out with instructions that they should return if symptoms persist or increased in intensity.

3. An Alvarado between 1-4: these patients, after being given initial symptomatic treatment, were released and sent home with instructions to return if symptoms persisted or their condition worsened.

The diagnosis of acute appendicitis was confirmed by the operative findings and the histopathological evaluation of the specimen appendectomy.

Finally, the reliability of the Alvarado ratings was assessed by calculating the negative appendectomy rate (the proportion of surgical patients with a normal appendix), which was 19.

7. Results

We conducted our study on patients with clinical features suggestive of acute appendicitis. A total of 100 patients were enrolled in this study. All patients who received conservative treatment were excluded from the study. In addition, five patients with a mass at the appendix, were also excluded from the study.

Of the 100 patients, 59 were female (59%) and 41 were male (41%) (the ratio of men to women was 1:1.4). The average age was 33.5 years (range 3-64 years). Most patients were younger.

The group results were good, as follows: we received 25 patients (25%) with a score of 1-4 Alvarado (Among whom 10 were female and 15 were male). All were released after the initial evaluation and symptomatic treatment. 3 patients were readmitted for a recurrence of pain with a typical picture of acute appendicitis and a score of 7 or more in 48 hours. They were admitted and underwent an appendectomy. Histopathological examination of part of appendicitis revealed in all patients an acute inflammation of the appendix and operative findings and histopathological reports have shown that all 3 patients had confirmed inflamed appendices.

51 patients (51%) had a score of 4-6. In the group of patients undergoing a CT scan, the morphological diagnosis of acute appendicitis was made in all cases (i.e. in 12 patients). In the second group subjected to repeated clinical examination, 5 patients progressed to acute appendicitis and were admitted to the operating room (appendicitis was confirmed by histopathology); 7 patients have had regression of the clinical picture and were released with symptomatic treatment.

8. Discussion and conclusions

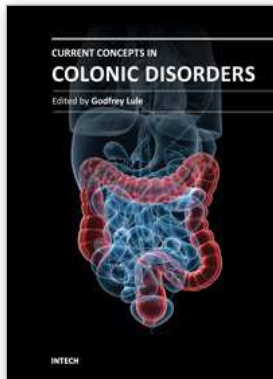
A healthy appendix on appendectomy should no longer exist given the sensitivity of the scanner before the critical period of suspected appendicitis. The Alvarado score was an artefact of size which serves to give greater assistance with diagnosis, especially among young surgeons.

The history, physical examination, temperature scanning of the complete blood count and abdominal defence are useful for achieving a more accurate diagnosis. In developed countries, advanced technology such as CT scans and laparoscopy are available and are useful in establishing a treatment regimen, but in less developed facilities such reviews are not so readily available in most hospitals and are also costly to do, especially if we advocate a careful and repeated clinical examination of 24 to 48 hours by experienced clinicians for patients with scores of 4 to 6. In fact, we cannot rely on a single survey (which counts as low level evidence), but rather must rely on a combination of complete physical examination and routine laboratory tests, such as complete blood count. The Alvarado score helped the medical decision-making for both senior surgeons and beginners.

The abdominal CT scan is the best way to test for acute appendicitis when the score is between 4 and 6. However, cost, feasibility and availability of this review still leave room for repeated examination, which requires hospitalization for 24 to 48 hours

9. References

- [1] Stephens PL, Mazzucco JJ. Comparison of ultrasound and the Alvarado score for the diagnosis of acute appendicitis. *Conn Med* 1999;63:137-40.
- [2] Lally KP, Cox CS, Andrassy RJ. Appendix. In: Townsend CM, Beauchamp RD, Evers BM, Mattox KL, editors. *Sabiston textbook of surgery: the biological basis of modern surgical practice*. 16th ed. Philadelphia: WB Saunders; 2001. p 917-28.
- [3] Ellis H, Nathanson LK. Appendix and appendectomy. In: Zinner MJ, Schwartz SI, Ellis H, editors. *Maingot's abdominal operations*. 10th ed. Stamford, CT: Appleton & Lange; 1997. p 1191-1227.
- [4] Hale DA, Molloy M, Pearl RH, Schutt DC, Jaques DP. Appendectomy: a contemporary appraisal. *Ann Surg* 1997 Mar;225(3):252-61.
- [5] Cuschieri A. The small intestine and vermiform appendix; In: Cuschieri A, G R, A R Mossa.(ed). *Essential surgical practice*. 3rd ed. London: Butter worth Heinman. 1995;1325-8
- [6] Pal KM, Khan A. Appendicitis, a continuing challenge. *J Pak Med Assoc* 1998;48:189-92.
- [7] Kumar V, Cotran RS, Robbins SL. Appendix; In *Robbin's Basic Pathology*. 5th ed. London:W.B Saunders 1992; 520
- [8] Dado G, Anania G, Baccarani U, Marcotti E, Donini A, Risaliti A et al. Application of a clinical score for the diagnosis of acute appendicitis in childhood. *J Pediatr Surg* 2000;35:1320-2. group. Diagnostic scores for acute appendicitis. *Eur J Surg* 1995;161:273-81
- [9] Fenyo G, Lindberg G, Blind P, Enochsson L, Oberg A. Diagnostic decision support in suspected acute appendicitis: validation of a simplified scoring system. *Eur J Surg* 1997;163:831-8.
- [10] Alverado A. A practical score for the early diagnosis of acute appendicitis. *Ann Emerg Med* 1986;15:557-65.
- [11] Bursali A, Arac M, Oner YA, Celik H, Eksioglu S, Gumus T. Evaluation of the normal appendix at low -dose non-enhanced spiral CT. *Diagn Interv Radiol* 2005;11:45-50.
- [12] Ghiatas AA, Chopra S, Chintapalli KN. Computed tomography of the normal appendix and acute appendicitis. *Eur Radiol* 1997; 7:1043-1047.
- [13] Miki T, Ogata S, Uto M. Enhanced multidetector- row computed tomography (MDCT) in the diagnosis of acute appendicitis and its severity. *Radiat Med* 2005; 23:242-255.
- [14] Rao PM, Rhea JT, Novelline RA. Helical CT technique for the diagnosis of appendicitis: prospective evaluation of a focused appendix CT examination. *Radiology* 1997; 202:139-144.
- [15] Wijetunga R, Tan B, Rouse J. Diagnostic accuracy of focused appendiceal CT in clinically equivocal cases of acute appendicitis. *Radiology* 2001; 221:747-753.
- [16] Rao PM, Rhea JT, Novelline RA. Helical CT combined with contrast material administered only through the colon for imaging of suspected appendicitis. *AJR Am J Roentgenol* 1997; 169:1275-1280.
- [17] Oliak D, Yamini D, Udami VM. Nonoperative management of perforated appendicitis without periappendiceal mass. *Am J Surg* 2000; 179:177-181.



Current Concepts in Colonic Disorders

Edited by Dr. Godfrey Lule

ISBN 978-953-307-957-8

Hard cover, 276 pages

Publisher InTech

Published online 05, January, 2012

Published in print edition January, 2012

The 21st Century has seen a resurgence of research of the gastrointestinal tract, especially since it was established that it plays a central role as an immune system organ and consequentially has a huge impact on causation, impact and transmission of most human ailments. New diseases such as the Acquired Immunodeficiency Syndrome, hepatitis and tumours of the gastrointestinal tract have emerged and they are currently subjects of intensive research and topics of scientific papers published worldwide. Old diseases like diarrhea have become extremely complex to diagnose with new and old pathogens, drugs, tumours and malabsorptive disorders accounting for the confusion. This book has set out algorithms on how to approach such conditions in a systematic way both to reach a diagnosis and to make patient management cheaper and more efficient. "Current Concepts in Colonic Disorders" attempts to put all the new information into proper perspective with emphasis on aetiopathogenesis and providing rational approach to management of various old and new diseases. As the book editor, I have found this first edition extremely interesting and easy to understand. Comments on how to improve the content and manner of presentation for future editions are extremely welcome.

How to reference

In order to correctly reference this scholarly work, feel free to copy and paste the following:

S. Loudjedi, M. Bensenane, N. Meziane, F. Ghirane and M. Kherbouche (2012). Alvarado Score Between 4 and 6, the Place of the CT Scan, Current Concepts in Colonic Disorders, Dr. Godfrey Lule (Ed.), ISBN: 978-953-307-957-8, InTech, Available from: <http://www.intechopen.com/books/current-concepts-in-colonic-disorders/alvarado-score-between-4-and-6-the-place-of-the-ct-scan>

INTECH
open science | open minds

InTech Europe

University Campus STeP Ri
Slavka Krautzeka 83/A
51000 Rijeka, Croatia
Phone: +385 (51) 770 447
Fax: +385 (51) 686 166
www.intechopen.com

InTech China

Unit 405, Office Block, Hotel Equatorial Shanghai
No.65, Yan An Road (West), Shanghai, 200040, China
中国上海市延安西路65号上海国际贵都大饭店办公楼405单元
Phone: +86-21-62489820
Fax: +86-21-62489821

© 2012 The Author(s). Licensee IntechOpen. This is an open access article distributed under the terms of the [Creative Commons Attribution 3.0 License](#), which permits unrestricted use, distribution, and reproduction in any medium, provided the original work is properly cited.