

## Alveolar Capillary Dysplasia as a Cause of Persistent Pulmonary Hypertension

**ABDUL RAZAK, PANKAJ KUMAR MOHANTY AND KARTHIK NAGESH N**

*From Department of Neonatology, Manipal Hospital, Bangalore, India.*

*Correspondence to:*  
*Dr N Karthik Nagesh,*  
*Head, Department of Neonatology,*  
*Manipal Group of Hospitals,*  
*Bangalore, India.*  
*drkarthiknagesh@gmail.com*  
*Received: April 07, 2015;*  
*Initial review: May 20, 2015;*  
*Accepted: August 21, 2015.*

**Background:** Persistent pulmonary hypertension (PPHN) in a term or late preterm has varied etiology. **Case characteristics:** A late preterm neonate operated for esophageal atresia with tracheo-esophageal fistula was complicated by severe pulmonary hypertension and unable to be weaned off from respiratory support. **Outcome:** The neonate expired by 15 weeks of life; diagnosis was made on postmortem lung biopsy. **Message:** Alveolar capillary dysplasia should be considered in a neonate with idiopathic refractory PPHN, if associated with anomalies.

**Keywords:** *Alveolar capillary dysplasia, Esophageal atresia, Late preterm.*

**P**ersistent pulmonary hypertension (PPHN) in the neonates is commonly seen with parenchymal lung diseases (pneumonia, meconium aspiration syndrome) and congenital cardiac diseases. When these are not the underlying cause of pulmonary hypertension, and if it is refractory to usual medical therapies, it presents a diagnostic challenge. We report a late preterm neonate operated for esophageal atresia with severe persistent pulmonary hypertension where the diagnosis was made on post-mortem lung biopsy.

### CASE REPORT

A 36-weeks gestational age (2560g weight), male, was born to a primigravide mother via emergency LSCS in view of polyhydramnios and preterm prolonged rupture of membranes. The infant was born non-vigorous through meconium stained liquor and required tracheal suctioning with positive pressure ventilation for 30 secs. After stabilization, the infant was transferred to neonatal intensive care unit with high flow oxygen support. The antenatal scans showed evidence of esophageal atresia with trachea-esophageal fistula. Surgical repair was performed after the initial stabilization and the infant was ventilated preoperatively. Respiratory deterioration after 12 hrs necessitated switch to high frequency ventilation from conventional ventilation. Blood gases showed severe respiratory acidosis, X-ray was unremarkable and echocardiogram showed elevated pulmonary pressures. Apart from PPHN, the deterioration was also thought due to chemical pneumonitis, as there was an anastomotic leak visible on dye study performed on 5<sup>th</sup> post-operative day; the leak was managed conservatively. The infant remained ventilator-dependent, and the oxygenation

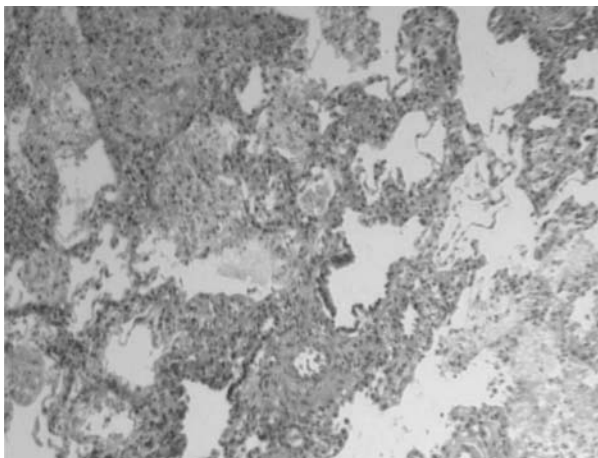
indices (were persistently high, 20). There was severe gastro-esophageal reflux (diagnosed by barium meal) and Ventilator-associated pneumonia, which led to repeated extubation failures. Endotracheal cultures grew *Acinetobacter* and *Pseudomonas*, which were treated with appropriate antibiotics. Feeding jejunostomy was performed at 8 weeks of postnatal life in view of severe gastro-esophageal reflux. Echocardiogram performed initially showed persistent pulmonary hypertension with large Ductus arteriosus (bidirectional shunt with right to left predominance) and partial anomalous pulmonary venous connection (PAPVC). PPHN was managed with nitric oxide, sildenafil, milrinone and bosentan, with marginal improvement. CT angiography was done which confirmed three pulmonary vein opening to left atrium and one vein was stenotic which opened to SVC. The repeat serial echocardiograms showed persistent large ductus arteriosus with shunting now predominantly from left to right and hence a decision to ligate the duct was made. Surgical ligation of hemodynamically-significant ductus arteriosus was performed at 11 weeks of postnatal life. The infant remained ventilator-dependent with high requirements despite feeding jejunostomy and surgical ligation of duct. Clinical discussions favoured primary PPHN and severe Chronic lung disease due to various multiple hits and the same was counselled to parents. Simultaneously, attempts to rule out the primary lung pathology for ventilator dependency were carried further.

Cystic fibrosis screening was negative including the common mutation analysis. High resolution chest CT was done to rule out other possibilities like idiopathic pulmonary fibrosis, pulmonary lymphangiectasia and structural malformations; it showed bilateral lower lobe

collapse, hyperinflated upper lung fields with mild septal prominence and a small airspace cavity in the right paracardiac area, signs of bronchopulmonary dysplasia. Baby remained critically ill with extensive intensive care support, eventually developed cardio-respiratory failure and died on day 103 of life. Histopathological examination of lung was performed after consent from parents; it revealed features consistent with alveolar capillary dysplasia (**Fig. 1**).

## DISCUSSION

Alveolar capillary dysplasia with misalignment of the pulmonary veins (ACD/MPV) is a rare and universally fatal disorder leading to respiratory failure early in life [1]. Most of affected infants present shortly after birth or within 48 hrs of life with hypoxic respiratory failure and are refractory to all medical therapies [2]. Newborns affected with ACD/MPV present with minimal or no parenchymal lung disease and severe idiopathic PPHN. Profound hypoxemia, with partial pressures of oxygen in arterial blood less than 30 mm Hg, and severe metabolic acidosis consistent with pulmonary hypertensive crisis and right ventricular failure are nearly always present. ACD/MPV should be suspected in neonates with primary/idiopathic PPHN who fail to respond to pulmonary vasodilator therapy including nitric oxide therapy and ECMO. While most of the affected babies present in neonatal period and expire early; so far four reports have been published of infants presenting with fulminant disease later (5 week to 7 month age) [3-6]. Two of them presented with symptoms serious enough to warrant brief periods of respiratory observation in a neonatal intensive care unit before discharge [3,6], the



**FIG. 1** Misaligned pulmonary veins, scarce dilated pulmonary capillaries located away from alveolar epithelium, absent alveolo-capillary barrier and muscularisation of distal arterioles. (See color image at website).

remaining two appeared asymptomatic and were discharged home as well babies [4,5]. Survival beyond three months after the onset is rare. Diagnosis of ACD/MPV is made only on histological grounds, characterized by misaligned pulmonary veins, scarce dilated pulmonary capillaries located away from alveolar epithelium, absent alveolo-capillary barrier, and muscularization of distal arterioles.

Newborns with ACD/MPV have multiple other congenital malformations of gastrointestinal tract, cardiovascular system, and genitourinary system in almost 80% of cases. PAPVC with esophageal atresia and tracheoesophageal fistula in our case with progressive pulmonary insufficiency prompted us to perform lung biopsy to rule out ACD/MPV. Antemortem lung biopsy was offered to parents; however it was not performed because of unstable clinical condition. Early diagnosis of this condition would prevent the newborn with ACD/MPV to undergo invasive therapies. However, CT scan performed showed dilated central pulmonary arteries; this finding was not given much importance and could have helped us in early diagnosis [7].

About 10% of alveolar capillary dysplasia are reported to have familial association [8]. Candidate gene involvement is now being researched and some case reports showed haplo-insufficiency for the fork-head *FOX* transcription factor gene cluster which may present in 40% of cases [9]. Genetic testing was not performed in our case.

The clinical approach to newborns with ACD/MPV is on the same lines as that for persistent primary pulmonary hypertension [10]. Index of suspicion should be high if a neonate with idiopathic PPHN is a non-responder to usual medical therapies and especially if there are any associated anomalies of the gastrointestinal, genitourinary, and cardiovascular systems. Early diagnosis by histologic evaluation of antemortem lung biopsy in these neonates warrants against unnecessary therapies and prolongation of medical treatment.

*Contributors:* All authors were involved in patient-management, and contributed to the review of literature. All authors approved the final version of the manuscript.

*Funding:* None; *Competing interests:* None stated.

## REFERENCES

1. Bishop NB, Stankiewicz P, Steinhorn RH. Alveolar capillary dysplasia. *Am J Respir Crit Care Med.* 2011;184:172-9.
2. Janney CG, Askin FB, Kuhn C. Congenital alveolar capillary dysplasia—an unusual cause of respiratory distress in the newborn. *Am J Clin Pathol.* 1981;76:722-7.
3. Ahmed S, Ackerman V, Faught P, Langston C. Profound

- hypoxemia and pulmonary hypertension in a 7-month-old infant: late presentation of alveolar capillary dysplasia. *Pediatr Crit Care Med.* 2008;9:e43-e6.
4. Abdallah HI, Karmazin N, Marks LA. Late presentation of misalignment of lung vessels with alveolar capillary dysplasia. *Crit Care Med.* 1993;21:628-30.
  5. Shankar V, Haque A, Johnson J, Pietsch J. Late presentation of alveolar capillary dysplasia in an infant. *Pediatr Crit Care Med.* 2006;7:177-9.
  6. Shehata BM, Abramowsky CR. Alveolar capillary dysplasia in an infant with trisomy 21. *Pediatr Dev Pathol.* 2005;8:696-700.
  7. Marshall GB, Silva CI, English JC, Levy RD, Müller NL. Misplaced pulmonary arteries in an adult patient with pulmonary hypertension. *Br J Radiol.* 2010;83:e5-9.
  8. Vassal H, Malone M, Petros A, Winter R. Familial persistent pulmonary hypertension of the newborn resulting from misalignment of the pulmonary vessels (congenital alveolar capillary dysplasia). *J Med Genet.* 1998;35:58-60.
  9. Yu S, Shao L, Kilbride H, Zwick D. Haploinsufficiency of *FOXF1* and *FOXC2* genes associated with lethal alveolar capillary dysplasia and congenital heart disease. *Am J Med Genet.* 2010;152A:1257-62.
  10. Miranda J, Rocha G, Soares H, Vilan A, Brandao O, Guimarães H. Alveolar capillary dysplasia with misalignment of pulmonary veins (ACD/MPV): A case series. *Case Rep Crit Care.* 2013;2013:1-4.
-