



Published in final edited form as:

J Perinat Med. 2010 ; 38(1): 39–44. doi:10.1515/JPM.2009.123.

Amniotic fluid volume in intra-amniotic inflammation with and without culture-proven amniotic fluid infection in preterm premature rupture of membranes

Si Eun Lee, MD, PhD¹, Roberto Romero, MD², Seung Mi Lee, MD¹, and Bo Hyun Yoon, MD, PhD¹

¹Department of Obstetrics and Gynecology, Seoul National University College of Medicine, Seoul, Republic of Korea

²Perinatology Research Branch, Eunice Kennedy Shriver National Institute of Child Health and Human Development, NIH, DHHS. Detroit, Michigan USA

Abstract

Objective—Previous studies reported that the clinical significance of intra-amniotic inflammation with a negative amniotic fluid (AF) culture is similar to that of intra-amniotic inflammation with microbiologically-proven AF infection. However, the magnitude of the fetal inflammatory response in these two conditions is different as gauged by umbilical cord C-reactive protein (CRP) concentrations. We undertook this study to determine if the frequency of oligohydramnios is different in these two conditions.

Methods—The amniotic fluid index (AFI) was measured in 205 patients with preterm premature rupture of membranes (PROM) (≤ 35 weeks). AF was cultured for aerobic and anaerobic bacteria and genital mycoplasmas. Intra-amniotic inflammation was defined as an elevated AF matrix metalloproteinase-8 (MMP-8) concentration (>23 ng/mL). Patients were divided into three groups according to the results of AF culture and the presence or absence of intra-amniotic inflammation: 1) without intra-amniotic inflammation and a negative culture (N=109); 2) with intra-amniotic inflammation and a negative culture (N=44); and 3) a positive culture (N=52).

Results—Patients with a positive culture had a higher frequency of oligohydramnios and a lower median AFI than those with a negative culture but with intra-amniotic inflammation ($p < 0.01$). However, there was no significant difference in the median AFI or in the frequency of oligohydramnios according to the presence or absence of intra-amniotic inflammation among patients with a negative culture ($p > 0.1$).

Conclusion—Oligohydramnios was more frequent in patients with culture-proven AF infection than in those with intra-amniotic inflammation and a negative AF culture.

Keywords

Amniotic fluid infection (AFI); amniotic fluid infection; fetal inflammatory response syndrome (FIRS); intra-amniotic inflammation; oligohydramnios, rupture of membranes

Correspondence to: Bo Hyun Yoon, MD, PhD, Department of Obstetrics and Gynecology, College of Medicine, Seoul National University, Seoul, 110-744, Korea. Tel: 82-2-2702-2826, Fax: 82-2-765-3002, Yoonbh@snu.ac.kr.

This study was presented at the 28th Annual Clinical Meeting of the Society for Maternal–Fetal Medicine, Dallas, TX, Jan. 28-Feb. 2, 2008.

Introduction

Microbial invasion of the amniotic cavity is present in one third of patients with preterm premature rupture of membranes (PROM) and is strongly associated with impending preterm delivery, adverse pregnancy and neonatal outcome [4,24,25]. Previous studies have reported that the clinical significance of intra-amniotic inflammation with a negative culture for microorganisms is similar to that of microbiologically-proven amniotic fluid (AF) infection [25,33]. However, proven AF infection, which is severe enough to yield a positive culture, may reflect a higher microbial burden and elicit a more intense fetal inflammatory response than intra-amniotic inflammation with a negative culture. A previous study documented that fetuses born to mothers with culture-proven AF infection had a higher umbilical cord plasma C-reactive protein (CRP) than those born to mothers with culture-negative intra-amniotic inflammation [10]. This could have different implications for fetal target organs, including the kidney.

Oligohydramnios is frequently present in preterm PROM [18,27,29]. Though the reduced AF volume is partly attributed to the escape of fluid through the site of membrane rupture, microbial invasion of the amniotic cavity and the subsequent fetal inflammatory response syndrome (FIRS) is known to be associated with oligohydramnios, which has been attributed to the decreased fetal urine production [18,30]. The purpose of this study was to determine if proven AF infection is associated with changes in AF volume.

Materials and Methods

Study design

The relationship between AF volume and intra-amniotic inflammation and/or AF infection was examined in 205 singleton pregnancies admitted to our university hospital with the diagnosis of preterm PROM who met the following criteria: (1) preterm pregnancy [gestational age (GA) ≤ 35 weeks]; (2) AF obtained for microbiologic studies by transabdominal amniocentesis or at the time of cesarean delivery; and (3) AF index (AFI) determined before AF retrieval according to the method described by Phelan et al. [19]. Oligohydramnios was defined as $AFI \leq 5$ cm.

Patients were divided into three groups according to the presence or absence of intra-amniotic inflammation and AF culture results: Group 1: patients without inflammation, without infection (a negative AF culture; N=109); Group 2: patients with intra-amniotic inflammation, without infection (a negative AF culture; N=44); and Group 3: patients with a positive AF culture (N=52). Retrieval of AF was performed after written informed consent was obtained. The Institutional Review Board of the participating institution approved the collection and use of these samples and information for research purposes.

AF studies

AF was cultured for aerobic and anaerobic bacteria, as well as genital mycoplasmas (*Mycoplasma hominis* and *Ureaplasma urealyticum*). An aliquot of AF was transported to the laboratory and examined in a hemocytometer chamber to determine the white blood cell (WBC) count. The remaining fluid was centrifuged and stored in polypropylene tubes at -70°C . Matrix metalloproteinase-8 (MMP-8) concentration was measured with a commercially available enzyme-linked immunosorbent assay (Amersham Pharmacia Biotech, Inc, Bucks, UK). The sensitivity of the test was 0.3 ng/mL. Intra- and inter-assay coefficients of variation were $<10\%$, respectively. MMP-8 was used to assess the presence of intra-amniotic inflammation because previous studies indicated that it is a sensitive and specific index of inflammation [1,12,17]. Intra-amniotic inflammation was defined as an elevated AF MMP-8 concentration (>23 ng/mL), as previously reported [17].

Diagnosis of chorioamnionitis

Clinical chorioamnionitis was diagnosed in the presence of maternal temperature of ≥ 37.8 °C and two or more of the following criteria: (1) uterine tenderness; (2) malodorous vaginal discharge; (3) maternal leukocytosis (WBC count of $>15,000$ cells/mm³); (4) maternal tachycardia (>100 beats/min); and (5) fetal tachycardia (>160 beats/min) [3]. Acute histologic chorioamnionitis was diagnosed if acute inflammatory changes were present on examination of the extra-placental membranes or the chorionic plate of the placenta, according to the criteria previously published [31]. Funisitis was diagnosed in the presence of neutrophil infiltration into the umbilical vessel walls or into Wharton's jelly.

Statistical analysis

Proportions were compared with the Fisher's exact test. A Kruskal-Wallis analysis of variance test was used for comparison of continuous variables among groups. Multiple comparisons between groups were performed with the Mann-Whitney U test. The amniocentesis-to-delivery interval was compared using the generalized Wilcoxon test for survival analysis. The interval-to-delivery of patients induced for maternal or fetal indications was treated as a censored observation, with a censoring time equal to the amniocentesis-to-delivery interval. A $P < 0.05$ was considered significant.

Results

The frequency of oligohydramnios (AFI ≤ 5 cm) was 29% (59/205). The prevalence of positive AF culture was 25% (52/205). Microorganisms isolated from the AF included *Ureaplasma urealyticum* (n=37), *Candida* species (n=4), *Streptococcus* species (n=4), *Escherichia coli* (n=3), coagulase-negative *Staphylococcus* (n=3), *Mycoplasma hominis* (n=3), and one isolate each of *Peptostreptococcus* species, *Corynebacterium* species, *Acinetobacter baumannii*, *Burkholderia cepalia*, *Staphylococcus hominis*, and *Staphylococcus epidermidis*. Six patients had polymicrobial infections (4 patients with 2 species, and 2 patients with 3 species of microorganisms).

Table 1 describes the clinical characteristics and pregnancy outcomes of the study population according to the results of AF culture and MMP-8 concentrations. Patients with intra-amniotic inflammation but a negative AF culture (Group 2) had a significantly lower median GA at delivery, and birth weight, and a higher rate of histologic chorioamnionitis and funisitis than those without intra-amniotic inflammation and a negative AF culture (Group 1). However, there was no significant difference in the frequency of oligohydramnios between groups 1 and 2 (26% vs. 16%; $p=0.2$).

There were no significant differences in the clinical characteristics and pregnancy outcomes between patients with intra-amniotic inflammation and a negative AF culture (Group 2) and those with positive AF culture (Group 3), except for the frequency of oligohydramnios, which was higher in group 3 than in group 2 (46% vs. 16%; $p < 0.005$).

Figure 1 shows that patients with a positive AF culture had a lower median AFI than those with a negative culture but with intra-amniotic inflammation (median, 5.1 [range 0–17.5] vs. median 8.4 [range 0–21.9]; $p < 0.01$). However, there was no significant difference in the median AFI according to the presence or absence of intra-amniotic inflammation in patients with a negative AF culture (median, 8.1 [range 0–31.0] vs. median 8.4 [range 0–21.9]; $p=0.8$).

Forty-six percent (24/52) of patients with a positive AF culture had oligohydramnios. Among patients with a positive AF culture, the median GA at amniocentesis and delivery, birth weight, and WBC count in AF, and the frequency of clinical chorioamnionitis (29% vs. 11%), histologic chorioamnionitis (100% vs. 78%), and funisitis (77% vs. 74%) were not significantly

different in patients with or without oligohydramnios. However, patients with oligohydramnios had a shorter interval-to-delivery than those without oligohydramnios (median, 38 hours [range 0–285 hours] vs. median 95 hours [range 7–748 hours]; $p < 0.001$, Figure 2).

Cox proportional hazards model analysis indicated that the presence of oligohydramnios (AFI ≤ 5 cm) was an independent predictor of the interval-to-delivery after adjustment for GA and the AF culture results [hazards ration (HR), 1.8; 95% Confidence interval (CI) (1.3–2.6)].

Comment

Principal findings of this study

1) Oligohydramnios is associated with microbiologically-proven AF infection; 2) among cases with proven AF infection, those with oligohydramnios had a shorter amniocentesis-to-delivery interval than those with an AFI > 5 cm.

AF infection, FIRS and oligohydramnios

Oligohydramnios is often associated with microbial invasion of the amniotic cavity [18,27–30]. Microorganisms in the AF can gain access to the fetus and elicit a systemic FIRS [5,23,26]. Pro-inflammatory cytokines released during FIRS can have effects on multiple fetal organ systems such as the brain and heart, leading to blood flow redistribution and cardiac dysfunction [22,30,34]. Reduction of renal blood flow during FIRS can result in the decrease of fetal urine production and the subsequent oligohydramnios. Indeed, a previous study indicated that umbilical cord plasma concentrations of interleukin-6, which is the hallmark of FIRS, are significantly elevated in fetuses with oligohydramnios and preterm PROM compared with those without oligohydramnios [30]. Therefore, there is solid evidence linking microbial invasion of the amniotic cavity, FIRS and oligohydramnios.

Intra-amniotic inflammation in the absence of proven AF infection

A novel finding of this study is that among patients with intra-amniotic inflammation, those with proven AF infection had a decreased AF volume, whereas those with a negative AF culture did not. Substantial evidence indicates that intra-amniotic inflammation is a risk factor for adverse pregnancy and neonatal outcome, regardless of the presence or absence of a positive AF culture [2,7–9,16,25,33,34]. However, the data presented herein demonstrates that a culture-proven infection has clinical implications beyond the presence of intra-amniotic inflammation with a negative AF culture in preterm PROM. This finding suggests that FIRS, in cases with intra-amniotic inflammation with a negative culture, may be milder than the one associated with a positive AF culture. Milder cases of FIRS may not be severe enough to cause a reduction of fetal urine production, which appears to occur in cases with proven AF infection and more severe FIRS. Indeed, studies in adults indicate that there is disease progression which begins with a systemic inflammatory response and advanced to sepsis, severe sepsis and septic shock [11,20].

We propose that fetuses with a positive AF cultures have a more severe systemic inflammatory response compared to those with intra-amniotic inflammation with a negative culture. Support for this hypothesis is derived from a prior report indicating that among patients with intra-amniotic inflammation, those with proven infection had a higher concentration of umbilical cord plasma CRP than those with a negative AF culture [10].

Intensity of FIRS

This study suggests that fetuses with positive AF cultures have a greater degree of systemic fetal inflammation compared to those with intra-amniotic inflammation and negative AF cultures. Why the difference? Intra-amniotic inflammation in the absence of proven AF

infection is commonly considered to be attributed to infection in which organisms escaped detection by traditional microbiological methods [15,32]. It is possible that the microbial burden of patients with a positive culture is greater than that of those with a negative culture. Small inoculum size of microorganisms probably contributed to the failure of cultivation. It is also possible that microorganisms recovered with culture techniques may be more virulent than those who resist cultivation in the laboratory.

FIRS in proven AF infection

AF infection is associated with immune responses [6,13,21], and FIRS has been also understood as an immune response, which can signal the initiation of parturition for the fetus to exit a hostile intrauterine environment [23]. Of interest, our data showed that among cases with proven AF infection, patients with oligohydramnios had an increased risk for impending delivery compared to those with normal AF volume. This suggests that fetuses with oligohydramnios in the presence of proven AF infection probably have an advanced stage of FIRS. However, this cannot be addressed with current data because the difference in the magnitude of FIRS between cases with and without oligohydramnios was not examined. Such issue requires a large cohort consisting of fetuses whose umbilical cord blood was retrieved at the time of AFI determination.

Unanswered questions, limitations and further considerations

Further studies are required to determine if oligohydramnios in the presence of proven AF culture is associated with a worse neonatal outcome. This question cannot be addressed with the sample size in this study.

Clinical implication in this study

This investigation indicated that oligohydramnios is associated with microbiologically proven AF infection, and that among cases with proven AF infection, patients with oligohydramnios had an increased risk for impending delivery compared with those with a normal AFI. Indeed, several studies have reported a higher frequency of sepsis in neonates born to mothers with oligohydramnios [14,28–30]. Therefore, we propose that the presence of oligohydramnios combined with the results of AF culture should be considered when planning the management of patients presenting preterm PROM.

Acknowledgments

This work was supported in part by Korea Science and Engineering Foundation (KOSEF) grant funded by the Korea government (MOST) (No. R01-2006-000-10607-0) and in part by the Intramural Research Program of the *Eunice Kennedy Shriver* National Institute of Child Health and Human Development, NIH, DHHS..

References

1. Angus SR, Segel SY, Hsu CD, Locksmith GJ, Clark P, Sammel MD, et al. Amniotic fluid matrix metalloproteinase-8 indicates intra-amniotic infection. *Am J Obstet Gynecol* 2001;185:1232–1238. [PubMed: 11717662]
2. Erez O, Romero R, Hoppensteadt D, Fareed J, Chaiworapongsa T, Kusanovic JP, et al. Premature labor: a state of platelet activation? *J Perinat Med* 2008;36(5):377–387. [PubMed: 18958919]
3. Gibbs RS, Blanco JD, St Clair PJ, Castaneda YS. Quantitative bacteriology of amniotic fluid from women with clinical intra-amniotic infection at term. *J Infect Dis* 1982;145:1–8. [PubMed: 7033397]
4. Gibbs RS, Romero R, Hillier SL, Eschenbach DA, Sweet RL. A review of premature birth and subclinical infection. *Am J Obstet Gynecol* 1992;166:1515–1528. [PubMed: 1595807]
5. Gomez R, Romero R, Ghezzi F, Yoon BH, Mazor M, Berry SM. The fetal inflammatory response syndrome. *Am J Obstet Gynecol* 1998;179:194–202. [PubMed: 9704787]

6. Hamill N, Romero R, Gotsch F, Pedro Kusanovic J, Edwin S, Erez O, et al. Exodux-1 (CCL20): evidence for the participation of this chemokine in spontaneous labor at term, preterm labor, and intrauterine infection. *J Perinat Med* 2008;36(3):217–227. [PubMed: 18576931]
7. Kim KW, Romero R, Park HS, Park CW, Shim SS, Jun JK, et al. A rapid matrix metalloproteinase-8 bedside test for the detection of intraamniotic inflammation in women with preterm premature rupture of membranes. *Am J Obstet Gynecol* 2007;197:292. e1–5. [PubMed: 17826425]
8. Kusanovic JP, Romero R, Mazaki-Tovi S, Chaiworapongsa T, Mittal P, Gotsch F, Erez O, Vaisbuch E, Edwin SS, Than NG, Camacho N, Pacora P, Rogers W, Hassan SS. Resistin in amniotic fluid and its association with intra-amniotic infection and inflammation. *J Matern Fetal Neonatal Med* 2008 Dec;21:902–916. [PubMed: 19065463]
9. Lee SE, Han BD, Park IS, Romero R, Yoon BH. Evidence supporting proteolytic cleavage of insulin-like growth factor binding protein-1 (IGFBP-1) protein in amniotic fluid. *J Perinat Med* 2008;36(4): 316–323. [PubMed: 18598121]
10. Lee SE, Romero R, Jung H, Park CW, Park JS, Yoon BH. The intensity of the fetal inflammatory response in intra-amniotic inflammation with and without microbial invasion of the amniotic cavity. *Am J Obstet Gynecol* 2007;197:294. e1–6. [PubMed: 17826426]
11. Levy MM, Fink MP, Marshall JC, Abraham E, Angus D, Cook D, et al. 2001 SCCM/ESICM/ACCP/ATS/SIS International Sepsis Definitions Conference. *Crit Care Med* 2003;31:1250–1256. [PubMed: 12682500]
12. Maymon E, Romero R, Chaiworapongsa T, Kim JC, Berman S, Gomez R, et al. Value of amniotic fluid neutrophil collagenase concentrations in preterm premature rupture of membranes. *Am J Obstet Gynecol* 2001;185:1143–1148. [PubMed: 11717648]
13. Mazaki-Tovi S, Romero R, Kusanovic JP, Erez O, Gotsch F, Mittal P, et al. Visfatin/Pre-B cell colony-enhancing factor in amniotic fluid in normal pregnancy, spontaneous labor at term, preterm labor and prelabor rupture of membranes: an association with subclinical intrauterine infection in preterm parturition. *J Perinat Med* 2008;36(6):485–496. [PubMed: 18598235]
14. Mercer BM, Rabello YA, Thurnau GR, Miodovnik M, Goldenberg RL, Das AF, et al. The NICHD-MFMU antibiotic treatment of preterm PROM study: impact of initial amniotic fluid volume on pregnancy outcome. *Am J Obstet Gynecol* 2006;194:438–445. [PubMed: 16458643]
15. Miralles R, Hodge R, McParland PC, Field DJ, Bell SC, Taylor DJ, et al. Relationship between antenatal inflammation and antenatal infection identified by detection of microbial genes by polymerase chain reaction. *Pediatr Res* 2005;57:570–577. [PubMed: 15695603]
16. Park CW, Lee SM, Park JS, Jun JK, Romero R, Yoon BH. The antenatal identification of funisitis with a rapid MMP-8 bedside test. *J Perinat Med* 2008;36:497–502. [PubMed: 19127606]
17. Park JS, Romero R, Yoon BH, Moon JB, Oh SY, Han SY, et al. The relationship between amniotic fluid matrix metalloproteinase-8 and funisitis. *Am J Obstet Gynecol* 2001;185:1156–1161. [PubMed: 11717650]
18. Park JS, Yoon BH, Romero R, Moon JB, Oh SY, Kim JC, et al. The relationship between oligohydramnios and the onset of preterm labor in preterm premature rupture of membranes. *Am J Obstet Gynecol* 2001;184:459–462. [PubMed: 11228503]
19. Phelan JP, Ahn MO, Smith CV, Rutherford SE, Anderson E. Amniotic fluid index measurements during pregnancy. *J Reprod Med* 1987;32:601–604. [PubMed: 3309290]
20. Rangel-Frausto MS, Pittet D, Costigan M, Hwang T, Davis CS, Wenzel RP. The natural history of the systemic inflammatory response syndrome (SIRS). A prospective study. *JAMA* 1995;273:117–123. [PubMed: 7799491]
21. Romero R, Espinoza J, Hassan S, Gotsch F, Kusanovic JP, Avila C, et al. Soluble receptor for advanced glycation end products (sRAGE) and endogenous secretory RAGE (esRAGE) in amniotic fluid: modulation by infection and inflammation. *J Perinat Med* 2008;36(5):388–398. [PubMed: 18593373]
22. Romero R, Espinoza J, Gonçalves LF, Gomez R, Medina L, Silva M, et al. Fetal cardiac dysfunction in preterm premature rupture of membranes. *J Matern Fetal Neonatal Med* 2004;16:146–157. [PubMed: 15590440]
23. Romero R, Gomez R, Ghezzi F, Yoon BH, Mazor M, Edwin SS, et al. A fetal systemic inflammatory response is followed by the spontaneous onset of preterm parturition. *Am J Obstet Gynecol* 1998;179:186–193. [PubMed: 9704786]

24. Romero R, Quintero R, Oyarzun E, Wu YK, Sabo V, Mazor M, et al. Intra-amniotic infection and the onset of labor in preterm premature rupture of the membranes. *Am J Obstet Gynecol* 1988;159:661–666. [PubMed: 3421266]
25. Shim SS, Romero R, Hong JS, Park CW, Jun JK, Kim BI, et al. Clinical significance of intra-amniotic inflammation in patients with preterm premature rupture of membranes. *Am J Obstet Gynecol* 2004;191:1339–1345. [PubMed: 15507963]
26. Smulian JC, Vintzileos AM, Lai YL, Santiago J, Shen-Schwarz S, Campbell WA. Maternal chorioamnionitis and umbilical vein interleukin-6 levels for identifying early neonatal sepsis. *J Matern Fetal Med* 1999;8:88–94. [PubMed: 10338061]
27. Vintzileos AM, Campbell WA, Nochimson DJ, Connolly ME, Fuenfer MM, Hoehn GJ. The fetal biophysical profile in patients with premature rupture of the membranes—an early predictor of fetal infection. *Am J Obstet Gynecol* 1985;152:510–516. [PubMed: 4014344]
28. Vintzileos AM, Campbell WA, Nochimson DJ, Weinbaum PJ. Degree of oligohydramnios and pregnancy outcome in patients with premature rupture of the membranes. *Obstet Gynecol* 1985;162–167. [PubMed: 3895069]
29. Vintzileos AM, Campbell WA, Nochimson DJ, Weinbaum PJ, Escoto DT, Mirochnick MH. Qualitative amniotic fluid volume versus amniocentesis in predicting infection in preterm premature rupture of the membranes. *Obstet Gynecol* 1986;67:579–583. [PubMed: 3515258]
30. Yoon BH, Kim YA, Romero R, Kim JC, Park KH, Kim MH, et al. Association of oligohydramnios in women with preterm premature rupture of membranes with an inflammatory response in fetal, amniotic and maternal compartments. *Am J Obstet Gynecol* 1999;181:784–788. [PubMed: 10521729]
31. Yoon BH, Romero R, Kim CJ, Jun JK, Gomez R, Choi JH, et al. Amniotic fluid interleukin-6: a sensitive test for antenatal diagnosis of acute inflammatory lesions of preterm placenta and prediction of perinatal morbidity. *Am J Obstet Gynecol* 1995;172:960–970. [PubMed: 7892891]
32. Yoon BH, Romero R, Kim M, Kim EC, Kim T, Park JS, et al. Clinical implications of detection of *Ureaplasma urealyticum* in the amniotic cavity with the polymerase chain reaction. *Am J Obstet Gynecol* 2000;183:1130–1137. [PubMed: 11084554]
33. Yoon BH, Romero R, Moon JB, Shim SS, Kim M, Kim G, et al. Clinical significance of intra-amniotic inflammation in patients with preterm labor and intact membranes. *Am J Obstet Gynecol* 2001;185:1130–1136. [PubMed: 11717646]
34. Yoon BH, Romero R, Park JS, Kim CJ, Kim SH, Choi JH, et al. Fetal exposure to an intra-amniotic inflammation and the development of cerebral palsy at the age of three years. *Am J Obstet Gynecol* 2000;182:675–681. [PubMed: 10739529]

Amniotic fluid index

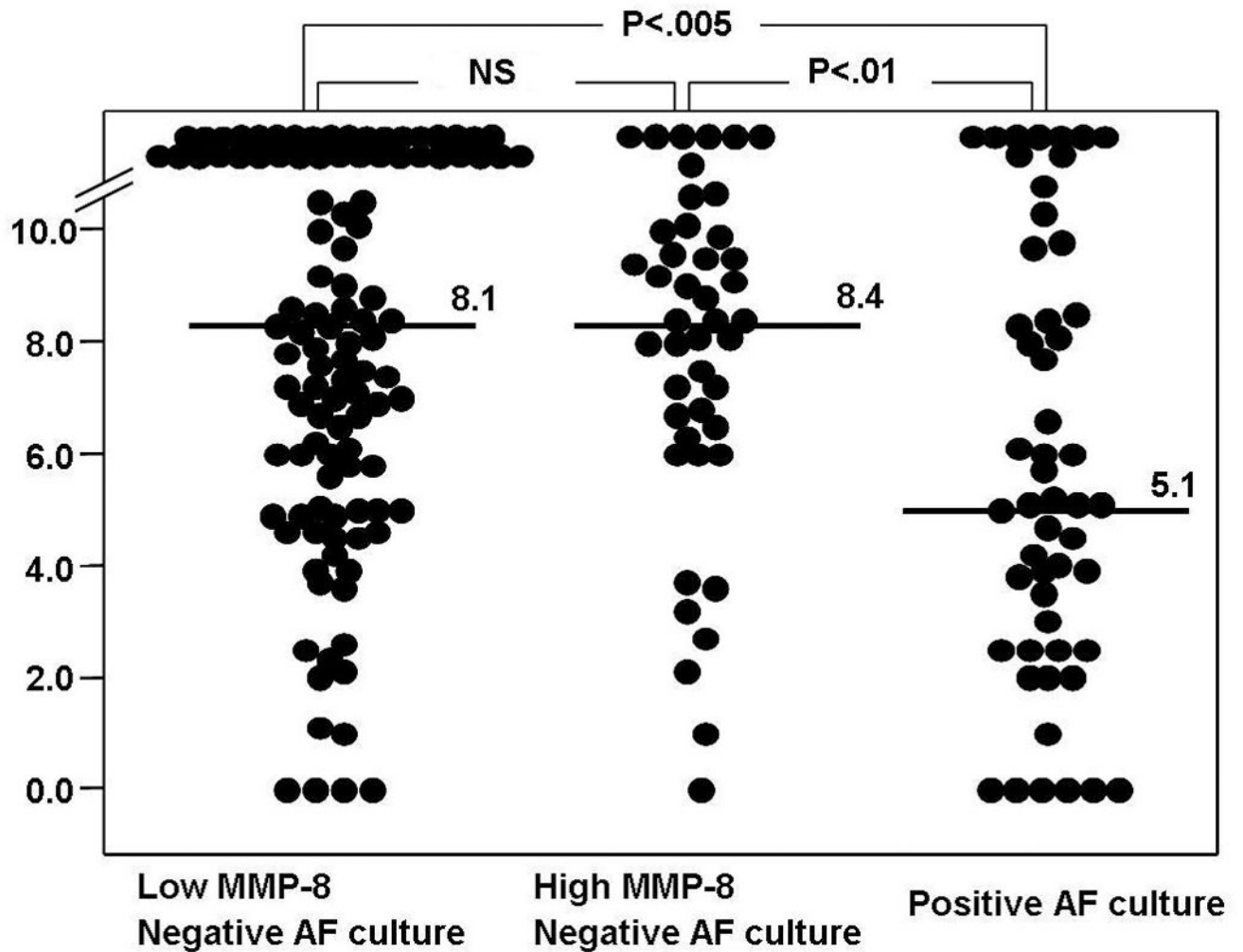


Figure 1.

Amniotic fluid index (AFI) according to the presence or absence of intra-amniotic inflammation and AF culture results: the median AFI in patients with intra-amniotic inflammation and a negative AF culture was significantly higher than that in patients with a positive AF culture, but was not different from that in patients without intra-amniotic inflammation and with a negative AF culture.

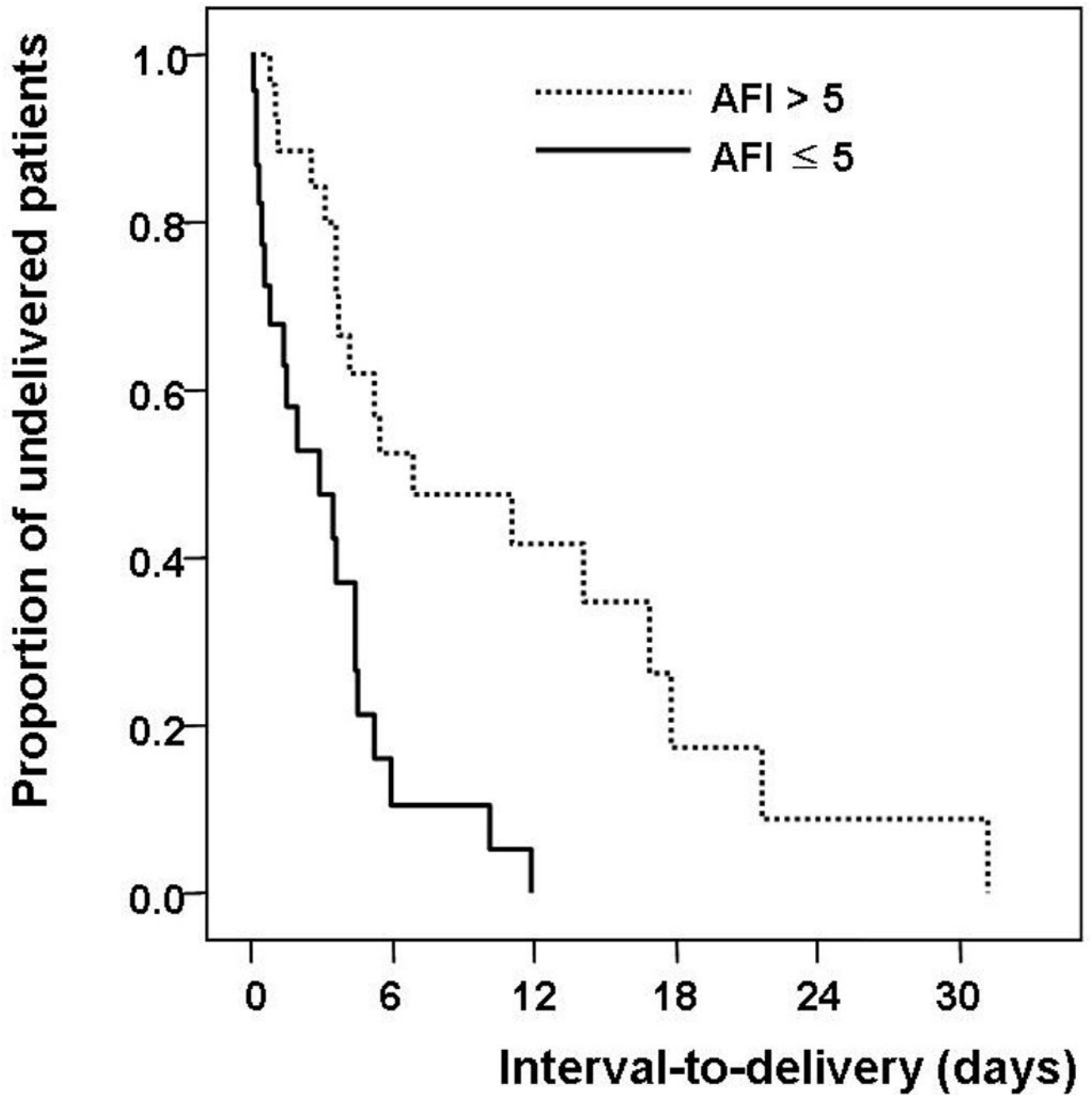


Figure 2. Survival analysis of interval-to-delivery among patients with preterm premature rupture of membranes and amniotic fluid infection according to the presence or absence of oligohydramnios (median, 38 hours; range, 0–285 hours vs. median, 95 hours; range, 7–748 hours; $P < 0.001$)

Table 1

Clinical characteristics and pregnancy outcomes of the study population according to the results of AF culture and MMP-8 concentrations

	(-) AF culture Low MMP-8 (group 1; n=109)	P ^a	(-) AF culture High MMP-8 (group 2; n=44)	P ^b	(+) AF culture (group 3; n=52)	P ^c
Maternal age (years)	30 (20-41)	NS	31 (23-43)	NS	29 (21-43)	NS
Nulliparity (n)	57 (52%)	NS	19 (43%)	NS	22 (42%)	NS
GA at amniocentesis (week) ^d	33.1 (20.4-35.0)	<.001	30.6 (21.7-34.9)	NS	30.8 (22.4-34.7)	<.001
GA at delivery (week) ^d	34.7 (25.0-41.6)	<.001	31.4 (22.3-35.0)	NS	31.5 (23.1-34.9)	<.001
Birth weight (g) ^d	2330 (660-4390)	<.001	1680 (520-2630)	NS	1625 (570-2410)	<.001
Amniocentesis-to-delivery interval (h) ^d	127.8 (2.2-3544.5)	<.001	47.0 (0-881.5)	NS	84.9 (0.2-748.4)	<.001
Preterm delivery (n)						
Within 36 weeks	90 (83%)	<.005	44 (100%)	(-)	52 (100%)	<.001
Within 34 weeks	32 (29%)	<.001	36 (82%)	NS	44 (85%)	<.001
Clinical chorioamnionitis	2 (2%)	NS	3 (7%)	NS	10 (19%)	<.001
Histologic chorioamnionitis (n/N)	41/95 (43%)	<.001	30/34 (88%)	NS	38/44 (86%)	<.001
Histologic chorioamnionitis; delivered \leq 48 h ^e	5/16 (31%)	<.005	14/15 (93%)	NS	16/18 (89%)	<.005
Funisitis (n/N)	18/95 (19%)	<.001	21/34 (62%)	NS	33/44 (75%)	<.001
Funisitis; delivered \leq 48 h ^e	1/16 (6%)	<.005	9/15 (60%)	NS	14/18 (78%)	<.001
AF WBC (cells/mm ³) ^d	1 (0-243)	<.001	414 (0->1000)	NS	314 (0->1000)	<.001
AF MMP-8 (ng/mL) ^d	1.4 (0.3-22.3)	<.001	184.4 (24.9-2874.5)	NS	255.6 (0.4-2370.6)	<.001
Oligohydramnios (AFI \leq 5)	28 (26%)	NS	7 (16%)	<.005	24 (46%)	<.05

Values are medians and ranges

AF, amniotic fluid; MMP-8, matrix metalloproteinase-8; Low MMP-8, matrix metalloproteinase-8 <23 ng/mL; High MMP-8, matrix metalloproteinase-8 >23 ng/mL; GA, gestational age; NS, not significant; WBC, white blood cell

^a Comparison between groups 1 and 2.^b Comparison between groups 2 and 3.^c Comparison between groups 3 and 1.

$P < .05$, by Kruskal-Wallis ANOVA test

§ To preserve a meaningful temporal relationship between the results of AF studies and histologic findings of the placenta obtained at delivery, cases delivered within 48 hours of amniocentesis were considered for the analysis