

Amyand's Hernia – Case Report and Review of the Literature

Ching-Ming Kwok^a Cheng-Hsi Su^c Wei-Kang Kwang^b
Yi-Chou Chiu^a

^aDivision of General Surgery, Department of Surgery, and ^bDepartment of Pathology, Cheng Hsin General Hospital, Taipei, Taiwan; ^cDivision of General Surgery, Department of Surgery, Taipei Veterans General Hospital, National Yang Ming University, Taipei, Taiwan, ROC

Key Words

Amyand's hernia · Inguinal hernia · Acute appendicitis

Abstract

Amyand's hernia is an extremely rare condition in which the appendix is positioned in the inguinal hernia sac. Acute appendicitis is much less common in this situation and few reports are found in the literature. We report a case of acute appendicitis with the tip of the appendix incarcerated outside the external ring of the right groin. A mobilized cecum and ascending colon were noticed during surgery. We conducted a review of the literature, emphasizing possible causes and suggesting a predisposing factor for the condition.

Introduction

Amyand's hernia is an extremely rare condition in which the inguinal hernia sac contains the appendix. This unusual situation is estimated to occur in approximately one percent of adult inguinal hernia cases [1]. The finding of acute appendicitis in Amyand's hernia is much less common. We describe a case of acute appendicitis in the inguinal hernia sac with an incarceration in the external ring; this led to distal appendicitis even though the appendix had a healthy body and base. Our report includes a review of the literature and further evaluation of predisposing factors in this case.

Case Report

An 85-year-old-male arrived at our hospital in 2006 presenting a right groin mass. His history included hypertension, coronary artery disease, and transient infarction accident, of which all were receiving regular medical treatment. Additionally, he had recently experienced urinary frequency and nocturia. A right groin mass had been protruding for 1 month prior to hospital admission, which increased in size when standing and before stool passage, but decreased in size after stool passage or

lying down. Mild tenderness had been noted for 1 week. The mass was not reducible. Our impression was inguinal hernia and the patient was admitted for surgical intervention.

Laboratory data were within normal limits. Blood pressure was well controlled. The patient was scheduled for elective surgery. The oblique conventional incision between external and internal rings was used to achieve a better approach. An appendix was found completely within the indirect sliding hernia sac ([fig. 1](#)). The distal end of the appendix was trapped by the external ring. Swelling and induration protruded outside the external ring toward the scrotum, leaving a mark on the vermiform organ ([fig. 2](#)). The body and base of the appendix was healthy and a moderate amount of clear ascites was found in the hernial sac. The distal portion of the appendix was attached to the distal portion of the hernial sac, which lay outside the external ring of the right groin. The mobilized cecum and ascending colon were far away from the paracolic space, apparently sliding until occupying the neck of the hernial sac. Appendectomy was performed and hernioplasty was done instantly with Bassini's method. The patient's postoperative condition was uneventful and he was discharged on the next day. He was followed up at our OPD one week later and the right groin looked good. Pathology revealed an acute suppurative appendicitis with mixed inflammatory cells in the appendiceal wall, presenting many eosinophils and small foci of granulomatous lesion ([fig. 3](#)).

Discussion

Amyand's hernia is defined as an uninflamed appendix in an inguinal hernia. This rare condition was named after the first surgeon to perform appendectomy, Claudius Amyand, an English surgeon of the 18th century who first described a case of acute appendicitis in a hernial sac in an 11-year-old child [2]. The first appendectomy ever to be performed in the USA, more than a century later, was also a case of Amyand's hernia in which an abscess with gangrenous appendicitis was found inside the hernial sac [3]. The incidence of Amyand's hernia is estimated to occur in approximately one percent of adult inguinal hernia repair cases [1]. Acute appendicitis occurs much less frequently, and perforated appendix and periappendicular abscess formation within an inguinal hernia sac is an extremely rare clinical entity [4]. Ryan presented 11 of 8,692 cases of acute appendicitis occurring in external hernia of all forms [5]. Thomas et al. reviewed seven cases of acute appendicitis in a series of external hernia (three inguinal) collected in 8 years [1]. A detailed description of the historical background and the management of Amyand's hernia was presented by R. Hutchinson in 1993 [6]. Other investigators have infrequently presented case reports and literature reviews [7, 8]. The incidence of acute appendicitis occurring in a hernial sac varies between the 0.13% reported by Ryan et al. in 1937 [2] and the 1% reported by Carey in 1967 [9]. More recently, C. D'Alia and his colleagues reported their unique case of acute appendicitis within the hernial sac in 1,341 inguinal hernia operations performed over 13 years in Messina University Hospital in 2003 [10]. Most reported cases of Amyand's hernia have occurred in the right inguinal region and only a few reported cases have occurred in the left inguinal region [8, 11].

The present case, diagnosed during surgery, is the first case of Amyand's hernia in our hospital, a 40-year-old district hospital with 800 beds. Acute appendicitis only occurred over the tip of the appendix located outside the external ring. The blood supply was affected by the narrowed external ring and distal appendicitis developed subsequently. The body and base of the appendix appeared to be healthy; the wide base of the hernial sac in the internal ring caused the vermiform organ to have a strange appearance. Neither turbid ascites nor pus formation was found inside the hernial sac, making an excellent prognosis. We preferred to perform the repair via the traditional procedure (Bassini's method) to prevent the possibility of infection by the insertion of a foreign body (mesh). Treatment procedures have been well discussed in many recent case reports, including mesh hernioplasty, endoscopic hernioplasty or the traditional method of hernioplasty, although controversy still exists. The necessity for incidental appendectomy in a non-

inflamed appendix also remains debatable [6]. Sharma et al. briefly discussed the management of Amyand's hernia among 18 patients in a 15-year period, including appendectomy followed by Bassini's repair, mesh hernioplasty after reduction of a normal appendix, and Bassini's hernia repair plus a lower midline laparotomy for pelvic washout. His strategy depended on the status of the appendix in the sac [12].

Discussions in recent reports emphasized the incidence and management of Amyand's hernia, highlighting the rarity and causes of the abnormality. Abu-Dalu and Urca have suggested that the appendix becomes more vulnerable to trauma in Amyand's hernia and is ultimately retained by adhesions. Its blood supply may subsequently be cut off or significantly reduced, resulting in inflammation and bacterial overgrowth. Contraction of the abdominal muscles and other sudden increases in intra-abdominal pressure may cause compression of the appendix, resulting in further inflammation [7]. Apart from the above opinions, we found a mobilized cecum and ascending colon in our case, allowing facile advancement of the appendix into the hernial sac. The tip of the appendix proceeded through the narrowed external ring and incarceration developed, followed by adhesion and non-reducibility of the segment. The cecum was pulled close to the internal ring. The congenital anomaly (mobilized ascending colon and cecum) is considered to be a predisposing factor for developing Amyand's hernia.

In addition, our pathology revealed many eosinophils in the inflamed appendix. Most often, the stained white cell differential in acute appendicitis is neutrophil-predominant. Less common, as in our case, is an eosinophil-predominant differential. The situation may be the result of an incarceration but no strangulation of the distal appendix for one week (prolonged reduction of blood supply without complete interruption), leading to a subacute inflammation of the organ. Moreover, the foci of granulomatous lesion further reflect a prolonged inflammatory process.

Preoperative diagnosis in this unusual condition is difficult. Weber was the only surgeon who reported making the correct diagnosis preoperatively [8]. Computed tomography scans may be useful in diagnosis, but are typically not performed routinely. We did not order abdominal CT scanning for our patient because he did not present as an emergency and strangulation was not considered during the preoperative period.

Differential diagnosis should include strangulated hernia, strangulated omentocele, Richter's hernia, testicular tumor with hemorrhage, acute hydrocele, inguinal adenitis, and epididymitis. The treatment for hernial appendicitis is appendectomy through the herniotomy with primary hernia repair using the same incision [13]. Only Lyass et al. reported a delayed wound closure due to a retroperitoneal abscess secondary to the appendicular inflammation [14]. Mesh is not suggested in the contaminated abdominal wall defects because of greater risk of wound infection and appendiceal stump fistula [13]. Laparoscopic reduction of Amyand's hernia has been described previously [15, 16]. The use of prostheses in this practice is still controversial.

Amyand's hernia is a rare condition that has been frequently diagnosed accidentally during a hernioplasty, and especially an incarcerated inguinal hernia diagnosed in the emergency room. It is closely linked to peritoneal spread of the septic process and may be life-threatening, with an incidence of mortality varying between 14 and 30% [9, 17, 18]; mortality risk is most likely associated with perforated appendix with or without periappendicular abscess formation, or even peritonitis. Consequently, our recommendation is that acute appendicitis should be considered as a potential cause for increasing morbidity in patients with incarcerated hernias. Awareness of this clinical entity would be useful in the preoperative evaluation of patients with non-reducible or

incarcerated inguinal hernias. This would likely result in more appropriate planning for surgical intervention.

Fig. 1. The appendix found completely in the right inguinal hernia sac (post herniotomy).

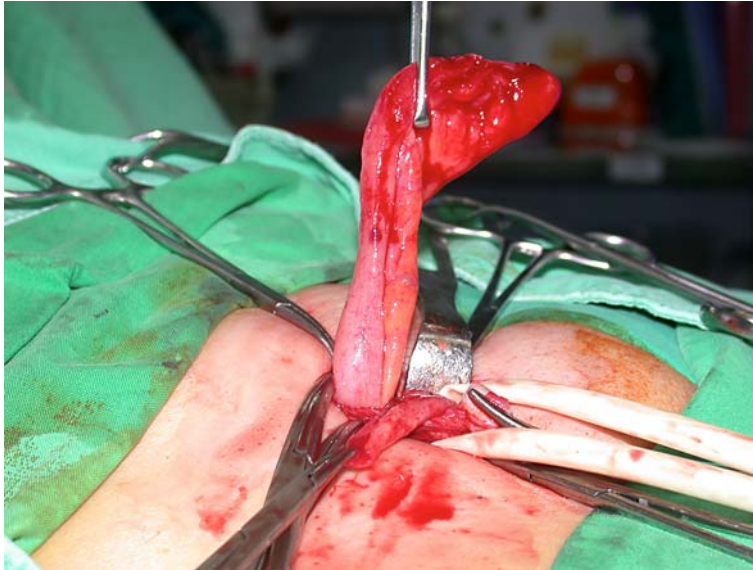

Fig. 2. Distal appendicitis with healthy base. The distal portion of the appendix was tightened over by the external ring, leaving a mark on the vermiform organ.

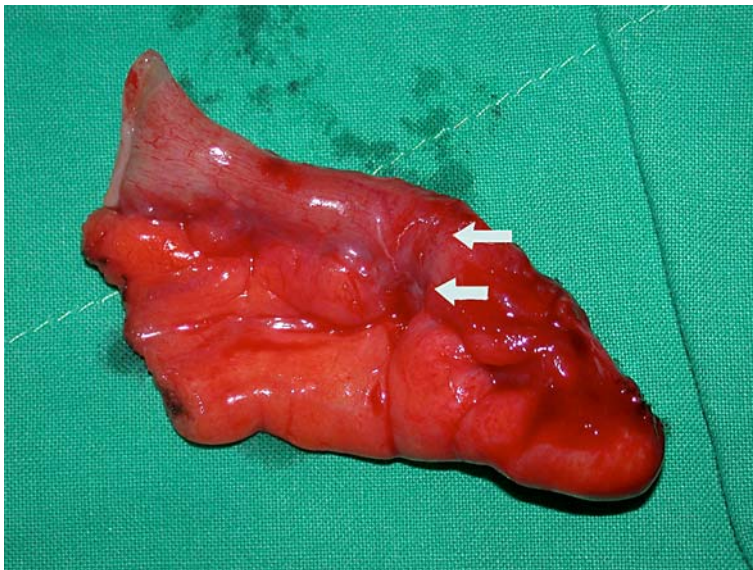
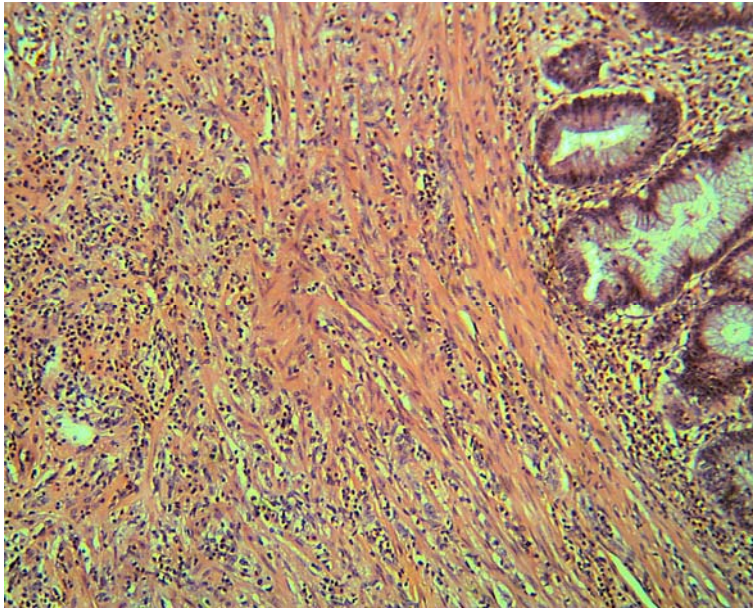


Fig. 3. Pathology. Mixed inflamed cells with eosinophil predominant in the appendiceal wall. HE stain. 100×.



References

- 1 Thomas WEG, Vowles KDJ, Williamson RCN: Appendicitis in external herniae. *Ann R Coll Surg Engl* 1982;64:121–122.
- 2 Amyand C: Of an inguinal rupture, with a pin in the appendix coeci, incrusted with stone; and some observations on wounds in the guts. *Phil Trans Royal Soc* 1736;39:329–342.
- 3 Creese PG: The first appendectomy. *Surg Gynecol Obstet* 1953;97:643–652.
- 4 Salemis NS, et al: Perforated appendix and periappendicular abscess within an inguinal hernia. *Hernia* 2007;10:528–530.
- 5 Ryan WJ: Hernia of the vermiform appendix. *Ann Surg* 1937;106:135–139.
- 6 Hutchinson R: Amyand's hernia. *J R Soc Med* 1993;86:104–105.
- 7 Abu-Dalu J, Urca I: Incarcerated inguinal hernia with a perforated appendix and periappendicular abscess. *Dis Colon Rectum* 1972;15:464–465.
- 8 Weber RV, Hunt ZC, Kraal JG: Amyand's hernia: Etiologic and therapeutic implications of the two complications. *Surg Rounds* 1999;22:552–556.
- 9 Carey LC: Appendicitis occurring in hernias: a report of 10 cases. *Surgery* 1967;61:236–238.
- 10 D'Alia C, et al: Amyand's hernia: case report and review of literature. *Hernia* 2003;7:89–91.
- 11 Gupta S, Sharma R, Kaushik R: Left-sided Amyand's hernia. *Singapore Med J* 2005;46:424–425.
- 12 Sharma H, et al: Amyand's hernia: a report of 18 consecutive patients over a 15-year period. *Hernia* 2007;11:31–35.
- 13 Logan MT, Nottingham JM: Amyand's hernia: a case report of an incarcerated and perforated appendix within an inguinal hernia and review of the literature. *Am Surg* 2001;67:628–629.
- 14 Lyass S, Kim A, Bauer J: Perforated appendicitis within an inguinal hernia: case report and review of the literature. *Am J Gastroenterol* 1997;92:700–702.
- 15 Vermillion JM, Abernathy SW, Snyder SK: Laparoscopic reduction of Amyand's hernia. *Hernia* 1999;3:159–160.
- 16 Luchs JS, Halpern D, Katz DS: Amyand's hernia: prospective CT diagnosis. *J Comput Tomogr* 2000;24:884–886.
- 17 Ottaviani M, Maglio MN, Papa F, Zitarelli V, Alario G, Di Marzo A: Acute gangrenous appendicitis in incarcerated inguinal hernia. A case report. *Minerva Chir* 1997;52:831–833.
- 18 Davies MG, O'Byrne P, Stephens RB: Perforated appendicitis presenting as an irreducible inguinal hernia. *Br J Clin Pract* 1990;44:494–495.