

An Anthropometric Study of Cranio-Facial Measurements and Their Correlation with Vertical Dimension of Occlusion among Saudi Arabian Subpopulations

Muhammed Irfan Majeed¹, Satheesh B. Haralur², Muhammed Farhan Khan¹, Maram Awdah Al Ahmari¹, Nourah Falah Al Shahrani¹, Sharaz Shaik¹

¹Department of Prosthodontics, College of Dentistry, King Khalid University, Kingdom of Saudi Arabia; ²College of Dentistry, King Khalid University, Kingdom of Saudi Arabia

Abstract

Citation: Majeed MI, Haralur SB, Khan MF, Al Ahmari MA, Al Shahrani NF, Shaik S. An Anthropometric Study of Cranio-Facial Measurements and Their Correlation with Vertical Dimension of Occlusion among Saudi Arabian Subpopulations. Open Access Maced J Med Sci. 2018 Apr 15; 6(4):680-686. <https://doi.org/10.3889/oamjms.2018.082>

Keywords: Anthropometric measurements; the Vertical dimension of occlusion; Cranio-facial measurements; Full mouth rehabilitation

***Correspondence:** Satheesh B. Haralur. Department of Prosthodontics, College of Dentistry, King Khalid University, Kingdom of Saudi Arabia. E-mail: hb_satheesh@yahoo.com

Received: 11-Feb-2018; **Revised:** 07-Mar-2018; **Accepted:** 13-Mar-2018; **Online first:** 28-Mar-2018

Copyright: © 2018 Muhammed Irfan Majeed, Satheesh B. Haralur, Muhammed Farhan Khan, Maram Awdah Al Ahmari, Nourah Falah Al Shahrani, Sharaz Shaik. This is an open-access article distributed under the terms of the Creative Commons Attribution-NonCommercial 4.0 International License (CC BY-NC 4.0)

Funding: This research did not receive any financial support

Competing Interests: The authors have declared that no competing interests exist

BACKGROUND: Determining and restoring physiological vertical dimension of occlusion (VDO) is the critical step during complete mouth rehabilitation. The improper VDO compromises the aesthetics, phonetics and functional efficiency of the prosthesis. Various methods are suggested to determine the accurate VDO, including the facial measurements in the clinical situations with no pre-extraction records. The generalisation of correlation between the facial measurements to VDO is criticised due to gender dimorphism and racial differences. Hence, it is prudent to verify the hypothesis of facial proportion and correlation of lower third of the face to remaining craniofacial measurements in different ethnic groups. The objective of the study was to evaluate the correlation of craniofacial measurements and OVD in the Saudi-Arabian ethnic group.

METHODOLOGY: Total of 228 participants from Saudi-Arabian Ethnic group were randomly recruited in this cross-sectional study. Fifteen craniofacial measurements were recorded with modified digital Vernier callipers, and OVD was recorded at centric occlusion. The obtained data were analysed by using the Spearman's correlation and linear regression analysis.

RESULTS: The Mean OVD in male participants was higher (69.25 ± 5.54) in comparison to female participants (57.41 ± 5.32). The craniofacial measurement of Exocanthion-right labial commissure and the Mesial wall of the right external auditory canal-orbitale lateral had a strong positive correlation with VDO. The strong correlation was recorded with a trichion-upper border of right eyebrow line and trichion-Nasion only in males. Meanwhile, the length of an auricle recorded the positive correlation in female participants.

CONCLUSIONS: Being simple and non-invasive technique, craniofacial measurements and linear equations could be routinely utilised to determine VDO.

Introduction

The prosthodontist has an important role in geriatric health care for an ever-increasing elder population with accompanying dental disabilities. The number of patients requiring prosthetic rehabilitation for complete or partial edentulism is continuously growing due to improved life expectancy across the world. The efficient prosthesis to replace the missing teeth helps to palliate the functional, aesthetic and psychological disabilities of the patient.

Complete denture prosthesis includes the replacement of the lost natural dentition and the associated structures of the maxilla and the mandible. Establishing the optimum maxilla-mandibular relations, including correct occlusal vertical dimension is crucial for the successful clinical performance of complete denture [1], implant-supported prosthesis [2] and full mouth rehabilitation for excessive dental attrition. According to the Glossary of Prosthodontic Terms, the occlusal vertical dimension (OVD) is defined as the distance between two selected anatomic or marked points (usually one on the tip of

the nose and the other on the chin) when in maximal intercuspal position [3]. Inaccurate OVD leads to multiple adverse effects on aesthetics, functional efficiency, temporomandibular joints, and masticatory muscles [4]. Furthermore, the improper dimension of the lower third of the face adversely affects the facial expression of the individual. Lack of reliable parameters makes the determination of OVD subjective and challenging task for the clinicians. Majority of researchers are of the opinion; the vertical dimension during denture rehabilitation ideally is similar to the OVD prior to the edentulous situation [5]. The methods to determine the OVD are broadly classified as Pre and Post extraction methods. The proposed pre-extraction methods are pre-extraction diagnostic casts [6], pre-extraction phonetics [7], cephalometric radiograph [8], profile tracing of the lower third of the face [9]. Reliability of these techniques are entirely dependent on the patient presentation in a dentate state. The pre-extraction methods are effective provided acceptable OVD, stable occlusion and satisfactory aesthetics prior to edentulism. Researchers have recommended numerous post extraction methods like physiologic rest position [10], facial aesthetic appearance [11], deglutition [12], cephalometric radiographs [13], post-extraction phonetics [14], measurement of the former dentures [15], fingers length [16] and anthropometric measurement. Anthropometry is the science of measuring the weight, size, and proportions of the human body, providing valuable and objective insights into how to characterize phenotypic variation and dysmorphology [17]. The anthropometric measurements are routinely obtained directly from subjects by utilising the callipers and measuring tapes. The philosophy of anthropometric measurement to determine OVD was derived from the Leonardo Da Vinci drawings, later explored further by researchers like Ivy, Good Friend and Willis. The additional advantages of anthropometry technique are simple, non-invasive, low-risk, and inexpensive

The generalisation of the correlation between craniofacial distances and the OVD is criticised owing to the likelihood of variation due to gender dimorphism and racial differences [18]. The knowledge of the correlation between Anthropometric measurement and OVD in local population will add the objectively during the full mouth rehabilitation with a complete denture, implant-supported prosthesis or fixed prosthesis. The studies on the correlation between Cranio-facial landmark's measurements and OVD in the Saudi-Arabian population are sparse in dental literature.

Hence the present study was designed with an objective to examine the correlation between the Occlusal vertical dimension and Craniofacial measurements in the Saudi-Arabian ethnic group. The objective was also to evaluate the variation of these correlations between male and female gender.

Material and Methods

The study proposal was approved by the institutional research ethics committee, at College of Dentistry, King Khalid University, Saudi Arabia (SRC/ETH/2016-17/037). The study design was a descriptive cross-sectional, and it was conducted between June 2017 to December 2017 in King Khalid University, Abha, Kingdom of Saudi Arabia. Total of 228 participants from Saudi Arabian ethnic groups, consisting of 72 males, 156 females were included in the study. The participants were randomly selected during their visits to King Khalid University dental clinic. The participants were in the age group of 20-40 years and residents across the Southern part of Saudi Arabia. The participants were explained about the study objectives and methodology; the informed consent was obtained. The participants with a full complement of permanent dentition without partial denture, and angle class I jaw relations were included in the study. The individuals with previous orthodontic or prosthodontic treatment, major stomatognathic surgery, temporomandibular disorders, facial deformities, asymmetry and scars in the lower part of the face were excluded from the study.

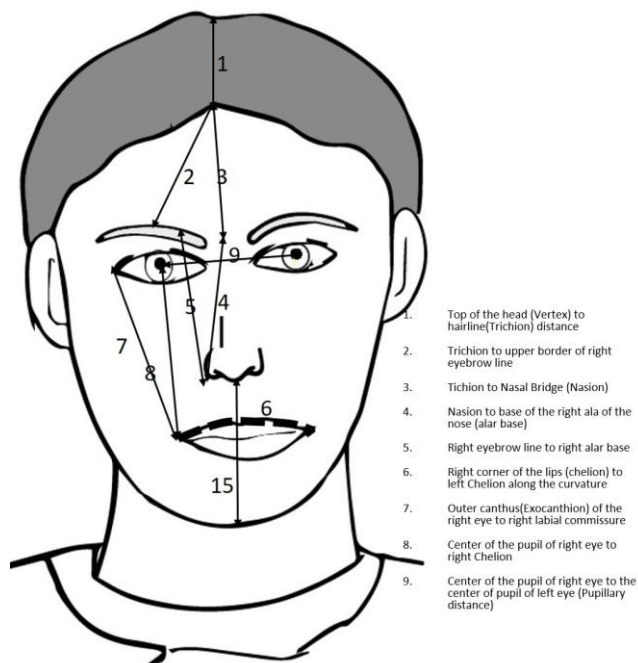


Figure 1: Figure displaying the craniofacial landmarks from 1-9

Before the craniofacial measurements, measurement training methods regarding the position of the participants, instrument handling, landmarks identification and recording procedures were confirmed and unified among the researchers. The digital callipers were calibrated with calibration rods. The facial measurements were recorded by two investigators. The inter-observer reliability was calibrated with a pilot study on 15 participants before the study. Intra-class correlation coefficient test was

performed (ICC value = 0.98, $P < 0.01$) to confirm the inter-observer reliability. The readings were independently recorded by two investigators and average was considered as final measurement.

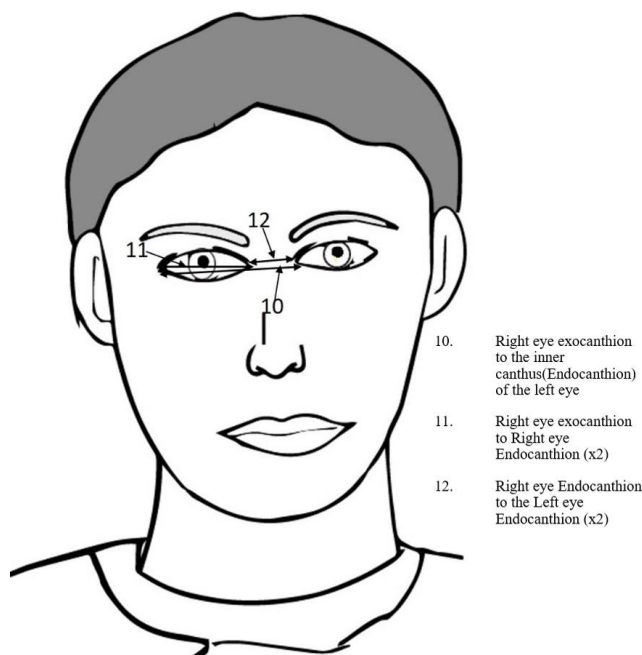



Figure 2: Figure displaying the craniofacial landmarks from 10-12

Participants were requested to sit in an upright position, head unsupported and occlusal plane parallel to the floor. It was verified with air bubble within the spirit level at the middle. The participants were guided to close at centric occlusion, and the soft-tissue points were marked by an indelible pencil. The facial measurements were registered with modified digital Vernier calliper (Mitutoyo 500-196, Illinois, USA). The Cranio-facial measurements [19] recorded during the study are as follows.

- 1) Top of the head (Vertex) to hairline (Trichion) distance
- 2) Trichion to the upper border of right eyebrow line
- 3) Trichion to Nasal Bridge (Nasion)
- 4) Nasion to the base of the right ala of the nose (alar base)
- 5) Right eyebrow line to the right alar base
- 6) Right corner of the lips (chelion) to left Chelion along the curvature
- 7) Outer canthus (Exocanthion) of the right eye to right labial commissure
- 8) Center of the pupil of the right eye to right chelion
- 9) Center of the pupil of the right eye to the centre of the pupil of the left eye (Pupillary

distance)

- 10) Right eye exocanthion to the inner canthus(Endocanthion) of the left eye
- 11) Right eye exocanthion to Right eye Endocanthion (x2)
- 12) Right eye Endocanthion to the Left eye Endocanthion (x2)
- 13) Mesial wall of the right external auditory canal to lateral corner of the bony orbit (orbitale laterale)
- 14) Superior surface of right ear to inferior surface of the right ear (length of the auricle)
- 15) The lower border of the septum of the nose (Subnasale) to most under the surface of the mandible (Gnathion). This measurement was considered as an occlusal vertical dimension for comparison with other cranio-facial dimensions.



13. Mesial wall of right external auditory canal to lateral corner of the bony orbit (orbitale laterale)
14. Superior surface of right ear to inferior surface of the right ear (length of the auricle)
15. Lower border of the septum of the nose (Subnasale) to most under surface of the mandible (Gnathion)

Figure 3: Figure displaying the craniofacial landmarks from 13-15

The statistical analysis was performed using the SPSS 19 software (IBM Corporation, Armonk, New York, USA). All the Cranio-Facial measurements were recorded in millimetres, and the mean, standard deviation were calculated. The correlation between the craniofacial measurements and the OVD were assessed by Spearman's rank correlation coefficient. The linear regression analysis was performed to determine the model fit equation to predict the OVD. The level of statistical significance was determined at $P < 0.05$.

Results

The descriptive values of all the craniofacial measurements recorded during the study for both gender are presented in Table 1. The Mean OVD (Subnasale-gnathion distance) for Saudi-Arabian ethnic male was recorded at 69.25 (5.54) mm, while the mean OVD for females was 57.41 (5.32) mm. There was a significant difference (Table 2) in the Mean OVD scores for males and female; $t(226) = 15.400, p = 0.000$.

Table 1: Descriptive statistics of vertical dimension of occlusion, and cranio-facial measurements for male participants (mm)

Cranio-facial landmarks	Mean (SD)	
	Male	Female
Subnasale-gnathion(ovd)	69.25 (5.54)	57.41 (5.32)
Vertex-trichion	113.15 (12.63)	85.58 (13.76)
Trichion-upper border of right eyebrow line	61.34 (8.65)	61.82 (7.94)
Trichion-nasion	65.30 (9.38)	65.00 (8.50)
Nasion-right alar base	61.83 (4.25)	63.32 (4.91)
Right eyebrow line-right alar base	63.22 (4.30)	63.10 (4.85)
Right Chelion-left Chelion along the curvature	65.01 (5.59)	62.45 (5.99)
Exocanthion of the right eye-right labial commissure	72.52 (4.45)	70.50 (4.02)
Center of the pupil of the right eye to right Chelion	64.42 (2.92)	64.86 (3.78)
Pupillary distance	65.87 (4.40)	57.79 (4.14)
Exocanthion of right eye-Endocanthion of the left eye	67.51 (4.06)	57.00 (5.04)
Exocanthion of right eye-Endocanthion of right eye (x2)	69.22 (5.43)	49.51 (11.16)
Endocanthion right eye-Endocanthion of left eye (x2)	66.37 (6.77)	54.37 (12.13)
Mesial wall of right external auditory canal-orbitale laterale	67.59 (4.34)	68.05 (4.54)
Length of the auricle	62.44 (3.50)	61.82 (4.44)

The Spearman's correlation test was performed (Table 3) to identify the presence of a relation between OVD and other craniofacial measurements. The results indicated the presence of statistically significant correlation ($p < 0.05$) between the OVD and Mesial wall of the right external auditory canal to Orbitale laterale, exocanthion of the right eye to Endocanthion of the left eye in both genders.

Table 2: Independent T-test to compare the OVD in male and female participants

	Levene's Test for Equality of Variances		t-test for Equality of Means						
	F	Sig.	t	df	Sig. (2-tailed)	Mean Difference	Std. Error Difference	95% Confidence Interval of the Difference	
								Lower	Upper
OVD Equal variances assumed	0.258	0.612	15.400	226	0.000	11.83333	0.76839	10.31921	13.34745
Equal variances not assumed			15.164	133.083	0.000	11.83333	0.78038	10.28978	13.37689

The recorded measurements between Right eyebrow line -alar base, Nasion-alar base on right side and exocanthion of the right eye-right labial commissure showed the positive correlation with OVD in both genders. The positive correlation between OVD and distance between Trichion to the upper border of right eyebrow line, trichion to nasion was observed only in males. The OVD was significantly correlated with measurements between Exocanthion of right eye-Endocanthion right eye and Endocanthion of right eye-Endocanthion of the left eye in Females.

Table 3: Spearman's correlation matrix between OVD and other craniofacial measurements in both gender

Measurement	Male		Female	
	r	P	r	P
Vertex-Trichion	-0.107	0.372	0.057	0.479
Trichion-upper border of right eyebrow line	0.467	0.000*	0.140	0.080
Trichion-Nasion	0.568	0.000*	0.131	0.103
Nasion-right alar base	0.304	0.009*	0.198	0.013*
Right eyebrow line-right alar base	0.517	0.000*	0.243	0.002*
Right Chelion-left Chelion along the curvature	0.499	0.000*	0.080	0.323
Exocanthion of right eye-right labial commissure	0.578	0.000*	0.365	0.000*
Center of the pupil of right eye to right Chelion	0.373	0.001*	0.251	0.002*
Pupillary distance	0.386	0.001*	0.274	0.001*
Exocanthion of right eye-Endocanthion of left eye	0.315	0.007*	0.236	0.003*
Exocanthion of right eye-Endocanthion of right eye (x2)	0.148	0.214	0.173	0.031*
Endocanthion right eye-Endocanthion of left eye (x2)	0.217	0.067	0.230	0.004*
Mesial wall of right external auditory canal-orbitale laterale	0.362	0.002*	0.221	0.006*
length of the auricle	0.013	0.910	0.209	0.009*

*p < 0.05.

The Regression analysis was performed for prediction of OVD using craniofacial measurements (Table 4) and to obtain the linear regression equations. The significant regression equations were found with all craniofacial measurements, except vertex-trichion distance, Exocanthion of the right eye to Endocanthion of the right eye in both genders.

Table 4: Summary of Simple Regression Analyses for Variables Predicting OVD and Cranio-facial measurements (Male N = 72, Female N = 156)

Variable	Male				Female			
	R ²	B	SEB	β	R ²	B	SEB	β
Vertex-trichion	0.026	-0.071	0.052	-0.16	0.001	0.013	0.031	0.032
Trichion-upper border of right eyebrow line	0.134	0.235	0.071	0.367*	0.003	0.034	0.054	0.052
Trichion-nasion	0.229	0.283	0.062	0.479*	0.003	0.035	0.050	0.057
Nasion-right alar base	0.132	0.473	0.145	0.363*	0.021	0.158	0.086	0.146
Right eyebrow line-right alar base	0.205	0.583	0.137	0.453*	0.032	0.197	0.087	0.180*
Right Chelion-left Chelion along the curvature	0.196	0.438	0.106	0.442*	0.007	0.073	0.071	0.082
Exocanthion of right eye-right labial commissure	0.294	0.675	0.125	0.542*	0.127	0.471	0.100	0.356*
Center of the pupil of right eye to right Chelion	0.119	0.655	0.213	0.345*	0.061	0.347	0.110	0.247*
Pupillary distance	0.126	0.464	0.140	0.369*	0.074	0.348	0.099	0.271*
Exocanthion of right eye-Endocanthion of left eye	0.087	0.402	0.156	0.295*	0.038	0.207	0.083	0.196*
Exocanthion of right eye-Endocanthion of right eye (x2)	0.030	0.176	0.120	0.173	0.003	0.027	0.038	0.057
Endocanthion right eye-Endocanthion of left eye (x2)	0.139	0.306	0.091	0.373*	0.011	0.047	0.035	0.106
Mesial wall of right external auditory canal-orbitale laterale	0.077	0.354	0.147	0.277*	0.050	0.253	0.092	0.224*
Length of the auricle	0.000	0.009	0.189	0.006	0.039	0.238	0.095	0.199*

*p < 0.05 Abbreviations: the unstandardized beta-B; the standard error for the unstandardized beta SE B, the standardised beta β.

The prediction for OVD was insignificant with the length of the right auricle in males. Meanwhile, the poor prediction was observed with Endocanthion of right eye-Endocanthion of the left eye, and all facial measurements from trichion in females. The linear regression equations to predict the OVD from different cranio-facial measurements are presented in Table 5.

For the male subjects, OVD could be determined from other cranio-facial measurements utilizing following equations: Trichion-upper border of right eyebrow line: $Y = 0.235 (IV) + 54.83$, Trichion – Nasion = $0.283 (IV) + 50.78$, Nasion-right alar base: $Y = 0.473 (IV) + 40.01$. The liner regression formula to predict OVD in both gender were: Right eyebrow line-right alar base: $Y = 0.583 (IV) + 32.37$ (males), $Y = 0.197 (IV) + 44.97$ (females), Exocanthion of right eye-right labial commissure: $Y = 0.675 (IV) + 20.323$ (males), $Y = 0.471 (IV) + 24.22$ (females), Center of

the pupil of right eye to right Chelion: $Y = 0.655 (IV) + 27.07$ (males), $Y = 0.347 (IV) + 34.91$ (females) and Pupillary distance: $Y = 0.464 (IV) + 38.68$ (males), $Y = 0.348 (IV) + 37.30$ (females).

Table 5: The regression equation to predict the OVD from different Cranio-facial measurements

Variable	Male	Female
	Regression equation	Regression equation
Vertex-trichion		
Trichion-upper border of right eyebrow line	$Y=0.235 (IV)+ 54.83$	
Trichion-nasion	$Y=0.283 (IV)+ 50.78$	
Nasion-right alar base	$Y=0.473 (IV)+ 40.01$	
Right eyebrow line-right alar base	$Y=0.583 (IV)+ 32.37$	$Y=0.197 (IV)+ 44.97$
Right Chelion-left Chelion along the curvature	$Y=0.438 (IV)+40.74$	
Exocanthion of right eye-right labial commissure	$Y=0.675 (IV)+20.323$	$Y=0.471 (IV)+24.22$
Center of the pupil of the right eye to right Chelion	$Y=0.655 (IV)+27.07$	$Y=0.347 (IV)+34.91$
Pupillary distance	$Y=0.464 (IV)+38.68$	$Y=0.348 (IV)+37.30$
Exocanthion of right eye-Endocanthion of left eye	$Y=0.402 (IV)+42.12$	$Y=0.207 (IV)+45.63$
Exocanthion of right eye-Endocanthion of the right eye (x2)		
Endocanthion right eye-Endocanthion of left eye (x2)	$Y=0.306 (IV)+48.95$	
Mesial wall of right external auditory canal-orbitale laterale	$Y=0.354 (IV)+45.31$	$Y=0.263 (IV)+39.54$
Length of the auricle		$Y=0.238 (IV)+42.72$

Abbreviations: OVD: occlusal vertical dimension; IV: Independent variable.

Discussion

Determination of accurate vertical dimension of occlusion is a critical clinical step during full mouth rehabilitation. It is challenging task for the clinicians to predict the appropriate OVD due to lack of teeth or the excessive loss of coronal tooth structure. The multiple clinical techniques are suggested by the researchers to determine accurate OVD. Cranio-facial measurements to predict the height of the lower third of the face is suggested by numerous authors. The hypothesis is on the premise of facial proportions and relationship of the lower third of the face with other craniofacial dimensions [20]. Multiple researchers have attempted to find the correlation between OVD and other craniofacial measurements in various ethnic groups. Since there is noticeable genotypic and phenotypic variation between ethnic groups [21], it is prudent to scrutinise the hypothesis in the different ethnic groups. Hence, this study was conducted to understand the association between OVD with craniofacial dimensions in Saudi-Arabian population.

In 1950 Fenn et al. [22], suggested the utilisation of dimension between outer canthus of an eye-angle of mouth to determine the accurate OVD. Several studies are conducted to evaluate the correlation between various craniofacial distances to predict the OVD and results are inconsistent. Boyanov [23] suggested the length of the upper lip to the distance measured from the tubercle of the mouth to the lower border of the chin is reliable for determining the OVD. The Chou et al. [24] proposed the eye – ear distance, but Al-Dhaher et al. [25], reported a non -

significant correlation between the clinical OVD and eye-ear distances in males.

The study results indicated the mean OVD for a male was higher than the female counterparts. The Mean OVD recorded during the study was similar to the results described by Al-Hamdany et al. [26], in Iraqi male (68.25 ± 6.13). The OVD amongst the female participants was analogous to the investigation conducted among Indian population by Ladda et al. [16], (56.7 ± 3.0 mm) and Kulkarni et al. [27], ($54-59$ mm). However, the Mean OVD in male gender was higher in the current study. Majority of craniofacial measurements in the males were significantly higher than the female subjects; the altered growth and development due to the sex-related characteristics are attributed to the difference [28].

The distance between the Nasion to Alar base and eyebrow line to the Alar base showed the significant correlation with OVD in both genders. The research results are in confirmation with the recommendation of Earl Pound et al. [29], regarding the complete denture construction and anterior teeth placements. The distance between the chelion along the curvature was found to be positively correlated ($p = 0.000$, $r = 0.499$) with OVD only in the male. As suggested by Abhishek Nagpal et al. [30], it is highly inconsistent to be used to predict OVD. The results were in agreement with the findings of the anthropological study conducted within the Pakistani population [31]. The present study showed the strong correlation between Right eyebrow line to right alar base measurement and OVD; the similar observation was recorded by Majeed et al. [31].

The statistically significant correlation was observed between OVD and the dimension between pupils to the chelion in both genders. The studies conducted by the Nur Emalina et al. [32], among Sundanese population observed the similar strong correlations between the OVD and the pupil-rima oris distance. The inter pupillary distance between left-right eye also had the strong correlation with OVD with a p-value of 0.001. The Exocanthion of the right eye-Endocanthion of left eye distance also indicated the strong predictive capability for OVD. The Mesial wall of the right external auditory canal to orbitale laterale (eye to ear width) and centre of the pupil of the right eye to Chelion showed the statistically significant correlation with OVD, a similar observation was reported by Basent el al. [7]. The Chou et al. [24], Abdul-Rassol [34] opined eye-ear distance is a reliable predictor for OVD estimation. Subsequently, Delic et al. [18], recommended the eye-ear distance as a dependable method to determine the OVD. Al - Dhaher et al. [25], reported the significant variation in the correlation between ear-eye distance and stated the positive correlation only in female groups.

There was a significant positive correlation between Exocanthion of right eye-right labial commissure and OVD in both genders. Nagpal et al.

[30], evaluated multiple craniofacial measurements to predict the OVD accurately, and they proposed the distance from the Exocanthion of the eye to the labial commissure and the distance from the distal canthus of the eye to the tragus of the ear as valuable adjuvants to determine the OVD.

Based on paleoanthropology, modern humans from Africa colonise Eurasia through the northern Sinai Peninsula and Bab al Mandab strait routes. The researchers indicate the Saudi-Arabian ethnic groups genetic flow from its African and Asian surrounding areas, including Africa, India, Indonesia. This could be the reason for the craniofacial measurements were similar to other nationals [35].

The cephalometric analysis of Saudi Arabian national indicated the convex profile with increased ANB angle, retrognathic mandible and bi maxillary protrusion in comparison to Caucasians [36]. The difference in correlation between male and female craniofacial measurements are due to the more prognathic mandibles and steeper mandibular angle in male in comparison to females, although the anterior lower face height is similar for both genders [37].

The results of the study are in agreement with the observation of Chou et al. [24], that the left facial measurements were more reliable in predicting OVD than right side measurements. The variation could be due to right hemisphere dominance for emotional expressions. The mobility of facial expression also exhibits facial asymmetry, and studies indicated the left side of the face is most commonly dominant in both males and females [38].

The study findings revealed the unreliability craniofacial measurements involving the trichion in estimating the OVD. The positive correlation was recorded with a trichion-upper border of right eyebrow line and Trichion-Nasion only in males. Meanwhile, the length of the auricle of the right ear recorded the positive correlation with OVD in female groups.

The direct in-vivo measurement is still considered as a gold standard due to multiple advantages like simple, low-cost and do not require complex instruments. The facial soft-tissue dimensions, spatial positions and proportions are helpful for the clinician to develop the treatment plan, analyse the final treatment outcome. The thickness of soft tissue covering the teeth and bone varies in a different location; hence dento-skeletal measurement alone is insufficient for clinical evaluation. An additional disadvantage of radiological evaluation is exposing individuals to radiation. The anatomic anthropometric description will help in quantifying craniofacial deformities to treat the congenital or traumatic facial disfigurements. Hence ethnically specific facial measurement is of great assistance for orthodontists, maxillofacial surgeons, pedodontist, plastic surgeon to identify, assess and develop appropriate the treatment plan to treat facial disharmony. The anthropometric database is also

utilised to identify the genetic disorders and recognize the individuals during forensic examinations. All facial measurements included in the present study excluding the measurement between Subnasale-Gnathion (OVD) is not affected due to teeth extraction. Hence, the unaffected craniofacial measurement will be helpful in predicting the OVD in edentulous patients and clinical situations with loss of occlusal dimension.

The limitation of the study was that only the Saudi-Arabian nationals were included in the study. Hence the results and regression formula cannot be extrapolated to other ethnic groups. The participants with Angles class I occlusion were included in the study; hence, the correlation in other malocclusion needs further investigation.

Within the limitations of the study, following conclusions were drawn.

The craniofacial measurement of Exocanthion of the right eye to right labial commissure and the Mesial wall of the right external auditory canal to orbitale lateral can be used a method for OVD approximation. The dimension between the centre of the pupil of the right eye to Chelion and Right eyebrow line to right alar base showed the strong positive correlation with OVD. Being simple and non-invasive technique, cranio-facial measurements could be routinely utilised to supplement the accurate determination of OVD. Researchers suggest the construction of ratios among all these craniofacial measurements to facilitate the subjective measurements of OVD, as using a calliper routinely is not highly applicable. It is recommended to utilise the linear regression equation and craniofacial measurements as an adjunct to determine the OVD in Saudi Arabian population.

References

1. de Almeida Rde C, da Rosa WL, Boscato N. The Effect of Occlusal Splint Pretreatment on Mandibular Movements and Vertical Dimension of Occlusion in Long-Term Complete Denture Wearers. *Int J Prosthodont.* 2016; 29(3):287-9. <https://doi.org/10.11607/ijp.4369> PMID:27148992
2. Al Baker A, Habib SR, Al Amri MD. Preserving esthetics, occlusion and occlusal vertical dimension in a patient with fixed prostheses seeking dental implant treatment. *Saudi Dent J.* 2016; 28(4):203-8. <https://doi.org/10.1016/j.sdentj.2016.05.003> PMID:27872552 PMCID:PMC5110469
3. The Glossary of Prosthodontic Terms. *J Prosthet Dent.* 2005; 94:10–92. <https://doi.org/10.1016/j.prosdent.2005.03.013>
4. Wang W, Wang J, Lu HY, Ma WS, Dong FS, Hu XY, et al. The effects of increasing occlusal vertical dimension on the deep masseter of rat at different ages. *Arch Oral Biol.* 2017; 74:12-20. <https://doi.org/10.1016/j.archoralbio.2016.10.031> PMID:27842253
5. Alhaji MN, Khalifa N, Abduo J, Amran AG, Ismail IA. Determination of occlusal vertical dimension for complete dentures patients: an updated review. *J Oral Rehabil.* 2017; 44(11):896-907.

- <https://doi.org/10.1111/joor.12522> PMID:28600914
6. Yanikoglu ND, Guldag MU, Duymus ZY. Determination of the occlusal vertical dimension: use of maxillary and mandibular posterior teeth measurement in edentate subjects. *Eur J Prosthodont Restor Dent*. 2005; 13(2):75-7. PMID:16011235
 7. Silverman MM. The speaking method in measuring vertical dimension. *J Prosthet Dent*. 1953; 3:193-199. [https://doi.org/10.1016/0022-3913\(53\)90127-9](https://doi.org/10.1016/0022-3913(53)90127-9)
 8. Strajnic L, Stanisic-Sinobad D, Markovic D, Stojanovic L. Cephalometric indicators of the vertical dimension of occlusion. *Coll Antropol*. 2008; 32(2):535-41. PMID:18756907
 9. Turner LC. The profile tracer: method for obtaining accurate pre-extraction records. *J Prosthet Dent*. 1969; 21(4):364-70. [https://doi.org/10.1016/0022-3913\(69\)90044-4](https://doi.org/10.1016/0022-3913(69)90044-4)
 10. Johnson A, Wildgoose DG, Wood DJ. The determination of freeway space using two different methods. *J Oral Rehabil*. 2002; 29(10):1010-3. <https://doi.org/10.1046/j.1365-2842.2002.00950.x> PMID:12421334
 11. Orenstein NP, Bidra AS, Agar JR, Taylor TD, Uribe F, Litt MD. Changes in Lower Facial Height and Facial Esthetics with Incremental Increases in Occlusal Vertical Dimension in Dentate Subjects. *Int J Prosthodont*. 2015; 28(4):363-70. <https://doi.org/10.11607/ijp.4288> PMID:26218018
 12. Shanahan TE. Physiologic vertical dimension and centric relation. 1956. *J Prosthet Dent*. 2004; 91(3):206-9. <https://doi.org/10.1016/j.prosdent.2003.09.002> PMID:15060486
 13. Yamashita S, Shimizu M, Katada H. A Newly Proposed Method to Predict Optimum Occlusal Vertical Dimension. *J Prosthodont*. 2015; 24(4):287-90. <https://doi.org/10.1111/jopr.12223> PMID:25251764
 14. Igic M, Kronic N, Aleksov L, Kostic M, Igic A, Petrovic MB, et al. Determination of vertical dimension of occlusion by using the phonetic vowel "O" and "E". *Vojnosanit Pregl*. 2015; 72(2):123-31. <https://doi.org/10.2298/VSP1502123I> PMID:25831903
 15. Bissasu M. Use of a patient's old complete denture to determine vertical dimension of occlusion. *J Prosthet Dent*. 2001; 85:413-414. <https://doi.org/10.1067/mpr.2001.114279> PMID:11319541
 16. Ladda R, Bhandari AJ, Kasat VO, Angadi GS. A new technique to determine vertical dimension of occlusion from anthropometric measurements of fingers. *Indian J Dent Res*. 2013; 24(3):316-20. <https://doi.org/10.4103/0970-9290.117993> PMID:24025877
 17. Farkas L. Examination. In: Farkas L, editor. *Anthropometry of the head and face*. 2nd ed. New York: Raven Press, 1994:3-56.
 18. Delic Z, Vukovojac S, Grzic R, Maricic D, Kovac Z, Kovacevic D. Evaluation of craniometric methods for determination of vertical dimension of occlusion-Part 2. *Coll Antropol*. 2003; 27(Suppl 1):191-194. PMID:12955909
 19. Misch CE. Clinical indications for altering vertical dimension of occlusion. Objective vs subjective methods for determining vertical dimension of occlusion. Quintessence international (Berlin, Germany: 1985). 2000; 31(4):280-2.
 20. Ivy RS. Dental and Facial Types. In: *The American System of Dentistry. Operative and Prosthetic Dentistry*. vol. 2. Pentland, Edinburgh, 1887:1030.
 21. Farkas LG, Katic MJ, Forrest CR, Alt KW, Bagic I, Baltadjiev G, et al. International anthropometric study of facial morphology in various ethnic groups/races. *J Craniofac Surg*. 2005; 16(4):615-46. <https://doi.org/10.1097/01.scs.0000171847.58031.9e> PMID:16077306
 22. Fenn HRB, Liddelov KP, Gimson AP. *Clinical dental prosthesis*. Ed.1 Staples press, London, 1953: 191.
 23. Boyanov B. Speedy and Exact Determining of the Vertical Dimension and Centric Relation of Edentulous Jaws. *J Istanbul Univ*. 1974; 8:9-18.
 24. Chou TM, Moore DJ, Young L Jr, Glaros AG. A diagnostic craniometric method for determining occlusal vertical dimension. *J Prosthet Dent*. 1994; 71:568-574. [https://doi.org/10.1016/0022-3913\(94\)90439-1](https://doi.org/10.1016/0022-3913(94)90439-1)
 25. Al-Dhaheer HA, AL-Huwaizi AFDetermination of the vertical dimension by cranio-facial measurement using clinical and cephalometric analysis (comparative study). *J Bagh College Dentistry*. 2009; 21:44-47.
 26. Al-Hamdany AK, Kassab NH. Correlation of vertical dimensions of soft tissue facial profiles. *Al-Rafidain Dent J*. 2010; 10(2): 243-253.
 27. Kulkarni N, Kohli M. Estimation and correlation of individual facial height and total body height. *J Int Oral Health*. 2011; 3(2):37-42.
 28. Oladipo GS, Esomonu C, Osogba IG. Craniofacial dimensions of Ijaw children and adolescents in Nigeria. *J Biomed Int*. 2010; 1(1):25-9.
 29. Pound E. The mandibular movements of speech and their seven related values. *J South Calif Dent Assoc*. 1966; 34(9):435-41. [https://doi.org/10.1016/0022-3913\(66\)90006-0](https://doi.org/10.1016/0022-3913(66)90006-0)
 30. Nagpal A, Parkash H, Bhargava A, Chittaranjan B: Reliability of different facial measurements for determination of vertical dimension of occlusion in edentulous using accepted facial dimensions recorded from dentulous subjects. *J Indian Prosthodont Soc*. 2014; 14(3):233-242. <https://doi.org/10.1007/s13191-013-0315-1> PMID:25183907 PMID:PMC4148510
 31. Majeed MI, Saleem T. Craniofacial Measurements for the determination of Occlusal Vertical Dimension and Gender Dimorphism in a Section of Pakistani Population. *Med Forum*. 2015; 26(1):55-57.
 32. Akhma NE, Sumarsongko T, Rikmasari R. Correlation between the occlusal vertical dimension and the pupil rima oris distance among sundanese population. *Padjadjaran Journal of Dentistry*. 2017; 29(2):630-137. <https://doi.org/10.24198/pjd.vol29no2.13657>
 33. Basnet BB, Parajuli PK, Singh RK, Suwal P, Shrestha P, Baral D. An anthropometric study to evaluate the correlation between the occlusal vertical dimension and length of the thumb. *Clinical, cosmetic and investigational dentistry*. 2015; 7:33. <https://doi.org/10.2147/CCIDE.S75872> PMID:25678817 PMID:PMC4322952
 34. Abdul-Rassol M. Facial Measurement Method for Determining Occlusal Vertical Dimension. *AL-Taqani J*. 2007; 20:13-17.
 35. Abu-Amero KK, Hellani A, Gonzalez AM, Larruga JM, Cabrera VM, Underhill PA. Saudi Arabian Y-Chromosome diversity and its relationship with nearby regions. *BMC genetics*. 2009; 10:59. <https://doi.org/10.1186/1471-2156-10-59> PMID:19772609 PMID:PMC2759955
 36. Aldrees AM. Lateral cephalometric norms for Saudi adults: A meta-analysis. *The Saudi dental journal*. 2011; 23(1):3-7. <https://doi.org/10.1016/j.sdentj.2010.09.002> PMID:24151411 PMID:PMC3770244
 37. Hassan AH. Cephalometric Norms for Saudi Adults Living in the Western Region of Saudi Arabia. *The Angle Orthodontist*. 2006; 76(1):109-13. PMID:16448278
 38. Ercan I, Ozdemir ST, Etoz A, Sigirli D, Tubbs RS, Loukas M, et al. Facial asymmetry in young healthy subjects evaluated by statistical shape analysis. *J Anat*. 2008; 213(6):663-9. <https://doi.org/10.1111/j.1469-7580.2008.01002.x> PMID:19094182 PMID:PMC2666135