

**AN INTERNATIONAL UROGYNECOLOGICAL
ASSOCIATION (IUGA) / INTERNATIONAL CONTINENCE
SOCIETY (ICS) JOINT REPORT ON THE TERMINOLOGY
FOR FEMALE ANORECTAL DYSFUNCTION**

**Abdul H Sultan[^], Ash Monga #[^], Joseph Lee*[^], Anton Emmanuel[^], Christine Norton[^],
Giulio Santoro[^], Tracy Hull[^], Bary Berghmans #[^], Stuart Brody[^], Bernard T. Haylen *[^],**

**Standardization and Terminology Committees IUGA* & ICS#,
Joint IUGA / ICS Working Group on Female Anorectal Terminology[^]**

Abdul H Sultan, MB ChB, MD, FRCOG Urogynaecologist and Obstetrician

Croydon University Hospital, Croydon. United Kingdom

Ash Monga, MB ChB, FRCOG Urogynaecologist

Princess Anne Hospital, Southampton. United Kingdom.

Joseph Lee, MB ChB, FRANZCOG, CU Urogynaecologist

Mercy Hospital for Women, Melbourne. Victoria. Australia.

Anton Emmanuel, Gastroenterologist

University College Hospital, London. United Kingdom

Christine Norton, Professor of Clinical Nursing

St Mary's Hospital, London. United Kingdom.

Giulio Santoro, Colorectal surgeon

Regional Hospital, Treviso. Italy.

Tracy Hull, Professor of Surgery

Cleveland Clinic Foundation, Cleveland. Ohio. U.S.A.

Bary Berghmans, Clinical epidemiologist and physiotherapist

Maastricht University Hospital, Maastricht. Netherlands.

Stuart Brody, Professor of Psychology

University of the West of Scotland, Paisley, United Kingdom

Bernard T. Haylen, Professor

University of New South Wales, Sydney. N.S.W. Australia.

Correspondence to:

Mr Abdul H Sultan,

Urogynaecology and Pelvic Floor Reconstruction Unit,

Croydon University Hospital

London Road,

Croydon, Surrey, CR7 7YE

United Kingdom

TEL" # 44 208 401 3161 abdul.sultan@croydonhealth.nhs.uk

ABSTRACT

Introduction: The terminology for anorectal dysfunction in women has long been in need of a specific clinically-based Consensus Report.

Methods: This Report combines the input of members of the Standardization and Terminology Committees of two International Organizations, the International Urogynecological Association (IUGA) and the International Continence Society (ICS), assisted on Committee by experts in their fields to form a Joint IUGA/ICS Working Group on Female Anorectal Terminology. Appropriate core clinical categories and subclassifications were developed to give an alphanumeric coding to each definition. An extensive process of X rounds of internal and external review was developed to exhaustively examine each definition, with decision-making by collective opinion (consensus).

Results: A Terminology Report for anorectal dysfunction, encompassing over XXX separate definitions, has been developed. It is clinically-based with the XX most common diagnoses defined. Clarity and user-friendliness have been key aims to make it interpretable by practitioners and trainees in all the different specialty groups involved in female pelvic floor dysfunction. Female-specific anorectal investigations

and imaging (ultrasound, radiology and MRI) has been included whilst appropriate figures have been included to supplement and help clarify the text.

Ongoing review is not only anticipated but will be required to keep the document updated and as widely acceptable as possible.

Conclusion: A consensus-based Terminology Report for female anorectal dysfunction terminology has been produced aimed at being a significant aid to clinical practice and a stimulus for research.

WORDS (*Introduction-Section 4*) XXXX

FIGURES XX

RELEVANT DISCLOSURES: (*need to update before publication*)

AH Sultan: Speaker for Astellas and Pfizer

A Monga: Consultant for Gynecare and AMS. Speaker for Astellas and Pfizer and advisor for Allergan.

J Lee: Received honoraria for talks and preceptor work from AMS and BSCI. Member of Department that administer AMS & BSCI grant for an investigator led studies

A Emmanuel: Served on advisory boards for Coloplast, Shire, Pfizer. Honoraria for talks from these companies as well as Ferring and Astra-Zeneca.

C Norton

G Santoro: Speaker for BK Medical

T Hull

B Berghmans: No disclosures.

S Brody: No disclosures

B Haylen: No disclosures

INTRODUCTION

The anatomical configuration of the anorectum is complex. The mechanisms that control continence and allow defecation are multifactorial and dependent on many factors such as the consistency of stool, bowel transit, rectal compliance and sensitivity, intact neurological function and integrity of the pelvic floor and anal sphincters.

Historically, anorectal physiological investigations have quite often produced inconsistent results. Until the advent of imaging techniques such as endoanal ultrasound, the etiology of fecal incontinence was largely attributed to pudendal neuropathy (1) . We now better understand the contribution of vaginal delivery to anal sphincter trauma (2). Imaging has taught us that training in clinical digital assessment can improve detection and repair of obstetric anal sphincter injuries and thereby minimise the risk of developing fecal incontinence (3) . Obstructive defecation is another common embarrassing problem and imaging techniques that attempt to capture the defecation process are often inconclusive (4). Artificial contrast material replicating normal fecal consistency for defecating proctography is not available and magnetic resonance imaging requires an upright scanner.

When multiple conditions such as fecal incontinence, obstructive defecation, urinary incontinence, neurological diseases, medical conditions etc. co-exist, management becomes increasingly difficult and multidisciplinary assessment becomes important (5). As the pelvic organs (bowel, bladder and vagina) are in close proximity to each other, clinicians need to be aware of the impact of dysfunction and surgery of one

organ may have on the neighbouring structures. It is therefore important for clinicians and pelvic surgeons to have more global knowledge and adopt a holistic approach to pelvic floor dysfunction.

There is a need for standardized terminology in female anorectal dysfunction to accumulate accurate prevalence data, perform the appropriate investigations, institute management and conduct audit and research. Lack of a unified definition of anal incontinence has resulted in variations in prevalence data from epidemiological data. “Pseudo incontinence” with mucoid leakage (usually caused by organic colonic disease, dietary sensitivity or fecal impaction) is often mistaken as fecal incontinence as questionnaires do not quite differentiate them. (6) There is indeed the need for a general terminology, forming a “backbone” or “core” terminology to which more specific terminologies can be attached (7).

Similar to a previous report (7) the female-specific terminology report should be:

(1) User-friendly: It should be able to be understood by all clinical and research users.

(2) Clinically-based: Symptoms, signs and validated investigations should be presented for use in forming workable diagnoses. The first three Sections will address symptoms, signs and assessment tools. The next two sections will describe anorectal physiological investigations and currently used pelvic imaging modalities routinely used in the office or anorectal laboratory to make those diagnoses. A number of related radiological investigations as well as magnetic resonance imaging

(MRI) have also been included. The value of electromyography and related nerve conduction, reflex latency and sensory investigations will be outlined.

(3) Able to indicate origin and to provide explanations: Where a term's existing definition (from one of multiple sources used) is deemed appropriate, that definition will be included and duly referenced. A number of terms in female anorectal function and dysfunction, because of their long term use, have now become generic, as apparent by their listing in medical dictionaries.

Where a specific explanation is deemed appropriate to explain a change from earlier definitions or to qualify the current definition, this will be included as an addendum to this paper (*Footnote [FN] 1,2,3....*). Wherever possible, evidence-based medical principles will be followed.

It is suggested that acknowledgement of these standards in written publications related to female anorectal dysfunction, be indicated by a footnote to the section "Methods and Materials" or its equivalent, to read as follows: "Methods, definitions and units conform to the standards jointly recommended by the International Urogynecological Association and the International Continence Society, except where specifically noted".

Methods: This report combines the input of Standardization and Terminology committee of two International Organizations, the International Urogynecological Association (IUGA) and the International Continence Society (ICS), assisted at intervals by many external reviewers. Core clinical categories and a subclassification were developed to give an alphanumeric coding to each definition. An extensive process of XXX rounds of internal and external reviews was developed to exhaustively examine each definition, with decision making by collective opinion

(consensus). Each review involved systematic solicitation and collation of judgements on each definition through sequential questions, together with summarized information and feedback of opinions derived from earlier response. Revisions of earlier response is encouraged in light of replies of other members of the panel, with reduction in range of answers and a convergence towards a consensus.

Section 1: SYMPTOMS

Symptom: Any morbid phenomenon or departure from the normal in structure, function, or sensation, experienced by the woman and indicative of disease (8) or a health problem. Symptoms are either volunteered by, or elicited from the individual, or may be described by the individual's caregiver (7, 9-10)

1.1 Anorectal Incontinence symptoms

Anal incontinence (symptom) (7): Complaint of involuntary loss of feces or flatus

(i) **Fecal incontinence (7):** Complaint of involuntary loss of feces

(a) Solid

(b) Liquid

(ii) **Flatus Incontinence(7):** Complaint of involuntary loss of flatus (gas)

(iii) **Double incontinence (NEW):** complaint of both anal incontinence and urinary incontinence [FN1]

(iv) **Coital fecal (flatal) incontinence (NEW):** fecal (flatal) incontinence occurring with vaginal intercourse (see related definition "Coital fecal urgency") [FN2]

(v) **Passive fecal (flatal) leakage (NEW):** involuntary soiling of liquid or solid stool (or flatus) without sensation or warning or difficulty wiping clean [FN3]

1.2 Anorectal Storage symptoms

(i) **Increased daytime defecation (NEW):** complaint that defecation occurs more frequently during waking hours than previously deemed normal by the woman.

(ii) **Nocturnal defecation (NEW):** complaint of interruption of sleep one or more times because of the need to defecate.

(iii) **Fecal (rectal) urgency** (7): Complaint of a sudden compelling desire to defecate that is difficult to defer

(a) Fecal urgency warning time: time from first sensation of urgency to voluntary defecation or fecal incontinence

(iv) **Fecal (flatal) urgency incontinence** (7): Complaint of involuntary loss of feces (gas) associated with (fecal) urgency.

(v) **Tenesmus: (NEW)**: a desire to evacuate the bowel, often accompanied by pain, cramping, and straining, in the absence of feces in the rectum.

(vi) **Coital Fecal Urgency (NEW)**: Feeling of impending bowel action during vaginal intercourse:

1.3 **Anorectal Sensory symptoms**

(i) **Diminished rectal sensation** (7): Complaint of diminished or absent sensation in the rectum.

(ii) **Increased rectal sensation (NEW)**: Complaint of a desire to defecate (during rectal filling) that occurs earlier or more persistent to that previously experienced.

1.4 **Defecatory and postdefecatory symptoms**

(i) **Constipation** (7) (**Updated**): Complaint that bowel movements are infrequent and/or incomplete and/or there is a need for frequent straining or manual assistance to defecate [FN4]

(a) slow transit: Delay in transit of bowel contents to reach rectum

(b) obstructed defecation: Complaint of difficulty in evacuation [FN5]

(ii) **Feeling of incomplete bowel evacuation (7)**: Complaint that the rectum does not feel empty after defecation and may be accompanied by a desire to defecate again

(iii) **Straining to defecate (7)**: Complaint of the need to make an intensive effort (by abdominal straining or Valsalva) to either initiate, maintain or improve defecation

(iv) **Sensation of blockage (NEW)**: Complaint of anorectal obstruction

(v) **Digitation (NEW)**: use of fingers in rectum or vagina to manually assist in evacuation of stool contents

(a) rectal digitation: use of fingers in rectum to physically extract stool contents to assist in evacuation

(b) vaginal digitation: use of fingers in vagina to assist in evacuation of stool. It could also be termed vaginal splinting

(vi) **Splinting (NEW)**: Support perineum or buttocks manually (usually with thumb or fingers) to assist in evacuation of stool content

1.5 **Anorectal prolapse symptoms**

(i) **Anorectal prolapse (updated)**: Complaint of a “bulge” or “something coming down” towards or through the anus/rectum. The woman may state she can either feel the bulge by direct palpation or see it aided with a mirror [FN 6]

1.6 **Anorectal pain symptoms (NEW)** [FN 7]:

(i) **Pain during straining/defecation**: Complaint of pain during defecation or straining to defecate

(ii) **Inflammatory pain**: Complaint of pain characterised by burning or stinging [FN8] (fissure, inflammation, sepsis)

(iii) **Non-inflammatory pain: (Blunted Anorectal Pain)**: Complaint of blunted anorectal pain, as opposed to sharp stinging or burning type of pain (proctalgia fugax, Levator ani syndrome, pudendal neuralgia) See Section 6.5.

1.7 **Anorectal sexual dysfunction symptoms** [FN9]

Symptoms of sexual dysfunction (7): A departure from normal sensation and/or function experienced by a woman during sexual activity.

Female sexual dysfunction (11): complaint of dyspareunia or impairment of sexual desire, arousal, or orgasm.

(i) **Receptive anal intercourse (NEW):** having a penis penetrating one's anus [FN 10]

(ii) **Other anal sexual practices with body parts:** stimulation of the anus and/or rectum with bodily parts other than the penis (e.g. finger, fist) for seemingly sexual purposes by the recipient and/or a partner

(iii) **Other anal sexual practices with non-living objects:** stimulation of the anus and/or rectum with non-living objects (e.g. dildo) for seemingly sexual purposes by the recipient and/or a partner.

(iv) **Anodyspareunia (12) (NEW):** Complaint of pain or discomfort associated with attempted or complete anal penetration. [FN11]

(v) **Coital fecal incontinence (7) (updated):** Fecal incontinence occurring with vaginal intercourse (see related definition "Feeling of impending bowel action during vaginal intercourse")

(vi) **Coital Fecal Urgency (NEW):** Feeling of impending bowel action during vaginal intercourse:

(vii) **Anal laxity (NEW):** Complaint of the feeling of a reduction in anal tone [FN 12]

1.8 **Miscellaneous anorectal symptoms**

(i) **Rectal bleeding / mucus (7):** complaint of the loss of blood / mucus per rectum [FN 13]

- (ii) **Perianal itching / pruritus ani (NEW)**: Itchy anus [FN14]
- (iii) **Flaturia (NEW)**: Complaint of passage of gas per urethra
- (iv) **Fecaluria (NEW)**: Complaint of passage of fecal material per urethra
- (v) **Vaginal flatus/faeces (NEW)**: Complaint of passage of flatus or feces per vaginam

Section 2: SIGNS

Sign: Any abnormality indicative of disease or health problem, discoverable on examination of the patient: an objective indication of disease or health problem (7).

2.1 Vaginal and anorectal inspection (23)

- (i) **Excoriation:** Perianal excoriation, skin rashes
- (ii) **Soiling:** Perianal faecal soiling or vaginal fecal soiling
- (iii) **Discharge:** Perianal or vaginal bloody or mucus discharge
- (iv) **Gaping anus:** non-coaptation of anal mucosa at rest
- (v) **Scars, sinuses, deformities, condylomata, papillomata, hematoma:** With perianal hematomas the lump may be anywhere around the anal margin and may be multiple. Pilonidal sinuses usually are a small mid-line pit with epithelialized edges. **Some of this may be best as an FN**
- (vi) **Deficient perineum/cloacal-like defect:** This is usually obvious on inspection as there is very little tissue between the anus and the vagina due to a deficiency of the anterior anal sphincter and resultant thinning of the perineum and rectovaginal septum. **This is a comment**

rather than a definition

(vii) **Anal Fissures:** Longitudinal split in the skin of the anal canal. The majority of fissures are found in the mid-line posteriorly and there may be a skin tag associated with them.

(viii) **Hemorrhoids:** abnormality of the normal cushion of specialized, highly vascular tissue in the anal canal in the submucosal space. Hemorrhoids can be divided into those originating above the dentate line which are termed internal and those originating below the dentate line which are termed external. Internal haemorrhoids are graded as follows

Grade I - bleeding without prolapse

Grade II - prolapse with spontaneous reduction

Grade III - prolapse with manual reduction

Grade IV - incarcerated, irreducible prolapse

Grade II and Grade III hemorrhoids will become evident on asking the patient to bear down and grade 4 piles are obvious at the time of the examination. A proctoscopy is essential in examining for hemorrhoids unless they are completely prolapsed.

(ix) **Anorectal prolapse:** Full thickness eversion of the lower part of the rectum and anal canal. The exposed mucosa is red with circumferential folds around the central pit, which is the lumen of the rectum. Look for associated utero-vaginal prolapse, fistulas, sepsis and ulcers.

(x) **Fistula in ano:** connects the lumen of the rectum or anal canal with the external surface. The opening of the fistula would be visible as a puckered scar or a small tuft of granulation tissue, within 2 – 4cm of the anal canal. The majority of the openings are in the postero-lateral segment and there may be discharge present.

(xi) **Rectovaginal fistula:** is a communication from the rectum to the vagina

(xii) Ano-rectal/vaginal/perineal fistula: is a communication from the anal canal to the vagina or perineal area

2.2 Vaginal examination

All examinations for pelvic organ prolapse should be performed with the woman's bladder empty (and if possible an empty rectum) (7). All compartments should be examined for prolapse but of particular relevance to ano-rectal dysfunction is posterior vaginal wall prolapse.

(i) **Posterior vaginal wall prolapse** (7): Observation of descent of the posterior vaginal wall. Most commonly, this would be due to rectal protrusion into the vagina (rectocele). Higher stage posterior vaginal wall prolapse after prior hysterectomy would generally involve some vaginal vault (cuff scar) descent and possible enterocele formation. Enterocele formation can also occur in the presence of an intact uterus.

2.3 Anorectal Examination:

The patient could lie in the left lateral position with neck and shoulders rounded so that the chin rests on the chest, hips flexed at 90 degrees, but the knees to be flexed at slightly less than 90 degrees so the patient's ankles are not in your way. Dorsal lithotomy position could also be used.

(i) **Perianal sensation/reflex:** described above

(ii) **Digital rectal examination:** The right index finger (still gloved) should be placed in the centre of the anus with the finger parallel to the skin of the perineum in the midline. The finger should then be pressed gently into the anal canal but at the same time pressed backwards against the skin of the posterior wall of the anal canal and underlying sling of the

puborectalis muscle. This overcomes most of the tone of anal sphincter and allows the finger to straighten and slip into the rectum. This will allow assessment of:

(a) Resting anal tone and assessment of contraction during voluntary squeeze of the anal sphincter as well as the levator muscles. Both the maximal contraction and the ability to maintain and repeat a contraction should be assessed. An involuntary contraction elicited during a cough is useful test in those patients who are embarrassed or find it difficult to squeeze voluntarily.

(b) Obvious hemorrhoids can be palpated but grade II and grade III. Haemorrhoids are better assessed by proctoscopy. Painful examination may be associated with fistula in ano, fissure in ano, infection or pilonidal abscess.

(c) Palpable anal sphincter gap. An assessment can be made of palpable ano sphincter gap to assess if there has been previous obstetric or surgical damage. The perineal body can be assessed for deficiency.

(d) Rectal contents. The contents of the rectum can be assessed, the feces may be hard or soft, the rectum may be empty or collapsed and sometimes ballooned out. This allows assessment of fecal impaction.

(e) Confirmation of presence of rectocele, enterocele or perineocele. Use of POP- Q staging [see FN15].

(f) Bidigital examination may be carried out with the patient supine in a gynecological examining position. By inserting the index finger in the vagina and the middle finger in the rectum, the rectovaginal septum and any intervening small bowel loops can be palpated to differentiate a rectocele from an enterocele, during a Valsalva manoeuvre.

(g) Rectal lesions. Any thickening or mass can be felt for such as carcinoma. It may be possible to suspect an intussusception and also to elicit a recto-vaginal fistula. If you can feel a mass with your fingertip ask the patient to strain down, this will often move the mass down to bring it within reach.

(h) An assessment can be made of the rectovesico/recto uterine pouch to look for extra rectal masses.

2.4 Examination of Pelvic Floor Muscle Function (7) Pelvic floor muscle function can be qualitatively defined by the tone at rest and the strength of a voluntary or reflex contraction as strong, normal, weak, or absent or by a validated grading symptom. Voluntary pelvic floor muscle contraction and relaxation may be assessed by visual inspection, by digital palpation (vaginal or anorectal) (circumferentially), electromyography, dynamometry, perineometry, or ultrasound. Factors to be assessed include muscle strength (static and dynamic) (graded as strong, normal, weak or absent), voluntary muscle relaxation (graded as absent, partial, complete, delayed), muscular endurance (ability to sustain maximal or near maximal force), repeatability (the number of times a contraction to maximal or near maximal force can be performed), duration, co-ordination, and displacement (24). Assessment can be made of each side of the pelvic floor separately to allow for any unilateral defects and asymmetry (24). Assessment of displacement (perineal elevation or descent) of the pelvic floor can be made during cough or Valsalva. Normally, there is no downward movement of the pelvic floor muscles or there is a ventral movement (perineal elevation, inward (cephalad) and upward movement of vulva, perineum and anus). Rectal examination: observations can include:

(a) Anal sphincter tone and strength: assessment on digital examination, as good or poor in the absence of any quantitative assessment.

(b) Anal sphincter tear: may be recognized as a clear “gap” in the anal sphincter on digital examination.

2.5 Squeeze pressure

Measurement of squeeze pressure involve the exertion of pressure, compressing the assessor's finger during digital palpation or using a mechanical device. The patient is asked to squeeze the PFM as hard as possible (maximum strength), to sustain the squeeze contraction (endurance), or to repeat squeeze contractions (repetitions). The measurement can be done in the anorectum using manual muscle testing with digital rectal palpation or pressure manometry in the vagina using manual muscle testing with digital vaginal palpation or pressure manometry, or dynamometry. So far, methodological properties, like validity, reproducibility and responsiveness of quantitative assessments and scales of pelvic floor squeeze pressure are questioned (25-33).

Pelvic floor muscle **spasm** or pelvic floor myalgia, was defined as the presence of contracted, painful muscles on palpation and elevated resting pressures (more than 40 cm H₂O) by vaginal manometry (35). Reissing's (36) definition of spasm: "An involuntary contraction of some or all of the pelvic floor muscles which prevents examination" FN16 (37)

Pelvic floor muscle **tenderness**: occurrence of the sensation of pain or painful discomfort of the pelvic floor muscles. Tenderness can be scored during a digital rectal (or vaginal) examination according to each subject's reactions: 0, no pain; 1, painful discomfort; 2, intense pain; with a maximum total score of 12 (38).

Pelvic floor muscle **traction** is the use of a pulling force to examine or treat pelvic floor muscles

- it might end pelvic muscle spasm
- it might relieve pain

2.6 General examination: Exclude anaemia, jaundice, lymphadenopathy etc. Anorectal dysfunction may be associated with systemic disease and intestinal malignancy and a thorough medical examination should observe for signs relating to these conditions

2.7 Neurological examination: In patients with possible neurogenic pelvic floor dysfunction there should be particular note of those neurological signs related to S2-4 but these should be complimented by a more general neurological examination as indicated. Specific to anorectal dysfunction, assessment of anal reflex and perianal sensation should be performed.

2.8 Abdominal examination:

- (1) Abdominal masses or distension
- (2) Scars indicating previous relevant surgery or trauma.
- (3) Tenderness

3. Assessment tools and questionnaires (non invasive)

Suggest further editing of this section into that which is essential. Try to make it more definitional limiting discussion.

3.1 Pictorial stool chart

The “Bristol stool chart” (Figure xx) has come into widespread use, despite little validation work. Loose or liquid stool will tend to cause urgency and make faecal incontinence (urge and passive) more likely. Hard stool is more difficult to evacuate. First described (but not published as a pictorial instrument) by Heaton et al (39, 40), it seems to have widespread face validity and recognition and is useful in conversations with patients about their stool consistency. It has not been validated as an outcome measure and a reported change in category may not represent sufficient degree of precision for use as a trial end point. Bliss has examined patient self reported stool consistency compared to measured water content of the same stool and found a reasonable correlation to one of four categories (41)

3.2 Bowel diary

Bowel diaries have been widely used in diagnostic and intervention studies. Patient recall is less accurate than a diary (42, 43). Patients tend to underestimate symptom frequency, in one study by over 50% (44). However, there are few published examples and no consensus on what should be included, examples varying with the bowel condition under investigation or purpose of a study. Elements that might be included:

- Urgency
- Faecal incontinence (amount, consistency)
- Flatus incontinence
- Passive staining/soiling (tends not be discrete episodes)
- Pads (changes, degree of soiling)
- Straining/difficulty/time in the toilet
- Unsuccessful attempts to defecate
- Assistive measures (e.g. digital stimulation, manual evacuation, irrigation)
- Laxative or rectal evacuant use
- Diet and fluids (type and/or timing)

A simple example is given in Figure xx. Symptoms or events can be added as relevant by annotating instructions for an individual patient. Patients often need careful and detailed instructions on how to complete a diary, and still many are poorly completed. An incomplete diary is difficult to interpret and is liable to misinterpretation as a low bowel/event frequency.

3.3 Symptom scores and questionnaires

Symptoms and their effect on individual patients varies greatly, there has been a move to questionnaires where patients pre-specify and score their most bothersome symptoms and then score the same symptoms again after intervention. One such approach, which can be used in any health condition is Measure Yourself Medical Outcome Profile (MYMOP) (45) where patients nominate and score their individual priority symptoms.

3.3.1 Fecal incontinence (FI)

The International Consultation on Incontinence (ICI) chapter 5B (46) has reviewed FI questionnaires and found none with a grade A recommendation (validity, reliability and responsiveness established with rigour). The ICI grades B (validity and reliability established with rigour, or validity, reliability and responsiveness indicated) and C (early development – further work required) are noted where available in the text below.

Original symptom scores for FI simply graded FI by consistency of stool lost (47) or by frequency of FI (48).

The Cleveland Clinic Score (49), Figure xx, often termed the “Wexner” score after the senior author, was the first attempt to have a more finely graded score based on both the frequency and consistency of FI and effect on lifestyle. In the original version it was physician-completed, although in subsequent literature it has also been completed by patients (grade C). The St Mark’s score (Figure xx) was an adaptation of the original Wexner score, adding scores for urgency and use of anti-diarrheals (grade C) (50) This has been found to correlate reasonably well to patients’ global assessment of their bowel function (51)

Figure xx: The Wexner fecal Incontinence score

Type of Fecal Incontinence	Never	Rarely	Sometimes	Weekly	Daily
Solid	0	1	2	3	4
Liquid	0	1	2	3	4
Gas	0	1	2	3	4

Wears a pad	0	1	2	3	4
Lifestyle alteration	0	1	2	3	4

Figure xx: The St Mark's fecal incontinence score

Type of FI	Never	Rarely	Sometimes	Weekly	Daily
Solid	0	1	2	3	4
Liquid	0	1	2	3	4
Gas	0	1	2	3	4
Lifestyle alteration	0	1	2	3	4
				No	Yes
Wears pad or plug				0	2
Takes constipating medicines				0	2
Lack of ability to defer defecation for 15 mins				0	4

The Fecal Incontinence Quality of Life Scale (grade B) (52) and Fecal Incontinence Severity Index (FISI) (grade B) (53) were developed using items suggested by experts and then proposed to patients for ranking.

The international consultation on incontinence questionnaire – bowels (ICIQ-B) (54) has 23 items developed by literature review, expert opinion and in-depth qualitative interviews with patients, to include items of greatest importance to both clinicians and people with symptoms (55) It has been validated up to the point of responsiveness to change, but further work is needed on this aspect. This is one module in the developing comprehensive range of validated tools for measuring different aspects of pelvic floor dysfunction using an approved methodology for item generation, psychometric validation and translation into different

languages of a questionnaire (<http://www.icig.net/>). The ICIQ-B has a scored bowel control and quality of life sub-scales.

The Manchester Health Questionnaire (56) and the Birmingham bowel and urinary symptoms questionnaire (BBUS-Q) (57) (both grade B) have not achieved widespread use.

3.3.2 Symptom scores and questionnaires – constipation

There has been no exercise similar to the ICI Chapter 5B (46) which has graded constipation questionnaires.

The Patient Assessment of Constipation Quality of Life questionnaire (PAC-QOL) (58) and the PAC-SYM (59) are the best validated and most widely used tools for idiopathic constipation (60). The PAC-SYM items were developed from the literature and patient focus group interviews. The validation process was robust and the instrument has 12 items grouped into three subscales (stool symptoms, rectal symptoms and abdominal symptoms), each scored 0-4. It has also been validated for use with constipated older people in a care home environment (60) and opioid-induced constipation (61).

The Constipation Treatment Satisfaction Questionnaire (CTSAT-Q) (62) is a recent addition and has not been widely used as yet.

The Cleveland Clinic constipation score gives a simple numerical total score (63) based on symptoms and physiological findings. Values allocated to symptoms and findings appear to be arbitrary. Validation has been limited.

The Constipation Assessment Scale (CAS) (64) was developed for use with cancer patients who develop symptoms as a result of cancer or its treatment.

The Knowles-Eccersley-Scott-Symptom (KESS) score (65) was designed to differentiate between different sub-groups of constipated patients. It is a scored 11 item questionnaire based on the Rome 11 criteria for constipation and the Cleveland Clinic constipation score (63). It has not achieved full psychometric validation.

Altomare has developed a scoring system specifically for the Obstructed Defecation Syndrome (66), but this has not been formally validated.

3.3.3 Symptom scores and questionnaires – other gastrointestinal disorders

There are numerous other gastrointestinal disorders which commonly co-exist with pelvic floor problems. It is beyond the scope of the document to review them all, but there are some well validated generic tools:

- The Gastrointestinal Quality of Life Index (GIQLI) (67) covers modules on the whole GI tract.
- The Functional Digestive Disorders Quality of Life Questionnaire (FDDQoL) (68) focuses on IBS and dyspepsia.
- Subjects global assessment of relief (SGA) (69) was developed for assessment of outcomes in constipation-predominant irritable bowel syndrome (IBS) intervention studies.

Of particular note is the IBS, the symptoms of which are commonly associated with the overactive bladder (OAB). The Rome 111 criteria for IBS are:

Recurrent abdominal pain or discomfort (an uncomfortable sensation not described as pain) at least 3 days/month in the last

6 months associated with *two or more* of the following:

- Improvement with defecation
- Onset associated with a change in frequency of stool

- Onset associated with a change in form (appearance) of stool

Criteria must be fulfilled for the last 3 months with symptom onset at least 6 months prior to diagnosis.

Symptoms that Cumulatively Support the Diagnosis of Irritable Bowel Syndrome

- Abnormal stool frequency (for research purposes “abnormal” may be defined as greater than 3 bowel movements per day and less than 3 bowel movements per week);
- Abnormal stool form (lumpy/hard or loose/watery stool);
- Abnormal stool passage (straining, urgency, or feeling of incomplete evacuation);
- Passage of mucus;
- Bloating or feeling of abdominal distension.

The neurogenic bowel dysfunction score gives a symptom-based score which has been tested in spinal cord injury (70).

3.4 Functional assessment

Many women with bowel symptoms have co-existing impairments to activities of daily living (ADL) and mobility, either due to co-existing neurological disability or frailty in advanced old age. This will be particularly prevalent in the nursing home population. This may impair their ability to manage bowel function and access the toilet. It is beyond this report to review this in detail and mobility impairment is often apparent on physical assessment. Where the impairment is unclear, observing the patient’s ability to self-toilet or use of a simple score such as the Bartel index (71) may be useful.

CONDITIONS	Tools	Clinical	Research / optional
	Bristol Stool Chart		
	Bowel Diary		

Fecal incontinence	<ul style="list-style-type: none"> • Cleveland Clinic Score / Wexner • St Marks Score • FI QoL • FISl • ICIQ-B 		
Constipation	<ul style="list-style-type: none"> • PAC-QoL • PAC-SYM • CTSAT-Q • KESS • Altomare • SGA 		

4. Anorectal Physiological Investigations

Good section though again Suggest further editing of this section into that which is essential. Try to make it more definitional limiting discussion.

Anorectal physiological assessment is a key part of the assessment of some patients with pelvic floor symptoms (72, 73). Accurate clinical assessment is a necessary complement to the physiological one, especially important as patients with bowel symptoms often also have other pelvic floor symptoms (74). A holistic approach to the pelvic floor is required, rather than dividing it into anterior, middle and posterior compartments. Anorectal physiological measurements provide a clinically meaningful, quantitative measure of a specific anorectal function. Continence and defecation however require the correct functioning and co-ordination of a multitude of motor and sensory sphincteric and suprasphincteric apparatus (75). It is only in the context of the patient's symptoms, thorough examination and radiological investigations that physiological measurements can be correctly interpreted.

4.1 Investigations to exclude organic disease

Anoscopy or proctoscopy is the inspection of the anal canal to identify anal fissure, fistula or haemorrhoids as a cause of anal symptoms.

Rigid sigmoidoscopy is a bedside test to inspect the rectal mucosa, with no bowel preparation.

Flexible sigmoidoscopy refers to the inspection of the distal colonic mucosa, typically up to the splenic flexure, with a 60cm flexible endoscope following enema preparation. Colonoscopy examines the entire colon following a full oral preparation to clear the bowel to allow this.

4.2 Anorectal Physiology Tests

Functional assessment tests of faecal incontinence and evacuatory disorders aim to qualify and quantify function, determine the etiology, guide management and monitor progress .

4.2.1 Manometry

Manometry assesses the mechanical strength of the anal sphincters (76, 77). A range of methods are available, including water perfused, solid state and microballoon systems. The channel openings in water perfused catheters and the pressure transducers in solid state catheters can be placed in different configurations. Typically they are arranged radially with four to eight points of measurement. They can also be arranged in a spiral configuration allowing simultaneous pressure measurements at different levels of the anal canal.

When using a catheter with radially arranged pressure transducers the pressure along the length of the canal is measured either by station pull-through or continuous pull-through . Station pull-through involves inserting the catheter to six centimeters from the anal verge, withdrawing the catheter at five to ten millimeter intervals and measuring for one to five minutes at each 'station' (see Figure 1). Continuous pull-through involves withdrawing the catheter at a set speed by hand or by a mechanical puller. As normal values can differ substantially between laboratories according to the style of catheter used, each unit is encouraged to generate its own normal data (72, 73).

In patients with faecal incontinence the value of manometry is:

- a) to define functional weakness of one or both sphincter muscles (as a compliment to anal endosonography);
- b) to support findings of other tests and to monitor outcome and predict response to biofeedback training;
- c) in cases where anal endosonography is not available, vector manometry may help identify anatomic defects of the anal sphincter complex.

In constipated patients the value of manometry is

- a) to exclude Hirschsprung's disease.
- b) to identify and predict responses to biofeedback training (pelvic floor dyssynergia = failure to expel a water-filled balloon).

4.2.1.1 Functional anal length

The functional length of the anal canal is calculated as the length of the high pressure zone; there is significant longitudinal variation in anal canal pressure and the region of the anal canal that has a pressure above 50% of the maximum pressure is defined as the high pressure zone (normal ranges for females 2-3cm, males 2.5-5cm).

4.2.1.2 Maximum Resting Pressure

The internal anal sphincter (IAS) exhibits continuous tonic activity and is responsible for 55-85% of the resting anal canal pressure (see Figure 1). Its contribution to resting tone is variable along the length of the anal canal with the proximal two thirds being more reliant on IAS tone to maintain adequate resting pressures (78, 79). The range of maximal resting pressure is typically between 60 -120 cmH₂O. The EAS has constant tonic activity contributing to the resting anal canal pressure. The tonic activity within the IAS is variable and slow and ultraslow waves have been identified. Slow waves occur with a frequency of 10 to 20 per minute: they are more frequent in the distal anal canal with the proposed

function of moving anal canal contents proximally into the rectum. Ultraslow waves are less than 2 per minute: they are likely to be a result of rectal stimulation inducing IAS relaxation. The IAS is 1-1.5cm long with its caudal margin demarcated anatomically by the intersphincteric groove, beyond which the EAS continues in isolation (80, 81).

4.2.1.3 The Maximum Squeeze Pressure

Although the EAS contributes to the resting pressure the specific function of the EAS can be assessed during the *squeeze* and *cough* manoeuvres. The pressure increment above resting pressures during these manoeuvres is a direct representation of EAS function. The normal range, as stated above, varies according to measurement modality in each laboratory, but is approximately above 60cmH₂O (81, 82)). Typically, higher values are obtained by automated pull-through rather than station withdrawal methodologies (72).

4.2.1.4 Involuntary maximum Squeeze Pressure

Commonly used manoeuvres are the cough and the Valsalva manoeuvre to measure this involuntary increment. Standardization of this response to the Valsalva maneuver has not been reported (72). The contraction of the EAS in response to raised intraabdominal pressure is usually reported as a present or absent response, rather than numerically.

4.2.1.5 Endurance Squeeze pressure:

To assess the endurance squeeze pressure, measurements are taken during a 5 – 10 second squeeze (normal \geq 5 seconds). Incontinent patients typically have fatigue rate of greater than two-thirds of initial pressure at the end of the sustained squeeze. By calculating fatigability, the fatigue rate (using linear regression on the mean pressure over one second periods throughout the endurance squeeze), a measurement can be derived which represents the time increased intra-anal pressure is observed during manoeuvres that

increase intra-abdominal and therefore intrarectal pressure in order to maintain a positive anorectal pressure gradient.

4.2.1.6 Rectoanal Inhibitory Reflex

Rectal distension induces a relaxation response in the IAS and is termed the recto-anal inhibitory reflex (RAIR). It is elicited by rapid insufflation and desufflation of 50mls of air into a balloon positioned in the distal rectum during anal manometry at the level of the proximal high pressure zone (73). A drop of at least 25% of resting pressure has to occur with subsequent restoration to at least two thirds of resting pressure for the RAIR to be deemed present. This reflex is absent in Hirschsprung's disease: of greater physiological meaning, this reflex is thought to underlie the sampling response that allows rectal content to be sensed by the anal mucosa, thus ensuring continence of flatus and stool (83).

4.2.1.7 Balloon Expulsion Pressure

Anal canal pressure measurement during straining and balloon expulsion can be performed on patients with evacuatory difficulty . An inappropriate increase in sphincter pressure on attempted voiding evacuation is usually reported as a present or absent response, rather than numerically. Such increased pressure is referred to as “anismus” or “paradoxical sphincter contraction”.

Parameters that are typically measured are:

- the functional length of the anal canal (normal ranges for females 2-3cm, males 2.5-5cm).
- at rest (maximal resting pressure normal values typically 60 -120 cmH₂O)
- on voluntary squeeze (normal increment typically 60-240 cmH₂O, typically higher in men and lower with age)

- with endurance squeeze (5-10 seconds contraction being held – this is usually reported as presence or absence of the ability to maintain at least 50% of maximal squeeze at end of that time period)
- with cough or Valsalva (to assess involuntary. “reflex”, activation) – this is typically > 60cmH₂O
- during distension of a rectal balloon (assess the recto-anal inhibitory reflex)
- in patients with suspected animus, anal canal pressures can be measured during straining to evacuate

4.2.1.8 Advanced Manometric techniques

4.2.1.8.1 Vector manometry

Vector manometry involves withdrawing (commonly using a mechanical puller) a radially arranged multi-channel anorectal manometry catheter through the length of the anal canal (84, 85). The following parameters are identified:

- Radial asymmetry index (RAI) is a quantitative measure of the radial symmetry and can be calculated at any level in the anal canal but most commonly refers to the level at which the highest resting pressure is generated. The principle is that an asymmetrical sphincter is more likely to have a sphincter defect.
- The vector volume is the volume of the 3D shape generated and provides a value which reflects the overall length and symmetry of the sphincter.

4.2.1.8.2 High resolution manometry

In this technique, a catheter with a large number of pressure sensors spaced less than 0.5mm apart along the length of the catheter. This allows complete definition of the intra-anal

pressure environment. The resulting data is displayed on a topographical three dimensional plot to allow easier pattern recognition. It is a measurement with the variables of pressure (displayed as the colour), distance into the anal canal (y-axis) and time (x-axis). Normal ranges are slightly higher than measured with standard manometry, but the readings agree well with each other (86).

4.2.1.8.3 Ambulatory Anorectal Manometry

Using solid state catheters, prolonged ano-rectal motor events have been recorded, including in ambulant subjects. The clinical applicability of these techniques has not been established (87-89).

4.2.2 Sensory Measurements

4.2.2.1 Assessment of rectal sensation to distension

Distension sensitivity testing is of proven value in:

- a) patients with faecal incontinence to help with biofeedback training by normalization of the initial sensation sensory thresholds;
- b) identifying visceral hypersensitivity, poor rectal compliance, or rectal irritability if maximal tolerated volumes are low (72, 73).

There is no evidence to support use of the sensory thresholds for diagnosis and biofeedback training of patients with constipation. Compliance testing has also not proven valuable in identifying candidates for specific therapies.

Rectal sensation to distension is most commonly assessed by manually inflating an intrarectal domestic balloon at a rate of approximately 5ml/second (79, 80, 90). The following are elicited:

- volume which elicits the first sensation of balloon expansion (threshold) [typical normal range 12-25ml]
- volume to get an urge to defaecate (typical normal range 35-65ml)
- maximal tolerated volume (typical normal range 120-300 ml).

[normal ranges for the latter two sensations are highly variable due to lack of consensus on measurement technique especially of the nature and speed of inflation of the balloon]

The pressure required to elicit these sensations can also be measured using an electro-mechanical barostat and may be more reproducible. The barostat measures the volume and the pressure required to elicit these volumes sensations (91, 92). Typically distension thresholds with a barostat are higher, with larger volumes being required to elicit the same sensation. However, again, the published ranges vary widely between units: typically distension volumes 1.5 to 3 times are published for thresholds with a barostat compared to manual balloon inflation

4.2.2.2 Mucosal Electrosensitivity

Mucosal electrical stimulation is performed using a probe with two ring electrodes between which a small electrical potential is applied generating an alternating square wave with a variable frequency. Anal and rectal sensory thresholds are assessed in this way. Normal ranges have been established as anal electrosensation <10mA, and rectal as <30mA (93).

4.2.3 Rectal Dynamics

4.2.3.1 Rectal Compliance

Rectal compliance is the term that describes the relationship between pressure and volume, reflecting the ability of the rectum to act as a reservoir and is assessed using a barostat. Inflating the bag within the rectum prior to the recording inflation protocol, known as conditioning, has been shown to improve the precision of compliance testing (83). Typically, compliance figures between 4 and 11 mmHg/ml are quoted as the normal range.

4.2.3.2 Rectal impedance planimetry

These studies are the preserve of research institutions rather than clinical practice. The rationale is to calculate the diameter or cross sectional area of an intra rectal bag during a distension sequence. Impedance planimetry measures the cross sectional area which enables the circumferential wall tension to be calculated(94).

4.2.4 Attempted Defecation and Balloon Expulsion

Patients with symptoms of prolapse and elderly patients with a history of constipation who present with passive incontinence should be thoroughly examined for the presence of a full thickness rectal prolapse. Patients are asked to strain as they would to pass stools whilst on a toilet or commode and given enough time to reproduce the prolapsing lump before examination.

Expulsion of a water filled balloon can be used in the assessment of constipated patients. The ability to expel the balloon within 1 minute may be a useful tool in demonstrating the absence of pelvic floor dyssynergia.

4.2.5 Neurophysiology

4.2.5.1 Single fiber EMG

Calculating EAS fiber density is another method of assessing denervation and reinnervation of the EAS. It is used almost exclusively as a research tool. Conventional EMG can be used to quantify the re-innervation of the EAS by detecting prolongation in the duration of the motor unit potential. A single fiber needle EMG technique is used to measure the muscle

fiber density in the external sphincter and puborectalis. A raised fiber density indicates reinnervation in the muscles which may occur following partial denervation

4.2.5.2 Concentric fiber EMG

Concentric needle EMG can be used to record activity in the external sphincter and puborectalis. The responses of these muscles to voluntary contraction, coughing and straining can be displayed. The data is qualitative and compared to appearances in these muscles at rest. The muscles can also be studied at several sites to define areas of functioning muscle and identify sites of muscle injury (sphincter mapping) although this is has now been superceded by anal endosonography.

4.2.5.3 Surface EMG

Surface recordings from the sphincter show increased activity with body actions and decreased activity in sleep. Needle EMG however is regarded as superior (95). Some centers use surface EMG as an indicator of anal sphincter activity to provide feedback for patients undergoing behavioral biofeedback training for faecal incontinence or constipation.

4.2.5.4 Pudendal nerve terminal motor latencies (PNTMLs)

The pudendal nerve is stimulated as it passes over the ischial spine using a specially designed electrode attached to the index finger of the assessor in the rectum (95). The surface EMG recording electrode which sits on the base of the assessor's index finger and measures external sphincter activity. The delay between the electrical stimulation of the pudendal nerve and the EMG activity of the EAS is the PNTML. The test does not reliably reflect the pudendal nerve damage. This may be because PNTMLs measure the speed of nerve conduction which involves the fastest nerve fibers which are least susceptible to damage. The latencies are reported as normal if below 2.2msec, but are also very operator

dependent, with poor reproducibility and hence not recommended for general clinical use (96).

4.4.6 Clinical Role of Anorectal Physiological Measurements

As can be seen from the above, the reliability, reproducibility, and clinical validity of these tests is unproven, owing to the variety of methodologies of measurement undertaken. Standardisation in each individual laboratory, with normal ranges from each laboratory, is therefore the required standard.

Figure 1: Typical station pull through manometry trace on a patient, with explanations

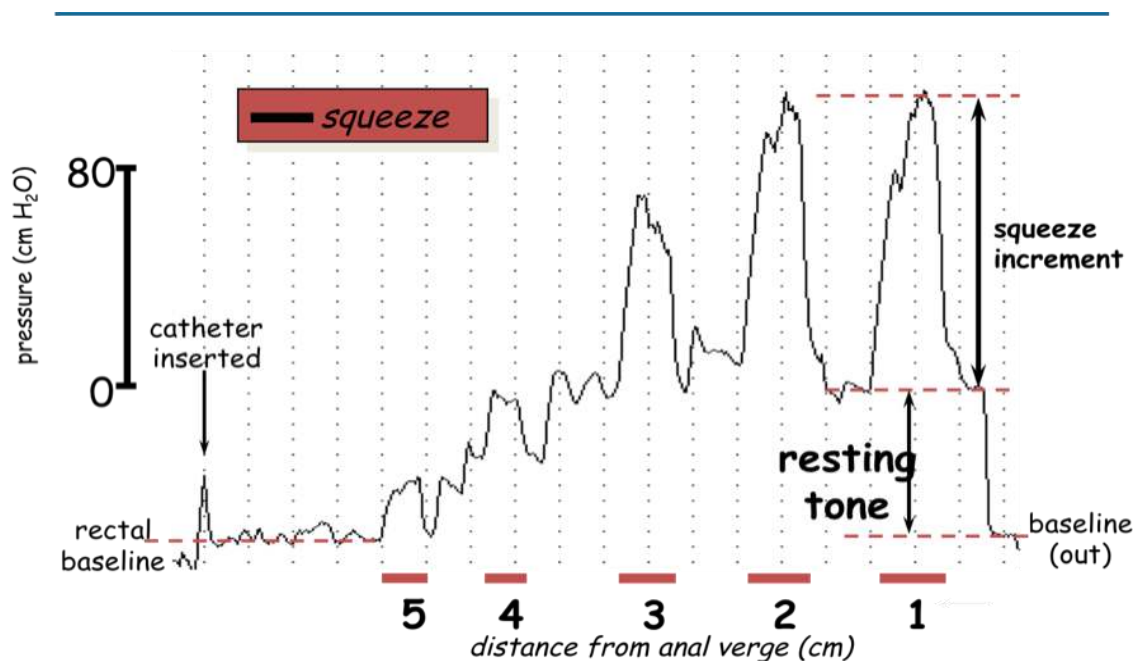
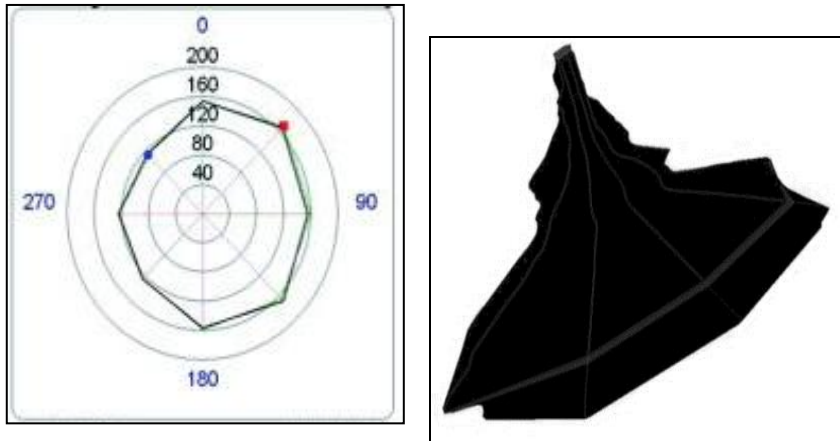


Figure 2: Vector volume anal manometry trace. The left hand panel illustrates the shape of the contour curve at a fixed point, and the right hand figure shows the integrated whole across the length of the sphincter (from proximal to distal). It is evident that the greatest pressure is exerted in the distal canal.



5: IMAGING

Good section though again Suggest further editing of this section into that which is essential. Try to make it more definitional limiting discussion.

5.1 Ultrasonography (2D/3D/4D) of the posterior compartment including anal sphincters, pelvic floor muscles and prolapse (Endoanal, Transperineal, Transvaginal)

Ultrasound is increasingly being incorporated as an investigation of posterior compartment disorders (7, 97) (Table I). An integrated multicompartamental pelvic floor ultrasonography with a combination of different modalities has been described to assess pelvic floor dysfunction for a global and multicompartamental perspective (98,99)

Modalities in current routine clinical use:

- (a) **Endoanal:** intraanal 360° sector scanning using rotational mechanical probe or radial electronic probe;

- (b) **Transperineal:** curved array probe applied in the perineum between the mons pubis and the anal margin. This term incorporates translabial ultrasound. Introital ultrasound is usually assumed to imply the placement of transducer with smaller footprints (such as end-firing endovaginal probe) within the introitus;
- (c) **Transvaginal:** intravaginal curvilinear, linear array, or 360° sector scanning.

5.1.1 Endoanal ultrasonography (EAUS)

The majority of current systems provide **2D Imaging** which give a 360° axial view of the anal canal and of the rectal wall (4, 100, 101). Endoanal ultrasound can be performed with the patient placed in the dorsal lithotomy, left lateral or prone position. Irrespective of the position, the probe should be rotated so that the anterior aspect of the anal canal is superior (12 o'clock) and left lateral is right (3 o'clock) on the screen. The anal canal is divided into three levels of assessment in the axial plane referring to the following anatomical structures:

- **Upper level:** the hyperechoic sling of the puborectals muscle (PR) and the complete ring of the internal anal sphincter (IAS) are visualized (FIGURE 1a).
- **Middle level:** corresponds to the superficial part of the EAS (concentric band of mixed echogenicity), the conjoined longitudinal layer, the IAS (concentric hypoechoic ring), and the transverse superficial perinei muscles (FIGURE 1b);
- **Lower level:** corresponds to the subcutaneous part of the EAS where the IAS is absent (FIGURE 1c).

The acquisition of a three-dimensional data volume (**3D ultrasound**) and the underlying techniques vary. Acquisition may be “**free-hand**” (**low resolution 3D**) or “**automatic computer-controlled**” (**high resolution 3D**) (102-103).

Fig 1a

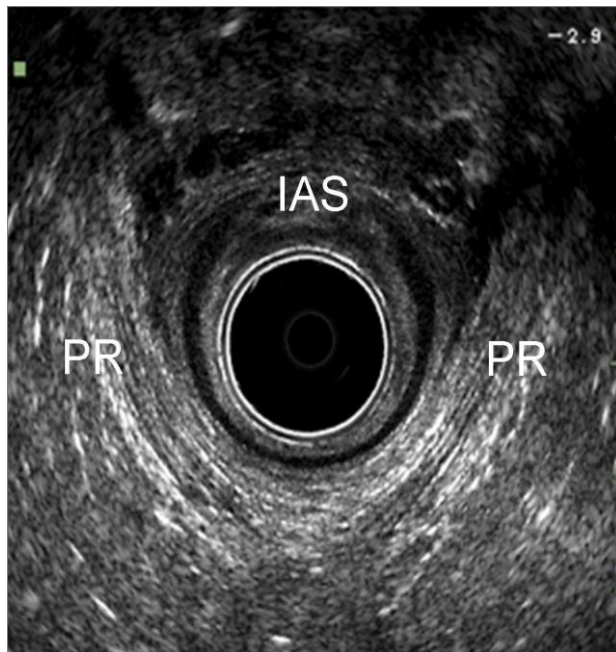


Fig 1 b

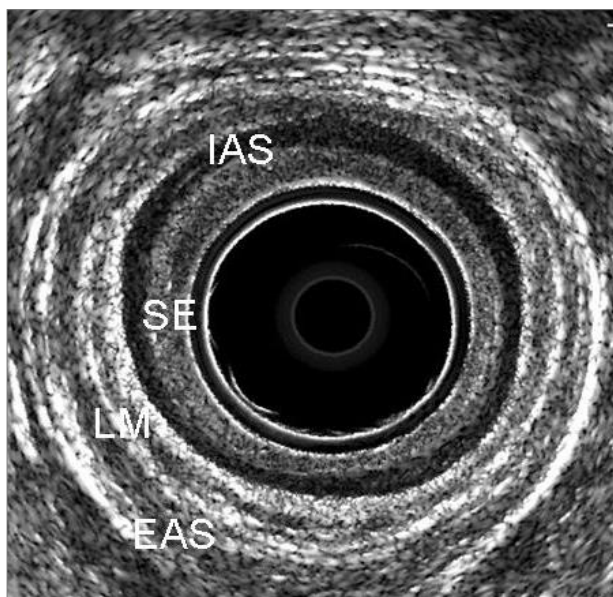


Fig.1c

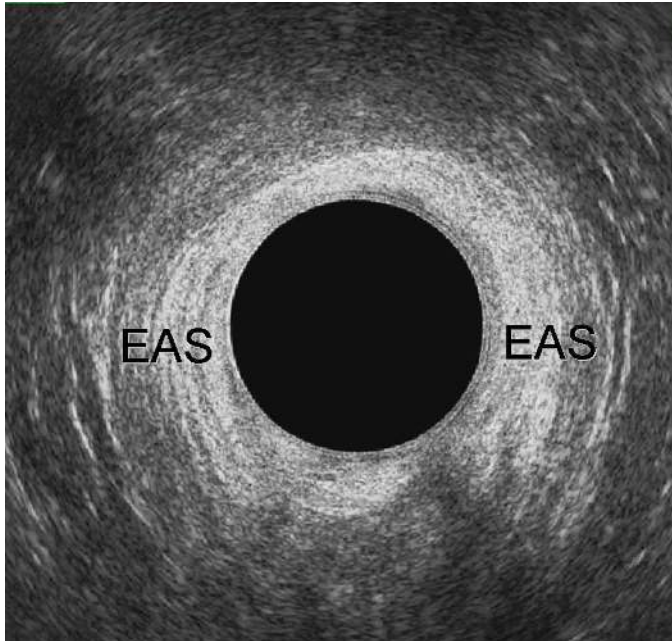

Figure 1: Endoanal ultrasonography. (a) Upper level of the anal canal; (b) Middle level of the anal canal; (c) Lower level of the anal canal. PR= puborectalis; IAS= internal anal sphincter; EAS= external anal sphincter; LM= longitudinal muscle; SE= subepithelium

5.1.2 Transperineal ultrasonography (TPUS)

Conventional convex transducers (frequencies between 3 and 6 MHz and field of view at least 70°) provide 2D imaging of the pelvic floor (104, 105). Transperineal ultrasound is performed with the patient placed in the dorsal lithotomy position, with the hips flexed and abducted. If necessary, the patient can be examined standing, to maximise descent of pelvic organs, especially if the patient finds it difficult to produce an effective Valsalva maneuver. No rectal or vaginal contrast is used. Perineal ultrasound provides sagittal, coronal and oblique sectional imaging, with the mid-sagittal plane being the most commonly used as this gives an overall assessment of all anatomical structures (bladder, urethra, vaginal walls, anal canal and rectum) between the posterior surface of the symphysis pubis (SP) and the posterior part of the levator ani (LA) (FIGURE 2a-2b). The imaging is usually performed at

rest, on maximal Valsalva maneuver and on pelvic floor muscle contraction (PFMC). The access to the mid-sagittal plane allows the following evaluations (106):

- Integrity of the perineal body: appearing as a triangular shaped, slightly hyperechoic structure anterior to the anal sphincter;
- Measurement of the anorectal angle (ARA): formed by the longitudinal axis of the anal canal and the posterior rectal wall;
- Dynamic assessment of the posterior compartment. During Valsalva it is possible to visualize descent of an enterocele, to assess the movement of the anterior rectal wall to detect a rectocele, and to evaluate movement of the PR and ARA to diagnose pelvic floor dyssynergy (FIGURE 2c).

Fig 2 a

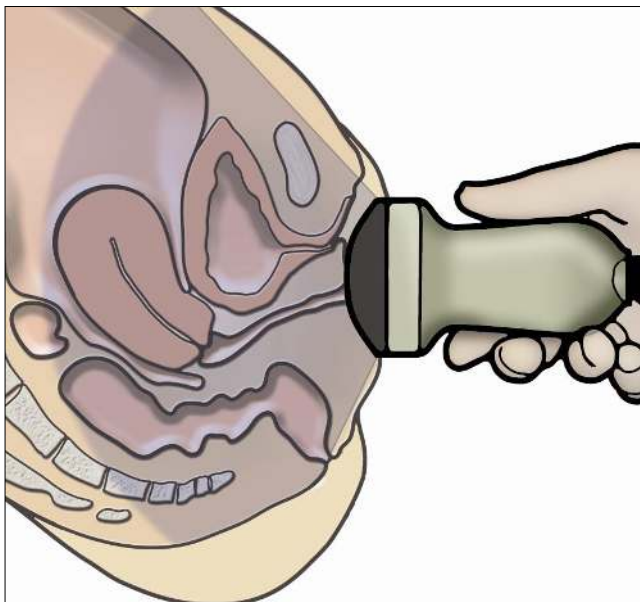


Fig 2b

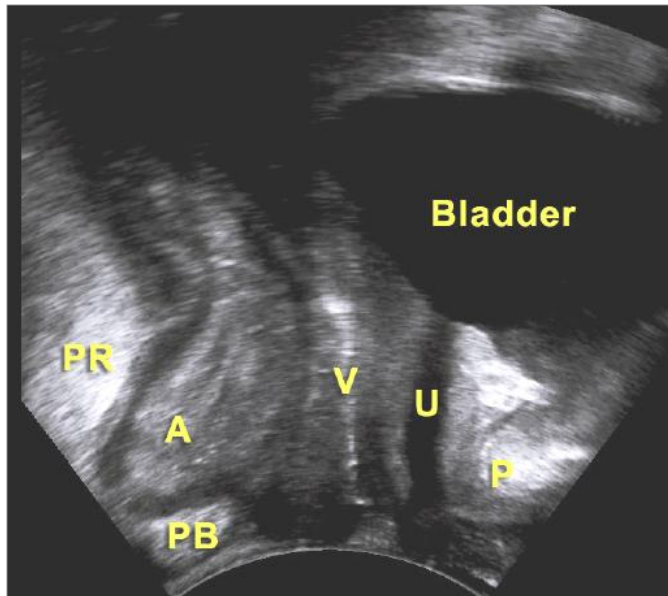


Fig 2c

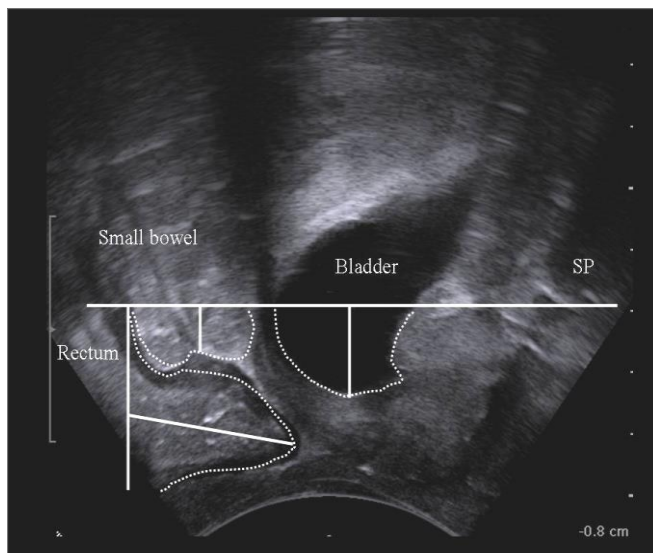


Figure 2: 2D-Transperineal ultrasound. (a) Schematic drawing; (b) Pelvic organs at rest; (c) Pelvic organs descent below the symphysis pubis line after Valsalva maneuver (cystocele, enterocele, rectocele). PR: puborectalis muscle; A: anal canal; PB: perineal body; V: vagina; U: urethra; P/SP: symphysis pubis

3D TPUS may be performed with volumetric probes (electronic curved array of 4–8 MHz). An advantage of this technique is the opportunity to obtain tomographic or multislice imaging, e.g. in the axial plane, in order to assess the entire PR and its attachment to the pubic rami (107) (FIGURE 3). It is also possible to measure the diameter and area of the levator hiatus (LH) and determine the degree of hiatal distension on Valsalva. Four dimensional (4D) imaging indicates real-time acquisition of volume ultrasound data.

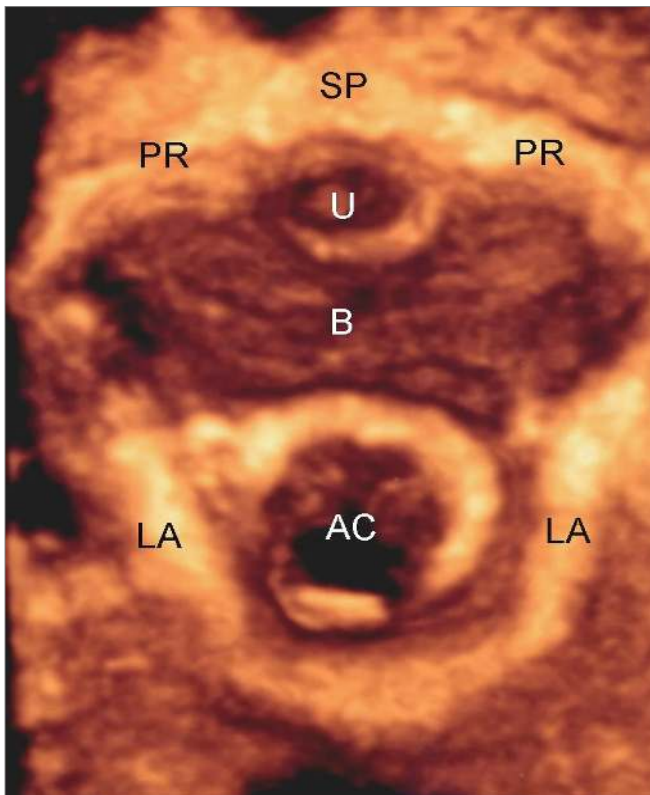


Figure 3: 3D-Transperineal ultrasound. Axial image of the pelvic floor at rest showing the LA attachment to the pubic rami (PR). AC: anal canal; LA: levator ani; B: bladder; U: urethra; SP: symphysis pubis

5.1.3 Transvaginal ultrasonography (TVUS)

Transvaginal ultrasound is performed with the patient placed in the dorsal lithotomy position. Currently, the transducers used for pelvic floor 3D TVUS are high multi-frequency (9-16 MHz), 360° rotational mechanical probe or radial electronic probe (9) (FIGURE 4a). The pelvic floor is divided into four levels of assessment in the axial plane referring to the following anatomical structures (108):

- **Level I:** at the highest level the bladder base is visualized on the screen at 12 o'clock position and the inferior third of the rectum at 6 o'clock position;
- **Level II:** corresponds to the bladder neck, the intramural region of the urethra and to the anorectal junction (ARJ). At this level the subdivisions of the LA (pubovaginalis, puboperinealis, puboanalis, puborectalis, and iliococcygeus) may be identified;
- **Level III:** corresponds to the midurethra and to the upper third of the anal canal. At this level the LA is visualized as a multilayer hyperechoic sling coursing lateral to the vagina and posteriorly to the anal canal and attaching to the inferior pubic ramus (FIGURE 4b). In the axial plane of minimal hiatal dimensions, identified as the minimal distance between the inferior edge of the SP and the anterior border of the LA at the ARA, the biometric indices (anteroposterior and transverse diameters, area) of the LH can be determined (FIGURE 4c)(109);
- **Level IV:** at the outer level, the perineal muscles (bulbospongiosus, ischiocavernosus and superficial transverse perineii muscles), the perineal body, the distal urethra and the middle and inferior third of the anal canal are visualized. The anterior-posterior diameter of the urogenital hiatus (UGH), corresponding to the SP-perineal body distance, can be determined (110).

Transvaginal ultrasound may be also performed with electronic probes with linear array which provide mid-sagittal image of the posterior compartment (99). The main advantage of this technique is the dynamic assessment of the anorectal region, during Valsalva and pelvic floor muscle contraction (PFMC).

Fig 4a

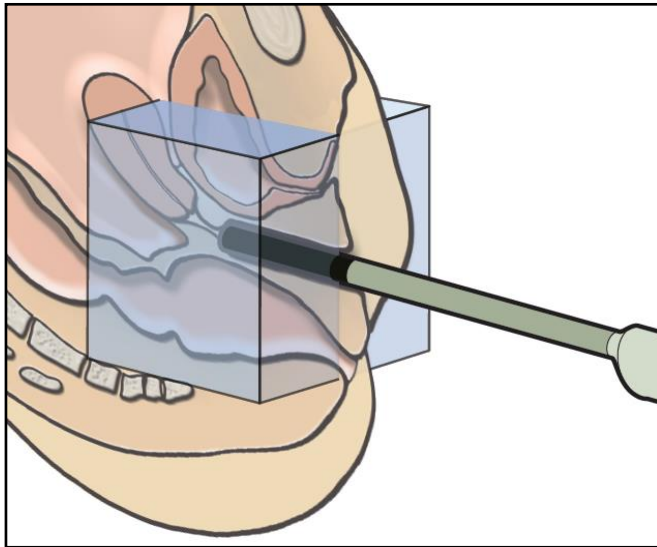


Fig 4b

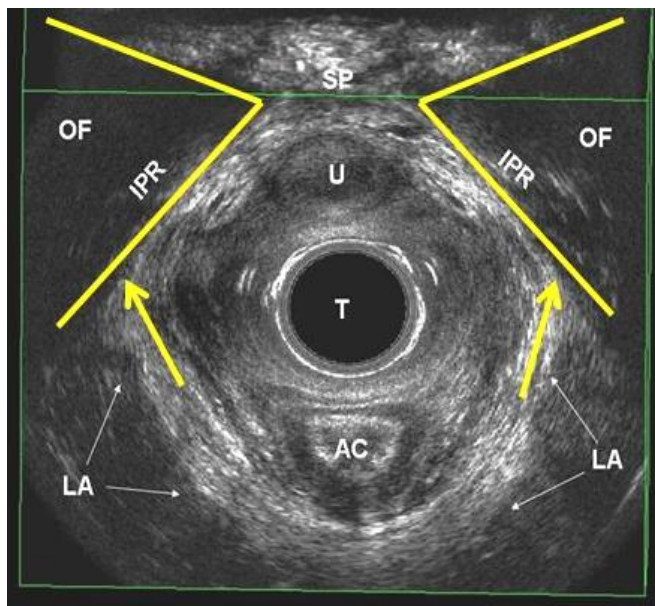


Fig 4c

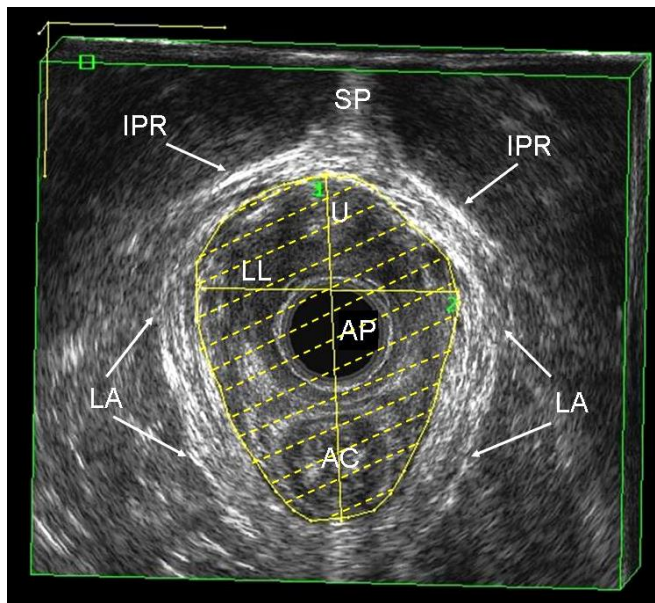


Figure 4: 3D-Endovaginal ultrasound. (a) Schematic drawing; (b) Axial image of the pelvic floor at Level III, showing the LA attachment to the inferior pubic rami (IPR) and (c) the levator hiatus. AC: anal canal; LA: levator ani; B: bladder; U: urethra; SP: symphysis pubis; OF: obturator foramen; T: transducer; AP: anteroposterior diameter of the levator hiatus; LL: laterolateral diameter of the levator hiatus

5.1.4 Clinical applications of ultrasonography of the posterior compartment

5.1.4.1 Fecal incontinence

EAUS has become the gold standard for morphological assessment of the anal canal (98). The International Consultation on Incontinence (ICI) (chapter 16) (111) has recommended EAUS as the first line imaging investigation for faecal incontinence to differentiate intact anal sphincters and sphincter lesions (defects, scarring, thinning, thickening and atrophy). The operator should identify if there is a combined or isolated lesion of the IAS and EAS and report the number of defects, as well as the extent of the defect circumferentially (radial angle in degrees or in hours of the clock) and longitudinally (proximal, distal or full length) (111-113). Using 3D EAUS, two scoring systems have been proposed to define the severity of anal sphincter damage (116-117).

EAUS has an important role in detecting undiagnosed anal sphincter injuries following vaginal delivery (2) and can be useful in the management of subsequent pregnancies

following OASIS (118). It is also useful to evaluate the results of treatment (anterior sphincter repair, bulking agent injections) (98, 111).

5.1.4.2 Levator ani injuries

Levator avulsion is the disconnection of the muscle from its insertion on the inferior pubic ramus and the pelvic sidewall, whereas tears may occur in any part of the muscle. Avulsion is a common consequence of overstretching of the LA during the second stage of labor and it is detectable by 3D TVUS and 3D TPUS imaging as the lateral attachments of the LA to the pubic bone are clearly visualized (119). Defects are usually visualized most clearly on maximal PFMC. Tomographic ultrasound imaging is particularly useful. Levator ani injuries affect the size of the levator hiatus, with a hiatal enlargement to over 25cm² on Valsalva maneuver defined as ‘ballooning’, and are related to symptoms and signs of prolapse .

5.1.4.3 Obstructed defecation syndrome (ODS)

The term obstructed defecation syndrome (synonym: “outlet obstruction”) encompasses all pelvic floor dysfunctions which are responsible for an incomplete evacuation of fecal contents from the rectum, straining at stool and vaginal digitations. During maximal Valsalva maneuver, dynamic TPUS and TVUS may be used to demonstrate (105, 120):

- **Rectocele:** herniation of a depth of over 10 mm of the anterior rectal wall;
- **Rectal intussusception:** invagination of the rectal wall into the rectal lumen, into the anal canal or exteriorized beyond the anal canal (rectal prolapse);
- **Enterocoele:** herniation of bowel loops into the vagina. It can be graded as small, when the most distal part descends into the upper third of the vagina, moderate, when it descends into the middle third of the vagina, or large, when it descends into the lower third of the vagina;
- **Dyssynergic defecation:** the ARA becomes narrower, the LH is shortened in the anteroposterior dimension, and the PR muscle thickens as a result of contraction.

5.1.4.4. Perianal abscesses and fistulas

5.2 MRI for anal sphincters and pelvic floor (static, dynamic, endocoil) upright, supine, left lateral position

5.2.1 Static MRI

Static MRI provides detailed information of the pelvic floor anatomy (121). Current state-of-the-art MR imaging of the pelvic floor includes imaging at a magnetic field strength of 1.5 Tesla (T), using pelvic or phased-array coils and T2-weighted fast-spin echo (FSE) sequences. The spatial resolution can be enhanced by using endoluminal (endorectal, endovaginal) coils. In combination with T2-weighted FSE sequences, endoluminal coils provide improved signal-to-noise ratio (SNR) and high resolution images (122). Based on T2-weighted turbo spin-echo sequences, muscles are relative hypointense, ligaments and fascia hypointense while fat and smooth muscle are hyperintense. The prominent pelvic floor structures of the posterior compartment visualized at MRI are (FIGURE 5):

- Perineal body and superficial perineal muscles
- Anal sphincters: the IAS is easily recognized as a circular hyperintense structure. It is approximately 2.9 mm thick on endoluminal MRI. The intersphincteric space is seen as a bright line on T2-weighted MRI. The EAS has a thickness of 4.1 mm on endoluminal imaging;
- Puborectalis muscle and levator ani;
- Rectum and rectal support.

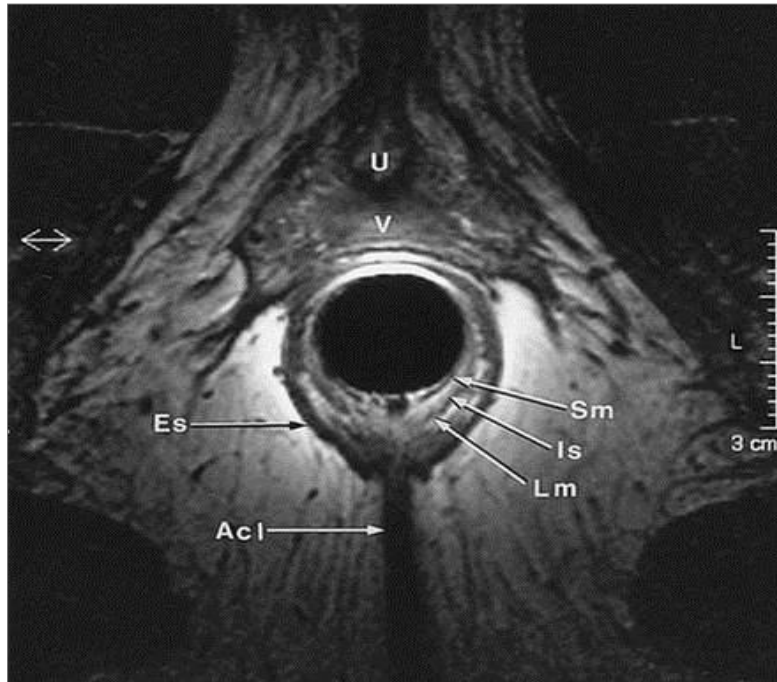


Figure 5: Static MRI. Axial image of the anal canal. U: urethra; V: vagina; SM: submucosa; IS: internal sphincter; LM: longitudinal muscle; ES: external sphincter; ACL: anococcygeal ligament

5.2.2 Dynamic MRI

With the development of fast multislice sequences MR imaging has gained increasing acceptance for dynamic imaging of pelvic floor. Because the posterior compartment is traditionally in the focus of interest, dynamic MR imaging of the pelvic floor is often called **“MR defecography”**(123) .

Dynamic pelvic imaging may be performed in an open-configuration MR system in the sitting position, or in a closed-configuration MR-system in the supine position. Both techniques are equally effective in identifying most of the clinically relevant abnormalities of the pelvic floor (123). For evaluation of the posterior compartment of the pelvic floor, the rectum should be filled with a contrast agent (ultrasound gel or mashed potatoes, gadolinium-based MR contrast agent) to study the actual act of defecation.

The use of reference lines for image evaluation is helpful (124, 125). The most used reference line is the pubococcygeal line (PCL), which is defined on midsagittal images as the line joining the inferior border of the SP to the last or second last coccygeal joint (FIGURE 6a). The ARJ is defined as the cross point between a line along the posterior wall of the distal part of the rectum and a line along the central axis of the anal canal. To determine pathologic pelvic floor descent, the measurements are made on the images, which show maximal organ descent, usually during maximal straining or during evacuation (FIGURE 6b). The ARA is defined as the angle between the posterior wall of the distal part of the rectum and the central axis of the anal canal and can be measured at rest, squeezing and straining. The extent of rectoceles, intussusception and enteroceles are measured.

The degree of pelvic floor relaxation is measured with two reference lines (FIGURE 6a): the H line which represents hiatal widening and extends from the inferior aspect of the SP to the posterior wall of the rectum at the level of the ARJ and the M line which represents hiatal descent and extends perpendicular from the PCL to the posterior end of the H line. Lesions of the pelvic musculofascial support result in widening of the hiatus and descent of the levator plate. Thus, the H and M lines tend to elongate with pelvic floor relaxation widening the levator plate descent. Abnormal pelvic floor relaxation is present, when the H line exceeds 6 cm, and when the M line exceeds 2 cm in length.

5.2.3 Clinical applications of MRI of the posterior compartment

5.2.3.1 Fecal incontinence (126-127).

5.2.3.2 Levator ani injuries

Abnormalities of the LA are identified on MRI as present or absent (128). Defect severity is further scored in each muscle from 0 (no defect) to 3 (complete loss). A summed score for the 2 sides (0 to 6) is assigned and grouped as minor (0-3) or major (4-6).

Fig 6a

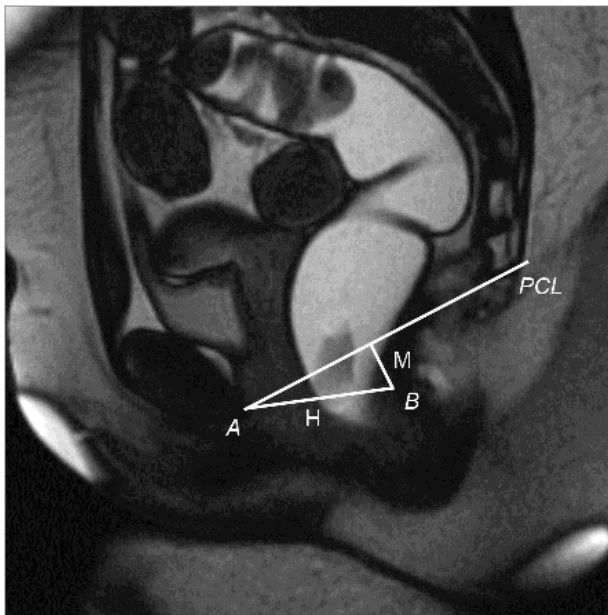


Fig 6b

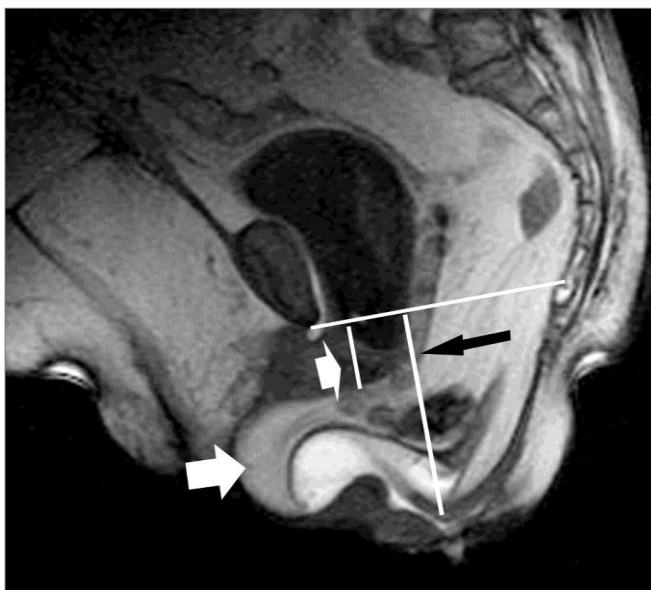


Figure 6: Dynamic MRI. (a) Midsagittal steady state free precession T2-weighted image obtained at straining shows landmarks used in the HMO-system. The landmarks are the inferior aspect of the symphysis pubis (*A*) and the posterior wall of the rectum at the level of the anorectal junction (*B*). The H line (*H*) represents the anteroposterior hiatal width and extends from *A* to *B*. The M line (*M*) represents hiatal descent and extends perpendicularly from the pubococcygeal line (*PCL*) to the posterior end of the H line. (b) During Valsalva maneuver, there is a bladder descent below the PCL (small white arrow), with a perineal descent (black arrow) and a rectocele developing with a posterior vaginal wall prolapse (long white arrow)

5.2.3.3 Obstructed defecation

During maximal Valsalva maneuver, dynamic MRI may be used to demonstrate:

- **Rectocele:** measured as the depth of wall protrusion beyond the expected margin of the normal anorectal wall. Based on sagittal MR-sections through mid of pelvis, rectoceles are graded as small (< 2cm), moderate (from 2 to 4cm), and large (> 4cm).
- **Rectal intussusception:** the infolding of the rectal mucosa occurring during defecation. An intrarectal intussusception, limited to the rectum, is distinguished from an intraanal intussusception, extending into the anal canal. The intussusception may be anteriorly, posteriorly, or circumferentially and may involve only the mucosa or the full thickness of the rectal wall;
- **Enterocele:** defined as a herniation of the peritoneal sac, which contains omental fat (peritoneocele), small bowel (enterocele) or sigmoid (sigmoidocele), into the rectovaginal or rectovesical space below the PCL. The largest distance between the PCL and the most inferior point of the enterocele is measured with a perpendicular line. Depending on this distance, small (< 3cm), moderate (3-6cm), and large (> 6cm) enteroceles are distinguished;
- **Dyssynergic defecation:** different structural imaging findings can be seen on dynamic pelvic MRI, including prominent impression of the puborectal sling, narrow anal canal, prolonged evacuation, a lack of descent of the pelvic floor and thus a failure to increase the ARA.

5.2.3.4 Perianal abscesses and fistulas

5.3 Defecating proctography

Evaluates in real time the morphology of rectum and anal canal in correlation with pelvic bony components both statically and dynamically by injection of a thick barium paste into the rectum and its subsequent evacuation (129). Contrast administration into the bladder and vagina provides a more comprehensive assessment of the pelvic organs and has been labeled “**dynamic cystoproctography**” (130).

At rest, the anal canal is closed and rectum assumes its normal upright configuration. The position of the pelvic floor is inferred by reference to the PCL (inferior margin of SP to the sacro-coccygeal junction) (FIGURE 7a). Perineal descent is measured from to this line to the ARJ, and may be up to 1.8cm at rest. During evacuation, a descent of up to 3cm from the rest position to anal canal opening is acceptable. The ARA is defined as the angle between the anal canal axis and the posterior rectal wall, and on average is around 90° (FIGURE 7b). The puborectalis length (PRL) can be estimated by measuring the distance between the ARA and SP. A normal emptying phase at the proctogram is described by five elements:

- Increase in the ARA by around 20 to 30 degrees;
- Obliteration of the puborectalis impression and the PRL increase by 3 to 4cm;
- Wide opening of the anal canal within a couple of seconds;
- Evacuation of rectal contents proceeding promptly and to completion;
- Lack of significant pelvic floor descent.

After evacuation is complete, the anal canal should close, the ARA recover and the pelvic floor return to its normal baseline position. Post toilet imaging may be required, particularly in those suspected of retained barium within rectoceles (FIGURE 7c).

Fig 7a

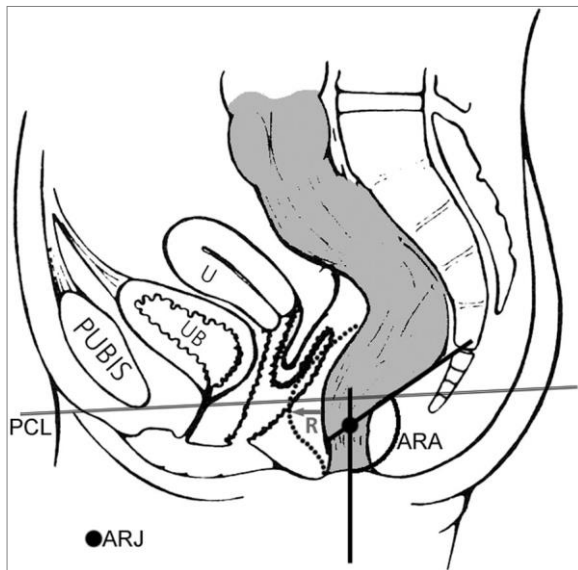


Fig 7b

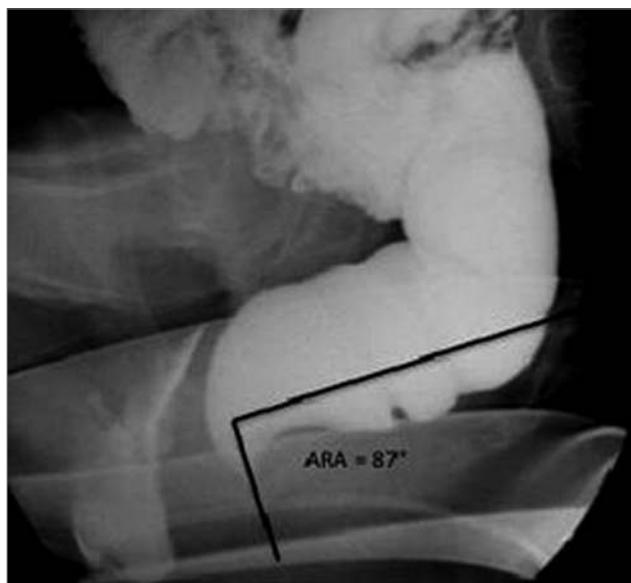


Fig 7c

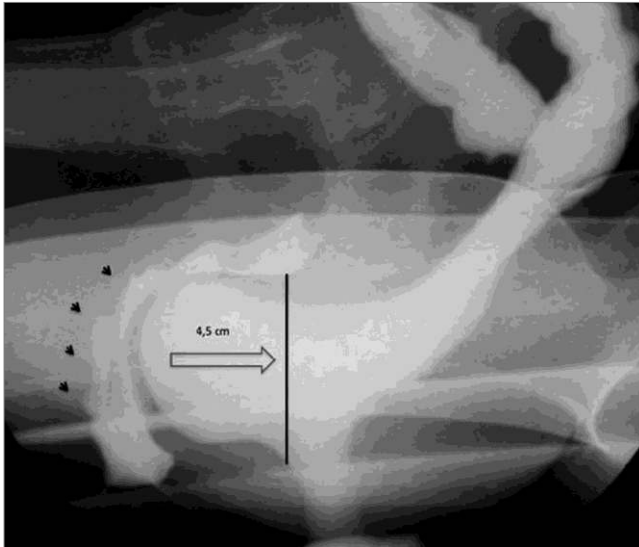


Figure 7: Defecating proctography. (a) Schematic drawing; (b) Measurement of the anorectal angle at rest (ARA); (c) Image during Valsalva manouever, showing the displacement of the anterior rectal wall (rectocele) with posterior vaginal wall prolapse (black arrows). PCL: pubococcygeal line; UB: urinary bladder; U: uterus; ARJ: anorectal junction; R: rectocele

5.3.1 Clinical applications of defecating proctography (131).

5.3.1.1 Pelvic floor descent

Pelvic floor descent, defined as the distance moved by the ARJ or ARA at rest to the point of anal canal opening, is considered abnormal if it exceeds 3cm (129).

5.3.1.2 Intussusception and prolapse

Intussusception refers to infolding of the rectal wall into the rectal lumen. It may be described as intra-rectal, intra-anal or external to form a complete rectal prolapse.

5.3.1.3 Rectocele

Rectocele diagnosis on evacuation proctography is defined as any anterior rectal bulge (FIGURE 7c). The depth of a rectocele is measured from the anterior border of the anal canal to the anterior border of the rectocele. A distance of <2cm is classified as small, 2-4cm as moderate and >4cm as large. Of more relevance however is barium trapping at the end of evacuation (defined as retention of >10% of the area, and this itself is related the size of the rectocele).

5.3.1.4 Enterocele

An enterocele is diagnosed when small bowel loops enter the peritoneal space between the rectum and vagina. Diagnosis of an enterocele on proctography is only really possible if oral contrast has been administered before the examination (129). Herniation of the sigmoid into the rectogenital space (sigmoidocele) is significantly less common than an enterocele.

5.3.1.5 Dyssynergic defecation

Various proctographic abnormalities have been described including prominent puborectal impression, a narrow anal canal, and acute anorectal angulation. However these observations may be found in normal controls and are in themselves unreliable distinguishing features.

5.4 Contrast enema

Contrast enema is used to identify colon pathology (benign and malignant lesions, diverticular disease, inflammatory conditions, congenital anomalies, intrinsic and extrinsic abnormalities) (97).

5.4.1 Single-contrast barium enema

Using an appropriate catheter, a barium-water mixture or a water-soluble solution of diatrizoate sodium (Gastrografin) is inserted into the colon with the patient in the prone position until the column of barium reaches the splenic flexure.

5.4.2 Double-contrast or air-contrast barium enema

This procedure has become the routine study for evaluation of the bowel (132). With the double-contrast examination, the colon is coated with a thin layer of contrast material and the bowel is distended with air so that the entire mucosal circumference is visualized.

5.5 Colonic transit studies (radio-opaque oral markers, pill transit, nuclear medicine scintigraphy)

Slow transit constipation can be distinguished by colonic transit studies (133, 134).

5.5.1 Radiological transit study

Segmental and total colonic transit time is assessed with the use of radio-opaque markers and sequential abdominal X-rays. There are different protocols. Most frequently used, utilizes a capsule containing 24 markers of 1x4.5mm. Patient takes one capsule on day 0 by mouth and X-ray is performed on day 5 (FIGURE 8). Patients who expel at least 80% markers on day 5 have normal colonic transit. Patients who retain 6 or more markers may have follow-up abdominal X-rays within several days. If remaining markers are scattered about the colon, the condition is slow transit or colonic inertia. If the remaining markers are accumulated in the rectum or rectosigmoid, this suggests functional outlet obstruction.

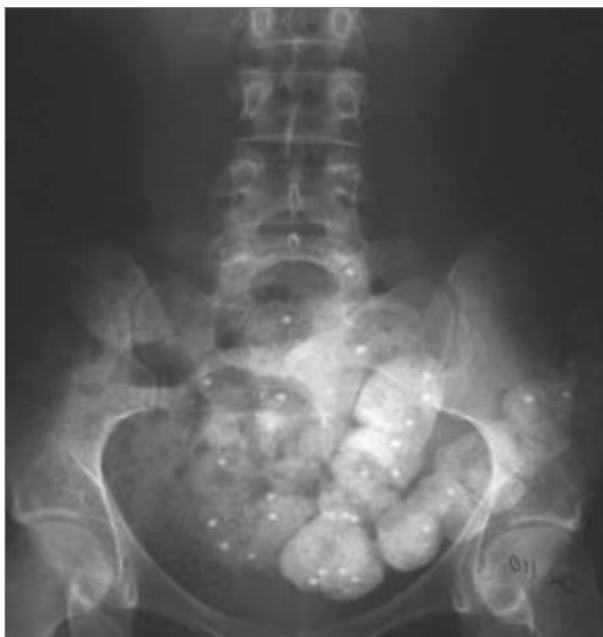

Figure 8: Radiologic transit study. On day 5, the remaining markers are more than 80%, suggesting functional outlet obstruction

5.5.2 Nuclear transit study

Colon scintigraphy is performed at 6, 24, and 48 hours in ventral and dorsal projection after oral administration of methacrylate-coated capsule of non-resorbable ¹¹¹In-dium-labeled polystyrene (¹¹¹In-DTPA) micropellets (133). The geometric center, as the sum of products of colon segment activity and colon segment number (1= ascending colon , 2= transverse colon, 3= descending colon , 4= rectosigmoid , and 5= evacuated feces) dividing by the total counts is used to determine the velocity of colonic transit. Meals normally reach the cecum at 6 hours and are evacuated in 30 to 58 hours. Retention of radioactivity in the proximal colon at 48 hours, indicates slow colonic transit while retention in the rectum indicates anorectal dysfunction.

Table I. Levels of evidence and grades of recommendation

CONDITIONS	IMAGING TECHNIQUES	LEVELS OF EVIDENCE	GRADE OF RECOMMENDATION
Fecal incontinence	<ul style="list-style-type: none"> • Endoanal US • Static MRI • Defecating proctography 	Level II	Grade B
		Level II	Grade B
		Level III	Grade C
Pelvic organ prolapse	<ul style="list-style-type: none"> • Dynamic MRI • Transperineal US • Defecating proctography 	Level II	Grade B
		Level II	Grade B
		Level II	Grade B
Obstructed defecation	<ul style="list-style-type: none"> • Dynamic MRI • Defecating proctography • Transperineal US 	Level II	Grade B
		Level II	Grade B
		Level III	Grade C
Perianal sepsis	<ul style="list-style-type: none"> • Static MRI • Endoanal US • Fistulography 	Level II	Grade B
		Level II	Grade B
		Level III	Grade C
Chronic pelvic pain	<ul style="list-style-type: none"> • Static MRI 	Level III	Grade C

6. DIAGNOSIS (most common) [defined as prevalence >10%] *Is this in women presenting with symptoms of anorectal dysfunction*

Diagnosis is based on symptoms, signs, examination, and any relevant diagnostic investigations

6.1 Local (fissures, hemorrhoids)

Fissure: Is a break in the lining of the anal canal with internal anal sphincter muscle being exposed and 90% of these are posterior.

Hemorrhoids: abnormality of the normal cushion of specialized, highly vascular tissue in the anal canal in the submucosal space. External hemorrhoids are located in the distal 2/3 of the anal canal, distal to the dentate line and covered by anoderm and seen on inspection. They typically are asymptomatic, with the most common symptom being difficulty with cleanliness and painless bleeding. They are painful if thrombosed. Internal hemorrhoids are located proximal to the dentate line and are typically evaluated by anoscopy.

6.2 Fecal incontinence

6.2.1 Anal sphincter disruption is due to discontinuity of the external anal sphincter, internal anal sphincter or both.

6.2.2 Hypocontractile/acontractile sphincter is due to neuropathy or atrophy

6.2.3 Combined anal sphincter disruption and hypocontractile/acontractile sphincter

6.2.4 Rectal overactivity could be associated with hypersensitivity (134,135)

6.2.5 Overflow incontinence seepage of stool due to faecal impaction

6.3 Obstructed defecation Syndrome

Definition: inability to empty the rectum due to physical blockage of the fecal stream during attempts at defecation. Constipation due to slow transit, irritable bowel syndrome, Hirschsprung's disease, megarectum, anismus are not within the remit of this standardization document

Associated features of obstructed defecation are:

6.3.1 Rectocele: hernia of the rectovaginal septum that invaginates into the vagina when the pelvic pressure is increased during valsalva or straining at defecation. Although rectoceles are common in women, few are symptomatic. (See FN 17)

6.3.2 Enterocele/sigmoidocele: Small bowel (enterocele) or sigmoid colon (sigmoidocele) that herniates into the pouch of Douglas and can occlude the rectum and prevent complete evacuation of the rectum or give a sense of incomplete evacuation.

6.3.3 Intussusception: full thickness invagination of the upper rectum without extrusion through the anus leading to interruption of flow of the fecal stream

6.3.4 Internal mucosal prolapse: Mucosal prolapse of the anterior, posterior or circumferential mucosal layer.

6.3.5 External rectal prolapse: Full thickness rectal prolapse outside the anal canal

6.4 Sepsis

6.4.1 Abscess/fistula in ano: cryptoglandular (90% of anorectal sepsis)

Definition: Infection in a non-Crohn's anal gland, located at the base of the dentate line, that initially forms an abscess which can be located in one of the potential spaces surrounding the anus and rectum. Diagnosis is typically made by examination and incision and drainage of the purulent material and MRI or anal endosonography may be useful. (See FN 18).

6.4.2 Perianal Crohn's disease: abscesses and fistula secondary to Crohn's disease. In 3% of patients this is the first and sometimes only symptom of Crohn's disease.

6.4.3 Ano-rectal/vaginal/perineal fistula: Abnormal communication resulting from cryptoglandular, obstetric, Crohn's disease, radiation, infection, trauma, or other causes.

Definition: A rectovaginal fistula is a communication from the rectum to the vagina and rarely the perineal area. The internal opening can occur anywhere in the rectum and could

be from diverticular disease fistulizing into the top of the vaginal cuff in a woman after a hysterectomy. This communication can exit into the vagina or any structure around the vagina including the perineal body or labia. Air and/or stool from the vagina is the usual symptom. A CT scan of the pelvis showing the rectosigmoid adherent to the vagina suggests the diagnosis. A vaginogram may display the fistula.

An anovaginal/perineal fistula is an abnormal communication from the anal canal to the vagina or perineal area. Visualization of the external and internal opening confirms the diagnosis. MRI is sometimes required in difficult situations to delineate the tract. Vaginogram may or may not display the communication.

6.5 Pain Syndromes

6.5.1 Levator ani syndrome

Definition: Episodic rectal pain caused by spasm of the levator ani muscle. Proctalgia fugax (fleeting pain in the rectum) and coccydynia (pain in the coccygeal region) are variants of levator ani syndrome.

Symptoms: Rectal spasm causes pain, typically unrelated to defecation, usually lasting > 20 min. The pain may be brief and intense or a vague ache high in the rectum. It may occur spontaneously or with sitting and can waken the patient from sleep and occurs more often on the left. The pain may feel as if it would be relieved by the passage of gas or a bowel movement. In severe cases, the pain can persist for many hours and recur frequently. The patient may have undergone various rectal operations for these symptoms, with no benefit.

Source: Ansari 2007 (Merck Manual Online Medical Library).

Signs: during clinical evaluation: a dull ache to the left 5 cm above the anus or higher in the rectum and a feeling of constant rectal pressure or burning. Physical examination can exclude other painful rectal conditions (eg, thrombosed hemorrhoids, fissures, abscesses, scarring from previous surgery). Physical examination is often normal, although tenderness

or tightness of the levator muscle, usually on the left, may be present. Occasionally the cause can be low back disorders

6.5.2 Proctalgia fugax

Definition: Proctalgia fugax (or Levator syndrome) is a severe, episodic, rectal and sacrococcygeal pain. (136) It can be caused by cramp of the pubococcygeus or levator ani muscles.

It most often occurs in the middle of the night and lasts for seconds to 20 minutes. During an episode which sometimes occurs after orgasm, the patient feels spasm-like, sometimes excruciating pain in the anus, often misinterpreted as a need to defecate. Because of the high incidence of internal anal sphincter thickening with the disorder, it is thought to be a disorder of the internal sphincter or that it is a neuralgia of pudendal nerves. It tends to occur infrequently (once a month or less).

Like all ordinary muscle cramps, it is a severe, deep rooted pain. Defecation can worsen the spasm, but may relieve it (138), or provide a measure of comfort. The pain might subside by itself as the spasm disappears on its own, or may persist or recur during the same night.

Signs: patients with proctalgia fugax are usually asymptomatic during the anorectal examination, leaving no signs or findings to support the condition, which is based on symptoms by history taking, diagnostic criteria, described above, and the exclusion of underlying organic disease (anorectal or endopelvic) with proctalgia (139) .

6.5.3 Pudendal neuralgia

Definition: Pudendal Neuralgia (PN) is a painful condition that is caused by inflammation of the pudendal nerve involving it's dermatome (140). It can affect both men and women. (See FN19)

Primary symptoms of PN include:

- a) Pelvic pain with sitting that may be less intense in the morning and increase throughout the day. Symptoms may decrease when standing or lying down. The pain can be perineal, rectal or in the clitoral / penile area; it can be unilateral or bilateral.
- b) Sexual dysfunction. In women, dysfunction manifests as pain or decreased sensation in the genitals, perineum or rectum. Pain may occur with or without touch. It may be difficult or impossible for the woman to achieve orgasm.
- c) Difficulty with urination / defecation. Patients may experience urinary hesitancy, urgency and/or frequency. Post-void discomfort is not uncommon. Patients may feel that they have to 'strain' to have a bowel movement and the movement may be painful and/or result in pelvic pain after. Constipation is also common among patients with PN. In severe cases, complete or partial urinary and/or fecal incontinence may result.
- d) Sensation of a foreign object being within the body. Some patients will feel as though there is a foreign object sitting inside the vagina or the rectum.

Signs : is important to note PN is largely a “rule out” condition. In other words, because its symptoms can be indicative of another problem, extensive testing by physical examination, assessment by touch, pinprick, bimanual pelvic palpation with attention to the pelvic floor muscles, in particular the levator and obturator muscles, tenderness of the bladder and sacrospinous ligaments are required to ensure that symptoms are not related to another condition. Maximum tenderness, or a trigger point can be produced by applying pressure to the ischial spine. Palpation of this area can reproduce pain and symptoms as a positive Tinel’s sign (138).

As PN is a diagnosis of exclusion, other conditions that should be excluded include coccygodynia, piriformis syndrome, interstitial cystitis, vulvodynia, vestibulitis, chronic pelvic pain syndrome, proctalgia, anorectal neuralgia, pelvic contracture syndrome/pelvic congestion, proctalgia fugax or levator ani syndrome.

In addition to eliminating other diagnoses, it is important to determine if the PN is caused by a true entrapment or other compression / tension dysfunctions. In almost all cases, pelvic floor dysfunction accompanies PN. Electrodiagnostic studies will help the practitioner determine if the symptoms are caused by a true nerve entrapment or by muscular problems and neural irritation.

6.6 Obstetric Anal Sphincter Injuries (OASIS)

OASIS are reported to occur in 0.5 to 14% of vaginal deliveries (2.9 to 19% of primiparous vaginal deliveries) (141). It has previously been shown in a prospective study that about one third of OASIS can be diagnosed 8 weeks after delivery by endoanal ultrasound alone. As these were not identified clinically, the injuries were believed to be “occult” (2). However, it has subsequently been proven that such injuries are not necessarily occult but in fact undiagnosed due to lack of expertise of midwives and doctors (3).

Training in diagnosis and management of perineal trauma has been shown to be suboptimal (142) and dedicated hands-on courses have shown significant improvements in diagnosis and classification of OASIS (143). Sultan et al therefore proposed a more descriptive classification of OASIS (Fig 1,2) (144) that has now been accepted internationally to support consistency in reporting (145 – 147). To avoid underestimation of the injury, if there is uncertainty regarding the full extent of the injury it should be classified as the greater degree eg. if one is unsure as to whether an injury is a Grade 3a or 3b it should be classified as 3b. This classification also has clinical relevance as it ensures increased vigilance for internal sphincter injuries that are best repaired soon after delivery (148) as persistent internal sphincter defects are associated with faecal incontinence (149). Examination techniques to improve detection of these injuries and avoiding pitfalls in diagnosis have been described in detail (141).

Fig 1 Classification of perineal trauma (141)

First degree: laceration of the vaginal epithelium or perineal skin only.

Second degree: involvement of the perineal muscles but not the anal sphincter.

Third degree: disruption of the anal sphincter muscles which should be further subdivided into:

3a: <50% thickness of external sphincter torn.

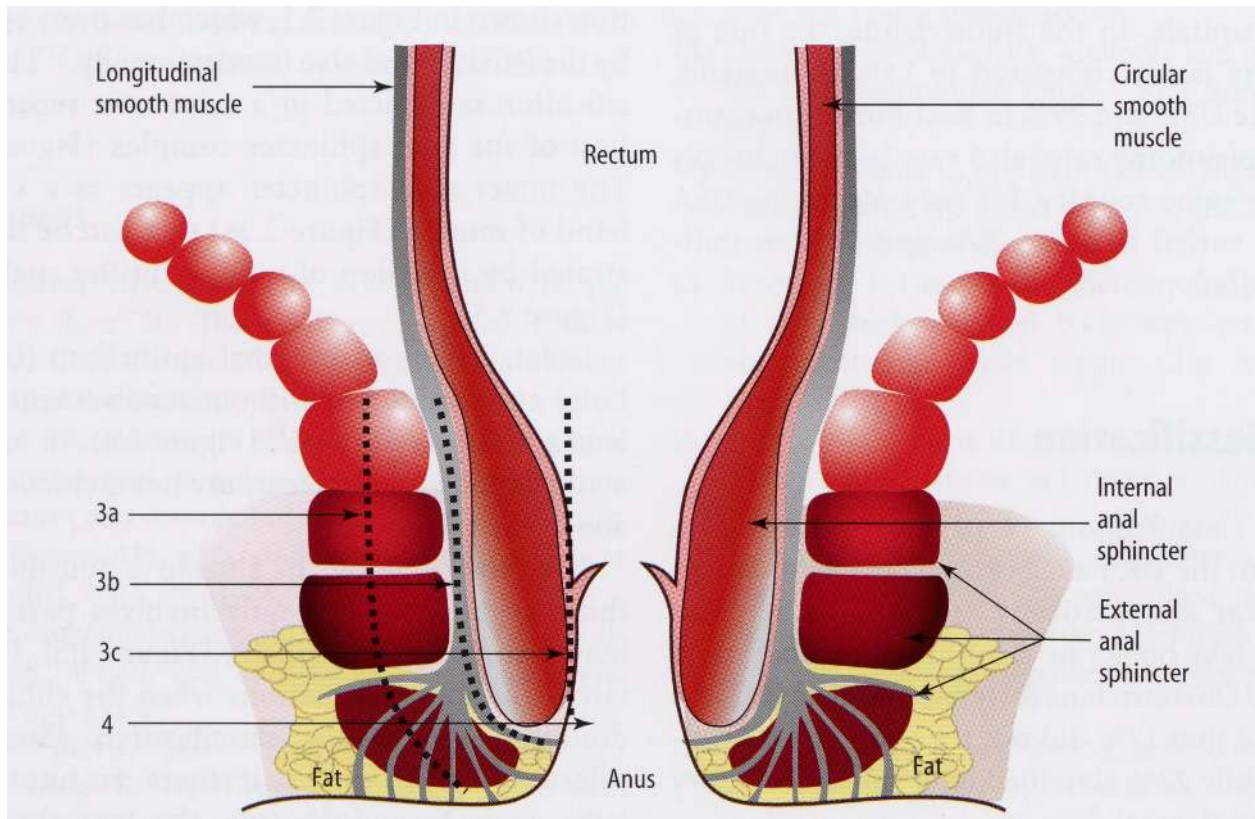
3b: >50% thickness of external sphincter torn.

3c: internal sphincter also torn.

Fourth degree: a third degree tear with disruption of the anal epithelium as well.

Button hole tear of rectum: Isolated tear of rectum without involvement of the anal sphincter

Fig 2 Classification of 3rd and 4th degree tears (with permission from Springer)



Footnotes

FN1: in regards to definition of various types of urinary incontinence, the interested reader can refer to (Haylen 2010) (7)

FN2: a history of receptive anal intercourse has been shown to increase the risk of anal incontinence (13)

FN3: Soiling is a bothersome disorder characterized by continuous or intermittent liquid anal discharge. It should be differentiated from discharge due to fistulae, proctitis, hemorrhoids and prolapse. Patients complain about staining of underwear and often wear protection.

- The discharge may cause inflammation of the perineal skin with excoriation, perianal discomfort, burning sensation, and itching.

- It often indicates the presence of an impaired internal sphincter function or a solid fecal mass in the rectum but could also be due to the inability to maintain hygiene due to hemorrhoids

FN4: *Rome III criteria for functional constipation:*

1. Must include *two or more* of the following:

- a. Straining during at least 25% of defecations
- b. Lumpy or hard stools in at least 25% of defecations
- c. Sensation of incomplete evacuation for at least 25% of defecations
- d. Sensation of anorectal obstruction/ blockage for at least 25% of defecations

e. Manual maneuvers to facilitate at least 25% of defecations (e.g., digital-evacuation, support of the pelvic floor)

f. Fewer than three defecations per week

2. Loose stools are rarely present without the use of laxatives

3. Insufficient criteria for irritable bowel syndrome

* Criteria fulfilled for the last 3 months with symptom onset at least 6 months prior to diagnosis

FN5: Difficulty evacuating stool, requiring straining efforts at defecation often associated with lumpy or hard stools, sensation of incomplete evacuation, feeling of anorectal blockage/obstruction or manual assistance to defecate (or inability to relax EAS / dyssynergic defecation)

FN6: Anorectal prolapse can be due to hemorrhoidal, mucosal, rectal prolapse or rectal intussusception. These definitions are further explained under “Signs”

FN7: this refers to pain localised to the anorectal region, and may include pain, pressure, or discomfort in the region of the rectum, sacrum, and coccyx that may be associated with pain in the gluteal region and thighs

FN8: Fissure pain during, and particularly after, defecation is commonly described as passing razor blades or glass shards. A history of receptive anal intercourse has been shown to increase the risk of anal incontinence, rectal bleeding and anal fissure(13)

FN9: Receptive anal intercourse is associated with increased risk of both any female sexual dysfunction (12), as well as with specifically female sexual arousal disorder with distress (15) (“a persistent or recurrent inability to attain [or to maintain until completion of the sexual activity] an adequate wetness and vaginal swelling response of sexual excitement”). The association of receptive anal intercourse with sexual dysfunction might be due to physiological and/or psychological processes. The psychological factors could include that emotional development problems (16, 17), poorer mood (18), poorer intimate attachment (19) as well as general dissatisfaction are associated with women’s receptive anal intercourse (20). Physiologic factors could include that: 1) mechanical stimulation of the anus and rectum during anal intercourse increases hemorrhoid risk, 2) women with hemorrhoidectomy have impaired sexual function, and 3) persons with hemorrhoids who have not yet had hemorrhoidectomy “are more likely to have abnormal perineal descent with pudendal neuropathy” (21,22) Thus, pudendal nerve dysfunction could be one mechanism leading to sexual dysfunction, and this might be the case even in the absence of diagnosed haemorrhoids (12)

FN10: a history of receptive anal intercourse has been shown to increase the risk of anal incontinence, rectal bleeding and anal fissure (13)

FN11: Unlike dyspareunia (from coitus), it might be normal to experience pain or discomfort during receptive anal intercourse.

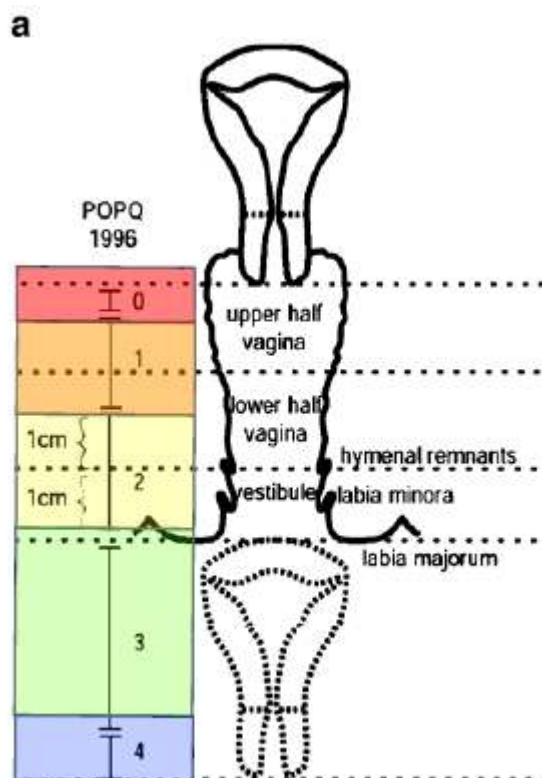
FN12: this may be accompanied by a finding of decreased anal resting tone (in some cases, the result of anal intercourse) – see under Signs. Damage to the internal anal sphincter is the likely basis

for the laxity. Unlike stool passage, receptive anal intercourse is not likely to elicit reflex relaxation of the internal sphincter.

FN13: a history of receptive anal intercourse has been shown to increase the risk of anal incontinence, rectal bleeding and anal fissure (13)

FN14: Pruritus ani has been classified into primary and secondary. The primary form is the classic syndrome of idiopathic pruritus ani. The secondary form implies an identifiable cause or a specific diagnosis.

FN15: Figure to be used from Pelvic floor dysfunction document (7) (figure 1a, 1b from ref7)



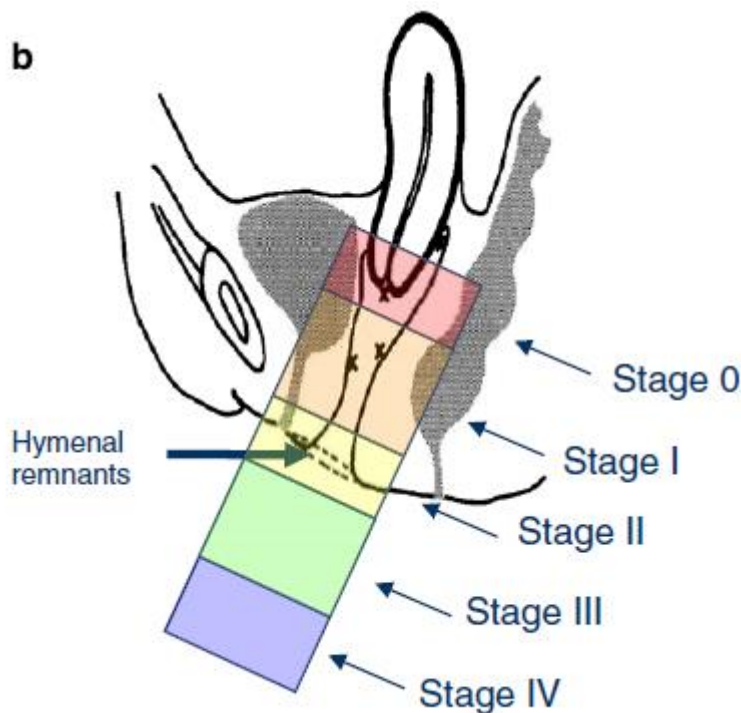


Fig. 1 a and b shows prolapse staging—0, I, II, III, and IV (uterine by the position of the leading edge of the cervix)

FN 16: there is no generally accepted definition of the term spasm and no consensus concerning how to differentiate severe muscle contractions from cramps, chronic muscle tension, or spasm (37)
 2) there is no consensus concerning which pelvic muscles are involved in the putative spasm related to anorectal dysfunction
 3. health professionals usually involved in the assessment of spasm rarely have sufficient expertise to diagnose pelvic floor muscle spasm.
 4) It is not clear whether spasm is a reaction to pain or whether pain occurs as a result of the spasm or both

FN17: a transverse defect rectocele occurs simply by a detachment of the perineal body from the rectovaginal fascia. The hammock of rectovaginal fascia supporting the rectum remains intact but separates from the perineal body. a midline vertical defect is created by a midline separation of the rectovaginal fascia, and a separation of the rectovaginal fascia can occur from the it's lateral attachments. Rectoceles are more commonly situated in the mid to distal aspect of the posterior vaginal wall

FN18: US should be the initial test in sepsis. For complex fistulas, recurrent fistulas or in Crohn's MRI could be necessary if US is not diagnostic

FN19-:The condition is also known as pudendal neuropathy, pudendal nerve entrapment, cyclist's syndrome, pudendal canal syndrome, or Alcock's syndrome.

-*Pudendal neuralgia:* (Labat, Nantes criteria) (14)

Burning anorectal pain typically over the course of the pudendal nerve. The Nantes criteria includes

- pain in the anatomical region of pudendal nerve innervation
- pain that is worse with sitting
- no waking at night with pain
- no sensory deficit on examination
- relief of symptoms with a pudendal block

- Coccydynia (coccygodynia) – complaint of with pain and point tenderness of the coccyx (this is NOT anorectal pain)

Acknowledgements

This document involves XXX rounds of full review of an initial draft, with collation of comments. Comments by those reviewers, Mr Phil Tooz-Hobson, Mr Bob Freeman, Mr Paul Moran, Prof Eckhard Petri, Prof Daa Rizk, Prof Gabriel Schaer, Assoc Prof Chris Maher, were gratefully acknowledged.

References

1. Snooks SJ, Setchell M, Swash M, Henry MM. Injury to innervation of pelvic floor sphincter musculature in childbirth. *Lancet*. 1984 Sep 8;2(8402):546-50. PubMed PMID: 6147604.
2. Sultan AH, Kamm MA, Hudson CN, Thomas JM, Bartram CI. Anal-sphincter disruption during vaginal delivery. *The New England Journal of Medicine*. 1993 Dec 23;329(26):1905-11. PubMed PMID: 8247054.
3. Andrews V, Sultan AH, Thakar R, Jones PW. Occult anal sphincter injuries--myth or reality? *BJOG : an international journal of obstetrics and gynaecology*. 2006 Feb;113(2):195-200. PubMed PMID: 16411998.
4. Dal Corso HM, D'Elia A, De Nardi P, Cavallari F, Favetta U, Pulvirenti D'Urso A, et al. Anal endosonography: a survey of equipment, technique and diagnostic criteria adopted in nine Italian centers. *Techniques in coloproctology*. 2007 Mar;11(1):26-33. PubMed PMID: 17357863.

5. Kapoor DS, Sultan AH, Thakar R, Abulafi MA, Swift RI, Ness W. Management of complex pelvic floor disorders in a multidisciplinary pelvic floor clinic. *Colorectal disease : the official journal of the Association of Coloproctology of Great Britain and Ireland*. 2008 Feb;10(2):118-23. PubMed PMID: 18199292.
6. Milsom I, Altman D, Lapitan MC, Nelson R, Sillen U, Thom D. Epidemiology of Urinary (UI) and Faecal (FI) Incontinence and Pelvic Organ Prolapse (POP). In: P Abrams L Cardozo S Khoury A Wein, Editors. 4th International Consultation on Incontinence. Chapter 1, page 35-111. Paris: Health Publication Ltd 2009
7. Haylen BT, de Ridder D, Freeman RM, Swift SE, Berghmans B, Lee J, et al. An International Urogynecological Association (IUGA)/International Continence Society (ICS) joint report on the terminology for female pelvic floor dysfunction. *International urogynecology journal*. 2010 Jan;21(1):5-26. PubMed PMID: 19937315.
8. Stedman's Medical Dictionary (2006) Lippincott, Williams and Wilkins, Baltimore, USA
9. Abrams P, Blaivas JG, Stanton SL, Andersen JT. The standardisation of terminology of lower urinary tract function. The International Continence Society Committee on Standardisation of Terminology. *Scandinavian journal of urology and nephrology Supplementum*. 1988;114:5-19. PubMed PMID: 3201169.
10. Abrams P, Cardozo L, Fall M, Griffiths D, Rosier P, Ulmsten U, et al. The standardisation of terminology of lower urinary tract function: report from the Standardisation Sub-committee of the International Continence Society. *Neurourology and urodynamics*. 2002;21(2):167-78. PubMed PMID: 11857671.
11. Toozs-Hobson P, Freeman R, Barber M, Maher C, Haylen B, Athanasiou S, et al. An International Urogynecological Association (IUGA)/International Continence Society (ICS) joint report on the terminology for reporting outcomes of surgical procedures for pelvic organ prolapse. *International urogynecology journal*. 2012 May;23(5):527-35. PubMed PMID: 22476543.

12. Brody S, Weiss P. Heterosexual anal intercourse: increasing prevalence, and association with sexual dysfunction, bisexual behavior, and venereal disease history. *Journal of sex & marital therapy*. 2011;37(4):298-306. PubMed PMID: 21707331.
13. Miles AJ, Allen-Mersh TG, Wastell C. Effect of anoreceptive intercourse on anorectal function. *Journal of the Royal Society of Medicine*. 1993 Mar;86(3):144-7. PubMed PMID: 8459377. Pubmed Central PMCID: 1293903.
14. Labat JJ, Riant T, Robert R, Amarenco G, Lefaucheur JP, Rigaud J. Diagnostic criteria for pudendal neuralgia by pudendal nerve entrapment (Nantes criteria). *Neurourology and urodynamics*. 2008;27(4):306-10. PubMed PMID: 17828787.
15. Weiss P, Brody S. Female sexual arousal disorder with and without a distress criterion: prevalence and correlates in a representative Czech sample. *The journal of sexual medicine*. 2009 Dec;6(12):3385-94. PubMed PMID: 19758283.
16. Brody S. The relative health benefits of different sexual activities. *The journal of sexual medicine*. 2010 Apr;7(4 Pt 1):1336-61. PubMed PMID: 20088868.
17. Costa RM, Brody S. Immature defense mechanisms are associated with lesser vaginal orgasm consistency and greater alcohol consumption before sex. *The journal of sexual medicine*. 2010 Feb;7(2 Pt 1):775-86. PubMed PMID: 19889144.
18. Hensel DJ, Fortenberry JD, Orr DP. Factors associated with event level anal sex and condom use during anal sex among adolescent women. *The Journal of adolescent health : official publication of the Society for Adolescent Medicine*. 2010 Mar;46(3):232-7. PubMed PMID: 20159499. Pubmed Central PMCID: 2824616.
19. Costa RM, Brody S. Anxious and avoidant attachment, vibrator use, anal sex, and impaired vaginal orgasm. *The journal of sexual medicine*. 2011 Sep;8(9):2493-500. PubMed PMID: 21676179.
20. Brody S, Costa RM. Satisfaction (sexual, life, relationship, and mental health) is associated directly with penile-vaginal intercourse, but inversely with other sexual behavior frequencies. *The journal of sexual medicine*. 2009 Jul;6(7):1947-54. PubMed PMID: 19453891.

21. Bruck CE, Lubowski DZ, King DW. Do patients with haemorrhoids have pelvic floor denervation? *International journal of colorectal disease*. 1988 Nov;3(4):210-4. PubMed PMID: 3198991.
22. Lin YH, Stocker J, Liu KW, Chen HP. The impact of hemorrhoidectomy on sexual function in women: a preliminary study. *International journal of impotence research*. 2009 Nov-Dec;21(6):343-7. PubMed PMID: 19693018.
23. Hutchinson's Clinical Methods 22nd Edition. Editors M Swash, M Glynn. WB Saunders 2002
24. Messelink B, Benson T, Berghmans B, Bo K, Corcos J, Fowler C et al. Standardization of terminology of pelvic floor muscle function and dysfunction: report from the Pelvic Floor Clinical Assessment Group of the International Continence Society. *Neurourol Urodyn* 2005; 24(4):374–380. PubMed PMID: 195977259.
25. Laycock J. Clinical evaluation of pelvic floor. In: Schussler B, Laycock J, Norton P, Stanton S, editors. *Pelvic floor re-education*. London: Springer-Verlag; 1994. p. 42–8.
26. Bo K, Finckenhagen HB. Vaginal palpation of pelvic floor muscle strength: inter-test reproducibility and comparison between palpation and vaginal squeeze pressure. *Acta obstetrica et gynecologica Scandinavica*. 2001 Oct;80(10):883-7. PubMed PMID: 11580731.
27. Morin M, Dumoulin C, Bourbonnais D, Gravel D, Lemieux MC. Pelvic floor maximal strength using vaginal digital assessment compared to dynamometric measurements. *Neurourology and urodynamics*. 2004;23(4):336-41. PubMed PMID: 15227651.
28. Isherwood PJ, Rane A. Comparative assessment of pelvic floor strength using a perineometer and digital examination. *BJOG : an international journal of obstetrics and gynaecology*. 2000 Aug;107(8):1007-11. PubMed PMID: 10955433.
29. Jeyaseelan S, Haslam J, Winstanley J, Roe BH, Oldham JA. Digital vaginal assessment: an inter-tester reliability study. *Physiotherapy*. 2001;87:243–250.
30. Laycock J, Jerwood D. Pelvic floor muscle assessment: the PERFECT scheme. *physiotherapy*. 2001;87(12):631– 642.

31. Hahn I, Milsom I, Ohlsson BL, Ekelund P, Uhlemann C, Fall M. Comparative assessment of pelvic floor function using vaginal cones, vaginal digital palpation and vaginal pressure measurements. *Gynecologic and obstetric investigation*. 1996;41(4):269-74. PubMed PMID: 8793498.
32. Kerschán-Schindl K, Uher E, Wiesinger G, Kaider A, Ebenbichler G, Nicolakis P, et al. Reliability of pelvic floor muscle strength measurement in elderly incontinent women. *Neurourology and urodynamics*. 2002;21(1):42-7. PubMed PMID: 11835423.
33. Jarvis S, Dietz H, Vancaillie T. A comparison between vaginal palpation, perineometry and ultrasound in the assessment of levator function. *Int Urogynecol J Pelvic Floor Dysfunct*. 2001;12(suppl 3):31.
34. Heitner C. *Valideringsonderzoek Naar Palpatie en Myofeedback bij Vrouwen Met Symptomen van Stress Urine-Incontinentie*. [Master of Science thesis]. Maastricht, the Netherlands: University of Maastricht; 2000. (deleted)
35. Abbott JA, Jarvis SK, Lyons SD, Thomson A, Vancaillie TG. Botulinum toxin type A for chronic pain and pelvic floor spasm in women: a randomized controlled trial. *Obstetrics and gynecology*. 2006 Oct;108(4):915-23. PubMed PMID: 17012454.
36. Reissing ED, Binik YM, Khalife S, Cohen D, Amsel R. Vaginal spasm, pain, and behavior: an empirical investigation of the diagnosis of vaginismus. *Archives of sexual behavior*. 2004 Feb;33(1):5-17. PubMed PMID: 14739686.
37. Mense S, Simons DG, Russell IJ. *Muscle Pain. Understanding its Nature, Diagnosis and Treatment*, 1st ed. Philadelphia: Lippincott Williams and Wilkins, 2001.
38. Montenegro ML, Mateus-Vasconcelos EC, Rosa e Silva JC, Nogueira AA, Dos Reis FJ, Poli Neto OB. Importance of pelvic muscle tenderness evaluation in women with chronic pelvic pain. *Pain medicine*. 2010 Feb;11(2):224-8. PubMed PMID: 20002593.
39. Heaton KW, Radvan J, Cripps H, Mountford RA, Braddon FE, Hughes AO. Defecation frequency and timing, and stool form in the general population: a prospective study. *Gut*. 1992 Jun;33(6):818-24. PubMed PMID: 1624166. Pubmed Central PMCID: 1379343.

40. Lewis SJ, Heaton KW. Stool form scale as a useful guide to intestinal transit time. *Scandinavian journal of gastroenterology*. 1997 Sep;32(9):920-4. PubMed PMID: 9299672.
41. Bliss DZ, Savik K, Jung H, Jensen L, LeMoine M, Lowry A. Comparison of subjective classification of stool consistency and stool water content. *Journal of wound, ostomy, and continence nursing : official publication of The Wound, Ostomy and Continence Nurses Society / WOCN*. 1999 May;26(3):137-41. PubMed PMID: 10711123.
42. Manning AP, Wyman JB, Heaton KW. How trustworthy are bowel histories? Comparison of recalled and recorded information. *Br Med J*. 1976 Jul 24;2(6029):213-4. PubMed PMID: 974496. Pubmed Central PMCID: 1687305.
43. Bharucha AE, Seide BM, Zinsmeister AR, Melton LJ, 3rd. Insights into normal and disordered bowel habits from bowel diaries. *The American journal of gastroenterology*. 2008 Mar;103(3):692-8. PubMed PMID: 18021288. Pubmed Central PMCID: 2557101.
44. Ashraf W, Park F, Lof J, Quigley EM. An examination of the reliability of reported stool frequency in the diagnosis of idiopathic constipation. *The American journal of gastroenterology*. 1996 Jan;91(1):26-32. PubMed PMID: 8561138.
45. Paterson C. Measuring outcomes in primary care: a patient generated measure, MYMOP, compared with the SF-36 health survey. *Bmj*. 1996 Apr 20;312(7037):1016-20. PubMed PMID: 8616351. Pubmed Central PMCID: 2350813.
46. Kelleher C, Staskin D, Cherian P, Cotterill N, Coyne K, Kopp Z, Symonds T. Patient-Reported Outcome Assessment. In: P Abrams L Cardozo S Khoury A Wein, Editors. 5th International Consultation on Incontinence. Chapter 5B, page 389-427. Paris: ICUD-EAU.2013
47. Parks AG. Royal Society of Medicine, Section of Proctology; Meeting 27 November 1974. President's Address. Anorectal incontinence. *Proceedings of the Royal Society of Medicine*. 1975 Nov;68(11):681-90. PubMed PMID: 1197295. Pubmed Central PMCID: 1864210.
48. Pescatori M, Anastasio G, Bottini C, Mentasti A. New grading and scoring for anal incontinence. Evaluation of 335 patients. *Diseases of the colon and rectum*. 1992 May;35(5):482-7. PubMed PMID: 1568401.

49. Jorge JM, Wexner SD. Etiology and management of fecal incontinence. *Diseases of the colon and rectum*. 1993 Jan;36(1):77-97. PubMed PMID: 8416784.
50. Vaizey CJ, Carapeti E, Cahill JA, Kamm MA. Prospective comparison of faecal incontinence grading systems. *Gut*. 1999 Jan;44(1):77-80. PubMed PMID: 9862829. Pubmed Central PMCID: 1760067.
51. Maeda Y, Pares D, Norton C, Vaizey CJ, Kamm MA. Does the St. Mark's incontinence score reflect patients' perceptions? A review of 390 patients. *Diseases of the colon and rectum*. 2008 Apr;51(4):436-42. PubMed PMID: 18219532.
52. Rockwood TH, Church JM, Fleshman JW, Kane RL, Mavrantonis C, Thorson AG, et al. Fecal Incontinence Quality of Life Scale: quality of life instrument for patients with fecal incontinence. *Diseases of the colon and rectum*. 2000 Jan;43(1):9-16; discussion -7. PubMed PMID: 10813117.
53. Rockwood TH, Church JM, Fleshman JW, Kane RL, Mavrantonis C, Thorson AG, et al. Patient and surgeon ranking of the severity of symptoms associated with fecal incontinence: the fecal incontinence severity index. *Diseases of the colon and rectum*. 1999 Dec;42(12):1525-32. PubMed PMID: 10613469.
54. Cotterill N, Norton C, Avery KN, Abrams P, Donovan JL. Psychometric evaluation of a new patient-completed questionnaire for evaluating anal incontinence symptoms and impact on quality of life: the ICIQ-B. *Diseases of the colon and rectum*. 2011 Oct;54(10):1235-50. PubMed PMID: 21904138.
55. Cotterill N, Norton C, Avery KN, Abrams P, Donovan JL. A patient-centered approach to developing a comprehensive symptom and quality of life assessment of anal incontinence. *Diseases of the colon and rectum*. 2008 Jan;51(1):82-7. PubMed PMID: 18008106.
56. Bug GJ, Kiff ES, Hosker G. A new condition-specific health-related quality of life questionnaire for the assessment of women with anal incontinence. *BJOG : an international journal of obstetrics and gynaecology*. 2001 Oct;108(10):1057-67. PubMed PMID: 11702838.
57. Hiller L, Radley S, Mann CH, Radley SC, Begum G, Pretlove SJ, et al. Development and validation of a questionnaire for the assessment of bowel and lower urinary tract symptoms in women.

BJOG : an international journal of obstetrics and gynaecology. 2002 Apr;109(4):413-23. PubMed PMID: 12013162.

58. Marquis P, De La Loge C, Dubois D, McDermott A, Chassany O. Development and validation of the Patient Assessment of Constipation Quality of Life questionnaire. *Scandinavian journal of gastroenterology*. 2005 May;40(5):540-51. PubMed PMID: 16036506.

59. Frank L, Kleinman L, Farup C, Taylor L, Miner P, Jr. Psychometric validation of a constipation symptom assessment questionnaire. *Scandinavian journal of gastroenterology*. 1999 Sep;34(9):870-7. PubMed PMID: 10522604.

60. Frank L, Flynn J, Rothman M. Use of a self-report constipation questionnaire with older adults in long-term care. *The Gerontologist*. 2001 Dec;41(6):778-86. PubMed PMID: 11723346.

61. Slappendel R, Simpson K, Dubois D, Keininger DL. Validation of the PAC-SYM questionnaire for opioid-induced constipation in patients with chronic low back pain. *European journal of pain*. 2006 Apr;10(3):209-17. PubMed PMID: 15914049.

62. Szeinbach SL, Baran RW, Bratten J, Jones MP. Psychometric development and validation of the chronic constipation treatment satisfaction questionnaire (CTSAT-Q). *Value in health : the journal of the International Society for Pharmacoeconomics and Outcomes Research*. 2009 Sep;12(6):1004-10. PubMed PMID: 19490553.

63. Agachan F, Chen T, Pfeifer J, Reissman P, Wexner SD. A constipation scoring system to simplify evaluation and management of constipated patients. *Diseases of the colon and rectum*. 1996 Jun;39(6):681-5. PubMed PMID: 8646957.

64. McMillan SC, Williams FA. Validity and reliability of the Constipation Assessment Scale. *Cancer nursing*. 1989 Jun;12(3):183-8. PubMed PMID: 2743302.

65. Knowles CH, Eccersley AJ, Scott SM, Walker SM, Reeves B, Lunniss PJ. Linear discriminant analysis of symptoms in patients with chronic constipation: validation of a new scoring system (KESS). *Diseases of the colon and rectum*. 2000 Oct;43(10):1419-26. PubMed PMID: 11052520.

66. Altomare DF, Spazzafumo L, Rinaldi M, Dodi G, Ghiselli R, Piloni V. Set-up and statistical validation of a new scoring system for obstructed defaecation syndrome. *Colorectal disease : the official journal of the Association of Coloproctology of Great Britain and Ireland*. 2008 Jan;10(1):84-8. PubMed PMID: 17441968.
67. Eypasch E, Williams JI, Wood-Dauphinee S, Ure BM, Schmulling C, Neugebauer E, et al. Gastrointestinal Quality of Life Index: development, validation and application of a new instrument. *The British journal of surgery*. 1995 Feb;82(2):216-22. PubMed PMID: 7749697.
68. Chassany O, Marquis P, Scherrer B, Read NW, Finger T, Bergmann JF, et al. Validation of a specific quality of life questionnaire for functional digestive disorders. *Gut*. 1999 Apr;44(4):527-33. PubMed PMID: 10075960. Pubmed Central PMCID: 1727453.
69. Muller-Lissner S, Koch G, Talley NJ, Drossman D, Rueegg P, Dunger-Baldauf C, et al. Subject's Global Assessment of Relief: an appropriate method to assess the impact of treatment on irritable bowel syndrome-related symptoms in clinical trials. *Journal of clinical epidemiology*. 2003 Apr;56(4):310-6. PubMed PMID: 12767407.
70. Krogh K, Christensen P, Sabroe S, Laurberg S. Neurogenic bowel dysfunction score. *Spinal cord*. 2006 Oct;44(10):625-31. PubMed PMID: 16344850.
71. Collin C, Wade DT, Davies S, Horne V. The Barthel ADL Index: a reliability study. *International disability studies*. 1988;10(2):61-3. PubMed PMID: 3403500.
72. Diamant NE, Kamm MA, Wald A, Whitehead WE. AGA technical review on anorectal testing techniques. *Gastroenterology*. 1999 Mar;116(3):735-60. PubMed PMID: 10029632.
73. Rao SS, Azpiroz F, Diamant N, Enck P, Tougas G, Wald A. Minimum standards of anorectal manometry. *Neurogastroenterology and motility : the official journal of the European Gastrointestinal Motility Society*. 2002 Oct;14(5):553-9. PubMed PMID: 12358684.
74. Soligo M, Salvatore S, Emmanuel AV, De Ponti E, Zoccatelli M, Cortese M, et al. Patterns of constipation in urogynecology: clinical importance and pathophysiologic insights. *American journal of obstetrics and gynecology*. 2006 Jul;195(1):50-5. PubMed PMID: 16813743.

75. Bajwa A, Emmanuel A. The physiology of continence and evacuation. Best practice & research Clinical gastroenterology. 2009;23(4):477-85. PubMed PMID: 19647684.
76. Gundling F, Seidl H, Scalercio N, Schmidt T, Schepp W, Pehl C. Influence of gender and age on anorectal function: normal values from anorectal manometry in a large caucasian population. Digestion. 2010;81(4):207-13. PubMed PMID: 20110704.
77. Rao SS, Hatfield R, Soffer E, Rao S, Beaty J, Conklin JL. Manometric tests of anorectal function in healthy adults. The American journal of gastroenterology. 1999 Mar;94(3):773-83. PubMed PMID: 10086665.
78. Read NW, Harford WV, Schmulen AC, Read MG, Santa Ana C, Fordtran JS. A clinical study of patients with fecal incontinence and diarrhea. Gastroenterology. 1979 Apr;76(4):747-56. PubMed PMID: 422003.
79. Caruana BJ, Wald A, Hinds JP, Eidelman BH. Anorectal sensory and motor function in neurogenic fecal incontinence. Comparison between multiple sclerosis and diabetes mellitus. Gastroenterology. 1991 Feb;100(2):465-70. PubMed PMID: 1985043.
80. Loening-Baucke V, Anuras S. Effects of age and sex on anorectal manometry. The American journal of gastroenterology. 1985 Jan;80(1):50-3. PubMed PMID: 3966455.
81. Orkin BA, Hanson RB, Kelly KA, Phillips SF, Dent J. Human anal motility while fasting, after feeding, and during sleep. Gastroenterology. 1991 Apr;100(4):1016-23. PubMed PMID: 2001798.
82. McHugh SM, Diamant NE. Effect of age, gender, and parity on anal canal pressures. Contribution of impaired anal sphincter function to fecal incontinence. Digestive diseases and sciences. 1987 Jul;32(7):726-36. PubMed PMID: 3595385.
83. Rao SS, Singh S. Clinical utility of colonic and anorectal manometry in chronic constipation. Journal of clinical gastroenterology. 2010 Oct;44(9):597-609. PubMed PMID: 20679903.
84. Schizas AM, Emmanuel AV, Williams AB. Vector volume manometry--methods and normal values. Neurogastroenterology and motility : the official journal of the European Gastrointestinal Motility Society. 2011 Sep;23(9):886-e393. PubMed PMID: 21722268.

85. Schizas AM, Emmanuel AV, Williams AB. Anal canal vector volume manometry. *Diseases of the colon and rectum*. 2011 Jun;54(6):759-68. PubMed PMID: 21552063.
86. Jones MP, Post J, Crowell MD. High-resolution manometry in the evaluation of anorectal disorders: a simultaneous comparison with water-perfused manometry. *The American journal of gastroenterology*. 2007 Apr;102(4):850-5. PubMed PMID: 17397410.
87. Kumar D, Waldron D, Williams NS, Browning C, Hutton MR, Wingate DL. Prolonged anorectal manometry and external anal sphincter electromyography in ambulant human subjects. *Digestive diseases and sciences*. 1990 May;35(5):641-8. PubMed PMID: 2331956.
88. Ferrara A, Pemberton JH, Grotz RL, Hanson RB. Prolonged ambulatory recording of anorectal motility in patients with slow-transit constipation. *American journal of surgery*. 1994 Jan;167(1):73-9. PubMed PMID: 8311143.
89. Ferrara A, Pemberton JH, Levin KE, Hanson RB. Relationship between anal canal tone and rectal motor activity. *Diseases of the colon and rectum*. 1993 Apr;36(4):337-42. PubMed PMID: 8458258.
90. Chiarioni G, Scattolini C, Bonfante F, Vantini I. Liquid stool incontinence with severe urgency: anorectal function and effective biofeedback treatment. *Gut*. 1993 Nov;34(11):1576-80. PubMed PMID: 8244147. Pubmed Central PMCID: 1374425.
91. Wald A, Tunuguntla AK. Anorectal sensorimotor dysfunction in fecal incontinence and diabetes mellitus. Modification with biofeedback therapy. *The New England journal of medicine*. 1984 May 17;310(20):1282-7. PubMed PMID: 6717494.
92. Merkel IS, Locher J, Burgio K, Towers A, Wald A. Physiologic and psychologic characteristics of an elderly population with chronic constipation. *The American journal of gastroenterology*. 1993 Nov;88(11):1854-9. PubMed PMID: 8237932.
93. Kamm MA, Lennard-Jones JE. Rectal mucosal electrosensory testing--evidence for a rectal sensory neuropathy in idiopathic constipation. *Diseases of the colon and rectum*. 1990 May;33(5):419-23. PubMed PMID: 2328631.

94. Andersen IS, Michelsen HB, Krogh K, Buntzen S, Laurberg S. Impedance planimetric description of normal rectoanal motility in humans. *Diseases of the colon and rectum*. 2007 Nov;50(11):1840-8. PubMed PMID: 17762962.
95. Wiesner A, Jost WH. EMG of the external anal sphincter: needle is superior to surface electrode. *Diseases of the colon and rectum* 2000;43(1): 116-117
96. Kiff ES, Swash M. Slowed conduction in the pudendal nerves in idiopathic (neurogenic) faecal incontinence. *The British journal of surgery*. 1984 Aug;71(8):614-6. PubMed PMID: 6743983.
97. Stoker J, Bartram CI, Halligan S. Imaging of the posterior pelvic floor. *European radiology*. 2002 Apr;12(4):779-88. PubMed PMID: 11960226.
98. Tubaro A, Vodusek DB, Amarenco G, Doumouchsis SK, DeLancey JOL, Fernando R, Khullar V, Puccini F, Podnar S. Imaging, neurophysiological testing and other tests. In: P Abrams L, Cardozo S, Khoury A, Wein, Editors. *5th International Consultation on Incontinence*. Chapter 7, page 507-622. Paris: ICUD-EAU.2013
99. Santoro GA, Wieczorek AP, Dietz HP, Mellgren A, Sultan AH, Shobeiri SA, Stankiewicz A, Bartram C. State of the art: an integrated approach to pelvic floor ultrasonography. *Ultrasound Obstet Gynecol*. 2011; 37(4):381-96. m CI, Halligan S. Imaging of the posterior pelvic floor. *European radiology*. 2002 Apr;12(4):779-88. PubMed PMID: 20814874.
100. Frudinger A, Halligan S, Bartram CI, Price AB, Kamm MA, Winter R. Female anal sphincter: age-related differences in asymptomatic volunteers with high-frequency endoanal US. *Radiology*. 2002 Aug;224(2):417-23. PubMed PMID: 12147837.
101. Sultan AH, Kamm MA, Talbot IC, Nicholls RJ, Bartram CI. Anal endosonography for identifying external sphincter defects confirmed histologically. *The British journal of surgery*. 1994 Mar;81(3):463-5. PubMed PMID: 8173933.
102. Williams AB, Bartram CI, Halligan S, Spencer JA, Nicholls RJ, Kmiot WA. Anal sphincter damage after vaginal delivery using three-dimensional endosonography. *Obstetrics and gynecology*. 2001 May;97(5 Pt 1):770-5. PubMed PMID: 11339932.

103. Williams AB, Cheetham MJ, Bartram CI, Halligan S, Kamm MA, Nicholls RJ, et al. Gender differences in the longitudinal pressure profile of the anal canal related to anatomical structure as demonstrated on three-dimensional anal endosonography. *The British journal of surgery*. 2000 Dec;87(12):1674-9. PubMed PMID: 11122183.
104. Santoro GA, Fortling B. The advantages of volume rendering in three-dimensional endosonography of the anorectum. *Diseases of the colon and rectum*. 2007 Mar;50(3):359-68. PubMed PMID: 17237912.
105. Dietz HP. Ultrasound imaging of the pelvic floor. Part I: two-dimensional aspects. *Ultrasound in obstetrics & gynecology : the official journal of the International Society of Ultrasound in Obstetrics and Gynecology*. 2004 Jan;23(1):80-92. PubMed PMID: 14971006.
106. Braekken IH, Majida M, Ellstrom-Engb M, Dietz HP, Umek W, Bo K. Test-retest and intra-observer repeatability of two-, three- and four-dimensional perineal ultrasound of pelvic floor muscle anatomy and function. *International urogynecology journal and pelvic floor dysfunction*. 2008 Feb;19(2):227-35. PubMed PMID: 17599234.
107. Dietz HP. Ultrasound imaging of the pelvic floor. Part II: three-dimensional or volume imaging. *Ultrasound in obstetrics & gynecology : the official journal of the International Society of Ultrasound in Obstetrics and Gynecology*. 2004 Jun;23(6):615-25. PubMed PMID: 15170808.
108. Santoro GA, Wieczorek AP, Stankiewicz A, Wozniak MM, Bogusiewicz M, Rechbereger T. High-resolution threedimensional endovaginal ultrasonography in the assessment of pelvic floor anatomy: a preliminary study. *Int Urogynecol J* 2009; 20: 1213–1222
109. Santoro GA, Wieczorek AP, Shobeiri SA, Mueller ER, Pilat J, Stankiewicz A, Battistella G. Interobserver and interdisciplinary reproducibility of 3D endovaginal ultrasound assessment of pelvic floor anatomy. *Int Urogynecol J Pelvic Floor Dysfunct* 22:53–59
110. Wagenlehner FME, Del Amo E, Santoro GA, Petros PE. Live anatomy of the perineal body in patients with 3rd degree rectocele. *Colorectal Dis* 2013 (in press).
111. Bliss DZ, Mellgren A, Whitehead WE, Chiarioni G, Emmanuel A, Santoro GA, Zbar A, Peden-McAlpine C, Northwood M, Sliker-ten Hove M, Berghmans B, Mimura. Assessment and

Conservative Management of Faecal Incontinence and Quality of Life in Adults. In: P Abrams L Cardozo S Khoury A Wein, Editors. 5th International Consultation on Incontinence. Chapter 16, page 1443-1486. Paris: ICUD-EAU.2013

112. Sultan AH, Kamm MA, Nicholls RJ, Bartram CI. Prospective study of the extent of internal anal sphincter division during lateral sphincterotomy. *Diseases of the colon and rectum*. 1994 Oct;37(10):1031-3. PubMed PMID: 7924711.

113. Richter HE, Fielding JR, Bradley CS, Handa VL, Fine P, FitzGerald MP, et al. Endoanal ultrasound findings and fecal incontinence symptoms in women with and without recognized anal sphincter tears. *Obstetrics and gynecology*. 2006 Dec;108(6):1394-401. PubMed PMID: 17138772.

114. Felt-Bersma RJ. Endoanal ultrasound in benign anorectal disorders: clinical relevance and possibilities. *Expert review of gastroenterology & hepatology*. 2008 Aug;2(4):587-606. PubMed PMID: 19072406.

115. Saranovic D, Barisic G, Krivokapic Z, Masulovic D, Djuric-Stefanovic A. Endoanal ultrasound evaluation of anorectal diseases and disorders: technique, indications, results and limitations. *European journal of radiology*. 2007 Mar;61(3):480-9. PubMed PMID: 17188828.

116. Starck M, Bohe M, Fortling B, Valentin L. Endosonography of the anal sphincter in women of different ages and parity. *Ultrasound in obstetrics & gynecology : the official journal of the International Society of Ultrasound in Obstetrics and Gynecology*. 2005 Feb;25(2):169-76. PubMed PMID: 15685668.

117. Norderval S, Markskog A, Rossaak K, Vonen B. Correlation between anal sphincter defects and anal incontinence following obstetric sphincter tears: assessment using scoring systems for sonographic classification of defects. *Ultrasound in obstetrics & gynecology : the official journal of the International Society of Ultrasound in Obstetrics and Gynecology*. 2008 Jan;31(1):78-84. PubMed PMID: 18059077.

118. Scheer I, Thakar R, Sultan AH. Mode of delivery after previous obstetric anal sphincter injuries (OASIS)--a reappraisal? *International urogynecology journal and pelvic floor dysfunction*. 2009 Sep;20(9):1095-101. PubMed PMID: 19475329.

119. Dietz HP, Moegni F, Shek KL. Diagnosis of levator avulsion injury: a comparison of three methods. *Ultrasound in obstetrics & gynecology : the official journal of the International Society of Ultrasound in Obstetrics and Gynecology*. 2012 Dec;40(6):693-8. PubMed PMID: 22605560.
120. Dietz HP, Steensma AB. Posterior compartment prolapse on two-dimensional and three-dimensional pelvic floor ultrasound: the distinction between true rectocele, perineal hypermobility and enterocele. *Ultrasound in obstetrics & gynecology : the official journal of the International Society of Ultrasound in Obstetrics and Gynecology*. 2005 Jul;26(1):73-7. PubMed PMID: 15973648.
121. Stoker J. Anorectal and pelvic floor anatomy. *Best practice & research Clinical gastroenterology*. 2009;23(4):463-75. PubMed PMID: 19647683.
122. Tan E, Anstee A, Koh DM, Gedroyc W, Tekkis PP. Diagnostic precision of endoanal MRI in the detection of anal sphincter pathology: a meta-analysis. *International journal of colorectal disease*. 2008 Jun;23(6):641-51. PubMed PMID: 18330582.
123. Mortelet KJ, Fairhurst J. Dynamic MR defecography of the posterior compartment: Indications, techniques and MRI features. *European journal of radiology*. 2007 Mar;61(3):462-72. PubMed PMID: 17145152.
124. Lakeman MM, Zijta FM, Peringa J, Nederveen AJ, Stoker J, Roovers JP. Dynamic magnetic resonance imaging to quantify pelvic organ prolapse: reliability of assessment and correlation with clinical findings and pelvic floor symptoms. *International urogynecology journal*. 2012 Nov;23(11):1547-54. PubMed PMID: 22531955. Pubmed Central PMCID: 3484313.
125. Bolog N, Weishaupt D. Dynamic MR imaging of outlet obstruction. *Romanian journal of gastroenterology*. 2005 Sep;14(3):293-302. PubMed PMID: 16200243.
126. Dobben AC, Terra MP, Slors JF, Deutekom M, Gerhards MF, Beets-Tan RG, et al. External anal sphincter defects in patients with fecal incontinence: comparison of endoanal MR imaging and endoanal US. *Radiology*. 2007 Feb;242(2):463-71. PubMed PMID: 17255418.
127. Terra MP, Beets-Tan RG, van Der Hulst VP, Dijkgraaf MG, Bossuyt PM, Dobben AC, et al. Anal sphincter defects in patients with fecal incontinence: endoanal versus external phased-array MR imaging. *Radiology*. 2005 Sep;236(3):886-95. PubMed PMID: 16014438.

128. DeLancey JO, Sorensen HC, Lewicky-Gaupp C, Smith TM. Comparison of the puborectal muscle on MRI in women with POP and levator ani defects with those with normal support and no defect. *International urogynecology journal*. 2012 Jan;23(1):73-7. PubMed PMID: 21822711. Pubmed Central PMCID: 3508430.
129. Brennan D, Williams G, Kruskal J. Practical performance of defecography for the evaluation of constipation and incontinence. *Seminars in ultrasound, CT, and MR*. 2008 Dec;29(6):420-6. PubMed PMID: 19166039.
130. Maglinte DD, Hale DS, Sandrasegaran K. Comparison between dynamic cystocolpoproctography and dynamic pelvic floor MRI: pros and cons: Which is the "functional" examination for anorectal and pelvic floor dysfunction? *Abdominal imaging*. 2012 Mar 24. PubMed PMID: 22446896.
131. Groenendijk AG, Birnie E, de Blok S, Adriaanse AH, Ankum WM, Roovers JP, et al. Clinical-decision taking in primary pelvic organ prolapse; the effects of diagnostic tests on treatment selection in comparison with a consensus meeting. *International urogynecology journal and pelvic floor dysfunction*. 2009 Jun;20(6):711-9. PubMed PMID: 19434388.
132. Rollandi GA, Biscaldi E, DeCicco E. Double contrast barium enema: technique, indications, results and limitations of a conventional imaging methodology in the MDCT virtual endoscopy era. *European journal of radiology*. 2007 Mar;61(3):382-7. PubMed PMID: 17161931.
133. Ghoshal UC, Sengar V, Srivastava D. Colonic Transit Study Technique and Interpretation: Can These Be Uniform Globally in Different Populations With Non-uniform Colon Transit Time? *Journal of neurogastroenterology and motility*. 2012 Apr;18(2):227-8. PubMed PMID: 22523737. Pubmed Central PMCID: 3325313.
134. Chan CLH, Lunniss PJ, Wang D, Williams NS, Scott SM. Rectal sensorimotor dysfunction in patients with urge faecal incontinence: evidence from prolonged manometric studies. *Gut* 2005;54:1263-1272 PubMed PMID: 15914573.
135. Santoro GA, Eitan BZ, Pryde A, Bartolo DC. Open study of low-dose amitriptyline in the

treatment of patients with idiopathic fecal incontinence. *Diseases of the colon and rectum*. 2000 Dec;43(12):1676-81; discussion 1681-2. PubMed PMID: 11156450.

136. Whitehead WE, Wald A, Diamant NE, Enck P, Pemberton JH, and Rao SS. Functional disorders of the anus and rectum. *Gut*. 1999;45 Suppl 2:II55–9)

137. In: Olden KW, Editor. *Handbook of functional gastrointestinal disorders* page 369 New York: M Dekker. 1996

138. Hibner M, Desai N, Robertson LJ, Nour M. Pudendal Neuralgia *Journal of Minimally Invasive Gynecology* 2010 Mar-Apr;17(2): 148-153. PubMed PMID: 20071246.

139. Potter MA, Bartolo DC. Proctalgia fugax. *Eur J Gastroenterol Hepatol* 2001 Nov;13(11): 1289-1290. PubMed PMID: 11692052.

140. Robert R, Prat-Pradal D, Labat JJ, Bensignor M, Raoul S, Rebai R, et al. Anatomic basis of chronic perineal pain: role of the pudendal nerve. *Surgical and radiologic anatomy : SRA*. 1998;20(2):93-8. PubMed PMID: 9658526.

141. Sultan AH, Thakar R, Fenner D. *Perineal and anal sphincter trauma*. London: Springer. 2007

142. Sultan AH, Kamm MA, Hudson CN. Obstetric perineal tears: an audit of training. *J Obstet Gynaecol* 1995;15:19-23.

143. Andrews V, Thakar R, Sultan AH. Structured hands-on training in repair of obstetric anal sphincter injuries (OASIS): an audit of clinical practice. *International urogynecology journal and pelvic floor dysfunction*. 2009 Feb;20(2):193-9. PubMed PMID: 19015800.

144. Sultan AH. Editorial: Obstetric perineal injury and anal incontinence. *Clinical Risk* 1999;5 (5):193-6

145. Norton C, Christiansen J, Butler U, Harari D, Nelson RL, Pemberton J, Price K, Rovnor E, Sultan A. Anal Incontinence. In Abrams P, Cardozo L, Khoury, Wein A (eds). *Incontinence* 2nd ed. Plymouth: Health Publication Ltd 2002:985-1044

146. Royal College of Obstetricians and Gynaecologists. *The Management of Third and Fourth Degree Perineal Tears*. London: RCOG Press: 2007. RCOG Guideline No. 29

147. Fernando R, Sultan A, Kettle C, Thakar , Radley S. Methods of repair for obstetric anal sphincter injury. Cochrane Systematic Reviews 2006 July 19;3:CD002866
148. Sultan AH, Monga AK, Kumar D, Stanton SL. Primary repair of obstetric anal sphincter rupture using the overlap technique. British journal of obstetrics and gynaecology. 1999 Apr;106(4):318-23. PubMed PMID: 10426237.
149. Mahony R, Behan M, Daly L, Kirwan C, O'Herlihy C, O'Connell PR. Internal anal sphincter defect influences continence outcome following obstetric anal sphincter injury. American journal of obstetrics and gynecology. 2007 Mar;196(3):217 e1-5. PubMed PMID: 17346526.