

An Ultrasonogram Reporting System for Thyroid Nodules Stratifying Cancer Risk for Clinical Management

Eleonora Horvath, Sergio Majlis, Ricardo Rossi, Carmen Franco, Juan P. Niedmann, Alex Castro, and Miguel Dominguez

Thyroid Board (E.H., S.M., R.R., J.P.N., A.C., M.D.), Clinica Alemana de Santiago, Av. Vitacura 5951 Santiago, Chile; and Instituto de Anatomia Patologica (C.F.), Av. Manquehue Norte 1707 of. 9 Santiago, Chile

Context: There is a high prevalence of thyroid nodules on ultrasonographic (US) examination. However, most of them are benign. US criteria may help to decide cost-effective management.

Objective: Our objective was to develop a standardized US characterization and reporting data system of thyroid lesions for clinical management: the Thyroid Imaging Reporting and Data System (TIRADS).

Design: This was a prospective study using the TIRADS, which is based on the concepts of the Breast Imaging Reporting Data System of the American College of Radiology.

Materials: A correlation of the US findings and fine needle aspiration biopsy (FNAB) results in 1959 lesions biopsied under US guidance and studied histologically during an 8-yr period was divided into three stages. In the first stage, 10 US patterns were defined. In the second stage, four TIRADS groups were defined according to risk. The percentages of malignancy defined in the Breast Imaging Reporting and Data System were followed: TIRADS 2 (0% malignancy), TIRADS 3 (<5% malignancy), TIRADS 4 (5–80% malignancy), and TIRADS 5 (>80% malignancy).

Results: The TIRADS classification was evaluated at the third stage of the study in a sample of 1097 nodules (benign: 703; follicular lesions: 238; and carcinoma: 156). Sensitivity, specificity, positive predictive value, negative predictive value, and accuracy were 88, 49, 49, 88, and 94%, respectively. The ratio of benign to malignant or follicular FNAB results currently is 1.8.

Conclusions: The TIRADS has allowed us to improve patient management and cost-effectiveness, avoiding unnecessary FNAB. In addition, we have established standard codes to be used both for radiologists and endocrinologists. (*J Clin Endocrinol Metab* 90: 1748–1751, 2009)

Thyroid nodules are highly prevalent; about one third of the adult population has thyroid nodules on ultrasonographic (US) examination (1, 2). However, less than 10% of them are malignant (3, 4). Several US characteristics have been proposed to identify nodules at risk for being malignant (5, 6). Most authors divide thyroid nodules into benign (colloid) nodules, follicular lesions, and malignant nodules.

The American College of Radiology developed the Breast Imaging Reporting and Data System (BI-RADS) (7) to characterize

in a standard fashion both mammographic and US breast lesions, and their correlation with malignancy.

The BI-RADS establishes a percentage of malignancy for each category; according to that, there is worldwide-accepted clinical management (8).

We decided to study the feasibility of applying this concept to the US evaluation of thyroid nodules and called it Thyroid Imaging Reporting and Data System (TIRADS), taking BI-RADS as a model. The goal was to group thyroid lesions in different cat-

egories with a percentage of malignancy similar to those accepted in the BI-RADS.

Materials and Methods

This is an 8-yr, prospective, institutional review board-approved study performed during three consecutive periods. A total of 1959 thyroid nodules submitted for fine needle aspiration biopsy (FNAB), was analyzed. Before proceeding to the FNAB, the operator filled a protocol for a database (FileMaker Pro 8.5; FileMaker, Inc., Santa Clara, CA). The US equipment used was the ATL HDI 5000 (Absolute Medical Equipment, Wesley Hills NY) and the Philips IU22 (Philips Healthcare, Andover, MA) with a 5–12 and 5- to 17-MHz probe and color Doppler.

FNAB was performed by five specialized radiologists, under US guidance using a 19 or 21-gauge needle attached to a 10-cc syringe. Upon aspiration a negative pressure was maintained until blood appeared in the hub of the syringe. Two or three drops of blood were placed on a glass slide to form a clot. Subsequently, the clot was removed from the glass slide and placed in 10% buffered formalin, embedded in paraffin, and sectioned for routine histological study (9). Two experienced pathologists read all the samples. The histological result of the FNAB was classified as either benign, indeterminate/suspicious (follicular lesions), or malignant, according to standard pathological criteria (10).

During stage I (from 2000–2001), we reviewed US findings of 362 thyroid nodules to define and specify their characteristics and establish US patterns. The following variables were considered: echostucture, echogenicity, shape, orientation, acoustic transmission, borders, surface, presence or absence of a capsule, calcifications, and vascularization (6).

At the second stage (from 2002–2003), we prospectively correlated the FNAB results of another set of 500 nodules with the defined US patterns and generated a TIRADS group classification (TIRADS 1–6 for general thyroid pathology and TIRADS 2–6 for nodules). The following categories were established:

- TIRADS 1: normal thyroid gland.
- TIRADS 2: benign conditions (0% malignancy).
- TIRADS 3: probably benign nodules (<5% malignancy).
- TIRADS 4: suspicious nodules (5–80% malignancy rate). A subdivision into 4a (malignancy between 5 and 10%) and 4b (malignancy between 10 and 80%) was optional.
- TIRADS 5: probably malignant nodules (malignancy >80%).
- TIRADS 6: category included biopsy proven malignant nodules.

In stage 3 (from 2003–2006), we prospectively validated the TIRADS evaluating 1097 additional selected nodules. Table 1 shows the US characteristics for each TIRADS group.

All nodules with a malignant FNAB result were submitted to surgery. Lesions that were benign by FNAB are being followed. In the group of patients with indeterminate or follicular lesions, 31% has been operated on, and the rest are being followed.

Sensitivity, specificity, positive predictive value (PPV), negative predictive value (NPV), and accuracy were calculated for the TIRADS group. For the evaluation, two groups were considered: benign and non-benign. The latter included both malignant and follicular lesions.

The radiologist performing the procedure filled a protocol stating his/her opinion about the indication for FNAB: “well indicated” vs. “would not perform FNAB.”

Results

The size of the lesions undergoing FNAB ranged from 4–60 mm.

Figure 1 shows the 10 US patterns derived from the analysis of 362 nodules seen during the first stage.

Table 1 shows the correlation of second-stage FNAB results and the US patterns, allowing us to define the TIRADS groups according to their risk of malignancy.

In Table 2, we show the correlation between the TIRADS classification and FNAB results of 1097 nodules (stage 3). Of them, 703 had a benign FNAB, and 394 had a “non-benign” diagnosis (follicular lesions and malignant tumors).

The average patient follow-up of the third stage (1097 nodules) is 3.9 yr (range 2.1–5.8).

The probability of a malignant FNAB in TIRADS 2, 3, 4 (4A and 4B), and 5 was 0, 3.4, 14 (7 and 27%), and 87%, respectively. The probability of finding a follicular lesion in the FNAB of nodules classified as TIRADS 2, 3, 4, and 5 was 0, 10.7, 31, and 3.1%, respectively.

Sensitivity, specificity, PPV, NPV, and accuracy were 88, 49, 49, 88, and 94%, respectively.

TABLE 1. US characteristics of thyroid nodules, 10 US patterns with their malignancy risk, and TIRADS category

Description of US pattern	US patterns	Malignancy	TIRADS
Anechoic with hyperechoic spots, nonvascularized lesion.	Colloid type 1		
Nonencapsulated, mixed, nonexpansile, with hyperechoic spots, vascularized lesion, “grid” aspect (spongiform nodule).	Colloid type 2	0%	TIRADS 2: benign findings
Nonencapsulated, mixed with solid portion, isoechogenic, expansile, vascularized nodule with hyperechoic spots.	Colloid type 3		
Hyper, iso, or hypoechoic, partially encapsulated nodule with peripheral vascularization, in Hashimoto’s thyroiditis.	Hashimoto pseudo-nodule	<5%	TIRADS 3: probably benign
Solid or mixed hyper, iso, or hypoechoic nodule, with a thin capsule.	Simple neoplastic pattern	5–10%	TIRADS 4A: undetermined
Hypoechoic lesion with ill-defined borders, without calcifications.	de Quervain pattern		
Hyper, iso, or hypoechoic, hypervascularized, encapsulated nodule with a thick capsule, containing calcifications (coarse or microcalcifications).	Suspicious neoplastic pattern		
Hypoechoic, nonencapsulated nodule, with irregular shape and margins, penetrating vessels, with or without calcifications	Malignant pattern A	10–80%	TIRADS 4B: suspicious
Iso or hypoechoic, nonencapsulated nodule with multiple peripheral microcalcifications and hypervascularization.	Malignant pattern B	>80%	TIRADS 5: consistent with malignancy
Nonencapsulated, isoechoic mixed hypervascularized nodule with or without calcifications, without hyperechoic spots.	Malignant pattern C Cancer, confirmed by previous biopsy	100%	TIRADS 6: malignant

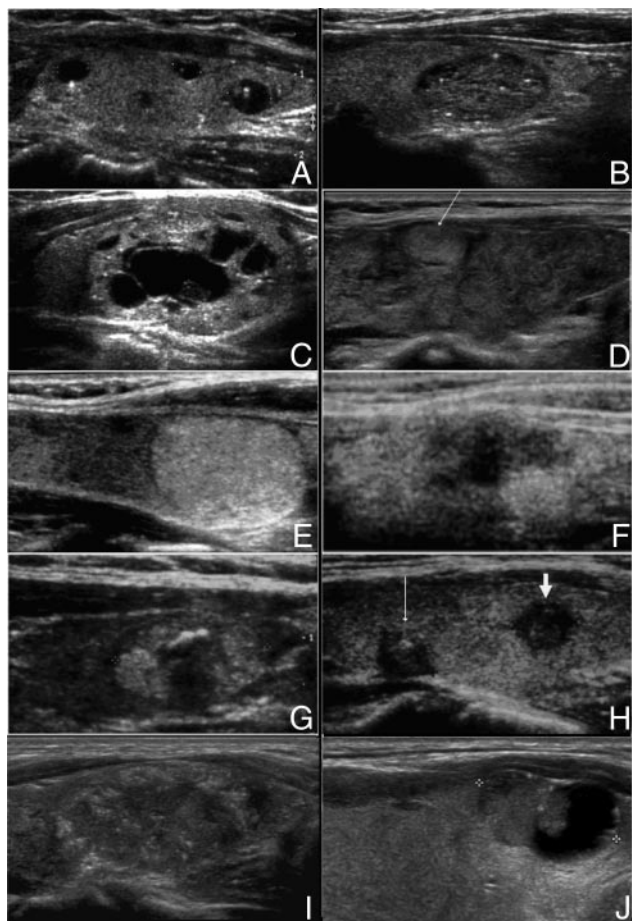


FIG. 1. A, US image of multiple typical colloid cysts: anechoic areas with hyperechoic spots (type 1 colloid pattern). B, US image of a type 2 colloid nodule: a mixed, nonexpansile, nonencapsulated structure with a “grid” appearance given by isoechoic solid areas and hyperechoic spots. The gland is not enlarged. C, US image of a colloid type 3 pattern: a mixed, nonencapsulated, expansile, isoechoic nodule with hyperechoic spots and broad septa. D, US aspect of Hashimoto thyroiditis with a pseudo-nodule: normal size heterogeneous gland with lobulated borders and a hyperechoic pseudo-nodule (arrow), partially surrounded by a halo. E, US image of a simple neoplastic pattern (4A): a solid hyperechoic nodule without calcifications, surrounded by a thin capsule. F, A hypoechoic area with ill-defined borders, without calcifications. This pattern may be found in both subacute thyroiditis and carcinomas. G, US image of a suspicious neoplastic pattern (4B): an encapsulated heterogeneous nodule with coarse calcifications, surrounded by a thick capsule. H, US image of malignant pattern A: solid hypoechoic, irregular nodules with ill-defined margins, with calcifications (thin arrow) or without calcifications (thick arrow). I, US image of malignant pattern B: solid, nonencapsulated, isoechoic, ill-defined nodule with a “salt and pepper” aspect, due to peripheral microcalcifications. J, US image of malignant pattern C: a mixed, isoechoic, vascularized, nonencapsulated nodule with calcifications and no hyperechoic spots.

Out of 238 patients with follicular lesions, 74 were operated on; 12% of them had a definite malignant diagnosis in the thyroidectomy specimen.

According to the radiologist’s opinion, 375 of 1097 nodules undergoing FNAB should not have been aspirated (34%). Of

them, 93% had a benign FNAB result, 6% showed a follicular lesion, and 1% was malignant. The malignant cases were three lesions TIRADS 3, measuring less than 10 mm.

Discussion

The widespread use of imaging US techniques has generated an overwhelming increase in the recognition of thyroid nodules. Thus, there is a need to establish some basic criteria to select nodules for FNAB to minimize costs and maximize benefits. FNAB is the best tool in helping to decide between nodules that require surgery and those that can be followed. One of the limitations of FNAB is the indeterminate or follicular lesion (11), although recent immunohistochemical studies are promising (12).

However, performing FNAB in all nodules is not cost effective; it is necessary to select cases according to the risk of malignancy. Current US classifications focused mainly on the characteristics of nonfollicular lesions (3–5), whereas the TIRADS classification is useful in the description of all types of US-detected lesions, including both benign nodules and follicular lesions.

We undertook this study to improve the US characterization of nodules and establish risk groups to decide which patient should be submitted to FNAB. The American College of Radiology has successfully used this type of system for breast lesions (7). We applied the same approach for thyroid lesions and developed the TIRADS.

The US characteristics allowed us to describe 10 patterns that encompass all types of thyroid lesions. The probability of malignancy in the TIRADS groups is similar to the range used in the BI-RADS; these ranges have been extremely helpful in clinical practice. According to our definition of risk groups, patients with TIRADS 2 (benign findings) do not require FNAB. Patients with TIRAD 3 lesions should be followed; some of these patients are biopsied when clinically warranted: if the nodule grows during follow-up, the patient is not able to come back for regular follow-up checkups, patients with higher risk of malignancy like those exposed to previous radiation to the neck, those with family history of thyroid cancer, etc. Patients with TIRADS 4 and 5 nodules must be biopsied, and frequently are operated on.

Sensitivity, specificity, PPV, NPV, and accuracy calculated for the TIRADS are biased because follicular lesions are included as “non-benign,” knowing that 80% of them are follicular adenomas. In the field of breast pathology, experts consider a group of “high risk lesions” as “non-benign” for statistical purposes (8); follicular lesions could be the thyroid counterpart of that group.

TABLE 2. Correlation of TIRADS categories and risk of malignancy in FNAB histology

FNAB (n = 1097)	TIRADS 2 (n = 62)		TIRADS 3 (n = 326)		TIRADS 4 (n = 642)		TIRADS 5 (n = 67)	
Benign	62 (100%)	62 (100%)	280 (85.9%)	280 (85.9%)	353 (55%)	353 (55%)	7 (10.4%)	7 (10.4%)
Follicular lesion	0%	0%	35 (10.7%)	46 (14.1%)	199 (31%)	289 (45%)	2 (3.1%)	60 (89.6%)
Cancer	0%	0%	11 (3.4%)	46 (14.1%)	90 (14%)	289 (45%)	58 (86.5%)	60 (89.6%)

Because thyroid neoplasias are slowly growing tumors (13), a long follow-up period is necessary to consider a nodule as benign in patients not undergoing thyroidectomy. Therefore, we may have to accept the stability of the US findings and FNAB for a period of at least 4–5 yr as an indicator of a benign nodule in those patients that are being followed.

The use of the TIRADS criteria has allowed us to reduce the number of FNABs. Patients who have nodules TIRADS 2 and 3 are not currently aspirated. The ratio of benign to malignant to follicular FNAB results is currently 1.8. This is a good yield and proves that we have an effective tool for selecting patients. Indeed, this result could improve if we use the TIRADS classification strictly.

We cannot pretend to confirm surgically all nodules classified as TIRADS 2 and 3 because it would not be ethically acceptable. In these cases we will have to use FNAB result as the gold standard, and a long-term follow-up will definitely confirm the FNAB diagnosis.

We would like to stress the fact that the TIRADS classification and the FNAB are complementary procedures. The TIRADS is only a tool used to select high-risk nodules for FNAB.

Conclusions

The TIRADS classification allows for a better selection of nodules submitted to FNAB, avoiding unnecessary procedures. In addition, we unify language and codes between radiologists and endocrinologists; in this way, there is an improvement both in patient management and cost-effective follow-up.

Acknowledgments

To all the members of the Thyroid Board and Ultrasound Unit from Clinica Alemana de Santiago, who believed in this project and supported it from the beginning, our wholehearted gratitude.

Address all correspondence and requests for reprints to: Carmen

Franco M.D., Instituto de Anatomía Patológica, Av. Manquehue Norte 1707 of. 9 Santiago, Chile. E-mail: carmen.afranco@gmail.com.

Disclosure Summary: The authors have nothing to declare.

References

1. Tan GH, Gharib H 1997 Thyroid incidentalomas: management approaches to nonpalpable nodules discovered incidentally on thyroid imaging. *Ann Intern Med* 126:226–231
2. Ezzat S, Sarti DA, Cain DR, Braunstein GD 1994 Thyroid incidentalomas: prevalence by palpation and ultrasonography. *Arch Intern Med* 154:1838–1840
3. Papini E, Guglielmi R, Bianchini A, Crescenzi A, Taccogna S, Nardi F, Panunzi C, Rinaldi R, Toscano V, Pacella CM 2002 Risk of malignancy in nonpalpable thyroid nodules: predictive value of ultrasound and color-Doppler features. *J Clin Endocrinol Metab* 87:1941–1946
4. Koike E, Noguchi S, Yamashita H, Murakami T, Ohshima A, Kawamoto H, Yamashita H 2001 Ultrasonographic characteristics of thyroid nodules: prediction of malignancy. *Arch Surg* 136:334–337
5. Kim EK, Park CS, Chung WY, Oh KK, Kim DI, Lee JT, Yoo HS 2002 New sonographic criteria for recommending fine-needle aspiration biopsy of nonpalpable solid nodules of the thyroid. *AJR Am J Roentgenol* 178:687–691
6. Nam-Goong IS, Kim HY, Gong G, Lee HK, Hong SJ, Kim WB, Shong YK 2004 Ultrasonography-guided fine-needle aspiration of thyroid incidentaloma: correlation with pathological findings. *Clin Endocrinol (Oxf)* 60:21–28
7. American College of Radiology, BI-RADS Committee 2003 ACR BI-RADS®-ultrasound. In: *ACR BI-RADS breast imaging and reporting data system: breast imaging atlas*. 4th ed. Reston, VA: American College of Radiology; 1–86
8. Stavros AT, Thickman D, Rapp CL, Dennis MA, Parker SH, Sisney GA 1995 Solid breast nodules: use of sonography to distinguish between benign and malignant lesions. *Radiology* 196:123–134
9. Domínguez M, Franco C, Contreras L, Torres J, Volpato R, Cerpa F, Pérez G, Martínez V 1995 [Fine needle aspiration biopsy of thyroid nodules. Analysis of results obtained using a new method with histological examination of the sample]. *Rev Med Chil* 123:982–990 (Spanish)
10. Clark DP, Faquin WC 2005 Approach to thyroid FNA cytopathology: an overview. In: Rosenthal DL, ed. *Thyroid cytopathology*. New York: Springer; 21–29
11. Gharib H, Papini E 2007 Thyroid nodules: clinical importance, assessment, and treatment. *Endocrinol Metab Clin North Am* 36:707–735
12. Franco C, Martínez V, Allamand JP, Medina F, Glasinovic A, Osorio M, Schachter D Molecular markers in thyroid fine needle aspiration biopsy: a prospective study. *Appl Immunohistochem Mol Morphol*, in press
13. Rosai J 2004 Thyroid gland. In: Rosai J, ed. *Rosai and Ackerman's surgical pathology*. 9th ed. Edinburgh: Mosby; 560–562