

Repository of the Max Delbrück Center for Molecular Medicine (MDC)
Berlin (Germany)
<http://edoc.mdc-berlin.de/eprintid/10911>

Genetic Testing and Molecular Biomarkers

Gert C. Scheper, Carola G.M. van Berkel, Lilia Leisle, Koen E. de Groot, Ab Errami, Thomas J. Jentsch, and Marjo S. Van der Knaap

This is a copy of an article published in the “Genetic Testing and Molecular Biomarkers” © 2010 copyright Mary Ann Liebert, Inc.; “Genetic Testing and Molecular Biomarkers” is available online at: <http://online.liebertpub.com>.

Published in final edited form as:

Genetic Testing and Molecular Biomarkers. 2010 April; 14(2): 255-257
doi: <http://dx.doi.org/10.1089/gtmb.2009.0148>
Mary Ann Liebert (U.S.A.) ►

Analysis of *CLCN2* as Candidate Gene for Megalencephalic Leukoencephalopathy with Subcortical Cysts

Gert C. Scheper,¹ Carola G.M. van Berkel,¹ Lilia Leisle,² Koen E. de Groot,¹ Ab Errami,³ Thomas J. Jentsch,² and Marjo S. Van der Knaap¹

Mutations in the gene *MLC1* are found in approximately 80% of the patients with the inherited childhood white matter disorder megalencephalic leukoencephalopathy with subcortical cysts (MLC). Genetic linkage studies have not led to the identification of another disease gene. We questioned whether mutations in *CLCN2*, coding for the chloride channel protein 2 (CIC-2), are involved in MLC. Mice lacking this protein develop white matter abnormalities, which are characterized by vacuole formation in the myelin sheaths, strikingly similar to the intramyelinic vacuoles in MLC. Sequence analysis of *CLCN2* at genomic DNA and cDNA levels in 18 MLC patients without *MLC1* mutations revealed some nucleotide changes, but they were predicted to be non-pathogenic. Further, in electrophysiological experiments, one of the observed amino acid changes was shown to have no effect on the CIC-2-mediated currents. In conclusion, we found no evidence suggesting that the *CLCN2* gene is involved in MLC.

Introduction

MEGALENCEPHALIC LEUKOENCEPHALOPATHY with subcortical cysts (MLC, MIM 604004) is a rare autosomal recessive white matter disorder. All patients develop macrocephaly during the first year of life and show a slow deterioration of motor functions with ataxia and spasticity. The combined features of magnetic resonance imaging are diagnostic for the disease: diffusely abnormal and mildly swollen cerebral white matter and subcortical cysts in the anterior temporal region and often also in the frontoparietal region (van der Knaap *et al.*, 1995). Electron microscopic studies of a brain biopsy performed in a patient in whom MLC was diagnosed revealed numerous vacuoles between lamellae of myelin sheaths with splitting at the intraperiod lines (van der Knaap *et al.*, 1996).

In approximately 80% of the patients in whom MLC is diagnosed, mutations in the gene *MLC1* are found (Leegwater *et al.*, 2001, 2002; Boor *et al.*, 2006). A group of patients remains, however, in which no *MLC1* mutations can be found despite a typical MLC phenotype. Genetic linkage studies with these families have failed to lead to the identification of another disease locus, possibly due to further genetic heterogeneity.

Recently, it was shown that mice lacking the gene *CLCN2*, encoding the chloride channel protein 2 (CIC-2), develop

widespread vacuolation in the brain and spinal cord (Blanz *et al.*, 2007). Vacuoles appeared within myelin sheaths of the central but not the peripheral nervous system. Similar to *MLC1*, *CIC-2* is localized in astrocytic endfeet lining blood vessels and in Bergman glia (Schmitt *et al.*, 2003; Boor *et al.*, 2005). The similarity in white matter abnormalities between patients in whom MLC was diagnosed and homozygous *CLCN2* knockout mice and the similar localization of the *MLC1* and *CIC-2* proteins in the brain put *CLCN2* forward as an excellent candidate for a second disease gene for MLC.

Materials and Methods

Patients and MLC1 analysis

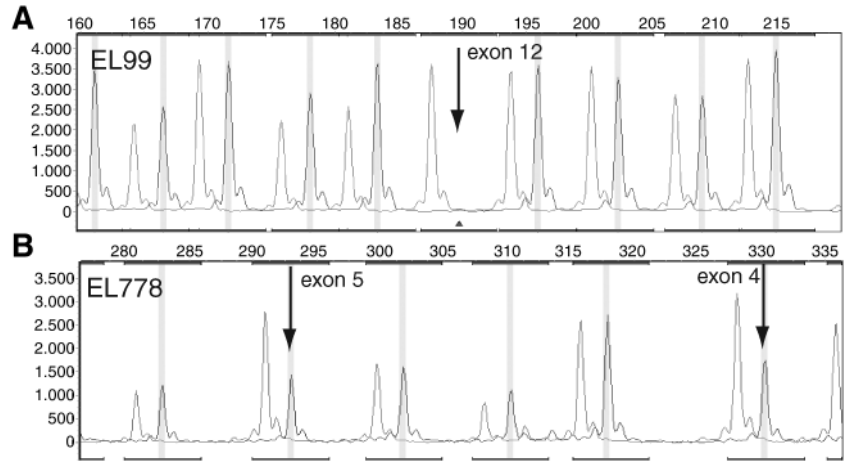
Eighteen patients with a typical clinical and magnetic resonance imaging phenotype for MLC, without evidence of involvement of the *MLC1* gene, were included in this study. *MLC1* analysis included DNA sequencing of both genomic DNA and cDNA, quantitative reverse transcriptase-polymerase chain reaction (PCR) (Boor *et al.*, 2006), and multiplex ligation-dependent probe amplification (MLPA) analysis (SALSA MLPA KIT P107 for neurometabolic disorders [MRC-Holland, Amsterdam, The Netherlands]). The resulting data were analyzed using GeneMarker (SoftGenetics, State College, PA).

¹Department of Pediatrics, VU University Medical Center, Amsterdam, The Netherlands.

²Leibniz Institute for Molecular Pharmacology (FMP) and Max Delbrück Center for Molecular Medicine (MDC) Berlin, Germany.

³MRC-Holland BV, Amsterdam, The Netherlands.

FIG. 1. Multiplex ligation-dependent probe amplification (MLPA) analysis of *MLC1*. The SALSA MLPA KIT P107 for neurometabolic disorders was used to find possible deletion of (parts of) *MLC1*. Two examples are shown for known deletions in the *MLC1* gene. (A) Homozygous deletion of exon 12 in patient EL99. The absence of a signal for *MLC1* exon 12 is indicated with an arrow in the trace of EL99 (right-hand peaks) compared with the control sample (left-hand peaks). (B) Heterozygous deletion of exons 4 and 5 in patient EL778. The reduced heights of the peaks representing exons 4 and 5 are indicated with arrows in the trace of EL778 (right-hand peaks) compared with the control sample (left-hand peaks). The other peaks represent exons of other genes that are part of the MLPA kit.



Use of patients' material for further genetic studies was approved by the Institutional Review Board of the VU University Medical Center.

Sequence analysis of *CLCN2*

GenBank reference sequences NM_004366.3 (mRNA) and NT_005612.16 (genomic DNA) were used to design PCR primers to analyze all exons and surrounding intronic regions of *CLCN2*. Primers were either designed using ExonPrimer or designed as previously described (Blanz *et al.*, 2007). PCR was carried out with Platinum Taq (Invitrogen, Carlsbad, CA) according to the manufacturer's protocol. PCR fragments were analyzed by cycle sequencing on an ABI3730 Genetic Analyzer (Applied Biosystems, Foster City, CA). For cDNA analysis, total RNA isolation and cDNA synthesis were carried out as described (Boor *et al.*, 2006). Overlapping fragments covering the complete *CLCN2* coding region were made by PCR with specific cDNA primers. The fragments

were analyzed by agarose electrophoresis and sequence analysis using forward and reverse cDNA primers. Primers sequences are available upon request.

Electrophysiology

The amino acid change p.Thr396Met was introduced into hCIC-2 (cloned in the expression vector pFROG) by site-directed mutagenesis and verified by sequencing. Two-electrode voltage-clamp analysis of *Xenopus* oocytes was performed as described (Blanz *et al.*, 2007).

In silico prediction

The possible effects of intronic changes on splicing were predicted with Netgene 2 (www.cbs.dtu.dk/services/NetGene2/) and BDGP Splice site prediction (www.fruitfly.org/seq_tools/splice.html). The possible pathogenicity of amino acid changes was predicted using PMUT (<http://>

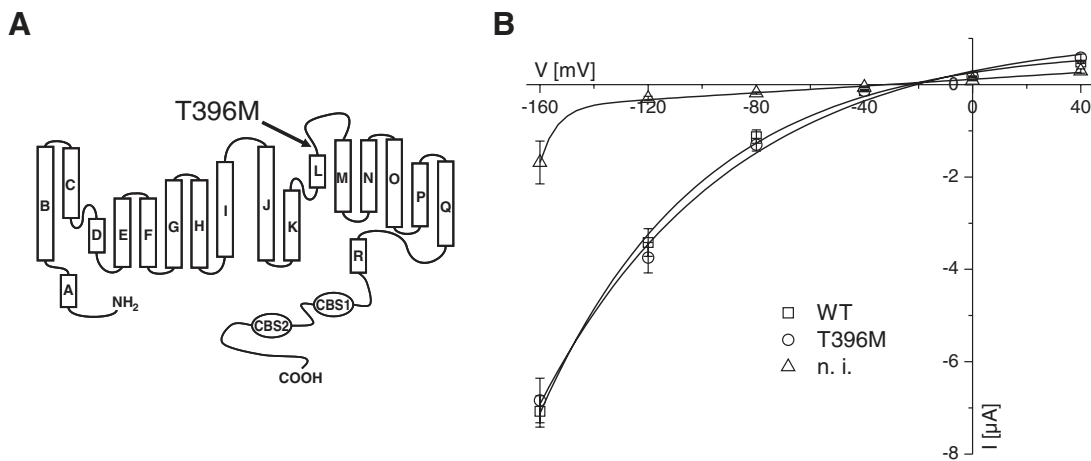


FIG. 2. Functional characterization of the chloride channel protein 2 (CIC-2) T396M mutant. (A) Schematic diagram showing the localization of the mutant residue in the CIC-2 protein. The transmembrane topology is based on the crystal structure of the *Escherichia coli* ecCIC-1. (B) Electrophysiological analysis by two-electrode voltage-clamp of *Xenopus* oocytes expressing wild type (WT) and mutant CIC-2. Current-voltage relationships of noninjected (n.i.) control oocytes and oocytes injected with WT and T396M mutant CIC-2. Currents were evaluated at the end of the voltage-step. Each data point represents the mean of >19 oocytes that were obtained from four different frogs. Error bars indicate standard error of mean. Curves were obtained by fitting double-exponential curves to the data points.

mmb2.pcb.ub.es:8080/PMut/) and PolyPhen (<http://genetics.bwh.harvard.edu/pph/>).

Results and Discussion

We selected a group of 18 patients in whom MLC was diagnosed and in whom we could not find *MLC1* mutations on genomic or cDNA level. In addition to the analyses described in Boor *et al.* (2006), genomic DNA was also analyzed by MLPA (Fig. 1). MLPA showed no evidence of genomic deletions in *MLC1* in any of the 18 patients.

For all 18 patients, the 24 exons of *CLCN2* and their surrounding intronic regions were analyzed. Besides several known single nucleotide polymorphisms, we found a heterozygous nucleotide change, c.203G>A, that results in the amino acid change p.Arg68His in one patient and the change c.1187C>T/p.Thr396Met in another patient. These changes were unique and were not observed in 180 controls. Prediction of the possible pathogenicity of these changes indicated that both changes were most likely benign amino acid substitutions.

In addition, one synonymous and several intronic changes were observed. *In silico* prediction did not suggest any possible effects on splicing of the intronic changes. We analyzed, nevertheless, *CLCN2* cDNA from all patients to study the possible presence of alternatively spliced variants of the CIC-2 mRNA. Splice variants lacking exons 6, 7, and 16 were observed in cDNA from both patient-derived and control lymphoblasts, so they are not specific for the disease samples. In three patients, a CIC-2 mRNA variant without exon 22 was observed. This variant was also expressed in control cells or in cells from other patients but at a lower level. No nucleotide changes were observed that could explain the higher levels of the Δ exon22 splice variant in the three patients. Most likely, the higher expression reflects a difference in the immortalization of the lymphocyte or in the culture conditions and not a genetic difference.

Of all the 18 patients, only one had two changes in the CIC-2 mRNA that could possibly account for the white matter disease in this patient, assuming an autosomal recessive mode of inheritance: p.Thr396Met and a relatively high level of the alternatively spliced mRNA lacking exon 22. According to the crystal structure of the *Escherichia coli* EcCIC-1 (Dutzler *et al.*, 2002), the affected amino acid is not located in a transmembrane helix but rather faces the extracellular medium (Fig. 2A). Further, Thr396 is not conserved in CIC homologs, and the effect of the change to methionine was predicted to be benign. Nonetheless, we tested the effect of this change on the chloride currents of CIC-2 by voltage-clamp recordings of *Xenopus* oocytes expressing wild-type CIC-2 or the p.Thr396Met variant (Fig. 2B). No difference in activation kinetics was seen between wild type and mutant CIC-2. Neither the magnitude nor the voltage-dependence of currents was changed by the mutation.

In conclusion, in our group of patients in whom MLC was diagnosed, we could not find a single patient who had two pathogenic mutations as would be expected for an autosomal recessive disease. In the original study that showed the phenotype of the *CLCN2* knockout mice, a cohort of 150 patients in whom leukodystrophy was diagnosed was analyzed for mutations in *CLCN2*. No positive findings similar to our results were reported, but it is unclear whether this group

contained any patients in whom MLC was diagnosed without *MLC1* mutations. One should mention, however, that CIC-2 knockout mice also display blindness and male infertility (Bosl *et al.*, 2001), which was not found or investigated in our cohort. All in all, present evidence does not support the hypothesis that mutations in *CLCN2* can cause MLC.

Acknowledgments

We thank Mathilde Fernandez Ojeda and Gajja Salomons (VU University Medical Center, Amsterdam) for their help with the MLPA analysis. Financial support was received from the Dutch Organization for Scientific Research (NWO, grant 903-42-097), The Hersenstichting (grant 10F02[2] 02), and the Optimix Foundation for Scientific Research.

Disclosure Statement

No competing financial interests exist.

References

- Blanz J, Schweizer M, Auberson M, *et al.* (2007) Leukoencephalopathy upon disruption of the chloride channel CIC-2. *J Neurosci* 27:6581–6589.
- Boor I, de Groot K, Mejaski-Bosnjak V, *et al.* (2006) Megalencephalic leukoencephalopathy with subcortical cysts: an update and extended mutation analysis of MLC1. *Hum Mutat* 27:505–512.
- Boor PK, de Groot K, Waisfisz Q, *et al.* (2005) MLC1: a novel protein in distal astroglial processes. *J Neuropathol Exp Neurol* 64:412–419.
- Bosl MR, Stein V, Hubner C, *et al.* (2001) Male germ cells and photoreceptors, both dependent on close cell-cell interactions, degenerate upon CIC-2 Cl(–) channel disruption. *EMBO J* 20:1289–1299.
- Dutzler R, Campbell EB, Cadene M, *et al.* (2002) X-ray structure of a CIC chloride channel at 3.0 Å reveals the molecular basis of anion selectivity. *Nature* 415:287–294.
- Leegwater PA, Boor PK, Yuan BQ, *et al.* (2002) Identification of novel mutations in MLC1 responsible for megalencephalic leukoencephalopathy with subcortical cysts. *Hum Genet* 110:279–283.
- Leegwater PA, Yuan BQ, van der Steen J, *et al.* (2001) Mutations of MLC1 (KIAA0027), encoding a putative membrane protein, cause megalencephalic leukoencephalopathy with subcortical cysts. *Am J Hum Genet* 68:831–838.
- Schmitt A, Gofferje V, Weber M, *et al.* (2003) The brain-specific protein MLC1 implicated in megalencephalic leukoencephalopathy with subcortical cysts is expressed in glial cells in the murine brain. *Glia* 44:283–295.
- van der Knaap MS, Barth PG, Stroink H, *et al.* (1995) Leukoencephalopathy with swelling and a discrepantly mild clinical course in eight children. *Ann Neurol* 37:324–334.
- van der Knaap MS, Barth PG, Vrensen GF, *et al.* (1996) Histopathology of an infantile-onset spongiform leukoencephalopathy with a discrepantly mild clinical course. *Acta Neuropathol* 92:206–212.

Address correspondence to:

Gert C. Scheper, Ph.D.
 Department of Pediatrics
 VU University Medical Center
 p/a W&N Building
 De Boelelaan 1085
 Amsterdam 1081HV
 The Netherlands

E-mail: gc.scheper@vumc.nl

