

## RESEARCH

# Analysis of the accuracy of linear measurements obtained by cone beam computed tomography (CBCT-NewTom)

CA Lascała<sup>\*,1</sup>, J Panella<sup>1</sup> and MM Marques<sup>2</sup>

<sup>1</sup>Department of Radiology, School of Dentistry, University of São Paulo, Brazil; <sup>2</sup>Department of Operative Dentistry, School of Dentistry, University of São Paulo, Brazil

**Objectives:** The conical beam computed tomography (CBCT) technique presents an innovation of tomographic imaging systems and subsequent volumetric image reconstruction for dentistry. When compared with other methods of tomographic imaging CBCT is characterized by rapid volumetric image acquisition from a single low radiation dose scan of the patient. The NewTom (NewTom 9000; Quantitative Radiology, Verona, Italy) is an example of such a CBCT machine dedicated to dental and maxillofacial imaging, particularly for surgical and/or prosthetics implant planning in the field of dentistry. The aim of this study was to evaluate the accuracy of the linear measurements obtained in CBCT images using a NewTom.

**Methods:** Thirteen measurements were obtained in dry skulls ( $n = 8$ ) between internal and external anatomical sites using a caliper. These were considered as real measurements. Then the dry skulls were submitted to CBCT imaging examinations. Radiographic distance measurements of the same dry skull anatomical sites were made using the NewTom QR-DVT 9000 software of the 2 mm-CTs axial section images and sagittal or coronal reconstructions. The data were compared by paired Student's *t*-test.

**Results:** The results showed that the real measurements were always larger than those for the CBCT images, but these differences were only significant for measurements of the internal structures of the skull base.

**Conclusions:** The conclusion of this study is that, although the CBCT image underestimates the real distances between skull sites, differences are only significant for the skull base and therefore it is reliable for linear evaluation measurements of other structures more closely associated with dentomaxillofacial imaging.

*Dentomaxillofacial Radiology* (2004) **33**, 291–294. doi: 10.1259/dmfr/25500850

**Keywords:** computed tomography, cone beam, X-ray computed, skull

## Introduction

The conical beam computed tomography (CBCT) technique introduces an innovation in modes of image scanning and volumetric reconstruction of computed tomography (CT) data. Due to rapid volumetric image acquisition (as low as 18 s) from a single low radiation dose scan of the patient and the low mA, the effective dose with the CBCT technique is significantly smaller than that achieved with

other CT imaging methods and is within the range of traditional dental imaging modalities.<sup>1–4</sup>

CBCT has been in operation now for several years. Its promise and application in dentistry have already been determined by its performance and low cost, together with low radiation dose.<sup>1–7</sup> However, accuracy verification for various uses has not yet been determined.

The CBCT technique could be applied in several dental areas such as implantology, surgery and oral diagnosis, among others. However, in order to determine the best application of CBCT in dentistry, it is necessary to analyse the accuracy of the data obtained related to distance measurements. Thus, the aim of this study was to evaluate

\*Correspondence to: Cesar Lascała, Departamento de Estomatologia, Faculdade de Odontologia, Universidade de São Paulo, Av. Prof. Lineu Prestes, 2227, São Paulo SP, 05508-900, Brazil; E-mail: cesaralasca@uol.com.br  
Received 4 March 2004; revised 16 July 2004; accepted 19 July 2004

the accuracy of the linear measurements in CBCT images in dentomaxillofacial as well as in other cranial areas.

## Material and methods

Eight dry skulls for the study were provided by the Anatomy Department of the Biosciences Institute at University of São Paulo. These were not identified by either age, gender or ethnic group. The Ethical Committee of the School of Dentistry, University of São Paulo, Brazil approved this research project.

For the experiments, 19 sites of the skull were chosen. At these anatomical sites 2 mm diameter metal spheres were fixed using godive (a thermoplastic material for prosthetics applications from DFL, RJ, Brazil).

The linear distances ( $n = 13$ ) were measured between the anatomical sites described in Table 1. The definition of the real distance between the selected sites was made using a high precision digital caliper directly on the dry skulls.

For obtaining the CBCT images each dry skull was immersed in water inside a plastic box. The skull was then immobilized with the median sagittal plane perpendicular to the horizontal plane, as recommended by the CBCT patient positioning protocol. Imaging was performed using the NewTom 9000 CBCT (Quantitative Radiology, Verona, Italy). The device was operated at 7 mA and

85 kV with a single scan time of 70 s. Upon completion, the skull was removed from the equipment and the image was processed with NewTom QR-DVT 9000 software. The images were obtained from 2 mm-CTs axial section and sagittal or coronal reconstructions. The same measurements made directly on the dry skulls were obtained from the CBCT images using the measuring tools of the QR-DVT 9000 software.

## Statistical analysis

The data corresponded to mean  $\pm$  standard deviation of eight replicates of the 13 measurements. The real measurements of the dry skulls were statistically compared with those obtained from the CT images of the same skull using the paired Student's *t*-test. The level of significance was 5% ( $P \leq 0.05$ ).

## Results

The data obtained from dry skulls (real measurements) as well as those from the NewTom CBCT images are expressed in Table 2. Figure 1 illustrates the steps of the experiments, such as the positioning of the metal spheres (Figure 1A), the images obtained from an axial section of the CT (Figure 1B) and from the coronal section of the CT (Figure 1C).

The data presented in the Table 2 shows that the real measurements were always larger than those taken from the tomographic images. However, these differences were only statistically significant for measurements taken between anatomical internal sites at the skull base.

## Discussion

The CBCT technique has been indicated for analysing skull structures. Image data is acquired in a digital format from a single 360° rotation scan around the patient. The digital data correspond to radiographic projection for each rotational step during the scan. Image reconstruction is made using an algorithm for volumetric tomography.<sup>8</sup> The purpose of this study was to test the accuracy of

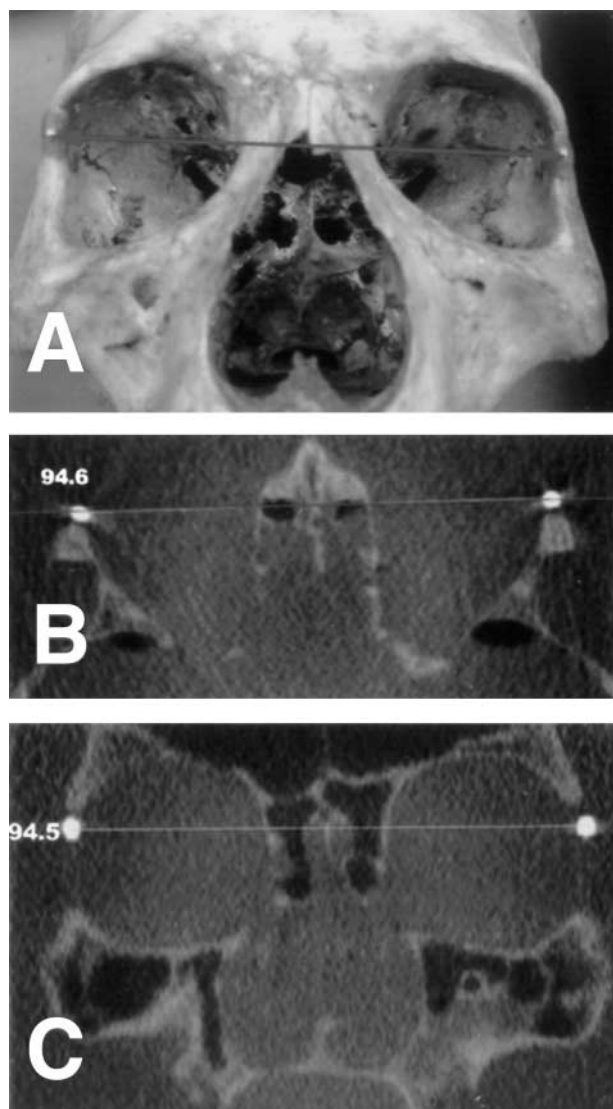
**Table 1** Anatomical sites used as references for the measurements

1	frontozygomatic suture – left (L) to frontozygomatic suture – right (R)
2	infraorbital foramen (L) to infraorbital foramen (R)
3	anterior nasal spine to posterior nasal spine
4	lateral pterygoid lamina (L) to lateral pterygoid lamina (R)
5	occipital condyle (L) to occipital condyle (R)
6	lateral pterygoid lamina (R) to posterior nasal spine
7	lateral pterygoid lamina (L) to posterior nasal spine
8	groove for superior petrosal sinus (L) to groove for superior petrosal sinus (R)
9	posterior clinoid process (L) to posterior clinoid process (R)
10	anterior clinoid process (R) to posterior clinoid process (R)
11	anterior clinoid process (L) to posterior clinoid process (L)
12	lateral pterygoid lamina (R) to anterior clinoid process (L)
13	lateral pterygoid lamina (L) to posterior clinoid process (R)

**Table 2** Measurements (mean  $\pm$  standard deviation) of the distances between the anatomical sites described in Table 1

Anatomical sites	Real (mm)	Axial (mm)	Coronal (mm)	Sagittal (mm)	P (Real X Ax)	P (Real X Co/Sg)
1	101.02 $\pm$ 7.32	99.48 $\pm$ 4.72	99.38 $\pm$ 4.86		0.19	0.17
2	54.1 $\pm$ 5.64	52.03 $\pm$ 4.08	51.88 $\pm$ 4		0.07	0.06
3	48.23 $\pm$ 4.28	45.86 $\pm$ 4.83		45.86 $\pm$ 4.68	0.10	0.08
4	52.26 $\pm$ 7.04	50.8 $\pm$ 7.06	50.62 $\pm$ 7.2		0.20	0.17
5	25.94 $\pm$ 5.92	23.91 $\pm$ 3.56	23.83 $\pm$ 3.44		0.08	0.07
6	29.7 $\pm$ 4.06	27.8 $\pm$ 2.69		28.37 $\pm$ 3.81	0.07	0.15
7	30.2 $\pm$ 5.00	28.01 $\pm$ 3.07		28.38 $\pm$ 3.23	0.14	0.14
8	29.98 $\pm$ 2.45	26.23 $\pm$ 2.53	25.9 $\pm$ 2.41		0.00 *	0.00 *
9	30.88 $\pm$ 1.37	24.38 $\pm$ 1.59	27.11 $\pm$ 1.52		0.00 *	0.00 *
10	29.61 $\pm$ 1.73	23.02 $\pm$ 2.08		25.36 $\pm$ 2.52	0.00 *	0.00 *
11	33.79 $\pm$ 9.03	29.76 $\pm$ 8.67		29.78 $\pm$ 8.65	0.00 *	0.00 *
12	40.05 $\pm$ 5.18	33.87 $\pm$ 4.66		36.62 $\pm$ 3.51	0.00 *	0.00 *
13	40.28 $\pm$ 2.18	34.72 $\pm$ 3.32		36.52 $\pm$ 1.35	0.00 *	0.00 *

\* significantly different ( $P \leq 0.05$ ); Ax, axial; Co, coronal; Sg, sagittal



**Figure 1** This figure exemplifies the measurements made in the experiments; in this case the measurements were made between the frontozygomatic sutures – left (L) to right (R). (A) Real distance at the dry skull; observe the metal spheres fixed at the skull sites; (B) axial section of the cone beam computed tomography (CBCT) and; (C) coronal section of the CBCT

measurements made in images obtained through the CBCT technique at several different areas of the skull.

Most of the anatomical sites selected for this project are outside of the dentomaxillofacial area because it was expected that this would be a better test of the capability of the CBCT scanner for accuracy throughout the skull. In fact, between the anatomical sites of the facial area analysed (1 and 2, Table 1) the measurements of the CBCT's images were statistically similar to the real measurements. The results showed that the real distances measured on dry skulls were always larger than those obtained from the CBCT images. However, these differences were only significant for measurements taken between structures at the skull base and not for other dentomaxillofacial structures.

Since the 1980s, great advances in available resources for dental radiology have occurred as represented by new equipment and adaptation of tomographic software previously used in medicine. The introduction of CT into the field of dentistry was such an advance, but it also presented with some limitations such as, degradation of the image quality due to artefacts from metallic dental restorations, extended examination time, and the incapacity of CT to reproduce thin image sections.<sup>9,10</sup>

Tomographic equipment improvements occurred simultaneously with the increased utilization of dental implant techniques, leading to the development of software specific for jaw analysis.<sup>10-12</sup> Tested accuracy of this equipment has prompted some authors to suggest that newer more reliable equipment is needed.<sup>13,14</sup>

Recently, a different form of volumetric CT was introduced, which uses the cone-beam technique instead of traditional fan-beam technique. Hashimoto *et al*<sup>6</sup> when comparing a CBCT unit (3DX Multi Image Micro CT) with the newest multidetector CT (Aquilion Multi-Slice CT), showed the superiority of the 3DX in the display of hard tissues associated with the dental region made with a substantially decreased radiation dose to the patient.

Currently, several commercial systems for CBCT dedicated to dentomaxillofacial imaging are available for dental diagnosis and treatment planning.<sup>7</sup> Besides the NewTom 9000<sup>1-4</sup> there are others such as MercurRay from Hitachi, Tokyo, Japan and Accutomo 3DX by Morita Co., Tokyo, Japan,<sup>6</sup> and I-CAT<sup>TM</sup> Imaging Sciences International, Hatfield, PA.<sup>7</sup>

The comparison between the real measurements and those taken from the CBCT digital images were mostly similar. At the internal sites of the skull base the digital images presented measurements significantly smaller than those of real distances. These results were expected because the NewTom 9000 was specifically designed for the regions of dental interest where the skull base is not included. Taken together, our results in accuracy of measurements and the low radiation doses from this technique reported by others<sup>1-7</sup> makes the CBCT technique very useful for dental applications.

Based on our results it is possible to conclude that the CBCT technique is reliable for being applied at different clinical situations where the linear measurements between anatomical sites are required, such as pre-operative assessment for dental implant and orthognathic surgeries, because the measurements made from the CBCT images are similar, although slightly smaller, than those of real or *in vivo* distances between skull sites, except for structures located at the skull base.

## Conclusion

The conclusion of this study is that, although the CBCT image underestimates the real distances between skull sites, differences are only significant for the skull base and therefore it is reliable for linear evaluation measurements of other structures more closely associated with dental and maxillofacial imaging.

**Acknowledgments**

We thank the “Associação Paulista de Cirurgiões-Dentistas (APCD)” for kindly allowing us to access the CBCT-NewTom equipment. We also thank Dr Miriam Turbino for the statistical

analysis of our data and to Dr Marcelo Cavalcanti for the critical review of the manuscript. We also thank the financial support from “Fundação de Amparo à Pesquisa do Estado de São Paulo (FAPESP)”, Brazil.

**References**

1. Mozzo P, Procacci C, Tacconi A, Martini PT, Andreis IA. A new volumetric CT machine for dental imaging based on the cone-beam technique: preliminary results. *Eur Radiol* 1998; **8**: 1558–1564.
2. Ludlow JB, Davies-Ludlow LE, Brooks SL. Dosimetry of two extraoral direct digital imaging devices: NewTom cone beam CT and Orthophos Plus DS panoramic unit. *Dentomaxillofac Radiol* 2003; **32**: 229–243.
3. Mah JK, Danforth RA, Bumann A, Hatcher D. Radiation absorbed in maxillofacial imaging with a new dental computed tomography device. *Oral Surg Oral Med Oral Pathol Oral Radiol Endod* 2003; **96**: 508–513.
4. Bianchi S, Anglesio S, Castellano S, Rizzi L, Ragona R. Absorbed doses and risk in implant planning: comparison between spiral CT and cone-beam CT. *Dentomaxillofac Radiol* 2003; **30**(1: 16.6):S28.
5. Ziegler CM, Woertcher R, Brief J, Hassfeld S. Clinical indications for digital volume tomography in oral and maxillofacial surgery. *Dentomaxillofac Radiol* 2002; **31**: 126–130.
6. Hashimoto K, Arai Y, Iwai K, Araki M, Kawashima S, Terakado M. A comparison of a new limited cone beam computed tomography machine for dental use with a multidetector row helical CT machine. *Oral Surg Oral Med Oral Pathol Oral Radiol Endod* 2003; **95**: 371–377.
7. Sukovic P. Cone beam computed tomography in craniofacial imaging. *Orthod Craniofac Res* 2003; **6** Suppl 1: 31–36.
8. Cho PS, Johnson RH, Griffin TW. Cone-beam CT for radiotherapy applications. *Phys Med Biol* 1995; **40**: 1863–1883.
9. Misch CE. Density of bone: effect on treatment plans, surgical approach, healing, and progressive bone loading. *Int J Oral Implantol* 1990; **6**: 23–31.
10. Schwarz MS, Rothman SL, Rhodes ML, Chafetz N. Computed tomography: Part I. Preoperative assessment of the mandible for endosseous implant surgery. *Int J Oral Maxillofac Implants* 1987; **2**: 137–141.
11. Curry TS, Dowdey JF, Murry Jr RC. *Chistensen's introduction to the physics of diagnostic radiology* (3rd edn). Philadelphia: Lea & Febiger, 1984, pp 234–261.
12. Vannier MW, Hildebolt CF, Conover G, Knapp RH, Yokoyama-Crothers N, Wang G. Three-dimensional dental imaging by spiral CT. A progress report. *Oral Surg Oral Med Oral Pathol Oral Radiol Endod* 1997; **84**: 561–570.
13. Cavalcanti MGP, Vannier MW. Quantitative analysis of spiral computed tomography for craniofacial clinical applications. *Dentomaxillofac Radiol* 1998; **27**: 344–350.
14. Kim DO, Kim HJ, Jung H, Jeong HK, Hong SI, Kim KD. Quantitative evaluation of acquisition parameters in three-dimensional imaging with multidetector computed tomography using human skull phantom. *J Digit Imaging* 2002; **15** Suppl 1: 254–257.