

Anatomic symmetry of root and root canal morphology of posterior teeth in Indian subpopulation using cone beam computed tomography: A retrospective study

Gnanasekaran Felsypremila¹, Thilla Sekar Vinothkumar², Deivanayagam Kandaswamy¹

Correspondence: Dr. Gnanasekaran Felsypremila
Email: pramisandy@gmail.com

¹Department of Conservative Dentistry and Endodontics, Faculty of Dental Sciences, Sri Ramachandra University, Tamil Nadu, India,
²Department of Restorative Dental Sciences, College of Dentistry, Jazan University, Jazan, Kingdom of Saudi Arabia

ABSTRACT

Objective: To investigate the anatomic symmetry of maxillary and mandibular posteriors in Indian subpopulation using cone beam computed tomography (CBCT). **Materials and Methods:** CBCT images of 246 patients that had at least one noncarious, posterior tooth free of restorations in each quadrant were enrolled for retrospective analysis. A total of 3015 teeth (811 maxillary premolars, 845 mandibular premolars, 738 maxillary molars, and 621 mandibular molars) were analyzed for number of roots and root canals, canal morphology and anatomic symmetry, and concurrent types between the maxilla and mandible. **Results:** There was no difference in the percentage of symmetry for maxillary first (81.5%) and second (81.5%) premolars. Mandibular second premolars (98.3%) exhibited greater symmetry than mandibular first premolars (96.1%). First molars (77.5% and 82.1%) showed greater symmetry than second molars (70.8% and 78.6%), in both maxillary and mandibular arches, respectively. The most common anatomy observed were: maxillary first premolars – 2 roots with 2 canals, maxillary second premolars – 1 root with 2 canals, mandibular first and second premolars – 1 root with 1 canal, maxillary first and second molars – 3 roots with 4 canals, and mandibular first and second molars – 2 roots with 3 canals. When compared with any other teeth, maximum asymmetry was observed in maxillary second molar (29.2%). **Conclusion:** The percentage of symmetry observed in the present study varied from 70% to 98% with least percentage of symmetry in maxillary second molars. These data should alert the clinicians while treating homonymous teeth of the same patient.

Key words: Anatomic symmetry, cone beam computed tomography, C-shaped canal, posterior teeth, radix entomolaris, radix paramolaris, root canal morphology

INTRODUCTION

A thorough knowledge of the root and the root canal morphology of all existing canals plays a significant role in determining the success of endodontic treatment.^[1] Successful treatment of endodontic complications is associated with diagnostic imaging techniques that provide information about the teeth and their surrounding structures.^[2]

Various *in vitro* methods used have been used for evaluating the root canal morphology.^[3] However, *in vivo* methods such as conventional periapical radiographs^[4] and cone beam computed tomography (CBCT) are

valuable diagnostic tools for assessing anatomic symmetry of teeth between the right and left sides in

This is an open access article distributed under the terms of the Creative Commons Attribution-NonCommercial-ShareAlike 3.0 License, which allows others to remix, tweak, and build upon the work non-commercially, as long as the author is credited and the new creations are licensed under the identical terms.

For reprints contact: reprints@medknow.com

How to cite this article: Felsypremila G, Vinothkumar TS, Kandaswamy D. Anatomic symmetry of root and root canal morphology of posterior teeth in Indian subpopulation using cone beam computed tomography: A retrospective study. Eur J Dent 2015;9:500-7.

DOI: 10.4103/1305-7456.172623

the same patient. This can be of high clinical relevance when treating multiple teeth in the same patient.^[3]

Recently, CBCT has been introduced to overcome the limitations of conventional radiographs such as distortion and superimposition of bony and dental structures.^[5] In addition, CBCT has proven useful in evaluating root canal morphology in the maxillary region^[6] and morphologic evaluation in endodontics.^[7] The posterior teeth have a more complex morphological variations, such as abnormal number of roots and root canals,^[8] existence of C-shaped root canals,^[9] radix entomolaris (RE),^[10] and radix paramolaris (RP).^[11]

The aim of the present study was to analyze the CBCT images of maxillary and mandibular posterior teeth in Indian subpopulation and to determine the bilateral symmetry in root and root canal configuration using CBCT.

MATERIALS AND METHODS

CBCT images of 246 patients, who required CBCT investigation, as part of their dental diagnosis and treatment for reasons including preoperative assessment for multiple implants, endodontic management of teeth with unusual root canal morphology, facial trauma, maxillary sinusitis, and orthodontic treatment because of impacted teeth were obtained from imaging center for inclusion in this retrospective study. The patients were selected with the mean age of 43 years (range, 15–70 years) who had at least one noncarious, posterior tooth free of restorations in each quadrant, since the scattering and beam hardening effects produced by CBCT technology can affect the quality of the image.^[12] This study was approved by Institutional Ethics Committee.

CBCT was performed by Kodak 9500 cone beam 3D (Carestream Health Inc., Rochester, NY) equipment with the following technical parameters: Field of view 18 cm × 20 cm, effective exposure time of 10.8 s (pulsated), tube voltage 60–90 kV, 2–15 mA (pulsated mode) with an estimated radiation dosage of 30–80 μ Sv and slice thickness of 0.2 mm.

CBCT images were analyzed using 3D module version 2.4 Kodak Dental Imaging software (Carestream Health Inc., Rochester, NY) on a 17-inch Samsung light emitting diode screen (Seoul, Korea) with a resolution of 1280 × 1024 pixels. The images obtained were viewed three-dimensionally as well as in the axial, sagittal, and coronal planes. CBCT images in all the three planes were observed for three times to get a

detailed view of the root canal system of the examined teeth. CBCT images were evaluated at the same time by a professional endodontist and oral radiologist, to obtain similar findings. In cases of complex root canal anatomy, where consensus could not be obtained after mutual consultation, a third evaluator (endodontist) was asked to confirm the root canal morphology and internal anatomy.

All the posterior teeth were examined according to the Vertucci's classification for number of roots and their morphology, the number of root canals in each root, configuration of the root canal system, and bilateral symmetry.^[13] Interarch and intra-arch comparison was performed for the bilateral symmetry of posterior teeth using Chi-square test using SPSS software version 16.0 (SPSS Inc. Chicago, IL) at a 0.05 significance level.

RESULTS

External anatomy of roots and number of root canals

In the 418 maxillary first premolars examined, 214 (51.2%) had 2 roots with individual canals and 204 (48.8%) had 1 root. 84.1% ($n = 172$) of the single rooted maxillary first premolar had 2 canals, and the remaining 15.9% ($n = 32$) had 1 canal. In the 393 maxillary second premolars examined, 37 (9.4%) had 2 roots with individual canals and 356 (90.6%) had 1 root. 44.9% ($n = 160$) of the single rooted maxillary second premolar had 2 canals, and the remaining 55.1% ($n = 196$) had 1 canal.

In the 447 mandibular first premolars examined, 9 (2.0%) had 2 roots with individual canals and 438 (98.0%) had 1 root. 5.4% ($n = 24$) of the single-rooted mandibular first premolar had 2 canals and the remaining 94.6% ($n = 414$) had 1 canal. In the 398 mandibular second premolars examined, 397 (99.7%) were found to have single root with single canal and remaining 1 (0.3%) had two canals.

In the 367 maxillary first molars [Figure 1] examined, 2 (0.5%) had 4 separate roots (mesiobuccal [MB], distobuccal [DB], mesiopalatal [MP], and distopalatal [DP]) with individual canals, 355 (96.8%) teeth had 3 separate roots; whereas 263 (74.1%) of the MB roots had second canal (MB2) and the other 92 (25.9%) MB roots had 1 canal. Of the 3 rooted teeth with MB2 ($n = 263$), 1 (0.4%) had 2 canals in palatal (P) root. The remaining 10 (2.7%) teeth had 2 roots; 1 (10%) had 5 canals (3 in buccal (B) and 2 in P), 2 (20%) had 4 canals, 6 (60%) had 3 canals, and 1 (10%) had 2 canals (C-shaped in the B root).

In the 371 maxillary second molars [Figure 2] examined, 4 (1.1%) had 4 separate roots (MB, DB, MP, and DP);

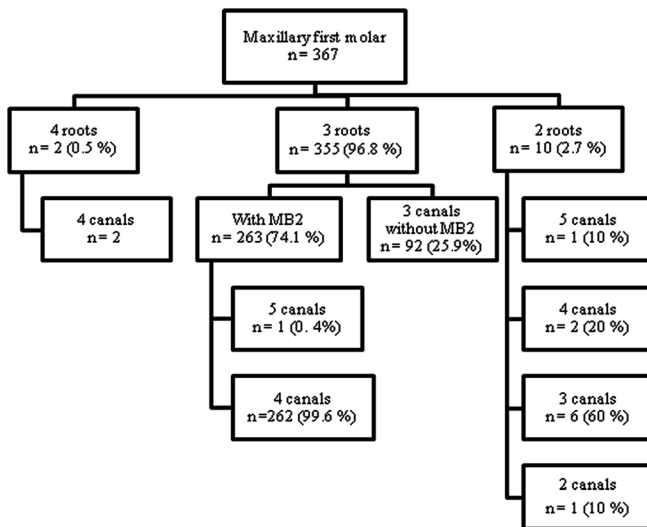


Figure 1: Distribution of roots and root canals observed in maxillary first molars

1 (25%) had MB2 and 3 (75%) had individual canals in the MB root. Two hundred and ninety-eight (80.3%) teeth had 3 separate roots; whereas 179 (60.1%) of the MB roots had 2 canals (MB1 and MB2) and other 119 (39.9%) MB roots had 1 canal. Of the 3 rooted teeth with MB2 ($n = 179$), 1 (0.6%) had 2 canals in P root. 33 (8.9%) teeth had 2 roots; 5 (15.2%) had 4 canals (1 had 3 in B and 1 in P, 4 had 2 in B and 2 in P), 19 (57.6%) had 3 canals (2 B and 1 in P), 9 (27.3%) had 2 canals. The remaining 36 (9.7%) teeth had 1 root; 1 (2.7%) had 4 canals, 6 (16.7%) had 3 canals, 18 (50%) had 2 canals, 9 (25%) had single canal, and 2 (5.6%) had C-shaped canal configuration. The overall frequency of C-shaped canal in maxillary second molar was 0.5%.

In the 299 mandibular first molars [Figure 3] examined, 17 (5.7%) had 3 separate roots, 280 (93.6%) had 2 roots, and 2 (0.7%) had 1 root. When 3 separate roots were present 15 (88.2%) teeth had RE; 1 (6.7%) had 5 canals (2 mesial [M], 1 DB and 2 distolingual [DL]) and 14 (93.3%) had 4 canals (2 M, 1 DB, and 1 DL). The remaining 2 (11.8%) out of 17 teeth had RP with 3 individual canals. When 2 roots were present, 6 (2.1%) had 5 canals (3 in M and 2 in distal [D]), 73 (26.1%) had 4 canals; 5 (6.8%) had 3 canals in the M root (MB, middle mesial [MM], and mesiolingual) and 1 canal in the D root, 68 (93.2%) had 2 canals in each root, 198 (70.7%) teeth had 3 canals (2 in the M root and 1 in the D root), and 3 (1.1%) teeth had 2 canals. The remaining 2 (0.7%) teeth had 1 root with C-shaped canal configuration. In the 297 teeth with more than 1 root, 11 (3.7%) had MM canal. The overall frequency of RE, RP, and C-shaped canal in mandibular first molar was 5%, 0.7%, and 0.7%, respectively.

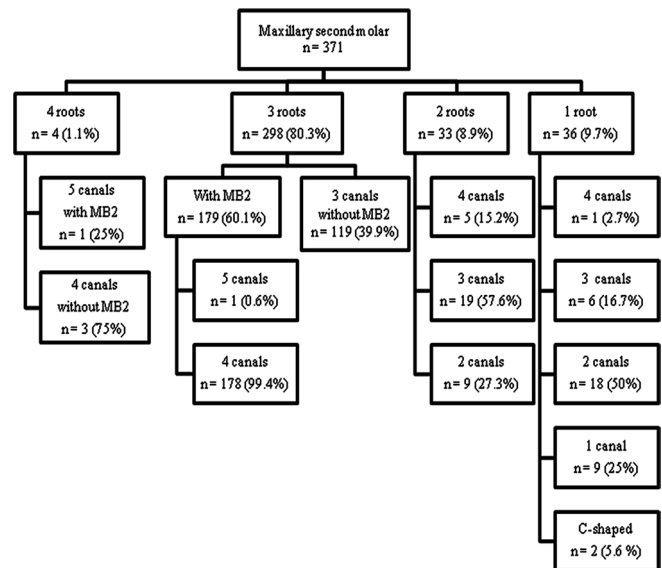


Figure 2: Distribution of roots and root canals observed in maxillary second molars

In the 322 mandibular second molars [Figure 4] examined, 8 (2.5%) had 3 separate roots, 286 (88.8%) had 2 roots, and the remaining 28 (8.7%) had 1 root. When 3 separate roots were present, 3 (37.5%) had RE, and the remaining 5 (62.5%) had RP with 3 individual canals. When 2 roots were present, 1 (0.3%) had 5 canals (3 in M and 2 in D), 14 (4.9%) had 4 canals; 5 (35.7%) had 3 canals in the M root and 1 canal in the D root, 9 (64.3%) had 2 canals in each root, 251 (87.8%) had 3 canals (2 in the M root and 1 in the D root), 20 (7%) had 2 canals. When 1 root were present, 1 (3.6%) had 3 canals, 1 (3.6%) had 2 canals, and the remaining 26 (92.8%) had C-shaped canal configuration. In the 294 teeth with more than 1 root, 3 (1%) had MM canal. The overall frequency of RE, RP, and C-shaped canal in mandibular second molar was 0.9%, 1.5%, and 8.1%, respectively.

Internal anatomy of root canals

In the maxillary first premolars examined, when 1 root was present, the root canal configuration was type I (15.9%), type II (26.1%), and type IV (58%). In the maxillary second premolar, when 1 root was present, the root canal configuration was type I (55.1%), type II (25.2%), type III (1.9%), type IV (15%), type V (1.9%), and type VI (0.9%). In the mandibular first premolar, when 1 root was present, the root canal configuration was type I (94%), type II (1.3%), type IV (2.7%), type V (1.3%), and C-shaped (0.7%). In the mandibular second premolar, when 1 root was present, the root canal configuration was type I (98.4%), type V (0.8%), and C-shaped (0.8%).

In the maxillary first molar, when MB2 was present the canal configuration of the M root was type II (60%),

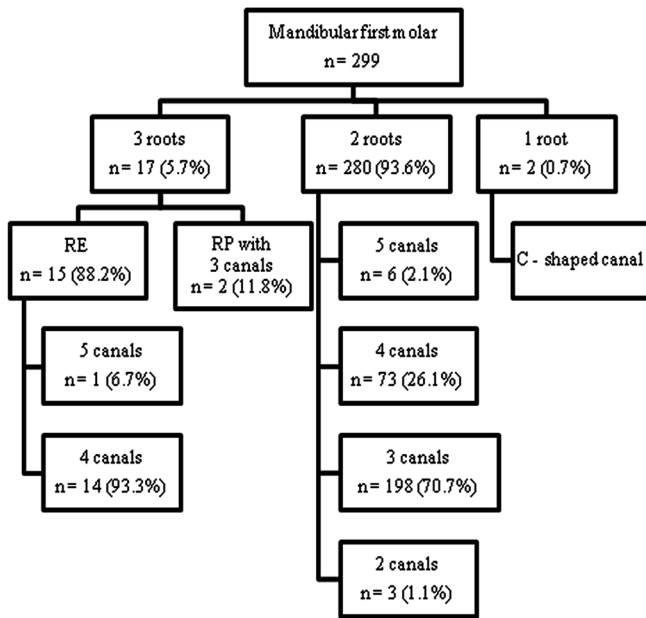


Figure 3: Distribution of roots and root canals observed in mandibular first molars

type III (1%), and type IV (39%). One of these teeth exhibiting MB2 had type IV configuration in the P root. When 2 roots with 5 canals were present, the canal configuration of B root was type VIII and P root was type IV, whereas when 2 roots with 4 canals were present, the canal configuration was 50% type VIII in the B root and 50% type IV in both B and P roots. When 2 roots with 3 canals were present, all the teeth had type IV canal configuration in the P root. When 2 roots with 2 canals were present, the canal configuration of the B root was C-shaped.

In the maxillary second molar, when MB2 was present the canal configuration of the M root was type II (67.3%), type IV (31.1%), and type V (1.6%). Two of these teeth showing MB2 had type IV canal configuration (3 roots with 5 canals) in the P root. When 2 roots with 4 canals were present, the canal configuration was 20% type VIII in the B root and 80% type IV in both the B and the P roots. When 2 roots with 3 canals were present the canal configuration of the B root was type IV. In single rooted teeth 16.7% had type VIII, 50% had type IV, 25% had type I, 5.6% had C-shaped canal configuration, and the remaining 2.7% had 4 separate canals that extend from the pulp chamber to the apex with distinct apical foramen (1 root with 4 canals).

In the mandibular first molar, when 3 roots with 5 canals were present, type IV canal configuration was seen in the M and DL roots. When 3 roots with 4 canals were present, the canal configuration of the

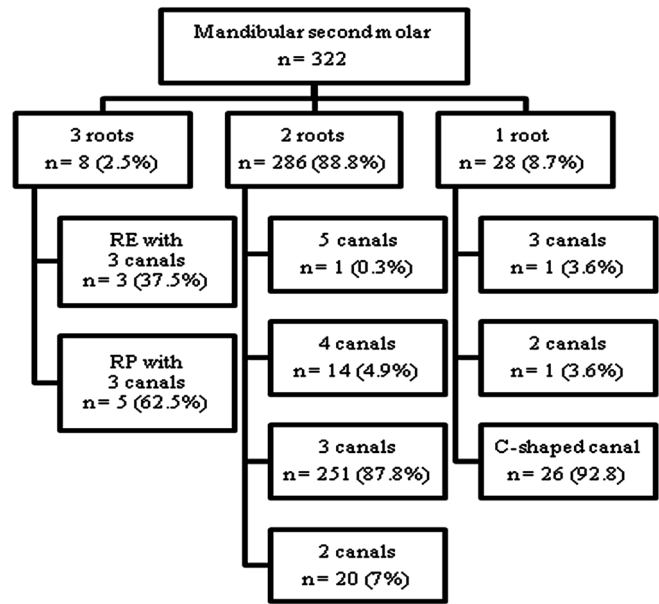


Figure 4: Distribution of roots and root canals observed in mandibular second molars

M root was type IV. When 2 roots with 5 canals were present, the canal configuration of the M root was type VIII, and the D root was type II. When 2 roots with 4 canals were present 6.8% of the teeth had type VIII in M root and type I in the D root, whereas 93.2% had type IV canal configuration in both M and D roots. When 2 roots with 3 canals were present, the canal configuration in the M root was 28.6% type II, and 71.4% type IV. When 1 root was present, the canal configuration was C-shaped.

In the mandibular second molar, when 2 roots with 5 canals were present, the canal configuration of the M root was type VIII, and the D root was type II. When 2 roots with 4 canals were present, 35.7% of the teeth had type VIII in the M root and type I in the D root, whereas 64.3% of the teeth had type IV in the M root and type II in the D root. When 2 roots with 3 canals were present, the canal configuration was 43.6% type II in the M root, and 56.4% type IV in the D root. When 1 root was present 3.6% had type VIII, 3.6% had type II, and 92.8% had C-shaped canal configuration.

Bilateral symmetry of posteriors

The analysis of bilateral symmetry for eligible patients with respect to number of roots and root canals was performed in the axial section of CBCT images. Of the 195 and 184 patients who had both of the maxillary first and second premolars, 81.5% (n = 159) and 81.5% (n = 150) showed anatomic symmetry, respectively [Table 1]. With respect to mandibular first and second premolars, 96.1% (n = 197) of 205 patients

and 98.3% ($n = 173$) of 176 patients showed anatomic symmetry, respectively [Table 2]. Of the 160 and 168 patients who had both of the maxillary first and the second molars, 77.5% ($n = 124$) and 70.8% ($n = 119$) showed anatomic symmetry, respectively [Table 3]. With regards to mandibular first and second molars, the symmetry was observed in 78.6% ($n = 103$) of 131 patients and 82.1% ($n = 124$) of 151 patients, respectively [Table 4]. The difference in bilateral symmetry between maxillary and mandibular

posterior teeth was statistically significant ($P < 0.001$; Chi-square test). However, the difference was not significant within the arch between the first and second of premolars and molars ($P > 0.05$; Chi-square test).

Concurrent configuration of premolars

The number of roots and root canals in first premolars [Table 5] and second premolars [Table 6] between the maxillary and mandibular arch were analyzed for the presence of concurrent combinations on both right and left side. Of the 181 and 196 patients, who had both of the right and left first premolars, respectively, 43% ($n = 77$) and 41.3% ($n = 81$) showed 2 roots with 2 canals and 1 root with 1 canal. Of the 164 patients who had both of the right and left second premolars, 50% ($n = 82$) and 47.6% ($n = 78$) showed 1 root with 2 canal and 1 root with 1 canal, respectively.

Table 1: Bilateral comparison of the number of roots and root canals in maxillary first and second premolars

	<i>n</i> (%)
Maxillary first premolar ($n=195$)	
Symmetry	159 (81.5)
2 roots with 2 canals	92 (57.8)
1 root with 2 canals	65 (40.9)
1 root with 1 canal	2 (1.3)
Asymmetry	36 (18.5)
1 root with 2 canals and 2 roots with 2 canals	24 (66.6)
1 root with 1 canal and 1 root with 2 canals	10 (27.8)
1 root with 1 canal and 2 roots with 2 canals	2 (5.6)
Maxillary second premolar ($n=184$)	
Symmetry	150 (81.5)
1 root with 2 canals	77 (51.3)
1 root with 1 canal	61 (40.7)
2 roots with 2 canals	12 (8.0)
Asymmetry	34 (18.5)
1 root with 1 canal and 1 root with 2 canals	26 (76.5)
2 roots with 2 canals and 1 root with 2 canals	7 (20.6)
1 root with 1 canal and 2 roots with 2 canals	1 (2.9)

Table 2: Bilateral comparison of the number of roots and root canals in mandibular first and second premolars

	<i>n</i> (%)
Mandibular first premolar ($n=205$)	
Symmetry	197 (96.1)
1 root with 1 canal	181 (91.9)
1 root with 2 canals	11 (5.6)
2 roots with 2 canals	4 (2.0)
C-shaped	1 (0.5)
Asymmetry	8 (3.9)
1 root with 2 canals and 1 root with 1 canal	5 (62.5)
2 roots with 2 canals and 1 root with 2 canals	1 (12.5)
2 roots with 2 canals and 1 root with 1 canal	1 (12.5)
1 root with 2 canals and C-shaped canal	1 (12.5)
Mandibular second premolar ($n=176$)	
Symmetry	173 (98.3)
1 root with 1 canal	171 (98.8)
1 root with 2 canals	1 (0.6)
C-shaped	1 (0.6)
Asymmetry	3 (1.7)
1 root with 1 canal and 1 root with 2 canals	2 (66.7)
1 root with 1 canal and C-shaped canal	1 (33.3)

DISCUSSION

CBCT has a good diagnostic accuracy in level with the digital operating microscope.^[14] Moreover, for the patients who require three dimensional investigations, CBCT with low radiation dose is preferred over traditional CT examination.^[15]

According to Pecora *et al.*,^[16] an incidence of 2.5% has been reported for maxillary first premolar with more than two canals in a Brazilian population. However, no such canal configuration was observed in our study. Although, aberration in root canal configuration of mandibular premolars like C-shaped canal^[17] and 4 roots with 4 canals^[18] have been previously reported in the literature, the most commonly observed root canal morphology was type I.^[19] A systematic review on permanent mandibular premolars for different ethnicities revealed poor correlation between the Indian population and the C-shaped canals.^[20] Accordingly, the results of our study showed type I canal configuration with the highest incidence rate of 94% in the mandibular I premolar, 98.4% in the mandibular II premolar, and the least incidence rate for C-shaped canal configuration (0.7–0.8%).

Various studies on maxillary molars revealed the incidence of MB2 ranging from 52% to 78% in the first molar and 15.1–58% in the second molar.^[3,21,22] In our present study, the frequency rate of MB2 was 74.1% in the first molar and 60.1% in the second molar. Moreover, one of the single rooted maxillary second molar had 4 canals. These unusual findings clearly demonstrate the effectiveness of CBCT.

Table 3: Bilateral comparison of the number of roots and root canals in maxillary first and second molars

	<i>n</i> (%)
Maxillary first molar (<i>n</i> =160)	
Symmetry	124 (77.5)
3 roots with 4 canals	98 (79.0)
3 roots with 3 canals	24 (19.4)
3 roots with 5 canals	1 (0.8)
2 roots with 3 canals	1 (0.8)
Asymmetry	36 (22.5)
3 roots with 3 canals and 3 roots with 4 canals	26 (72.1)
3 roots with 4 canals and other configurations	7 (19.5)
3 roots with 3 canals and other configurations	3 (7.4)
Maxillary second molar (<i>n</i> =168)	
Symmetry	119 (70.8)
3 roots with 4 canals	62 (52.1)
3 roots with 3 canals	41 (34.5)
1 root with 2 canals	4 (3.3)
2 roots with 2 canals	3 (2.5)
2 roots with 4 canals	2 (1.7)
2 roots with 3 canals	2 (1.7)
1 root with 3 canals	2 (1.7)
1 root with 1 canal	2 (1.7)
3 roots with 5 canals	1 (0.8)
Asymmetry	49 (29.2)
3 roots with 3 canals and 3 roots with 4 canals	26 (53.1)
3 roots with 3 canals and other configurations	8 (16.2)
3 roots with 4 canals and other configurations	5 (10.3)
1 root with 2 canals and other configurations	5 (10.3)
2 roots with 3 canals and other configurations	4 (8.1)
1 root with 3 canals and 1 root with 4 canals	1 (2)

Various literatures have highlighted the presence of MM canals^[23,24] and middle distal canals^[25] in the mandibular molars in different population. The MM canal was present in both mandibular first molars (3.7%) and second molars (0.9%) whereas none of the examined teeth had a middle distal canal.

The frequency of RE in mandibular first molars ranges from 3% to 40% in different populations (Indian 0.2%).^[10] However, it is least common in the mandibular second molars.^[11] In contradiction, the frequency of RP was relatively more in mandibular second molars than that of mandibular first molars.^[11] Similarly, the frequency of RE was more in the mandibular first molars (5%) than that of mandibular second molars (0.9%), whereas the frequency of RP is more in the mandibular second molars (1.5%) than that of the mandibular first molars (0.7%) in our study. In mandibular first molars, one of the teeth with RE had 2 canals in the DL root which has not been reported in the literature.

Table 4: Bilateral comparison of the number of roots and root canals in mandibular first and second molars

	<i>n</i> (%)
Mandibular first molar (<i>n</i> =131)	
Symmetry	103 (78.6)
2 roots with 3 canals	72 (69.9)
2 roots with 4 canals	23 (22.3)
3 roots with 4 canals	5 (4.9)
2 roots with 2 canals	2 (1.9)
3 roots with 3 canals	1 (1)
Asymmetry	28 (21.4)
2 roots with 4 canals and 2 roots with 3 canals	18 (64.2)
2 roots with 5 canals and 2 roots with 4 canals	5 (17.9)
2 roots with 3 canals and 3 roots with 4 canals	3 (10.7)
3 roots with 5 canals and 3 roots with 4 canals	1 (3.6)
2 roots with 2 canals and 2 roots with 3 canals	1 (3.6)
Mandibular second molar (<i>n</i> =151)	
Symmetry	119 (70.8)
2 roots with 3 canals	103 (83.1)
C-shaped canal	8 (6.5)
2 roots with 4 canals	5 (4)
2 roots with 2 canals	5 (4)
1 root with 1 canal	2 (1.6)
3 roots with 3 canals	1 (0.8)
Asymmetry	49 (29.2)
2 roots with 3 canals and other configurations	19 (70.4)
C-shaped canal and other configurations	7 (25.9)
3 roots with 3 canals and 2 roots with 4 canals	1 (3.7)

Significant ethnic variations have been seen in the frequency of C-shaped root canal system in mandibular molars among the Japanese,^[26] Chinese,^[6] and Burmese population.^[9] As far as Indian population is concerned, C-shaped canals are most commonly associated with mandibular second molars.^[24,27] Accordingly, the results of our study showed a maximum incidence for C-shaped (8.1%) canals in mandibular second molars and an unusual incidence of C-shaped canal configuration in the maxillary second molars (0.5%). In addition, one tooth had similar configuration in the buccal root, which is a rare presentation.

When bilateral comparison was performed between the arches and mandibular posteriors (97.1% in premolars and 80.5% in molars) exhibited greater symmetry ($P < 0.001$) than the maxillary posteriors (81.5% in premolars and 74.1% in molars). However, no remarkable variation was observed in the first and the second premolars for both arches. When molars were compared within the arches, the maxillary first molars (77.5%) exhibited greater symmetry than that of the second molars (70.8%), whereas the mandibular second molars (82.1%) showed greater symmetry ($P > 0.05$) than that of the

Table 5: Concurrent types of roots and root canals in first premolars between maxillary and mandibular arches

	n (%)
Right first premolar (14 and 44)	
Concurrent types (n=181)	
2 roots with 2 canals and 1 root with 1 canal	77 (43)
1 root with 2 canals and 1 root with 1 canal	71 (39)
2 roots with 2 canals and 2 roots with 2 canals	4 (2)
1 root with 1 canal and 1 root with 1 canal	14 (7.7)
2 roots with 2 canals and 1 root with 2 canals	14 (7.7)
1 root with 2 canals and C-shaped	1 (0.6)
Left first premolar (24 and 34)	
Concurrent types (n=196)	
2 roots with 2 canals and 1 root with 1 canal	81 (41.3)
1 root with 2 canals and 1 root with 1 canal	74 (37.9)
1 root with 1 canal and 1 root with 1 canal	18 (9.2)
2 roots with 2 canals and 1 root with 2 canals	13 (6.6)
2 roots with 2 canals and 2 roots with 2 canals	4 (2)
1 root with 2 canals and 1 root with 2 canals	4 (2)
1 root with 2 canals and 2 roots with 2 canals	1 (0.5)
2 roots with 2 canals and 1 root with 2 canals	1 (0.5)

Table 6: Concurrent types of roots and root canals in second premolars between maxillary and mandibular arches

	n (%)
Right second premolar (15 and 45)	
Concurrent types (n=164)	
1 root with 2 canals and 1 root with 1 canal	82 (50)
1 root with 1 canal and 1 root with 1 canal	67 (40.9)
2 roots with 2 canals and 1 root with 1 canal	12 (7.3)
2 roots with 2 canals and 1 root with C-shaped	1 (0.6)
1 root with 2 canals and 1 root with 2 canals	2 (1.2)
Left second premolar (25 and 35)	
Concurrent types (n=164)	
1 root with 2 canals and 1 root with 1 canal	78 (47.6)
1 root with 1 canal and 1 root with 1 canal	67 (40.9)
2 roots with 2 canals and 1 root with 1 canal	15 (9.1)
1 root with 2 canals and 1 root with 2 canals	2 (1.2)
2 roots with 2 canals and 1 root with C-shaped	1 (0.6)
1 root with 1 canal and 1 root with 2 canals	1 (0.6)

first molars (78.6%). The percentage of symmetry for maxillary molars in White and Chinese population was found to be 75.8% and 84%, respectively.^[3,6] However, a lesser percentage of symmetry (74.1%) was observed in our population. In contrast, this ethnic variation was reversed for maxillary first premolars with a greater percentage of symmetry (81.5%) in our population than that of the Chinese population (64%).^[27]

Bilateral symmetry was frequently encountered in maxillary first and second premolars when 2 roots with 2 canals (57.8%) and 1 root with 2 canals (51.3%)

were present, respectively. The most common type of symmetry in mandibular first and second premolars was 1 root with 1 canal (91.9% and 98.8%, respectively). High frequency of symmetry was observed in 3 roots with 4 canals in both first (79%) and second (52.1%) maxillary molars. Similarly, 2 roots with 3 canals showed the maximum percentage (83.1% and 69.9%) of symmetry in mandibular first and second molars, respectively which is very commonly seen in Indian population.^[24]

In comparison with any other teeth, maximum percentage of asymmetry was observed in maxillary second molar (29.2%). When 3 roots with 3 canals were present on one side and 3 roots with 4 canals were present on the other side, higher frequency of asymmetry was observed in maxillary first molars (72.1%) and second molars (53.2%). This type of asymmetry could be attributed to the variation in the complex anatomy of the MB root.^[3] In mandibular first molars, maximum asymmetry (64.2%) was seen in 2 roots with 3 canals and 2 roots with 4 canals. Maximum concurrent anatomy was found to be 2 roots with 2 canals, and 1 root with 2 canals in first and second maxillary premolars, respectively when the patients had 1 root with 1 canal in the mandibular premolars. These data are of great clinical importance in locating, negotiating, and managing the entire root canal system while treating multiple teeth in the same patient.

CONCLUSION

The overall average percentage of symmetry observed in our study was 83.9% ranging from 70% to 98% depending upon the tooth considered. In almost 30% of the CBCT images analyzed, the root canal configurations of the homonymous teeth are not alike especially for the maxillary second molar which is a technical challenge for the clinician.

Financial support and sponsorship
Nil.

Conflicts of interest

There are no conflicts of interest.

REFERENCES

1. Cleghorn BM, Christie WH, Dong CC. The root and root canal morphology of the human mandibular first premolar: A literature review. *J Endod* 2007;33:509-16.
2. Liang YH, Yuan M, Li G, Shemesh H, Wesselink PR, Wu MK. The ability of cone-beam computed tomography to detect simulated buccal and lingual recesses in root canals. *Int Endod J* 2012;45:724-9.

3. Plotino G, Tocci L, Grande NM, Testarelli L, Messineo D, Ciotti M, *et al.* Symmetry of root and root canal morphology of maxillary and mandibular molars in a white population: A cone-beam computed tomography study *in vivo*. J Endod 2013;39:1545-8.
4. Yew SC, Chan K. A retrospective study of endodontically treated mandibular first molars in a Chinese population. J Endod 1993;19:471-3.
5. Cotton TP, Geisler TM, Holden DT, Schwartz SA, Schindler WG. Endodontic applications of cone-beam volumetric tomography. J Endod 2007;33:1121-32.
6. Zhang R, Yang H, Yu X, Wang H, Hu T, Dummer PM. Use of CBCT to identify the morphology of maxillary permanent molar teeth in a Chinese subpopulation. Int Endod J 2011;44:162-9.
7. Matherne RP, Angelopoulos C, Kulild JC, Tira D. Use of cone-beam computed tomography to identify root canal systems *in vitro*. J Endod 2008;34:87-9.
8. Alaçam T, Tinaz AC, Genç O, Kayaoglu G. Second mesiobuccal canal detection in maxillary first molars using microscopy and ultrasonics. Aust Endod J 2008;34:106-9.
9. Gulabivala K, Aung TH, Alavi A, Ng YL. Root and canal morphology of Burmese mandibular molars. Int Endod J 2001;34:359-70.
10. De Moor RJ, Deroose CA, Calberson FL. The radix entomolaris in mandibular first molars: An endodontic challenge. Int Endod J 2004;37:789-99.
11. Calberson FL, De Moor RJ, Deroose CA. The radix entomolaris and paramolaris: Clinical approach in endodontics. J Endod 2007;33:58-63.
12. Patel S. New dimensions in endodontic imaging: Part 2. Cone beam computed tomography. Int Endod J 2009;42:463-75.
13. Vertucci FJ. Root canal anatomy of the human permanent teeth. Oral Surg Oral Med Oral Pathol 1984;58:589-99.
14. de Toubes KM, Côrtes MI, Valadares MA, Fonseca LC, Nunes E, Silveira FF. Comparative analysis of accessory mesial canal identification in mandibular first molars by using four different diagnostic methods. J Endod 2012;38:436-41.
15. Scarfe WC, Farman AG, Sukovic P. Clinical applications of cone-beam computed tomography in dental practice. J Can Dent Assoc 2006;72:75-80.
16. Pécora JD, Saquy PC, Sousa Neto MD, Woelfel JB. Root form and canal anatomy of maxillary first premolars. Braz Dent J 1992;2:87-94.
17. Velmurugan N, Sandhya R. Root canal morphology of mandibular first premolars in an Indian population: A laboratory study. Int Endod J 2009;42:54-8.
18. Sachdeva GS, Ballal S, Gopikrishna V, Kandaswamy D. Endodontic management of a mandibular second premolar with four roots and four root canals with the aid of spiral computed tomography: A case report. J Endod 2008;34:104-7.
19. Awawdeh LA, Al-Qudah AA. Root form and canal morphology of mandibular premolars in a Jordanian population. Int Endod J 2008;41:240-8.
20. Kottoor J, Albuquerque D, Velmurugan N, Kuruvilla J. Root anatomy and root canal configuration of human permanent mandibular premolars: A systematic review. Anat Res Int 2013;2013:254250.
21. al Shalabi RM, Omer OE, Glennon J, Jennings M, Claffey NM. Root canal anatomy of maxillary first and second permanent molars. Int Endod J 2000;33:405-14.
22. Yoshioka T, Kikuchi I, Fukumoto Y, Kobayashi C, Suda H. Detection of the second mesiobuccal canal in mesiobuccal roots of maxillary molar teeth *ex vivo*. Int Endod J 2005;38:124-8.
23. Holtzmann L. Root canal treatment of a mandibular first molar with three mesial root canals. Int Endod J 1997;30:422-3.
24. Neelakantan P, Subbarao C, Subbarao CV, Ravindranath M. Root and canal morphology of mandibular second molars in an Indian population. J Endod 2010;36:1319-22.
25. Cantatore G, Berutti E, Castelluci A. Missed anatomy: Frequency and clinical impact. Endod Topics 2006;15:3-31.
26. Cleghorn BM, Goodacre CJ, Christie WH. Morphology of teeth and their root canal system. In: Ingle JL, Backland LK, Baumgartner JC, editors. Endodontics. 6th ed. Hamilton, ON: BC Decker Inc.; 2008. p. 151-210.
27. Tian YY, Guo B, Zhang R, Yu X, Wang H, Hu T, *et al.* Root and canal morphology of maxillary first premolars in a Chinese subpopulation evaluated using cone-beam computed tomography. Int Endod J 2012;45:996-1003.

Access this article online

Quick Response Code:



Website:
www.eurjdent.com