

Electronic Thesis and Dissertation Repository

3-21-2018 4:00 PM

Anatomy of the Infrarenal Aortic Plexus: Implications for Nerve-Sparing Retroperitoneal Lymph Node Dissection

Tyler Beveridge, *The University of Western Ontario*

Supervisor: Allman, Brian L, *The University of Western Ontario*

Co-Supervisor: Power, Nicholas E, *The University of Western Ontario*

A thesis submitted in partial fulfillment of the requirements for the Doctor of Philosophy degree in Anatomy and Cell Biology

© Tyler Beveridge 2018

Follow this and additional works at: <https://ir.lib.uwo.ca/etd>

Recommended Citation

Beveridge, Tyler, "Anatomy of the Infrarenal Aortic Plexus: Implications for Nerve-Sparing Retroperitoneal Lymph Node Dissection" (2018). *Electronic Thesis and Dissertation Repository*. 5260.
<https://ir.lib.uwo.ca/etd/5260>

This Dissertation/Thesis is brought to you for free and open access by Scholarship@Western. It has been accepted for inclusion in Electronic Thesis and Dissertation Repository by an authorized administrator of Scholarship@Western. For more information, please contact wlsadmin@uwo.ca.

ABSTRACT

Nerve-sparing is a well-established technique to preserve ejaculation in men undergoing retroperitoneal lymph node dissections (RPLND) for testis cancer. In the post-chemotherapy setting, surgeons are faced with extensive disease, distorted anatomy, and increasingly complicated resections. As such, reports indicate that despite attempts to nerve-spare, 21-24% of patients still experience post-operative ejaculatory dysfunction. Worse yet, many institutions still do not attempt to nerve-spare, reporting ejaculatory dysfunction in 75-100% of patients. Although nerve-sparing may not always be indicated, experts conservatively estimate it is achievable in >50% of patients with advanced-stage disease in the post-chemotherapy setting.

We contend that a poor understanding of the retroperitoneal sympathetic nerves has limited the efficacy, refinement and implementation of precise nerve-sparing practices during RPLND. Ultimately, success in nerve-sparing requires comfort with the normal neurovascular anatomy of the retroperitoneum; however, this is difficult to achieve because the relevant sympathetic networks (i.e., the aortic plexus) have not been comprehensively described and are often illustrated inconsistently. Therefore, the goal of the present thesis is to provide the first comprehensive characterization of the aortic plexus as it pertains to nerve-sparing RPLND.

This was achieved through three specific aims: *(i)* to determine the organization of the aortic plexus by characterizing the anatomy of the constituent nerves and ganglia (Chapters 2 & 3), *(ii)* to describe the surgically-relevant variations of the lumbar splanchnic nerves adjoining the aortic plexus (Chapter 4), and *(iii)* to examine the neurovascular relationship between the sympathetic nerves of the aortic plexus and the lumbar vessels as it relates to RPLND (Chapter 5).

Through dissection of human cadavers, the infrarenal aortic plexus was organized into two longitudinal cords, each containing two constituent ganglia. Two (range 1-4) lumbar splanchnic nerves (LSN), typically coursing anteromedial to the lumbar veins, join each cord. Despite varying in their position, 98% of LSNs originate from the lumbar sympathetic chains superior to the inferior mesenteric artery. In 85% of individuals,

retroaortic LSNs coursed between the common iliac vessels to join the superior hypogastric plexus. Future studies should seek to determine the specific portions of the aortic plexus imperative to preserving ejaculation.

Keywords

Superior Hypogastric Plexus, Lumbar Splanchnic Nerve, Sympathetic Nervous System, Adrenergic, Neurons, Ganglion, Spermatic Ganglia, Prehypogastric Ganglion, Inferior Mesenteric Ganglion, Human, Testis Cancer, RPLND, Ejaculation, Anejaculation, Retrograde Ejaculation, Male Sexual Function, Ejaculatory Dysfunction.

CO-AUTHORSHIP STATEMENT

This thesis contains materials from published manuscripts (Chapters 2, 3, 4, & 5). The first author on all manuscripts was Tyler S. Beveridge; Chapter 4 was co-first authored with Dale E. Fournier in acknowledging his significant contributions to the dissections, measurements and analyses as an undergraduate volunteer in our lab.

Chapter 2 was co-authored by Dr. Marjorie Johnson, Dr. Adam Power, Dr. Nicholas E. Power (co-senior author), and Dr. Brian L. Allman (co-senior author).

Chapter 3 was co-authored by Dr. Marjorie Johnson, Dr. Nicholas E. Power (co-senior author), and Dr. Brian L. Allman (co-senior author).

Chapter 4 was co-authored by Dale E. Fournier (co-first author), Adam M.R. Groh, Dr. Marjorie Johnson, Dr. Nicholas E. Power, and Dr. Brian L. Allman (senior author).

Chapter 5 was co-authored by Dr. Brian L. Allman, Dr. Marjorie Johnson, Dr. Adam Power, Dr. Joel Sheinfeld, and Dr. Nicholas Power (senior author).

Tyler S. Beveridge was responsible for: conceiving the studies presented in Chapters 3 & 4, and Appendix D. He was additionally responsible for collecting the data, interpreting the data, writing the manuscripts, and illustrating the figures in all chapters.

ACKNOWLEDGMENTS

Firstly, a special acknowledgment to my primary supervisors, Drs. Brian Allman & Nicholas Power (Co-Primary Supervisors), for their unwavering mentorship:

Nick, I fondly recall our first correspondence over email. You briefly suggested we perform “an anatomic definition of the nerves of anterograde ejaculation”. I continue to be surprised by how such a seemingly simple suggestion has amounted to more than half a decade of work, several extra-departmental/institutional collaborations, and multiple publications; and still, we continue to work toward answering this important question. I am immensely proud of the work we have accomplished together, and am excited to see the future studies take shape. Thank you for your continued advocacy and investment – your excitement and passion for our research and your practice continues to be an inspiration.

Brian, thank you for the considerable amount of time you have invested with me over the past 5+ years. During this time, you have fundamentally changed the way I approach education and research, and I am continually motivated by your cleverness and reflective nature to problems. Most importantly, you have shown me that a good scientist is not only one who excels in their field, but one who has the skills to make any project better – irrespective of the discipline. You have undoubtedly improved the quality of our work beyond any expectation, and I am truly grateful for that.

A special thank you to my supervisory committee: Dr. Katherine Willmore (Advisor), and Dr. Timothy Wilson (Advisor) for their continued support, guidance and encouragement throughout my PhD. Finally, Dr. Marjorie Johnson (Graduate Affairs Committee Member); thank you for being such an extraordinary mentor and friend.

Adam Groh, thank you for being such a wonderful colleague and friend. Your investment to our work as an undergraduate student was beyond expectation, but greatly appreciated. I am continually impressed by your prowess in research and am thankful for the considerable amount of thought and involvement you continue to dedicate to our work.

Linda Jackson, I am forever grateful of your altruism. You have always had an open-door policy with me and have been pivotal in my development as a histologist. Thank you for all the time and resources you have given me over the years.

Special thank you to Dale Fournier and Christopher Balestrini, for their voluntary help with the cadaveric dissections and data collection over the past years. I also wish to thank Colin Moore and Dr. Charles Rice for loaning their equipment for us to use, as well as for providing their continued expertise and feedback to the project. Lee-Anne Fochesato, thank you for your administrative help and expertise in the ethics review process for our research. I would also like to acknowledge Western University, and CIHR for their financial support of my studies.

Thank you to Haley Linklater and Kevin Walker, the supervisors of the HAASE Anatomy Lab at Western University, for their help obtaining the cadaveric specimens, and providing me a suitable and safe environment to work, no matter how unusual the request. Your support and advocacy for our research does not go unnoticed.

I am grateful to the donors and their families; their selfless contribution to anatomical research and the body bequeathal program at Western University has single-handedly enabled this important work. Your generosity will not be forgotten and I will fondly remember my experiences with you.

Thank you to my fellow graduate students, faculty, and staff, past and present, in the Department of Anatomy and Cell Biology, for supporting me, and offering feedback, expertise and friendship throughout this endeavour. You have all uniquely contributed to making every day of my graduate studies enjoyable.

Finally, thank you to my wife, parents, and friends for supporting me in life, encouraging me to follow my interests, and helping me to keep up a good work-life balance. Without you all, I would not have considered research, nor a career in academia.

TABLE OF CONTENTS

Abstract	iii
Co-Authorship Statement.....	v
Acknowledgments.....	vi
Table of Contents	viii
List of Tables	xiii
List of Figures.....	xiv
List of Appendices	xvi
List of Acronyms	xvii
Preface.....	xviii
Chapter 1 The Peripheral Neuroanatomy of Ejaculation: A Review	1
1.1 General Introduction	1
1.1.1. Neurophysiology of Ejaculation	1
1.1.1.1. The Spinal Ejaculation Generator	2
1.1.1.2. Supraspinal Modulation of Ejaculation	4
1.1.1.3. Neurophysiology of Phase I – Seminal Emission	4
1.1.1.4. Neurophysiology of Phase II - Expulsion	5
1.1.1.5. Peripheral Neuroanatomy of Ejaculation	6
1.1.2. Ejaculatory Dysfunction	14
1.1.2.1. Retrograde Ejaculation & Neurogenic Anejaculation	14
1.1.3. Preventing Iatrogenic Ejaculatory Dysfunction after Retroperitoneal Surgery	15
1.1.3.1. Evolution of Nerve-sparing RPLND for Testis Cancer	16
1.2 Overview of Thesis	18

1.2.1. Study 1	18
1.2.2. Study 2	19
1.2.3. Study 3	19
1.2.4. Study 4	20
1.3 References	21
Chapter 2 Anatomy of the Nerves and Ganglia of the Aortic Plexus in Males.....	33
2.1 Abstract	33
2.2 Introduction	34
2.3 Materials and Methods.....	35
2.3.1. Dissection.....	36
2.3.2. Histology.....	37
2.3.2.1. Haematoxylin-Eosin Staining.....	37
2.3.2.2. Anti-Tyrosine Hydroxylase Staining.....	37
2.4 Results	39
2.4.1. Dissections	42
2.4.1.1. Aortic Plexus – Left Side	42
2.4.1.2. Aortic Plexus – Right Side	44
2.4.2. Histology.....	46
2.5 Discussion	49
2.6 Acknowledgements	54
2.7 Author Contributions	54
2.8 References	55
Chapter 3 Histological Verification of the Prehypogastric and Ovarian Ganglia Confirms a Bilaterally Symmetrical Organization of the Ganglia Comprising the Aortic Plexus in Female Human Cadavers	58
3.1 Abstract	58

3.2 Introduction	59
3.3 Materials and Methods	61
3.4 Results	62
3.4.1. Topography of the Ganglia	62
3.4.2. Histology of the Ganglia	64
3.5 Discussion	69
3.6 Acknowledgements	72
3.7 Author Contributions	72
3.8 References	73
Chapter 4 The Anatomy of the Infrarenal Lumbar Splanchnic Nerves in Human Cadavers: Implications for Retroperitoneal Nerve-sparing Surgery.....	76
4.1 Abstract	76
4.2 Introduction	77
4.3 Materials and Methods	79
4.3.1. Dissection.....	79
4.3.2. Measurement Protocol	80
4.3.3. Data Analyses and Statistics	80
4.4 Results	84
4.5 Discussion	93
4.6 Acknowledgements	96
4.7 Author Contributions	96
4.8 References	97
Chapter 5 Retroperitoneal Lymph Node Dissection: Anatomical and Technical Considerations from a Cadaveric Study.....	100
5.1 Abstract	100
5.2 Introduction	101

5.3 Materials and Methods.....	103
5.4 Results	104
5.4.1. Infrarenal Vascular Relationships.....	104
5.4.2. Sympathetic Nerves and Infrarenal Lumbar Vessels.....	106
5.5 Discussion	108
5.5.1. Paracaval Node Dissection	108
5.5.2. Interaortocaval Node Dissection.....	111
5.5.3. Preaortic Node Dissection.....	112
5.5.4. Para-aortic Node Dissection	112
5.6 Conclusions	115
5.7 Acknowledgments.....	115
5.8 References	116
Chapter 6 General Discussion and Summary	119
6.1 General Discussion.....	119
6.1.1. Anatomical Considerations – Microganglia and Accessory Ganglia	119
6.1.2. Clinical Considerations – Retroaortic Lumbar Splanchnic Nerves	120
6.2 Future Work	122
6.2.1. An Animal Model to Study the Peripheral Control of Ejaculation.....	123
6.3 Overall Summary	127
6.4 References	128
Appendices.....	132
Appendix A. Hematoxylin and eosin staining protocol using standard regressive procedures.....	133
Appendix B. Anti-TH immunohistochemical staining protocol.	134
Appendix C. Photomicrographs of the constituent ganglia from the aortic plexus ..	135
Appendix D. Accessory Right Spermatic Ganglion Case Report.....	140

Abstract.....	140
Introduction.....	140
Methods.....	141
Results.....	142
Discussion.....	145
References.....	147
Appendix E. Research Ethics Board Approval.....	149
Appendix F. Copyright Permissions	154
Curriculum Vitae	164

LIST OF TABLES

Table 1. Ejaculation is spared after partial nerve-sparing during RPLND.....	10
Table 2. Constituent ganglia of the aortic plexus are consistently present.....	67
Table 3. Descriptive statistics of the infrarenal lumbar splanchnic nerves.....	86
Table 4. A minority of men maintain antegrade ejaculation after bilateral RPLND without nerve-sparing.....	121

LIST OF FIGURES

Figure 1. Overview of the spinal ejaculation reflex and its neural components.....	3
Figure 2. Unilateral lesions insufficient to cause ejaculatory dysfunction.	9
Figure 3. Axonal organization of the lumbar sympathetic nerves.	11
Figure 4. The autonomic supply to the pelvic organs.....	13
Figure 5. Anatomy of the aortic plexus.	40
Figure 6. The aortic plexus is bilaterally organized.....	41
Figure 7. Typical left side of the aortic plexus.	43
Figure 8. Typical right side of the aortic plexus.	45
Figure 9. The prehypogastric ganglion.	47
Figure 10. Histology confirms the presence of neurons in the constituent ganglia of the aortic plexus.	48
Figure 11. Tyrosine hydroxylase confirms the adrenergic nature of the ganglia.	51
Figure 12. Homologous ganglia in the female aortic plexus confirms bilateral organization in humans.	60
Figure 13. Representative photo of the aortic plexus.	63
Figure 14. Histology confirms the presence of neurons within the prehypogastric ganglion.....	65
Figure 15. Tyrosine hydroxylase confirms the adrenergic nature of the ganglia.	68
Figure 16. Evolution of nomenclature to accurately describe the lumbar splanchnic nerves.	82

Figure 17. The positions of the lumbar splanchnic nerves are prone to variation and are not bilaterally symmetrical.....	83
Figure 18. The anatomy of the infrarenal lumbar splanchnic nerves in 3D	87
Figure 19. A representative model of the infrarenal lumbar splanchnic nerve anatomy.	88
Figure 20. A representative right retroaortic lumbar splanchnic nerve.	90
Figure 21. Retroaortic lumbar splanchnic nerves join the superior hypogastric plexus below the aortic bifurcation.	91
Figure 22. Lumbar splanchnic nerves joining the infrarenal aortic plexus course in parallel.....	92
Figure 23. Lumbar arteries and veins can be landmarked within three regions of the infrarenal great vessels using structures visible from an anterior approach.	105
Figure 24. Neurovascular relationships relevant to nerve-sparing RPLND.	107
Figure 25. Visualizing the neurovascular anatomy pertinent to a nerve-sparing interaortocaval nodal dissection.....	109
Figure 26. Vessel loops are used to maintain visualization of lumbar splanchnic nerves at their origin.....	110
Figure 27. Visualizing the neurovascular anatomy pertinent to a nerve-sparing para-aortic nodal dissection.....	114
Figure 28. A conservation of anatomy in the aortic plexus exists between boars and humans, from Groh et al. (2018).....	126
Figure 29. Accessory spermatic ganglion associated with the presence of an accessory retrocaval testicular artery.....	144

LIST OF APPENDICES

Appendix A. Hematoxylin and eosin staining protocol using standard regressive procedures.	133
Appendix B. Anti-TH immunohistochemical staining protocol.....	134
Appendix C. Photomicrographs of the constituent ganglia from the aortic plexus	135
Appendix D. Accessory Right Spermatic Ganglion Case Report.....	140
Appendix E. Research Ethics Board Approval.....	149
Appendix F. Copyright Permissions	154

LIST OF ACRONYMS

a.....	Accessory
CTRL	Control
DAB	Diaminobenzidine
H&E	Haematoxylin and Eosin
IHC.....	Immunohistochemistry
IMA.....	Inferior Mesenteric Artery
IMG.....	Inferior Mesenteric Ganglion
IMN.....	Intermesenteric Nerve
IMP	Interior Mesenteric Plexus
IVC.....	Inferior Vena Cava
L	Lumbar
LA	Lumbar Artery
LCI	Left Common Iliac Artery
LRV.....	Left Renal Vein
LSG.....	Left Spermatic Ganglion
LSN.....	Lumbar Splanchnic Nerve
LV	Lumbar Vein
MBP	Myelin Basic Protein
NS	Nerve-sparing
NSGCT	Nonseminomatous Germ Cell Tumor
PBS	Phosphate Buffered Saline
PHG.....	Prehypogastric Ganglion
RPLND	Retroperitoneal Lymph Node Dissection
RSG.....	Right Spermatic Ganglion
S	Sacral
SCG.....	Sympathetic Chain Ganglion
SHP.....	Superior Hypogastric Plexus
SMA.....	Superior Mesenteric Artery
T	Thoracic
TA	Testicular Artery
TV	Testicular Vein
TH	Tyrosine Hydroxylase
VIP	Vasointestinal Peptide

PREFACE

Following orchiectomy and chemotherapy, retroperitoneal lymph node dissection (RPLND) has proven to be a highly-effective surgery in the treatment of testis cancer to remove residual masses/metastases from the deep abdomen – boasting >95% cure rates and little-to-no risk of recurrence (Jewett & Groll, 2007). Unfortunately, the literature reports that 17-100% of men with advanced disease will be functionally infertile following this surgery (Jewett et al., 1988; Coogan et al., 1996; Pettus et al., 2009; Heidenreich & Pfister, 2012; Nowroozi et al., 2015; Dimitropoulos et al., 2016). This is due to unintentional damage to the aortic plexus (Jewett & Groll, 2007; Katz & Eggener, 2009) – a preventable complication that is particularly concerning given testis cancer primarily affects men 15-29 years of age (Canadian Cancer Society, 2015) whom are early in their reproductive years.

Nerve-sparing during RPLND remains a suitable method to preserve ejaculatory function (Jewett & Groll, 2007). During bilateral dissections, it requires surgeons to locate and preserve individual fibers from within their surgical field (Pearce et al., 2013) – a substantial task considering the anatomy of the preaortic sympathetic plexuses have not been described in much detail, nor have the relevant fibers in control of ejaculation been isolated. Not surprisingly, nerve-sparing is associated with variable success. For example, in a 2012 review Heidenreich and Pfister reported ejaculatory dysfunction in 75% of patients who underwent bilateral post-chemotherapy RPLND, (Heidenreich & Pfister, 2012) while in 2009, Pettus et al. found that antegrade ejaculation was maintained in 79% of their patients treated with bilateral post-chemotherapy RPLND (Pettus et al., 2009). Although differences in the stage and/or the size of the residual mass are apparent between the reports, surgeon comfort with the normal neural anatomy of the retroperitoneum is a significant factor in the success of RPLND (Jewett & Groll, 2007) and a possible contributing factor to these disparate results. Furthermore, we assert that the poor anatomical understanding of the sympathetic nerves in the deep abdomen has impeded the use of nerve-sparing during RPLND. Therefore, the goal of the present thesis is to provide the first comprehensive characterization of the normal anatomy of the aortic plexus and its variations as it pertains to improving nerve-sparing RPLND.

CHAPTER 1

THE PERIPHERAL NEUROANATOMY OF EJACULATION: A REVIEW

In the present chapter, an introduction to the anatomy and physiology of ejaculation is presented with a particular focus given to describing the neural circuitry in control, and the anatomy of these pathways as it relates to retroperitoneal surgery. The purpose of this chapter is to provide an overview of the current literature, and introduce the rationale for the present thesis and the studies herein. Preference is given to studies pertaining to humans.

1.1 General Introduction

1.1.1. Neurophysiology of Ejaculation

The ejaculation reflex involves the coordination of several pelvic organs and can be divided into two distinct phases: seminal emission and expulsion (Coolen et al., 2004; Giuliano & Clément, 2005). During seminal emission, mature spermatozoa in the epididymis are transported by rhythmic smooth muscle contraction of the vas deferens into the posterior urethra (Steers, 1994). Here, the spermatozoa are mixed with fluid secretions from the seminal vesicles and prostate gland to form semen (Giuliano & Clément, 2005). To limit exposure of the semen to unviable conditions of urine, the bladder neck (also referred to as the cervix of the bladder or internal urethral orifice) is closed by a constant contraction of the internal urethral sphincter (Gosling & Dixon, 1975; Gosling et al., 1977; Thomas, 1983; Gosling, 1986; Kihara et al., 1992; Ando et al., 1993). Expulsion is characterized by the antegrade propulsion of the semen within the urethra towards the penile meatus. This process is driven by rhythmic contraction of the striated perineal muscles; however, continued closure of the bladder neck is necessary to prevent retrograde flow of the semen into the bladder (Whitelaw & Smithwick, 1951; Jewett et al., 1988; Yavetz et al., 1994; Jefferys et al., 2012). In contrast, orgasm is a central neural process that is accountable for the extragenital responses and subjective pleasurable feeling that accompanies expulsion in some mammalian species; it is not part of the ejaculation reflex (Coolen et al., 2004; Giuliano & Clément, 2005).

1.1.1.1. The Spinal Ejaculation Generator

It is well established that ejaculation is controlled by divisions of the somatic, parasympathetic and sympathetic nervous systems (Coolen et al., 2004; Giuliano & Clément, 2005). The integration and coordination of these systems is mediated by the spinal ejaculation generator (also referred to as a spinal pattern generator [McKenna et al., 1991], spinal pacemaker [Sachs & Garinello, 1979] or central pattern generator [Carro-Juárez et al., 2003]) located within the L3-L5 spinal cord (Coolen et al., 2004). Its role is to process afferent innervation and trigger ejaculation when a sufficient threshold of stimulation is reached (Coolen et al., 2004). Without it, a normal physiological ejaculation cannot be elicited (Truitt & Coolen, 2002; Allard et al., 2005). A schematic overview is shown in Figure 1.

The precise mechanism underlying the ability of the spinal ejaculation generator to trigger ejaculation continues to be a topic of research; however, it is accepted that the afferent stimulation can originate from somatic, visceral and/or cortical sources. It is known that somatosensory information from the glans penis, carried by the dorsal nerve of the penis, is responsible for a large proportion of afferent stimulation leading to ejaculation (Herbert, 1973; Steers, 1994; Yang & Bradley, 1999; Coolen et al., 2004; Fode et al., 2015). It has also been postulated from animal studies that visceral afferent fibers detecting distention of the posterior urethra by either saline (Carro-Juárez et al., 2003) or seminal emission (Kimura, 1970; Fode et al., 2015) may contribute to eliciting expulsion; however, clinical findings do not fully support this hypothesis (Coolen et al., 2004). In addition, the brain has influence to modulate the threshold of sensitivity required by the spinal ejaculation generator to elicit an ejaculation (Coolen et al., 2004; Allard et al., 2005).

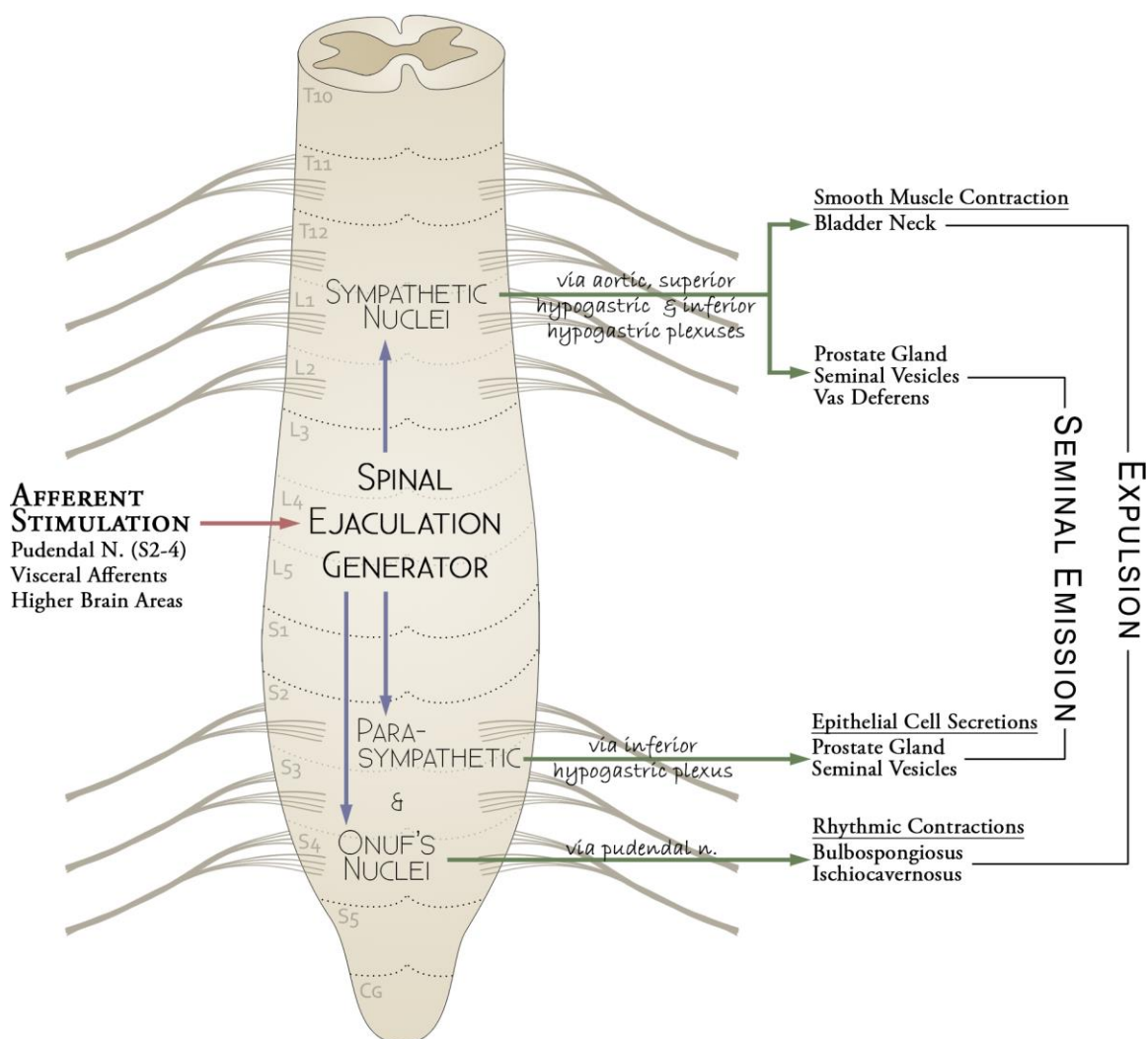


Figure 1. Overview of the spinal ejaculation reflex and its neural components.

The spinal ejaculation generator triggers seminal emission and expulsion after reaching a threshold of afferent stimulation. Epithelial secretion by the prostate and seminal vesicles are controlled by parasympathetic nerves whereas smooth muscle contraction of the sex glands, vas deferens and bladder neck are controlled by sympathetic nerves. During expulsion, rhythmic perineal contractions to propel the semen is mediated by specialized motor neurons in Onuf's nucleus in the sacral spinal cord.

1.1.1.2. Supraspinal Modulation of Ejaculation

Higher brain areas, particularly the medial preoptic area, paraventricular nucleus of the hypothalamus, and the rostral nucleus paragigantocellularis, have been shown to exhibit hierarchical control of the spinal ejaculation generator by either exciting or inhibiting its function (Coolen et al., 2004). The rostral nucleus paragigantocellularis extends serotonergic fibers which directly synapse on the neurons of the spinal ejaculation generator, suppressing the ejaculatory reflex (Marson & McKenna, 1992; Marson et al., 1992). There is evidence to suggest the paraventricular nucleus of the hypothalamus has an excitatory effect on the spinal ejaculation generator via a release of oxytocin which facilitates ejaculatory behaviour in addition to shortening the post-ejaculation refractory period in rats (Coolen et al., 2004). The medial preoptic area is thought to exhibit an excitatory affect through dopamine acting on D₂ receptors which appears to modulate other ejaculatory-related supraspinal regions, rather than acting on the lumbosacral spinal cord directly (Hull et al., 1997; Coolen et al., 2004).

However, the excitatory/inhibitory influence of the supraspinal structures over the spinal ejaculation generator is not necessary since a reflexive ejaculation can still be achieved in human patients (Sønksen et al., 1994; Brackett et al., 1998, 2010; Ibrahim et al., 2016) and animal models (McKenna et al., 1991; Staudt et al., 2012) which have complete spinal transection above the 10th thoracic spinal level. This indicates that, although influenced by higher brain areas, the spinal ejaculator generator alone is sufficient to produce a physiological ejaculation – assuming somatic and autonomic supply to the genitals and pelvic organs remain intact.

1.1.1.3. Neurophysiology of Phase I – Seminal Emission

The emission phase involves sequentially coordinated smooth muscle contraction of the seminal tract and bladder neck to mobilize spermatozoa and secretions from the accessory sexual glands to the posterior urethra (Giuliano & Clément, 2005). This process is mediated by the sympathetic nuclei of the T12-L2 spinal cord and sacral parasympathetic nucleus in the S2-4 spinal cord (Chéhensse et al., 2013). Secretion by the glandular epithelia of the seminal vesicles (Kepper & Keast, 1997) and prostate gland

(Wang et al., 1991) are under parasympathetic control, and are primarily activated by acetylcholine. In contrast, adrenergic innervation by sympathetic nerves causes contraction of the glandular smooth muscle cells that are responsible for moving the secretions into the posterior urethra (Crosby et al., 1962; Wang et al., 1991; Coolen et al., 2004). Sympathetic innervation of the vas deferens, mediated by the α_1 -adrenergic receptors, also induces smooth muscle contraction that transports spermatozoa from the distal epididymis to the posterior urethra (Kolbeck & Steers, 1992; Steers, 1994; Kihara et al., 1997; Kihara, Sato, & Oshima, 1998). Additionally, sympathetic innervation by norepinephrine on α_1 -adrenergic receptors facilitates closure of the bladder neck by causing contraction of the internal urethral sphincter during seminal emission as well as during expulsion (Gosling & Dixon, 1975; Kimura, Adachi, et al., 1975; Gosling et al., 1977; Coolen et al., 2004).

1.1.1.4. Neurophysiology of Phase II - Expulsion

The second (and final) phase of ejaculation corresponds with rhythmic synchronous contraction of the striated perineal muscles, combined with a constant contraction of the internal urethral sphincter to ensure closure of the bladder neck (Whitelaw & Smithwick, 1951; Jewett et al., 1988; Yavetz et al., 1994; Jefferys et al., 2012). The role of the striated perineal muscles (including, but not limited to, the bulbospongiosus, ischiocavernosus muscles and the external anal/urethral sphincters) is to forcefully propel the semen through the urethra (Bohlen et al., 1980; Gerstenberg et al., 1990). In contrast to the adrenergic control of the internal urethral sphincter, these muscles are somatically innervated by the pudendal nerve (S2-4), with their motor neuron soma residing in Onuf's nucleus within the sacral spinal cord (Schröder, 1985). Although it is well acknowledged that Onuf's nucleus contains somatic motor neurons, it exhibits a unique morphology that is different than other motor neuron groups (Schröder, 1985) – perhaps owing to its unique integration with other autonomic reflexes involved in ejaculation. For example, Onuf's nucleus appears to be unaffected during amyotrophic lateral sclerosis (ALS) and other motor neuron degenerative diseases; however, is heavily affected in degenerative diseases of visceromotor neurons like Shy-Drager syndrome, amongst others, where somatic neuron populations are usually spared (Schröder, 1985). These

remarkable observations indicate that Onuf's nucleus is a specialized group of somatic motor neurons that can be voluntarily controlled, yet can also be involuntarily triggered to act in reflexive patterns during expulsion.

1.1.1.5. Peripheral Neuroanatomy of Ejaculation

It is generally accepted that the sympathetic control of seminal emission and the internal urethral sphincter in humans originates in the lower thoracic, and upper lumbar spinal levels (Crosby et al., 1962; Jewett et al., 1988; Keating, 2004; Jefferys et al., 2012). Preganglionic sympathetic fibers to the bladder neck originate from the T12-L1 (with varying contributions from T10-11 and L2) spinal cord (Crosby et al., 1962; Jänig & McLachlan, 1987; Jewett et al., 1988; Fowler et al., 2008; Gomez-Amaya et al., 2015). Here, they descend the lumbar sympathetic chain to extend through the lumbar splanchnic nerves (Learmonth, 1931; Weidner et al., 1994; Kaiho et al., 2003, 2004) at the level of L1, L2 and/or L3 ganglia, depending on the report (Whitelaw & Smithwick, 1951; Crosby et al., 1962; Jewett et al., 1988). However, the anatomical precision of these reports may be undermined when considering the extreme variation common to the lumbar sympathetic chain ganglia (Perlow & Vehe, 1935; Yeager & Cowley, 1948; Webber, 1958).

Fibers controlling seminal emission are reported by Crosby et al. (1965) to originate in the L1-2, or L3 spinal cord, and immediately extend within the lumbar splanchnic nerve(s) from the same region (Learmonth, 1931; Weidner et al., 1994; Kaiho et al., 2003, 2004). The aforementioned innervation of ejaculation is bilateral and evidence from a series of sympathectomies (Whitelaw & Smithwick, 1951) and nerve-sparing retroperitoneal lymph node dissections (RPLND) for testis cancer (Jewett et al., 1988) suggests unilateral preservation may be sufficient to maintain function. A summary of Whitelaw & Smithwick's (1951) findings are illustrated in Figure 2 and the outcomes from Jewett et al. (1988) are shown in Table 1.

After extending from the lumbar sympathetic chain, the lumbar splanchnic nerves coalesce with the fibers of aortic plexus (also referred to as the intermesenteric plexus) and descend along the anterior aspect of the infrarenal abdominal aorta (Dyce, 1934;

Southam, 1959; Keating, 2004; Mirilas & Skandalakis, 2010). It is well known that the fibers of ejaculation course within the lumbar splanchnic nerves (Learmonth, 1931; Kimura, Miyata, et al., 1975; Ando et al., 1993; Weidner et al., 1994; Kaiho et al., 2003, 2004) and, therefore, through the aortic plexus; however, the topographical anatomy of this network in humans remains widely inconsistent between sources (e.g., compare Fig. 1140 from Dwight et al., 1930; Figs. 66 & 68 from Kuntz, 1945; Figs. 110 & 111 from Mitchell, 1953; Figs. 1-4 from Southam, 1959; Figs. 1511-1513 from Spalteholz & Spanner, 1967; Fig. 12.80 from Gray, 1973; Figs. 20.102, 20.113 & 20.114 from Hollinshead, 1974; Fig. 38.7 from O’Rahilly, 1986; Figs. 1 & 2 from Colleselli et al., 1990; Figs. 2-4 from Donohue et al., 1990; Fig. 6.71 from Woodburne & Burkel, 1994; Figs. 4.137, 4.138 & 4.140 from Drake et al., 2005; Figs. 6 & 9 from Mirilas & Skandalakis, 2010; and, Plates 297, 302 & 319 from Netter, 2011). Gross cadaveric observations from rats, cats, rabbits, dogs, and horses suggests the aortic plexus has variable morphology between species with descriptions ranging from a singular fiber, to two trunks or a diffuse network of nerves (Langley & Anderson, 1896; Dyce, 1934; Mizeres, 1955; Baron et al., 1985a; Kihara, Sato, & Oshima, 1998; Kihara, Sato, Ishizaka, et al., 1998).

At the base of the inferior mesenteric artery resides the inferior mesenteric ganglion (Southam, 1959; Jänig & McLachlan, 1987) – the location where preganglionic fibers controlling ejaculation would synapse (Crosby et al., 1962; Pidsudko, 2014a); however, no experimental data exists to substantiate this hypothesis in humans. In fact, contrary to classical anatomical descriptions, a minority of fibers within the lumbar splanchnic nerves are postganglionic indicating some fibers synapse within the sympathetic chain before extending through the lumbar splanchnic nerves (Kraima et al., 2015). Whether the postganglionic fibers, specifically, within the lumbar splanchnic nerves have innervation to the organs involved in ejaculation has yet to be studied. A summary of the efferent sympathetic outflow to the pelvis is schematized in Figure 3.

Distal to the inferior mesenteric ganglion in humans, the aortic plexus converges into a bundle of fibers called the superior hypogastric plexus (also referred to as the presacral nerve) that descends into the pelvis (Langley & Anderson, 1896; Whitelaw & Smithwick,

1951; Crosby et al., 1962; Jewett et al., 1988; Keating, 2004; Mirilas & Skandalakis, 2010). The superior hypogastric plexus is a distinct band of neural tissue ranging from a few millimeters to 1-2 centimeters in width with a variety of morphologies including: a single nerve, two parallel nerves, a plexiform arrangement, or a dense quadrate shaped bundle (Learmonth, 1931; Paraskevas et al., 2008). The lateral position of the superior hypogastric plexus with respect to the aortic bifurcation may vary; however, it is most often centered a few millimeters left of the aortic midline (Paraskevas et al., 2008; Lu et al., 2009). It is well-established that the superior hypogastric plexus contains the fibers imperative to normal ejaculation (Learmonth, 1931; Brindley et al., 1989; Kihara et al., 1991, 1992; Kihara, Sato, Ishizaka, et al., 1998).

RATE OF EJACULATORY DYSFUNCTION BY REGION OF SYMPATHECTOMY

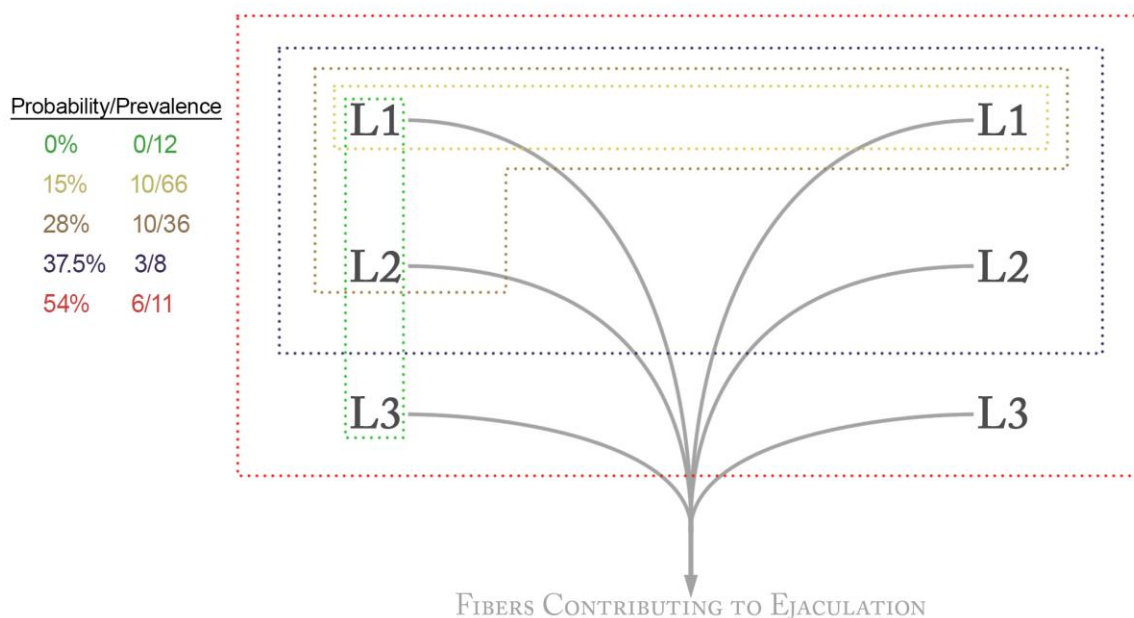


Figure 2. Unilateral lesions insufficient to cause ejaculatory dysfunction.

The present illustration was drawn to summarize the relevant findings from Whitelaw & Smithwick (1951) during their study of thoracolumbar sympathectomies on sexual function in humans. Their findings indicate the L1-L3 sympathetic chain ganglia are important for ejaculation; however, not all ganglia are required to maintain function. In fact, unilateral preservation is sufficient to maintain ejaculation, and the probability of experiencing ejaculatory dysfunction was related to the number of lumbar sympathetic chain ganglia removed during the procedure.

Table 1. Ejaculation is spared after partial nerve-sparing during RPLND.

Summary of the post-operative ejaculatory function following nerve-sparing RPLND, modified from Jewett et al. (1988). Post-operative ejaculation in many patients indicated not all lumbar splanchnic nerves are needed for ejaculatory function. However, the nerves required for antegrade ejaculation may vary between individuals given varying outcomes after similar nerve roots were spared (compare patients 2 & 15, or 13 & 20).

Patient No.	Side of Tumor	Nerve Roots Spared		Postoperative Ejaculation	Follow-up (months)
		Right	Left		
1	Left	L2,3	L3	+	31
2	Left	L2,3		+	30
3	Right	L1-3		+	27
4	Left	L1-3		+	27
5	Right		L2,3	+	22
6	Right	L1,2	L3	+	18
7	Left	L1,2	L2	+	17
8	Left	L1,2	L1,2	+	15
9	Left	L3	L1,2	+	14
10	Right	L1-3		+	11
11	Left	L1,2		+	11
12	Right	L1-3	T12, L1,2	+	9
13	Left	T12, L1		+	8
14	Right		L1,2	+	7
15	Left	L2,3		-	6
16	Right	T12, L1,2	L1-3	+	6
17	Right		L3	+	5
18	Left	L2,3	L1-3	+	3
19	Right		L1,2	+	3
20	Right	T12, L1		-	2

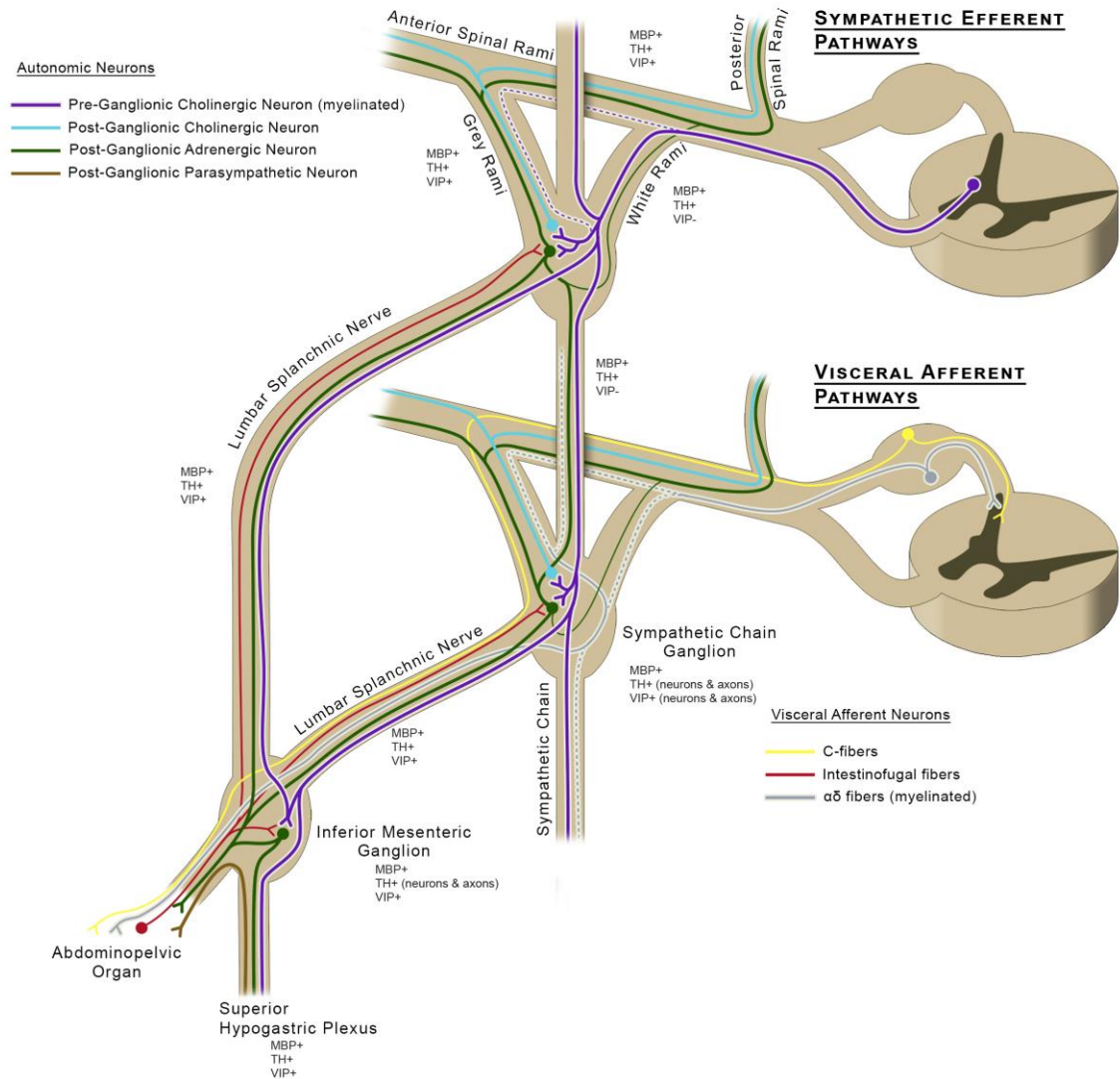


Figure 3. Axonal organization of the lumbar sympathetic nerves.

Based on an immunohistochemical analysis by Kraima et al. (2015). Myelinated preganglionic sympathetic nerves (purple) from the intermediolateral horn of the lumbar spinal cord exit via the ventral roots and travel to the sympathetic chain ganglia via the white rami communicantes; however, some fibers will also route through the grey rami. The fibers in control of ejaculation will synapse on unmyelinated post-ganglionic adrenergic neurons (green) in the sympathetic chain, preaortic ganglia or continue into the pelvis to synapse. MBP, Myelin Basic Protein; TH, Tyrosine Hydroxylase; VIP, Vasointestinal Peptide.

This was demonstrated in humans by Learmonth (1931) who observed smooth muscle contractions of the internal urethral sphincter, prostate gland and seminal vesicles following electrical stimulation of an intact superior hypogastric plexus, as well as the distal end of a completely transected plexus (Learmonth, 1931). These findings have been further substantiated by Brindley et al. (1989) who demonstrated that electrical stimulation of the superior hypogastric plexus in paraplegic men was sufficient to induce seminal emission and antegrade expulsion (Brindley et al., 1989). Furthermore, disruption of the superior hypogastric plexus, as well as the fibers of the aortic plexus and/or lumbar splanchnic nerves, are associated with ejaculatory dysfunction following retroperitoneal and/or pelvic surgeries (Stahlgren & Ferguson, 1959; Weinstein & Machleder, 1975; Balslev & Harling, 1983; Danzi et al., 1983; Jewett et al., 1988; Hojo et al., 1991; Enker, 1992; Yavetz et al., 1994; Maeda et al., 2003; Keating, 2004; Liang et al., 2007; Jewett & Groll, 2007; Katz & Eggener, 2009; Lu et al., 2009; Veroux et al., 2010; Han et al., 2010; Carragee et al., 2011; Doeksen et al., 2011; Heidenreich & Pfister, 2012; Hsiao et al., 2012; Nowroozi et al., 2015).

After converging into the superior hypogastric plexus, the sympathetic fibers divide into left and right hypogastric nerves and descend into the pelvis (Mauroy et al., 2003). Here, they merge with the parasympathetic pelvic splanchnic nerves from S2-4 (Alsaid et al., 2011), with possible minor contributions from S1 (Ali et al., 2004) or S5 (Baader & Herrmann, 2003) to form the left and right inferior hypogastric plexus (Mauroy et al., 2003) which course anteriorly along the lateral walls of the rectum (Hojo et al., 1991; Baader & Herrmann, 2003; Alsaid et al., 2009). The sympathetic fibers will then extend through their respective plexuses to innervate the smooth muscle of the seminal vesicles, prostate gland, vas deferens and bladder neck to facilitate antegrade flow of semen during both seminal emission and expulsion (Crosby et al., 1962; Wang et al., 1991; Kolbeck & Steers, 1992; Steers, 1994; Kihara & De Groat, 1997; Kihara et al., 1997; Kihara, Sato, & Oshima, 1998; Ali et al., 2004). Figure 4 provides a neuroanatomical overview of the peripheral autonomic plexuses involved in the control of ejaculation.

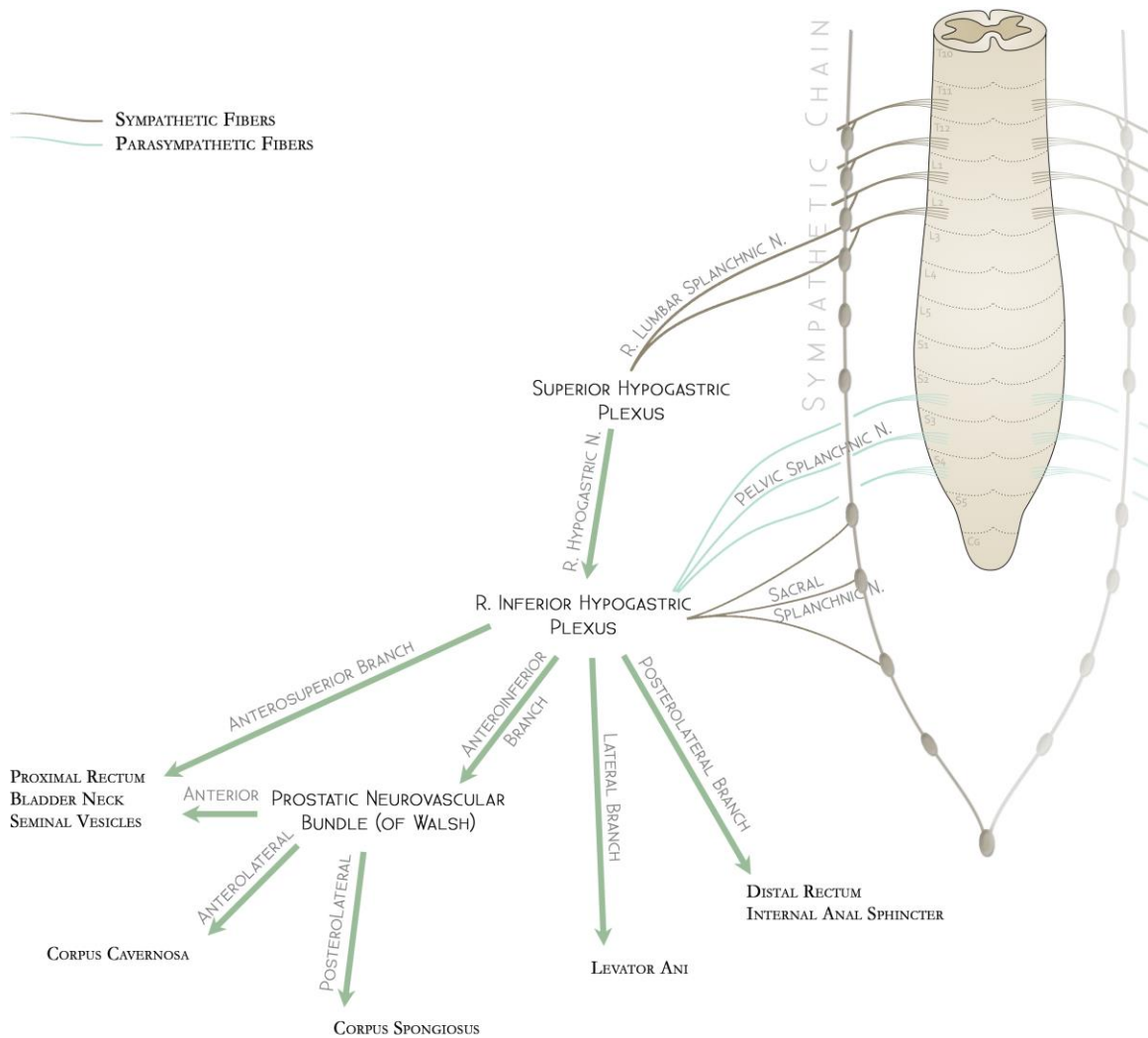


Figure 4. The autonomic supply to the pelvic organs.

The neuroanatomical organization of the abdominal and pelvic autonomic plexuses based on the current literature (Walsh et al., 1983; Baader & Herrmann, 2003; Mauroy et al., 2003; Costello et al., 2004; Keating, 2004; Alsaid et al., 2009, 2011). For brevity, only the right side was illustrated; however, a bilaterally symmetric left side exists (communicating with the right side via the superior hypogastric plexus). Note that the nomenclature used to describe the branches of the inferior hypogastric plexus are relative to the rectum, whereas the branches of the prostatic neurovascular bundle (of Walsh) are relative to the prostate. Brown – sympathetic fibers; Teal – parasympathetic fibers; Green – mixed autonomic fibers.

1.1.2. Ejaculatory Dysfunction

Several types of ejaculatory dysfunction exist that alter the normal physiological process described above. Idiopathic causes typically include: premature ejaculation, where ejaculation occurs prior to intromission or shortly after, or delayed ejaculation, which is characterized by an inability to ejaculate (also referred to as anorgasmia or idiopathic anejaculation) (Ohl et al., 2011). In both conditions, the neurological reflex loop of ejaculation remains intact; therefore, the pathophysiology is likely multifactorial and may have an underlying psychological component (Buvat, 2011; Chen, 2016; Kalejaiye et al., 2017). In contrast, retrograde ejaculation and neurogenic anejaculation are acquired conditions that result due to a range of physical impairments – most predictably, following iatrogenic injury during surgery in the retroperitoneum.

1.1.2.1. Retrograde Ejaculation & Neurogenic Anejaculation

Retrograde ejaculation is characterized by a reflux of semen into the bladder during expulsion caused by an impaired ability to properly close the bladder neck (Yavetz et al., 1994; Ohl et al., 2008, 2011). This can be caused by: certain medications, such as α -adrenergic antagonists (e.g., tamsulosin) in the treatment of prostatic enlargement causing urethral obstruction (Hellstrom et al., 2009), or by damage to the internal urethral sphincter (Aggarwal & Lemack, 2015) or its sympathetic innervation (Keating, 2004; Jewett & Groll, 2007). The former can be managed by changes in medication whereas the latter two situations may be transient or permanent.

With neurogenic anejaculation, patients experience a loss of seminal emission. In patients with spinal cord injuries at T10 or higher (and other neurodegenerative spinal cord diseases such as transverse myelitis or multiple sclerosis), this is often due to an inability to reach the threshold to trigger ejaculation (Brackett et al., 2010; Ohl et al., 2011; Ibrahim et al., 2016). Alternatively, neurogenic anejaculation can result from direct impairment to the neurological reflex loop as seen in patients with spinal cord injuries at T11 or below (Brackett et al., 2010; Ohl et al., 2011; Ibrahim et al., 2016), or patients with damage to the sympathetic nerves innervating the smooth muscle of the vas deferens and accessory sex glands (Kedia et al., 1975; Ohl et al., 2011).

Most commonly, damage to the peripheral nerves controlling seminal emission and/or bladder neck closure occurs after surgical procedures; however, autonomic neuropathy secondary to diabetes has also been documented as a progressive cause of retrograde ejaculation and neurogenic anejaculation in patients (Dunsmuir & Holmes, 1996; Sexton & Jarow, 1997).

1.1.3. Preventing Iatrogenic Ejaculatory Dysfunction after Retroperitoneal Surgery

Iatrogenic ejaculatory dysfunction (i.e., retrograde ejaculation and/or neurogenic anejaculation) is a significant post-operative complication in men undergoing retroperitoneal surgery. It is caused by unintended surgical injury to the sympathetic nerves of the lumbar sympathetic chain, aortic plexus, and/or superior hypogastric plexus responsible for internal urethral sphincter contraction and/or seminal emission (Keating, 2004; Jewett & Groll, 2007; Katz & Eggener, 2009).

This can occur in any retroperitoneal or pelvic surgery that involves dissection near the infrarenal abdominal aorta and/or lateral aspects of the colon including: RPLND for testis cancer (Jewett et al., 1988; Jewett & Groll, 2007; Lambert & Fisch, 2007; Katz & Eggener, 2009; Heidenreich & Pfister, 2012; Hsiao et al., 2012; Pearce et al., 2013; Nowroozi et al., 2015; Dimitropoulos et al., 2016), retroperitoneal aortic repair (Weinstein & Machleder, 1975; Veroux et al., 2010), anterior approach lumbar fusion (Carragee et al., 2011), or total mesorectal excision (Stahlgren & Ferguson, 1959; Balslev & Harling, 1983; Danzi et al., 1983; Hojo et al., 1991; Enker, 1992; Maeda et al., 2003; Keating, 2004; Liang et al., 2007; Han et al., 2010; Doeksen et al., 2011).

Today, the highest risk of post-operative ejaculatory dysfunction appears to be in men undergoing RPLND for advanced testis cancer with upwards of 75-100% of patients affected in recent reports (Heidenreich & Pfister, 2012; Nowroozi et al., 2015; Dimitropoulos et al., 2016). Furthermore, ejaculatory dysfunction in this patient population is particularly concerning considering testis cancer primarily affects young men between the ages of 15 and 29 years (Canadian Cancer Society, 2015) – many of whom have not yet had children. Although urologists are well-aware that preserving the

relevant sympathetic nerves during RPLND can prevent this complication, refinement of nerve-sparing techniques has been limited by a poor understanding of the neuroanatomy and is therefore not yet widely adopted by all institutions.

1.1.3.1. Evolution of Nerve-sparing RPLND for Testis Cancer

Testis cancer is the most common malignancy in young men with an annual estimate of 1050 new cases in Canada (Canadian Cancer Society, 2015), 2,418 new cases in the United Kingdom (Cancer Research UK, 2014), and 8,850 new cases in the United States (American Cancer Society, 2017) – a national average of 3, 7 and 24 (respectively) new diagnoses daily. Since the middle of the 20th century, RPLND has been successfully performed for the treatment of advanced-stage testis cancer (Cooper et al., 2002). It was well-known that patients with retroperitoneal metastases could be cured (Albers, 2004), albeit at the risk of post-operative ejaculatory dysfunction and potential functional infertility due to damage of the sympathetic nerves (Jewett & Groll, 2007). With limited descriptions and inconsistencies between illustrations of the anatomy, attempts to spare the nerves were made by reducing the surgical boundaries so as to avoid them. The evolution of this avoidance method of nerve-sparing was driven by emerging lymph node mapping studies that revealed testis cancer metastases to the lymph nodes tended to be ipsilateral to the affected testicle (Ray et al., 1974; Weissbach & Boedefeld, 1987). In response, several modified surgical templates for RPLND were developed (Donohue et al., 1993; Janetschek et al., 1994; Sheinfeld & Herr, 1998; Nelson et al., 1999; Krege et al., 2008) to resect ipsilateral lymphatic tissue, while avoiding dissection of the contralateral nerves. Given the success of these approaches in improving the rate of antegrade ejaculation postoperatively (Richie, 1990; Doerr et al., 1993; Katz & Eggener, 2009), modified surgical templates for RPLND gained popularity and continued to be used at many international centers (Steiner et al., 2006; Beck et al., 2007; Pearce et al., 2013; Cho et al., 2017).

However, more recently, studies have challenged the worth of modified templates based on the risk of leaving extratemplate metastatic disease (Carver et al., 2007; Eggener et al., 2007). In fact, it is estimated that, in the post-chemotherapy setting, at least 7% to 32% (depending on the surgical template used) of patients would have extratemplate disease

left behind (Carver et al., 2007). Because an effort to spare ejaculation should never be made at the risk of incomplete cancer resection (Jewett & Groll, 2007), a full bilateral surgical template is considered most prudent for advanced-stage cancer, and nerve-sparing should only be performed where possible (Carver et al., 2007).

Nerve-sparing during bilateral template resections requires surgeons to locate and preserve individual fibers from within their surgical field (Pearce et al., 2013). In patients with low-grade disease, nerve-sparing during bilateral RPLND has been demonstrated by experienced surgeons to preserve antegrade ejaculation at a rate of 90-100% (Jewett et al., 1988; Donohue et al., 1990) – a substantial task considering the anatomy of the preaortic sympathetic plexuses in humans has not been described in much detail, nor have the relevant fibers in control of ejaculation been isolated. During post-chemotherapy RPLND for advanced-stage disease, nerve-sparing becomes less successful as surgeons are tasked with navigating increasingly distorted anatomy and resecting more extensive disease (Jewett & Groll, 2007). Not surprisingly, nerve-sparing in the post-chemotherapy setting is associated with variable rates of antegrade ejaculation. For example, in a 2012 review, Heidenreich and Pfister reported ejaculatory dysfunction in 75% of patients who underwent bilateral post-chemotherapy RPLND (Heidenreich & Pfister, 2012), while, others have demonstrated antegrade ejaculation could be maintained in 74-79% of patients treated with bilateral post-chemotherapy RPLND (Coogan et al., 1996; Pettus et al., 2009). Although differences in the stage and/or the size of the residual mass are apparent between the reports, surgeon comfort with the normal neural anatomy of the retroperitoneum is a significant factor in the success of RPLND (Jewett & Groll, 2007) and a possible contributing factor to these disparate results. Worse yet, some institutions still do not attempt to nerve-spare during post-chemotherapy RPLND and report ejaculatory dysfunction in the large majority of, if not all, patients (Nowroozi et al., 2015; Dimitropoulos et al., 2016). Given that it is estimated that nerve-sparing in the post-chemotherapy setting is achievable in at least 50% of patients (Jewett & Groll, 2007), a limited understanding of the sympathetic nerves in the abdomen is possibly impeding the implementation and success of nerve-sparing techniques in the post-chemotherapy setting.

1.2 Overview of Thesis

We contend that a poor anatomical understanding of the sympathetic nerves in the deep abdomen has limited the efficacy, refinement and promulgation of precise nerve-sparing practices during bilateral RPLND. Therefore, the goal of the present thesis is to provide the first comprehensive characterization of the normal anatomy of the human aortic plexus (Studies 1 & 2) and its variations (Study 3) as it pertains to improving bilateral nerve-sparing RPLND (Study 4).

1.2.1. Study 1

It is generally accepted that the lumbar splanchnic nerves join the aortic plexus to synapse in various preaortic ganglia including the inferior mesenteric ganglion (Baron et al., 1985a, 1985b; Jänig & McLachlan, 1987; Rusu, 2009; Gray, 2010; Motoc et al., 2010). However, anatomical descriptions are inconsistent with respect to the number of lumbar splanchnic nerves that supply aortic plexus (Mitchell, 1953; Hollinshead, 1971; Gray, 1973; Woodburne & Burkel, 1994; Mirilas & Skandalakis, 2010). Furthermore, descriptions and illustrations of the organization of the aortic plexus and its constituent ganglia are inconsistent and often incomplete (O’Rahilly, 1986; Mirilas & Skandalakis, 2010; Motoc et al., 2010; Netter, 2011; Moore et al., 2014). Given that only a few human cadaveric studies exist to describe portions of the aortic plexus (Colleselli et al., 1990; Rusu, 2009; Motoc et al., 2010), it remains unclear whether inconsistencies between textbooks (Kuntz, 1945; Mitchell, 1953; Spalteholz & Spanner, 1967; Hollinshead, 1971; Gray, 1973; Woodburne & Burkel, 1994; Netter, 2011) are artistic depictions or differ based on true human variability as determined by unpublished dissection.

To address these apparent inconsistencies, this study provides the first comprehensive mapping of the aortic plexus in male cadavers using standard dissection and histological techniques.

1.2.2. Study 2

In providing the first detailed anatomical description of the aortic plexus and its ganglia in human males during Study 1 (Beveridge, Johnson, et al., 2015), we characterized the prehypogastric ganglion: a previously-unidentified structure that appears to be the right-sided equivalent of the well-acknowledged inferior mesenteric ganglion. Ultimately, characterization of the prehypogastric ganglion revealed that the organization of the aortic plexus in males is bilaterally symmetrical around four major constituent prevertebral ganglia (left/right spermatic ganglia, prehypogastric ganglion, and inferior mesenteric ganglion). These findings contrast the classical characterization of the aortic plexus as a variable, convoluted network of nerves (Kuntz, 1945; Spalteholz & Spanner, 1967; Hollinshead, 1974; Mirilas & Skandalakis, 2010; Netter, 2011).

Because our previous study only investigated the anatomy of the aortic plexus in males, it remained uncertain whether females also exhibit the prehypogastric ganglion.

Furthermore, the literature does not contain any primary reports of homologous structures to the male spermatic ganglia (i.e., ovarian ganglia) in humans. Therefore, the second study investigated whether a conserved organization is seen in the female aortic plexus with particular emphasis on examining the existence of the prehypogastric and ovarian ganglia through gross cadaveric dissection and histological analysis.

1.2.3. Study 3

In acknowledging that the aortic plexus in males and females is consistently bilateral in its organization from the results of the two previous studies (Beveridge, Johnson, et al., 2015, 2016), it was also observed that it was rarely symmetrical in its positioning. This was particularly apparent in the inconsistent positioning of the lumbar splanchnic nerves – a variation that may complicate nerve-sparing during retroperitoneal surgery. To date, the known anatomy and variations of the lumbar splanchnic nerves has only been understood from qualitative observations (Lu et al., 2009; Rusu, 2009; Motoc et al., 2010). Specifically, a range of two to four lumbar splanchnic nerves may be observed joining the aortic plexus (Mitchell, 1953; Hollinshead, 1971; Gray, 1973; Woodburne & Burkel, 1994; Mirilas & Skandalakis, 2010) with the possibility of another joining the

superior hypogastric plexus (Dwight et al., 1930; Learmonth, 1931; Mitchell, 1953; Duncan & Jonck, 1965; Hollinshead, 1971; O’Rahilly, 1986; Mirilas & Skandalakis, 2010). Details about their prevalence and/or course are rarely discussed.

Considering the precise involvement of each lumbar splanchnic nerve in seminal emission and antegrade ejaculation is not yet understood, an investigation into their variations may assist comprehensive nerve-sparing techniques for surgeons. As such, the third study of this thesis will use human cadaveric specimens to quantify the prevalence, course and positional deviations of the infrarenal lumbar splanchnic nerves joining the aortic and superior hypogastric plexus.

1.2.4. Study 4

To achieve complete resection of lymphatic tissue during RPLND, the great vessels must be mobilized. This is achieved by locating, ligating and then sectioning the lumbar arteries and veins entering the posterior aspect of the great vessels to facilitate rolling them laterally (Scardino et al., 2011; Wein, 2012). Given the complexities of resecting lymphatic tissue and residual masses in the post-chemotherapy setting, nerve-sparing with complete vascular control of the lumbar vessels may be difficult to achieve (Jewett & Groll, 2007). It is clear that a strong understanding of the neurovascular anatomy is required for success (Jewett & Groll, 2007). Several studies exist (including the previous studies in this thesis) to provide a foundation for understanding the normal retroperitoneal neurovascular anatomy (Banagan et al., 1976; Colleselli et al., 1990; Baniel et al., 1995; Lu et al., 2009; Mirilas & Skandalakis, 2010; Beveridge, Johnson, et al., 2015; Beveridge, Power, et al., 2015; Beveridge et al., 2017); however, the clinical usefulness of this information is limited by the lack of studies examining the relationship of the neural and vascular anatomy as it pertains to surgical interventions.

In the final study of this thesis, we address this issue by examining the relationship between the sympathetic nerves and the lumbar vessels within the boundaries of an infrahilar bilateral template using human cadavers. With this understanding, we will discuss strategies to navigate these structures during bilateral RPLND.

1.3 References

- 1) Aggarwal H, Lemack GE (2015). Primary Bladder Neck Obstruction in Men and Women: An Update on Diagnosis and Management. *Current Bladder Dysfunction Reports*, 10(3), 288–294.
- 2) Albers P (2004). Resection of retroperitoneal residual tumor after chemotherapy for testicular cancer indication and surgical techniques. *Critical Reviews in Oncology/Hematology*, 50(1), 79–85.
- 3) Ali M, Johnson IP, Hobson J, Mohammadi B, Khan F (2004). Anatomy of the Pelvic Plexus and Innervation of the Prostate Gland. *Clinical Anatomy*, 17(2), 123–129.
- 4) Allard J, Truitt WA, McKenna KE, Coolen LM (2005). Spinal cord control of ejaculation. *World Journal of Urology*, 23(2), 119–126.
- 5) Alsaïd B, Bessede T, Karam I, Abd-Alsamad I, Uhl JF, Benoît G, ... Delmas V (2009). Coexistence of adrenergic and cholinergic nerves in the inferior hypogastric plexus: Anatomical and immunohistochemical study with 3D reconstruction in human male fetus. *Journal of Anatomy*, 214(5), 645–654.
- 6) Alsaïd B, Moszkowicz D, Peschaud F, Bessede T, Zaitouna M, Karam I, ... Benoit G (2011). Autonomic-somatic communications in the human pelvis: Computer-assisted anatomic dissection in male and female fetuses. *Journal of Anatomy*, 219(5), 565–573.
- 7) American Cancer Society (2017). What are the Key Statistics about Testicular Cancer? Retrieved December 29, 2017, from <https://www.cancer.org/cancer/testicular-cancer/about/key-statistics.html>
- 8) Ando M, Kihara K, Sato K, Sato T, Oshima H (1993). Regulation of the bladder neck closure by lumbar splanchnic nerves at ejaculation in the dog. *Neurourology and Urodynamics*, 12(1), 91–98.
- 9) Baader B, Herrmann M (2003). Topography of the pelvic autonomic nervous system and its potential impact on surgical intervention in the pelvis. *Clinical Anatomy*, 16(2), 119–130.
- 10) Balslev I, Harling H (1983). Sexual dysfunction following operation for carcinoma of the rectum. *Diseases of the Colon & Rectum*, 26(12), 785–788.
- 11) Banagan K, Gelb D, Poelstra K, Ludwig S (1976). Anatomic Mapping of the Lumbar Nerve Roots during a Direct Lateral Transpsoas Approach to the Spine: A Cadaveric Study. *Spine*, 36(11), 687–691.
- 12) Baniel J, Foster R, Donohue J (1995). Surgical Anatomy of the Lumbar Vessels: Implication for Retroperitoneal Surgery. *Journal of Urology*, 153(5), 1422–1425.

- 13) Baron R, Jänig W, McLachlan EM (1985a). On the anatomical organization of the lumbosacral sympathetic chain and the lumbar splanchnic nerves of the cat-Langley revisited. *Journal of the Autonomic Nervous System*, 12(4), 289–300.
- 14) Baron R, Jänig W, McLachlan EM (1985b). The afferent and sympathetic components of the lumbar spinal outflow to the colon and pelvic organs in the cat. I. The hypogastric nerve. *The Journal of Comparative Neurology*, 238(2), 135–46.
- 15) Beck SDW, Foster RS, Bihrlé R, Donohue JP, Einhorn LH (2007). Is full bilateral retroperitoneal lymph node dissection always necessary for postchemotherapy residual tumor? *Cancer*, 110(6), 1235–1240.
- 16) Beveridge TS, Fournier DE, Groh AMR, Johnson M, Power NE, Allman BL (2017). The anatomy of the infrarenal lumbar splanchnic nerves in human cadavers: implications for retroperitoneal nerve-sparing surgery. *Journal of Anatomy*, 232(1), 124–133.
- 17) Beveridge TS, Johnson M, Power A, Power NE, Allman BL (2015). Anatomy of the nerves and ganglia of the aortic plexus in males. *Journal of Anatomy*, 226(1), 93–103.
- 18) Beveridge TS, Johnson M, Power NE, Allman BL (2016). Histological verification of the prehypogastric and ovarian ganglia confirms a bilaterally symmetrical organization of the ganglia comprising the aortic plexus in female human cadavers. *Journal of Anatomy*, 228(5), 805–811.
- 19) Beveridge TS, Power A, Johnson M, Power NE, Allman BL (2015). The lumbar arteries and veins: Quantification of variable anatomical positioning with application to retroperitoneal surgery. *Clinical Anatomy*, 28(5), 649–660.
- 20) Bohlen JG, Held JP, Sanderson MO (1980). The male orgasm: pelvic contractions measured by anal probe. *Archives of Sexual Behavior*, 9(6), 503–521.
- 21) Brackett NL, Ferrell SM, Aballa TC, Amador MJ, Padron OF, Sønksen J, Lynne CM (1998). An analysis of 653 trials of penile vibratory stimulation in men with spinal cord injury. *Journal of Urology*, 159(6), 1931–1934.
- 22) Brackett NL, Lynne CM, Ibrahim E, Ohl DA, Sønksen J (2010). Treatment of infertility in men with spinal cord injury. *Nature Reviews Urology*, 7(3), 162–172.
- 23) Brindley GS, Sauerwein D, Hendry WF (1989). Hypogastric plexus stimulators for obtaining semen from paraplegic men. *British Journal of Urology*, 64(1), 72–77.
- 24) Buvat J (2011). Pathophysiology of Premature Ejaculation. *Journal of Sexual Medicine*, 8(Suppl. 4), 316–327.

- 25) Canadian Cancer Society (2015). Canadian Cancer Statistics Special topic: Predictions of the future burden of cancer in Canada. *Public Health Agency of Canada*, 1–151.
- 26) Cancer Research UK (2014). Testicular Cancer Statistics. Retrieved December 29, 2017, from <http://www.cancerresearchuk.org/health-professional/cancer-statistics/statistics-by-cancer-type/testicular-cancer>
- 27) Carragee EJ, Mitsunaga KA, Hurwitz EL, Scuderi GJ (2011). Retrograde ejaculation after anterior lumbar interbody fusion using rhBMP-2: A cohort controlled study. *The Spine Journal*, 11(6), 511–516.
- 28) Carro-Juárez M, Cruz SL, Rodríguez-Manzo G (2003). Evidence for the involvement of a spinal pattern generator in the control of the genital motor pattern of ejaculation. *Brain Research*, 975(1–2), 222–228.
- 29) Carver BS, Shayegan B, Eggener S, Stasi J, Motzer RJ, Bosl GJ, Sheinfeld J (2007). Incidence of metastatic nonseminomatous germ cell tumor outside the boundaries of a modified postchemotherapy retroperitoneal lymph node dissection. *Journal of Clinical Oncology*, 25(28), 4365–4369.
- 30) Chéhensse C, Bahrami S, Denys P, Clément P, Bernabé J, Giuliano F (2013). The spinal control of ejaculation revisited: A systematic review and meta-analysis of anejaculation in spinal cord injured patients. *Human Reproduction Update*, 19(5), 507–526.
- 31) Chen J (2016). The pathophysiology of delayed ejaculation. *Translational Andrology and Urology*, 5(4), 549–562.
- 32) Cho JS, Kaimakliotis HZ, Cary C, Masterson TA, Beck S, Foster R (2017). Modified retroperitoneal lymph node dissection for post-chemotherapy residual tumour: a long-term update. *BJU International*, 120(1), 104–108.
- 33) Colleselli K, Poisel S, Schachtner W, Bartsch G (1990). Nerve-preserving bilateral retroperitoneal lymphadenectomy: Anatomical study and operative approach. *The Journal of Urology*, 144(2), 293–298.
- 34) Coogan CL, Hejase MJ, Wahle GR, Foster RS, Rowland RG, Bihrlé R, Donohue JP (1996). Nerve sparing post-chemotherapy retroperitoneal lymph node dissection for advanced testicular cancer. *The Journal of Urology*, 156(5), 1656–1658.
- 35) Coolen LM, Allard J, Truitt WA, McKenna KE (2004). Central regulation of ejaculation. *Physiology and Behavior*, 83(2), 203–215.
- 36) Cooper JF, Leadbetter WF, Chute R (2002). The thoracoabdominal approach for retroperitoneal gland dissection: its application to testis tumors. 1950. *The Journal of Urology*, 167(2), 920–926.

- 37) Costello AJ, Brooks M, Cole OJ (2004). Anatomical studies of the neurovascular bundle and cavernosal nerves. *BJU International*, 94(7), 1071–1076.
- 38) Crosby EC, Humphrey T, Lauer EW (1962). *Correlative Anatomy of the Nervous System*. New York: The Macmillan Company.
- 39) Danzi M, Ferulano GP, Abate S, Califano G (1983). Male sexual function after abdominoperineal resection for rectal cancer. *Diseases of the Colon & Rectum*, 26(10), 665–668.
- 40) Dimitropoulos K, Karatzas A, Papandreou C, Daliani D, Zachos I, Pisters LL, Tzortzis V (2016). Sexual dysfunction in testicular cancer patients subjected to post-chemotherapy retroperitoneal lymph node dissection: A focus beyond ejaculation disorders. *Andrologia*, 48(4), 425–430.
- 41) Doeksen A, Gooszen JA, Van Duijvendijk P, Tanis PJ, Bakx R, Slors JFM, Van Lanschot JJB (2011). Sexual and urinary functioning after rectal surgery: A prospective comparative study with a median follow-up of 8.5 years. *International Journal of Colorectal Disease*, 26(12), 1549–1557.
- 42) Doerr A, Skinner EC, Skinner DG (1993). Preservation of ejaculation through a modified retroperitoneal lymph node dissection in low stage testis cancer. *The Journal of Urology*, 149(6), 1472–1474.
- 43) Donohue J, Foster R, Rowland R, Bihrlé R, Jones J, Geier G (1990). Nerve-sparing retroperitoneal lymphadenectomy with preservation of ejaculation. *Journal of Urology*, 144(2), 287–291.
- 44) Donohue JP, Thornhill J, Foster R, Rowland R, Bihrlé R (1993). Retroperitoneal lymphadenectomy for clinical stage A testis cancer (1965 to 1989): modifications of technique and impact on ejaculation. *Journal of Urology*, 149(2), 237–243.
- 45) Drake R, Vogl W, Mitchell A (2010). Abdomen. In W. Schmitt & R. Gruliow (Eds.), *Gray's Anatomy for Students* (2nd ed., pp. 343–345). Philadelphia PA: Churchill Livingstone Elsevier.
- 46) Duncan H, Jonck L (1965). The Presacral Plexus in Anterior Fusion of the Lumbar Spine. *South African Journal of Surgery*, 3(2), 93–96.
- 47) Dunsmuir WD, Holmes SAV (1996). The aetiology and management of erectile, ejaculatory, and fertility problems in men with diabetes mellitus. *Diabetic Medicine*, 13(8), 700–708.
- 48) Dwight T, McMurrich J, Hamann C (1930). The Sympathetic System of Nerves. In G. Peirsol (Ed.), *Human Anatomy* (9th ed., pp. 1366–1374). London: J.B. Lippincott Company.

- 49) Dyce KM (1934). The Splanchnic Nerves and Major Abdominal Ganglia of the Horse. *Journal of Anatomy*, 92(1), 62–74.
- 50) Eggener SE, Carver BS, Sharp DS, Motzer RJ, Bosl GJ, Sheinfeld J (2007). Incidence of Disease Outside Modified Retroperitoneal Lymph Node Dissection Templates in Clinical Stage I or IIA Nonseminomatous Germ Cell Testicular Cancer. *The Journal of Urology*, 177(3), 937–943.
- 51) Enker WE (1992). Potency, cure, and local control in the operative treatment of rectal cancer. *Archives of Surgery*, 127(12), 1396–1402.
- 52) Fode M, Ohl DA, Sønksen J (2015). A step-wise approach to sperm retrieval in men with neurogenic anejaculation. *Nature Reviews. Urology*, 12(11), 607–616.
- 53) Fowler CJ, Griffiths D, de Groat WC (2008). The neural control of micturition. *Nature Reviews: Neuroscience*, 9(6), 453–66.
- 54) Gerstenberg TC, Levin RJ, Wagner G (1990). Erection and ejaculation in man. Assessment of the electromyographic activity of the bulbocavernosus and ischiocavernosus muscles. *British Journal of Urology*, 65(4), 395–402.
- 55) Giuliano F, Clément P (2005). Physiology of ejaculation: Emphasis on serotonergic control. *European Urology*, 48(3), 408–417.
- 56) Gomez-Amaya SM, Barbe MF, de Groat WC, Brown JM, Tuite GF, Corcos J, ... Ruggieri MR (2015). Neural reconstruction methods of restoring bladder function. *Nature Reviews: Urology*, 12(2), 100–118.
- 57) Gosling J (1986). The distribution of noradrenergic nerves in the human lower urinary tract. *Clinical Science*, 70(Suppl. 14), 3s–6s.
- 58) Gosling J, Dixon J (1975). The structure and innervation of smooth muscle in the wall of the bladder neck and proximal urethra. *British Journal of Urology*, 47(5), 549–558.
- 59) Gosling J, Dixon J, Lendon R (1977). The Autonomic Innervation of the Human Male and Female Bladder Neck and Proximal Urethra. *The Journal of Urology*, 118(2), 302–305.
- 60) Gray H (1973). Sympathetic System. In C. Goss (Ed.), *Gray's Anatomy* (29th ed., pp. 1025–1036). Philadelphia: Lea & Febiger.
- 61) Gray H (2010). The Nervous System, The Sympathetic Nervous System. In T. Pick & R. Howden (Eds.), *Gray's Anatomy* (15th ed., pp. 779–791). New York, NY: Barnes & Noble.

- 62) Han SL, Shen X, Zeng QQ, Guo SC, Cheng J, Zhu GB (2010). Analysis of super-low anterior resection for rectal cancer from a single center. *Journal of Gastrointestinal Cancer*, 41(3), 159–164.
- 63) Heidenreich A, Pfister D (2012). Retroperitoneal lymphadenectomy and resection for testicular cancer: an update on best practice. *Therapeutic Advances in Urology*, 4(4), 187–205.
- 64) Hellstrom WJG, Giuliano F, Rosen RC (2009). Ejaculatory Dysfunction and Its Association with Lower Urinary Tract Symptoms of Benign Prostatic Hyperplasia and BPH Treatment. *Urology*, 74(1), 15–21.
- 65) Herbert J (1973). The role of the dorsal nerves of the penis in the sexual behaviour of the male rhesus monkey. *Physiology and Behaviour*, 10(2), 293–300.
- 66) Hojo K, Vernava AM, Sugihara K, Katumata K (1991). Preservation of urine voiding and sexual function after rectal cancer surgery. *Diseases of the Colon and Rectum*, 34(7), 532–539.
- 67) Hollinshead WH (1971). *Anatomy for Surgeons: Volume 2 - The Thorax, Abdomen, and Pelvis*. (2nd ed.). New York, NY: Harper & Row, Publishers.
- 68) Hollinshead WH (1974). *Textbook of Anatomy* (3rd ed.). Hagerstown, MD: Harper & Row, Publishers.
- 69) Hsiao W, Deveci S, Mulhall JP (2012). Outcomes of the management of post-chemotherapy retroperitoneal lymph node dissection-associated anejaculation. *BJU International*, 110(8), 1196–1200.
- 70) Hull EM, Du J, Lorrain DS, Matuszewich L (1997). Testosterone, preoptic dopamine, and copulation in male rats. *Brain Research Bulletin*, 44(4), 327–333.
- 71) Ibrahim E, Lynne CM, Brackett NL (2016). Male fertility following spinal cord injury: An update. *Andrology*, 4(1), 13–26.
- 72) Janetschek G, Reissigl A, Peschel R, Hobisch A, Bartsch G (1994). Laparoscopic retroperitoneal lymph node dissection for clinical stage I nonseminomatous testicular tumor. *Urology*, 44(3), 382–391.
- 73) Jänig W, McLachlan EM (1987). Organization of lumbar spinal outflow to distal colon and pelvic organs. *Physiological Reviews*, 67(4), 1332–404.
- 74) Jefferys A, Siassakos D, Wardle P (2012). The management of retrograde ejaculation: A systematic review and update. *Fertility and Sterility*, 97(2), 306–312.
- 75) Jewett MA, Groll RJ (2007). Nerve-Sparing Retroperitoneal Lymphadenectomy. *Urologic Clinics of North America*, 34(2), 149–158.

- 76) Jewett MA, Kong YP, Goldberg SD, Sturgeon JF, Thomas GM, Alison RE, Gospodarowicz MK (1988). Retroperitoneal Lymphadenectomy for Testis Tumor with Nerve Sparing for Ejaculation. *The Journal of Urology*, 139(6), 1220–1224.
- 77) Kaiho Y, Nakagawa H, Ito A, Satoh M, Ikeda Y, Saito S, Arai Y (2004). Ipsilateral Seminal Emission Generated by Electrostimulation of the Lumbar Sympathetic Nerve During Nerve Sparing Laparoscopic Retroperitoneal Lymph Node Dissection for Testicular Cancer. *The Journal of Urology*, 172(3), 928–931.
- 78) Kaiho Y, Nakagawa H, Takeuchi A, Ito A, Satoh M, Kurokawa K, Arai Y (2003). Electrostimulation of sympathetic nerve fibers during nerve-sparing laparoscopic retroperitoneal lymph node dissection in testicular tumor. *International Journal of Urology*, 10(5), 284–286.
- 79) Kalejaiye O, Almekaty K, Blecher G, Minhas S (2017). Premature ejaculation: challenging new and the old concepts. *F1000Research*, 6(F1000 Faculty Rev), 2084.
- 80) Katz MH, Eggener SE (2009). The evolution, controversies, and potential pitfalls of modified retroperitoneal lymph node dissection templates. *World Journal of Urology*, 27(4), 477–483.
- 81) Keating JP (2004). Sexual function after rectal excision. *ANZ Journal of Surgery*, 74(4), 248–259.
- 82) Kedia KR, Markland C, Fraley EE (1975). Sexual function following high retroperitoneal lymphadenectomy. *Journal of Urology*, 114(2), 237–239.
- 83) Kepper ME, Keast JR (1997). Location, immunohistochemical features, and spinal connections of autonomic neurons innervating the rat seminal vesicles. *Biology of Reproduction*, 57(5), 1164–74.
- 84) Kihara K, De Groat W (1997). Sympathetic efferent pathways projecting to the bladder neck and proximal urethra in the rat. *Journal of the Autonomic Nervous System*, 62(3), 134–142.
- 85) Kihara K, Sato K, Ando M, Sato T, Oshima H (1991). Lumbosacral sympathetic trunk as a compensatory pathway for seminal emission after bilateral hypogastric nerve transections in the dog. *The Journal of Urology*, 145(3), 640–643.
- 86) Kihara K, Sato K, Ando M, Sato T, Oshima H (1992). A mechanism of retrograde ejaculation after bilateral hypogastric nerve transections in the dog. *Journal of Urology*, 148(4), 1307–1309.
- 87) Kihara K, Sato K, Ishizaka K, Oshima H (1998). Preservation of ejaculatory function by reconstruction of the canine hypogastric nerve. *Journal of Neurosurgery*, 88(4), 726–733.

- 88) Kihara K, Sato K, Oshima H (1997). Sympathetic efferent pathways projecting to the vas deferens in the rat. *The Anatomical Record*, 248(2), 291–299.
- 89) Kihara K, Sato K, Oshima H (1998). Sympathetic efferent pathways projecting to the vas deferens. *Microscopy Research and Technique*, 42(6), 398–408.
- 90) Kimura Y (1970). On Peripheral Nerves Controlling Ejaculation. *Tohoku Journal of Experimental Medicine*, 105(2), 177–190.
- 91) Kimura Y, Adachi K, Kisaki N, Ise K (1975). Role of alpha-adrenergic receptor mechanism in closure of the internal urethral orifice during ejaculation. *Urology International*, 30(5), 341–349.
- 92) Kimura Y, Miyata K, Adachi K, Kisaki N (1975). Peripheral nerves controlling the closure of internal urethral orifice during ejaculation. *Urology International*, 30(3), 218–227.
- 93) Kolbeck SC, Steers WD (1992). Neural regulation of the vas deferens in the rat: an electrophysiological analysis. *The American Journal of Physiology*, 263(2 Pt 2), R331-338.
- 94) Kraima AC, van Schaik J, Susan S, van de Velde CJH, Hamming JF, Lakke EAJF, DeRuiter MC (2015). New insights in the neuroanatomy of the human adult superior hypogastric plexus and hypogastric nerves. *Autonomic Neuroscience: Basic and Clinical*, 189, 60–67.
- 95) Krege S, Beyer J, Souchon R, Albers P, Albrecht W, Algaba F, ... von der Maase H (2008). European Consensus Conference on Diagnosis and Treatment of Germ Cell Cancer: A Report of the Second Meeting of the European Germ Cell Cancer Consensus group (EGCCCG): Part I. *European Urology*, 53(3), 478–496.
- 96) Kuntz A (1945). Anatomic structure and relationships, the female sex organs. In *The Autonomic Nervous System* (3rd ed., p. 32,314). Philadelphia PA: Lea & Febiger.
- 97) Lambert SM, Fisch H (2007). Infertility and Testis Cancer. *Urologic Clinics of North America*, 34(2), 269–277.
- 98) Langley JN, Anderson HK (1896). The Innervation of the Pelvic and adjoining Viscera: Part VII. Anatomical Observations. *Journal of Physiology*, 20(4–5), 371–406.
- 99) Learmonth JR (1931). A contribution to the neurophysiology of the urinary bladder in man. *Brain*, 54(2), 147–176.
- 100) Liang J, Lai H, Lee P (2007). Laparoscopic Pelvic Autonomic Nerve-Preserving Surgery for Patients with Lower Rectal Cancer after Chemoradiation Therapy. *Annals of Surgical Oncology*, 14(4), 1285–1287.

- 101) Lu S, Xu Y, Chang S, Zhang Y, Shi J, Ding ZH, ... Zhong S (2009). Clinical anatomy study of autonomic nerve with respect to the anterior approach lumbar surgery. *Surgical and Radiologic Anatomy*, 31(6), 425–430.
- 102) Maeda K, Maruta M, Utsumi T, Sato H, Toyama K, Matsuoka H (2003). Bladder and male sexual functions after autonomic nerve-sparing TME with or without lateral node dissection for rectal cancer. *Techniques in Coloproctology*, 7(1), 29–33.
- 103) Marson L, List M, McKenna K (1992). Lesions of the nucleus paragigantocellularis alter ex copula penile reflexes. *Brain Research*, 592(1–2), 187–192.
- 104) Marson L, McKenna K (1992). A role for 5-hydroxytryptamine in descending inhibition of spinal sexual reflexes. *Experimental Brain Research*, 88(2), 313–320.
- 105) Mauroy B, Demondion X, Drizenko A, Gouillet E, Bonnal JL, Biserte J, Abbou C (2003). The inferior hypogastric plexus (pelvic plexus): Its importance in neural preservation techniques. *Surgical and Radiologic Anatomy*, 25(1), 6–15.
- 106) McKenna KE, Chung SK, Mcvary KT (1991). A model for the study of sexual function in anesthetized male and female rats. *Am J Physiol*, 261(5), R1276-85.
- 107) Mirilas P, Skandalakis J (2010). Surgical Anatomy of the Retroperitoneal Spaces, Part IV: Retroperitoneal Nerves. *The American Surgeon*, 76(3), 253–262.
- 108) Mitchell G (1953). The Abdominal Part of the Sympathetic System. In *Anatomy of the Autonomic Nervous System* (1st ed., pp. 257–296). Edinburgh.
- 109) Mizeres N (1955). The Anatomy of the Autonomic Nervous System in the Dog. *American Journal of Anatomy*, 96(2), 285–318.
- 110) Moore K, Dalley A, Agur A (2014). Abdomen. In C. Taylor (Ed.), *Clinical Oriented Anatomy* (7th ed., p. 304). Philadelphia PA: Lippincott Williams & Wilkins.
- 111) Motoc A, Rusu MC, Jianu AM (2010). The spermatic ganglion in humans: An anatomical update. *Romanian Journal of Morphology and Embryology*, 51(4), 719–723.
- 112) Nelson J, Chen R, Bishoff J, Oh W, Kantoff P, Donehower R, Kavoussi L (1999). Laparoscopic retroperitoneal lymph node dissection for clinical stage I nonseminomatous germ cell testicular tumors. *Urology*, 54(6), 1064–1067.
- 113) Netter F (2011). Back and Spinal Cord, Abdomen, Pelvis and Perineum. In J. Hansen (Ed.), *Atlas of Human Anatomy* (5th ed., Plates 160, 297, 319, 389, 390). Philadelphia PA: Saunders Elsevier.

- 114) Nowroozi M, Ayati M, Arbab A, Jamshidian H, Ghorbani H, Niroomand H, ... Ghadian A (2015). Postchemotherapy Retroperitoneal Lymph Node Dissection in Patients with Nonseminomatous Testicular Cancer: A Single Center Experiences. *Nephrology and Urology Monthly*, 7(5), 1–5.
- 115) O’Rahilly R (1986). The Abdomen. In A. Meier (Ed.), *Anatomy: A Regional Study of Human Structure* (5th ed., pp. 433–436). Philadelphia PA: W.B. Saunders Company.
- 116) Ohl D, Quallich S, Sønksen J, Brackett N, Lynne C (2008). Anejaculation and retrograde ejaculation. *Urologic Clinics of North America*, 35(2), 211–220.
- 117) Ohl DA, Quallich SA, Sønksen J, Brackett NL, Lynne CM (2011). Ejaculatory Dysfunction (Sabanegh E., Ed.), *Male Infertility*. Totowa, NJ: Humana Press.
- 118) Paraskevas G, Tsitsopoulos P, Papaziogas B, Natsis K, Martoglou S, Stolidou A, Kitsoulis P (2008). Variability in superior hypogastric plexus morphology and its clinical applications: A cadaveric study. *Surgical and Radiologic Anatomy*, 30(6), 481–488.
- 119) Pearce S, Steinberg Z, Eggener S (2013). Critical evaluation of modified templates and current trends in retroperitoneal lymph node dissection. *Current Urology Reports*, 14(5), 511–517.
- 120) Perlow S, Vehe K (1935). Variations in the gross anatomy of the stellate and lumbar sympathetic ganglia. *The American Journal of Surgery*, 30(3), 454–458.
- 121) Pettus JA, Carver BS, Masterson T, Stasi J, Sheinfeld J (2009). Preservation of Ejaculation in Patients Undergoing Nerve-Sparing Postchemotherapy Retroperitoneal Lymph Node Dissection for Metastatic Testicular Cancer. *Urology*, 73(2), 328–331.
- 122) Pidsudko Z (2014). Immunohistochemical characteristics and distribution of neurons in the paravertebral, prevertebral and pelvic ganglia supplying the urinary bladder in the male pig. *Journal of Molecular Neuroscience*, 52(1), 56–70.
- 123) Ray B, Hajdu SI, Whitmore WF (1974). Distribution of retroperitoneal lymph node metastases in testicular germinal tumors. *Cancer*, 33(2), 340–348.
- 124) Richie JP (1990). Clinical stage 1 testicular cancer: The role of modified retroperitoneal lymphadenectomy. *Journal of Urology*, 144(5), 3–4.
- 125) Rusu MC (2009). Accessory lumbar splanchnic ganglia in humans: A case report. *Anatomical Science International*, 84(3), 253–256.
- 126) Sachs BD, Garinello LD (1979). Spinal pacemaker controlling sexual reflexes in male rats. *Brain Research*, 171(1), 152–156.

- 127) Scardino P, Linehan W, Zelefsky M, Vogelzang N (2011). *Comprehensive Textbook of Genitourinary Oncology* (L. W. & Wilkins, Ed.) (4th ed.). Philadelphia PA.
- 128) Schröder H (1985). Anatomical and pathoanatomical studies on the spinal efferent systems innervating pelvic structures. *Journal of the Autonomic Nervous System*, 14(1), 23–48.
- 129) Sexton WJ, Jarow JP (1997). Effect of diabetes mellitus upon male reproductive function. *Urology*, 49(4), 508–513.
- 130) Sheinfeld J, Herr H (1998). Role of surgery in management of germ cell tumor. *Seminars in Oncology*, 25(2), 203–209.
- 131) Sønksen J, Biering-Sørensen F, Kristensen J (1994). Ejaculation induced by penile vibratory stimulation in men with spinal cord injuries. The importance of the vibratory amplitude. *Paraplegia*, 32(10), 651–660.
- 132) Southam J (1959). The Inferior Mesenteric Ganglion. *Journal of Anatomy*, 93, 304–308.
- 133) Spalteholz W, Spanner R (1967). The Nervous System. In *Atlas of Human Anatomy* (16th ed., pp. 816–817). Philadelphia PA: F.A. Davis Company.
- 134) Stahlgren LH, Ferguson LK (1959). Effects of Abdominoperineal Resection on Sexual Function in Sixty Patients with Ulcerative Colitis. *AMA Archives of Surgery*, 78(4), 604–610.
- 135) Staudt MD, Truitt WA, Mckenna KE, de Oliveira CVR, Lehman MN, Coolen LM (2012). A Pivotal Role of Lumbar Spinothalamic Cells in the Regulation of Ejaculation via Intraspinous Connections. *Journal of Sexual Medicine*, 9(9), 2256–2265.
- 136) Steers WD (1994). Physiology of the vas deferens. *World Journal of Urology*, 12(5), 281–285.
- 137) Steiner H, Peschel R, Müller T, Akkad T, Gozzi C, Bartsch G (2006). Post-chemotherapy retroperitoneal lymph node dissection - is full bilateral resection always necessary? *European Urology Supplements*, 5(2), 97.
- 138) Thomas A (1983). Ejaculatory dysfunction. *Fertility and Sterility*, 39(4), 445–454.
- 139) Truitt WA, Coolen LM (2002). Identification of a potential ejaculation generator in the spinal cord. *Science*, 297(5586), 1566–1569.
- 140) Veroux P, D'Arrigo G, Veroux M, Giaquinta A, Lomeo A (2010). Sexual dysfunction after elective endovascular or hand-assisted laparoscopic abdominal

- aneurysm repair. *European Journal of Vascular and Endovascular Surgery*, 40(1), 71–75.
- 141) Walsh PC, Lepor H, Eggleston JC (1983). Radical Prostatectomy with Preservation of Sexual Function: Anatomical and Pathological Considerations. *The Prostate*, 4(5), 473–485.
- 142) Wang J -M, McKenna KE, Lee C (1991). Determination of prostatic secretion in rats: Effect of neurotransmitters and testosterone. *The Prostate*, 18(4), 289–301.
- 143) Webber RH (1958). A Contribution on the Sympathetic Nerves in the Lumbar Region. *The Anatomical Record*, 24(12), 581–604.
- 144) Weidner W, Zöller G, Sauerwein D, Fischer C, Hummel G, Kallerhoff M, Ringert R (1994). A modified technique for nerve-sparing retroperitoneal lymph node dissection in stage II nonseminomatous germ cell tumors using intraoperative measurement of bladder neck pressure alterations following sympathetic nerve fiber electrostimulation. *European Urology*, 26(1), 67–70.
- 145) Wein A (2012). Male Genitalia. In L. Kavoussi, A. Novick, A. Partin, & C. Peters (Eds.), *Campbell-Walsh Urology* (10th ed., pp. 874–876). Philadelphia PA: Saunders Elsevier.
- 146) Weinstein MH, Machleder H (1975). Sexual Function After Aorto-Iliac Surgery. *Annals of Surgery*, 181(6), 787–790.
- 147) Weissbach L, Boedefeld E (1987). Localization of solitary and multiple metastases in stage II nonseminomatous testis tumor as basis for a modified staging lymph node dissection in stage I. *Journal of Urology*, 138(1), 77–82.
- 148) Whitelaw G, Smithwick R (1951). Some Secondary Effects of Sympathectomy with Particular Reference to Disturbance of Sexual Function. *The New England Journal of Medicine*, 245(4), 121–130.
- 149) Woodburne R, Burkel W (1994). The Autonomic Nerves of the Abdomen. In *Essentials of Human Anatomy* (9th ed., pp. 502–507). New York, NY: Oxford University Press.
- 150) Yang CC, Bradley WE (1999). Innervation of the human glans penis. *The Journal of Urology*, 161(1), 97–102.
- 151) Yavetz H, Yogev L, Hauser R, Lessing JB, Paz G, Homonnai ZT (1994). Retrograde ejaculation. *Human Reproduction*, 9(3), 381–386.
- 152) Yeager G, Cowley R (1948). Anatomical Observations on the Lumbar Sympathetics with Evaluation of Sympathectomies in Organic Peripheral Vascular Disease. *Annals of Surgery*, 127(5), 953–967.

CHAPTER 2

ANATOMY OF THE NERVES AND GANGLIA OF THE AORTIC PLEXUS IN MALES

In the present chapter, a detailed study of the nerves and ganglia of the aortic plexus in males is described. A version of this chapter is published in the *Journal of Anatomy*, Volume 226, Issue 1, Pages 93-103. Histological protocols used in the following study are listed in Appendix A (H&E) and Appendix B (IHC).

2.1 Abstract

It is well accepted that the aortic plexus is a network of pre- and post-ganglionic nerves overlying the abdominal aorta, which is primarily involved with the sympathetic innervation to the mesenteric, pelvic and urogenital organs. Because a comprehensive anatomical description of the aortic plexus and its connections with adjacent plexuses are lacking, these delicate structures are prone to unintended damage during abdominal surgeries. Through dissection of fresh, frozen human cadavers (n = 7), the present study aimed to provide the first complete mapping of the nerves and ganglia of the aortic plexus in males. Using standard histochemical procedures, ganglia of the aortic plexus were verified through microscopic analysis using haematoxylin & eosin (H&E) and anti-tyrosine hydroxylase stains. All specimens exhibited four distinct sympathetic ganglia within the aortic plexus: the right and left spermatic ganglia, the inferior mesenteric ganglion and one previously unidentified ganglion, which has been named the prehypogastric ganglion by the authors. The spermatic ganglia were consistently supplied by the L1 lumbar splanchnic nerves and the inferior mesenteric ganglion and the newly characterized prehypogastric ganglion were supplied by the left and right L2 lumbar splanchnic nerves, respectively. Additionally, our examination revealed the aortic plexus does have potential for variation, primarily in the possibility of exhibiting accessory splanchnic nerves. Clinically, our results could have significant implications for preserving fertility in men as well as sympathetic function to the hindgut and pelvis during retroperitoneal surgeries.

2.2 Introduction

As part of the autonomic nervous system, the sympathetic chains are a pair of bilaterally symmetrical trunks of segmental ganglia located lateral to the vertebral column which receive preganglionic neurons from the thoracolumbar segments of the spinal cord [thoracic (T) 1 – lumbar (L) 2] (Dwight et al., 1930; Gray, 2010; Mirilas & Skandalakis, 2010). Myelinated axons from the intermediate horn of the thoracolumbar spinal cord generally penetrate the sympathetic chain and synapse with the constituent ganglion cells (Sadler, 2010). However, some of these preganglionic axons continue beyond the sympathetic chain as splanchnic nerves, and ultimately synapse within preaortic (prevertebral/collateral) ganglia located in plexuses overlying the visceral branches of the aorta (Hollinshead, 1974). Emerging from the thoracic region, the greater, lesser and least splanchnic nerves synapse within the coeliac, superior mesenteric and aorticorenal ganglia before supplying the abdominal organs except the hindgut (Loukas et al., 2010). Sympathetic innervation of the hindgut and pelvic viscera occurs via the lumbar splanchnic nerves which synapse in the aortic plexus – the network of autonomic nerves overlying the abdominal aorta between the superior mesenteric artery and the bifurcation of the common iliac arteries (Dwight et al., 1930; Spalteholz & Spanner, 1967; Gray, 2010).

It is generally accepted that the lumbar splanchnic nerves synapse within various preaortic ganglia (e.g. inferior mesenteric; right and left spermatic) (Baron et al., 1985b; Jänig & McLachlan, 1987; Rusu, 2009; Gray, 2010; Motoc et al., 2010); however, it remains unclear how many lumbar splanchnic nerves actually supply the aortic plexus. For example, although it is commonly suggested that four pairs of lumbar splanchnic nerves exist, the number said to supply the aortic plexus varies in the literature from two to four pairs (Spalteholz & Spanner, 1967; Hollinshead, 1974; Mirilas & Skandalakis, 2010; Netter, 2011). More specifically, some reports suggest that the first lumbar splanchnic nerve does not contribute to the aortic plexus directly but rather connects to the superior mesenteric ganglion (Netter, 2011) and/or the coeliac ganglion (Rusu, 2009; Mirilas & Skandalakis, 2010). In contrast, other studies have reported that the first

lumbar splanchnic nerve does indeed supply the aortic plexus (Rusu, 2009) and targets the spermatic ganglia (Motoc et al., 2010).

Given these conflicting reports regarding the splanchnic nerves, it is perhaps not surprising that the currently available anatomical descriptions and illustrations of the aortic plexus can appear inconsistent and/or incomplete. Additional confusion can arise when one considers both the written (Moore et al., 2014) and illustrative (O’Rahilly, 1986) suggestions that minor, unnamed ganglia may exist within the aortic plexus. For example, a textbook illustration of the prevertebral ganglia shows an unlabelled ‘swelling’ within the aortic plexus that is drawn distinctly, yet at the same level as the inferior mesenteric ganglion (O’Rahilly, 1986; reprinted in Mirilas & Skandalakis, 2010).

To address the apparent inconsistencies in the splanchnic nerve supply to the aortic plexus as well as the incomplete description of its constituent ganglia, we endeavoured to complete the first comprehensive mapping of the aortic plexus and its connections with adjacent plexuses in males. This was achieved through meticulous dissection of fresh, frozen human cadavers. Standard histological techniques and microscopy were then used to confirm the identification of sympathetic ganglionic tissue collected during dissection.

2.3 Materials and Methods

The anatomy of the aortic plexus was investigated in seven fresh, frozen male human cadavers [mean age at death = 75.4 years (range 53–97)]. Specimens were obtained with permission from the body bequeathal program at Western University, London ON, Canada, in accordance with the Anatomy Act of Ontario and Western’s Committee for Cadaveric Use in Research. Specimens with history or evidence of previous retroperitoneal surgery were excluded from the study population. One specimen showed evidence of a small infrarenal abdominal aortic aneurysm (<3 cm) and another specimen suffered from neurofibromatosis – neither of which appeared to disrupt the normal anatomy of the aortic plexus, and these specimens were thus included in the study population.

2.3.1. Dissection

A superficial midline incision was made from the xiphoid process to the pubic symphysis, arcing left of the umbilicus. An incision was made through the linea alba and the anterior wall of the peritoneal sac, exposing the peritoneal cavity. A horizontal incision at the level of the umbilicus was made from the right to the left midaxillary line to divide the anterior body wall into four segments. An oblique incision along the root of the mesentery was made from the suspensory muscle of the duodenum towards the cecum. The ascending and descending colon were mobilized by incising the right and left paracolic gutters, and the sigmoid colon was detached from the rectum. The intestines, pancreas and remaining posterior parietal peritoneum were then reflected superiorly to expose the infrarenal retroperitoneum. Care was made to landmark the left renal vein, ureters, inferior mesenteric vessels and gonadal vessels. Dissection of the aortic plexus was completed by first identifying the right lumbar splanchnic nerves within the interaortocaval fat. The right lumbar splanchnic nerves were followed posteriorly to locate the right sympathetic chain and anteriorly to isolate preaortic nerves of the aortic plexus. Then, dissection of the left sympathetic chain, and left lumbar splanchnic nerves provided the foundation to elucidate any undissected preaortic nerves. Care was taken to properly distinguish intermesenteric nerves of the aortic plexus, classically defined as nerves coursing posterior to the left renal vein (Jänig & McLachlan, 1987), from those which coursed anterior to the left renal vein within the mesenteric plexus, which we differentially classified as intraperitoneal branches of the mesenteric plexuses. The present study did not investigate the anatomy of the intraperitoneal branches of the mesenteric plexuses nor the potential parasymphetic contributions to the aortic plexus.

The position of all ganglia and nerves relative to the infrarenal aortic branches were documented in writing and with photography. Photographs were taken using a Nikon D7000 DSLR camera with a Sigma 18–200 mm, f/3.5–6.3 lens or Nikon Macro 105 mm, f/ 2.8 lens. Higher magnification photographs were taken using a surgical microscope with an OMAX 3.2MP mounted camera. In a subset of specimens, the tissues identified as ganglia of the aortic plexus were excised for histological and immunohistochemical analysis and verification.

2.3.2. Histology

To verify the macroscopic identification of ganglia during gross dissection, histological techniques were used to determine whether the identified structures contained neuron cell bodies. Ganglia removed during dissection were immediately fixed in 10% formalin solution for a minimum of 24 h before paraffin-embedding. Specimens were sectioned at 5 μm thicknesses using a Microm HM-325 Microtome, and placed on Surgipath X-tra Precleaned Micro Slides (Leica Microsystems). A Zeiss A1 light microscope was used to examine the specimens. Calibrated and scaled photomicrographs were taken using a Zeiss AxioCam MRc microscope-mounted camera and processed using AXIOVISION LE software.

2.3.2.1. Haematoxylin-Eosin Staining

All acquired ganglia were subject to haematoxylin-eosin (H&E) staining. Tissues were warmed at 60 °C for 30 min and then were stained with H&E using standard regressive method procedures (Kiernan, 1990). Neuron cell bodies were identified based on previously described qualitative characteristics of peripheral sympathetic ganglia: neurons with eccentrically placed nuclei and prominent nucleoli containing abundant cytoplasmic lipofuscin surrounded by circumferential, yet irregularly arranged satellite cells amongst elongated Schwann cell nuclei (Ovalle & Nahirney, 2008; Young et al., 2014). To determine consistencies in the microscopic structures, slides were additionally compared against a positive control (i.e. the sympathetic chain ganglion, which was positive for neuron cell bodies) and a negative control (i.e. the sciatic nerve, which contains sympathetic axons but is void of neuron cell bodies).

2.3.2.2. Anti-Tyrosine Hydroxylase Staining

A previously unidentified ganglion, which we called the prehypogastric ganglion (discussed in detail below), was identified in addition to the three known ganglia of the aortic plexus. To further characterize whether this ganglion contained sympathetic neurons, immunohistochemistry was performed using an anti-tyrosine hydroxylase antibody (anti-TH) (Sigma, monoclonal anti-tyrosine hydroxylase clone TH-2, mouse IgG1 isotype, Prod. No. T 1299). Tyrosine hydroxylase is an enzyme involved in

catecholamine synthesis, and its presence has been used in previous studies to characterize neurons as sympathetic in nature (Amino et al., 2005; Motoc et al., 2010).

Immunohistochemical sections were heated to 37 °C for a minimum of 12 h, and then stained using standard immunohistochemical procedures (Kiernan, 1990; Dako, 2013). Antigen retrieval was performed in citrate buffer pH 6.0, in a de-cloaking chamber before blocking (Dako, 2013). Slides were incubated for 1 h with 0.5 $\mu\text{L mL}^{-1}$ of anti-TH, as established by preliminary titrations. The application of the secondary antibody was completed using an ImmPRESS Anti-Mouse Ig Peroxidase Polymer Detection Kit (Vector Laboratories, Cat. No. MP-7402) and was then labelled with DAB (DAB Peroxidase Substrate Kit, 3,3'-diaminobenzidine, Vector Laboratories, Cat. No. SK-4100) as per standard protocols (Vector Laboratories, 2010, 2013). Haematoxylin was used as the counterstain (Dako, 2013).

Serial sections of matched specimens were used as negative controls and followed identical procedures, except for the application of the primary antibody, anti-TH. A side-by-side comparison of the tissue with its negative control was completed to determine true positive anti-TH staining relative to non-specific background noise (false-positive staining). Positive controls (positive for sympathetic neuron cell bodies) for the immunohistochemical experiments were completed on cadaver-matched lumbar sympathetic chain or inferior mesenteric ganglia. The positive controls served two purposes. First, positive staining of these tissues confirmed a successful experiment. Secondly, having positive controls from each specimen provided an indicator of antigen preservation post-mortem. Preliminary experiments revealed that specimens dissected more than 2 months post-mortem had poor antigen preservation as indicated by the negative staining, positive control tissue. Because of this result, only specimens dissected within 2 months post-mortem were included in the immunohistochemical analysis.

2.4 Results

The aortic plexus consisted of a symmetrically organized network of nerves overlying the aorta between the left renal vein and the bifurcation of the common iliac arteries.

Proximal nerves were referred to as nerves 'supplying' the plexus, and distal nerves as 'branches'. The nomenclature for the lumbar sympathetic chain ganglia was in accordance with the system described by O'Rahilly (1986), in which the lumbar sympathetic chain ganglia are named based on their rami communicantes. Specifically, the first lumbar (L1) sympathetic chain ganglion is identified by its rami communicantes to the T12 and L1 spinal nerves, and the second lumbar (L2) sympathetic chain ganglion is connected to the L1 and L2 spinal nerves.

The aortic plexus was always supplied by the lumbar sympathetic chains via lumbar splanchnic nerves (LSN), and in the majority of subjects, intermesenteric nerves from the aorticorenal and superior mesenteric ganglia were also found to supply the aortic plexus superiorly. The results of the dissections and histological analysis are summarized comprehensively in Figure 5. The aortic plexus was bilaterally symmetrical in that it comprised a left and right cord, supplied by the L1 and L2 LSN, and had consistent projections to the inferior mesenteric plexus overlying the inferior mesenteric artery, the superior hypogastric plexus descending into the pelvis, as well as the spermatic plexus overlying the testicular arteries (Figure 6). The right and left cords of the aortic plexus were defined as the longitudinal collection of nerves lying just lateral to the midline of the aorta (Dwight et al., 1930), which extended from just inferior to the left renal vein, towards the inferior mesenteric plexus and superior hypogastric plexus, where they converged.

Ganglia of the aortic plexus were visually differentiated from typical nerves by the presence of a dark spot within the nervous tissue. Given that microscopic analysis revealed a high concentration of neuron cell bodies in this dark region, we suggest the colour differentiation seen during gross dissection may be analogous and conceptually similar to grey matter (unmyelinated neuron cell bodies) visible in the central nervous system.

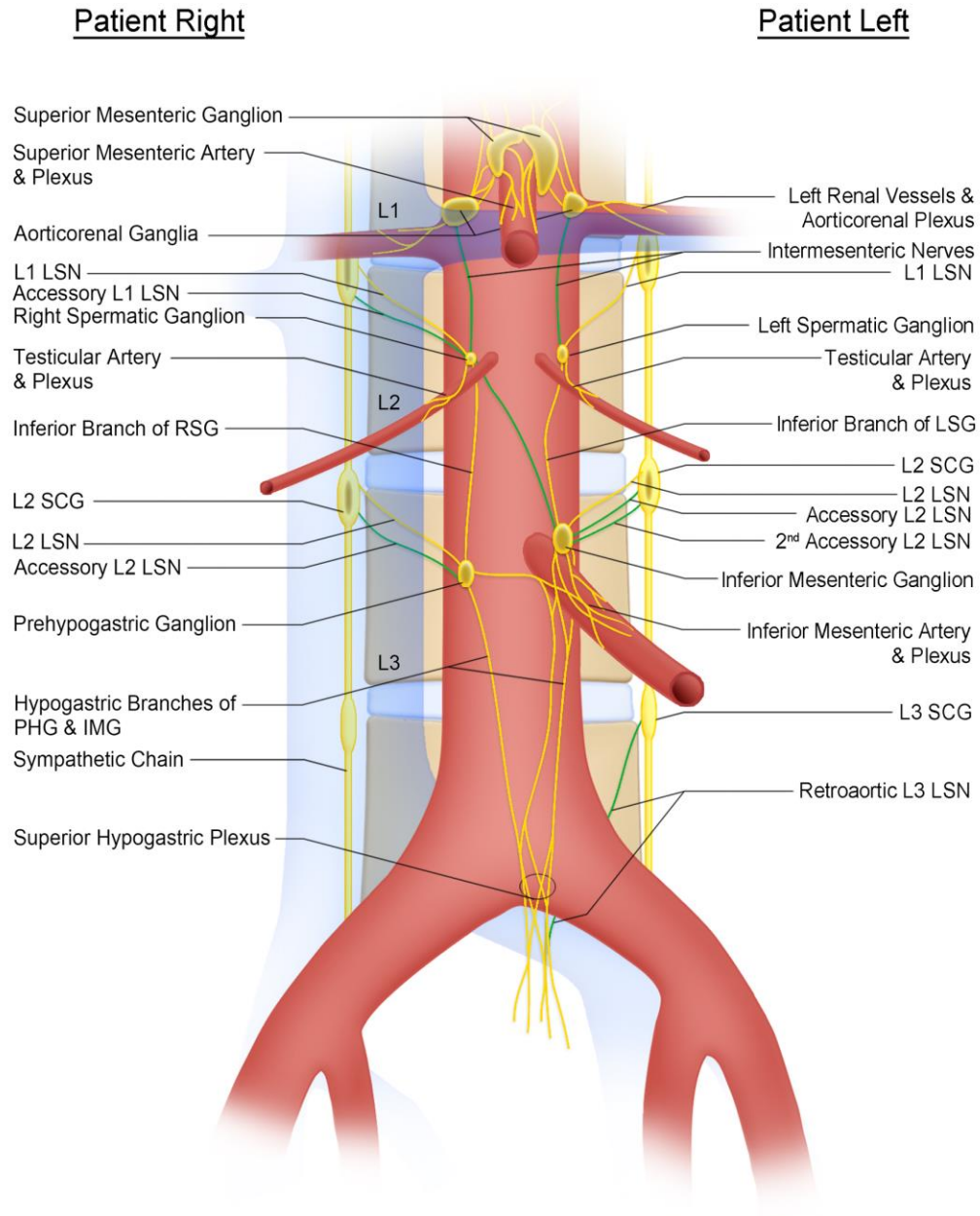


Figure 5. Anatomy of the aortic plexus.

A comprehensive illustration which summarizes the results of the anatomical dissections and histological analyses. Nerves and ganglia coloured yellow were present in all dissections, whereas nerves coloured green were present in a subset of specimens. IMG, inferior mesenteric ganglion; LSG, left spermatic ganglion; LSN, lumbar splanchnic nerve; PHG, prehypogastric ganglion; RSG, right spermatic ganglion; SCG, sympathetic chain ganglion.

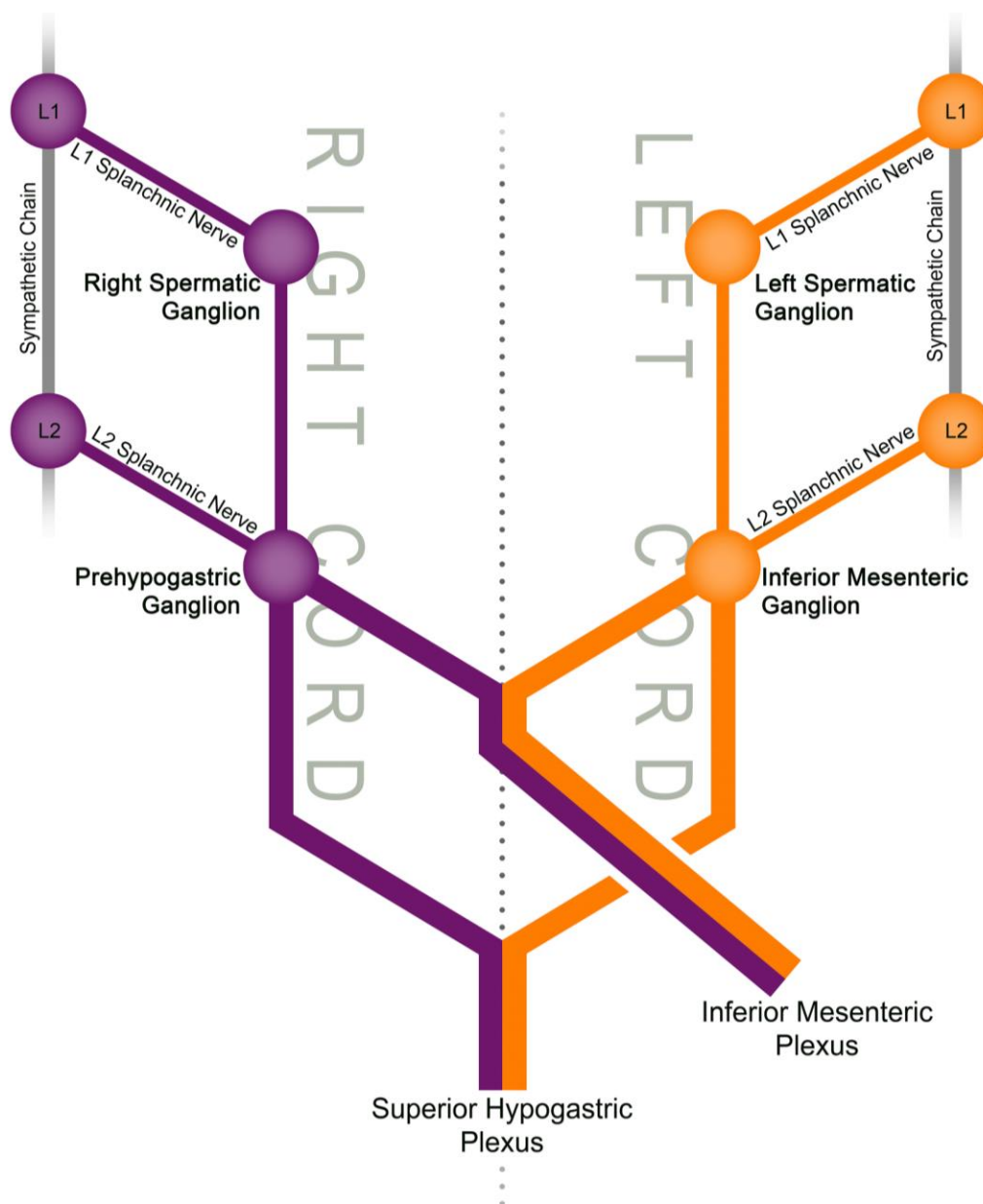


Figure 6. The aortic plexus is bilaterally organized.

A schematic representation of the organization of the aortic plexus highlighting its bilateral symmetry about the aorta (represented by the dotted line). Both the right and left L1 lumbar splanchnic nerves supply the respective spermatic ganglia, whereas the L2 lumbar splanchnic nerves supply the prehypogastric and inferior mesenteric ganglia before branching to the inferior mesenteric plexus or superior hypogastric plexus.

2.4.1. Dissections

2.4.1.1. Aortic Plexus – Left Side

Figure 7 depicts a typical view of the left side of the aortic plexus. In all specimens, the left cord was supplied by the left L1 and L2 LSN extending from the left L1 and L2 sympathetic chain ganglia, respectively. Accessory LSNs were not seen accompanying the left L1 LSN; however, they were commonly (observed in 6/7 specimens) associated with the left L2 LSN. Interestingly, two of these specimens exhibited a second accessory L2 LSN, bringing the total number of L2 LSNs to three. The L3 LSN did not travel anterior to the aorta or contribute to the aortic plexus. In the six specimens in which an L3 LSN was observed, it took a retroaortic course, supplying the superior hypogastric plexus directly. This retroaortic left L3 LSN travelled between the left common iliac artery and vein, and joined the posterior side of the superior hypogastric plexus at approximately the level of the sacral promontory.

The left L1 and L2 LSN directly supplied the left spermatic ganglion (LSG) and the inferior mesenteric ganglion (IMG), respectively. The IMG was found in all seven specimens lateral to the origin of the inferior mesenteric artery and was identified by its darker colour among the nerves of the inferior mesenteric plexus. It should be noted that in two specimens, an accessory IMG was found on the caval side of the inferior mesenteric plexus. The LSG was consistently found in close proximity to the left testicular artery. The LSG was identified in an equal number of specimens overlying the testicular artery as it was being positioned just inferior to it (3/7 for each). In the last specimen (1/7), the LSG was located superior to the left testicular artery. Motoc et al. (2010) described the LSG as being supplied by both the L1 splanchnic nerve and the intermesenteric branch from the aorticorenal/superior mesenteric ganglia, but we observed a lack of intermesenteric supply to the LSG in two specimens. Consistent with Motoc et al. (2010), the LSG was always supplied by the left L1 LSN and was positively identified by its external branches to the spermatic plexus overlying the left testicular artery. The LSG also had an inferior branch that connected to the IMG, as well as intraperitoneal connections to the inferior mesenteric plexus, bypassing the IMG, in four specimens. Figure 7 also shows an example of intraperitoneal branches apparently

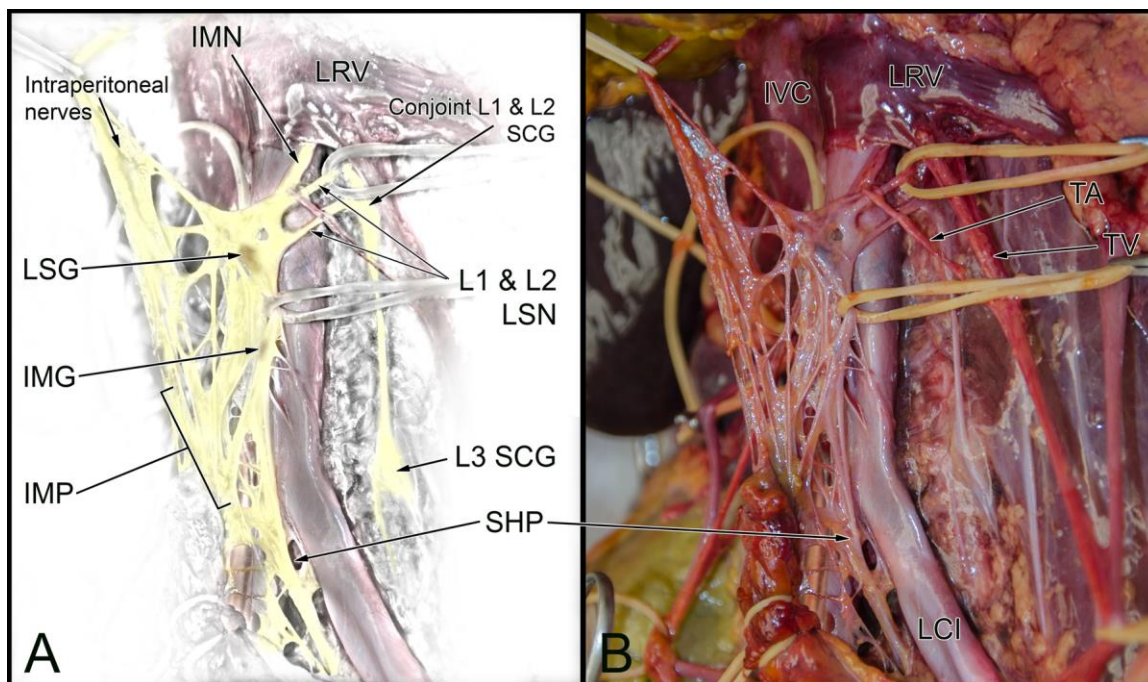


Figure 7. Typical left side of the aortic plexus.

An illustrative representation (A) and photograph (B) of a typical view of the left side of the aortic plexus. The characteristic dark spot can be seen within the left spermatic ganglion (LSG) and the inferior mesenteric ganglion (IMG), later confirmed with histology to contain neuron cell bodies. Note the distinction between intraperitoneal nerves of the mesenteric plexus destined for the enteric plexus of the hindgut (being pulled away by a vessel loop), and the intermesenteric nerves (IMN) running posterior to the left renal vein (LRV) to connect the LSG and the superior mesenteric ganglion (not shown). IMP, inferior mesenteric plexus; LCI, left common iliac artery; LSN, lumbar splanchnic nerve; SCG, sympathetic chain ganglion; SHP, superior hypogastric plexus; TA, testicular artery; TV, testicular vein.

travelling superior towards the hindgut, which are distinct from the intermesenteric nerves coming from the superior mesenteric ganglion to supply the spermatic ganglion. It should be noted that in this photograph, the intraperitoneal nerves are not in anatomical position, as the hindgut had been reflected onto the cadaver's precordium during dissection, thus pulling the intraperitoneal branches of the inferior mesenteric plexus superiorly and out of anatomical position.

2.4.1.2. Aortic Plexus – Right Side

The right side of the aortic plexus was found to have a similar organization to the left side (Figure 8). The right cord was supplied by the right L1 and L2 LSN. Accessory LSNs were seen accompanying the right L1 and L2 LSN in two specimens. Also, similar to the left side, L3 LSNs were never observed supplying the aortic plexus. In fact, no right L3 LSNs were observed within the dissection limits of this study as they were presumably located inferior to the bifurcation of the common iliac arteries. The right L1 LSN consistently supplied the right spermatic ganglia (RSG). The RSG was positively identified by its characteristic branches to the spermatic plexus overlying the right testicular artery (Motoc et al., 2010). The RSG was usually observed overlying the origin of the right testicular artery (4/7) but was alternatively found positioned both superior (2/7) and inferior (1/7) to the artery in other specimens. Similar to the LSG, the RSG was inconsistently supplied by the intermesenteric nerves from the aorticorenal and superior mesenteric ganglia; an intermesenteric supply to the RSG was observed in four specimens.

In addition to the external branches to the spermatic plexus, the RSG branched to the inferior mesenteric plexus (5/7 specimens) as well as inferiorly (termed the inferior branch of the RSG, as described by Motoc et al. 2010) towards the superior hypogastric plexus (7/7 of specimens). More specifically, the inferior branch of the RSG was observed to consistently supply a previously unnamed ganglion within the right cord of the aortic plexus before contributing to the superior hypogastric plexus. Because of the lack of association of this ganglion to an arterial branch of the aorta (as the other ganglia of the aortic plexus are classically named), we elected to name it the prehypogastric ganglion due to its major branch and relative position to the superior hypogastric plexus.

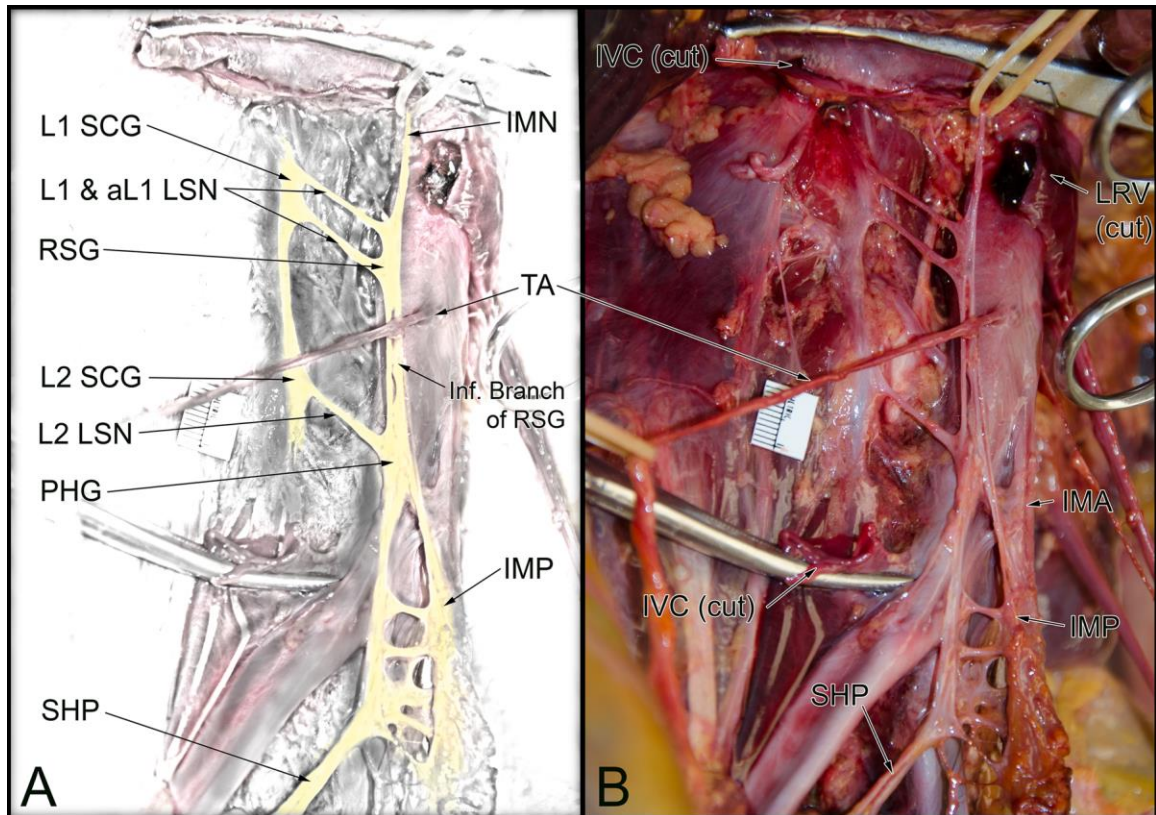


Figure 8. Typical right side of the aortic plexus.

An illustrative representation (A) and photograph (B) of a typical right cord of the aortic plexus. The inferior vena cava (IVC) has been removed during dissection to view the right sympathetic chain ganglia (SCG) and their connections to the right cord of the aortic plexus. This particular specimen exhibited an accessory L1 lumbar splanchnic nerve (aL1 LSN) in addition to the normal anatomy. IMA, inferior mesenteric artery; IMN, intermesenteric nerve; IMP, inferior mesenteric plexus; IVC, inferior vena cava; LSN, lumbar splanchnic nerve; PHG, prehypogastric ganglion; RSG, right spermatic ganglion; SHP, superior hypogastric plexus; TA, testicular artery.

The prehypogastric ganglion was present in all seven specimens and was consistently located inferior to the RSG, between the aorta and inferior vena cava around the level of the inferior mesenteric artery. The specific position of the prehypogastric ganglion varied slightly between specimens; however, given it was not closely associated with arterial branches of the aorta like the other ganglia of the aortic plexus, precise positional differences were not determined. Due to the lack of a vascular landmark, the position of the prehypogastric ganglion was best determined by identifying the nerves connected distally and proximally to it, as described below. The prehypogastric ganglion typically had an elongated shape with a dark centre measuring between 1 and 6 mm in length. Superiorly, it was supplied by the inferior branch of the right spermatic ganglion, and posteriorly, it was supplied by the right L2 LSN coming from the right L2 sympathetic chain ganglion. The prehypogastric ganglion extended branches to the left, supplying the inferior mesenteric plexus, as well as directly inferior, to constitute the major nerve branch (and right-sided contribution) to the superior hypogastric plexus. These branches were observed in all seven specimens and no variations were seen. Figure 9 is a typical photograph of the prehypogastric ganglion in situ, demonstrating the darkened central portion of ganglionic tissue.

2.4.2. Histology

We consistently identified four distinct ganglia during the dissection of the aortic plexus. All ganglia from a subset of cadavers ($n = 4$) underwent microscopic analysis. This revealed tissue similar to the positive control, which exhibited neuronal cell bodies consistent with the typical descriptions of sympathetic ganglia found in the literature (Ovalle & Nahirney, 2008; Young et al., 2014). Figure 10 illustrates the complete histological analysis of all four ganglia from one of the four specimens. This microscopic finding supports the dissection results, indicating that the aortic plexus consists of four distinct ganglia: the left and right spermatic ganglia, inferior mesenteric ganglion, and a prehypogastric ganglion.

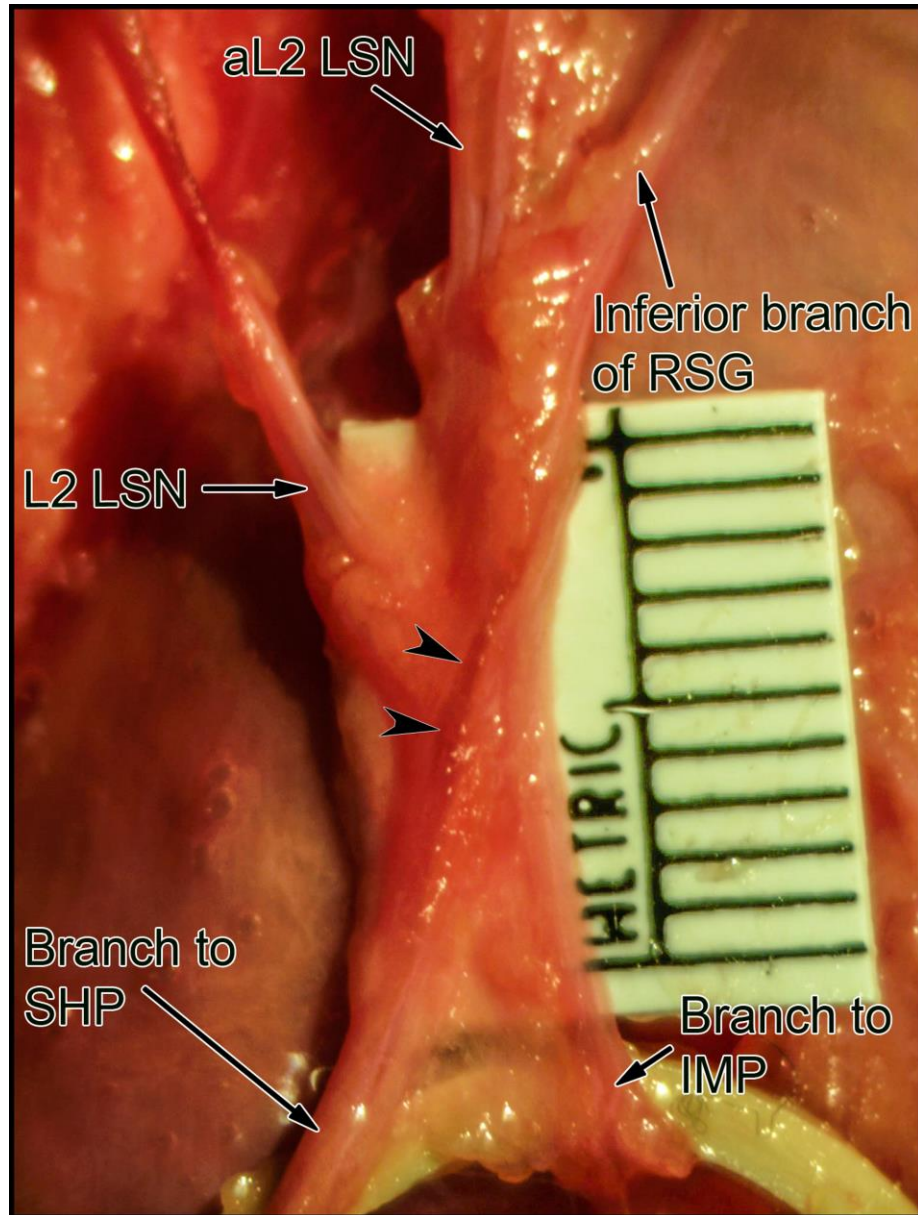


Figure 9. The prehypogastric ganglion.

A high magnification photograph of the prehypogastric ganglion. Note the dark centre indicated by the arrowheads, which was shown with histology to contain the highest concentration of neuron cell bodies. The prehypogastric ganglion in this specimen is supplied by two right L2 lumbar splanchnic nerves (LSN), as well as the inferior branch of the right spermatic ganglion (RSG). The prehypogastric ganglion has consistent branches to the superior hypogastric plexus (SHP), and the inferior mesenteric plexus (IMP). aL2 LSN accessory L2, lumbar splanchnic nerve.

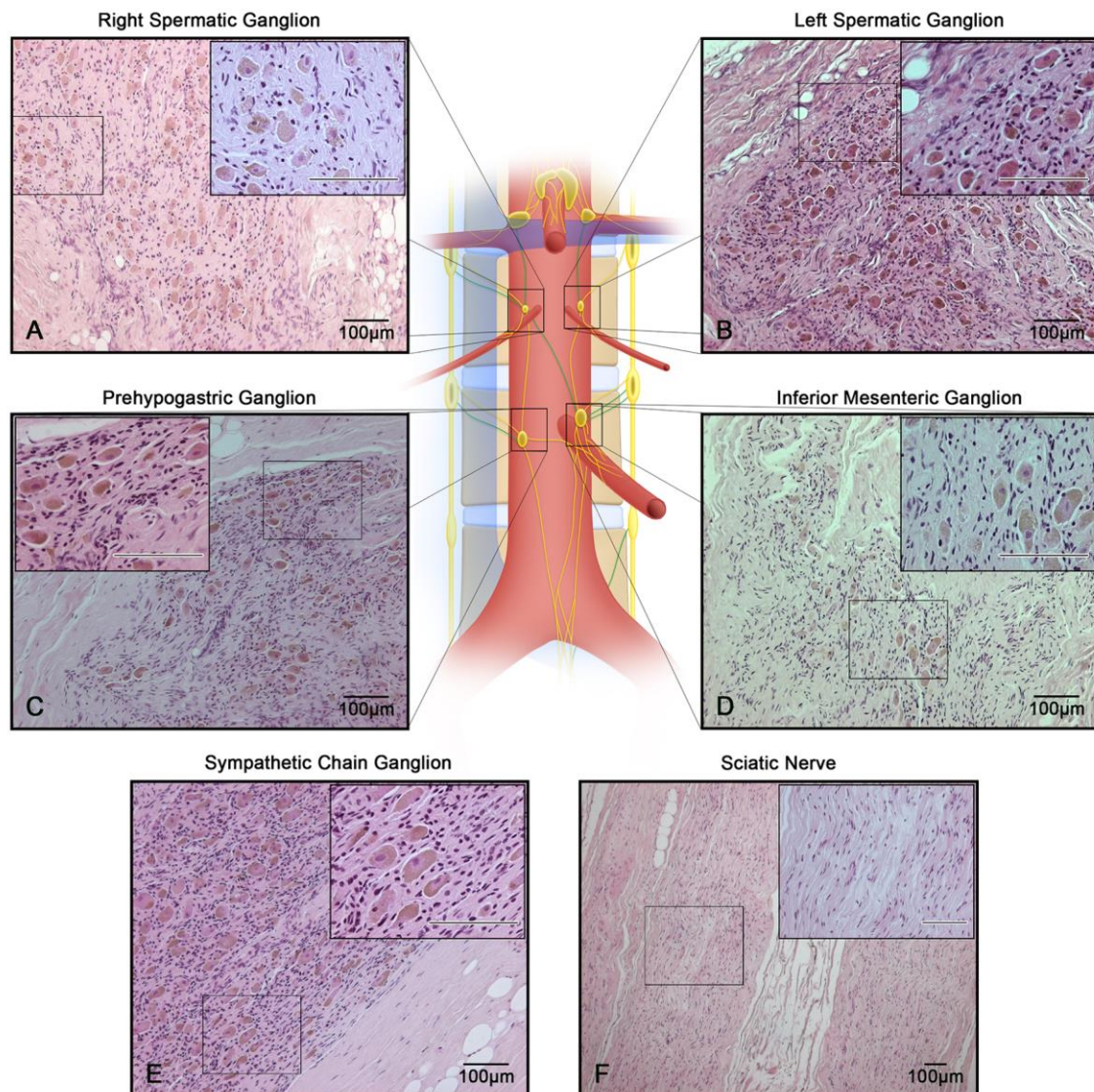


Figure 10. Histology confirms the presence of neurons in the constituent ganglia of the aortic plexus.

Haematoxylin-eosin (H&E) staining of all four ganglia of the aortic plexus from a common specimen, compared with known positive and negative ganglionic tissue. The presence of neuron cell bodies in all four samples (A-D) indicates the plexus is composed of four distinct ganglia. (A) Right spermatic ganglion. (B) Left spermatic ganglion. (C) Prehypogastric ganglion. (D) Inferior mesenteric ganglion. (E) Positive tissue, lumbar sympathetic chain ganglion. (F) Negative tissue, sciatic nerve.

Immunohistochemical analysis was completed on the prehypogastric ganglia to verify it as a sympathetic ganglion of the aortic plexus. Only prehypogastric ganglia from cadavers dissected within 2 months post-mortem were included during the immunohistochemical analysis. Cadavers dissected later than 2 months post-mortem were excluded because positive controls from these specimens returned false-negative results due to poor antigen preservation post-mortem. It appears that autolysis of the tissues and destruction of the antigen had occurred in these specimens, perhaps due to multiple thaw-refreeze cycles prior to dissection. Thus, three of the seven specimens were included in the immunohistochemical characterization of the prehypogastric ganglion. In all three specimens, the prehypogastric ganglion was found to be immunopositive for tyrosine hydroxylase, indicating the neurons were catecholaminergic and thus sympathetic in nature (Amino et al., 2005; Motoc et al., 2010). The results of microscopic analysis of the prehypogastric ganglion are shown in Figure 11.

2.5 Discussion

The present study has provided the first complete gross anatomical and microscopic description of the aortic plexus in fresh, frozen male cadavers. The aortic plexus was supplied by the L1 and L2 splanchnic nerves and intermesenteric nerves from the aorticorenal/superior mesenteric ganglia, and made significant contributions to the inferior mesenteric plexus, spermatic plexuses and superior hypogastric plexus. Moreover, the aortic plexus was organized into two longitudinal cords, which coursed in parallel until they converged to continue into the pelvis as the superior hypogastric plexus. In all specimens, four distinct ganglia were identified that were located within the two cords, near the intersection of the lumbar splanchnic nerves. Within the left cord, the left spermatic ganglion and the well-described inferior mesenteric ganglion were observed. Located within the right cord were the right spermatic ganglion and a previously unnamed ganglion, which we have called the prehypogastric ganglion.

The prehypogastric ganglion, supplied by the right L2 lumbar splanchnic nerve, was consistently observed to reside in the inferior portion of the right cord, at a similar level to the inferior mesenteric ganglion. To our knowledge, this structure has never been discussed in the literature or labelled in any previous diagrams of the aortic plexus. That

said, it is possible that the prehypogastric ganglion is depicted as an unnamed ‘swelling’ in an illustration of the aortic plexus found in a textbook by O’Rahilly (1986). However, it is difficult to be certain whether this ‘swelling’ depicts the prehypogastric ganglion because several aspects of this drawing fail to match key anatomical features of the aortic plexus found in the present study and described in the literature (e.g. presence of the left- and right spermatic ganglia, and left-sided lumbar splanchnic nerves supplying the aortic plexus) (Dwight et al., 1930; Motoc et al., 2010). Ultimately, the present study has provided the first characterization of this ganglion by way of both photographic documentation (Figure 8) and histological verification of its sympathetic nature (Figure 11).

Before deciding on the nomenclature for the prehypogastric ganglion (see Results section Dissections, Aortic Plexus - Right Side), we first considered the possibility that it was a secondary (accessory) inferior mesenteric ganglion, as this would be akin to the anatomy of the coeliac ganglia (Dwight et al., 1930; O’Rahilly, 1986; Drake et al., 2010). Anatomical textbooks have characterized the inferior mesenteric ganglion as a structure residing distal to the origin of the inferior mesenteric artery, which is embedded within the nerves of the inferior mesenteric plexus itself, and provides an important relay for nerves travelling along the inferior mesenteric artery to supply the hindgut (Dwight et al., 1930; O’Rahilly, 1986). In contrast to this description, the prehypogastric ganglion (i) was not closely associated with the origin of the inferior mesenteric artery, (ii) was distinct from the dense inferior mesenteric plexus extending along the inferior mesenteric artery to supply the hindgut, and (iii) instead resided on the right side of the aorta with seemingly more significant contributions extending towards the superior hypogastric plexus to the pelvis. Furthermore, in two specimens, we observed and histologically verified the presence of a secondary (accessory) inferior mesenteric ganglion embedded in the caval aspect of the inferior mesenteric plexus that was in addition to the distinct prehypogastric ganglion – findings which further support our contention that the prehypogastric ganglion should not be categorized as a secondary inferior mesenteric ganglion.

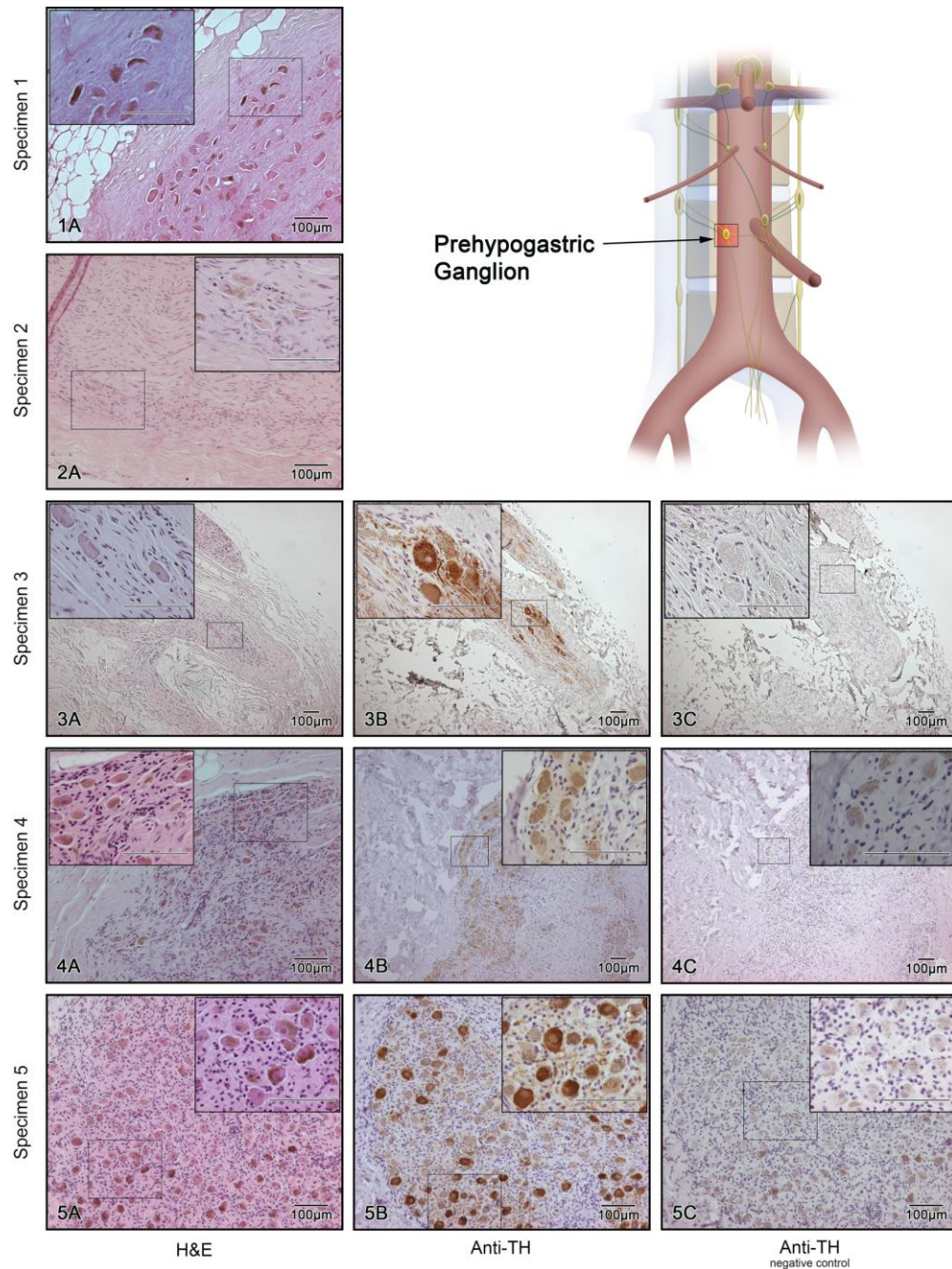


Figure 11. Tyrosine hydroxylase confirms the adrenergic nature of the ganglia.

Histological staining of the prehypogastric ganglion collected from five specimens (1–5). Column A represents haematoxylin-eosin (H&E) staining. Column B represents staining with anti-tyrosine hydroxylase antibody (anti-TH). Column C is the negative control for Column B which followed identical immunohistochemical procedures, except for the application of the primary antibody, anti-TH.

In acknowledging the prehypogastric ganglion as a distinct structure of the aortic plexus, it is reasonable to suggest that it may be the right-sided developmental equivalent of the inferior mesenteric ganglion. In support of this suggestion, both the inferior mesenteric ganglion (left-sided) and the prehypogastric ganglion (right-sided) are supplied by the respective inferior spermatic branches of the spermatic ganglia as well as the L2 lumbar splanchnic nerves (Figure 5 and Figure 6). Furthermore, histological analysis confirmed that the prehypogastric ganglion, like the inferior mesenteric ganglion, is sympathetic in nature, as shown by positive anti-TH staining (Figure 11), and has comparable microscopic structure (Figure 10). Finally, both ganglia seem to contribute to the inferior mesenteric plexus and the superior hypogastric plexus (Figure 7 and Figure 8), further supporting the suggestion that these two ganglia are bilateral, embryologic equivalents of each other.

As schematized in Figure 6, the overall neural organization of the aortic plexus seems to exhibit bilateral symmetry in its organization of ganglia and nerves; findings which are contrary to its classical characterization as a highly convoluted network of nerves. The idea of bilateral symmetry is consistent with our current knowledge of the preganglionic peripheral sympathetic system as a whole. Examples of such symmetry include the presence of bilateral sympathetic chains extending from the cranium to the ganglion impar at the base of the sacrum, as well as the presence of symmetrically paired splanchnic nerves and their respective ganglia throughout the thoracolumbar region. It is hypothesized the symmetrical organization of the peripheral sympathetic system is largely influenced by a bilateral migration of neuroblast cells from the neural crest after the 5th week of development (Sadler, 2010; Takahashi et al., 2013).

It is worth noting that there are likely significant clinical implications in failing to appreciate that the aortic plexus is derived of bilaterally symmetrical cords, and that significant nerves, as well as the newly characterized prehypogastric ganglion, exist within the right cord on the caval side of the aorta. In fact, an incomplete understanding of the organization of the aortic plexus and its extensions into the pelvis may have predisposed these fine structures to the unintended damage during abdominal surgeries, such as retroperitoneal lymph node dissections for testicular cancer (Jewett & Groll,

2007; Heidenreich & Pfister, 2012; Hsiao et al., 2012), anterior approach lumbar fusion surgeries (Lu et al., 2009) and abdominal aortic aneurysm replacements (Veroux et al., 2010). This unintended trauma could have widespread complications as the sympathetic nerves within the aortic plexus ultimately serve the spermatic plexus to the male gonads (Motoc et al., 2010), the inferior mesenteric plexus to the hindgut, and the superior hypogastric plexus to the pelvic urogenital viscera (Jänig & McLachlan, 1987; Giuliano & Clément, 2005). Given the apparent contribution of the prehypogastric ganglion to the superior hypogastric plexus (Figure 5 and Figure 8), and potential risk of damage due to its position distinct from any aortic branches, we hypothesize that this ganglion may be a significant structure in the neural path resulting in anejaculation if damaged (Jänig & McLachlan, 1987; Giuliano & Clément, 2005; Heidenreich & Pfister, 2012; Hsiao et al., 2012; Wein, 2012).

In summary, through dissection of fresh, frozen human cadavers, the present study has provided the first complete mapping of the nerves and ganglia of the aortic plexus. All specimens exhibited a bilaterally symmetrical arrangement of four distinct sympathetic ganglia within the aortic plexus: the right and left spermatic ganglia, the inferior mesenteric ganglion and one previously unidentified ganglion, which has been named the prehypogastric ganglion. Because our examination revealed the aortic plexus has the potential for variation, primarily in the possibility of exhibiting accessory splanchnic nerves, a follow-up study with a larger sample size should be completed to determine accurately the extent of its variability. Furthermore, future directions of this research should also include a comprehensive functional investigation of each nerve of the plexus, with descriptions of the spinal contributions and visceral supply. Clinically, this information may help identify the nerves of the aortic plexus responsible for significant post-operative morbidities, such as anejaculation, following retroperitoneal surgeries.

2.6 Acknowledgements

The authors would like to thank: the supervisors of the HAASE anatomy lab at Western University, Haley Linklater and Kevin Walker for their help with the cadaveric dissections, Linda Jackson from the Department of Pathology for her technical expertise in histology, and Dr. Nagalingam Rajakumar for his contributions to the immunohistochemistry. The authors have no conflict of interest with the content of the manuscript.

2.7 Author Contributions

N.P.: study conception. All authors: study design. T.S.B.: data acquisition and analysis; illustrations. T.S.B. and B.L.A.: data interpretation and writing and critical revision of the manuscript. All authors contributed to the final version of manuscript and approved its content.

2.8 References

- 1) Amino T, Orimo S, Itoh Y, Takahashi A, Uchihara T, Mizusawa H (2005). Profound cardiac sympathetic denervation occurs in Parkinson disease. *Brain Pathology*, 15(1), 29–34.
- 2) Baron R, Jänig W, McLachlan EM (1985). The afferent and sympathetic components of the lumbar spinal outflow to the colon and pelvic organs in the cat. I. The hypogastric nerve. *The Journal of Comparative Neurology*, 238(2), 135–46.
- 3) Dako (2013). Part 1: The Staining Process. In C. Taylor & L. Rudbeck (Eds.), *Immunohistochemical Staining Methods* (6th ed., pp. 20–93). Denmark: Dako Denmark.
- 4) Drake R, Vogl W, Mitchell A (2010). Abdomen. In W. Schmitt & R. Gruliow (Eds.), *Gray's Anatomy for Students* (2nd ed., pp. 343–345). Philadelphia PA: Churchill Livingstone Elsevier.
- 5) Dwight T, McMurrich J, Hamann C (1930). The Sympathetic System of Nerves. In G. Peirsol (Ed.), *Human Anatomy* (9th ed., pp. 1366–1374). London: J.B. Lippincott Company.
- 6) Giuliano F, Clément P (2005). Physiology of ejaculation: Emphasis on serotonergic control. *European Urology*, 48(3), 408–417.
- 7) Gray H (2010). The Nervous System, The Sympathetic Nervous System. In T. Pick & R. Howden (Eds.), *Gray's Anatomy* (15th ed., pp. 779–791). New York, NY: Barnes & Noble.
- 8) Heidenreich A, Pfister D (2012). Retroperitoneal lymphadenectomy and resection for testicular cancer: an update on best practice. *Therapeutic Advances in Urology*, 4(4), 187–205.
- 9) Hollinshead WH (1974). *Textbook of Anatomy* (3rd ed.). Hagerstown, MD: Harper & Row, Publishers.
- 10) Hsiao W, Deveci S, Mulhall JP (2012). Outcomes of the management of post-chemotherapy retroperitoneal lymph node dissection-associated anejaculation. *BJU International*, 110(8), 1196–1200.
- 11) Jänig W, McLachlan EM (1987). Organization of lumbar spinal outflow to distal colon and pelvic organs. *Physiological Reviews*, 67(4), 1332–404.
- 12) Jewett MA, Groll RJ (2007). Nerve-Sparing Retroperitoneal Lymphadenectomy. *Urologic Clinics of North America*, 34(2), 149–158.
- 13) Kiernan JA (1990). *Histological & Histochemical Methods: Theory and Practice* (2nd ed.). New York: Pergamon Press.

- 14) Loukas M, Klaassen Z, Merbs W, Tubbs RS, Gielecki J, Zurada A (2010). A review of the thoracic splanchnic nerves and celiac ganglia. *Clinical Anatomy*, 23(5), 512–522.
- 15) Lu S, Xu Y, Chang S, Zhang Y, Shi J, Ding ZH, ... Zhong S (2009). Clinical anatomy study of autonomic nerve with respect to the anterior approach lumbar surgery. *Surgical and Radiologic Anatomy*, 31(6), 425–430.
- 16) Mirilas P, Skandalakis J (2010). Surgical Anatomy of the Retroperitoneal Spaces, Part IV: Retroperitoneal Nerves. *The American Surgeon*, 76(3), 253–262.
- 17) Moore K, Dalley A, Agur A (2014). Abdomen. In C. Taylor (Ed.), *Clinical Oriented Anatomy* (7th ed., p. 304). Philadelphia PA: Lippincott Williams & Wilkins.
- 18) Motoc A, Rusu MC, Jianu AM (2010). The spermatic ganglion in humans: An anatomical update. *Romanian Journal of Morphology and Embryology*, 51(4), 719–723.
- 19) Netter F (2011). Back and Spinal Cord, Abdomen, Pelvis and Perineum. In J. Hansen (Ed.), *Atlas of Human Anatomy* (5th ed., Plates 160, 297, 319, 389, 390). Philadelphia PA: Saunders Elsevier.
- 20) O’Rahilly R (1986). The Abdomen. In A. Meier (Ed.), *Anatomy: A Regional Study of Human Structure* (5th ed., pp. 433–436). Philadelphia PA: W.B. Saunders Company.
- 21) Ovalle W, Nahirney P (2008). Nervous Tissue. In E. O’Grady & M. Thiel (Eds.), *Netter’s Essential Histology* (pp. 128–129). Philadelphia: Saunders Elsevier.
- 22) Rusu MC (2009). Accessory lumbar splanchnic ganglia in humans: A case report. *Anatomical Science International*, 84(3), 253–256.
- 23) Sadler T (2010). Autonomic Nervous System. In C. Taylor, K. Horvath, & B. Martz (Eds.), *Langman’s Medical Embryology* (11th ed., pp. 319–322). Baltimore, MD: Lippincott Williams & Wilkins.
- 24) Spalteholz W, Spanner R (1967). The Nervous System. In *Atlas of Human Anatomy* (16th ed., pp. 816–817). Philadelphia PA: F.A. Davis Company.
- 25) Takahashi Y, Sipp D, Enomoto H (2013). Tissue interactions in neural crest cell development and disease. *Science*, 341(6148), 860–3.
- 26) Vector Laboratories (2010). ImmPRESS reagent anti-mouse IG peroxidase cat. no. MP-7402. Retrieved February 20, 2014, from <http://www.vectorlabs.com/data/%0Aprotocols/MP-7402.pdf>
- 27) Vector Laboratories (2013). DAB peroxidase substrate cat. no. SK-4100. Retrieved February 20, 2014, from <http://www.vectorlabs.com/data/protocols/SK-4100.pdf>

- 28) Veroux P, D'Arrigo G, Veroux M, Giaquinta A, Lomeo A (2010). Sexual dysfunction after elective endovascular or hand-assisted laparoscopic abdominal aneurysm repair. *European Journal of Vascular and Endovascular Surgery*, 40(1), 71–75.
- 29) Wein A (2012). Male Genitalia. In L. Kavoussi, A. Novick, A. Partin, & C. Peters (Eds.), *Campbell-Walsh Urology* (10th ed., pp. 874–876). Philadelphia PA: Saunders Elsevier.
- 30) Young B, O'Dowd G, Woodford P (2014). Nervous Tissue. In H. A (Ed.), *Wheater's Functional Histology: A Text and Colour Atlas* (6th ed., p. 139). Philadelphia: Churchill Livingstone Elsevier.

CHAPTER 3

HISTOLOGICAL VERIFICATION OF THE PREHYPOGASTRIC AND OVARIAN GANGLIA CONFIRMS A BILATERALLY SYMMETRICAL ORGANIZATION OF THE GANGLIA COMPRISING THE AORTIC PLEXUS IN FEMALE HUMAN CADAVERS

In characterizing the prehypogastric ganglion, we revealed that the organization of the aortic plexus in males is bilaterally arranged – findings that contrast its classical portrayal as a variable, convoluted network of nerves. In the present chapter, we investigate if homologous ganglia and, ultimately, a structural conservation exists in the female aortic plexus. The content of this chapter is published in the *Journal of Anatomy*, Volume 228, Issue 5, Pages 805-811. Histological protocols used in the following study are listed in Appendix A (H&E) and Appendix B (IHC). Supplemental images referenced in this manuscript are contained in Appendix C.

3.1 Abstract

The aortic plexus is a network of sympathetic nerves positioned along the infrarenal abdominal aorta. Recently, we characterized the aortic plexus and its ganglia (inferior mesenteric, left/right spermatic, and prehypogastric ganglion) in males; however, the literature minimally describes its anatomy in females. In the present study, we conducted the first histological examination of the left and right ovarian ganglia, while also investigating whether females, like males, exhibit a prehypogastric ganglion. The ganglia were dissected from embalmed (n = 32) and fresh (n = 1) human cadavers, and H&E staining was used to confirm the presence of a left ovarian ganglion in 31/31 specimens, a right ovarian ganglion in 29/29 specimens and a prehypogastric ganglion in 25/28 specimens. Comparable to the topographic arrangement in males, there is a bilateral organization of the ganglia comprising the aortic plexus in females. More specifically, the left and right ovarian ganglia were positioned in close relation to their respective ovarian artery, whereas the prehypogastric ganglion was positioned within the right cord of the aortic plexus, contralateral to the inferior mesenteric ganglion. Using immunohistochemistry, it was shown that all ganglia from the fresh cadaver stained positive for tyrosine hydroxylase, thereby confirming their sympathetic nature. Having

provided the first topographical and histological characterization of the ovarian and prehypogastric ganglia in females, future studies should seek to determine their specific function.

3.2 Introduction

The aortic plexus is a complex network of sympathetic nerves overlying the infrarenal abdominal aorta containing significant innervation to the hindgut and pelvic organs. In males, disruption of the aortic plexus during retroperitoneal surgery is commonly associated with loss of antegrade ejaculation, and thus fertility (Flynn & Price, 1984; Jewett et al., 1988; Jewett & Groll, 2007; Katz & Eggener, 2009; Veroux et al., 2010; Heidenreich & Pfister, 2012; Hsiao et al., 2012). Although nerve-sparing surgical procedures are currently recommended, the normal anatomy of the aortic plexus and its ganglia have not been described in significant detail. Motivated by this, our group recently published the first detailed anatomical description of the aortic plexus and its ganglia in human males through dissection, followed by a histological examination of fresh frozen cadavers (Beveridge, Johnson, et al., 2015). Importantly, our study characterized the prehypogastric ganglion, a novel structure which we suggested could be the right-sided equivalent of the well-acknowledged inferior mesenteric ganglion. Ultimately, characterization of the prehypogastric ganglion revealed that the topography of the aortic plexus in males is bilaterally symmetrical, organized around the four constituent prevertebral ganglia (left/right spermatic ganglia, prehypogastric ganglion, and inferior mesenteric ganglion) as seen in Figure 12 (Beveridge, Johnson, et al., 2015). These findings contrast the classical characterization of the aortic plexus as a variable, convoluted network of nerves (Kuntz, 1945; Spalteholz & Spanner, 1967; Hollinshead, 1974; Mirilas & Skandalakis, 2010; Netter, 2011).

Because our previous study only examined males, it remains uncertain whether females also exhibit the newly described prehypogastric ganglion. Moreover, although the existence of the inferior mesenteric ganglion in females is well-established (Jänig & McLachlan, 1987; Choi & Novembre, 1999), the current literature does not contain any primary reports of homologous structures to the male spermatic ganglia in humans.

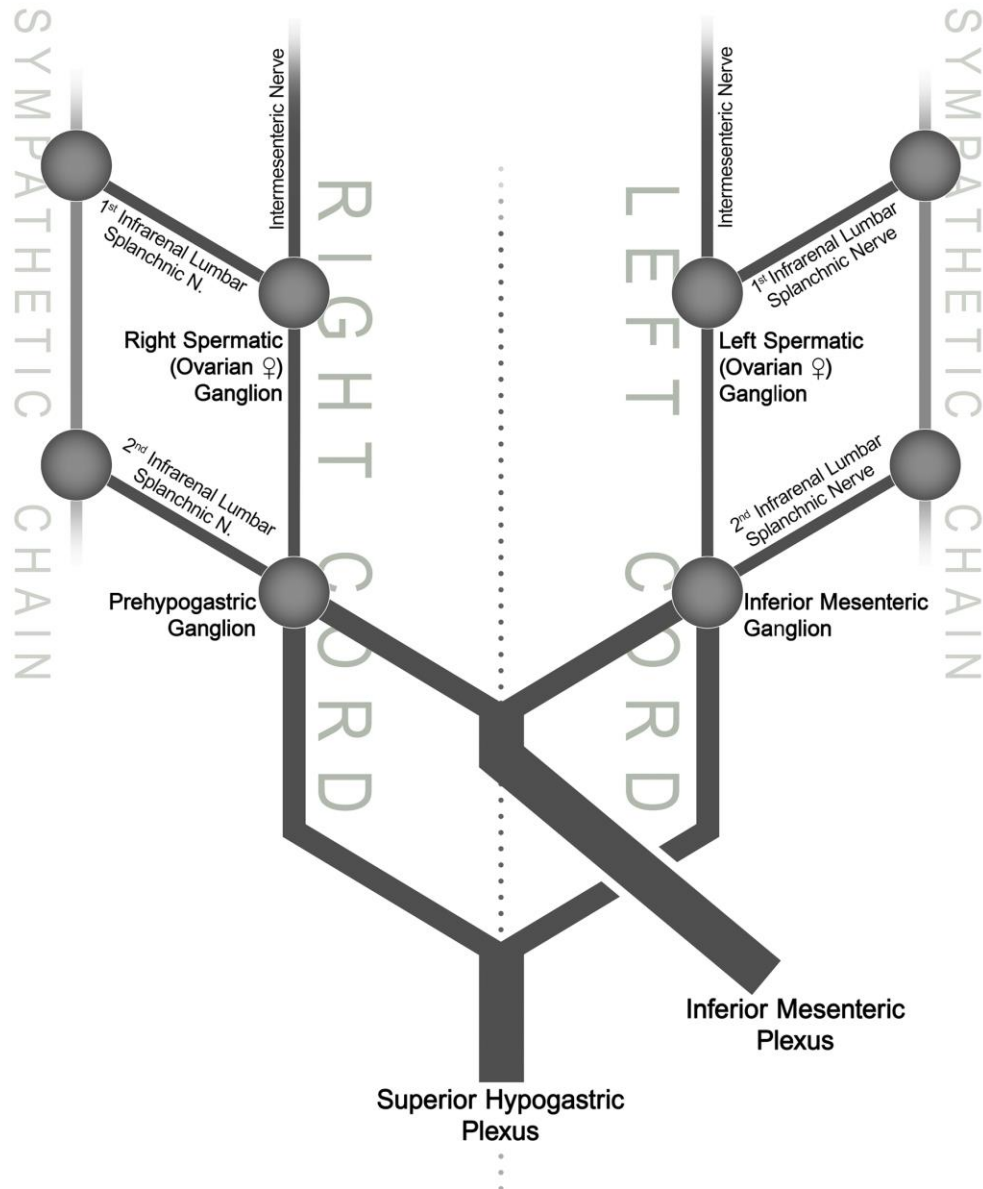


Figure 12. Homologous ganglia in the female aortic plexus confirms bilateral organization in humans.

Adapted from Beveridge et al. (2015), this illustration schematically demonstrates the organization of the human aortic plexus around the four constituent ganglia: the right/left spermatic (ovarian ♀) ganglia, prehypogastric ganglion and the inferior mesenteric ganglion. It is important to note that this bilateral arrangement around the four ganglia of the aortic plexus has only ever been demonstrated in males. This study aims to examine the homologous ganglia, if present, in females.

Although the existence of ovarian ganglia has been alluded to in two classical human anatomy textbooks (Kuntz, 1945; Crosby et al., 1962), to our knowledge the only scientific investigations demonstrating these structures were conducted on pigs, cats and rats (Langley & Anderson, 1896; McNeill & Burden, 1986; Klein & Burden, 1988a, 1988b; Czaja et al., 2001).

Therefore, through gross cadaveric dissection and histological tissue verification, the present study investigated in females the possible existence of: (1) a prehypogastric ganglion as the right-sided equivalent structure to the inferior mesenteric ganglion, and (2) ovarian ganglia as homologous structures to the left and right spermatic ganglia in males. Collectively, these results would confirm whether the aortic plexus in females exhibits a topographical arrangement of ganglia consistent with that of males (Figure 12).

3.3 Materials and Methods

In a population of 33 female cadavers (one fresh frozen, 32 embalmed; mean age = 78.2, SD = 12.5), the structures suspected to be the right ovarian, left ovarian and prehypogastric ganglia were dissected, and then excised for histological verification. Because the abdomen of the embalmed cadavers had been previously dissected by medical students at our institution, we excluded specimens where the complete aortic plexus was grossly over-dissected ($n = 1$) or specific portions of the aortic plexus were damaged, in which case only ganglia from the regions that remained intact were examined ($n = 6$). All cadaveric specimens were acquired and dissected in accordance with the Anatomy Act of Ontario. The ganglia were identified during dissection within the left or right cords of the aortic plexus near the intersections of the infrarenal lumbar splanchnic nerves. Most commonly, the ganglia were identified as focal swellings or regions of nerve containing slightly darker matter, which has been suggested as a marker of neuron cell bodies likely due to the accumulation of lipofuscin (Beveridge, Johnson, et al., 2015). If no obvious ganglion was present, a small portion of tissue was excised from the expected location in case the ganglion was too small to be observed macroscopically.

To verify whether the acquired tissues were ganglia, 5- μ m sections were stained with Hematoxylin and Eosin (H&E) using standard regressive procedures, and then examined

for the presence of neuron cell bodies. If no neuron cell bodies were observed, subsequent serial sections at varying depths were examined throughout the tissue. The specimens obtained from the single fresh, frozen cadaver were additionally used to verify the adrenergic nature of the neurons through staining with anti-tyrosine hydroxylase antibody (anti-TH) following a previously published protocol (Beveridge, Johnson, et al., 2015). Scaled micrographs were taken using a Zeiss AxioCam MRc microscope camera.

3.4 Results

Through dissection and examination of the 32 female cadavers included in this study, 26 had intact aortic plexuses and macroscopic identification of the left ovarian, right ovarian and prehypogastric ganglia was attempted. In the remaining six specimens, partial over-dissection of the aortic plexus was present as a result of medical students' laboratory exercises at our institution. In these six cases, only the area of the aortic plexus which remained intact was examined. Collectively, tissue suspected to be the left ovarian ganglia (n = 31), right ovarian ganglia (n = 29) and prehypogastric ganglia (n = 28) were collected for histological examination with H&E staining to verify whether the obtained specimens truly contained neuron cell bodies and could thus be classified as ganglia.

3.4.1. Topography of the Ganglia

In all of the specimens examined, the ovarian ganglia were located just inferior to the left renal vein, near the origin of the ovarian arteries. They were identified during dissection as the slightly enlarged portion of neural tissue near the junction of the intermesenteric nerve descending from the aorticorenal/superior mesenteric plexuses as it intersected with the first infrarenal lumbar splanchnic nerve. The prehypogastric ganglion was located at approximately the level of the inferior mesenteric artery, within the right cord of the aortic plexus – the same position as described in males. It was most easily identified by landmarking the position of the second infrarenal lumbar splanchnic nerve on the right side as it intersects the right cord of the aortic plexus. Figure 13 illustrates the position of the examined ganglia in situ during the dissection of the fresh cadaver.

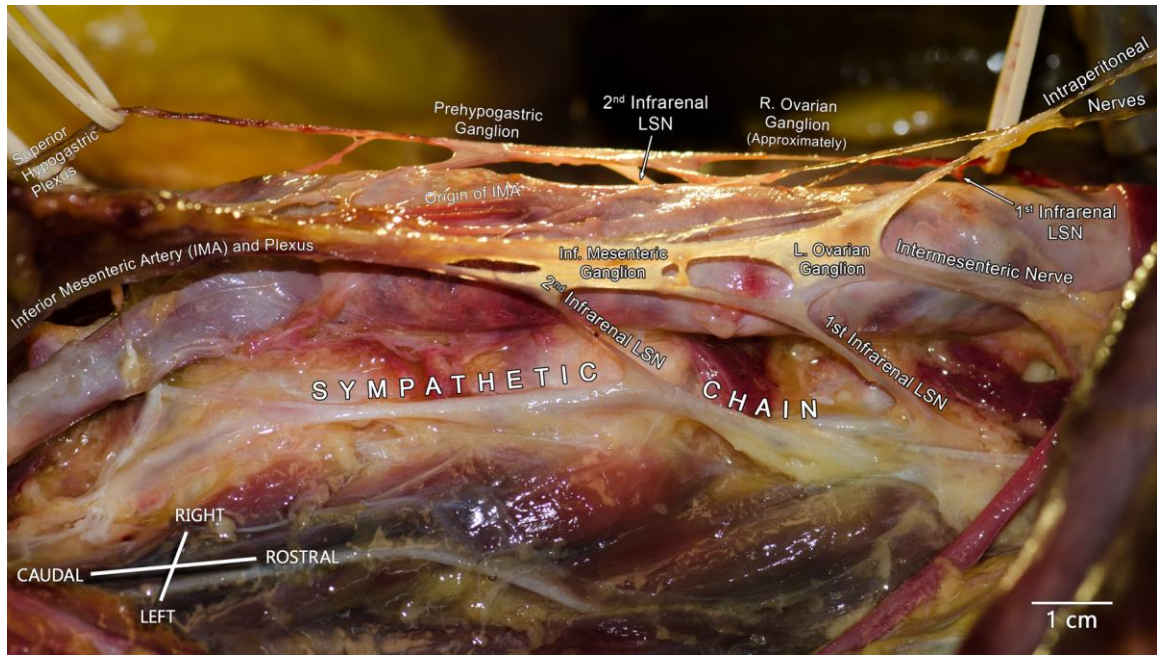


Figure 13. Representative photo of the aortic plexus.

A photograph of the aortic plexus taken from the left side of the body. The left cord of the aortic plexus is featured in the foreground, clearly illustrating the connections of the left ovarian and inferior mesenteric ganglia with that of the first and second infrarenal lumbar splanchnic nerves (LSN) extending from the sympathetic chain. In the background, the right cord of the aortic plexus is visible, with the prehypogastric ganglion identifiable. Given the perspective of the photo, the right ovarian ganglion is not clearly seen, but a label has been placed to illustrate the approximate location of the structure.

3.4.2. Histology of the Ganglia

Abundant collections of neuron cell bodies (not uncommonly amounting to more than 100 neurons per histological section) were observed in all excised ovarian ganglia and 25/28 prehypogastric ganglia. The remaining 3/28 'prehypogastric ganglia' were inconclusive in their histological examinations since they were not completely devoid of neuron cell bodies, yet they contained a notable lack of these cells compared with the other examined tissues. This distinction is shown in Figure 14. Specifically, Figure 14A demonstrates a typical micrograph from a tissue specimen confirmed to be a prehypogastric ganglion by the presence of satellite cells surrounding numerous neuron cell bodies with eccentrically placed nucleoli and abundant cytoplasmic lipofuscin. Alternatively, Figure 14B demonstrates a micrograph of tissue which was not classified as being a prehypogastric ganglion due to the unusually low number of neuron cell bodies.

The three inconclusive samples underwent subsequent sectioning to ensure the actual ganglionic portion of the tissue was not positioned at a different depth. By sectioning two to three slices at four different depths, approximately 40–50 neurons were observed in the first sample (Specimen 24C; Supporting Information Appendix C), whereas a total of nine neurons were counted throughout the second sample (Specimen 21C; Appendix C). In the last sample, sectioning at six different depths revealed a scant three neuron cell bodies in total (Specimen 20C; Appendix C). Limited by the cremation of our specimens shortly after dissection, we were not able to revisit the cadavers to determine whether the low number of neuron cell bodies observed was an indication of (1) identification error during dissection, in that only a small portion of the prehypogastric ganglion was excised and the rest remained in situ, (2) an anatomical variation whereby the prehypogastric ganglion was truly not present in these specimens, but rather a microganglion was excised instead, or (3) some disease or process of aging had occurred, resulting in atrophy of the prehypogastric ganglion, leaving only a small minority of neurons.

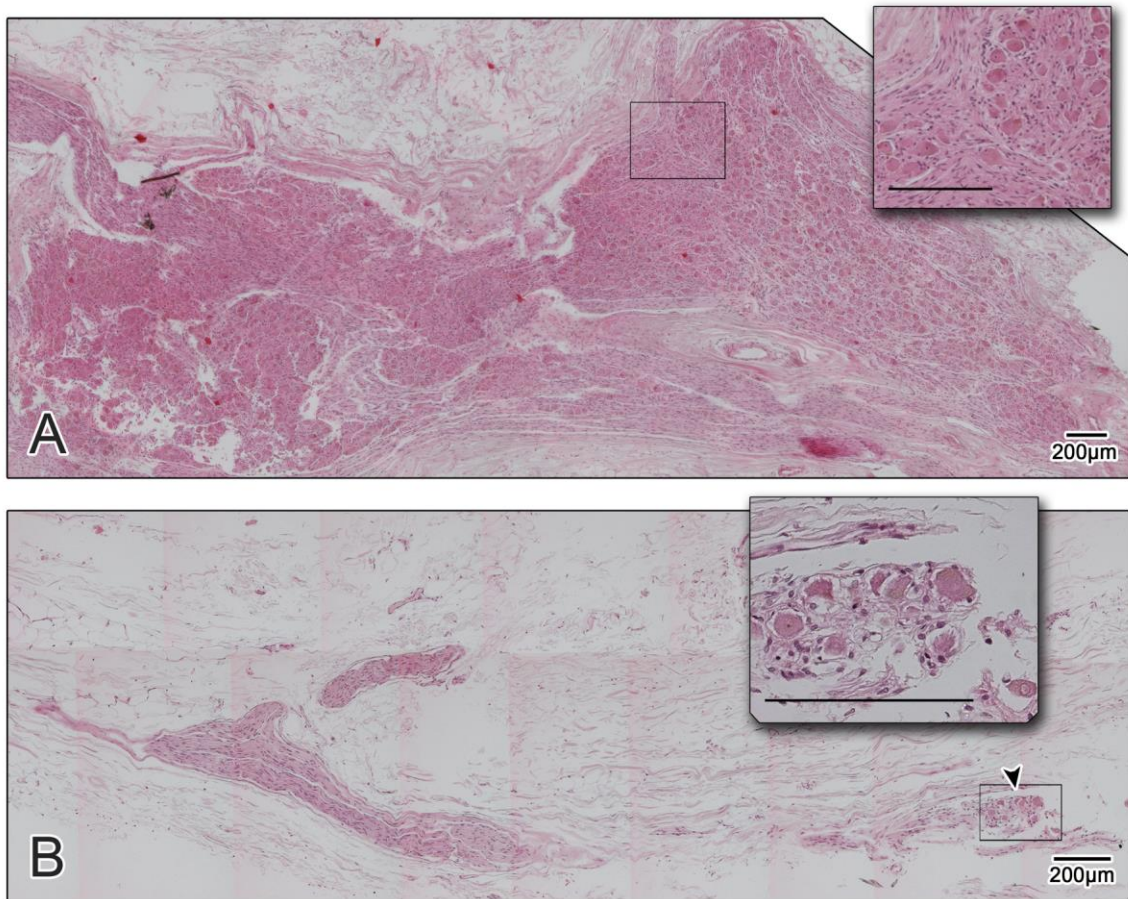


Figure 14. Histology confirms the presence of neurons within the prehypogastric ganglion.

Panel A demonstrates histology from a typical prevertebral ganglion of the aortic plexus. Specifically, this is a photomerge of the prehypogastric ganglion from specimen #14. Panel B demonstrates a photomerge of the tissue thought to be a prehypogastric ganglion at the time of excision (Specimen #21); however, only nine neuron cell bodies were seen in this section clustered at the location indicated by the arrowhead. Neuron cell bodies were not observed in any other examined depths of the tissue.

Given that the ovarian ganglia from these three cadavers appeared normal (see Specimens 20–21 & 24, columns A & B; Appendix C), the third possibility is unlikely. Based on the histology, we suspect that the prehypogastric ganglion was incorrectly excised and only a piece of it was obtained, which explains why only a few neurons were present at the edge of the sectioned tissue. Nevertheless, we must acknowledge that we are not certain of this and the variable presence of the prehypogastric ganglion may still be a possibility.

Therefore, given the drastically smaller number of neuron cell bodies in these three samples, it remains inconclusive whether these cadavers contained a prehypogastric ganglion. A summary of the complete histological examination is shown in Table 2.

Photomicrographs of the ganglia from each specimen are provided in the Appendix C.

In the single fresh, frozen cadaver, subsequent staining on the left ovarian, right ovarian and prehypogastric ganglia were immunopositive for tyrosine hydroxylase, thereby confirming the cells were adrenergic sympathetic neurons (Figure 15).

Immunohistochemical staining of the inferior mesenteric ganglion from the same specimen is also shown, as it represents the positive control for the immunohistochemical experiment.

Table 2. Constituent ganglia of the aortic plexus are consistently present.

A summary of the results from the H&E staining used to verify the macroscopically identified ganglia. All excised specimens were microscopically confirmed to be ganglia with the exception of three ‘prehypogastric ganglia’. No tissues were completely devoid of neuron cell bodies.

	Right Ovarian Ganglion	Left Ovarian Ganglion	Prehypogastric Ganglion
N excised (total)	29	31	28
N confirmed as ganglia (abundant neuron cell bodies)	29	31	25
N inconclusive (notable lack of neurons throughout the tissue)	0	0	3
N devoid of neurons	0	0	0

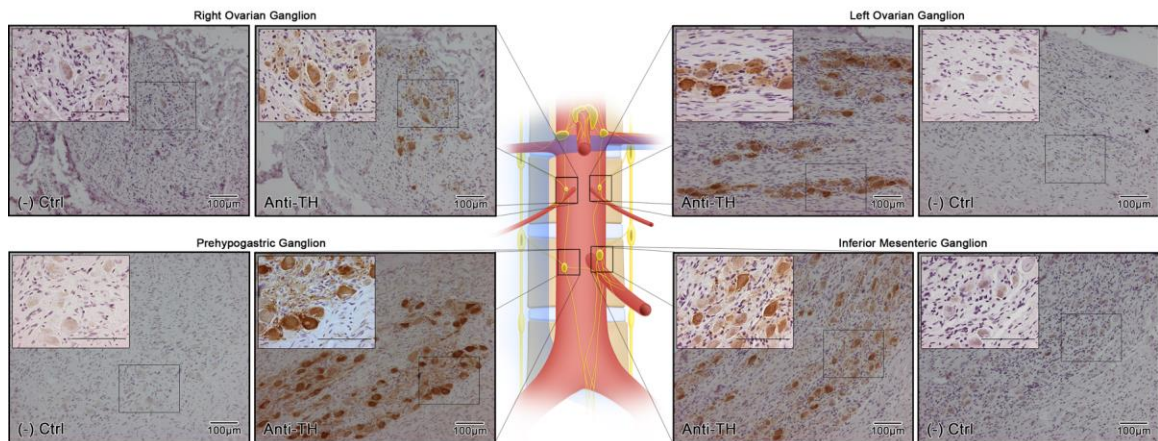


Figure 15. Tyrosine hydroxylase confirms the adrenergic nature of the ganglia.

Immunohistochemical staining of the right/left ovarian and prehypogastric ganglia were positive for tyrosine hydroxylase, indicating the adrenergic nature of the constituent neurons. Staining of the inferior mesenteric ganglion was used as positive control tissue. Tissue-specific negative controls (- ctrl), which underwent identical procedures save the application of the primary antibody, are also presented.

3.5 Discussion

In the present study, dissection and histological analysis of cadaveric specimens were used to identify the left ovarian, right ovarian and prehypogastric ganglia as constituent structures of the aortic plexus in human females. Consistent with previous scientific reports of ovarian ganglia in pigs, cats and rats (Langley & Anderson, 1896; McNeill & Burden, 1986; Klein & Burden, 1988a, 1988b; Czaja et al., 2001), histological examination of the excised tissue obtained during dissection revealed that all examined specimens contained right (n = 29) and left (n = 31) ovarian ganglia in similar topographic locations as the spermatic ganglia in males (Motoc et al., 2010; Beveridge, Johnson, et al., 2015). Thus, the present study provides histological verification of the ovarian ganglia in humans, which to our knowledge had only been alluded to in two classical textbooks (Kuntz, 1945; Crosby et al., 1962). In rats, it was shown that the nerves of the ovarian ganglia and plexuses mainly innervate the vasculature of the ovary. This is in contrast to the fibers coming from the celiac plexus via the superior ovarian nerve which innervate both ovarian vasculature and interstitial tissue (Lawrence & Burden, 1980; Aguado, 2002). Furthermore, it has been suspected that visceral afferent fibers traveling via the ovarian plexuses account for the intermenstrual pain (Mittelschmerz) some women associate with ovulation (Davidson, 1934; Crosby et al., 1962). More recently, Czaja et al. (2001) identified a major population of sympathetic neurons in the ovarian ganglia of pigs which innervate the ipsilateral ampulla and isthmus of the oviduct. Although the purpose of the sympathetic innervation from the ovarian ganglia to the oviduct remains unknown, a possible vasoconstrictive role and/or a role in smooth muscle contraction is likely.

In addition, the present study revealed using histology that the vast majority (25/28) of cadavers had a prehypogastric ganglion. Importantly, these findings provide the first reported evidence of the prehypogastric ganglion in females. In each cadaver, the prehypogastric ganglion was positioned in the same position as demonstrated in males (Beveridge, Johnson, et al., 2015). Taken together, these results confirm that the recently discovered prehypogastric ganglion is a consistent structure of the human aortic plexus.

Collectively, our results demonstrate that female cadavers exhibit ovarian and prehypogastric ganglia in positions that are consistent with that of the homologous structures in males (Motoc et al., 2010; Beveridge, Johnson, et al., 2015); findings which further confirm that the aortic plexus is organized in a bilaterally symmetrical manner. Given the demonstrated symmetry of the four ganglia of the aortic plexus in males and now females (as schematized in Figure 12), one could ask whether the prehypogastric ganglion is in fact the right sided developmental equivalent structure to the inferior mesenteric ganglion because of its chiral anatomy within the contralateral (right) cord of the aortic plexus. Although it is generally accepted that humans possess one well defined inferior mesenteric ganglion (Jänig & McLachlan, 1987) with the possibility of variable accessory inferior mesenteric ganglia (Kuntz & Jacobs, 1955; O’Rahilly, 1986; Beveridge, Johnson, et al., 2015), dissection and histological examination of the inferior mesenteric plexus of human fetuses revealed the possibility of two well-defined inferior mesenteric ganglia, supplied by the respective right and left lumbar splanchnic nerves (Fig. 4 in Southam, 1959). Based on Southam’s (1959) developmental observations, it is reasonable to suggest that a right and left inferior mesenteric ganglion could develop in humans, with the former becoming what we have identified as the prehypogastric ganglion in the adult and the latter becoming the inferior mesenteric ganglion proper.

Considering the possibility that the prehypogastric ganglion develops from the fetal right inferior mesenteric ganglion, the anatomy of the human aortic plexus becomes congruent with the known anatomy of other species such as the cat, guinea pig, rabbit, dog (Jänig & McLachlan, 1987) and pig, where it is generally accepted that a right- and a left-sided inferior mesenteric ganglion exist in both male (Kaleczyc et al., 1995; Ragonieri et al., 2013; Pidsudko, 2014a) and female adults (Majewski et al., 1991). In the context of this comparative anatomy, it appears that the prehypogastric ganglion and the inferior mesenteric ganglion proper of humans are equivalent to the right and left inferior mesenteric ganglia of other mammals, respectively. Although a clear similarity in these ganglia exists across species, the differences in the current nomenclature importantly acknowledges the topographical and morphological differences in their anatomy. Conventionally, the nomenclature of the prevertebral ganglia are given according to the plexus to which they are associated (O’Rahilly, 1986), thus, the nomenclature of the

prehypogastric ganglion describes its anatomy distinct from the inferior mesenteric artery (Figure 13) with seemingly more significant communications with the superior hypogastric plexus (Beveridge, Johnson, et al., 2015). This is in contrast to the anatomy of the left and right inferior mesenteric ganglia of non-primate mammals, such as the pig, where it is well established that they are positioned bilaterally, immediately adjacent to the inferior mesenteric artery (Kaleczyc et al., 1995; Pidsudko, 2014a) in an orientation resembling the anatomy of the bi-lobed celiac ganglia positioned around the base of the celiac artery in humans (see Plate 302 in Netter, 2011; Figure 1136 in Dwight et al., 1930). Ultimately, the anatomical distinction of the prehypogastric ganglion from the inferior mesenteric ganglion is of importance for surgeons tasked with navigating the intricacies of the aortic plexus during retroperitoneal procedures; especially since the function of the prehypogastric ganglion remains unclear.

In the original description of the prehypogastric ganglion in males, our group hypothesized it might be a structure which, if damaged, results in anejaculation because of its apparent contribution to the superior hypogastric plexus and potential risk for surgical damage due to its position distinct from arterial branches of the aorta (Beveridge, Johnson, et al., 2015). Given that anejaculation is characterized by a loss of seminal emission, it appears unlikely that this would be the sole function of a structure that has now been identified in females. Rather, our revised suggestion is that the prehypogastric ganglion is instead and/or additionally responsible for contraction of the internal urethral sphincter, a function common to both sexes. This hypothesis is particularly compelling since contraction of the internal urethral sphincter functions in both sexes to retain urine in the bladder; however, it is also imperative for antegrade ejaculation in males (Jung et al., 2012).

In conclusion, the present study provides histological verification of the left ovarian, right ovarian and prehypogastric ganglia in females. Although several suggestions about the possible role of these ganglia have been proposed based on their anatomy, it is important to note that their exact purpose, particularly in humans, remains unknown. Ultimately, future studies are needed to elucidate the specific function(s) of the ovarian and prehypogastric ganglia in humans.

3.6 Acknowledgements

The authors would like to thank: the donors and their families, because this research would not be possible without their generosity; the supervisors of the HAASE anatomy lab at Western University, Haley Linklater and Kevin Walker, for their help with the cadaveric dissections; and, Linda Jackson from the Department of Pathology for her technical expertise in histology. The authors have no conflict of interest with the content of the manuscript.

3.7 Author Contributions

T.S.B.: study conception; data acquisition and analysis; illustrations. T.S.B. and B.L.A.: data interpretation, writing and critical revision of the manuscript. All authors contributed to the overall study design as well as providing edits and approval of the final version of the manuscript.

3.8 References

- 1) Aguado LI (2002). Role of the central and peripheral nervous system in the ovarian function. *Microscopy Research and Technique*, 59(6), 462–473.
- 2) Beveridge TS, Johnson M, Power A, Power NE, Allman BL (2015). Anatomy of the nerves and ganglia of the aortic plexus in males. *Journal of Anatomy*, 226(1), 93–103.
- 3) Choi Y, Novembre E (1999). Continuous inferior mesenteric ganglion block for the control of abdominal pain. *Regional Anesthesia Pain Medicine*, 24(4), 358–360.
- 4) Crosby EC, Humphrey T, Lauer EW (1962). *Correlative Anatomy of the Nervous System*. New York: The Macmillan Company.
- 5) Czaja K, Kaleczyc J, Pidsudko Z, Franke-Radowiecka A, Lakomy M (2001). Distribution of efferent neurones innervating the oviduct in the pig. *Folia Morphologica*, 60(4), 243–248.
- 6) Davidson AH (1934). Ovarian Conditions as Causes of Pelvic Pain. *The British Medical Journal*, 2(3848), 623–624.
- 7) Dwight T, McMurrich J, Hamann C (1930). The Sympathetic System of Nerves. In G. Peirsol (Ed.), *Human Anatomy* (9th ed., pp. 1366–1374). London: J.B. Lippincott Company.
- 8) Flynn JC, Price CT (1984). Sexual Complication of Anterior Fusion of Lumbar Spine. *Spine*, 9(5), 489–492.
- 9) Heidenreich A, Pfister D (2012). Retroperitoneal lymphadenectomy and resection for testicular cancer: an update on best practice. *Therapeutic Advances in Urology*, 4(4), 187–205.
- 10) Hollinshead WH (1974). *Textbook of Anatomy* (3rd ed.). Hagerstown, MD: Harper & Row, Publishers.
- 11) Hsiao W, Deveci S, Mulhall JP (2012). Outcomes of the management of post-chemotherapy retroperitoneal lymph node dissection-associated anejaculation. *BJU International*, 110(8), 1196–1200.
- 12) Jänig W, McLachlan EM (1987). Organization of lumbar spinal outflow to distal colon and pelvic organs. *Physiological Reviews*, 67(4), 1332–404.
- 13) Jewett MA, Groll RJ (2007). Nerve-Sparing Retroperitoneal Lymphadenectomy. *Urologic Clinics of North America*, 34(2), 149–158.

- 14) Jewett MA, Kong YP, Goldberg SD, Sturgeon JF, Thomas GM, Alison RE, Gospodarowicz MK (1988). Retroperitoneal Lymphadenectomy for Testis Tumor with Nerve Sparing for Ejaculation. *The Journal of Urology*, 139(6), 1220–1224.
- 15) Jung J, Ahn HK, Huh Y (2012). Clinical and functional anatomy of the urethral sphincter. *International Neurourology Journal*, 16(3), 102–106.
- 16) Kaleczyc J, Timmermans J, Majewski M, Lakomy M, Scheuermann DW (1995). Distribution and immunohistochemical characteristics of neurons in the porcine caudal mesenteric ganglion projecting to the vas deferens and seminal vesicle. *Cell & Tissue Research*, 282(1), 59–68.
- 17) Katz MH, Eggener SE (2009). The evolution, controversies, and potential pitfalls of modified retroperitoneal lymph node dissection templates. *World Journal of Urology*, 27(4), 477–483.
- 18) Klein CM, Burden HW (1988a). Anatomical localization of afferent and postganglionic sympathetic neurons innervating the rat ovary. *Neuroscience Letters*, 85(2), 217–222.
- 19) Klein CM, Burden HW (1988b). Substance P- and vasoactive intestinal polypeptide (VIP)-immunoreactive nerve fibers in relation to ovarian postganglionic perikarya in para- and prevertebral ganglia: evidence from combined retrograde tracing and immunocytochemistry. *Cell Tissue Research*, 252(2), 403–410.
- 20) Kuntz A (1945). Anatomic structure and relationships, the female sex organs. In *The Autonomic Nervous System* (3rd ed., p. 32,314). Philadelphia PA: Lea & Febiger.
- 21) Kuntz A, Jacobs MW (1955). Components of Periarterial Extensions of Celiac and Mesenteric Plexuses. *Anatomical Record*, 123(4), 509–520.
- 22) Langley JN, Anderson HK (1896). The Innervation of the Pelvic and adjoining Viscera: Part VII. Anatomical Observations. *Journal of Physiology*, 20(4–5), 371–406.
- 23) Lawrence IE, Burden HW (1980). The origin of the extrinsic adrenergic innervation to the rat ovary. *The Anatomical Record*, 196(1), 51–59.
- 24) Majewski M, Heym C, Igg F, Red S (1991). The origin of ovarian neuropeptide Y (NPY) – immunoreactive nerve fibres from the inferior mesenteric ganglion in the pig. *Cell and Tissue Research*, 266(3), 591–596.
- 25) McNeill DL, Burden HW (1986). Neuropeptide Y and somatostatin immunoreactive perikarya in preaortic ganglia projecting to the rat ovary. *Journal of Reproductive Fertility*, 78(2), 727–732.
- 26) Mirilas P, Skandalakis J (2010). Surgical Anatomy of the Retroperitoneal Spaces, Part IV: Retroperitoneal Nerves. *The American Surgeon*, 76(3), 253–262.

- 27) Motoc A, Rusu MC, Jianu AM (2010). The spermatic ganglion in humans: An anatomical update. *Romanian Journal of Morphology and Embryology*, 51(4), 719–723.
- 28) Netter F (2011). Back and Spinal Cord, Abdomen, Pelvis and Perineum. In J. Hansen (Ed.), *Atlas of Human Anatomy* (5th ed., Plates 160, 297, 319, 389, 390). Philadelphia PA: Saunders Elsevier.
- 29) O’Rahilly R (1986). The Abdomen. In A. Meier (Ed.), *Anatomy: A Regional Study of Human Structure* (5th ed., pp. 433–436). Philadelphia PA: W.B. Saunders Company.
- 30) Pidsudko Z (2014). Immunohistochemical characteristics and distribution of neurons in the paravertebral, prevertebral and pelvic ganglia supplying the urinary bladder in the male pig. *Journal of Molecular Neuroscience*, 52(1), 56–70.
- 31) Ragionieri L, Botti M, Gazza F, Sorteni C, Chiochetti R, Clavenzani P, ... Panu R (2013). Localization of peripheral autonomic neurons innervating the boar urinary bladder trigone and neurochemical features of the sympathetic component. *European Journal of Histochemistry*, 57(2), 93–105.
- 32) Southam J (1959). The Inferior Mesenteric Ganglion. *Journal of Anatomy*, 93, 304–308.
- 33) Spalteholz W, Spanner R (1967). The Nervous System. In *Atlas of Human Anatomy* (16th ed., pp. 816–817). Philadelphia PA: F.A. Davis Company.
- 34) Veroux P, D’Arrigo G, Veroux M, Giaquinta A, Lomeo A (2010). Sexual dysfunction after elective endovascular or hand-assisted laparoscopic abdominal aneurysm repair. *European Journal of Vascular and Endovascular Surgery*, 40(1), 71–75.

CHAPTER 4

THE ANATOMY OF THE INFRARENAL LUMBAR SPLANCHNIC NERVES IN HUMAN CADAVERS: IMPLICATIONS FOR RETROPERITONEAL NERVE-SPARING SURGERY

Based on our recent research elucidating the anatomy of the aortic plexus, we have learned it is comprised of two parallel cords which run paramedially along the anterior surface of the infrarenal abdominal aorta. Consistently, the aortic plexus contains four prevertebral ganglia, arranged bilaterally with two in each cord. Like all anatomical structures, the aortic plexus is prone to variation. A detailed description of the potential variations in the anatomy of the aortic plexus is warranted by surgeons attempting to spare these nerves during retroperitoneal surgery. The present chapter addresses this need by providing the first quantitative study of the infrarenal lumbar splanchnic nerves. The content of this chapter is published in the *Journal of Anatomy*, Volume 232, Issue 1, Pages 124-133.

4.1 Abstract

Injury to the nerves of the aortic- and superior hypogastric plexuses during retroperitoneal surgery often results in significant post-operative complications, including retrograde ejaculation and/or loss of seminal emission in males. Although previous characterizations of these plexuses have done well to provide a basis for understanding the typical anatomy, additional research into the common variations of these plexuses could further optimize nerve-sparing techniques for retroperitoneal surgery. To achieve this, the present study aimed to document the prevalence and positional variability of the infrarenal lumbar splanchnic nerves (LSNs) through gross dissection of 26 human cadavers. In almost all cases, two LSNs were observed joining each side of the aortic plexus, with 48% (left) and 33% (right) of specimens also exhibiting a third joining inferior to the left renal vein. As expected, the position of the LSNs varied greatly between specimens. That said, the vast majority (98%) of LSNs joining the aortic plexus were found to originate from the lumbar sympathetic trunk above the level of the inferior mesenteric artery. It was also found that, within specimens, adjacent LSNs often coursed in parallel. In addition to these nerves, 85% of specimens also demonstrated retroaortic

LSN(s) that were angled more inferior compared with the other LSNs ($p < 0.05$), and exhibited a unique course between the aorta/common iliac arteries and the left common iliac vein before joining the superior hypogastric plexus below the aortic bifurcation. These findings may have significant implications for surgeons attempting nerve-sparing procedures of the sympathetic nerves in the infrarenal retroperitoneum such as retroperitoneal lymphadenectomies. We anticipate that the collective findings of the current study will help improve such retroperitoneal nerve-sparing surgical procedures, which may assist in preserving male ejaculatory function post-operatively.

4.2 Introduction

The major source of sympathetic innervation to the pelvic organs is provided by the aortic- and superior hypogastric plexuses. Overlying the infrarenal abdominal aorta, the aortic plexus receives sympathetic supply from the lumbar sympathetic trunk and suprarenal preaortic plexuses via lumbar splanchnic nerves (LSNs) and intermesenteric nerves, respectively (Motoc et al., 2010; Beveridge, Johnson, et al., 2015). After extending branches to form the inferior mesenteric plexus, the main cords of the aortic plexus converge near the aortic bifurcation as the superior hypogastric plexus that descends into the pelvis to innervate the smooth muscle of the urogenital organs, including the internal urethral sphincter, ductus deferens, prostate gland and seminal vesicles (Learmonth, 1931; Mitchell, 1953; Crosby et al., 1962; Duncan & Jonck, 1965; Brindley et al., 1989; Coolen et al., 2004; Paraskevas et al., 2008; Beveridge, Johnson, et al., 2015). Unfortunately, given their seemingly variable positioning in the retroperitoneum and pelvis, the delicate nerves of the aortic and/or superior hypogastric plexus are at risk of damage during retroperitoneal surgery, which can result in significant postoperative complications, including loss of seminal emission and/or retrograde ejaculation in males (Duncan & Jonck, 1965; Johnson & McGuire, 1981; Flynn & Price, 1984; Jewett et al., 1988; Jewett & Groll, 2007; Veroux et al., 2010; Heidenreich & Pfister, 2012; Hsiao et al., 2012). Although this preventable post-operative complication is well acknowledged in the surgical literature, additional research into the common variations of the nerves comprising and contributing to the aortic- and

superior hypogastric plexuses could further optimize nerve-sparing techniques for retroperitoneal surgeons.

Based on cadaveric and surgical investigations, most of our understanding of the LSNs has been derived from qualitative observations (Motoc et al., 2010; Beveridge, Johnson, et al., 2015, 2016). Classical anatomical texts reference four LSNs on each side with two–four joining the aortic plexus (Mitchell, 1953; Hollinshead, 1971; Gray, 1973; Woodburne & Burkel, 1994; Mirilas & Skandalakis, 2010), and more recent cadaveric studies have supported this assertion by reporting two consistent infrarenal LSNs (with the potential for accessory fibers) joining the intermesenteric nerves of the aortic plexus (Beveridge, Johnson, et al., 2015, 2016; Beveridge, Allman, et al., 2016). Moreover, below the aortic bifurcation, some sources indicate the possibility of a LSN(s) joining the superior hypogastric plexus (Dwight et al., 1930; Learmonth, 1931; Mitchell, 1953; Duncan & Jonck, 1965; Hollinshead, 1971; O’Rahilly, 1986; Mirilas & Skandalakis, 2010; Beveridge, Johnson, et al., 2015); however, details about their prevalence and/or course are rarely discussed. Of the reports available, it remains unclear whether these fibers course: (i) anterior to the common iliac arteries (see fig. 38.7 from O’Rahilly, 1986; fig. 6–71 from Woodburne & Burkel, 1994; fig. 9 from Mirilas & Skandalakis, 2010; plate 389 from Netter, 2011); (ii) between the aortic bifurcation and the left common iliac vein (see fig. 1 from Learmonth, 1931; fig. 110 from Mitchell, 1953; Beveridge et al. 2015a); or (iii) posterior to the left common iliac vein (see fig. 1140 from Dwight et al. 1930; fig. 1 from Learmonth, 1931; fig. 9 from Mirilas & Skandalakis, 2010; plates 297 and 392 from Netter, 2011). Furthermore, inconsistencies exist with respect to whether one (Dwight et al., 1930; Hollinshead, 1971; O’Rahilly, 1986; Mirilas & Skandalakis, 2010; Beveridge, Johnson, et al., 2015) or two (Learmonth, 1931; Woodburne & Burkel, 1994) LSNs are present on each side that extend to join the superior hypogastric plexus. Based on our own observations (Beveridge, Johnson, et al., 2015), it is our prediction that LSN(s) joining the superior hypogastric plexus, when present, will course behind the aortic bifurcation, yet anterior to the left common iliac vein.

Given that the precise involvement of each LSN in seminal emission and antegrade ejaculation is not yet understood, further investigation is warranted to quantify the positional deviations of the LSNs in order to assist comprehensive nerve-sparing retroperitoneal surgery. Although the position of the LSNs may vary greatly, based on our own dissections, we predict that the course of adjacent LSNs will remain similar within specimens (i.e., each LSN will course in parallel to one another within an individual). Ultimately, to complement previous observations and address the aforementioned predictions, the present study endeavored to provide the first quantification of the prevalence, positional deviations and course of the infrarenal LSNs adjoining the aortic- and superior hypogastric plexuses through dissection and measurement of human cadavers.

4.3 Materials and Methods

This study was conducted on 26 embalmed human cadavers (16 females, 10 males; $\mu_{\text{age at death}} = 80.4 \pm 9.8$ years; range 59–97 years) over a period of two years from the HEART (Haase Education in Anatomy & Research Technologies) Lab at Western University, ON, Canada. All data were obtained in accordance with the Anatomy Act of Ontario and Western's Cadaveric Use in Research. Specimens were excluded from the present study if they exhibited evidence of previous infrarenal retroperitoneal dissection that may have altered the anatomy ($n = 10$), or retroperitoneal disease that may have altered the position of the aortic plexus ($n = 8$; i.e., abdominal aortic aneurysms greater than 3 cm, local metastases).

4.3.1. Dissection

The preaortic sympathetic nerves were dissected from the left renal vein to the pelvic inlet. LSNs were carefully isolated where they intersected the left/right cord of the aortic plexus or the posterior aspect of the superior hypogastric plexus, and followed posteriorly to their origin at the lumbar sympathetic trunk. Because all LSNs joining the superior hypogastric plexus below the aortic bifurcation coursed posterior to the common iliac arteries, they were referred to (and grouped for analysis) as retroaortic LSNs. Nerves were pinned during dissection in preparation for measurement.

4.3.2. Measurement Protocol

To quantify the position of each LSN, we measured its origin (proximal position at the sympathetic trunk) and termination (distal position at the cord of the aortic plexus or superior hypogastric plexus) relative to the aortic bifurcation along the rostrocaudal axis. This positional metric was adopted based on its successful implementation in a previous study that examined the position of the lumbar arteries and veins within the infrarenal retroperitoneum (Beveridge, Power, et al., 2015). In addition, measurements of the infrarenal abdominal aortic length, rostrocaudal position of the inferior mesenteric artery and lateral position of the superior hypogastric plexus were obtained to standardize and contextualize the data reported in the study. To determine the lateral positioning of the superior hypogastric plexus, the width of the plexus and its distance from each side of the aorta were measured at the level of the aortic bifurcation.

Inter- and intra-rater reliability of the measurement protocol was performed using an intraclass correlation coefficient in a two-way mixed model assessing absolute agreement. To assess inter-rater reliability, two raters (Raters A and B) measured the same three specimens on different days, and were blinded to all previous measurements. Subsequently, Rater A measured a different specimen on two different days (blinded from all previous measurements) to assess intra-rater reliability. An excellent agreement of 0.998 (0.995–0.999: 95% CI) and 0.995 (0.984–0.998: 95% CI) was determined for inter- and intra-rater reliability, respectively. All measurements used in this study were obtained by Rater A because his performance underwent both inter- and intra-rater reliability analyses.

4.3.3. Data Analyses and Statistics

To assess the variability of the number and positioning of LSNs, we first needed to implement a strategy that grouped alike LSNs between individuals. This was a challenging task given the potential for inaccuracy inherent to the inconsistency of the infrarenal region (Yeager & Cowley, 1948; Hollinshead, 1971; Mirilas & Skandalakis, 2010; Beveridge, Allman, et al., 2016; Beveridge, Johnson, et al., 2016). Classically, the LSNs are named by the sympathetic trunk ganglia to which they are associated (Figure

16A). Unfortunately, this method can be unreliable (Hollinshead, 1971) due to the extreme variability present in the anatomy of the lumbar sympathetic trunk (Yeager & Cowley, 1948; Gray, 1973; Mirilas & Skandalakis, 2010; Gandhi et al., 2013). Recognizing this shortcoming of the classical nomenclature, we previously elected to refer to the LSNs joining the aortic plexus in their order relative to the left renal vein (i.e. first infrarenal LSN, etc.), as seen in Figure 16B (Beveridge, Allman, et al., 2016; Beveridge, Johnson, et al., 2016). However, this approach proved problematic for the present study because subtle positional variations in the left renal vein inappropriately changed how nerves were grouped for subsequent statistical analysis. Thus, in the present study, we instead grouped the LSNs for analysis based on their position relative to the aortic bifurcation (i.e. the most inferior LSNs were grouped together, etc.; Figure 16C). Note that this strategy was used to describe the LSNs joining the aortic plexus, whereas the retroaortic LSNs that joined the superior hypogastric plexus were identified and grouped based on their unique coursing pattern posterior to the aorta/common iliac arteries.

Prior to statistical analyses, the positions of the LSNs were normalized to the infrarenal length of the abdominal aorta to limit the variability associated with size differences between specimens. In most cases, normalized values were preferentially reported; however, some raw measurements were also included (see Results). To examine if the positions of the left and right LSNs were similar, we calculated the difference between where a pair of LSNs (e.g. the right and left lowest LSNs) joined the aortic/superior hypogastric plexus (Δd) using normalized values. A value of Δd equal to zero indicated perfect positional symmetry. To determine if adjacent LSNs on the same side coursed in parallel, we calculated the difference in position between the connections of each LSN with the sympathetic trunk and the aortic/superior hypogastric plexus (Δp) using normalized values. Subsequently, each side was independently compared using non-parametric one-way analysis of variance tests (Kruskal–Wallis H-tests, $\alpha = 0.05$). Non-parametric statistics were used because the calculated values of Δp were not normally distributed (Shapiro–Wilk, $p < 0.05$). For clarity, an example of Δd and Δp values can be seen in Figure 17C.

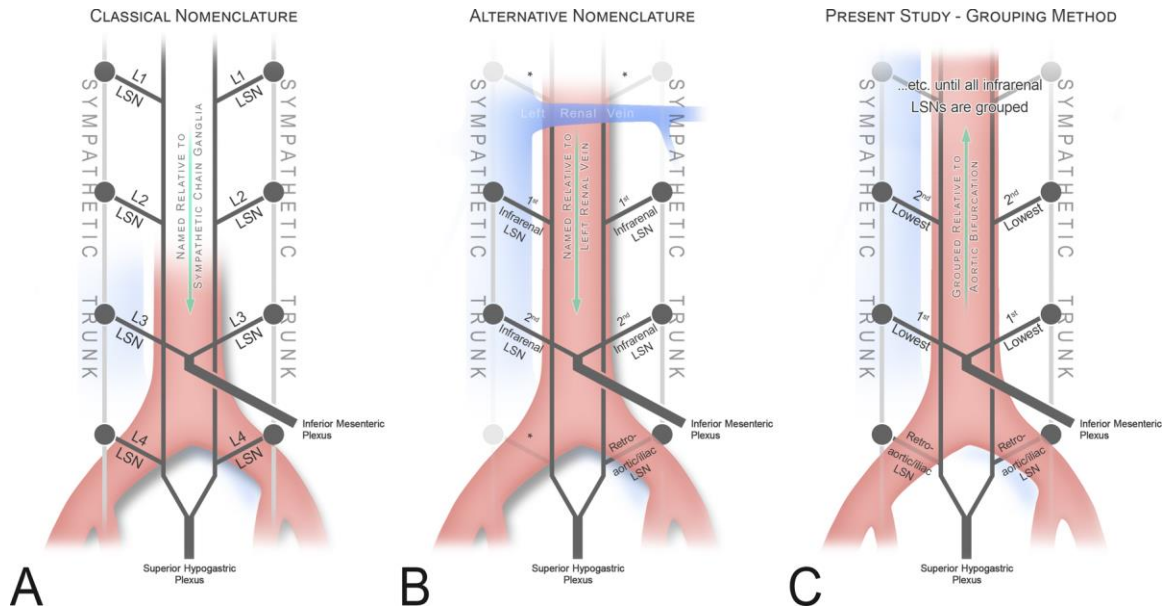


Figure 16. Evolution of nomenclature to accurately describe the lumbar splanchnic nerves.

An illustration of the different nomenclatures used in the literature compared with the grouping method used in this study. (A) Illustrates how the lumbar splanchnic nerves (LSNs) are classically named as per the sympathetic trunk ganglia from which they originate (Hollinshead, 1971; Mirilas & Skandalakis, 2010). (B) Illustrates a more contemporary strategy used in the primary literature where LSNs are named in order relative to the left renal vein (Beveridge, Allman, et al., 2016; Beveridge, Johnson, et al., 2016); an asterisk (*) indicates portions of the plexus not examined in these studies. To accurately group alike LSNs for comparison in this study, the retroaortic LSNs were grouped and the remaining (above the aortic bifurcation) were grouped in ascending order (C).

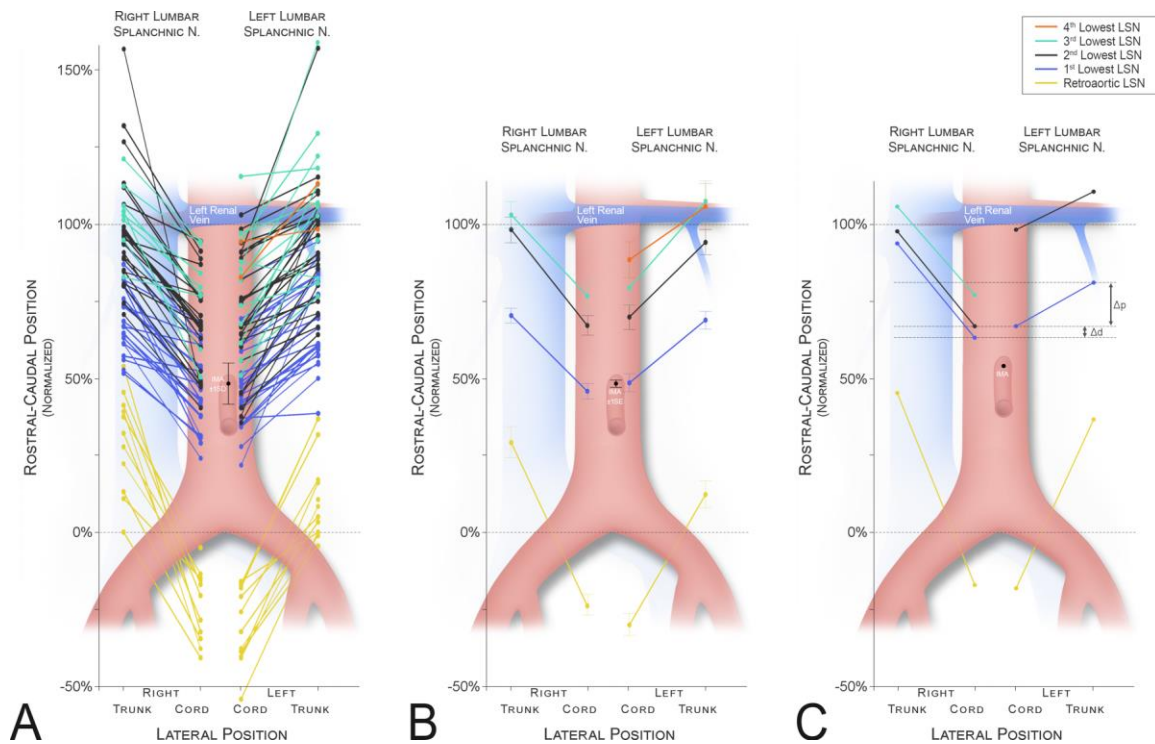


Figure 17. The positions of the lumbar splanchnic nerves are prone to variation and are not bilaterally symmetrical.

A graphic illustration showing the position of the infrarenal lumbar splanchnic nerves (LSNs) as they join the cord of the aortic plexus and the lumbar sympathetic trunk relative to the total infrarenal space (100%). (A) Each individual nerve that was measured in the study. (B) The mean position of each nerve with the associated standard error of that mean. (C) The measurements taken from a typical specimen (#1849) that illustrates, at the individual level, the position of LSNs on one side does not always predict the contralateral positions (see the pair of 2nd lowest LSNs coloured in black). Irrespective of this, consistency in the angle of projection (Δp) between ipsilateral LSNs can also be observed in this specimen (refer to Figure 22 for statistics). Retroaortic LSN – yellow; most inferior LSN – blue; second inferior LSN – black; third inferior LSN – teal; and fourth inferior LSN – orange.

Data were handled and calculations were completed with Excel (Version 2016, Microsoft), and all statistical tests were performed using SPSS® Statistics (Version 24, IBM). Statistical power was determined using G*Power v3.1.9.2. Graphical figures were generated with Excel or SPSS®, then stylized and formatted using Adobe Photoshop CS6. Photos were obtained using a Nikon D80 DSLR camera, and 3D modeling of the findings was completed using Blender (Version 2.78a, Blender Foundation).

4.4 Results

Of the 26 human cadavers included in this study, 21 had an intact retroperitoneum prior to examination; the remaining five specimens had a partially dissected retroperitoneum as a result of medical students' laboratory exercises at our institution. In these five cases, only the regions of the retroperitoneal plexuses that remained untouched were examined. Therefore, the present study examined the variability in the number and position of the LSNs on the right ($n = 24$) and left sides ($n = 25$) of the aortic plexus. In our study population, the mean distance from the aortic bifurcation to the inferior mesenteric artery and inferior border of the left renal vein was 44.0 ± 6.6 mm and 91.6 ± 12.8 mm, respectively. Of the specimens with bilaterally intact/ untouched anatomy around the bifurcation ($n = 22$), the diameter of the aorta (at the level of the aortic bifurcation) was measured to be 30.8 ± 6.8 mm. In 17/22 (77%) of these specimens, the center of the superior hypogastric plexus was shifted left of the aortic bifurcation 2.7 ± 2.4 mm; the remaining five were shifted right of the bifurcation 1.8 ± 1.4 mm. Irrespective of this predominant left-sided shift, the superior hypogastric plexus still extended right of the bifurcation in 90.9% ($n = 20/22$) specimens. Overall, the superior hypogastric plexus extended 4.5 ± 3.2 mm right and 7.9 ± 4.0 mm left of the bifurcation, exhibiting an average width of 12.4 ± 4.4 mm.

A total of 142 LSNs ($n_{\text{LEFT}} = 76$, $n_{\text{RIGHT}} = 66$) were identified joining the cords of the aortic plexus (Figure 17A). In most cases ($n = 136$, 95%), the LSNs existed as a single fiber bundle coursing at an anteroinferior angle. In a few cases ($n = 7$, 5%; $n_{\text{LEFT}} = 3$, $n_{\text{RIGHT}} = 4$), a variation was observed where a LSN originated from two points on the lumbar sympathetic trunk and converged to a common fiber prior to joining the aortic plexus. In these cases, the larger root was used as the connection with the sympathetic

trunk for statistical analyses (larger root was superior in 4/7 specimens). The mean difference between the two roots was 13.1 ± 7.3 mm (range 4.1–25.6 mm). On the right side, the two roots were often seen coursing on either side of a lumbar vein.

A variable number of one to four LSNs joined the cords of the aortic plexus below the level of the left renal vein, with two most commonly present (prevalence left = 52%; right = 63%). The prevalence and location of each LSN is further reported in Table 3. As shown in Figure 17A, there was considerable variability in the rostrocaudal position of the LSNs. Still, 118/120 (98.3%) LSNs that extended to join the aortic plexus originated from the sympathetic trunk superior to the level of the inferior mesenteric artery. Of these, 69.5% (n = 82) also joined the aortic plexus at a position superior to the inferior mesenteric artery. No LSNs were observed joining the aortic plexus along the lower 21.8% (left) and 24.1% (right) of the infrarenal abdominal aortic length. The mean position of each LSN is shown graphically in Figure 17B, and schematically in three dimensions in Figure 18. Although the mean difference in positions between the left and right sides of each LSN ranged from 2.6% to 2.8% (Figure 17B), this was rarely observed at the individual level, as noted by the wide standard deviations associated with the mean Δd of each pair (mean $\Delta d_{1st \text{ lowest LSN}} = 3.7 \pm 13.7\%$, mean $\Delta d_{2nd \text{ lowest LSN}} = 1.7 \pm 22.1\%$, mean $\Delta d_{3rd \text{ lowest LSN}} = 2.9 \pm 13.6\%$). Figure 17C shows data obtained from a typical specimen (specimen #1849) that illustrates how the position of the LSNs on one side did not often mirror the contralateral positions. This relationship can also be seen in Figure 19, where the anatomy for this specimen is shown in three dimensions, panelled in 60° increments.

Table 3. Descriptive statistics of the infrarenal lumbar splanchnic nerves.

Descriptive statistics for the LSNs joining the infrarenal aortic plexus and superior hypogastric plexus. Nerves grouped inferiorly-superiorly (1–4) and compared relative to the total infrarenal space (100%). Reported are the total number of splanchnic nerves identified and at which level. LSN, lumbar splanchnic nerve.

	LSN Order	LSN (%)	Relative Proximal Position (%)			Relative Distal Position (%)		
			Mean	SD	Range	Mean	SD	Range
Left	4 th Lowest	2 (8)	106.0	10.5	98.6-113.4	88.7	8.2	82.0-94.5
	3 rd Lowest	12 (48)	107.7	23.3	76.6-159.1	79.6	18.7	51.0-115.6
	2 nd Lowest	25 (100)	94.4	19.8	64.2-157.2	70.1	19.6	35.6-103.1
	1 st Lowest	25 (100)	69.1	13.9	38.6-94.5	48.7	14.3	21.8-82.4
	Retroaortic	12 (48)	12.4	15.1	-4.5-36.8	-29.9	12.6	-54.2-(-15.0)
Right	3 rd Lowest	8 (33)	103.2	11.4	82.9-121.3	77.0	15.4	50.5-94.5
	2 nd Lowest	23 (96)	98.5	19.6	70.7-157.0	67.3	15.2	40.4-94.6
	1 st Lowest	24 (100)	70.6	11.2	82.9-121.3	46.0	12.2	24.1-68.3
	Retroaortic	11 (46)	29.4	16.4	0.0-53.8	-23.7	11.6	-40.8-(-5.0)

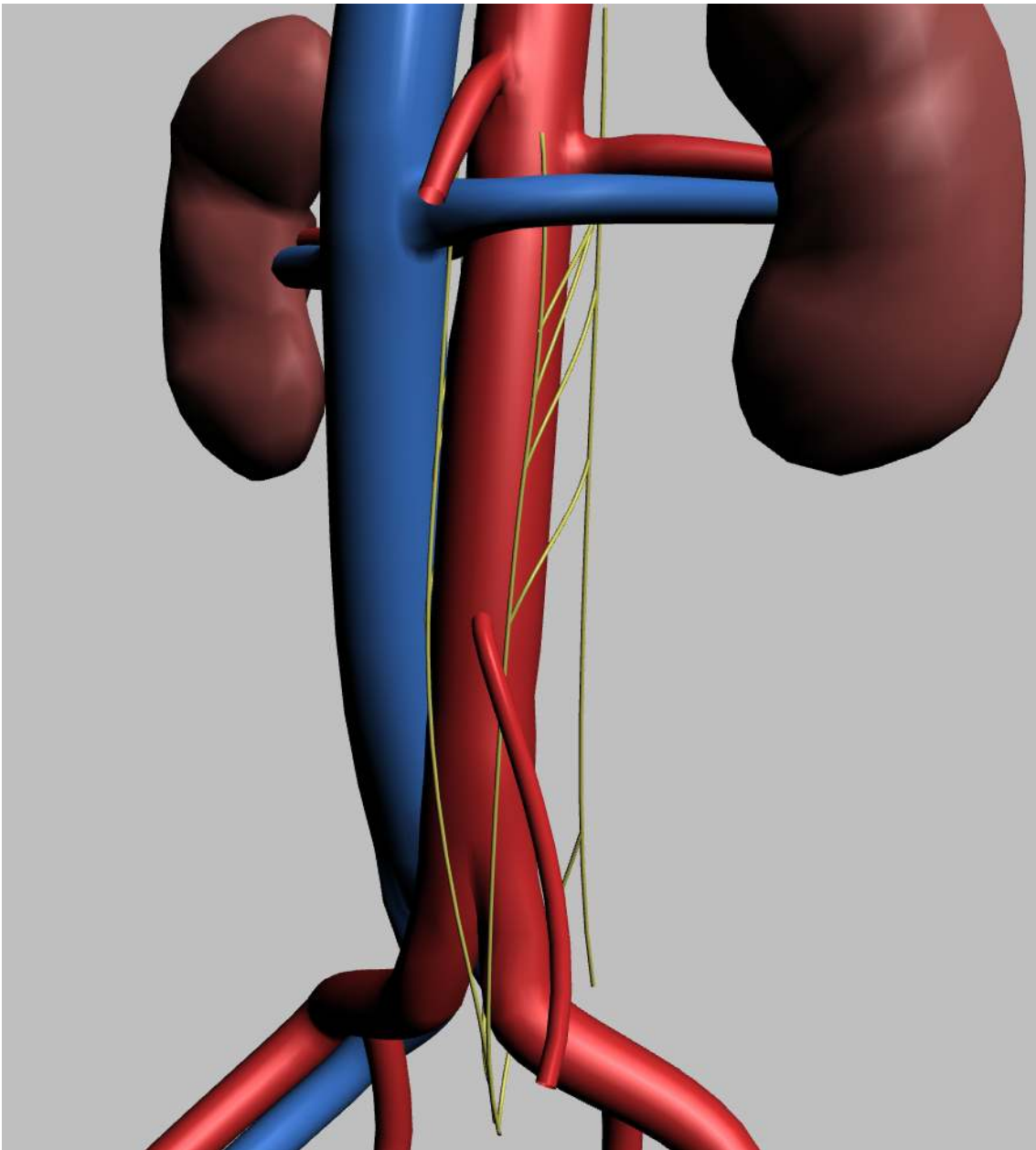


Figure 18. The anatomy of the infrarenal lumbar splanchnic nerves in 3D

A 3D model (click to activate if using Adobe Acrobat Reader) showing the average position and course of the infrarenal lumbar splanchnic nerves (LSNs) as determined from the present study. The rostrocaudal positions of the LSNs are drawn to scale relative to the infrarenal length. Adobe Acrobat Reader is required to interact with the 3D model.

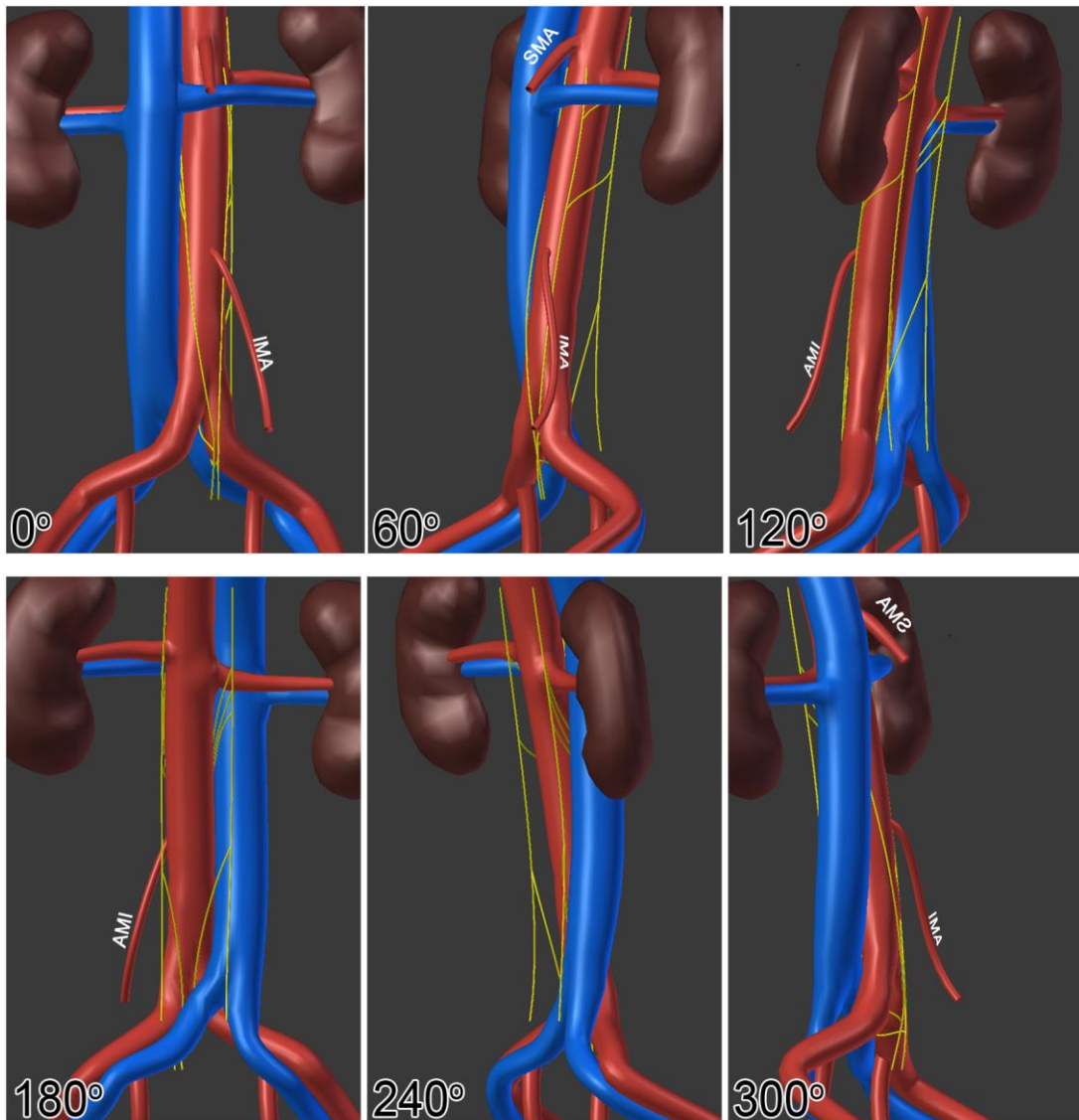


Figure 19. A representative model of the infrarenal lumbar splanchnic nerve anatomy.

A 3D representation of the data acquired from a single representative specimen (#1849). The first panel (0°) represents an anterior view of the infrarenal region, then each subsequent panel rotates 60° clockwise around the rostrocaudal axis (i.e. 180° represents the posterior view) IMA, inferior mesenteric artery; SMA, superior mesenteric artery.

In 85% (n = 22/26) of specimens, a retroaortic LSN was present joining the superior hypogastric plexus below the aortic bifurcation. They were observed bilaterally (n = 8), unilaterally (n_{LEFT} = 8, n_{RIGHT} = 3), or were considered to have inconclusive laterality (n_{LEFT} = 2, n_{RIGHT} = 1) due to a lack of contralateral examination because of exclusion due to prior trainee dissection. In the remaining 15% (n = 4/26) of specimens, retroaortic LSNs were bilaterally absent in three and not examined in one due to previous bilateral dissection in the region of interest by trainees. In contrast to the LSNs joining the aortic plexus, retroaortic LSNs invariably coursed behind the aorta/common iliac artery and anterior to the left common iliac vein to join the superior hypogastric plexus below the aortic bifurcation. Figure 20 demonstrates this relationship in the case of a right retroaortic LSN, and Figure 21 shows the anatomy of a typical left retroaortic LSN. As seen in Figure 17A, the retroaortic LSNs (yellow) had scant positional overlap with the LSNs that joined the aortic plexus (blue, teal and orange). When bilaterally present, the difference in position where each side joined the superior hypogastric plexus was rarely similar (mean $\Delta d_{\text{retroaortic LSN}} = 2.6 \pm 12.9\%$). Additional descriptive statistics are presented in Table 3.

To examine our prediction that adjacent LSNs on the same side course in parallel (i.e. project at the same orientation angle), the Δp (refer to Figure 17C) of each LSN was compared. In line with this prediction, the left and right LSNs were analyzed independent of one another. A significant difference was observed for both the right [Kruskal–Wallis H-test; $\chi^2(3) = 19.8$, $p = 0.00$] and left LSNs [Kruskal–Wallis H-test; $\chi^2(3) = 10.1$, $p = 0.02$]. Post hoc analyses indicated the Δp for the retroaortic LSNs (left mean rank $\Delta p_{\text{retroaortic LSN}} = 55.0$; right mean rank $\Delta p_{\text{retroaortic LSN}} = 55.8$) were significantly different from all other nerves on the right (mean rank $\Delta p_{\text{1st lowest LSN}} = 25.8$, mean rank $\Delta p_{\text{2nd lowest LSN}} = 33.3$, mean rank $\Delta p_{\text{3rd lowest LSN}} = 26.6$), and from the lowest two LSNs on the left (mean rank $\Delta p_{\text{1st lowest LSN}} = 32.6$, mean rank $\Delta p_{\text{2nd lowest LSN}} = 34.4$, mean rank $\Delta p_{\text{3rd lowest LSN}} = 38.4$). The results of the analysis are shown in Figure 22. It is important to note that this trend was also often observed at the individual level, as illustrated in specimen #1849 (Figure 17C and Figure 19)

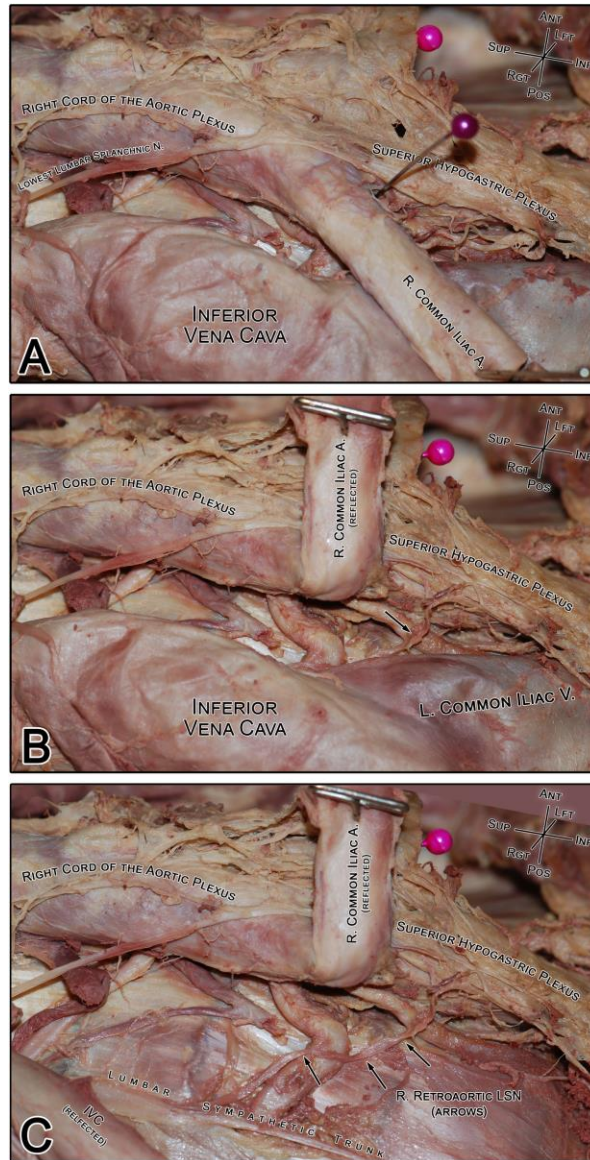


Figure 20. A representative right retroaortic lumbar splanchnic nerve.

A photograph of the gross dissection of a typical right retroaortic lumbar splanchnic nerve (LSN; specimen #1854). (A) The course of the retroaortic LSN cannot be clearly observed without moving the vasculature. For reference, the purple pin indicates the bifurcation of the aorta. (B) Reflecting the right common iliac artery reveals the underlying retroaortic nerve (black arrow) and its connection with the superior hypogastric plexus. (C) Lateral translation of the inferior vena cava reveals the entire course of the retroaortic nerve from the lumbar sympathetic trunk to the superior hypogastric plexus. IVC, inferior vena cava.

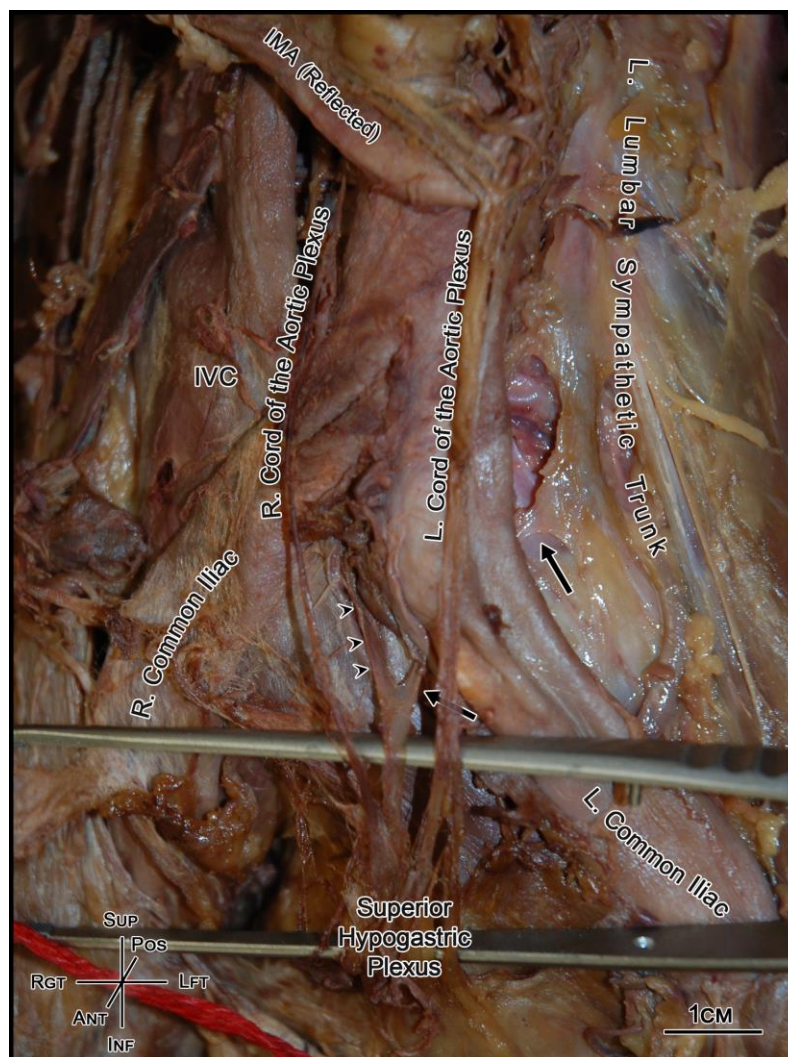


Figure 21. Retroaortic lumbar splanchnic nerves join the superior hypogastric plexus below the aortic bifurcation.

An anterior view of the infrarenal retroperitoneum showing the aortic bifurcation and superior hypogastric plexus. The overlaid superior hypogastric plexus (held up by forceps) is supplied by the right and left cords of the aortic plexus. In addition, it is supplied posteriorly by the right (arrowheads) and left (arrows) retroaortic lumbar splanchnic nerves (LSNs). Note, in this specimen, the bilateral retroaortic nerves converged into a common nerve immediately prior to joining superior hypogastric plexus; a unique observation to this study that has been briefly acknowledged in the previous literature (Learmonth, 1931). IMA, inferior mesenteric artery; IVC, inferior vena cava.

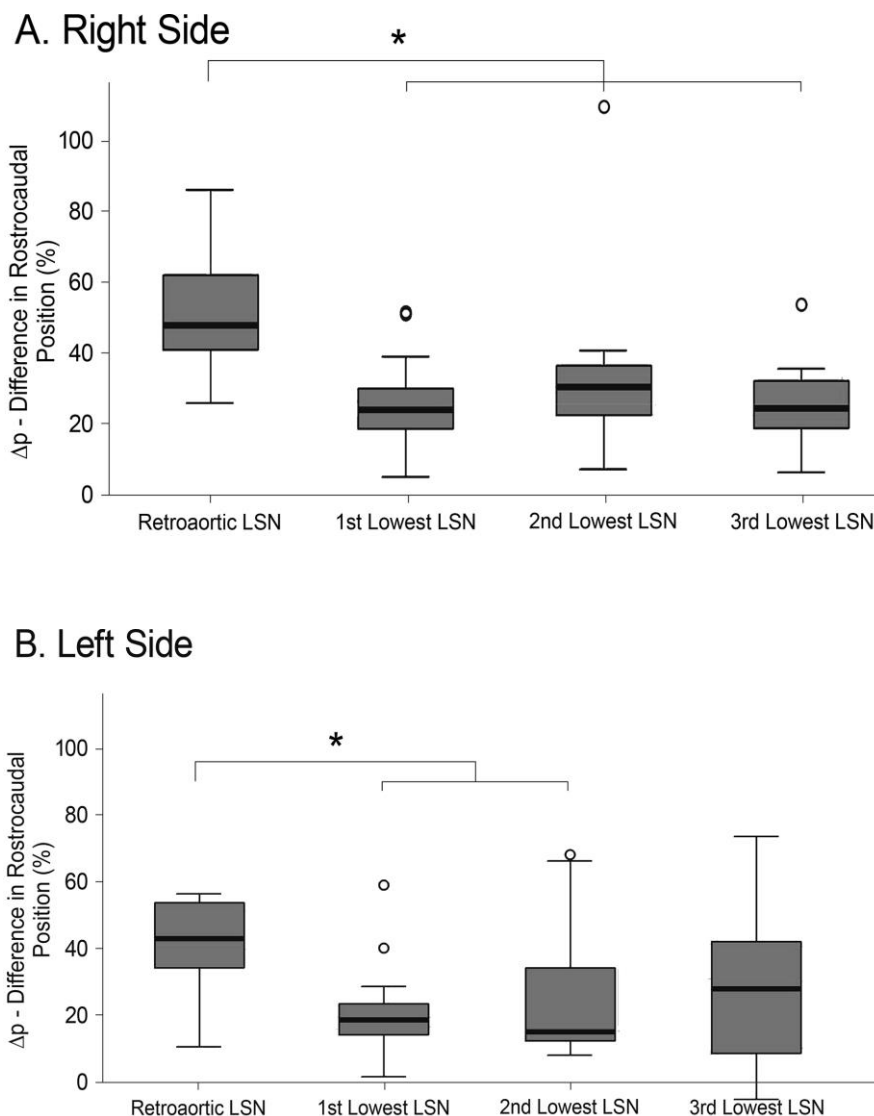


Figure 22. Lumbar splanchnic nerves joining the infrarenal aortic plexus course in parallel.

A box-whisker plot showing the difference in rostrocaudal position (Δp) of the origin and termination of each group of infrarenal lumbar splanchnic nerves (LSNs) on the right (A) and left (B) side of the body. Outliers, calculated by SPSS®, are represented by hollow dots. Significance at the $p < 0.05$ level is denoted with an asterisk. As shown, the LSNs joining the aortic plexus typically course in parallel, whereas the length and angle of the retroaortic LSNs on each side are significantly different. Note, the 3rd lowest LSN on the left was not significantly different from any other nerve.

4.5 Discussion

Variations in the LSNs adjoining the aortic and superior hypogastric plexuses may complicate complete nerve sparing during retroperitoneal surgery. As such, the present study used dissection of cadaveric specimens to quantify the prevalence, course and positional deviations of the infrarenal LSNs. In doing so, our results also clarified the inconsistency that is currently present in the literature regarding the path of the LSNs that join the superior hypogastric plexus below the bifurcation.

The LSNs joining the superior hypogastric plexus are occasionally illustrated in anatomical images, yet the course of these nerves relative to the common iliac vessels varies between authors (see Introduction). In the present study, this quandary was resolved by the fact that all LSNs joining the superior hypogastric plexus invariably coursed between the aorta/common iliac arteries and the left common iliac vein (Figure 18 – Figure 21). Despite exhibiting a consistent course, retroaortic LSNs were variably present, with confirmed unilateral absence in 11 (44%) specimens and complete bilateral absence in three (12%) specimens. However, when present, only one retroaortic LSN was observed per side. This contrasts drawings by Learmonth (1931) and descriptions from Woodburne & Burkel (1994) that suggest both the third and fourth LSNs join the superior hypogastric plexus. Although this arrangement was not observed in the present population, the potential for additional retroaortic fibers could very well exist in some people considering the acknowledged disorganization of lumbar sympathetic trunk ganglia that may predispose such a variation (Yeager & Cowley, 1948; Mitchell, 1953; Webber, 1958; Hollinshead, 1971; Gray, 1973; Woodburne & Burkel, 1994; Mirilas & Skandalakis, 2010; Gandhi et al., 2013).

Despite the extreme variation of the lumbar sympathetic nerves described in previous literature, recent qualitative observations of the aortic plexus have suggested that it is almost always bilateral in its organization, but not necessarily symmetrical in its positioning (Beveridge, Johnson, et al., 2015, 2016). Put another way, the aortic plexus often has the same number of LSNs on its left and right sides, but the position of these nerves may not be mirrored. Despite only minor differences between the overall mean positions of each LSN joining the aortic plexus (range $\Delta d = 1.7\text{--}3.7\%$), as seen in Figure

17B, our results show large standard deviations when averaging the positional differences of the left- and right-matched LSNs within individuals (mean $\Delta d_{\text{retroaortic LSN}} = 2.6 \pm 12.9\%$, mean $\Delta d_{\text{1st lowest LSN}} = 3.7 \pm 13.7\%$, mean $\Delta d_{\text{2nd lowest LSN}} = 1.7 \pm 22.1\%$, mean $\Delta d_{\text{3rd lowest LSN}} = 2.9 \pm 13.6\%$). This suggests that, on average, the positions of the contralateral LSNs are similar yet, within an individual, the position of a left LSN is rarely the same as the associated right LSN, and vice versa. These data are consistent with the suggestions and qualitative findings present in the previous literature (Beveridge, Johnson, et al., 2015; Beveridge, Allman, et al., 2016).

Given this clear positional variability of the infrarenal LSNs joining the aortic plexus within individuals, landmarking these fibers during surgery may be difficult to achieve. With that said, our findings indicate that there are no LSNs adjoining the aortic plexus within the lower 21.8% (left) and 24.1% (right) of the infrarenal abdominal aorta, with 98% (n = 118) originating from the sympathetic trunk above the level of the inferior mesenteric artery. In addition, the present study saw no evidence of a 'preaortic' LSN joining the superior hypogastric plexus below the bifurcation. This knowledge may be welcomed by surgeons tasked with removing caudal interaortocaval masses, or those posterior to the inferior mesenteric artery. Although the lower aspect of the abdominal aorta does not have any LSNs adjoining the aortic plexus, it is important to recognize the presence of the lumbar sympathetic trunk and retroaortic LSN overlying the anterior longitudinal ligament of the vertebral column in this region. As detailed above, the present study clarified the path of these LSNs as they coursed 'between' the common iliac arteries and left common iliac vein (Figure 17, Figure 20 and Figure 21). In addition, it was noted that despite the similar course (Δp) of the rest of the LSNs, the retroaortic LSNs are significantly longer and course more inferiorly ($p < 0.05$), perhaps owing to their necessary descent along the anterior vertebral column before extending to join the superior hypogastric plexus. On average, the retroaortic LSNs joined the superior hypogastric plexus $29.9 \pm 12.6\%$ (left) and $23.7 \pm 11.6\%$ (right) of the infrarenal abdominal aortic length 'inferior' to the bifurcation. Considering the function of the retroaortic LSNs remains unknown, surgeons attempting presacral lymphandectomies should consider sparing these fibers when possible (in addition to the sacral and pelvic splanchnic nerves, more inferiorly). Furthermore, surgeries that attempt to

circumnavigate the superior hypogastric plexus should be aware of these fibers given the aforementioned anatomy and possible risk for iatrogenic injury when mobilizing the superior hypogastric plexus.

In conclusion, the present study commonly observed two to three infrarenal LSNs joining the aortic plexus that varied greatly in rostrocaudal position. Within specimens, the position of the LSNs on one side rarely predicted the position of the contralateral nerves; however, adjacent nerves on the same side joining the aortic plexus typically coursed in parallel to one another. More inferiorly, retroaortic LSNs were observed in the majority (85%) of specimens, present both unilaterally and bilaterally with no obvious predominance to a particular side. Of note, the retroaortic LSNs exhibited a significantly different (more inferior) course relative to the LSNs joining the aortic plexus. Specifically, the retroaortic LSNs coursed between the common iliac arteries and the left common iliac vein before joining the superior hypogastric plexus below the bifurcation. Because the precise components of the retroperitoneal sympathetic plexuses involved in ejaculation still remain unknown, complete nerve sparing, when possible, remains the most prudent surgical approach. Ultimately, we are optimistic that the collective findings of the present study will further inform anatomists as well as benefit surgeons tasked with navigating and sparing these delicate structures during retroperitoneal and pelvic surgeries. Further studies are recommended to explore the specific role of the individual nerves described in this manuscript as they pertain to seminal emission and antegrade ejaculation to allow further refinement of nerve-sparing techniques.

4.6 Acknowledgements

The authors would like to extend thanks to: Haley Linklater and Kevin Walker for their contributions in the HEART Anatomy Lab; Christian Buchanan-Fraser for his help in data recording; Santiago Cobos C for his help modeling the 3D anatomy; and finally, the donors and their families – without their generosity, this research would not have been possible. The authors have no conflict of interest with the content of the manuscript.

4.7 Author Contributions

TSB, NEP, BLA, study conception; TSB, DEF, AG, data acquisition and analysis; TSB, DEF, figure illustrations; TSB, DEF, AG, MJ, BLA, data interpretation; TSB, DEF, BLA, writing and critical revision of the manuscript.

All authors contributed to the overall study design as well as providing edits and approval of the final version of the manuscript.

4.8 References

- 1) Beveridge TS, Allman BL, Johnson M, Power A, Sheinfeld J, Power NE (2016). Retroperitoneal Lymph Node Dissection: Anatomical and Technical Considerations from a Cadaveric Study. *The Journal of Urology*, 196(6), 1764–1771.
- 2) Beveridge TS, Johnson M, Power A, Power NE, Allman BL (2015). Anatomy of the nerves and ganglia of the aortic plexus in males. *Journal of Anatomy*, 226(1), 93–103.
- 3) Beveridge TS, Johnson M, Power NE, Allman BL (2016). Histological verification of the prehypogastric and ovarian ganglia confirms a bilaterally symmetrical organization of the ganglia comprising the aortic plexus in female human cadavers. *Journal of Anatomy*, 228(5), 805–811.
- 4) Beveridge TS, Power A, Johnson M, Power NE, Allman BL (2015). The lumbar arteries and veins: Quantification of variable anatomical positioning with application to retroperitoneal surgery. *Clinical Anatomy*, 28(5), 649–660.
- 5) Brindley GS, Sauerwein D, Hendry WF (1989). Hypogastric plexus stimulators for obtaining semen from paraplegic men. *British Journal of Urology*, 64(1), 72–77.
- 6) Coolen LM, Allard J, Truitt WA, McKenna KE (2004). Central regulation of ejaculation. *Physiology and Behavior*, 83(2), 203–215.
- 7) Crosby EC, Humphrey T, Lauer EW (1962). *Correlative Anatomy of the Nervous System*. New York: The Macmillan Company.
- 8) Duncan H, Jonck L (1965). The Presacral Plexus in Anterior Fusion of the Lumbar Spine. *South African Journal of Surgery*, 3(2), 93–96.
- 9) Dwight T, McMurrich J, Hamann C (1930). The Sympathetic System of Nerves. In G. Peirsol (Ed.), *Human Anatomy* (9th ed., pp. 1366–1374). London: J.B. Lippincott Company.
- 10) Flynn JC, Price CT (1984). Sexual Complication of Anterior Fusion of Lumbar Spine. *Spine*, 9(5), 489–492.
- 11) Gandhi KR, Verma VK, Chavan SK, Joshi SD, Joshi SS (2013). The morphology of lumbar sympathetic trunk in humans: A cadaveric study. *Folia Morphologica (Poland)*, 72(3), 217–222.
- 12) Gray H (1973). Sympathetic System. In C. Goss (Ed.), *Gray's Anatomy* (29th ed., pp. 1025–1036). Philadelphia: Lea & Febiger.

- 13) Heidenreich A, Pfister D (2012). Retroperitoneal lymphadenectomy and resection for testicular cancer: an update on best practice. *Therapeutic Advances in Urology*, 4(4), 187–205.
- 14) Hollinshead WH (1971). *Anatomy for Surgeons: Volume 2 - The Thorax, Abdomen, and Pelvis*. (2nd ed.). New York, NY: Harper & Row, Publishers.
- 15) Hsiao W, Deveci S, Mulhall JP (2012). Outcomes of the management of post-chemotherapy retroperitoneal lymph node dissection-associated anejaculation. *BJU International*, 110(8), 1196–1200.
- 16) Jewett MA, Groll RJ (2007). Nerve-Sparing Retroperitoneal Lymphadenectomy. *Urologic Clinics of North America*, 34(2), 149–158.
- 17) Jewett MA, Kong YP, Goldberg SD, Sturgeon JF, Thomas GM, Alison RE, Gospodarowicz MK (1988). Retroperitoneal Lymphadenectomy for Testis Tumor with Nerve Sparing for Ejaculation. *The Journal of Urology*, 139(6), 1220–1224.
- 18) Johnson RM, McGuire EJ (1981). Urogenital complications of anterior approaches to the lumbar spine. *Clinical Orthopaedics and Related Research*, (154), 114–118.
- 19) Learmonth JR (1931). A contribution to the neurophysiology of the urinary bladder in man. *Brain*, 54(2), 147–176.
- 20) Mirilas P, Skandalakis J (2010). Surgical Anatomy of the Retroperitoneal Spaces, Part IV: Retroperitoneal Nerves. *The American Surgeon*, 76(3), 253–262.
- 21) Mitchell G (1953). The Abdominal Part of the Sympathetic System. In *Anatomy of the Autonomic Nervous System* (1st ed., pp. 257–296). Edinburgh.
- 22) Motoc A, Rusu MC, Jianu AM (2010). The spermatic ganglion in humans: An anatomical update. *Romanian Journal of Morphology and Embryology*, 51(4), 719–723.
- 23) Netter F (2011). Back and Spinal Cord, Abdomen, Pelvis and Perineum. In J. Hansen (Ed.), *Atlas of Human Anatomy* (5th ed., Plates 160, 297, 319, 389, 390). Philadelphia PA: Saunders Elsevier.
- 24) O’Rahilly R (1986). The Abdomen. In A. Meier (Ed.), *Anatomy: A Regional Study of Human Structure* (5th ed., pp. 433–436). Philadelphia PA: W.B. Saunders Company.
- 25) Paraskevas G, Tsitsopoulos P, Papaziogas B, Natsis K, Martoglou S, Stoltidou A, Kitsoulis P (2008). Variability in superior hypogastric plexus morphology and its clinical applications: A cadaveric study. *Surgical and Radiologic Anatomy*, 30(6), 481–488.

- 26) Veroux P, D'Arrigo G, Veroux M, Giaquinta A, Lomeo A (2010). Sexual dysfunction after elective endovascular or hand-assisted laparoscopic abdominal aneurysm repair. *European Journal of Vascular and Endovascular Surgery*, 40(1), 71–75.
- 27) Webber RH (1958). A Contribution on the Sympathetic Nerves in the Lumbar Region. *The Anatomical Record*, 24(12), 581–604.
- 28) Woodburne R, Burkel W (1994). The Autonomic Nerves of the Abdomen. In *Essentials of Human Anatomy* (9th ed., pp. 502–507). New York, NY: Oxford University Press.
- 29) Yeager G, Cowley R (1948). Anatomical Observations on the Lumbar Sympathetics with Evaluation of Sympathectomies in Organic Peripheral Vascular Disease. *Annals of Surgery*, 127(5), 953–967.

CHAPTER 5

RETROPERITONEAL LYMPH NODE DISSECTION: ANATOMICAL AND TECHNICAL CONSIDERATIONS FROM A CADAVERIC STUDY

It is clear that a strong understanding of the neurovascular anatomy is required to perform a successful nerve-sparing retroperitoneal lymph node dissection (Jewett & Groll, 2007). Several studies exist, including the previous studies in this thesis, to provide a foundation for understanding the normal retroperitoneal neurovascular anatomy; however, the clinical usefulness of this knowledge is limited by a lack of studies examining the relationship of the neural and vascular anatomy as it pertains to surgical interventions.

In the present chapter, we address this issue by examining the relationship between the sympathetic nerves and the lumbar vessels in the context of performing a retroperitoneal lymph node dissection. A version of this chapter is published in the *Journal of Urology*, Volume 196, Issue 6, Pages 1764-1771.

5.1 Abstract

Purpose: Metastatic testis cancer in the retroperitoneum presents a technical challenge to urologists in the primary and post-chemotherapy settings. Where possible, bilateral nerve sparing retroperitoneal lymph node dissection should be performed in an effort to preserve ejaculatory function. However, this is often difficult to achieve, given the complex neurovascular anatomy. We performed what is to our knowledge the first comprehensive examination of the anatomical relationships between the sympathetic nerves of the aortic plexus and the lumbar vessels to facilitate navigation and nerve sparing during bilateral retroperitoneal lymph node dissection.

Materials and Methods: The relative anatomy of the infrarenal vasculature (lumbar vessels, right gonadal vein and inferior mesenteric artery) was investigated in 21 embalmed human cadavers. The complex relationships between these vessels and the sympathetic nerves of the aortic plexus were examined by dissection of an additional 8 fresh human cadavers.

Results: Analysis of the infrarenal vasculature from 21 cadavers demonstrated that the position of the right gonadal vein and the inferior mesenteric artery may be useful to locate the right superior lumbar vein and the first pair of infrarenal lumbar arteries as well as the common lumbar trunk (vein) and the second pair of infrarenal lumbar arteries, respectively. Furthermore, the lumbar splanchnic nerves supplying the aortic plexus were most often positioned anteromedial to the respective lumbar vein.

Conclusions: The current study describes the complex neurovascular relationships that are crucial to performing successful nerve sparing retroperitoneal lymph node dissection. Surgical techniques are also discussed. Collectively, these results may help surgeons decrease the rate of postoperative retrograde ejaculation and/or anejaculation.

5.2 Introduction

Retroperitoneal lymph node dissection for nonseminomatous germ cell tumors (NSGCT) remains an effective treatment for metastatic disease (Albers, 2004; Jewett & Groll, 2007; Stephenson et al., 2007; Katz & Eggener, 2009; Heidenreich & Pfister, 2012). With the advent of cisplatin-based chemotherapy, primary retroperitoneal lymph node dissection (RPLND) has become less popular for treating early stage disease (Jewett & Groll, 2007). Currently, surveillance and/or chemotherapy following orchiectomy remains the common practice for managing stage I disease, whereas chemotherapy is the primary treatment for low risk stage II NSGCT (Heidenreich & Pfister, 2012). Therefore, with the improvement in treating early stage NSGCT, RPLND is most often performed to treat advanced staged disease and post-chemotherapy residual masses. However, primary RPLND may re-emerge as a treatment for early stage disease, given our understanding of the increased long-term risk of secondary malignancies and cardiovascular morbidity after chemotherapy (Haugnes et al., 2010, 2012).

Today modified surgical templates that limit contralateral dissection (Weissbach & Boedefeld, 1987; Donohue et al., 1993; Janetschek et al., 1994; Sheinfeld & Herr, 1998; Nelson et al., 1999) continue to be used at many international centers to improve the rate of antegrade ejaculation postoperatively (Richie, 1990; Doerr et al., 1993; Katz & Eggener, 2009). However, studies have since challenged the usefulness of these templates

based on viable extratemplate disease (Carver et al., 2007; Eggener et al., 2007). It is estimated that in the post-chemotherapy setting at least 7% to 32% of patients would have extratemplate disease depending on the template used (Carver et al., 2007). Because an effort to spare ejaculation should never be made at the risk of incomplete cancer resection (Jewett & Groll, 2007), it was concluded that a full bilateral infrahilar template spanning the left renal vein superiorly, the ureters laterally and the aortic bifurcation inferiorly is most prudent and nerve sparing should only be performed where possible (Carver et al., 2007).

When performed, nerve sparing in the post-chemotherapy setting is associated with variable rates of antegrade ejaculation. For example, in a 2012 review Heidenreich and Pfister reported ejaculatory dysfunction in 75% of patients who underwent bilateral post-chemotherapy RPLND (Heidenreich & Pfister, 2012), while Pettus et al found that antegrade ejaculation was maintained in 79% of their patients treated with bilateral post-chemotherapy RPLND (Pettus et al., 2009). Although differences in the stage and/or the size of the residual mass are apparent between the reports, surgeon comfort with the normal neurovascular anatomy of the retroperitoneum is a significant factor in the success of RPLND (Jewett & Groll, 2007) and a possible contributing factor to these disparate results. Surprisingly, literature on the neurovascular anatomy of the infrarenal retroperitoneum is relatively sparse and much of what is known about the topic has only emerged recently.

Today it is generally accepted that the lumbar arteries are regularly spaced and bilaterally paired with the second to fourth pairs commonly encountered below the level of the left renal vein (LRV) (Baniel et al., 1995; Beveridge, Power, et al., 2015). In contrast, the lumbar veins are variable, unpaired vessels that preferentially drain into the left posterior side of the inferior vena cava (IVC) (Baniel et al., 1995; Beveridge, Power, et al., 2015). They are positioned at a distance from each other that segmentally increases closer to the ilio caval confluence (Beveridge, Power, et al., 2015). Studies have also described the anatomy of the sympathetic nerves comprising the aortic plexus. Specifically, it has been

shown that the aortic plexus is supplied by at least two lumbar splanchnic nerves¹ (LSN) on each side and it is composed of two parallel nerves (cords), each containing two major ganglia (Beveridge, Johnson, et al., 2015). Collectively, these studies provide a strong foundation for understanding the retroperitoneal neurovascular anatomy. However, the clinical usefulness of this information is limited by the lack of studies integrating the mentioned anatomy by examining their relationships with each other.

We addressed this issue by examining the relationship between the sympathetic nerves and the lumbar vessels within the boundaries of an infrahilar bilateral template. This was achieved by dissecting human cadavers. Our findings are extrapolated to discuss strategies to navigate these structures during RPLND.

5.3 Materials and Methods

In a population of 22 embalmed cadavers with no evidence of retroperitoneal disease we measured the positions of the lumbar vessels, the inferior mesenteric artery (IMA) and the right gonadal vein from the inferior border of the LRV. All measurements were normalized by the length of the infrarenal abdominal aorta before statistical analysis. Since these cadavers had been previously dissected by medical students, we excluded one specimen in which the retroperitoneum was grossly over dissected.

The relationship of the sympathetic nerves comprising the aortic plexus to that of the lumbar vessels was explored during the dissection of 8 fresh cadavers using a transabdominal approach.

¹In much of the urological literature the lumbar splanchnic nerves are referred to as postganglionic nerves/fibers (Eggenger et al., 2007; Jewett & Groll, 2007; Katz & Eggenger, 2009; Pettus et al., 2009). In the current report, the former (anatomical) nomenclature is used. This decision was made because the latter (urological) nomenclature misconstrues the fact that these nerves mainly comprise preganglionic/presynaptic axons that do not synapse until the prevertebral ganglia of the aortic plexus (Jänig & McLachlan, 1987).

All data were obtained in accordance with the Western University committee for cadaveric use in research (approval 15052013). Statistical analyses were completed with SPSS® Statistics 20 and power was determined with G*Power, version 3.1.9.2 (<http://www.gpower.hhu.de/en.html>). The final vascular data set was analyzed using the Welch ANOVA with sufficient power ($1 - \beta = 0.8$, $\alpha = 0.05$) to detect small to moderate (0.30) effect size. All assumptions of the statistical test were satisfied.

5.4 Results

5.4.1. Infrarenal Vascular Relationships

In the included population of 21 embalmed cadavers several vascular relationships were identified (Figure 23). A significant difference in vessel position was found (Welch $F_{8,59.3} = 130.7$, $p < 0.05$, partial $\eta^2 = 0.868$). In particular, Games-Howell post-hoc analyses indicated significantly different positions between the superior vessels (right gonadal vein, right superior lumbar vein and second pair of lumbar arteries), middle vessels (common lumbar trunk, IMA and third pair of lumbar arteries) and inferior vessels (left and right inferior lumbar veins, and fourth pair of lumbar arteries). In each vessel grouping (e.g., superior vessels, including right gonadal vein vs right superior lumbar vein vs second pair of lumbar arteries) no significant differences in position were seen (Figure 23).

These findings suggest that the right gonadal vein may be useful to approximate the location of the right superior lumbar vein, if present, and/or the second pair of lumbar arteries. Likewise, the IMA may be useful to approximate the location of the common lumbar trunk, if present, and/or the third pair of lumbar arteries.

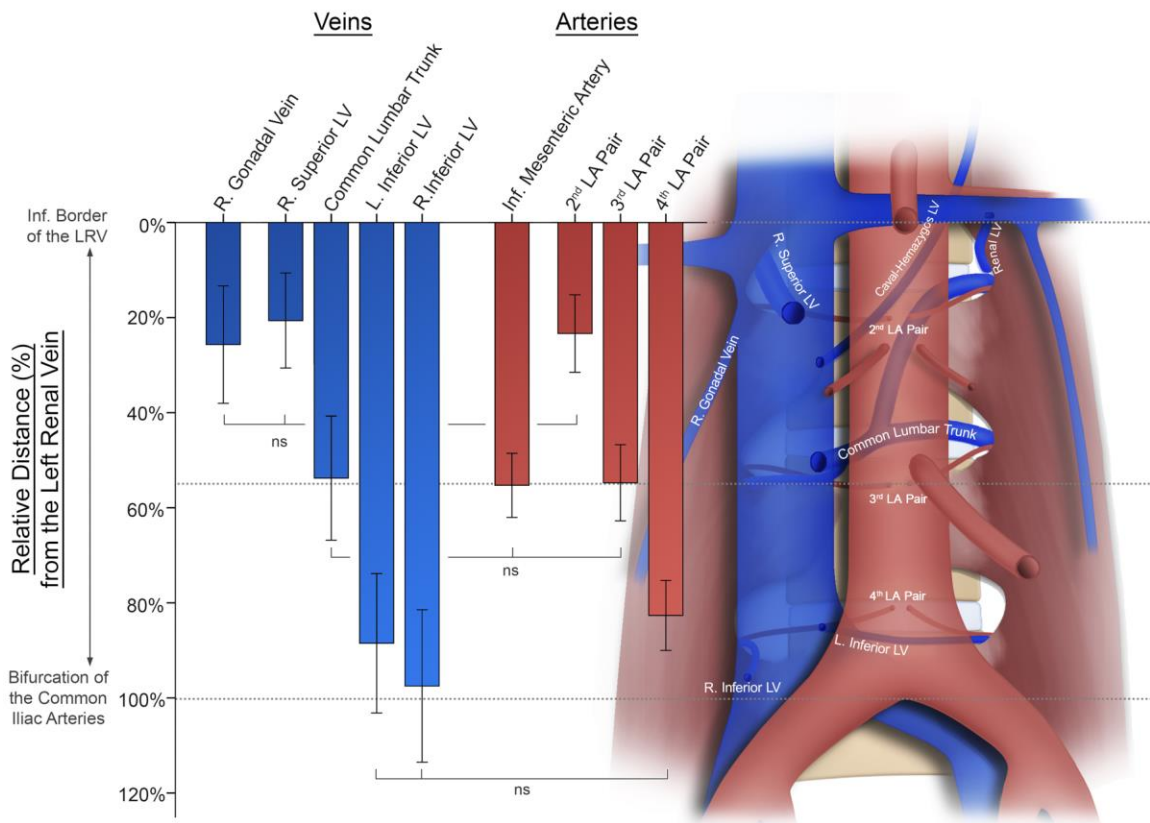


Figure 23. Lumbar arteries and veins can be landmarked within three regions of the infrarenal great vessels using structures visible from an anterior approach.

Relative position of infrarenal lumbar arteries (LA) and veins (LV), right gonadal vein and inferior mesenteric artery. Posthoc analyses demonstrated statistically significant difference between superior vessels, including right gonadal vein, right superior lumbar vein and second pair of lumbar arteries, middle vessels, including common lumbar trunk, IMA and third pair of lumbar arteries, and inferior vessels, including left and right inferior lumbar veins, and fourth pair of lumbar arteries. In each vessel grouping (e.g., superior vessel group of right gonadal vein vs right superior lumbar vein vs second pair of lumbar arteries) no significant difference (ns) in position was seen. Error bars represent ± 1 SD. Dotted gray lines indicate position of left renal vein inferior border, IMA origin and bifurcation of common iliac arteries.

5.4.2. Sympathetic Nerves and Infrarenal Lumbar Vessels

In eight fresh cadavers, the relationship of the sympathetic nerves to the lumbar vessels was explored. On the right side, the origin of the first infrarenal LSN coursed from the sympathetic chain, often just superior to the inferior border of the LRV (Figure 24). Its position in the interaortocaval adipose tissue was often complicated, given the close association with the right superior lumbar vein, which was often observed in this region. Usually the first infrarenal LSN coursed medial to this lumbar vein, where it then intersected the right cord of the aortic plexus near the right testicular artery.

The second infrarenal LSN coursed in parallel to the first one, originating from the sympathetic chain approximately one vertebral level caudal. This nerve most often coursed anteromedial to the middle common lumbar trunk and/or the third (second infrarenal) lumbar artery before intersecting the right cord of the aortic plexus at the position of the prehypogastric ganglion (Figure 24A).

As seen in this specimen, the neurovascular anatomy may be complicated by the presence of an accessory LSN, which often runs in parallel with the LSN proper. This neural variation is common to the right and the left sides of the aortic plexus.

On the left side, the first infrarenal LSN originated from the sympathetic chain near the level of the inferior border of the LRV. It typically extended anteroinferior to merge with the intermesenteric nerve from the more rostral sympathetic plexuses, forming the left cord of the aortic plexus (Figure 24). The renal-lumbar vein, if present, often complicated exposure of a portion of the sympathetic plexus, given its position between the first infrarenal LSN and the left intermesenteric nerve (Figure 24B) or lateral to both nerves. The second infrarenal LSN typically branched from the sympathetic chain more superiorly than its right-side counterpart. Its origin was at approximately the level of the left testicular artery. It was seen branching off the sympathetic chain as high as where the second (first infrarenal) pair of lumbar arteries disappeared deep to the psoas major.

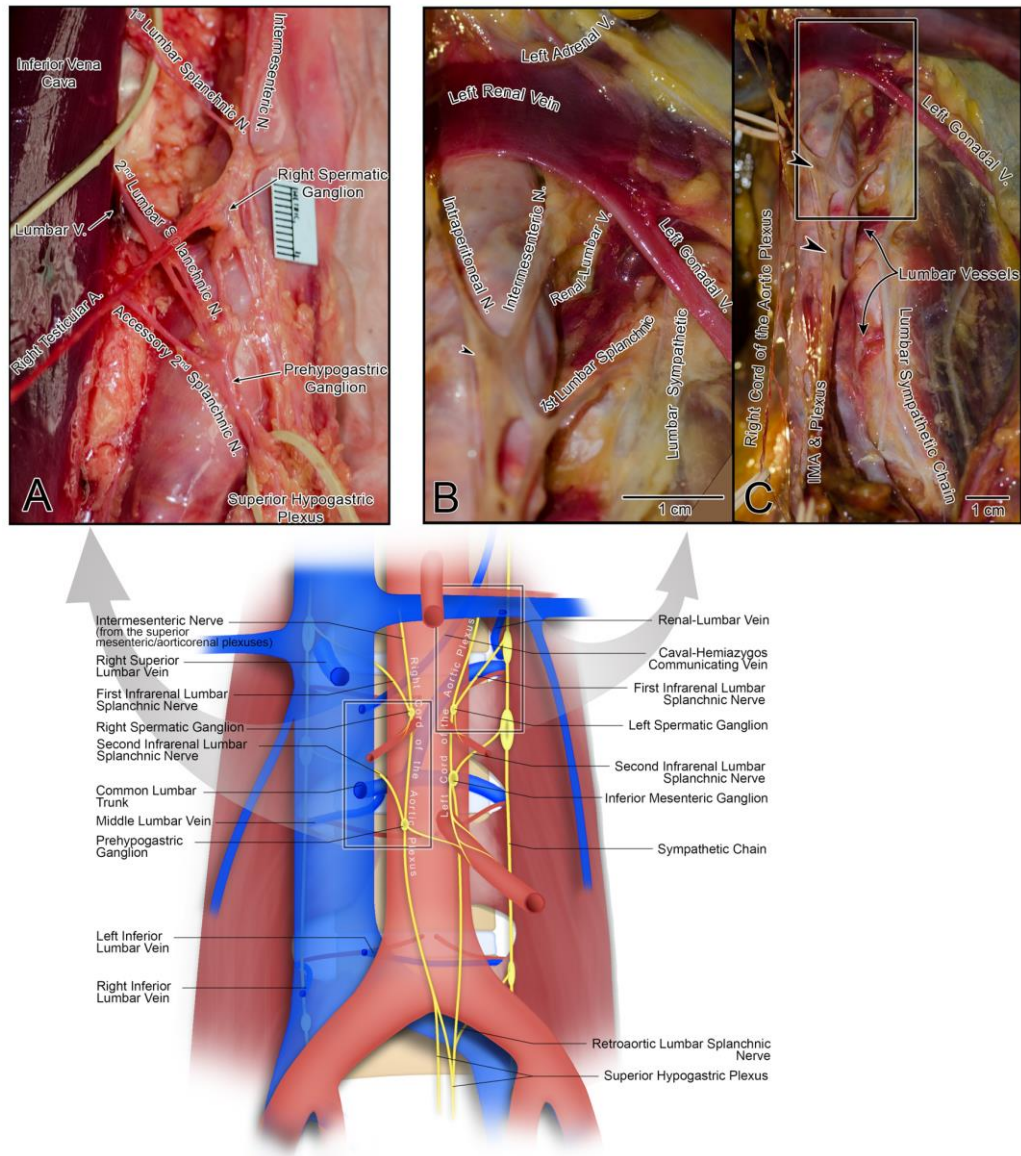


Figure 24. Neurovascular relationships relevant to nerve-sparing RPLND.

Relationships of sympathetic nerves and ganglia of aortic plexus to position of infrarenal lumbar arteries and veins. A) neurovascular relationship of second infrarenal lumbar splanchnic nerve to lumbar vein and to accessory second infrarenal lumbar splanchnic nerve. B) In this specimen, renal-lumbar vein joins left renal vein, coursing between intermesenteric nerve and first infrarenal lumbar splanchnic nerve. In some specimens, first infrarenal lumbar splanchnic nerve may course anteromedial to this vein. C) Full left side dissection of cadaver. Arrowheads indicate approximate position of 2 left side constituent ganglia of aortic plexus.

5.5 Discussion

Several studies describe the anatomy of the nerves and vasculature in the retroperitoneum as it pertains to surgical interventions (Banagan et al., 1976; Lu et al., 2009; Mirilas & Skandalakis, 2010). However, given the complexities of retroperitoneal masses during bilateral RPLND, nerve sparing and complete vascular control of the lumbar vessels may be difficult to achieve (Jewett & Groll, 2007). In the current study, we describe the neurovascular relationships of the lumbar vessels and the sympathetic nerves of the aortic plexus, which may aid in managing these structures during RPLND. We discuss our findings in a regional context as it pertains to the practice of RPLND. Note that nerve sparing is never performed at the cost of potentially leaving residual tumor (Jewett & Groll, 2007; Scardino et al., 2011).

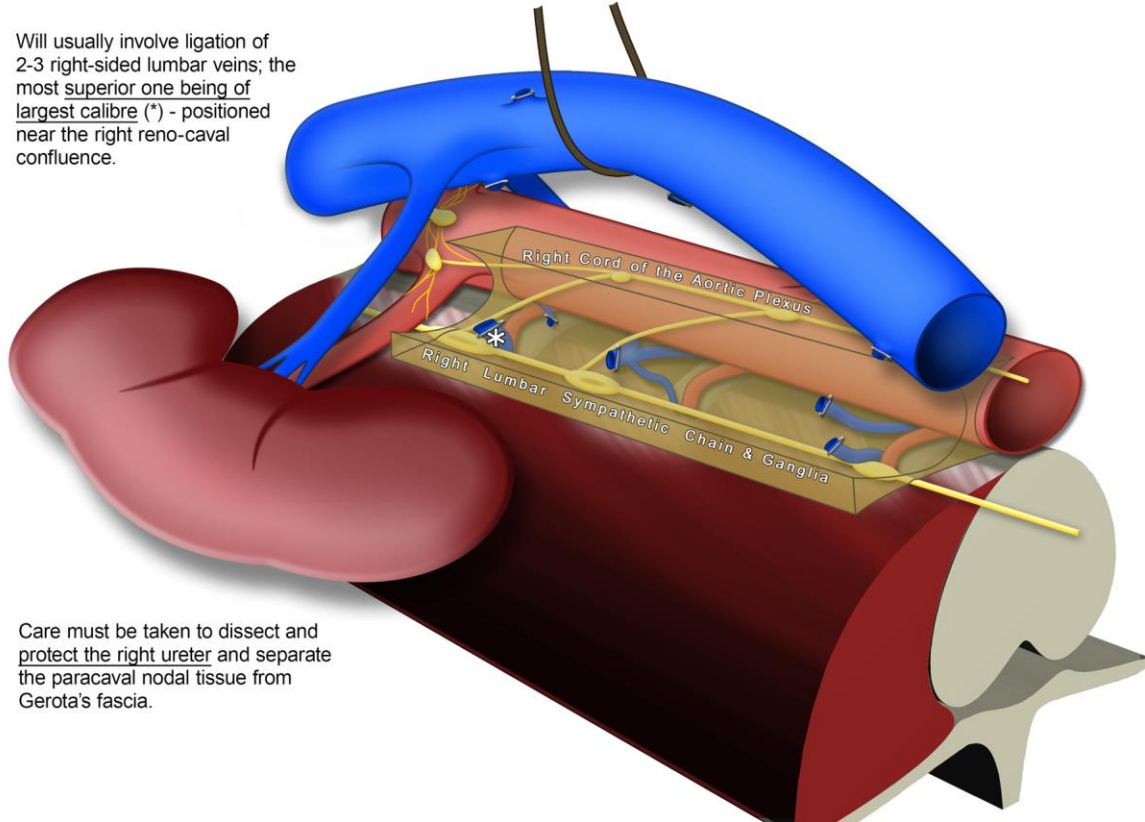
5.5.1. Paracaval Node Dissection

Care must be taken to dissect and protect the right ureter while separating the paracaval nodal tissue from Gerota's fascia (Scardino et al., 2011). After ligating the right gonadal vein (Scardino et al., 2011), nodal tissue can be dissected from the caval adventitia with ease because this region is void of sympathetic nerves (Mirilas & Skandalakis, 2010). With the IVC rolled left, a variable number of lumbar veins (usually two or three) may be encountered that drain the right side. Typically, the right superior lumbar vein (usually of large diameter) will be located near the right renocaval junction, often superior to the right gonadal vein. Midway along the infrarenal IVC a smaller lumbar vein may be seen that has a tendency to drain into the left side of the IVC or form a common trunk with one of the left side lumbar veins (Beveridge, Power, et al., 2015). Lastly, the right inferior lumbar vein may be noted draining near the level of the ilio caval confluence.

With a right-side approach, the plane between the paracaval nodal tissue and the fascia overlying the psoas major muscle can be cleaved to expose the sympathetic chain and the origin of the LSNs. In a minority of individuals, a lumbar vessel may aberrantly course lateral to the sympathetic chain.

PARACAVAL & INTERAORTOCAVAL NODAL DISSECTION

Will usually involve ligation of 2-3 right-sided lumbar veins; the most superior one being of largest calibre (*) - positioned near the right reno-caval confluence.



Care must be taken to dissect and protect the right ureter and separate the paracaval nodal tissue from Gerota's fascia.

Figure 25. Visualizing the neurovascular anatomy pertinent to a nerve-sparing interaortocaval nodal dissection.

Position of sympathetic nerves in interaortocaval nodal tissue (translucent brown area). This image shows how dissection in plane of caval adventitia allows for ligation of right and left lumbar veins as they join IVC without complication by sympathetic nerves. After ligation IVC can be mobilized to facilitate interaortocaval node dissection (Figure 26).

PARACAVAL & INTERAORTOCAVAL NODAL DISSECTION (CONT.)

Using the split-and-roll technique on the IVC, remaining lumbar veins can be isolated and divided.

A minimum of two infrarenal lumbar splanchnic nerves are present. The splanchnic nerves (*) are identified at their origin from the right sympathetic chain under the IVC as the first step of nerve-sparing.

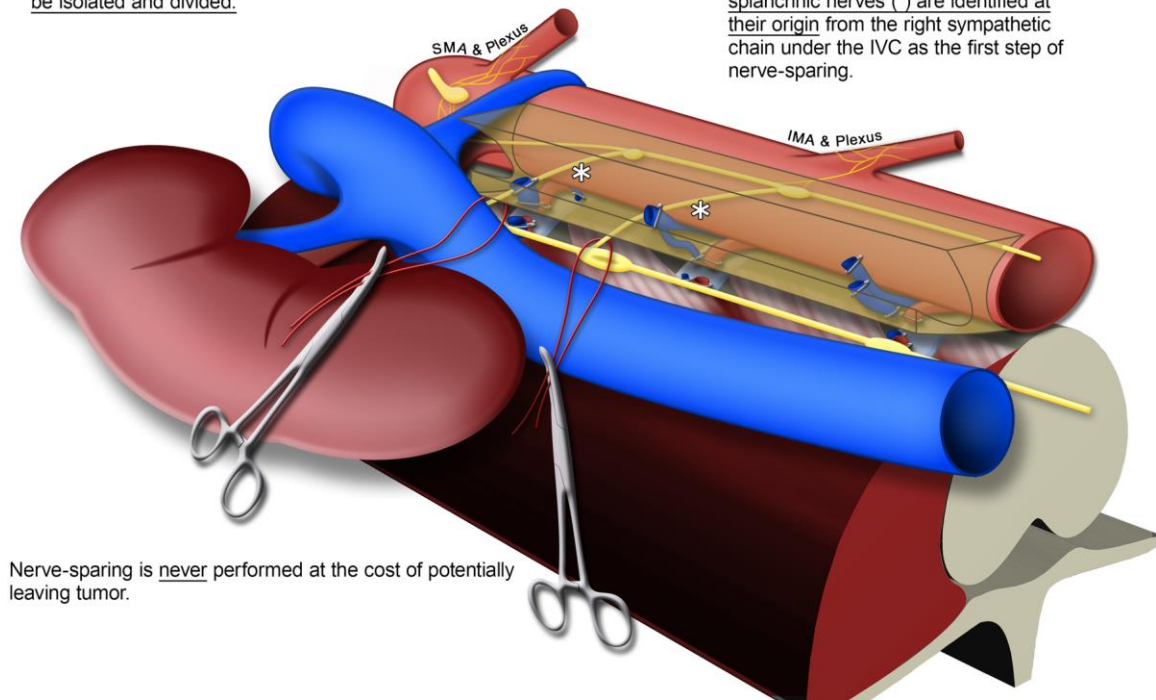


Figure 26. Vessel loops are used to maintain visualization of lumbar splanchnic nerves at their origin.

First nerve sparing steps after IVC mobilization. With IVC rolled laterally plane between nodal tissue (translucent brown area) and fascia overlying psoas major muscle can be separated to identify right sympathetic chain and origin of lumbar splanchnic nerves. Vessel loops help maintain visualization of infrarenal lumbar splanchnic nerves as they are spared from interaortocaval nodal tissue. SMA, superior mesenteric artery.

5.5.2. Interaortocaval Node Dissection

Using the split-and-roll technique on the IVC, the plane between the interaortocaval nodal tissue and the caval adventitia can be separated without encountering sympathetic nerves. This plane can be followed to identify the left lumbar veins (variable), which were typically observed draining centrally (i.e., between the most cranial and caudal right lumbar veins) and into the left side of the IVC. Usually, two left lumbar veins were observed, of which the largest and most prevalent (the common lumbar trunk) may be landmarked using the IMA. It often receives multiple left side tributaries. Therefore, ligation of this singular vessel should be noted because it may necessitate multiple para-aortic ligations.

The second most common vessel, the left inferior lumbar vein, is located closer to the ilio caval confluence, approximately where the right common iliac artery crosses the IVC. If a right inferior lumbar vein is present, the left one is typically slightly rostral. After ligation, full control of the lumbar veins should be achieved and the IVC can be fully mobilized (Figure 25).

With the right sympathetic chain exposed, meticulous dissection should be done anterior to identify the LSNs. Usually, there are two LSNs joining the infrarenal portion of the aortic plexus, spaced approximately one vertebral level apart. However, the presence of accessory LSNs of comparable size coursing near and in parallel with the LSN proper is a common possibility. Vessel loops should be placed around the LSNs for reference (Figure 26) (Scardino et al., 2011).

Following the right LSNs anterior will reveal the right cord of the aortic plexus, a longitudinal nerve running along the anteromedial aspect of the infrarenal abdominal aorta, which contributes to the formation of the superior hypogastric plexus (Beveridge, Johnson, et al., 2015). With the right-side nerves spared, the preaortic nodes can be split with care taken to preserve any preaortic nerves that may connect with the contralateral cord of the aortic plexus. Most often branches extend from the prehypogastric ganglion near the intersection of the second infrarenal LSN and the right cord to join the inferior

mesenteric plexus. Subsequently, dissection can proceed along the aortic adventitia to identify the right lumbar arteries.

Usually, three pairs of lumbar arteries are present along the infrarenal abdominal aorta. The position of the middle pair (the third lumbar arteries) is approximated using the origin of the IMA (Figure 23). Once identified, the adjacent pairs of lumbar arteries can be identified at a distance away equal to a third of the length of the infrarenal abdominal aorta (Beveridge, Power, et al., 2015).

5.5.3. Preaortic Node Dissection

Preaortic node removal will primarily focus on preserving the rostral portions of the cords (intermesenteric nerves). Nerves of interest to maintain antegrade ejaculation should course posterior to the LRV. This is opposed to intraperitoneal nerves entering the mesentery, which during RPLND appear to course anterior to the LRV after the abdominal viscera is reflected superior. To aid dissection the IMA may be sacrificed if an adequate blood supply to the colon is maintained by the marginal artery (of Drummond) (Scardino et al., 2011).

5.5.4. Para-aortic Node Dissection

Para-aortic dissection is often challenging, particularly at the superior border, which can be a potential source of in-field recurrence. Care must be taken to identify and preserve the left ureter, which often requires ureterolysis if a residual mass is present. Dissection can proceed along the plane of the aortic adventitia to identify the left lumbar artery or arteries. Studies have indicated a strong tendency for the lumbar arteries to be positioned at similar levels (Baniel et al., 1995; Beveridge, Power, et al., 2015). Therefore, the position of the right lumbar arteries can facilitate locating their respective left side pairs.

Sparing the intermesenteric nerve as it joins with the first infrarenal LSN may be complicated by a renal-lumbar vein coursing lateral to the aorta that drains aberrantly into the LRV at a position just posterior to the left gonadal vein (Li et al., 2011; Beveridge, Power, et al., 2015). The intermesenteric nerve will course medial to the renal-lumbar

vein (Figure 24B and Figure 27). The first infrarenal LSN can course anteromedial or posterolateral to this vein.

While the organization of the aortic plexus is usually bilaterally symmetrical (Beveridge, Johnson, et al., 2015), it should be appreciated that it rarely has a bilaterally symmetrical position. Thus, the position of the right LSNs cannot be used to landmark the left LSNs.

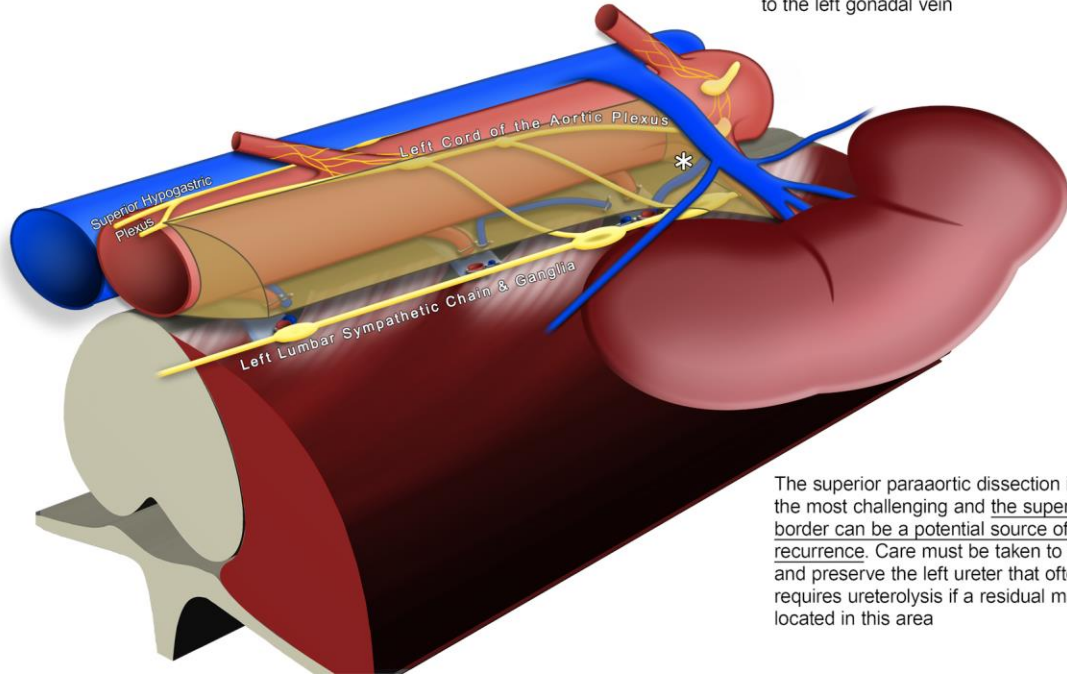
Near the origin of the IMA, at about the intersection of the second infrarenal LSN with the left cord of the aortic plexus, the inferior mesenteric ganglion can be identified. Numerous branches will extend along the IMA to form the inferior mesenteric plexus to the hindgut. However, the left cord will continue posterior to the IMA to join the right cord, forming the superior hypogastric plexus, which is usually situated left of the aortic midline (Lu et al., 2009).

The inferior para-aortic nodal tissue can be accessed by incising the white line of Toldt to mobilize the descending colon, facilitating medial reflection of the distal bowels and their mesentery (Scardino et al., 2011). Care should be taken to identify the distal lumbar sympathetic chain and the retroaortic LSN, if present (Figure 23). Note that retroaortic LSNs will course between the left common iliac artery and vein to join the superior hypogastric plexus directly (Beveridge, Johnson, et al., 2015).

PREAORTIC & PARAAORTIC NODAL DISSECTION

The inferior mesenteric artery can be sacrificed to aid dissection if adequate blood supply to the colon is maintained by the marginal artery (of Drummond)

Dissection of the paraaortic nerves and lymphatic tissue may be complicated by the presence of a lumbar vein (*) draining aberrantly into the left renal vein, posterior to the left gonadal vein



The superior paraaortic dissection is often the most challenging and the superior border can be a potential source of in-field recurrence. Care must be taken to identify and preserve the left ureter that often requires ureterolysis if a residual mass is located in this area

Figure 27. Visualizing the neurovascular anatomy pertinent to a nerve-sparing para-aortic nodal dissection.

Lateral perspective of preaortic and para-aortic nodal dissection. Lumbar vessels are ligated as they disappear deep to psoas major. Care should be taken to identify sympathetic chain in this dissection plane along with associated lumbar splanchnic nerves, which course through para-aortic nodal packet (translucent brown area). Often ligation of more lumbar veins may be needed, given tendency of upper veins to drain into common trunk along middle of IVC, which is ligated during interaortocaval dissection. At cranial border dissection is often complicated by lumbar vein aberrantly draining into left renal vein, which intimately courses along first infrarenal lumbar splanchnic nerve and/or the intermesenteric nerve from superior mesenteric/aorticorenal plexuses.

5.6 Conclusions

We examined the complex relationships of the lumbar vessels and sympathetic nerves in the infrarenal retroperitoneum. This information is crucial when performing successful nerve sparing bilateral RPLND and it may decrease the incidence of postoperative retrograde ejaculation and/or anejaculation.

5.7 Acknowledgments

Haley Linklater and Kevin Walker, HAASE Anatomy Laboratory, and Christopher Balestrini, Department of Anatomy and Cell Biology, Schulich School of Medicine and Dentistry, Western University, assisted with cadaveric dissection.

5.8 References

- 1) Albers P (2004). Resection of retroperitoneal residual tumor after chemotherapy for testicular cancer indication and surgical techniques. *Critical Reviews in Oncology/Hematology*, 50(1), 79–85.
- 2) Banagan K, Gelb D, Poelstra K, Ludwig S (1976). Anatomic Mapping of the Lumbar Nerve Roots during a Direct Lateral Transpsoas Approach to the Spine: A Cadaveric Study. *Spine*, 36(11), 687–691.
- 3) Baniel J, Foster R, Donohue J (1995). Surgical Anatomy of the Lumbar Vessels: Implication for Retroperitoneal Surgery. *Journal of Urology*, 153(5), 1422–1425.
- 4) Beveridge TS, Johnson M, Power A, Power NE, Allman BL (2015). Anatomy of the nerves and ganglia of the aortic plexus in males. *Journal of Anatomy*, 226(1), 93–103.
- 5) Beveridge TS, Power A, Johnson M, Power NE, Allman BL (2015). The lumbar arteries and veins: Quantification of variable anatomical positioning with application to retroperitoneal surgery. *Clinical Anatomy*, 28(5), 649–660.
- 6) Carver BS, Shayegan B, Eggener S, Stasi J, Motzer RJ, Bosl GJ, Sheinfeld J (2007). Incidence of metastatic nonseminomatous germ cell tumor outside the boundaries of a modified postchemotherapy retroperitoneal lymph node dissection. *Journal of Clinical Oncology*, 25(28), 4365–4369.
- 7) Doerr A, Skinner EC, Skinner DG (1993). Preservation of ejaculation through a modified retroperitoneal lymph node dissection in low stage testis cancer. *The Journal of Urology*, 149(6), 1472–1474.
- 8) Donohue JP, Thornhill J, Foster R, Rowland R, Bihrlé R (1993). Retroperitoneal lymphadenectomy for clinical stage A testis cancer (1965 to 1989): modifications of technique and impact on ejaculation. *Journal of Urology*, 149(2), 237–243.
- 9) Eggener SE, Carver BS, Sharp DS, Motzer RJ, Bosl GJ, Sheinfeld J (2007). Incidence of Disease Outside Modified Retroperitoneal Lymph Node Dissection Templates in Clinical Stage I or IIA Nonseminomatous Germ Cell Testicular Cancer. *The Journal of Urology*, 177(3), 937–943.
- 10) Haugnes HS, Bosl GJ, Boer H, Gietema JA, Brydøy M, Oldenburg J, ... Fosså SD (2012). Long-term and late effects of germ cell testicular cancer treatment and implications for follow-up. *Journal of Clinical Oncology*, 30(30), 3752–3763.
- 11) Haugnes HS, Wethal T, Aass N, Dahl O, Klepp O, Langberg CW, ... Fosså SD (2010). Cardiovascular risk factors and morbidity in long-term survivors of testicular cancer: A 20-year follow-up study. *Journal of Clinical Oncology*, 28(30), 4649–4657.

- 12) Heidenreich A, Pfister D (2012). Retroperitoneal lymphadenectomy and resection for testicular cancer: an update on best practice. *Therapeutic Advances in Urology*, 4(4), 187–205.
- 13) Janetschek G, Reissigl A, Peschel R, Hobisch A, Bartsch G (1994). Laparoscopic retroperitoneal lymph node dissection for clinical stage I nonseminomatous testicular tumor. *Urology*, 44(3), 382–391.
- 14) Jänig W, McLachlan EM (1987). Organization of lumbar spinal outflow to distal colon and pelvic organs. *Physiological Reviews*, 67(4), 1332–404.
- 15) Jewett MA, Groll RJ (2007). Nerve-Sparing Retroperitoneal Lymphadenectomy. *Urologic Clinics of North America*, 34(2), 149–158.
- 16) Katz MH, Eggener SE (2009). The evolution, controversies, and potential pitfalls of modified retroperitoneal lymph node dissection templates. *World Journal of Urology*, 27(4), 477–483.
- 17) Li G, Dong J, Lu JS, Zu Q, Yang SX, Li HZ, ... Zhang X (2011). Anatomical variation of the posterior lumbar tributaries of the left renal vein in retroperitoneoscopic left living donor nephrectomy. *International Journal of Urology*, 18(7), 503–509.
- 18) Lu S, Xu Y, Chang S, Zhang Y, Shi J, Ding ZH, ... Zhong S (2009). Clinical anatomy study of autonomic nerve with respect to the anterior approach lumbar surgery. *Surgical and Radiologic Anatomy*, 31(6), 425–430.
- 19) Mirilas P, Skandalakis J (2010). Surgical Anatomy of the Retroperitoneal Spaces, Part IV: Retroperitoneal Nerves. *The American Surgeon*, 76(3), 253–262.
- 20) Nelson J, Chen R, Bishoff J, Oh W, Kantoff P, Donehower R, Kavoussi L (1999). Laparoscopic retroperitoneal lymph node dissection for clinical stage I nonseminomatous germ cell testicular tumors. *Urology*, 54(6), 1064–1067.
- 21) Pettus JA, Carver BS, Masterson T, Stasi J, Sheinfeld J (2009). Preservation of Ejaculation in Patients Undergoing Nerve-Sparing Postchemotherapy Retroperitoneal Lymph Node Dissection for Metastatic Testicular Cancer. *Urology*, 73(2), 328–331.
- 22) Richie JP (1990). Clinical stage 1 testicular cancer: The role of modified retroperitoneal lymphadenectomy. *Journal of Urology*, 144(5), 3–4.
- 23) Scardino P, Linehan W, Zelefsky M, Vogelzang N (2011). Comprehensive Textbook of Genitourinary Oncology (L. W. & Wilkins, Ed.) (4th ed.). Philadelphia PA.
- 24) Sheinfeld J, Herr H (1998). Role of surgery in management of germ cell tumor. *Seminars in Oncology*, 25(2), 203–209.

- 25) Stephenson AJ, Bosl GJ, Motzer RJ, Bajorin DF, Stasi JP, Sheinfeld J (2007). Nonrandomized comparison of primary chemotherapy and retroperitoneal lymph node dissection for clinical stage IIA and IIB nonseminomatous germ cell testicular cancer. *Journal of Clinical Oncology*, 25(35), 5597–5602.
- 26) Weissbach L, Boedefeld E (1987). Localization of solitary and multiple metastases in stage II nonseminomatous testis tumor as basis for a modified staging lymph node dissection in stage I. *Journal of Urology*, 138(1), 77–82.

CHAPTER 6

GENERAL DISCUSSION AND SUMMARY

Using gross cadaveric dissection, this thesis provides the first detailed description of the aortic plexus (Chapters 2 & 3) and its variations (Chapter 4) in humans as it relates to retroperitoneal lymph node dissections (RPLND) for testis cancer (Chapter 5). The present chapter will discuss certain results as it relates to RPLND, introduce important future directions of the research, and end with an overall summary of the thesis.

6.1 General Discussion

6.1.1. Anatomical Considerations – Microganglia and Accessory Ganglia

From the present work, it is clear that the aortic plexus contains four major constituent ganglia (Beveridge, Johnson, et al., 2015, 2016). In addition, the aortic plexus and its adjacent plexuses may also contain minor, unnamed microganglia (Hollinshead, 1974; Jänig & McLachlan, 1987; Rusu, 2009; Moore et al., 2014; Beveridge, Johnson, et al., 2015). During our study of the aortic plexus in Chapter 2, we observed microganglia (confirmed with histology) supplementing the normal anatomy. In 2/8 specimens, an accessory inferior mesenteric ganglion was present. Both accessory inferior mesenteric ganglia were embedded within the nerves of the inferior mesenteric plexus, located on the medial aspect of the inferior mesenteric artery, significantly smaller than the inferior mesenteric ganglion proper and distinct from the prehypogastric ganglion. One of the specimens containing an accessory inferior mesenteric ganglion, also contained an extra ganglion, which was located near the rostral end of the superior hypogastric plexus, inferior to the prehypogastric ganglion. In our observations, the presence of microganglia did not alter the gross organization of the aortic plexus/superior hypogastric plexus and, therefore, these variable structures are of lesser importance from a surgical standpoint. That said, during the present studies we did encounter one specimen that had an accessory spermatic ganglion that was associated with an accessory lumbar splanchnic nerve and accessory testicular artery – a variation that could complicate intraoperative nerve-sparing. For reference, the case report of this variation is provided in Appendix D.

6.1.2. Clinical Considerations – Retroaortic Lumbar Splanchnic Nerves

It was well-known that RPLND can cure advanced-stage testis cancer (Albers, 2004) at the risk of developing post-operative ejaculatory dysfunction due to damage of the sympathetic nerves (Jewett & Groll, 2007). The development of nerve-sparing RPLND has provided a means to preserve ejaculation in patients while maintaining a thorough cancer resection (Jewett et al., 1988; Donohue et al., 1990; Jewett & Groll, 2007; Large et al., 2009; Heidenreich & Pfister, 2012; Wells et al., 2017). Without nerve-sparing, the risk of ejaculatory dysfunction following full bilateral template surgery is almost certain (Table 4). However, despite not nerve-sparing, ejaculatory dysfunction is not always seen (Kom et al., 1971; Nijman et al., 1982, 1987; Nowroozi et al., 2015). This observation is not intuitive because bilateral resection should uniformly remove the infrarenal aortic plexus and no known collateral sympathetic pathways to mediate antegrade ejaculation exist. In dogs, compensatory control of seminal emission (Kihara et al., 1991), but not closure of the bladder neck (Kihara et al., 1992), has been demonstrated following complete bilateral transection of the hypogastric nerves (distal extension of the aortic plexus); however, without bladder neck closure, seminal emission alone would only ever result in retrograde ejaculation. Thus, no literature exists to explain how bilateral RPLND without nerve-sparing can occasionally spare ejaculatory function.

We assert partial nerve-sparing – unbeknownst to the surgeons – to explain this phenomenon. In Chapter 2, we observed in our dissections of human cadavers, the possibility of a retroaortic lumbar splanchnic nerve extending from the lumbar sympathetic chain to join the superior hypogastric plexus directly (Beveridge, Johnson, et al., 2015). In Chapter 4, we further characterized these nerves to be present in 85% of individuals, invariably coursing posterior to the aorta to emerge from between the common iliac arteries and left common iliac vein to join the superior hypogastric plexus inferior to the bifurcation (Beveridge et al., 2017). Given the variable presence of this nerve and potential protection afforded by its position deep to the abdominal aorta (Figure 20), its unintentional preservation may explain the minority of men with antegrade ejaculation despite undergoing bilateral RPLND without nerve-sparing.

Table 4. A minority of men maintain antegrade ejaculation after bilateral RPLND without nerve-sparing.

A compilation of studies reporting the rate of ejaculatory dysfunction (EjD) in men after bilateral retroperitoneal lymph node dissection (RPLND) for testis cancer without nerve-sparing (NS).

<i>Study</i>	<i>Total No. Patients (Bilateral RPLND, no NS)</i>	<i>Number with EjD (%)</i>
(Dimitropoulos et al., 2016)	53	53 (100%)
(Nowroozi et al., 2015)	17	15 (88%)
(Nijman et al., 1987)	101	89 (88%)
(Nijman et al., 1982)	14	12 (86%)
(Kom et al., 1971)	9	6 (67%)

6.2 Future Work

In the present thesis, we provide the first comprehensive characterization of the aortic plexus (Beveridge, Johnson, et al., 2015, 2016) and its variations (Beveridge et al., 2017) which are prone to damage during testis cancer surgery — findings that have informed novel nerve-sparing techniques (Beveridge, Allman, et al., 2016). However, preservation of the aortic plexus in its entirety is often not feasible in patients with advanced disease and nerve-sparing should never be attempted at the risk of an incomplete cancer resection (Jewett & Groll, 2007). Therefore, surgical effort should be focused on sparing the nerves of the aortic plexus relevant to ejaculation, since transection of the sympathetic nerves to the colon and pelvic organs does not appear to have any perceivable effects (Jänig & McLachlan, 1987). Importantly, focusing surgical effort on sparing only the nerves relevant to ejaculation may: *(i)* reduce the overall time of the surgery, *(ii)* improve rates of post-operative antegrade ejaculation, and *(iii)* allow for more accurate pre-operative predictions of a patient's ability to ejaculate after RPLND, given the extent of their individual disease. Unfortunately, it remains unknown which nerves of the aortic plexus are in control of seminal emission and/or the internal urethral sphincter. Therefore, a necessary extension of the work presented in this thesis is to uncover the neural pathways of the aortic plexus controlling seminal emission and the internal urethral sphincter.

Clues about the pathways of innervation pertaining to ejaculation can be gleaned from comparing the ejaculatory function of patients undergoing nerve-sparing/modified template/bilateral template RPLND (Jewett et al., 1988; Large et al., 2009; Pearce et al., 2013) or lumbar sympathectomies (Whitelaw & Smithwick, 1951). Most significantly, these studies have demonstrated that preservation of every sympathetic nerve in the retroperitoneum is not necessary to preserve antegrade ejaculation. Moreover, it appears unilateral preservation may be sufficient to maintain normal sexual function (See Figure 2). These suggestions are clearly substantiated in the study by Jewett et al. (1988) that reported which lumbar splanchnic nerves were spared in 20 patients that underwent RPLND, and the corresponding post-operative ejaculatory status for each (See Table 1). Interestingly, no clear correlation is seen between which nerves were spared and post-operative ejaculatory status. For example, nerve-sparing of only the right L2,3 lumbar

splanchnic nerves in Patient #2 was sufficient to maintain antegrade ejaculation post-operatively, but not for Patient #15 (Jewett et al., 1988). This suggests the arrangement of the fibers controlling ejaculation are prone to variation between individuals; however, this cannot be said with absolute certainty considering the lumbar splanchnic nerves in this study were defined by the vertebral level that the ganglion of origin resided upon – a method of nomenclature acknowledged to be inconsistent (Perlow & Vehe, 1935; Yeager & Cowley, 1948; Webber, 1958).

Taken together, the current surgical literature provides compelling evidence to suggest most lumbar splanchnic nerves and/or intermesenteric nerves play a role in seminal emission and bladder neck closure; however, preservation of every nerve is not required for normal ejaculation. It would appear partial nerve-sparing causes paresis of the smooth muscles controlling ejaculation that can manifest as ejaculatory dysfunction once a threshold of function is reached. Electrophysiological recordings paired with lesion-and-test models would provide a suitable means to investigate this hypothesis. However, an understanding of the neuromuscular pathophysiology of retrograde ejaculation and neurogenic anejaculation is a prerequisite for these studies. To properly elucidate this etiology, a non-clinical experimental model is required.

6.2.1. An Animal Model to Study the Peripheral Control of Ejaculation

Clinical studies have provided compelling evidence to suggest that many, if not all, nerves of the infrarenal aortic plexus are involved with ejaculation. However, a translatable animal model is required to properly examine the etiology of retrograde ejaculation/neurogenic anejaculation, and identify the precise nerve(s) – or perhaps proportion of nerves – necessary to avoid post-operative ejaculatory dysfunction. Given the variable morphology of the aortic plexus between species (Langley & Anderson, 1896; Dyce, 1934; Baron et al., 1985a; Kihara, Sato, & Oshima, 1998; Kihara, Sato, Ishizaka, et al., 1998), it is imperative that the prospective model show comparable anatomy to humans (i.e., two parallel intermesenteric cords containing the right and left spermatic, inferior mesenteric, and prehypogastric or equivalent, ganglia).

Rats have been extensively used to study the neurophysiology of ejaculation (Kihara & De Groat, 1997; Truitt & Coolen, 2002; Carro-Juárez et al., 2003; Coolen et al., 2004; Allard et al., 2005; Staudt et al., 2012); however, the anatomy of the murine aortic plexus is typically reduced to a single nerve (the intermesenteric nerve) supplying a single inferior (caudal) mesenteric ganglion (Jänig & McLachlan, 1987; Kihara & De Groat, 1997; Kihara et al., 1997) making this model less suitable for studying incomplete lesions in the periphery.

Cats were first used to describe the anatomy of the aortic plexus at the end of the 19th century (Langley & Anderson, 1896). The feline aortic plexus is comprised of 2-4 inferior (caudal) mesenteric ganglia, and remarkable spermatic/ovarian ganglia; however, like rats, they exhibit a single intermesenteric nerve rather than a preaortic plexus (Langley & Anderson, 1896; Jänig & McLachlan, 1987). Additionally, our own unpublished experiences with rats and cats have demonstrated that the retroperitoneal sympathetic nerves are tenuous and difficult to manipulate when attempting to model a nerve-sparing lymphadenectomy.

Furthermore, dogs appear to have comparable anatomy to humans; three pairs of lumbar splanchnic nerves joining the infrarenal aortic (intermesenteric) plexus that is demonstrated to contain gonadal ganglia and an inferior (caudal) mesenteric ganglion (Mizeres, 1955). The morphology of the constituent cords are supported in more recent drawings (Kihara et al., 1992; Ando et al., 1993); however, another study from the same group raises possible inconsistency by illustrating a singular intermesenteric nerve in place of the aortic plexus (Kihara, Sato, Ishizaka, et al., 1998). Furthermore, the majority of studies describe a single inferior (caudal) mesenteric ganglion in dogs (Mizeres, 1955; Kihara et al., 1992; Ando et al., 1993; Kihara, Sato, Ishizaka, et al., 1998) whereas one review indicates a bi-lobed ganglion in this species (Jänig & McLachlan, 1987). Thus, additional studies are needed to determine if a homologous structure to the human prehypogastric ganglion is present in dogs.

Finally, boars have been identified as suitable model for urogenital research due to their anatomical and functional resemblance to humans (Dalmose et al., 2000; Burdzińska et

al., 2012; Ragonieri et al., 2013; Pidsudko, 2014a, 2014b). Furthermore, their use in a study immunotracing the innervation of the bladder shows a pair of inferior mesenteric ganglia respectively supplied by a right and left intermesenteric nerves (see Fig 3. in Pidsudko, 2014a) suggesting a possible organizational homology to the inferior mesenteric and prehypogastric ganglia in humans. Research from our lab has further substantiated this organizational homology. Using serial histology, we delineated a neural separation, devoid of neuron cell bodies, between the porcine caudal mesenteric ganglia that confirmed they were in fact two distinct structures and not one unified ganglion (Groh et al., 2018). Furthermore, we showed the porcine aortic plexus exhibited comparable organizational symmetry overall, complete with two longitudinal intermesenteric cords, each supplied by lumbar splanchnic nerves from the respective lumbar sympathetic chains (Figure 28) – findings that indicate a structural homology to humans (Groh et al., 2018).

To further identify the potential usefulness of the boar as a suitable animal model for ejaculatory research, it is important to consider not only the structural homology to humans, but also physiological similarities. Indeed, we recently demonstrated stimulation of the aortic plexus caused closure of the bladder neck (Groh et al., 2018) – a functional homology to the known neural anatomy and physiology of the internal urethral sphincter in humans (Learmonth, 1931; Whitelaw & Smithwick, 1951; Brindley et al., 1989; Keating, 2004). Importantly, our results indicate that a partial (unilateral) aortic plexus lesion was not associated with a loss of bladder neck closure (Groh et al., 2018) – findings that are congruent with the observed antegrade ejaculation following partial nerve sparing in humans (Whitelaw & Smithwick, 1951; Jewett et al., 1988).

With these findings that support the boar as a comparable model to study the peripheral innervation supplying the internal urethral sphincter, future studies can begin to study the etiology of retrograde ejaculation and identify the precise neural pathways imperative to avoid post-operative ejaculatory dysfunction. Such work is ongoing in our lab where we are investigating the specific regions of the internal urethral sphincter impacted by various (partial/unilateral) nerve lesions and its associated ability to resist retrograde flow during ejaculation.

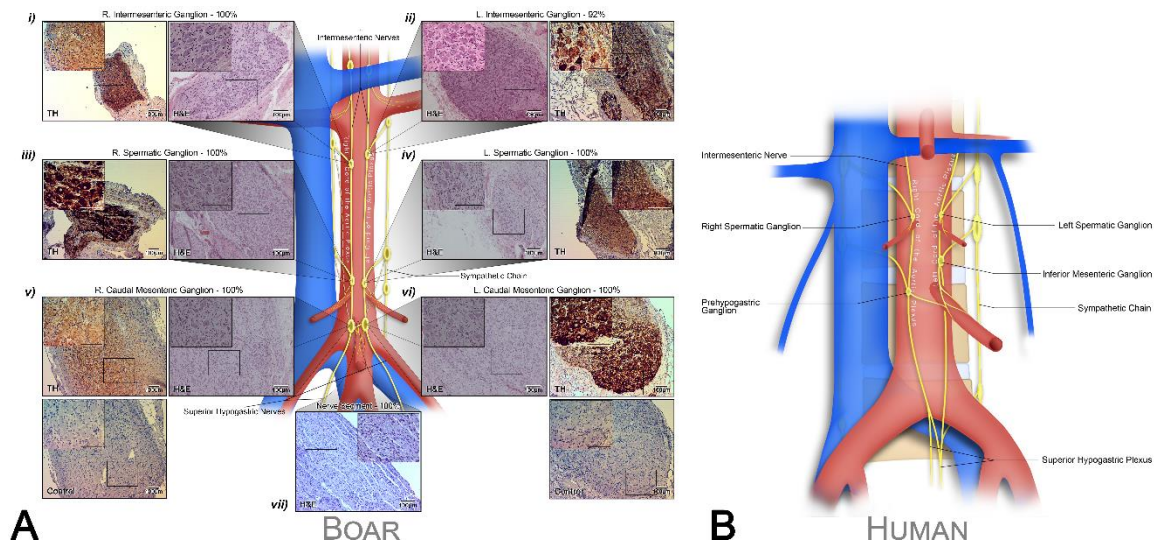


Figure 28. A conservation of anatomy in the aortic plexus exists between boars and humans, from Groh et al. (2018).

The neuroanatomical structure of the porcine aortic plexus (A) was compared to the known anatomy of humans (B). Histological sections stained with H&E are presented in panels (i-vi) for each ganglion of the porcine aortic plexus, and reveal prominent collections of neuronal cell bodies. Each of these panels (i-vi) is complemented by sections stained for tyrosine hydroxylase that confirm the adrenergic nature of the ganglia; panels v/vi also include representative negative controls for the immunohistochemical stain. Lastly, panel vii presents a representative serial section stained with H&E of the neural segment between the right and left caudal mesenteric ganglia that is devoid of neuronal cell bodies, indicating a clear distinction between these two neural structures.

6.3 Overall Summary

Using gross cadaveric dissection, we have provided the first detailed description of the aortic plexus (Chapters 2 & 3) and its variations (Chapter 4) in humans. The aortic plexus was found to be symmetrically organized into two longitudinal cords that coursed in parallel until they converged to continue into the pelvis as the superior hypogastric plexus (Beveridge, Johnson, et al., 2015, 2016). Each cord contained two constituent ganglia located near and around the junction of the infrarenal lumbar splanchnic nerves within the cords of the aortic plexus: the left & right spermatic/ovarian ganglia, the prehypogastric ganglion and the inferior mesenteric ganglion (Beveridge, Johnson, et al., 2015, 2016). Furthermore, the lumbar splanchnic nerves joining the aortic plexus consistently coursed in parallel in an anteroinferior direction from the lumbar sympathetic chains to merge with the two intermesenteric cords of the aortic plexus (Beveridge et al., 2017). Despite these consistencies in the general organization of the aortic plexus, the position and number of lumbar splanchnic nerves was subject to significant variability. Typically, two lumbar splanchnic nerves joined each side of the infrarenal aortic plexus, with the possibility of encountering as little as one or as many as four on each side (Beveridge et al., 2017). Furthermore, the position of the lumbar splanchnic nerves within individuals was not similar; however, 98% of lumbar splanchnic nerves originated from the lumbar sympathetic chain superior to the level of the inferior mesenteric artery (Beveridge et al., 2017). Below of the origin of the inferior mesenteric artery, 85% of individuals exhibited a retroaortic lumbar splanchnic nerve(s) that coursed between the aorta/common iliac arteries and the left common iliac vein to join the posterior aspect of the superior hypogastric plexus (Beveridge et al., 2017). As an extension to this neuroanatomical characterization, in Chapter 5 we studied their relationship to the lumbar arteries and veins to inform precise nerve-sparing strategies for retroperitoneal lymph node dissection (Beveridge, Allman, et al., 2016). Armed with a comprehensive understanding of the surgical anatomy of the aortic plexus in humans, future studies should seek to determine which nerves are specifically involved with ejaculation, and the pathways imperative to preserving fertility during retroperitoneal surgery.

6.4 References

- 1) Albers P (2004). Resection of retroperitoneal residual tumor after chemotherapy for testicular cancer indication and surgical techniques. *Critical Reviews in Oncology/Hematology*, 50(1), 79–85.
- 2) Allard J, Truitt WA, McKenna KE, Coolen LM (2005). Spinal cord control of ejaculation. *World Journal of Urology*, 23(2), 119–126.
- 3) Ando M, Kihara K, Sato K, Sato T, Oshima H (1993). Regulation of the bladder neck closure by lumbar splanchnic nerves at ejaculation in the dog. *Neurourology and Urodynamics*, 12(1), 91–98.
- 4) Baron R, Jänig W, McLachlan EM (1985). On the anatomical organization of the lumbosacral sympathetic chain and the lumbar splanchnic nerves of the cat—Langley revisited. *Journal of the Autonomic Nervous System*, 12(4), 289–300.
- 5) Beveridge TS, Allman BL, Johnson M, Power A, Sheinfeld J, Power NE (2016). Retroperitoneal Lymph Node Dissection: Anatomical and Technical Considerations from a Cadaveric Study. *The Journal of Urology*, 196(6), 1764–1771.
- 6) Beveridge TS, Fournier DE, Groh AMR, Johnson M, Power NE, Allman BL (2017). The anatomy of the infrarenal lumbar splanchnic nerves in human cadavers: implications for retroperitoneal nerve-sparing surgery. *Journal of Anatomy*, 232(1), 124–133.
- 7) Beveridge TS, Johnson M, Power A, Power NE, Allman BL (2015). Anatomy of the nerves and ganglia of the aortic plexus in males. *Journal of Anatomy*, 226(1), 93–103.
- 8) Beveridge TS, Johnson M, Power NE, Allman BL (2016). Histological verification of the prehypogastric and ovarian ganglia confirms a bilaterally symmetrical organization of the ganglia comprising the aortic plexus in female human cadavers. *Journal of Anatomy*, 228(5), 805–811.
- 9) Brindley GS, Sauerwein D, Hendry WF (1989). Hypogastric plexus stimulators for obtaining semen from paraplegic men. *British Journal of Urology*, 64(1), 72–77.
- 10) Burdzińska A, Crayton R, Dybowski B, Koperski L, Idziak M, Fabisiak M, ... Radziszewski P (2012). Urethral distension as a novel method to simulate sphincter insufficiency in the porcine animal model. *International Journal of Urology*, 19(7), 676–682.
- 11) Carro-Juárez M, Cruz SL, Rodríguez-Manzo G (2003). Evidence for the involvement of a spinal pattern generator in the control of the genital motor pattern of ejaculation. *Brain Research*, 975(1–2), 222–228.

- 12) Coolen LM, Allard J, Truitt WA, McKenna KE (2004). Central regulation of ejaculation. *Physiology and Behavior*, 83(2), 203–215.
- 13) Dalmose AL, Hvistendahl JJ, Olsen LH, Eskild-Jensen A, Djurhuus JC, Swindle MM (2000). Surgically induced urologic models in swine. *Journal of Investigative Surgery*, 13(3), 133–145.
- 14) Dimitropoulos K, Karatzas A, Papandreou C, Daliani D, Zachos I, Pisters LL, Tzortzis V (2016). Sexual dysfunction in testicular cancer patients subjected to post-chemotherapy retroperitoneal lymph node dissection: A focus beyond ejaculation disorders. *Andrologia*, 48(4), 425–430.
- 15) Donohue J, Foster R, Rowland R, Bihrlé R, Jones J, Geier G (1990). Nerve-sparing retroperitoneal lymphadenectomy with preservation of ejaculation. *Journal of Urology*, 144(2), 287–291.
- 16) Dyce KM (1934). The Splanchnic Nerves and Major Abdominal Ganglia of the Horse. *Journal of Anatomy*, 92(1), 62–74.
- 17) Groh AMR, Moore CW, El-Warrak A, Seager SW, Power NE, Allman BL, Beveridge TS (2018). Electroejaculation Functions Primarily by Direct Activation of Pelvic Musculature: Perspectives from a Porcine Model. *Translational Research in Anatomy*, In Press. DOI: 10.1013/j.tria.2018.01.001
- 18) Heidenreich A, Pfister D (2012). Retroperitoneal lymphadenectomy and resection for testicular cancer: an update on best practice. *Therapeutic Advances in Urology*, 4(4), 187–205.
- 19) Hollinshead WH (1974). Textbook of Anatomy (3rd ed.). Hagerstown, MD: Harper & Row, Publishers.
- 20) Jänig W, McLachlan EM (1987). Organization of lumbar spinal outflow to distal colon and pelvic organs. *Physiological Reviews*, 67(4), 1332–404.
- 21) Jewett MA, Groll RJ (2007). Nerve-Sparing Retroperitoneal Lymphadenectomy. *Urologic Clinics of North America*, 34(2), 149–158.
- 22) Jewett MA, Kong YP, Goldberg SD, Sturgeon JF, Thomas GM, Alison RE, Gospodarowicz MK (1988). Retroperitoneal Lymphadenectomy for Testis Tumor with Nerve Sparing for Ejaculation. *The Journal of Urology*, 139(6), 1220–1224.
- 23) Keating JP (2004). Sexual function after rectal excision. *ANZ Journal of Surgery*, 74(4), 248–259.
- 24) Kihara K, De Groat W (1997). Sympathetic efferent pathways projecting to the bladder neck and proximal urethra in the rat. *Journal of the Autonomic Nervous System*, 62(3), 134–142.

- 25) Kihara K, Sato K, Ando M, Sato T, Oshima H (1991). Lumbosacral sympathetic trunk as a compensatory pathway for seminal emission after bilateral hypogastric nerve transections in the dog. *The Journal of Urology*, 145(3), 640–643.
- 26) Kihara K, Sato K, Ando M, Sato T, Oshima H (1992). A mechanism of retrograde ejaculation after bilateral hypogastric nerve transections in the dog. *Journal of Urology*, 148(4), 1307–1309.
- 27) Kihara K, Sato K, Ishizaka K, Oshima H (1998). Preservation of ejaculatory function by reconstruction of the canine hypogastric nerve. *Journal of Neurosurgery*, 88(4), 726–733.
- 28) Kihara K, Sato K, Oshima H (1997). Sympathetic efferent pathways projecting to the vas deferens in the rat. *The Anatomical Record*, 248(2), 291–299.
- 29) Kihara K, Sato K, Oshima H (1998). Sympathetic efferent pathways projecting to the vas deferens. *Microscopy Research and Technique*, 42(6), 398–408.
- 30) Kom C, Mulholland SG, Edson M (1971). Etiology of infertility after retroperitoneal lymphadenectomy. *Journal of Urology*, 105(4), 528–530.
- 31) Langley JN, Anderson HK (1896). The Innervation of the Pelvic and adjoining Viscera: Part VII. Anatomical Observations. *Journal of Physiology*, 20(4–5), 371–406.
- 32) Large MC, Sheinfeld J, Eggener SE (2009). Retroperitoneal lymph node dissection: Reassessment of modified templates. *BJU International*, 104(9 B), 1369–1375.
- 33) Learmonth JR (1931). A contribution to the neurophysiology of the urinary bladder in man. *Brain*, 54(2), 147–176.
- 34) Mizeres N (1955). The Anatomy of the Autonomic Nervous System in the Dog. *American Journal of Anatomy*, 96(2), 285–318.
- 35) Moore K, Dalley A, Agur A (2014). Abdomen. In C. Taylor (Ed.), *Clinical Oriented Anatomy* (7th ed., p. 304). Philadelphia PA: Lippincott Williams & Wilkins.
- 36) Nijman JM, Jager S, Boer PW, Kremer J, Oldhoff J, Koops HS (1982). The treatment of ejaculation disorders after retroperitoneal lymph node dissection. *Cancer*, 50(12), 2967–2971.
- 37) Nijman JM, Schraffordt Koops H, Oldhoff J, Kremer J, Jager S (1987). Sexual function after bilateral retroperitoneal lymph node dissection for nonseminomatous testicular cancer. *Archives Andrology*, 18(3), 255–267.
- 38) Nowroozi M, Ayati M, Arbab A, Jamshidian H, Ghorbani H, Niroomand H, ... Ghadian A (2015). Postchemotherapy Retroperitoneal Lymph Node Dissection in

- Patients with Nonseminomatous Testicular Cancer: A Single Center Experiences. *Nephrology and Urology Monthly*, 7(5), 1–5.
- 39) Pearce S, Steinberg Z, Eggner S (2013). Critical evaluation of modified templates and current trends in retroperitoneal lymph node dissection. *Current Urology Reports*, 14(5), 511–517.
- 40) Perlow S, Vehe K (1935). Variations in the gross anatomy of the stellate and lumbar sympathetic ganglia. *The American Journal of Surgery*, 30(3), 454–458.
- 41) Pidsudko Z (2014a). Immunohistochemical characteristics and distribution of neurons in the paravertebral, prevertebral and pelvic ganglia supplying the urinary bladder in the male pig. *Journal of Molecular Neuroscience*, 52(1), 56–70.
- 42) Pidsudko Z (2014b). Immunohistochemical characteristics and distribution of sensory dorsal root ganglia neurons supplying the urinary bladder in the male pig. *Journal of Molecular Neuroscience*, 52(1), 71–81.
- 43) Ragionieri L, Botti M, Gazza F, Sorteni C, Chiocchetti R, Clavenzani P, ... Panu R (2013). Localization of peripheral autonomic neurons innervating the boar urinary bladder trigone and neurochemical features of the sympathetic component. *European Journal of Histochemistry*, 57(2), 93–105.
- 44) Rusu M (2009). Accessory lumbar splanchnic ganglia in humans: A case report. *Anatomical Science International*, 84(3), 253–256.
- 45) Staudt MD, Truitt WA, Mckenna KE, de Oliveira CVR, Lehman MN, Coolen LM (2012). A Pivotal Role of Lumbar Spinothalamic Cells in the Regulation of Ejaculation via Intraspinial Connections. *Journal of Sexual Medicine*, 9(9), 2256–2265.
- 46) Truitt WA, Coolen LM (2002). Identification of a potential ejaculation generator in the spinal cord. *Science*, 297(5586), 1566–1569.
- 47) Webber R (1958). A Contribution on the Sympathetic Nerves in the Lumbar Region. *The Anatomical Record*, 130(3), 581–604.
- 48) Wells H, Hayes MC, O'Brien T, Fowler S (2017). Contemporary retroperitoneal lymph node dissection (RPLND) for testis cancer in the UK – a national study. *BJU International*, 119(1), 91–99.
- 49) Whitelaw G, Smithwick R (1951). Some Secondary Effects of Sympathectomy with Particular Reference to Disturbance of Sexual Function. *The New England Journal of Medicine*, 245(4), 121–130.
- 50) Yeager G, Cowley R (1948). Anatomical Observations on the Lumbar Sympathetics with Evaluation of Sympathectomies in Organic Peripheral Vascular Disease. *Annals of Surgery*, 127(5), 953–967.

APPENDICES

Appendix A. Hematoxylin and eosin staining protocol using standard regressive procedures.

Obtained from Department of Oral Pathology.

H & E Protocol

1. Xylene (5 minutes)
2. Xylene (5 minutes)
3. Xylene (3 minutes)
4. 100% EtOH (2 minutes)
5. 100% EtOH (1 minute)
6. 95% EtOH (2 minutes)
7. 95% EtOH (1 minute)
8. 95% EtOH (1 minute)
9. H₂O (2 minutes)
10. Hematoxylin (3 minutes)
11. Rinse in H₂O
12. 2 to 3 dips in Acid Alcohol (1% HCl in 70% EtOH)
13. Rinse in H₂O
14. Dip in Ammonium Alcohol (2% NH₄OH in 70% EtOH), until stain turns blue (~2-3 dips)
15. Rinse in H₂O
16. Eosin (3 minutes)
17. Rinse in H₂O
18. 70% EtOH (1 minute or 10 dips)
19. 95% EtOH (1 minute or 10 dips)
20. 95% EtOH (1 minute or 10 dips)
21. 100% EtOH (1 minute or 10 dips)
22. 100% EtOH (1 minute or 10 dips)
23. 100% EtOH (1 minute or 10 dips)
24. Xylene (5 minutes)
25. Xylene (5 minutes)
26. Mount and Coverslip

Appendix B. Anti-TH immunohistochemical staining protocol.

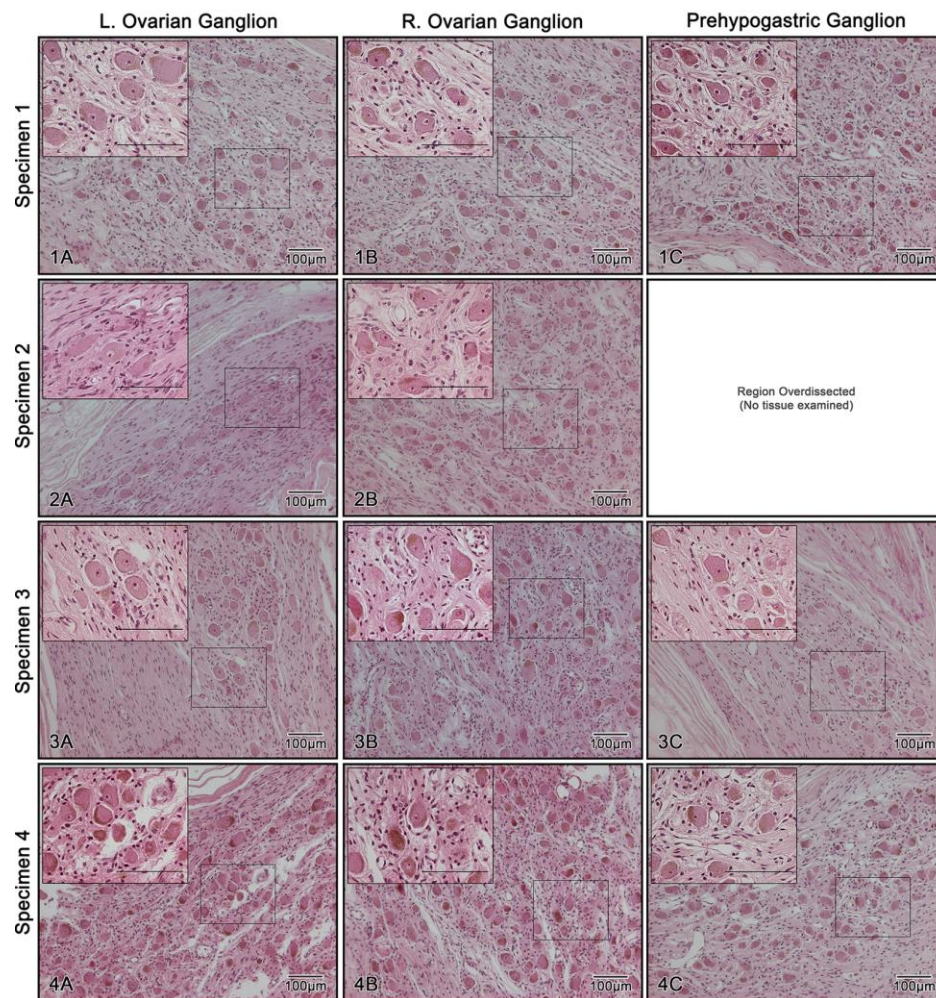
Obtained from Department of Oral Pathology.

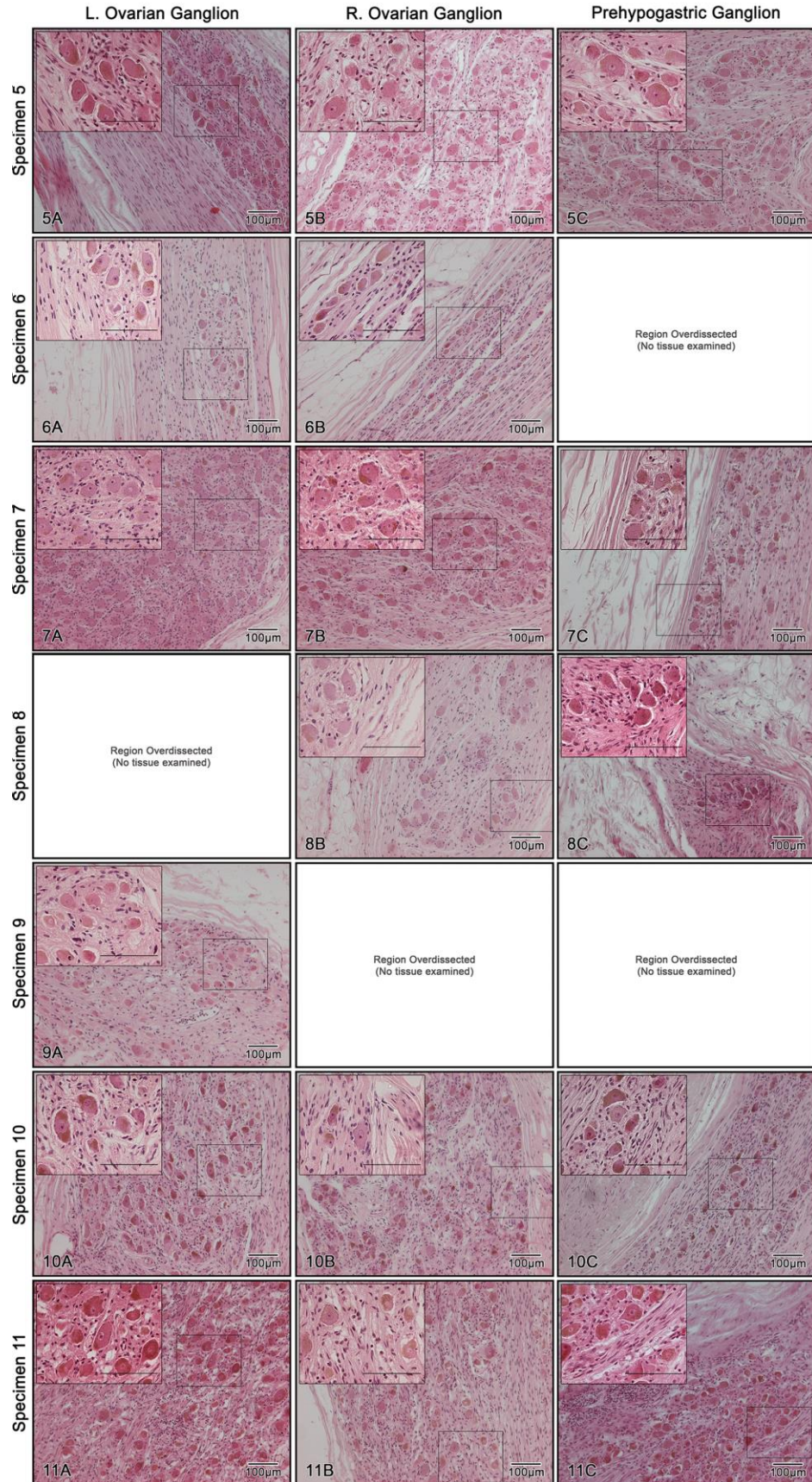
IHC Protocol

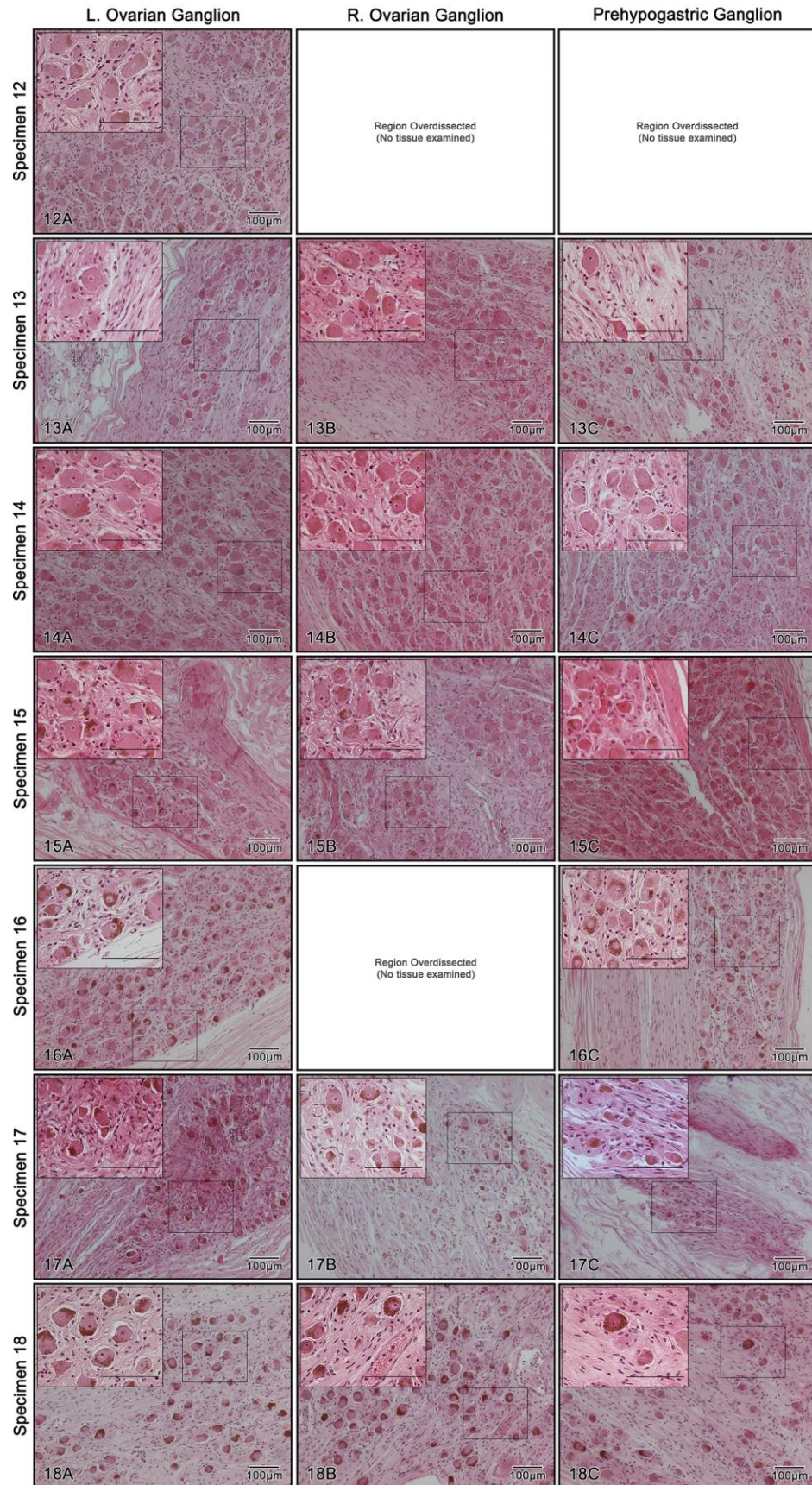
1. Complete Steps 1-9 from the H&E Protocol (**Appendix A**)
2. Slides are quenched with fresh 3% H₂O₂ in MeOH (prepared from 20mL 30% H₂O₂ in 180mL MeOH) for 5 minutes
3. Rinse in H₂O (5 minutes)
4. Rinse in Phosphate Buffered Saline (PBS) on shaker (5 minutes)
5. Antigen Retrieval is done in citrate buffer (pH 6.0) in a decloaking chamber (place 500mL of distilled H₂O in bottom of decloaking chamber)
6. Rinse in H₂O, then in PBS
7. Slides are blocked in 10% horse serum at room temperature (30 minutes), then drained onto paper towel. **DO NOT RINSE IN PBS**
8. Slides are incubated with monoclonal antibody anti-TH [0.5 µL/mL, as determined by preliminary titration experiments] at room temperature in a humidified chamber (1 hour)
9. Rinse in PBS on shaker (5 minutes)
10. Slides are incubated with ImmPress Kit (anti-mouse horse-radish peroxidase micropolymer solution) at room temperature (30 minutes)
11. Rinse in PBS on shaker (5 minutes)
12. Diaminobenzidine (DAB) is prepared (5mL distilled H₂O + 2 drops of buffer + 4 drops of DAB + 2 drops of H₂O₂, in that order with vortexing after each step)
13. Slides are incubated with DAB (10 minutes maximum)
14. The reaction is stopped with distilled H₂O, and drained into the waste container
15. Rinse in H₂O
16. Hematoxylin (1 minutes)
17. Rinse in H₂O
18. 2 to 3 dips in Acid Alcohol (1% HCl in 70% EtOH)
19. Rinse in H₂O
20. Dip in Ammonium Alcohol (2% NH₄OH in 70% EtOH), until stain turns blue (~2-3 dips)
21. Rinse in H₂O
22. 70% EtOH 1 minute or 10 dips
23. 95% EtOH 1 minute or 10 dips
24. 95% EtOH 1 minute or 10 dips
25. 100% EtOH 1 minute or 10 dips
26. 100% EtOH 1 minute or 10 dips
27. 100% EtOH 1 minute or 10 dips
28. Xylene 5 minutes
29. Xylene 5 minutes
30. Mount and Coverslip

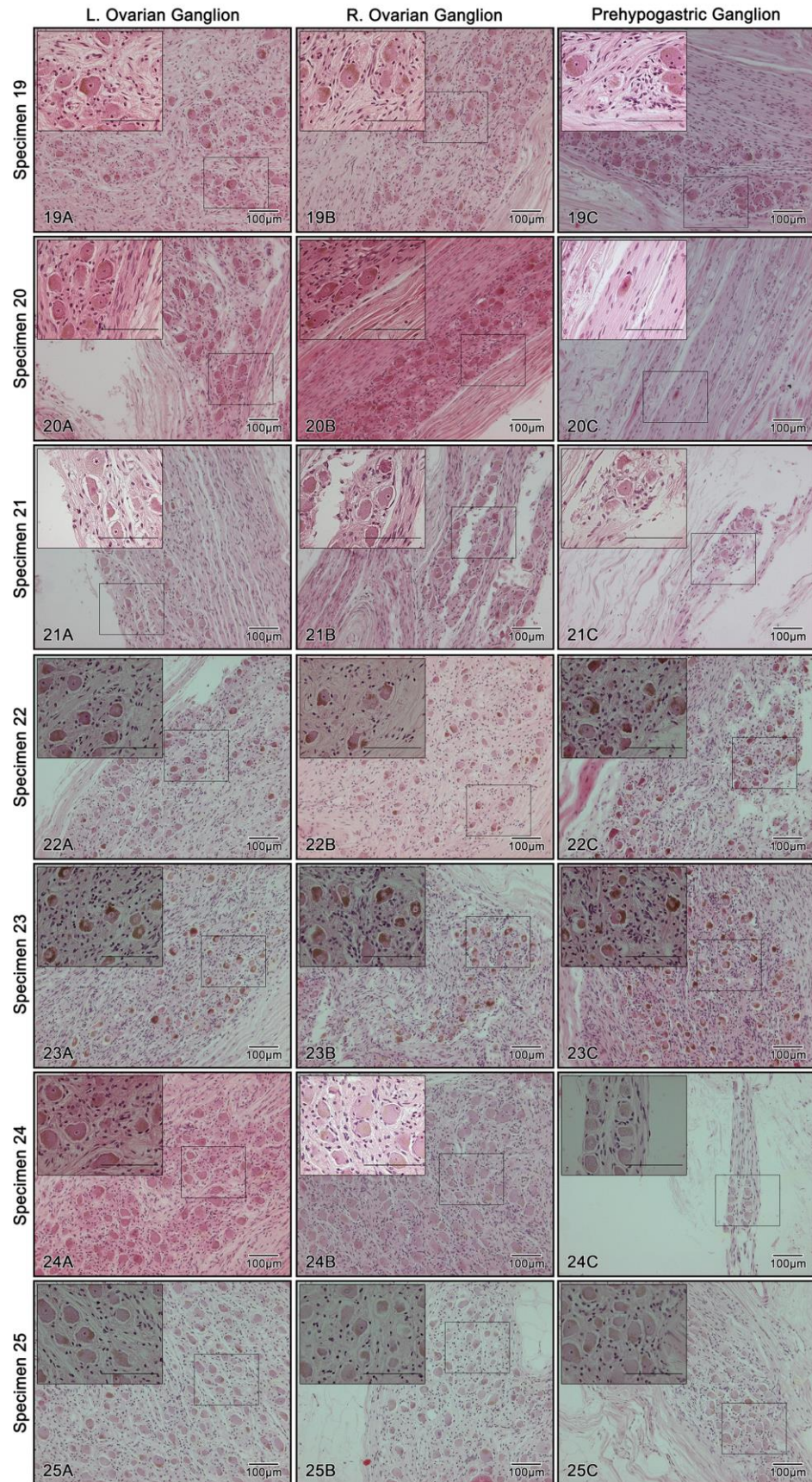
Appendix C. Photomicrographs of the constituent ganglia from the aortic plexus

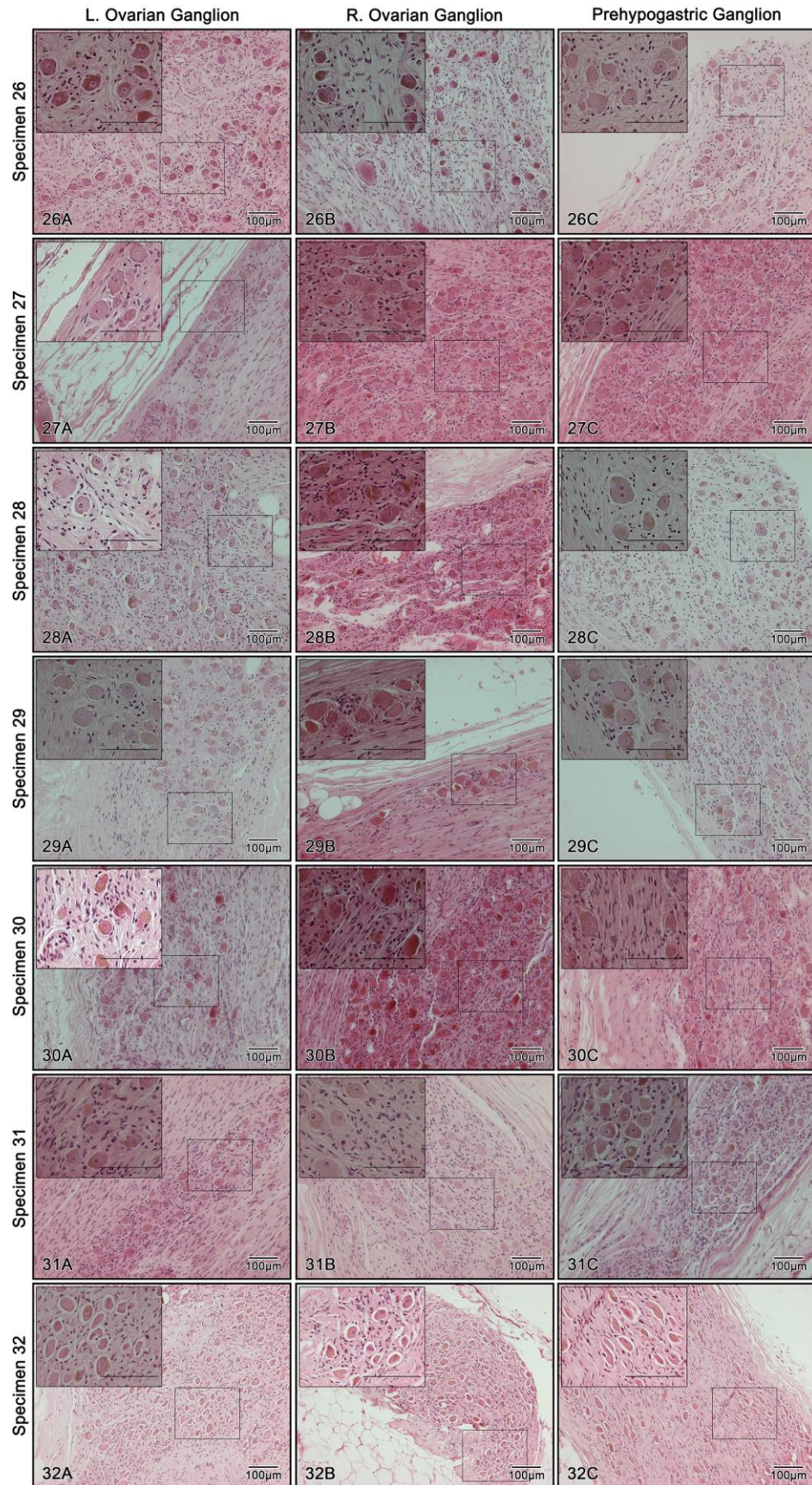
The study presented in Chapter 3 references a compilation of photomicrographs showing the histology of all examined tissues in the study. These micrographs are presented on the subsequent pages; Columns A, B and C show histology from the left ovarian ganglia, right ovarian ganglia and prehypogastric ganglia, respectively.











Appendix D. Accessory Right Spermatic Ganglion Case Report

Abstract

The spermatic ganglia are collections of sympathetic neuron cell bodies located within the right cord of the aortic plexus, positioned at the origin of the testicular arteries in males. During routine dissection of the aortic plexus at our institution, one specimen exhibited a second (accessory) testicular artery on the right side which coursed retrocausal. Histology was used to confirm the presence of an accessory right spermatic ganglion at the base of the accessory retrocausal testicular artery. Interestingly, the accessory spermatic ganglion was also supplied by its own accessory right lumbar splanchnic nerve. This is the first case to describe the anatomy of an accessory spermatic ganglion in a specimen which exhibits an accessory testicular artery on the right side. In addition to a detailed description of this neurovascular variation, this case report discusses a possible developmental rationale which may be of interest to surgeons who aim to preserve these sympathetic nerves and their variations during retroperitoneal surgeries.

Introduction

The spermatic ganglia are the superior constituent ganglia of the aortic plexus (Beveridge, Johnson, et al., 2015). Located near the origin of the testicular arteries in males (Motoc et al., 2010; Beveridge, Johnson, et al., 2015), the spermatic ganglia are supplied by the first (most superior) infrarenal lumbar splanchnic nerve joining the aortic plexus (Beveridge, Johnson, et al., 2015). Additionally, they may also receive neural fibers by way of intermesenteric nerves from the aorticorenal/superior mesenteric plexuses (Motoc et al., 2010; Beveridge, Power, et al., 2015). These ganglia are recognizable by their distal branches extending along the testicular arteries to comprise the spermatic plexus. The spermatic ganglia also exhibit an inferior branch that extends caudally along the abdominal aorta towards the inferior positioned, prevertebral ganglia of the aortic plexus; the inferior mesenteric ganglion on the left and prehypogastric ganglion on the right (Beveridge, Johnson, et al., 2015).

The topographical location of the spermatic ganglia is achieved during embryogenesis. At this time, the neural crest cells (primitive post-ganglionic neurons) delaminate from the dorsal neural tube, and migrate ventrally towards the developing dorsal aorta (Huber, 2006; Schoenwolf, 2009; Takahashi et al., 2013; Kameda, 2014). Although several chemotactic factors have been identified which mediate this process, the exact mechanisms behind the morphogenesis of the spermatic ganglia, specifically, remain unclear.

In the present case report, a previously unreported variation in the anatomy of the right spermatic ganglia is discussed which may provide insight into the complex migratory mechanisms driving the development of these ganglia. Here, we present data from a dissection of a fresh frozen human cadaver which exhibited an accessory spermatic ganglion positioned at the origin of an accessory retrocaval testicular artery on the right side.

Methods

The data from the present case report was acquired from dissection of a fresh, frozen human cadaver [Male; Age at death = 65 years; Medical Hx = Cardiac Arrest, Coronary Artery Disease, Hypertension, Bladder cancer]. This specimen was obtained and dissected in accordance with the Anatomy Act of Ontario and Western's Committee for Cadaveric Use in Research, approval #15052013. A transabdominal approach was used to access the retroperitoneum and dissection of the aortic plexus was achieved using a previously reported protocol (Beveridge, Johnson, et al., 2015).

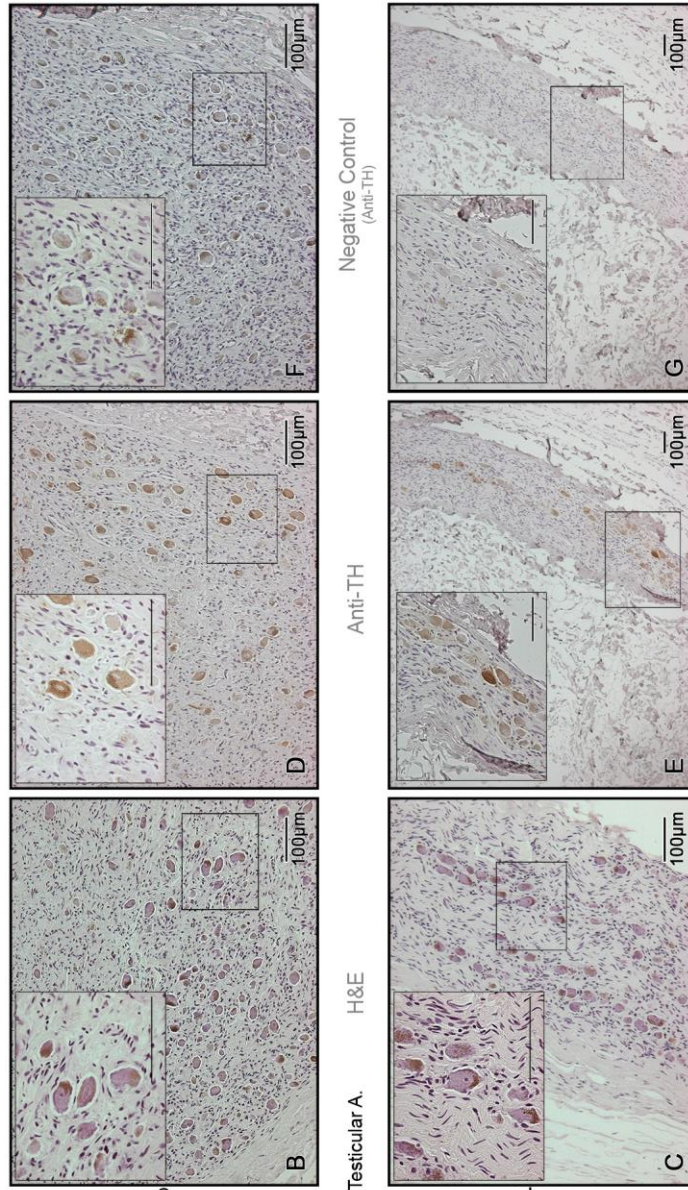
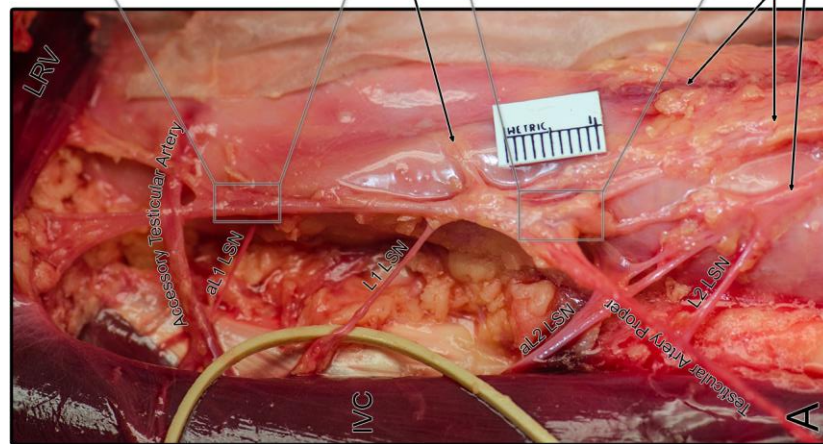
To confirm the macroscopic identification of a sympathetic ganglion, haematoxylin-eosin (H&E) staining with standard regressive procedures was used to visualize the presence of neuron cell bodies while anti-tyrosine hydroxylase (Anti-TH) immunostaining was used to verify the sympathetic nature of the neurons (Motoc et al., 2010; Kameda, 2014) using previously referenced protocols (Beveridge, Johnson, et al., 2015). Histology was performed on 5µm sections taken from paraffin embedded tissue.

Results

During routine dissection of the aortic plexus at our institution, one specimen exhibited an accessory retrocaval testicular artery in addition to the testicular artery proper on the right side (Figure 29A). The right testicular artery proper was defined as the vessel which was more closely paired to the left testicular artery. The accessory right testicular artery was located 2.9cm superior to the origin of the testicular artery proper, just inferior to the left renal vein. The accessory testicular artery coursed retrocaval before pairing with the testicular vein and testicular artery proper, lateral to the inferior vena cava.

At the base of both right testicular arteries, within the right cord of the aortic plexus, was an observable swelling of nervous tissue. Both swellings were excised to undergo histological analysis to verify their characterization as sympathetic ganglia. H&E staining of this tissue demonstrated the presence of neuronal cell bodies containing abundant lipofuscin granules, surrounded by irregularly arranged satellite cells (Figure 29B-C). Additionally, immunohistochemical staining for both specimens was tyrosine hydroxylase positive thus confirming their sympathetic nature (Figure 29D-G). The identified ganglia were further characterized as accessory/proper spermatic ganglia given their association with the respective right testicular arteries. Each spermatic ganglion was supplied by a separate lumbar splanchnic nerve; however, both lumbar splanchnic nerves originated from one unified lumbar sympathetic chain ganglion. In addition to the supply by the first lumbar splanchnic nerve, the right spermatic ganglion proper had some connections to an accessory L2 lumbar splanchnic nerve (observable in Figure 29).

As expected, inferior to the right spermatic ganglion proper, the prehypogastric ganglion was identified as a distinct structure supplied by the lumbar splanchnic nerve branching from the second lumbar sympathetic chain ganglion. The identification of the prehypogastric ganglion was also histologically verified for comprehensiveness (data not shown). The anatomical arrangement of the accessory right spermatic ganglion, right spermatic ganglion proper, and the prehypogastric ganglion within the right cord of the aortic plexus can be seen in Figure 29.



Accessory R. Spermatic Ganglion
Origin of Testicular A.
R. Spermatic Ganglion Proper
IMA and Plexus
Prehypogastric Ganglion (histology not shown)

Negative Control
(Anti-TH)

Anti-TH

H&E

Figure 29. Accessory spermatic ganglion associated with the presence of an accessory retrocaval testicular artery.

Panel A shows the right side of the aortic plexus in a specimen exhibiting an accessory, retrocaval testicular artery on the right side. Interestingly, the accessory testicular artery was accompanied by an accessory right spermatic ganglion, supplied by a unique accessory lumbar splanchnic nerve (aL1 LSN) from the L1 lumbar sympathetic chain ganglion (not visible). Panels B and C reveal H&E staining from both the accessory right spermatic ganglion, and the right spermatic ganglion proper, respectively. Likewise, Panels D/E and F/G demonstrate anti-TH staining and negative control staining from both the accessory right spermatic ganglion, and the right spermatic ganglion proper. This specimen also exhibited an accessory L2 lumbar splanchnic nerve (aL2 LSN). aL1/2 LSN accessory L1 or L2 lumbar splanchnic nerve; IMA inferior mesenteric artery; IVC inferior vena cava; LRV left renal vein; L1/2 LSN L1 or L2 lumbar splanchnic nerve.

Discussion

The present study describes a specimen which exhibited an accessory right spermatic ganglion at the origin of an accessory retrocaval testicular artery on the right side. The development of an accessory retrocaval testicular artery is not an unusual vascular variation given the previous reports of – and embryological rationales behind – the development of accessory testicular arteries (Deepthinath et al., 2006; Rusu, 2006; Nayak et al., 2007; Singh et al., 2011) or retrocaval testicular arteries (Mirapeix et al., 1996; Motoc et al., 2010; Reddy et al., 2011; Singh et al., 2011) in the literature. However, the present report also describes the anatomy of an accessory spermatic ganglion, positioned at the origin of the accessory testicular artery; a previously unreported finding which suggests a possible embryological association between the developing testicular arteries and the migration of the sympathetic neurons that form the spermatic ganglia.

In development, the migration of the neural crest cells from the dorsal neural tube during the 4th and 5th week of embryogenesis gives rise to the sympathetic chain ganglia and the prevertebral ganglia (Huber, 2006; Schoenwolf, 2009; Takahashi et al., 2013; Kameda, 2014). Bone morphogenic proteins from the developing dorsal aorta mediate this process by inducing the production of specific chemoattractant factors in the para-aortic region (Saito et al., 2012). Although several factors have been identified to understand the aggregation of neurons into compact masses or ganglia in the developing sympathetic chain (for review, see Kameda, 2014), our understanding of the mechanisms which mediate the precise morphogenesis of the prevertebral ganglia are less understood (Lumb & Schwarz, 2015).

A cadaveric study by Motoc et al. (2010), suggested that the topographical position of the spermatic ganglia is not influenced by the origin of the testicular arteries. This was supported by their observation of the left spermatic ganglion in the expected location within the aortic plexus during the dissection of a specimen that exhibited a left testicular artery originating from the left renal artery rather than the abdominal aorta (Motoc et al., 2010).

In contrast to this previous suggestion regarding the development of the spermatic ganglia, our observations support the theory that there is a developmental association between the testicular arteries and the spermatic ganglia. Specifically, we observed that development of an accessory testicular artery was associated with the development of an accessory spermatic ganglion; a finding which is congruent with the well-established understanding that the major prevertebral ganglia (i.e. the celiac, superior mesenteric, aorticorenal, and inferior mesenteric ganglia) develop around the origin of the abdominal aortic branches. Given our observation of an accessory spermatic ganglion paired with the development of an accessory testicular artery, it is not unreasonable to suggest that abdominal aortic branches (like the developing dorsal aorta) may play an integral role in mediating migration of the prevertebral ganglia. Therefore, we theorize that the developing branches of the abdominal aorta (embryologic splanchnic and vitelline arteries) play a role honing the migration of the neural crest cells with a prevertebral fate, by adjusting the distribution of the chemotactic factors initially mediated by the dorsal aorta; the outcome facilitating congregation around the origin of arterial branches. This suggestion is further supported by unpublished data from Schwarz in 2008, who observed ectopically positioned sympathetic ganglia closely associated with blood vessels in *Neuropilin1* knockout embryos (Lumb & Schwarz, 2015). In their 2015 review, Lumb & Schwartz proceed to suggest that their observation of vascular-associated, ectopic aggregations of sympathetic neurons in embryos with inhibited gangliogenesis may suggest underlying migratory signals from blood vessels. To explore this theory, future embryological studies elucidating how these developing arteries may alter migratory signaling in the para-aortic mesenchyme are needed.

From the present report, it is clear the development of an accessory spermatic ganglia and lumbar splanchnic nerve supply can be associated with the development of an accessory testicular artery. Although it remains unclear whether the vasculature influences the aberrant morphology of the nerves and ganglia, the present data suggests that the morphology of the aortic plexus may be predicted based on the anatomy of the arterial branches. This technique may be of particular interest to surgeons tasked with nerve-sparing during retroperitoneal procedures.

References

- 1) Beveridge TS, Johnson M, Power A, Power NE, Allman BL (2015). Anatomy of the nerves and ganglia of the aortic plexus in males. *Journal of Anatomy*, 226(1), 93–103.
- 2) Beveridge TS, Power A, Johnson M, Power NE, Allman BL (2015). The lumbar arteries and veins: Quantification of variable anatomical positioning with application to retroperitoneal surgery. *Clinical Anatomy*, 28(5), 649–660.
- 3) Deepthinath R, Sathesha N, Mehta R, Bhat S, Rodrigues V, Samuel V, ... Prasad A (2006). Multiple variations in the paired arteries of abdominal aorta. *Clinical Anatomy*, 19(6), 566–568.
- 4) Huber K (2006). The sympathoadrenal cell lineage: Specification, diversification, and new perspectives. *Developmental Biology*, 298(2), 335–343.
- 5) Kameda Y (2014). Signaling molecules and transcription factors involved in the development of the sympathetic nervous system, with special emphasis on the superior cervical ganglion. *Cell and Tissue Research*, 357(3), 527–548.
- 6) Lumb R, Schwarz Q (2015). Sympathoadrenal neural crest cells: The known, unknown and forgotten? *Development Growth and Differentiation*, 57(2), 146–157.
- 7) Mirapeix RM, Sañudo JR, Ferreira B, Domenech-Mateu JM (1996). A retrocaval right testicular artery passing through a hiatus in a bifid right renal vein. *Journal of Anatomy*, 189(3), 689–690.
- 8) Motoc A, Rusu MC, Jianu AM (2010). The spermatic ganglion in humans: An anatomical update. *Romanian Journal of Morphology and Embryology*, 51(4), 719–723.
- 9) Nayak SR, J JP, D’Costa S, Prabhu L V., Krishnamurthy A, Pai MM, Prakash (2007). Multiple anomalies involving testicular and suprarenal arteries: embryological basis and clinical significance. *Romanian Journal of Morphology and Embryology*, 48(2), 155–159.
- 10) Reddy S, Bhat SM, Mathew JG, Shetty PC, Gorantla VR, Jetti R, Vollala VR (2011). A Common Trunk of Origin of the Right Testicular and Middle Suprarenal Arteries with a Retrocaval Course. *Indian Journal of Surgery*, 73(4), 314–315.
- 11) Rusu MC (2006). Human bilateral doubled renal and testicular arteries with a left testicular arterial arch around the left renal vein. *Romanian Journal of Morphology and Embryology*, 47(2), 197–200.
- 12) Saito D, Takase T, Murai H, Takahashi Y (2012). The Dorsal Aorta Initiates a Molecular Cascade that Instructs Sympatho-Adrenal Specification. *Science*, 336, 1578–1581.

- 13) Schoenwolf G (2009). Larsen's Human Embryology (4th ed.). Churchill Livingstone Elsevier.
- 14) Singh R, Jaiswal A, Shamal S, Singh S (2011). Variation in the Origin of the Testicular Arteries and Drainage of the Right Testicular Vein. *International Journal of Morphology*, 29(2), 614–616.
- 15) Takahashi Y, Sipp D, Enomoto H (2013). Tissue interactions in neural crest cell development and disease. *Science*, 341(6148), 860–3.

Appendix E. Research Ethics Board Approval

Policies and Procedures for use of the cadaveric anatomy lab and cadaveric material at Western University, Department of Anatomy Cell Biology.

USE OF CADAVERIC MATERIAL FOR RESEARCH PURPOSES ***Department of Anatomy & Cell Biology, Western University.***

1. The use of human material is governed by the Anatomy Act of Ontario. Under the Act, the Department of Anatomy & Cell Biology (ACB) is ultimately responsible for the appropriate use and disposal of the cadavers it receives through its *Body Bequeathal Programme*. Therefore, all requests for the use of cadaveric material in research may be reviewed by the Inspector of Anatomy for Ontario (Chief Coroner) if necessary and, after use, all specimens must be returned to the Department for proper disposal.
2. For research to be carried out outside the gross anatomy laboratories in the Department of Anatomy & Cell Biology the following criteria must be met. Each request for cadaveric material will be reviewed by the ACB internal Committee for Use of Cadaveric Material for Research. This committee consists of a Chair (Dr. Marjorie Johnson) 3 other clinical anatomy faculty members and a member of the Pathology Department (currently Dr. Ted Tweedie). These members are appointed by the committee chair.

Criteria:

 - i. Specimens must be stored in a secure location, out of the public view. Similarly, the research must not be carried out in a public place.
 - ii. Specimens must be transported to and from the Department of Anatomy & Cell Biology concealed in containers that give no indication as to content and accompanied by a member of clinical anatomy. If the specimens are to be taken off-campus, a letter from the Department of Anatomy & Cell Biology authorizing their transportation must accompany the specimens. See Part I (Part I is not relevant to present thesis and therefore not included in this appendix).
 - iii. If specimens are being used in the cadaveric anatomy lab, investigators must follow the lab regulations outlined in Part II.
 - iv. All specimens must be returned to the anatomy lab supervisor (Haley Linklater) for cremation in accordance with the Bequeathal program policies.
 - v. All specimens are anonymized so that investigators receive a specimen number. Only the age, sex and cause of death, if needed, will be provided to the investigators. All other donor information, as part of the Bequeathal program, is kept locked in the office of the anatomy lab supervisor.
3. Specimens may not generally be photographed or videotaped, except under special circumstances. If filming or photography is needed, please complete the form in Part III.

4. The request for approval should be submitted as a 1-5-page summary of the research proposal under the following headings:

Name(s) & Title(s) and contact information of Applicant(s):

Co-PI:

Dr. Brian L. Allman, PhD Dept. of ACB
 Dr. Nicholas Power, MD Dept. of Surgery, Urology

PhD Student:

Tyler Beveridge, MSc Dept. of ACB

Title (of project): The anatomy of the infrarenal aortic plexus
Approval # 15052013

Hypothesis: Improvements to nerve-sparing surgery are impeded by a poor anatomical understanding of the retroperitoneal sympathetic plexuses.

Description of Project:

Specimen Handling:

- Dissection of the retroperitoneum (deep abdomen and pelvis) will be completed using standard techniques.
- Anonymity of the cadavers will be maintained by use of specimen numbers, and only non-identifiable photographs of the tissue will be taken for publication purposes.
- Specimens will be cremated at the end of each year, as per standard handling procedures in the gross anatomy lab.
- Tissue samples excised for histology will be stored in the locked office of the PhD Student, Tyler Beveridge for a period of 5 years, following completion of his degree, as per standard data handling protocols. At which point, the tissue will be cremated along with other general cadaveric waste from the Anatomy Lab.

Facilities:

- All cadaveric dissection will occur in the gross anatomy facilities (Haase Anatomy Lab and/or morgue) in the Medical Sciences Building at Western University.
- Tissue samples excised for histology will be processed at the University Hospital, and stained using the facilities offered by Linda Jackson, in the Department of Oral Pathology in Dental Sciences Building 4th Floor.
- Microscopy will take place in both the Department of Oral Pathology and Department of Anatomy and Cell Biology.

Study Duration:

- Anticipated completion of study and student's degree: April 2018.

Significance/Relevance (of study): Improved anatomical characterization of the sympathetic nerves in the abdomen may benefit nerve-sparing to preserve male fertility during retroperitoneal surgery

Source of Funding: CIHR CGS-D Student Scholarship

5. The proposal will be reviewed by the Committee for Use of Cadaveric Material for Research for approval. The proposal should be submitted electronically to the committee Chair, who may forward the proposal to the Inspector of Anatomy if clarification is needed.
6. An approval number will be assigned to each project, which may be used for ethics approval.
7. A statement of completion and a summary of project findings is to be submitted by the project PI no later than one year after completion of the study.
8. The Bequeathal program and all records are reviewed by the Chief Coroner's Office on an annual basis, including a summary of donors used for research or extracurricular educational programs, when requested.

Part II - Western University Human Anatomy Laboratory Regulations.

This Laboratory comes under the jurisdiction of the Solicitor General of the Province of Ontario through the General Inspector of Anatomy. It and the conduct of all those in it are subject to the relevant sections of the *Human Tissue Gift Act*, the *Anatomy Act*, the *Coroners Act* and the *Cemeteries Act*.

1. No one is allowed in the lab unless supervised by the laboratory staff or the instructor delegated by the Associate Chair of Clinical Anatomy or Chair Committee for Cadaveric Use in Research.
2. In all matters of conduct, in the absence of the Head of the School of Anatomy, the Sr. Lab Demonstrator is the final authority. In the absence of the Sr. Lab Demonstrator, the instructor delegated by the Head of the School of Anatomy is the final authority.
3. No frivolity or acts which could be construed as disrespectful to the cadavers will be tolerated.
4. A clean white lab coat must be worn at all times in the lab as a sign of respect to the deceased and for barrier protection when handling the dissections.
5. Some people consider wearing a hat, especially a baseball cap, as disrespectful in the presence of a deceased body. Wearing a hat is, therefore, not allowed in the lab, except for religious reasons.
6. Closed toed shoes are required at all times in the lab.
7. Disposable nitrile gloves must be worn when handling the dissections.
8. No smoking, eating, or drinking is permitted in the lab.
9. No photograph or video recording may be taken without the permission of the Head of the School of Anatomy. Since most cell phones have a camera, use of cell phones inside the anatomy lab is not allowed.

By signing below, you agree that you have read and will abide by the rules and regulations of the human anatomy lab.

Printed Name: Tyler S. Beveridge Date: May 15, 2013

Signature: _____

Part III - Request for Photography/Videography

Please provide the following information:

Name: Tyler S. BeveridgeDepartment or Affiliation: Anatomy and Cell Biology

Daytime Contact

Number: _____

Email Address: _____

Date of Laboratory Visit: Throughout Graduate Studies, 2013 - 2018

Specimens or Body

Regions to be Viewed: RetroperitoneumPurpose of Photography
and/or Videography(please be specific): Research Publications, Presentations and ThesisWho will see the results
of this project?Scientific Community via presentations and publications

Please sign below stating that you agree with the terms and conditions:

This request for photography and/or videography is solely in the interest of education. The results of this work will never be used to earn a profit.

Photographs and/or video recordings will not contain images that could identify the donor in any way.

SignatureMay 15, 2013
Date**Request Approved?**Yes x

No _____

SignatureMay 15, 2013
DateDirector of Clinical Anatomy, ACB

Title of Authority

Appendix F. Copyright Permissions

JOHN WILEY AND SONS LICENSE TERMS AND CONDITIONS

Jan 05, 2018

This Agreement between Western University -- Tyler Beveridge ("You") and John Wiley and Sons ("John Wiley and Sons") consists of your license details and the terms and conditions provided by John Wiley and Sons and Copyright Clearance Center.

License Number	4256530665899
License date	Dec 26, 2017
Licensed Content Publisher	John Wiley and Sons
Licensed Content Publication	Journal of Anatomy
Licensed Content Title	Anatomy of the nerves and ganglia of the aortic plexus in males
Licensed Content Author	Tyler S. Beveridge, Marjorie Johnson, Adam Power, Nicholas E. Power, Brian L. Allman
Licensed Content Date	Nov 9, 2014
Licensed Content Pages	11
Type of Use	Dissertation/Thesis
Requestor type	Author of this Wiley article
Format	Print and electronic
Portion	Full article
Will you be translating?	No
Title of your thesis / dissertation	Anatomy of the Infrarenal Aortic Plexus: Implications for Nerve-sparing Retroperitoneal Lymph Node Dissection
Expected completion date	Mar 2018
Expected size (number of pages)	200
Requestor Location	Western University 1551 Richmond Street London, ON N6A 3K7 Canada Attn: Western University
Publisher Tax ID	EU826007151
Billing Type	Invoice
Billing Address	Western University 1551 Richmond Street London, ON N6A 3K7 Canada Attn: Western University
Total	0.00 CAD

JOHN WILEY AND SONS LICENSE TERMS AND CONDITIONS

Jan 05, 2018

This Agreement between Western University -- Tyler Beveridge ("You") and John Wiley and Sons ("John Wiley and Sons") consists of your license details and the terms and conditions provided by John Wiley and Sons and Copyright Clearance Center.

License Number	4256530719739
License date	Dec 26, 2017
Licensed Content Publisher	John Wiley and Sons
Licensed Content Publication	Journal of Anatomy
Licensed Content Title	Histological verification of the prehypogastric and ovarian ganglia confirms a bilaterally symmetrical organization of the ganglia comprising the aortic plexus in female human cadavers
Licensed Content Author	Tyler S. Beveridge, Marjorie Johnson, Nicholas E. Power, Brian L. Allman
Licensed Content Date	Jan 11, 2016
Licensed Content Pages	7
Type of Use	Dissertation/Thesis
Requestor type	Author of this Wiley article
Format	Print and electronic
Portion	Full article
Will you be translating?	No
Title of your thesis / dissertation	Anatomy of the Infrarenal Aortic Plexus: Implications for Nerve-sparing Retroperitoneal Lymph Node Dissection
Expected completion date	Mar 2018
Expected size (number of pages)	200
Requestor Location	Western University 1551 Richmond Street London, ON N6A 3K7 Canada Attn: Western University
Publisher Tax ID	EU826007151
Billing Type	Invoice
Billing Address	Western University 1551 Richmond Street London, ON N6A 3K7 Canada Attn: Western University
Total	0.00 CAD

JOHN WILEY AND SONS LICENSE TERMS AND CONDITIONS

Jan 05, 2018

This Agreement between Western University -- Tyler Beveridge ("You") and John Wiley and Sons ("John Wiley and Sons") consists of your license details and the terms and conditions provided by John Wiley and Sons and Copyright Clearance Center.

License Number	4256530766842
License date	Dec 26, 2017
Licensed Content Publisher	John Wiley and Sons
Licensed Content Publication	Journal of Anatomy
Licensed Content Title	The anatomy of the infrarenal lumbar splanchnic nerves in human cadavers: implications for retroperitoneal nerve-sparing surgery
Licensed Content Author	Tyler S. Beveridge, Dale E. Fournier, Adam M.R. Groh, Marjorie Johnson, Nicholas E. Power, Brian L. Allman
Licensed Content Date	Nov 21, 2017
Licensed Content Pages	10
Type of Use	Dissertation/Thesis
Requestor type	Author of this Wiley article
Format	Print and electronic
Portion	Full article
Will you be translating?	No
Title of your thesis / dissertation	Anatomy of the Infrarenal Aortic Plexus: Implications for Nerve-sparing Retroperitoneal Lymph Node Dissection
Expected completion date	Mar 2018
Expected size (number of pages)	200
Requestor Location	Western University 1551 Richmond Street London, ON N6A 3K7 Canada Attn: Western University
Publisher Tax ID	EU826007151
Billing Type	Invoice
Billing Address	Western University 1551 Richmond Street London, ON N6A 3K7 Canada Attn: Western University
Total	0.00 CAD

JOHN WILEY AND SONS LICENSE TERMS AND CONDITIONS

This copyrighted material is owned by or exclusively licensed to John Wiley & Sons, Inc. or one of its group companies (each a "Wiley Company") or handled on behalf of a society with which a Wiley Company has exclusive publishing rights in relation to a particular work (collectively "WILEY"). By clicking "accept" in connection with completing this licensing transaction, you agree that the following terms and conditions apply to this transaction (along with the billing and payment terms and conditions established by the Copyright Clearance Center Inc., ("CCC's Billing and Payment terms and conditions"), at the time that you opened your RightsLink account (these are available at any time at <http://myaccount.copyright.com>).

Terms and Conditions

- The materials you have requested permission to reproduce or reuse (the "Wiley Materials") are protected by copyright.
- You are hereby granted a personal, non-exclusive, non-sub licensable (on a stand-alone basis), non-transferable, worldwide, limited license to reproduce the Wiley Materials for the purpose specified in the licensing process. This license, **and any CONTENT (PDF or image file) purchased as part of your order**, is for a one-time use only and limited to any maximum distribution number specified in the license. The first instance of republication or reuse granted by this license must be completed within two years of the date of the grant of this license (although copies prepared before the end date may be distributed thereafter). The Wiley Materials shall not be used in any other manner or for any other purpose, beyond what is granted in the license. Permission is granted subject to an appropriate acknowledgement given to the author, title of the material/book/journal and the publisher. You shall also duplicate the copyright notice that appears in the Wiley publication in your use of the Wiley Material. Permission is also granted on the understanding that nowhere in the text is a previously published source acknowledged for all or part of this Wiley Material. Any third party content is expressly excluded from this permission.
- With respect to the Wiley Materials, all rights are reserved. Except as expressly granted by the terms of the license, no part of the Wiley Materials may be copied, modified, adapted (except for minor reformatting required by the new Publication), translated, reproduced, transferred or distributed, in any form or by any means, and no derivative works may be made based on the Wiley Materials without the prior permission of the respective copyright owner. **For STM Signatory Publishers clearing permission under the terms of the [STM Permissions Guidelines](#) only, the terms of the license are extended to include subsequent editions and for editions in other languages, provided such editions are for the work as a whole in situ and does not involve the separate exploitation of the permitted figures or extracts**. You may not alter, remove or suppress in any manner any copyright, trademark or other notices displayed by the Wiley Materials. You may not license, rent, sell, loan, lease, pledge, offer as security, transfer or assign the Wiley Materials on a stand-alone basis, or any of the rights granted to you hereunder to any other person.
- The Wiley Materials and all of the intellectual property rights therein shall at all times remain the exclusive property of John Wiley & Sons Inc, the Wiley Companies, or their respective licensors, and your interest therein is only that of having possession of and the right to reproduce the Wiley Materials pursuant to Section 2 herein during the continuance of this Agreement. You agree that you own no right, title or interest in or to the Wiley Materials or any of the intellectual property rights therein. You shall have no rights hereunder other than the license as provided for above in Section 2. No right, license or interest to any trademark, trade name, service mark or other branding ("Marks") of WILEY or its licensors is granted hereunder, and you agree that you shall not assert any such right, license or interest with respect thereto
- NEITHER WILEY NOR ITS LICENSORS MAKES ANY WARRANTY OR REPRESENTATION OF ANY KIND TO YOU OR ANY THIRD PARTY, EXPRESS, IMPLIED OR STATUTORY, WITH RESPECT TO THE MATERIALS OR THE ACCURACY OF ANY INFORMATION CONTAINED IN THE MATERIALS, INCLUDING, WITHOUT LIMITATION, ANY IMPLIED WARRANTY OF MERCHANTABILITY, ACCURACY, SATISFACTORY QUALITY, FITNESS FOR A PARTICULAR PURPOSE, USABILITY, INTEGRATION OR NON-INFRINGEMENT AND ALL SUCH WARRANTIES ARE HEREBY EXCLUDED BY WILEY AND ITS LICENSORS AND WAIVED BY YOU.
- WILEY shall have the right to terminate this Agreement immediately upon breach of this Agreement by you.
- You shall indemnify, defend and hold harmless WILEY, its Licensors and their respective directors, officers, agents and employees, from and against any actual or threatened claims, demands, causes of action or proceedings arising from any breach of this Agreement by you.
- IN NO EVENT SHALL WILEY OR ITS LICENSORS BE LIABLE TO YOU OR ANY OTHER PARTY OR ANY OTHER PERSON OR ENTITY FOR ANY SPECIAL, CONSEQUENTIAL, INCIDENTAL, INDIRECT, EXEMPLARY OR PUNITIVE DAMAGES, HOWEVER CAUSED, ARISING OUT OF OR IN CONNECTION WITH THE DOWNLOADING, PROVISIONING, VIEWING OR USE OF THE MATERIALS REGARDLESS OF THE FORM OF ACTION, WHETHER FOR BREACH OF CONTRACT, BREACH OF WARRANTY, TORT, NEGLIGENCE, INFRINGEMENT OR OTHERWISE (INCLUDING, WITHOUT LIMITATION, DAMAGES BASED ON LOSS OF PROFITS, DATA, FILES, USE, BUSINESS OPPORTUNITY OR CLAIMS OF THIRD PARTIES), AND WHETHER OR NOT THE PARTY HAS BEEN ADVISED OF THE POSSIBILITY OF SUCH DAMAGES. THIS LIMITATION SHALL APPLY NOTWITHSTANDING ANY FAILURE OF ESSENTIAL PURPOSE OF ANY LIMITED REMEDY PROVIDED HEREIN.

- Should any provision of this Agreement be held by a court of competent jurisdiction to be illegal, invalid, or unenforceable, that provision shall be deemed amended to achieve as nearly as possible the same economic effect as the original provision, and the legality, validity and enforceability of the remaining provisions of this Agreement shall not be affected or impaired thereby.
- The failure of either party to enforce any term or condition of this Agreement shall not constitute a waiver of either party's right to enforce each and every term and condition of this Agreement. No breach under this agreement shall be deemed waived or excused by either party unless such waiver or consent is in writing signed by the party granting such waiver or consent. The waiver by or consent of a party to a breach of any provision of this Agreement shall not operate or be construed as a waiver of or consent to any other or subsequent breach by such other party.
- This Agreement may not be assigned (including by operation of law or otherwise) by you without WILEY's prior written consent.
- Any fee required for this permission shall be non-refundable after thirty (30) days from receipt by the CCC.
- These terms and conditions together with CCC's Billing and Payment terms and conditions (which are incorporated herein) form the entire agreement between you and WILEY concerning this licensing transaction and (in the absence of fraud) supersedes all prior agreements and representations of the parties, oral or written. This Agreement may not be amended except in writing signed by both parties. This Agreement shall be binding upon and inure to the benefit of the parties' successors, legal representatives, and authorized assigns.
- In the event of any conflict between your obligations established by these terms and conditions and those established by CCC's Billing and Payment terms and conditions, these terms and conditions shall prevail.
- WILEY expressly reserves all rights not specifically granted in the combination of (i) the license details provided by you and accepted in the course of this licensing transaction, (ii) these terms and conditions and (iii) CCC's Billing and Payment terms and conditions.
- This Agreement will be void if the Type of Use, Format, Circulation, or Requestor Type was misrepresented during the licensing process.
- This Agreement shall be governed by and construed in accordance with the laws of the State of New York, USA, without regards to such state's conflict of law rules. Any legal action, suit or proceeding arising out of or relating to these Terms and Conditions or the breach thereof shall be instituted in a court of competent jurisdiction in New York County in the State of New York in the United States of America and each party hereby consents and submits to the personal jurisdiction of such court, waives any objection to venue in such court and consents to service of process by registered or certified mail, return receipt requested, at the last known address of such party.

WILEY OPEN ACCESS TERMS AND CONDITIONS

Wiley Publishes Open Access Articles in fully Open Access Journals and in Subscription journals offering Online Open. Although most of the fully Open Access journals publish open access articles under the terms of the Creative Commons Attribution (CC BY) License only, the subscription journals and a few of the Open Access Journals offer a choice of Creative Commons Licenses. The license type is clearly identified on the article.

The Creative Commons Attribution License

The [Creative Commons Attribution License \(CC-BY\)](#) allows users to copy, distribute and transmit an article, adapt the article and make commercial use of the article. The CC-BY license permits commercial and non-

Creative Commons Attribution Non-Commercial License

The [Creative Commons Attribution Non-Commercial \(CC-BY-NC\) License](#) permits use, distribution and reproduction in any medium, provided the original work is properly cited and is not used for commercial purposes.(see below)

Creative Commons Attribution-Non-Commercial-NoDerivs License

The [Creative Commons Attribution Non-Commercial-NoDerivs License](#) (CC-BY-NC-ND) permits use, distribution and reproduction in any medium, provided the original work is properly cited, is not used for commercial purposes and no modifications or adaptations are made. (see below)

Use by commercial "for-profit" organizations

Use of Wiley Open Access articles for commercial, promotional, or marketing purposes requires further explicit permission from Wiley and will be subject to a fee.

Further details can be found on Wiley Online Library <http://olabout.wiley.com/WileyCDA/Section/id-410895.html>

Other Terms and Conditions:

v1.10 Last updated September 2015

ELSEVIER LICENSE TERMS AND CONDITIONS

Jan 05, 2018

This Agreement between Western University -- Tyler Beveridge ("You") and Elsevier ("Elsevier") consists of your license details and the terms and conditions provided by Elsevier and Copyright Clearance Center.

License Number	4262710962871
License date	Jan 05, 2018
Licensed Content Publisher	Elsevier
Licensed Content Publication	The Journal of Urology
Licensed Content Title	Retroperitoneal Lymph Node Dissection: Anatomical and Technical Considerations from a Cadaveric Study
Licensed Content Author	Tyler S. Beveridge, Brian L. Allman, Marjorie Johnson, Adam Power, Joel Sheinfeld, Nicholas E. Power
Licensed Content Date	Dec 1, 2016
Licensed Content Volume	196
Licensed Content Issue	6
Licensed Content Pages	8
Start Page	1764
End Page	1771
Type of Use	reuse in a thesis/dissertation
Intended publisher of new work	other
Portion	full article
Format	both print and electronic
Are you the author of this Elsevier article?	Yes
Will you be translating?	No
Title of your thesis/dissertation	Anatomy of the Infrarenal Aortic Plexus: Implications for Nerve-sparing Retroperitoneal Lymph Node Dissection
Expected completion date	Mar 2018
Estimated size (number of pages)	200
Requestor Location	Western University 1551 Richmond Street London, ON N6A 3K7 Canada Attn: Western University
Billing Type	Invoice
Billing Address	Western University 1551 Richmond Street London, ON N6A 3K7 Canada Attn: Western University
Total	0.00 CAD

ELSEVIER LICENSE TERMS AND CONDITIONS

Jan 05, 2018

This Agreement between Western University -- Tyler Beveridge ("You") and Elsevier ("Elsevier") consists of your license details and the terms and conditions provided by Elsevier and Copyright Clearance Center.

License Number	4262711110081
License date	Jan 05, 2018
Licensed Content Publisher	Elsevier
Licensed Content Publication	The Journal of Urology
Licensed Content Title	Retroperitoneal Lymphadenectomy for Testis Tumor with Nerve Sparing for Ejaculation
Licensed Content Author	Michael A.S. Jewett, Young-Soo P. Kong, Susan D. Goldberg, Jeremy F.G. Sturgeon, Gillian M. Thomas, Ruth E. Alison, Mary K. Gospodarowicz
Licensed Content Date	Jun 1, 1988
Licensed Content Volume	139
Licensed Content Issue	6
Licensed Content Pages	4
Start Page	1220
End Page	1223
Type of Use	reuse in a thesis/dissertation
Intended publisher of new work	other
Portion	figures/tables/illustrations
Number of figures/tables/illustrations	1
Format	both print and electronic
Are you the author of this Elsevier article?	No
Will you be translating?	No
Original figure numbers	Table 1
Title of your thesis/dissertation	Anatomy of the Infrarenal Aortic Plexus: Implications for Nerve-sparing Retroperitoneal Lymph Node Dissection
Expected completion date	Mar 2018
Estimated size (number of pages)	200
Requestor Location	Western University 1551 Richmond Street London, ON N6A 3K7 Canada Attn: Western University
Billing Type	Invoice
Billing Address	Western University 1551 Richmond Street London, ON N6A 3K7 Canada Attn: Western University
Total	0.00 CAD

ELSEVIER LICENSE TERMS AND CONDITIONS

INTRODUCTION

1. The publisher for this copyrighted material is Elsevier. By clicking "accept" in connection with completing this licensing transaction, you agree that the following terms and conditions apply to this transaction (along with the Billing and Payment terms and conditions established by Copyright Clearance Center, Inc. ("CCC"), at the time that you opened your Rightslink account and that are available at any time at <http://myaccount.copyright.com>).

GENERAL TERMS

2. Elsevier hereby grants you permission to reproduce the aforementioned material subject to the terms and conditions indicated.

3. Acknowledgement: If any part of the material to be used (for example, figures) has appeared in our publication with credit or acknowledgement to another source, permission must also be sought from that source. If such permission is not obtained then that material may not be included in your publication/copies. Suitable acknowledgement to the source must be made, either as a footnote or in a reference list at the end of your publication, as follows:

"Reprinted from Publication title, Vol /edition number, Author(s), Title of article / title of chapter, Pages No., Copyright (Year), with permission from Elsevier [OR APPLICABLE SOCIETY COPYRIGHT OWNER]." Also Lancet special credit - "Reprinted from The Lancet, Vol. number, Author(s), Title of article, Pages No., Copyright (Year), with permission from Elsevier."

4. Reproduction of this material is confined to the purpose and/or media for which permission is hereby given.

5. Altering/Modifying Material: Not Permitted. However figures and illustrations may be altered/adapted minimally to serve your work. Any other abbreviations, additions, deletions and/or any other alterations shall be made only with prior written authorization of Elsevier Ltd. (Please contact Elsevier). No modifications can be made to any Lancet figures/tables and they must be reproduced in full.

6. If the permission fee for the requested use of our material is waived in this instance, please be advised that your future requests for Elsevier materials may attract a fee.

7. Reservation of Rights: Publisher reserves all rights not specifically granted in the combination of (i) the license details provided by you and accepted in the course of this licensing transaction, (ii) these terms and conditions and (iii) CCC's Billing and Payment terms and conditions.

8. License Contingent Upon Payment: While you may exercise the rights licensed immediately upon issuance of the license at the end of the licensing process for the transaction, provided that you have disclosed complete and accurate details of your proposed use, no license is finally effective unless and until full payment is received from you (either by publisher or by CCC) as provided in CCC's Billing and Payment terms and conditions. If full payment is not received on a timely basis, then any license preliminarily granted shall be deemed automatically revoked and shall be void as if never granted. Further, in the event that you breach any of these terms and conditions or any of CCC's Billing and Payment terms and conditions, the license is automatically revoked and shall be void as if never granted. Use of materials as described in a revoked license, as well as any use of the materials beyond the scope of an unrevoked license, may constitute copyright infringement and publisher reserves the right to take any and all action to protect its copyright in the materials.

9. Warranties: Publisher makes no representations or warranties with respect to the licensed material.

10. Indemnity: You hereby indemnify and agree to hold harmless publisher and CCC, and their respective officers, directors, employees and agents, from and against any and all claims arising out of your use of the licensed material other than as specifically authorized pursuant to this license.

11. No Transfer of License: This license is personal to you and may not be sublicensed, assigned, or transferred by you to any other person without publisher's written permission.

12. No Amendment Except in Writing: This license may not be amended except in a writing signed by both parties (or, in the case of publisher, by CCC on publisher's behalf).

13. Objection to Contrary Terms: Publisher hereby objects to any terms contained in any purchase order, acknowledgment, check endorsement or other writing prepared by you, which terms are inconsistent with these terms and conditions or CCC's Billing and Payment terms and conditions. These terms and conditions, together with CCC's Billing and Payment terms and conditions (which are incorporated herein), comprise the entire agreement between you and publisher (and CCC) concerning this licensing transaction. In the event of any conflict between your obligations established by these terms and conditions and those established by CCC's Billing and Payment terms and conditions, these terms and conditions shall control.

14. Revocation: Elsevier or Copyright Clearance Center may deny the permissions described in this License at their sole discretion, for any reason or no reason, with a full refund payable to you. Notice of such denial will be made using the contact information provided by you. Failure to receive such notice will not alter or invalidate the denial. In no event will Elsevier or Copyright Clearance Center be responsible or liable for any costs, expenses or damage incurred by you as a result of a denial of your permission request, other than a refund of the amount(s) paid by you to Elsevier and/or Copyright Clearance Center for denied permissions.

LIMITED LICENSE

The following terms and conditions apply only to specific license types:

15. Translation: This permission is granted for non-exclusive world **English** rights only unless your license was granted for translation rights. If you licensed translation rights you may only translate this content into the languages you requested. A professional translator must perform all translations and reproduce the content word for word preserving the integrity of the article.

16. Posting licensed content on any Website: The following terms and conditions apply as follows: Licensing material from an Elsevier journal: All content posted to the web site must maintain the copyright information line on the bottom of each image; A hyper-text must be included to the Homepage of the journal from which you are licensing at <http://www.sciencedirect.com/science/journal/xxxxx> or the Elsevier homepage for books at <http://www.elsevier.com>; Central Storage: This license does not include permission for a scanned version of the material to be stored in a central repository such as that provided by Heron/XanEdu.

Licensing material from an Elsevier book: A hyper-text link must be included to the Elsevier homepage at <http://www.elsevier.com>. All content posted to the web site must maintain the copyright information line on the bottom of each image.

Posting licensed content on Electronic reserve: In addition to the above the following clauses are applicable: The web site must be password-protected and made available only to bona fide students registered on a relevant course. This permission is granted for 1 year only. You may obtain a new license for future website posting.

17. For journal authors: the following clauses are applicable in addition to the above:

Preprints:

A preprint is an author's own write-up of research results and analysis, it has not been peer-reviewed, nor has it had any other value added to it by a publisher (such as formatting, copyright, technical enhancement etc.).

Authors can share their preprints anywhere at any time. Preprints should not be added to or enhanced in any way in order to appear more like, or to substitute for, the final versions of articles however authors can update their preprints on arXiv or RePEc with their Accepted Author Manuscript (see below).

If accepted for publication, we encourage authors to link from the preprint to their formal publication via its DOI. Millions of researchers have access to the formal publications on ScienceDirect, and so links will help users to find, access, cite and use the best available version. Please note that Cell Press, The Lancet and some society-owned have different preprint policies. Information on these policies is available on the journal homepage.

Accepted Author Manuscripts: An accepted author manuscript is the manuscript of an article that has been accepted for publication and which typically includes author-incorporated changes suggested during submission, peer review and editor-author communications.

Authors can share their accepted author manuscript:

- immediately
 - via their non-commercial person homepage or blog
 - by updating a preprint in arXiv or RePEc with the accepted manuscript
 - via their research institute or institutional repository for internal institutional uses or as part of an invitation-only research collaboration work-group
 - directly by providing copies to their students or to research collaborators for their personal use
 - for private scholarly sharing as part of an invitation-only work group on commercial sites with which Elsevier has an agreement
- After the embargo period
 - via non-commercial hosting platforms such as their institutional repository
 - via commercial sites with which Elsevier has an agreement

In all cases accepted manuscripts should:

- link to the formal publication via its DOI
- bear a CC-BY-NC-ND license - this is easy to do
- if aggregated with other manuscripts, for example in a repository or other site, be shared in alignment with our hosting policy not be added to or enhanced in any way to appear more like, or to substitute for, the published journal article.

Published journal article (JPA): A published journal article (PJA) is the definitive final record of published research that appears or will appear in the journal and embodies all value-adding publishing activities including peer review co-ordination, copy-editing, formatting, (if relevant) pagination and online enrichment.

Policies for sharing publishing journal articles differ for subscription and gold open access articles:

Subscription Articles: If you are an author, please share a link to your article rather than the full-text. Millions of researchers have access to the formal publications on ScienceDirect, and so links will help your users to find, access, cite, and use the best available version.

Theses and dissertations which contain embedded PJAs as part of the formal submission can be posted publicly by the awarding institution with DOI links back to the formal publications on ScienceDirect.

If you are affiliated with a library that subscribes to ScienceDirect you have additional private sharing rights for others' research accessed under that agreement. This includes use for classroom teaching and internal training at the institution (including use in course packs and courseware programs), and inclusion of the article for grant funding purposes.

Gold Open Access Articles: May be shared according to the author-selected end-user license and should contain a [CrossMark logo](#), the end user license, and a DOI link to the formal publication on ScienceDirect.

Please refer to Elsevier's [posting policy](#) for further information.

18. **For book authors** the following clauses are applicable in addition to the above: Authors are permitted to place a brief summary of their work online only. You are not allowed to download and post the published electronic version of your chapter, nor may you scan the printed edition to create an electronic version. **Posting to a repository:** Authors are permitted to post a summary of their chapter only in their institution's repository.

19. **Thesis/Dissertation:** If your license is for use in a thesis/dissertation your thesis may be submitted to your institution in either print or electronic form. Should your thesis be published commercially, please reapply for permission. These requirements include permission for the Library and Archives of Canada to supply single copies, on demand, of the complete thesis and include permission for Proquest/UML to supply single copies, on demand, of the complete thesis. Should your thesis be published commercially, please reapply for permission. Theses and dissertations which contain embedded PJAs as part of the formal submission can be posted publicly by the awarding institution with DOI links back to the formal publications on ScienceDirect.

Elsevier Open Access Terms and Conditions

You can publish open access with Elsevier in hundreds of open access journals or in nearly 2000 established subscription journals that support open access publishing. Permitted third party re-use of these open access articles is defined by the author's choice of Creative Commons user license. See our [open access license policy](#) for more information.

Terms & Conditions applicable to all Open Access articles published with Elsevier:

Any reuse of the article must not represent the author as endorsing the adaptation of the article nor should the article be modified in such a way as to damage the author's honour or reputation. If any changes have been made, such changes must be clearly indicated.

The author(s) must be appropriately credited and we ask that you include the end user license and a DOI link to the formal publication on ScienceDirect.

If any part of the material to be used (for example, figures) has appeared in our publication with credit or acknowledgement to another source it is the responsibility of the user to ensure their reuse complies with the terms and conditions determined by the rights holder.

Additional Terms & Conditions applicable to each Creative Commons user license:

CC BY: The CC-BY license allows users to copy, to create extracts, abstracts and new works from the Article, to alter and revise the Article and to make commercial use of the Article (including reuse and/or resale of the Article by commercial entities), provided the user gives appropriate credit (with a link to the formal publication through the relevant DOI), provides a link to the license, indicates if changes were made and the licensor is not represented as endorsing the use made of the work. The full details of the license are available at <http://creativecommons.org/licenses/by/4.0>.

CC BY NC SA: The CC BY-NC-SA license allows users to copy, to create extracts, abstracts and new works from the Article, to alter and revise the Article, provided this is not done for commercial purposes, and that the user gives appropriate credit (with a link to the formal publication through the relevant DOI), provides a link to the license, indicates if changes were made and the licensor is not represented as endorsing the use made of the work. Further, any new works must be made available on the same conditions. The full details of the license are available at <http://creativecommons.org/licenses/by-nc-sa/4.0>.

CC BY NC ND: The CC BY-NC-ND license allows users to copy and distribute the Article, provided this is not done for commercial purposes and further does not permit distribution of the Article if it is changed or edited in any way, and provided the user gives appropriate credit (with a link to the formal publication through the relevant DOI), provides a link to the license, and that the licensor is not represented as endorsing the use made of the work. The full details of the license are available at <http://creativecommons.org/licenses/by-nc-nd/4.0>. Any commercial reuse of Open Access articles published with a CC BY NC SA or CC BY NC ND license requires permission from Elsevier and will be subject to a fee.

Commercial reuse includes:

- Associating advertising with the full text of the Article
- Charging fees for document delivery or access
- Article aggregation
- Systematic distribution via e-mail lists or share buttons

Posting or linking by commercial companies for use by customers of those companies.

20. Other Conditions:

v1.9

CURRICULUM VITAE

TYLER S. BEVERIDGE

DEPARTMENT: Anatomy and Cell Biology

REVISION DATE: December 20, 2017

ADDRESS: Western University, Schulich School of Medicine and Dentistry, Department of Anatomy & Cell Biology, Dental Sciences Building, Rm 4010A, London ON, Canada, N6A 5C1

EDUCATION

University Degrees

2018/03	PhD	Western University, Canada	Anatomy & Cell Biology
2014/04	MSc	Western University, Canada	Clinical Anatomy
2011/04	BHSc	McMaster University, Canada	Health Sciences (Music Min.)

Doctoral Thesis

2014 – 2018 Anatomy of the Infrarenal Aortic Implications for Nerve-Sparing RPLND

Supervisors

Dr. Brian Allman, PhD
Dr. Nicholas Power, MD

Master's Thesis

2012 – 2014 Vascular Anatomy of Retroperitoneal Lymph Node Dissections for Testis Cancer: A Cadaveric Study Characterizing Patterns and Variation of the Lumbar Arteries and Veins

Dr. Nicholas Power, MD

Honour's Thesis

2010 – 2011 Evaluating the Use of Reflective Practice in a Nonprofessional, Undergraduate Clinical Communication Skills Course

Carl deLottinville, MSW

RELATED WORK EXPERIENCE

2014 – 2017	Instructor/Lecturer, Dept. of Anatomy & Cell Biology, UWO
2012 – 2017	Teaching Assistant, Dept. of Anatomy & Cell Biology, UWO
2015/09	Visiting Professor, Dept. of Anatomy, Embryology and Histology, American University of the Caribbean School of Medicine

AWARDS, HONOURS, FELLOWSHIPS & SCHOLARSHIPS

Awards and Honours

2017	Best Overall 3D Printed Medical Device; MedicalMarker.org Make-A-Thon
2016	Francis Chan Humanitarian Award; altruism, compassion and selflessness
2016/02	Publication of the Month; Schulich Medicine & Dentistry's Current Affairs
2015	1 st Place Grad Student Poster; American Association of Anatomists Intl' Meeting
2014	Alan W. Hrychshyn Award in Clinical Anatomy; special merit and achievement
2014	1 st Place Grad Student Poster; American Association of Anatomists Intl' Meeting
2014	Western's Certificate in University Teaching and Learning
2008 – 2011	Dean's Honour List, McMaster University

Fellowships and Scholarships

2018	Propel Summer Incubator (PSI) Fellowship (offered), value \$15,000
2018	Western Accelerator Entrepreneurial Fellowship (declined), value \$12,000
2017	WORLDiscoveries® – Student Innovation Scholars Fellowship, value \$1,500
2017	Nellie L. Farthing Memorial Fellowship in the Medical Sciences, value \$3,000
2017	Drs. M. and C. Macklin Fellowship for Teaching & Research in Medical Sciences, value \$4,250
2016 – 2018	Doctoral Excellence Research Award, value \$10,000/yr
2015 – 2018	Canadian Institutes of Health Research (CIHR), Doctoral Award (CGS-D), value \$35,000/yr
2015	Nellie L. Farthing Memorial Fellowship in the Medical Sciences, value \$3,000
2015	Ontario Graduate Scholarship (declined), value \$15,000
2014	Anatomy & Cell Biology PhD Entrance Scholarship, value \$10,000
2014 – 2017	American Association of Anatomists Student Travel Scholarship, value \$350/yr
2012 – 2018	Western Graduate Research Scholarship, value \$4,500/yr
2007 – 2011	McMaster President's Award of Excellence, value \$12,000

PUBLICATIONS

Published Articles in Peer-Reviewed Journals

8. Groh A, Moore CW, El-Warrak A, Seager S, Power NE, Allman BL and **Beveridge TS** (2018). Electroejaculation Functions Primarily by Direct Activation of Pelvic Musculature: Perspectives from a Porcine Model. *Translational Research in Anatomy*. In Press. DOI: 10.1013/j.tria.2018.01.001
7. **Beveridge TS**, Fournier DE, Groh A, Johnson M, Power NE, Allman BL (2017). The Anatomy of the Infrarenal Lumbar Splanchnic Nerves in Human Cadavers: Implications for Retroperitoneal Nerve-Sparing Surgery. *Journal of Anatomy*. 232(1): 124-133.
6. Moore CW, **Beveridge TS**, Rice CL (2017). Fiber Type Composition of the Palmaris Brevis Muscle: Implications for Palmar Function. *Journal of Anatomy*. 231(4): 626-633.
5. **Beveridge TS**, Allman BL, Johnson M, Power A, Sheinfeld, J and Power NE. (2016). Retroperitoneal lymph node dissection: Anatomical and technical considerations from a cadaveric study. *Journal of Urology*. 196(6):1764-1771.

4. **Beveridge TS**, Johnson M, Power NE and Allman BL (2016). Histological verification of the prehypogastric and ovarian ganglia confirms a bilaterally symmetrical organization of the ganglia comprising the aortic plexus in female human cadavers. *Journal of Anatomy*. 228(5): 805-811.
3. **Beveridge TS**, Johnson M, Power A, Power NE and Allman BL (2015). Anatomy of the nerves and ganglia of the aortic plexus in males. *Journal of Anatomy*. 226(1):93-103.
2. **Beveridge TS**, Johnson M, Power A, Power NE and Allman BL (2015). The lumbar arteries and veins: quantification of variable anatomical positioning with application to retroperitoneal surgery. *Clinical Anatomy*. 28(5): 649-660.
1. **Beveridge TS**, Fruchter LL, Sanmartin CV, deLottinville CB (2013). Evaluating the use of reflection in the teaching and learning of communication skills. *Teaching in Higher Education*, 19(1): 58-71.

Journal Articles Currently Under Peer-Review

2. Hewison C, Kolaczek S, Catherine S, Berardelli R, Lording T, **Beveridge TS**, Akindolire J, Herman B, Hurtig M, Gordon K, Getgood A (In Review). Meniscal Allograft Extrusion under Physiological Load - a Cadaveric Comparison of Two Surgical Techniques. *Knee Surgery, Sports Traumatology, Arthroscopy*.
1. Kolaczek S, Hewison C, Catherine S, Berardelli R, **Beveridge TS**, Herman B, Hurtig M, Getgood A, Gordon K (In Review). 3D Strain in Native Medial Meniscus Is Comparable to Medial Meniscus Allograft Transplant. *Knee Surgery, Sports Traumatology, Arthroscopy*.

Peer-Reviewed Conference Proceedings (Only International Conferences are Listed)

11. Legault JA, **Beveridge TS**, Johnson MI, Lanting BA (2018). Subvastus Lateralis Approach to Total Knee Arthroplasty – A Cadaveric Evaluation. *American Association of Anatomists at Experimental Biology*, San Diego CA.
10. Groh AMR, Moore CW, El-Warrak A, Seager SW, Power N, Allman BL, **Beveridge TS** (2017). What is the Mechanism Underlying Electroejaculation? Evidence from a Porcine Model. *American Association of Anatomists Regional Meeting*, Pittsburgh PA.
9. **Beveridge TS**, Groh AM, Moore CW, El-Warrak A, Johnson M, Power N, Allman BL (2017). Development of a Porcine Model to Study the Aortic Plexus and Innervation to the Internal Urethral Sphincter: Implications for Preventing Retrograde Ejaculation. *The FASEB Journal*, 31(1 Suppl.), 899-3. *American Association of Anatomists at Experimental Biology*, Chicago IL.
8. Moore CW, **Beveridge TS**, Rice CL (2017). Does Palmaris Brevis Structure Allow for Protection Against Prolonged Overlying Compression? An Ultrasound and Immunohistochemical Investigation. *The FASEB Journal*, 31(1 Suppl.), 902-15. *American Association of Anatomists at Experimental Biology*, Chicago IL.
7. **Beveridge TS**, Johnson M, Power N, Allman BL (2016). Standardization of nodal counting in the obturator fossa of cadaveric specimens. *The FASEB Journal*, 30(1 Suppl.), 1045-5. *American Association of Anatomists at Experimental Biology*, San Diego CA.
6. **Beveridge TS**, Johnson M, Power N, Allman BL (2015). Histology of the Ovarian Ganglia and Prehypogastric Ganglion of the Aortic Plexus in Females. *American Association of Anatomists Canadian Regional Meeting*, London ON.

5. **Beveridge T**, Johnson M, Power N, Allman B (2015). A histological examination of the ovarian ganglia and prehypogastric ganglion of the aortic plexus in females. *The FASEB Journal*, 29(1 Suppl.), 703-1. American Association of Anatomists at Experimental Biology, Boston MA.
4. Mintz N, **Beveridge TS**, Sandig M, Johnson M, Allman BL (2015). A histological examination of the lumbar sympathetic trunk. *The FASEB Journal*, 29(1 Suppl.), 703-2. American Association of Anatomists at Experimental Biology, Boston MA.
3. **Beveridge TS**, Johnson M, Power A, Allman BL, Power N (2014). The anatomy of post-chemotherapy retroperitoneal lymph node dissections for testis cancer: A cadaveric study of the aortic plexus and patterns of the lumbar vessels. *Canadian Urological Association Journal*, 8(5-6 Suppl. 3). Canadian Urology Association, St. John's NF.
2. **Beveridge TS**, Johnson M, Power A, Allman BL, Power N (2014). MP10-08 An anatomical perspective of post-chemotherapy retroperitoneal lymph node dissections: The aortic plexus and variations in lumbar vessels. *The Journal of Urology*, 191(4 Suppl.). American Urology Association, Orlando FL.
1. **Beveridge TS**, Johnson M, Power A, Power N, Allman BL (2014). An anatomical update of the aortic plexus with clinical implications for retroperitoneal surgery. *The FASEB Journal*, 28(1 Suppl.), 726-6. American Association of Anatomists at Experimental Biology, San Diego CA.

Invited Lectures

6. **Beveridge TS** (2017). Preventing Ejaculatory Dysfunction following Testicular Cancer Surgery: A Multi-Modal Approach from Cadavers to Clinic. Departmental Seminar. *Department of Anatomy and Cell Biology Seminar Series*. Western University London ON.
5. **Beveridge TS** (2017). Preventing Functional Infertility in Males Undergoing Retroperitoneal Surgery: Development of a Translational Model of Ejaculation. Invited Lecture. *Canadian Association for Laboratory Animal Science Conference*. London ON.
4. **Beveridge TS** (2016). Clinically-oriented cadaveric research: Discovery of the prehypogastric ganglion and its possible implications for preventing post-operative ejaculatory dysfunction. Invited Talk. *Asia-Pacific International Congress of Anatomist (APICA)*. Singapore.
3. **Beveridge TS** (2014). An Anatomical Perspective of pc-RPLND: The Aortic Plexus and Variations in Lumbar Vessels. Moderated Poster. *American Urology Association Annual Meeting*. Orlando FL.
2. **Beveridge TS** (2014). The anatomy of RPLND: A cadaveric study of the aortic plexus and the lumbar vessels. *JK Wyatt Urology Research Day*. London ON.
1. **Beveridge TS** (2013). A novel ganglion of the aortic plexus: Rekindling discovery in cadaveric anatomy. *Anatomy & Cell Biology Research Day*. London ON.