



Anatomy of the lateral retinaculum of the knee

A. M. Merican,
A. A. Amis

From Imperial
College London,
London, England

Anatomical descriptions of the lateral retinaculum have been published, but the attachments, name or even existence of its tissue bands and layers are ill-defined. We have examined 35 specimens of the knee. The deep fascia is the most superficial layer and the joint capsule is the deepest. The intermediate layer is the most substantial and consists of derivatives of the iliotibial band and the quadriceps aponeurosis. The longitudinal fibres of the iliotibial band merge with those of the quadriceps aponeurosis adjacent to the patella. These longitudinal fibres are reinforced by superficial arciform fibres and on the deep aspect by transverse fibres of the iliotibial band. The latter are dense and provide attachment of the iliotibial band to the patella and the tendon of vastus lateralis obliquus.

Our study identifies two important new findings which are a constant connection of the deep fascia to the quadriceps tendon superior and lateral to the patella, and, a connection of the deeper transverse fibres to the tendon of vastus lateralis obliquus.

The lateral retinaculum of the knee is not a distinct anatomical structure but is composed of various fascial layers on the anterolateral aspect of the joint. The anatomy of the lateral retinaculum has been described, but the literature includes differing interpretations of the tissue bands and layers of the retinaculum, their names, attachments or even their existence. The medial patellofemoral ligament has been examined more recently and its detailed anatomy characterised.¹⁻⁵ This introduction will describe some of the different interpretations of the anatomy of the lateral retinaculum which have been published previously.

According to Kaplan,⁶ the first fascial layer is the fascia lata, the deep fascia, which envelops the knee from the thigh. It covers the patellar region but does not adhere to the quadriceps apparatus. The iliotibial band is integral to the deep fascia and is a lateral thickening of it. An anterior expansion of the iliotibial band curves forward to form a group of arciform fibres which blend with the fascia lata covering the patella.

Fulkerson and Gossling⁷ described the anatomy of the lateral retinaculum in two separate layers. The superficial oblique layer originates from the iliotibial band and interdigitates with the longitudinal fibres of vastus lateralis. The deep layer consists of the deep transverse retinaculum with the epicondylopatellar ligament proximally and the patellofibular ligament dis-

tally. The latter proceeds obliquely to attach to the lateral meniscus and the tibia. The epicondylopatellar ligament is probably the same as a ligament described by Kaplan,⁸ who introduced the terms epicondylopatellar ligament (superior retinaculum) and meniscopatellar ligament (inferior patellar retinaculum). The diagram in his article depicts a patella infera in which the epicondylopatellar ligament arising from the superior aspect of the patella is attached proximally to the lateral femoral epicondyle. It does not clearly define whether the epicondylopatellar ligament is derived from an expansion of the quadriceps apparatus or from the capsule.

Reider et al⁹ described the lateral patellofemoral ligament as a palpable thickening of the joint capsule connecting the patella to the femoral epicondyle. They felt that this was in agreement with Kaplan's description of the lateral epicondylopatellar ligament. Fulkerson and Gossling⁷ also claimed agreement with Kaplan, but described the band as extra-capsular.

Others have given differing versions of the lateral retinaculum. Some have stated that it consists of a longitudinal and horizontal component,^{10,11} while others have described multiple layers¹² and complex interconnections.¹³

Descriptions of the anatomy of the lateral joint capsule in relation to the patellofemoral

■ A. M. Merican, BM,
MS(Orth), Associate Professor
Department of Orthopaedic
Surgery
University of Malaya Medical
Center, 59100 Kuala Lumpur,
Malaysia.

■ A. A. Amis, DSc(Eng),
Professor
Departments of Mechanical
Engineering and
Musculoskeletal Surgery
Imperial College London, South
Kensington Campus, London
SW7 2AZ, UK.

Correspondence should be sent
to Professor A. A. Amis; e-mail:
a.amis@imperial.ac.uk

©2008 British Editorial Society
of Bone and Joint Surgery
doi:10.1302/0301-620X.90B4.
20085 \$2.00

J Bone Joint Surg [Br]
2008;90-B:527-34.
Received 13 August 2007;
Accepted 7 December 2007

joint also vary. Fulkerson and Gossling⁷ described the combined structure of the joint capsule and synovium as thin, providing little retinacular support. Others have described the complex arrangement of the joint capsule and recognised its role in tibiofemoral stability, but have made no specific mention of the patellofemoral joint.^{12,13} However, some authors have suggested that these capsular bands have a role in stabilising the patellofemoral joint and have described these thickenings as ligaments with various names.⁸⁻¹¹ These ligaments vary in width and may be absent in one-third of knees.^{9,10}

The description of the lateral retinaculum has been confusing because it is made up of condensations of tissue which merge together, and there have been different interpretations of these structures. In general, it is agreed that the deep fascia of the thigh passes over the patella and braces it. The iliotibial band is a derivative of the deep fascia and by its expansions contributes to the retinaculum. The fibres of the quadriceps apparatus contribute to the retinaculum either directly or through aponeurotic expansions and in its deeper layer there are transverse fibres which connect the underside of the iliotibial band to the patella. The sequence and exact arrangement of the layers and whether one is distinct from the next are contentious. The anatomical studies⁶⁻¹³ differ regarding the attachments of the bands and raise the following questions. Is the epicondylopatellar ligament equivalent to the lateral patellofemoral ligament? What are its attachments? Is it a distinct band and is it extracapsular or a thickening of the capsule? Similar considerations also apply to the meniscopatellar, patellotibial and patellomeniscal 'ligaments'. The dense transverse fibres are often referred to as a lateral patellofemoral ligament, but some of the literature suggests that they do not attach to the femur.^{7,10,11}

Our aims were to elucidate the anatomy of the lateral soft-tissue restraints of the patella, to identify tissue bands which were morphologically important for further biomechanical investigation and to represent the anatomy of the anterolateral aspect of the patellofemoral joint in a manner useful for surgeons.

Materials and Methods

We dissected 30 formalin-fixed knees and five fresh-frozen specimens. The fixed knees were provided by the Anatomy Department of Imperial College London at Charing Cross Hospital, London, United Kingdom. The fresh knees were obtained from a tissue bank (International Institute for the Advancement of Medicine, Jessup, Pennsylvania). The appropriate informed consent and approval of the Riverside Research Ethics Committee was obtained.

The skin and subcutaneous tissue were removed after identifying the deep fascia in the thigh from proximal to distal. Then, the deep fascial layer was incised longitudinally, beginning in the proximal thigh on the anterior midline proceeding distally in the midline over the patella. It was easily separated from the underlying muscle in the

anterior part of the thigh and usually also from the deeper tissue overlying the patella. In the region of the patella and tibial tuberosity, abnormal thickening of the underlying bursae may cause adherence of the layers. If the incision starts over the patella or distal to the knee more than one layer may be lifted when the fascial incision is extended. However, in most cases the tissue planes overlying the patella were more easily separated because of intervening bursae and the tissue was reflected laterally from the midline in layers. Blunt dissection was used as much as possible to avoid inadvertently entering a deeper plane, but in some areas cutting adherent tissue was necessary to display the anatomy. The tissue layers were dissected progressively until the interior of the lateral joint capsule was displayed.

Measurements were taken of the dimensions of the patellar and soft tissue using a ruler. Tangential photographs were taken with a ruler incorporated in the photograph to allow image analysis in order to verify measurements. We used the OsiriX medical imaging software version 2.3 (Digital Imaging Unit, University Hospital, Geneva, Switzerland) for this purpose.

Results

Deep fascia. The first layer deep to the skin and subcutaneous tissue was the deep fascia. The latter passed over the patella. It was not attached to the patella and was easily separated from it, provided that there was no abnormal thickening of the pre-patellar bursa. Laterally, the deep fascia thickened to form the iliotibial band in the lateral part of the thigh. The iliotibial band had a long posterior attachment to the linea aspera of the femur via the lateral intermuscular septum. Distally this femoral attachment terminated at the proximal part of the lateral condyle of the femur. On average, this anchorage was 8 mm (SD 7.1, -5 to 20) proximal to the level of the widest point of the patella measured when the knee was extended. Deep to the deep fascia in the thigh was the quadriceps muscle. Distally, as the muscle became the quadriceps tendon, there was an intervening layer, the quadriceps aponeurosis. The deep fascia was anchored to the quadriceps aponeurosis proximally. Lateral to the patella, and for a variable distance distally, the deep fascia was attached to the iliotibial band. The deep fascia was incised in the midline and reflected laterally (Figs 1 and 2).

The quadriceps aponeurosis and iliotibial band. Figures 1 and 2 show the reflected deep fascia held on its underside by a lateral extension of the quadriceps aponeurosis. The apex of this attachment was a mean of 28 mm (7 to 50) proximal to the proximal edge of the patella and in line with its lateral edge. The attachment of the deep fascia to the underlying quadriceps aponeurosis extended further laterally and distally from this apex. A surgeon approaching the lateral aspect of the knee in a subfascial approach from the midline should incise here to reflect the deep fascia further laterally. This attachment is just anterior to the point at which the deep fascia condenses to become

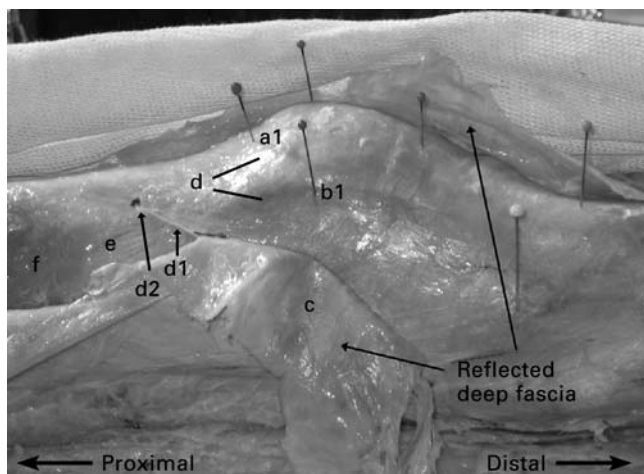


Fig. 1

Photograph of a lateral view of the deep area with the deep fascia reflected. The proximal (a1) and the lateral edges (b1) of the patella and the deep aspect (c) are seen. The quadriceps aponeurosis (d) overlies the quadriceps tendon and continues over the region of the patella and also alongside the lateral edge of the patella (arrows). The lateral extension of the quadriceps aponeurosis (d1) anchors the deep fascia (c) and the apex of this attachment (d2) is adherent to the quadriceps tendon. A portion of the quadriceps tendon (e) and vastus lateralis (f) can be seen.

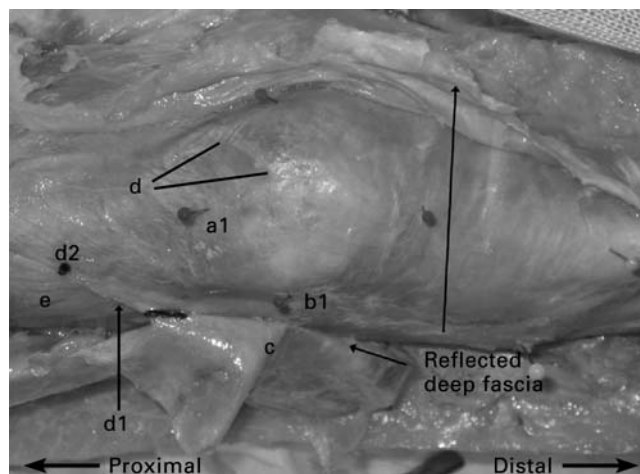


Fig. 2

Photograph of an anterior view of the deep area with the deep fascia reflected. The proximal (a1) and the lateral edges (b1) of the patella and the deep aspect (c) are seen. The quadriceps aponeurosis (d) overlies the quadriceps tendon and continues over the patella and also alongside its lateral edge. The lateral extension of the quadriceps aponeurosis (d1) anchors the deep fascia (c) and the apex of this attachment (d2) is adherent to the quadriceps tendon. A portion of the quadriceps tendon (e) can be seen.

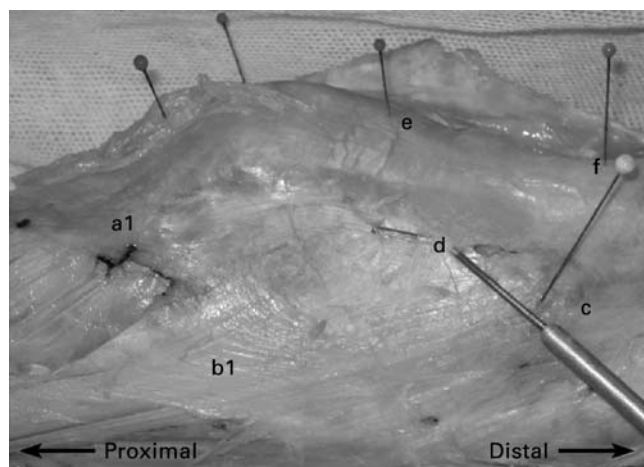


Fig. 3

Photograph of a lateral view of the iliotibial band and quadriceps aponeurosis. The quadriceps aponeurosis (a1) and iliotibial band (b1) converge. The main component of the iliotibial band is longitudinal and attaches to Gerdy's tubercle (c). The most superficial fibres of the iliotibial band (d) sweep obliquely over the deep iliotibial fibres and then the quadriceps aponeurosis overlying the patella and its tendon. In this specimen these superficial fibres of the iliotibial band are relatively thin and are lifted up with a probe. These arciform fibres pass superficial to the quadriceps aponeurosis and merge with it over the distal patella and the patellar tendon. Between the distal pole of the patella (e) and the tibial tuberosity (f) the underlying patellar tendon can be seen.




Fig. 4

Photograph of a lateral view of the iliotibial band and the quadriceps aponeurosis. The superficial fibres of the iliotibial band seen in Figure 3 have been removed. The descending fibres of the quadriceps aponeurosis (a1) and the iliotibial band (b1) converge. The main component of the iliotibial band attaches to Gerdy's tubercle (c). The more anterior fibres curve anteriorly (d) then descend slightly posteriorly (e) alongside the quadriceps aponeurosis becoming indistinguishable from it. The lateral edge of the patella is seen (f).

the iliotibial band and occurs where the posterior part of the quadriceps aponeurosis and the anterior part of the iliotibial band converge (Fig. 3).

The bulk of the fibres of the iliotibial band run in a longitudinal direction to Gerdy's tubercle.¹² The anterior fibres

curve anteriorly to meet the descending fibres of the quadriceps aponeurosis and then descend with the quadriceps aponeurosis, becoming indistinguishable from it. The fibres on the superficial surface of the iliotibial band proceed obliquely over the anterior fibres of the iliotibial band and

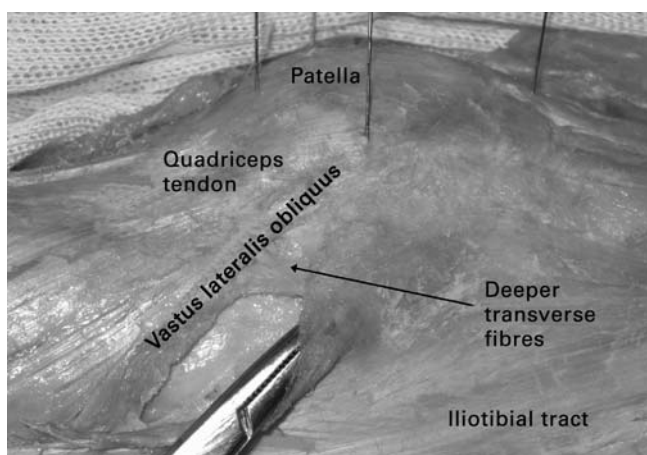


Fig. 5a




Fig. 5b

Photographs showing a) the tendon of vastus lateralis obliquus and b) the attachment of the deeper transverse fibres to it. The angular measurement of the tendon of vastus lateralis obliquus is demonstrated. The photograph is taken such that the medial and lateral patellar pins are in the line of sight. An angle is constructed with one limb perpendicular to this line and the other along the tendon of vastus lateralis obliquus as shown.

then the quadriceps aponeurosis, being firmly adherent to both. They extend anteriorly up to the distal patella and the patellar tendon where they fuse with the aponeurotic layer of quadriceps. This makes the quadriceps aponeurosis overlying the patellar tendon appear to have a more transverse orientation of its fibres. In Figure 3 a probe has been placed deep to these superficial fibres. In this specimen these fibres are thin and the underlying, more dense fibres are seen. Kaplan⁶ named these fibres which cross obliquely on to, and blending with, the fascia of the patella 'arciform fibres', although he attributed them as being the more anterior fibres of the iliotibial band. These fibres have also been functionally called the iliopatellar band,¹² which is likely to be analogous with the superficial oblique retinaculum.⁷

The convergence of the descending fibres of the quadriceps aponeurosis along the lateral edge of the patella and the iliotibial band is shown in Figures 3 and 4.

Vastus lateralis obliquus. A deep attachment between the underside of the iliotibial band and the tendon of vastus lateralis obliquus marks the proximal beginning of the deeper transverse fibres of the iliotibial band (Fig. 5). When the tendon could be followed all the way to the bony patella, as was the case in most knees, it was attached close to the most lateral edge of the patella, where the bone was widest. In other knees, anatomical variation of the distal attachment made it impossible to tell if or where this attachment to the patella took place. The angle of pull measured relative to the longitudinal axis of the patella was a mean of 38° (20° to 60°) posterior (Fig. 5b). The higher this angle, the greater the posterolateral force vector acting on the patella.

Deeper transverse fibres of the iliotibial band. These were not a distinctly separate layer. The proximal edge of this band was located easily by finding its attachment between the postero-

lateral edge of vastus lateralis obliquus and the deep aspect of the iliotibial band. In order to uncover it further distally, the longitudinal overlying fibres were removed by sharp dissection. To identify its distal extent, the longitudinal fibres of the iliotibial band were split apart just proximal and anterior to Gerdy's tubercle. This split was continued proximally until resistance was met when the deeper transverse fibres were encountered (Fig. 6).

The width of this band of deep transverse fibres was measured proximally to distally from the point at which it met the oblique tendon and in line with the tangent of the mediolateral patellar axis. The mean width was 37 mm (18 to 52). The proximal edge where it met vastus lateralis obliquus was located a mean of 20 mm (12 to 31) lateral to, and 20 mm (7 to 32) proximal to the most lateral point of the patella. The deep transverse fibres of the iliotibial band connected to the patella and vastus lateralis obliquus. They were not attached to the lateral epicondyle of the femur.

Lateral patellofemoral and patellomeniscal ligaments. The joint capsule was thickened laterally to form the lateral patellofemoral ligament. This capsular thickening was variable from knee to knee and the margins were difficult to define exactly. The lateral patellofemoral ligament was attached to the lateral patella at its widest part and anchored to the lateral femoral epicondyle (Fig. 7). Similarly, a condensation of capsule connecting the inferolateral part of the patella to the anterolateral aspect of the lateral meniscus was identified, but again it was difficult to measure its dimensions. This has been termed the meniscopatellar^{6,10} or patellomeniscal ligament.¹¹ These capsular ligaments vary considerably and are not always found.^{6,9,10}

Patellotibial ligament. There have been different interpretations of the patellotibial ligament/band.^{7,8,11,13} It has been

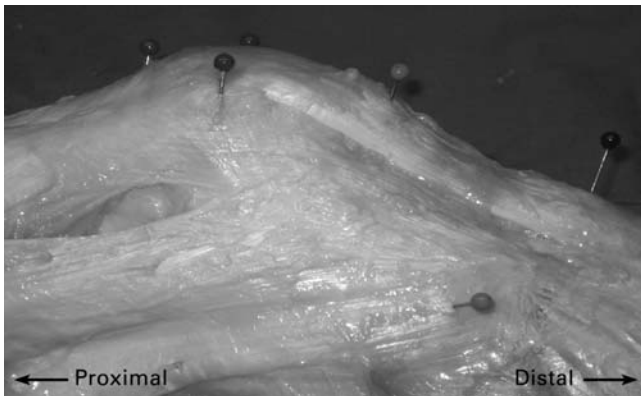


Fig. 6a

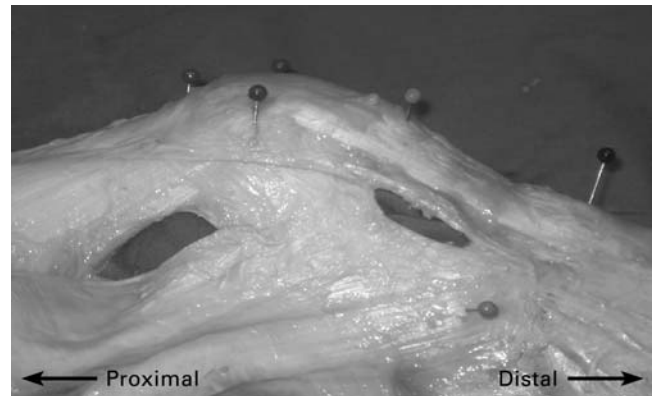


Fig. 6b

Photographs showing the deep transverse fibres of the iliotibial band (iliotibial band-patella). a) The superficial longitudinal fibres are split and detached to reveal b) the underlying deeper fibres. These are transverse in orientation and attach the iliotibial band to the tendon of the vastus lateralis obliquus proximally and the lateral edge of the patella distally.

described as being the same as the quadriceps aponeurosis layer.¹¹ Our findings agree with that description. The longitudinal fibres of the quadriceps aponeurosis descended distally alongside the lateral border of the patella and the patellar tendon. They were attached to the lateral tibial condyle between the tibial tuberosity and Gerdy's tubercle. This layer also fused anteriorly with the deeper joint capsule, adjacent to and along the length of the patellar tendon.

Lateral superior genicular artery. This arose from the popliteal artery posteriorly. It coursed anteriorly towards the patella between the capsule and the iliotibial band. It remained deep to the iliotibial band and was closely applied to the deep part of the deeper transverse fibres. It issued capsular branches distally and an oblique branch which coursed over the superficial aspect of the distal part of vastus lateralis obliquus (Fig. 8). As the main artery approached the patella, its relationship with the end of the oblique tendon of vastus lateralis was variable. However, further anteriorly, after crossing the edge of the patella, the artery always remained in the plane deep to the quadriceps aponeurosis and the continuation of the quadriceps tendon overlying the patella. The artery drifted proximally as it went further anteriorly towards the proximal pole of the patella, where it then continued to the medial side and met a longitudinal branch approximately in the midline of the patella.

The quadriceps aponeurosis was easily separated from the quadriceps tendon in the prepatellar region, but further laterally around the edge of the patella it became adherent to deeper tissues as it interacted with the anterior fibres of the iliotibial band. The surgeon who wishes to protect the genicular artery during an outside-in lateral retinacular release can most easily localise it by beginning in the region overlying the patella, deep to the quadriceps aponeurosis, and then following the vessel laterally past the lateral edge

of the patella towards the area for tissue release. The quadriceps aponeurosis was thin overlying the patella, so that the vessel was visible through this layer, once the more superficial deep fascia had been reflected. The artery could then be located more easily than if the exploration had started laterally where the tissue was more dense and adherent.

The position of the artery at the lateral border of the patella was measured. The most lateral point of the patella corresponded to the proximodistal equator of the articular surface and this was visualised by accessing the joint from the medial side. The proximal distance from this equator to the vessel at the lateral border of the patella was measured. As the artery crossed the lateral edge of the patella it was a mean of 10 mm (0 to 16) proximal to the proximodistal equator of the articular surface of the patella. When releasing the lateral retinaculum arthroscopically from within the joint, caution must be exercised when the release crosses proximally beyond the proximodistal equator of the articular surface.

Discussion

The tissues which restrain the patella from its lateral aspect have been shown to include the deep fascia in the most superficial layer, the quadriceps aponeurosis and iliotibial band in the intermediate layer and the joint capsule in the deepest layer. The description of these may help to reconcile some of the differences found in the literature. In particular, the use of photographs rather than schematic diagrams or artists' impressions may be more realistic. Our study has included measurements to allow specific features to be located.

The deep fascia is not attached to the patella but is adherent to deeper tissues laterally, thus acting as a brace. The longitudinal fibres of the iliotibial band merge with those of the quadriceps aponeurosis lateral and adjacent to the

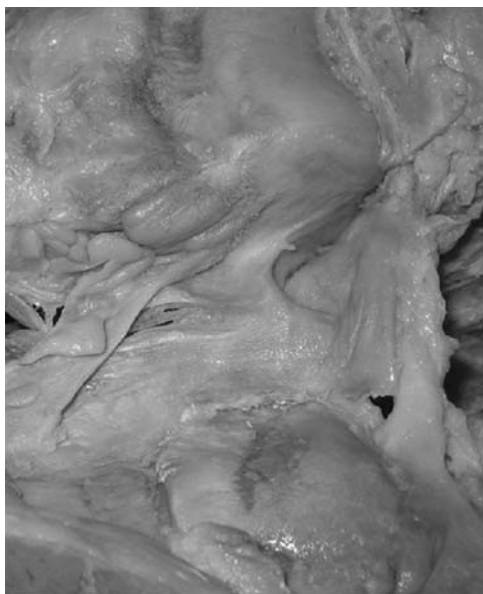

Fig. 7a

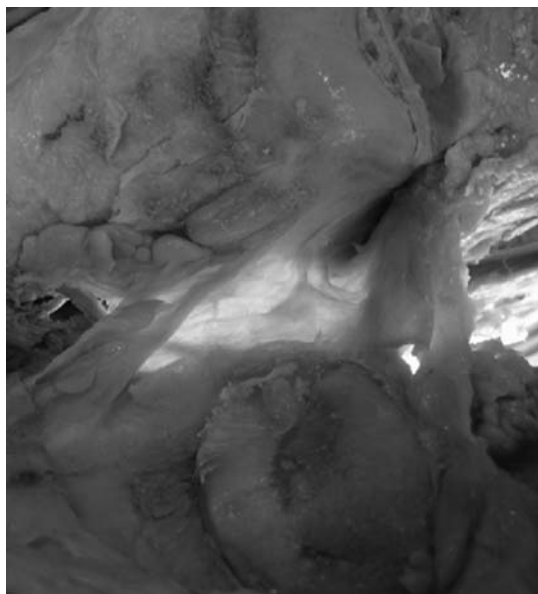


Fig. 7b

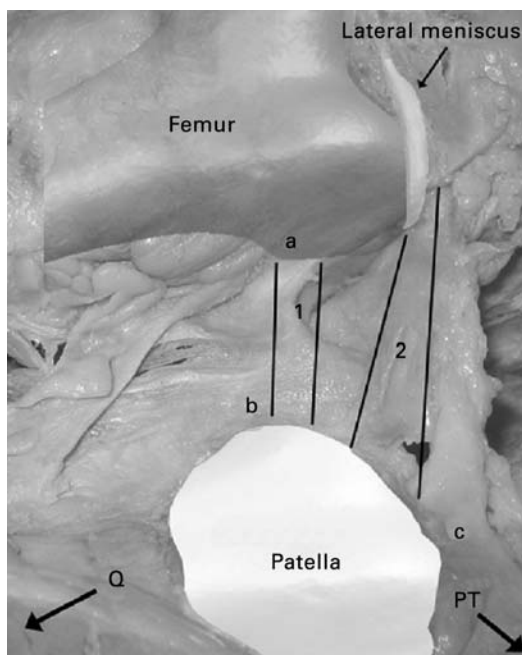


Fig. 7c

Photographs showing the lateral patellofemoral and patellomeniscal ligaments. a) The right knee is opened medially and the patella is everted to view the lateral capsule from within and b) with a light source placed to transilluminate the capsule. Thickenings of the capsule form these ligaments. c) The same photograph as in a) and b) with an overlay of a graphical model of the femur and meniscus for orientation (a, lateral femoral epicondyle; b, lateral edge of everted patella; and c, for the distal pole of the patella; Q, quadriceps; PT, patellar tendon; 1, lateral patellofemoral ligament; and 2, patellomeniscal ligament).

patella, forming an intermediate layer. This longitudinal retinaculum is adherent to the patella, the quadriceps tendon proximal to the patella and the joint capsule adjacent to the patellar tendon distal to the patella. These longitudinal fibres are reinforced by the transverse retinaculum which consists of superficial fibres of the iliotibial band, the iliopatellar or arciform fibres and the deeper transverse fibres of the iliotibial band. The superficial fibres cross obliquely over and adhere to the quadriceps aponeurosis overlying the patella and its tendon. The most substantial

structure consists of the deeper transverse fibres which are dense and anchor the lateral edge of the patella and the tendon of vastus lateralis obliquus to the iliotibial band. These should be termed the iliotibial band-patella fibres. They are not a distinctly separate layer, but adhere to the deep aspect of the iliotibial band.

The location, bulk and orientation of the iliotibial band-patella fibres suggest that they may play an important role in the lateral restraint of the patellofemoral joint. However, these transverse fibres lack a direct connection to the femur,

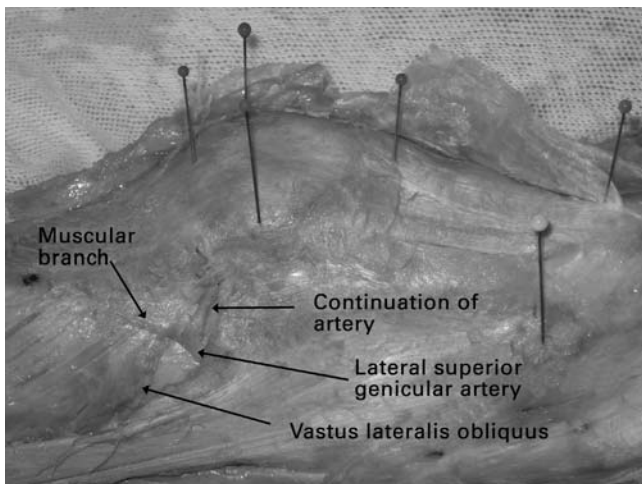


Fig. 8

Photograph showing the lateral superior genicular artery. The quadriceps aponeurosis overlying the patella, the quadriceps tendon and the patellar tendon have been removed. The lateral superior genicular artery courses anteriorly from the underside of the iliotibial band towards the patella. It has an oblique branch which passes over vastus lateralis. Vastus lateralis obliquus is shown arising from the lateral intermuscular septum.

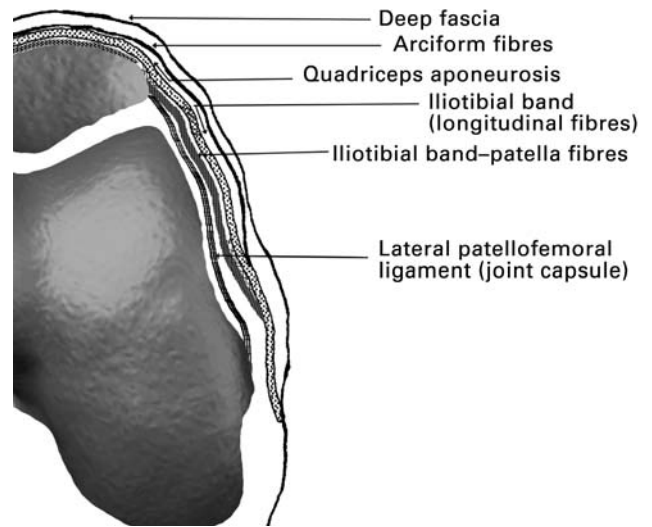


Fig. 9

A cross-sectional diagram illustrating the components of the lateral retinaculum of the knee at the level of the lateral femoral epicondyle.

unlike the lateral patellofemoral ligament, which by virtue of the capsular attachment of the femur fixes the ligament at the lateral epicondyle. Unlike the lateral patellofemoral ligament, however, the transverse fibres are more prominent and are consistently found. Moreover, the part of the iliotibial band to which the deeper transverse band is attached is relatively fixed in a longitudinal direction as a short segment. Proximally, it is anchored to the proximal aspect of the femoral condyle at a mean of 8 mm (SD 7.1) proximal to the widest part of the patella and distally to Gerdy's tubercle of the tibia. In view of its longitudinal orientation, tension in the iliotibial band would not be thought to affect patellofemoral tracking. However, when the bony fixation mentioned above and the transverse fibres are taken into account, it is likely that tension in the iliotibial band plays a role in the function of the lateral retinaculum. Two clinical studies have described an association between a tight iliotibial band and patellar maltracking.^{14,15} A biomechanical study showed that with loading of the iliotibial band the patella translated laterally in most angles of flexion, shifting the area of patellofemoral contact laterally.¹⁶

Our study has shown three new findings:

1) A connection of the deep fascia to the quadriceps tendon proximal and lateral to the patella through the lateral extension of the quadriceps aponeurosis (Figs 3 and 4); 2) the connection of the deeper transverse fibres to the tendon of vastus lateralis obliquus (Fig. 5); and 3) the intimate relationship between the quadriceps aponeurosis and the iliotibial band with the convergence of the longitudinal fibres of both structures and the fusion of the iliopatellar fibres of the iliotibial band to the quadriceps aponeurosis overlying the patella and its tendon.

The first finding indicates that the deep fascia has an anchorage which should make it more effective as a brace for the patella. This connection is always present and it is a useful landmark for the surgeon to incise, localise vastus lateralis obliquus and then access the deeper transverse fibres of the iliotibial band. This lateral extension of the quadriceps aponeurosis anchors the deep fascia close to the point at which it thickens to form the iliotibial band and thus, proximally to distally, is the beginning of the interaction of the quadriceps aponeurosis and the iliotibial band.

The connection of the deeper transverse fibres to the tendon of vastus lateralis obliquus is reminiscent of the interaction of the medial patellofemoral ligament with vastus medialis obliquus.^{1,3} In addition to the direct attachment of the deeper transverse fibres to the patella, this connection affords an additional retinacular action by ensuring a lateral/posterior pull of the tendon. Vastus lateralis obliquus was found to pull a mean of 38° (20° to 60°) posteriorly in our study; it had previously been noted to be 35° lateral and 33° posterior to the femoral axis.¹⁷

The lateral retinaculum is thus a complex structure which is difficult to delineate because of converging and interdigitating structures. It is principally an interaction of tissue interconnections from the iliotibial band and the components of the quadriceps apparatus acting on the patella. They are composed of longitudinal fibres reinforced by horizontal fibres. There are also deeper capsular structures which link the patella to the lateral femoral epicondyle and the lateral meniscus, but these are less substantial. We did not find an extracapsular band linking the patella to the lateral epicondyle.

In order to standardise descriptive terminology, the following scheme is suggested. The lateral retinacular complex of the knee is subdivided into superficial, intermediate and deep layers (Fig. 9). These components consist of derivatives of fascia, the quadriceps apparatus and the capsule. The deeper, more transverse fibres from the iliotibial band may be termed the iliotibial band-patella fibres; they are not lateral patellofemoral fibres.

We thank Professor P. Aichroth for his invaluable advice, support and suggestions. We also thank Professor J. A. Firth and the Human Anatomy Unit, Charing Cross Hospital, Imperial College London.

A. M. Merican was supported by the University of Malaya, the Government of Malaysia and by a project grant from the Arthritis Research Campaign.

No benefits in any form have been received or will be received from a commercial party related directly or indirectly to the subject of this article.

References

1. Amis AA, Firer P, Mountney J, Senavongse W, Thomas NP. Anatomy and biomechanics of the medial patellofemoral ligament. *Knee* 2003;10:215-20.
2. Nomura E, Inoue M, Osada N. Anatomical analysis of the medial patellofemoral ligament of the knee, especially the femoral attachment. *Knee Surg Sports Traumatol Arthrosc* 2005;13:510-15.
3. Panagiotopoulos E, Strzelczyk P, Herrmann M, Scuderi G. Cadaveric study on static medial patellar stabilizers: the dynamizing role of the vastus medialis obliquus on medial patellofemoral ligament. *Knee Surg Sports Traumatol Arthrosc* 2006;14:7-12.
4. Smirk C, Morris H. The anatomy and reconstruction of the medial patellofemoral ligament. *Knee* 2003;10:221-7.
5. Tuxøe J, Teir M, Winge S, Nielsen PL. The medial patellofemoral ligament: a dissection study. *Knee Surg Sports Traumatol Arthrosc* 2002;10:138-40.
6. Kaplan EB. Surgical approach to the lateral (peroneal) side of the knee joint. *Surg Gynecol Obstet* 1957;104:346-56.
7. Fulkerson JP, Gossling HR. Anatomy of the knee joint lateral retinaculum. *Clin Orthop* 1980;53:183-8.
8. Kaplan EB. Some aspects of functional anatomy of the human knee joint. *Clin Orthop* 1962;23:18-29.
9. Reider B, Marshall JL, Koslin B, Ring B, Girgis FG. The anterior aspect of the knee joint. *J Bone Joint Surg [Am]* 1981;63-A:351-6.
10. Blauth M, Tillmann B. Stressing on the human femoro-patellar joint. I: components of a vertical and horizontal tensile bracing system. *Anat Embryol (Berl)* 1983;168:117-23.
11. Dye SF. Patellofemoral anatomy. In: Fox IM, Del Pizzo W, eds. *The patellofemoral joint*. New York: McGraw-Hill Inc., 1993:3-6.
12. Terry GC, Hughston JC, Norwood LA. The anatomy of the iliopatellar band and iliotibial tract. *Am Sports Med* 1986;14:39-45.
13. Seebacher JR, Inglis AE, Marshall JL, Warren RF. The structure of the posterolateral aspect of the knee. *J Bone Joint Surg [Am]* 1982;64-A:536-41.
14. Puniello MS. Iliotibial band tightness and medial patellar glide in patients with patellofemoral dysfunction. *J Orthop Sports Phys Ther* 1993;17:144-8.
15. Wu CC, Shih CH. The influence of iliotibial tract on patellar tracking. *Orthopedics* 2004;27:199-203.
16. Kwak SD, Ahmad CS, Gardner TR. Hamstrings and iliotibial band forces affect knee kinematics and contact pattern. *J Orthop Res* 2000;18:101-8.
17. Farahmand F, Senavongse W, Amis AA. Quantitative study of the quadriceps muscles and trochlear groove geometry related to instability of the patellofemoral joint. *J Orthop Res* 1998;16:136-43.