

## Iliac aneurysm associated with arteriovenous fistula

Daniel Mendes Pinto<sup>1</sup>; Leonardo Ghizoni Bez<sup>1</sup>; José Olímpio Dias Júnior<sup>1,1</sup>; Caetano de Sousa Lopes<sup>1</sup>; Ari Mandil<sup>1,1</sup>

<sup>1</sup>Vascular surgeons, Hospital Felício Rocho, Belo Horizonte, MG, Brazil.

<sup>1,1</sup>Cardiologist and vascular ultrasonography, Belo Horizonte, MG, Brazil.

<sup>1,1</sup>Interventionist cardiologist, Hospital Felício Rocho, Belo Horizonte, MG, Brazil.

### Correspondence

J Vasc Bras. 2007;6(3):297-300.

---

### ABSTRACT

Rupture of aortoiliac aneurysms into the iliac vein or vena cava is an uncommon complication. Many signs and symptoms develop as a result of venous hypertension, which makes preoperative diagnosis difficult, such as leg edema, dyspnea, hematuria, signs of renal or cardiac insufficiency. Abdominal bruit, associated with pulsatile mass and abdominal pain, is the key for clinical diagnosis. Preoperative recognition of arteriovenous fistula is important for surgical planning. We report a case of right internal and common iliac artery aneurysm associated with fistula into the common iliac vein. Initial symptoms were right leg edema and dyspnea, which induced to the incorrect diagnosis of deep vein thrombosis.

Keywords: Iliac aneurysm, arteriovenous fistula, ruptured aneurysm.

---

### RESUMO

A ruptura dos aneurismas aorto-iliacos para a veia ilíaca ou veia cava é uma complicação pouco comum. A hipertensão venosa leva a vários sinais e sintomas, o que dificulta o diagnóstico pré-operatório, tais como edema do membro inferior, dispnéia, hematúria, sinais de insuficiência renal ou cardíaca. Sopro abdominal é a chave do diagnóstico clínico, associado à massa pulsátil e dor abdominal. O reconhecimento da fistula arteriovenosa no pré-operatório é importante para o planejamento cirúrgico. Relatamos um caso de aneurisma da artéria ilíaca comum e interna direita associado a fístula para veia ilíaca comum, cursando, inicialmente, com edema do membro inferior direito e dispnéia, o que levou ao diagnóstico incorreto de trombose venosa profunda.

Palavras-chave: Aneurisma ilíaco, fístula arteriovenosa, aneurisma roto.

---

## Introduction

Spontaneous rupture of aortoiliac aneurysms into iliac veins or vena cava is a rare complication, found in less than 1% of cases submitted to surgery.<sup>1,2</sup> We report a case of common iliac and right internal artery aneurysm with fistula into the common iliac vein, whose initial presentation was right lower limb (RLL) edema and dyspnea, causing diagnostic confusion with deep venous thrombosis and pulmonary embolism.

## Case report

A 75-year-old patient had sudden edema of the right lower limb (RLL) and dyspnea. Although Doppler ultrasound did not reveal signs of venous thrombosis, anticoagulation therapy was started, due to suspicion of pulmonary embolism. During outpatient control, abdominal murmur and thrill and absence of right femoral pulse were diagnosed. An abdominal ultrasound showed right iliac artery aneurysm measuring 8 cm in diameter, when the patient was then referred to a vascular surgeon.

Oral anticoagulants were suspended, and abdominal angiographic tomography showed right common and internal iliac artery aneurysm and simultaneous contrast of the inferior vena cava (Figure 1). An arterial Doppler examination of the RLL revealed reverse diastolic flow of large amplitude and distal flow with reduced systolic velocities. Due to a wide communication between the aneurysm and the venous system, abdominal arteriography did not reveal the fistula site adequately.

During surgical exploration, communication between the common iliac artery and the common iliac vein was identified. Bleeding was controlled with digital compression of the fistula and its direct repair, with reconstruction using bifurcated Dacron graft (Figure 2). Blood loss was calculated in 2,800 mL.

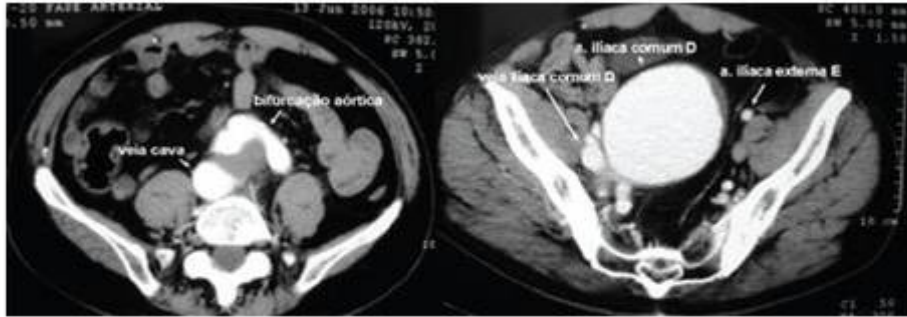


Figure 1 - Angiographic tomography showing vena cava contrast and image of the common iliac artery aneurysm

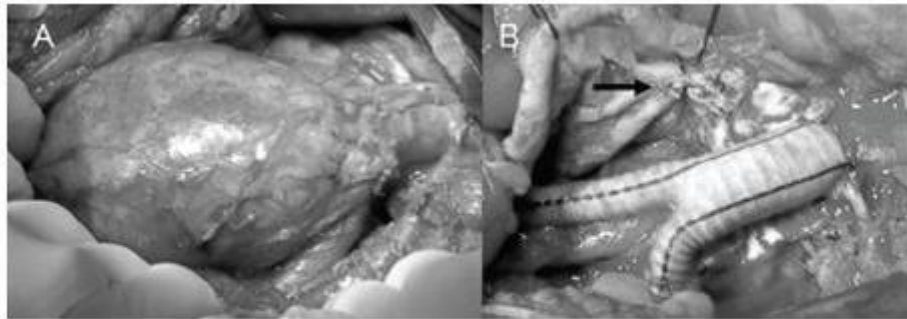


Figure 2 - A) Right common iliac artery aneurysm; B) repair using bifurcated graft (black arrow indicates the site of suture of the fistula with the iliac vein)

There were no postoperative complications. Six months later, the patient had no dyspnea and presented palpable tibial pulses.

## Discussion

The arteriovenous fistula (AVF) that occurs with aortoiliac aneurysms is a clinical entity described in series of cases in the literature, with incidence between 0.2 and 2.22% in all infrarenal aneurysms submitted to surgery,<sup>3</sup> and may reach 6% among ruptured aneurysms.<sup>2</sup> Besides atherosclerotic aneurysms, which represent the majority, other causes are syphilitic, mycotic aneurysms secondary to Marfan's syndrome, Ehlers-Danlos syndrome, Takayasu arteritis,<sup>4-7</sup> after surgery for herniated lumbar disc<sup>8</sup> and secondary to abdominal penetrating or, more rarely, blunt traumas.<sup>9,10</sup>

Many series including a small number of cases report diagnostic difficulty. Communications between the aorta and vena cava account for most cases. Few approach ilio-iliac fistulas.<sup>11</sup> Davis et al.<sup>12</sup> reported only five cases of ilio-iliac fistulas along 18 cases submitted to surgery for 27 years. In a review article, Bonamigo described the importance of diagnosing AVF associated with aneurysm and mentioned two cases treated with presence of rupture.<sup>13</sup>

Clinical presentation ranges according to fistula size and location and the patient's cardiopulmonary

function. In a recent review of 12 cases of independent iliac aneurysms, Carvalho et al. reported that 83% had unspecific abdominal pain.<sup>14</sup> The classical diagnostic triad of aneurysm associated with AVF is abdominal pain, pulsatile mass and abdominal murmur. Abdominal murmur is the most common sign, but it can be missing due to presence of thrombi in the aneurysmal sac next to the fistula.<sup>15</sup>

Congestive cardiac insufficiency is described between 11.5 and 28% of cases.<sup>16</sup> Increased venous pressure and compression of adjacent veins lead to lower limb edema. As a consequence of venous hypertension, there may be hematuria, renal insufficiency, scrotal edema and rectal bleeding.<sup>17</sup>

Rupture of aortic aneurysm into the vena cava has clear symptoms of abdominal pain, which leads to a fast surgical treatment. On the other hand, ruptured iliac aneurysms into the iliac-caval system has fewer symptoms; it is common for patients to remain weeks or months without being diagnosed until surgery.<sup>16</sup>

In the present case, the patient remained for 7 weeks without a definitive diagnosis of AVF. Initial event was RLL edema with dyspnea. Episodes of dyspnea probably resulted from a temporary cardiac decompensation after physical efforts. After the surgery, episodes of dyspnea were discontinued.

Diagnosis was confirmed by imaging examinations performed to investigate the aneurysm, especially angiographic tomography of the abdomen. Contrast can be seen in the iliac veins or vena cava in the arterial stage (Figure 1). Angiographic tomography can sometimes reveal the fistula site, but usually this information is obtained from arteriography.<sup>18</sup>

Identifying aortocaval fistula before surgery is extremely important for surgical approach. Preoperative diagnosis ranges between 17-70% (mean of 34%) among published series.<sup>12</sup> Perioperative mortality is higher when AVF is not diagnosed.<sup>16</sup> Of the five deaths reported by Cinara et al. (19.5% of cases), any had previous diagnosis of the fistula.<sup>11</sup> Those authors focus on the fact that aneurysm rupture into the vena cava or iliac vein has lower mortality than retroperitoneal, intraperitoneal rupture or into intestinal loops, when diagnosed before the surgery.

Usual treatment is direct suture of the fistula, after opening of the aneurysmal sac, followed by aortoiliac reconstruction. There are reports of ligation in the common iliac vein. Other less common options are use of graft patch and vena cava clipping.<sup>10,12</sup>

There are few reports of stent-grafts used in the treatment of aortocaval fistulas. Nine cases of endovascular treatment for atherosclerotic aneurysms associated with AVF have been published.<sup>19,20</sup> AVF can complicate endovascular treatment of aneurysms due to (1) dissection of the common femoral artery is difficult due to dilated superficial veins with increased flow; and (2) high AVF flow, which makes visualization of renal arteries difficult.<sup>21</sup> A hemodynamic alteration described by Lau et al. was sudden increase of peripheral vascular resistance, caused by abrupt fall of cardiac output after AVF occlusion with stent-graft release.<sup>22</sup> This leads to hard-to-control hypertension. Such change is not common in open surgery due to aortic clamping and bleeding.

In conclusion, despite the low frequency of AVF in aortoiliac aneurysms, a careful physical examination should raise clinical suspicion. Abdominal murmur is the most common sign, sometimes associated with pain and abdominal mass palpation. Identifying the fistula before the surgery is crucial for surgical planning and reduction in mortality.

## References

1. Baker WH, Sharzer LA, Ehrenhaft JL. [Aortocaval fistula as a complication of abdominal aortic aneurysms](#). Surgery. 1972;72:933-8.
2. Schmidt R, Bruns C, Walter M, Erasmi H. [Aorto-caval fistula--an uncommon complication of infrarenal aortic aneurysms](#). Thorac Cardiovasc Surg. 1994;42:208-11.
3. Miani S, Giorgetti PL, Arpesani A, Giuffrida GF, Biasi GM, Ruberti U. [Spontaneous aorto-caval fistulas from ruptured abdominal aortic aneurysms](#). Eur J Vasc Surg. 1994;8:36-4.
4. Davidovic LB, Kostic DM, Cvetkovic SD, et al. Aorto-caval fistulas. Cardiovasc Surg. 2002;10:555-60.
5. Hardin CA. [Ruptured abdominal aneurysm occurring in Marfan's syndrome: attempted repair with the use of a nylon prosthesis](#). N Engl J Med. 1959;260:821-2.
6. Lynch HT, Larsen AL, Wilson R, Magnuson CL. [Ehlers-Danlos syndrome and "congenital" arteriovenous fistulae: a clinicopathologic study of a family](#). JAMA. 1965;194:1011-4.
7. Gronemeyer PS, de Mello DE. [Takayasu's disease with aneurysm of right common iliac artery and ilio-caval fistula in a young infant: case report and review of the literature](#). Pediatrics. 1982;69:626-31.
8. Jarstfer BS, Rich NM. [The challenge of arteriovenous formation following disk surgery: a collective review](#). J Trauma. 1976;16:726-33.
9. Machiedo GW, Jain KM, Swan KG, Petrocelli JC, Blackwood JM. [Traumatic aorto-caval fistula](#). J Trauma. 1983;23:243-7.
10. Mattox KL, Whisennand HH, Espada R, Beall AC. [Management of acute combined injuries to the aorta and inferior vena cava](#). Am J Surg. 1975;130:720-4.
11. Cinara IS, Davidovic LB, Kostic DM, Cvetokvic SD, Jakovljevic NS, Koncar IB. [Aorto-caval fistulas: a review of eighteen years experience](#). Acta Chir Belg. 2005;105:616-20.
12. Davis PM, Gloviczki P, Cherry KJ, et al. [Aorto-caval and ilio-iliac arteriovenous fistulae](#). Am J Surg. 1998;176:115-8.
13. Bonamigo T, Siliprandi LR. Diagnóstico do aneurisma da aorta abdominal. Rev Med Santa Casa, Porto Alegre. 1990;1:186-93.
14. Carvalho ATY, Prado V, Neto HJG, Caffaro RA. [Aspectos cirúrgicos dos aneurismas isolados das artérias ilíacas](#). J Vasc Bras. 2006;5:203-8.
15. Weinbaum FI, Riles TS, Imparato AM. [Asymptomatic vena cava fistulization complicating abdominal aortic aneurysm](#). Surgery. 1984;96:126-8.
16. Brewster DC, Cambria RP, Moncure AC, et al. [Aortocaval and iliac arteriovenous fistulas: recognition and treatment](#). J Vasc Surg. 1991;13:253-64; discussion 264-5.

17. Brewster DC, Ottinger LW, Darling RC. [Hematuria as a sign of aorto-caval fistula](#). Ann Surg. 1977;186:766-71.
18. Adili F, Balzer JO, Ritter RG, et al. [Ruptured abdominal aortic aneurysm with aorto-caval fistula](#). J Vasc Surg. 2004;40:582.
19. Williamson AE, Annunziata G, Cone LA, Smith J. [Endovascular repair of a ruptured abdominal aortic and iliac artery aneurysm with an acute ilio caval fistula secondary to lymphoma](#). Ann Vasc Surg. 2002;16:145-9.
20. Vetrhus M, McWilliams R, Tan CK, Brennan J, Gilling-Smith G, Harris PL. [Endovascular repair of abdominal aortic aneurysms with aortocaval fistula](#). Eur J Vasc Endovasc Surg. 2005;30:640-3.
21. Umscheid T, Stelter WJ. [Endovascular treatment of an aortic aneurysm ruptured into the inferior vena cava](#). J Endovasc Ther. 2000;7:31-5.
22. Lau LL, O'reilly MJ, Johnston LC, Lee B. [Endovascular stent-graft repair of primary aortocaval fistula with an abdominal aortoiliac aneurysm](#). J Vasc Surg. 2001;33:425-8.

 Correspondence:

Daniel Mendes Pinto

Av. do Contorno, 9495/01

CEP 30110-130 – Belo Horizonte, MG, Brazil

Email: [dmpnet@terra.com.br](mailto:dmpnet@terra.com.br)

Manuscript received June 19, 2007, accepted June 28, 2007.